



Bőrpatológiai
Metszetszeminárium
2013. szeptember 27.

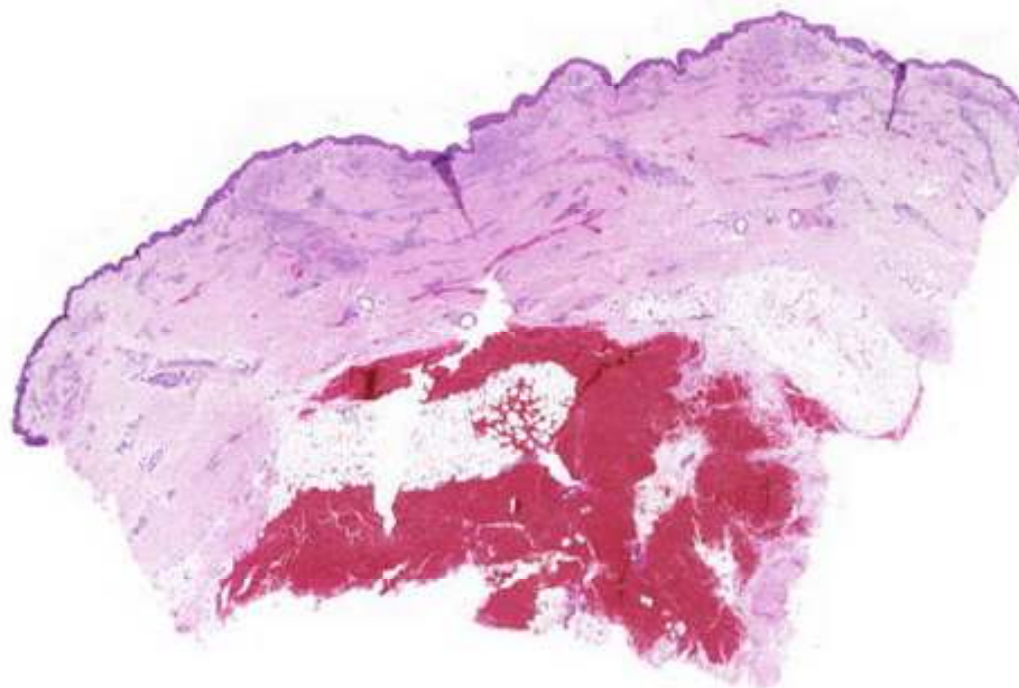
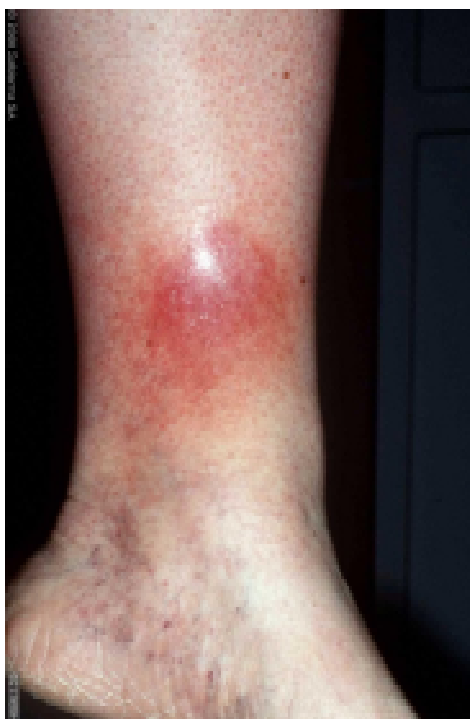20. eset
Bemutatja:
Sápi Zoltán

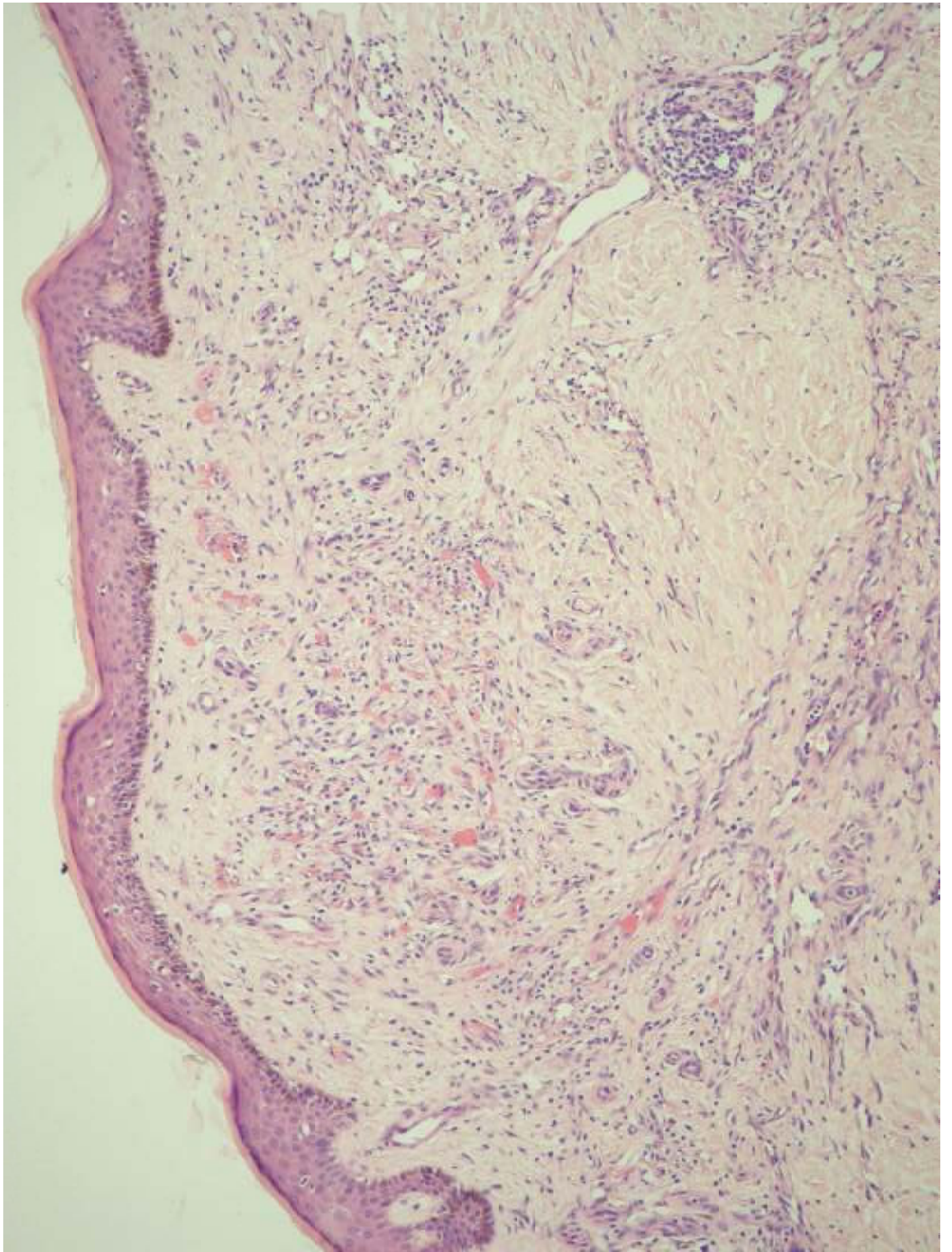


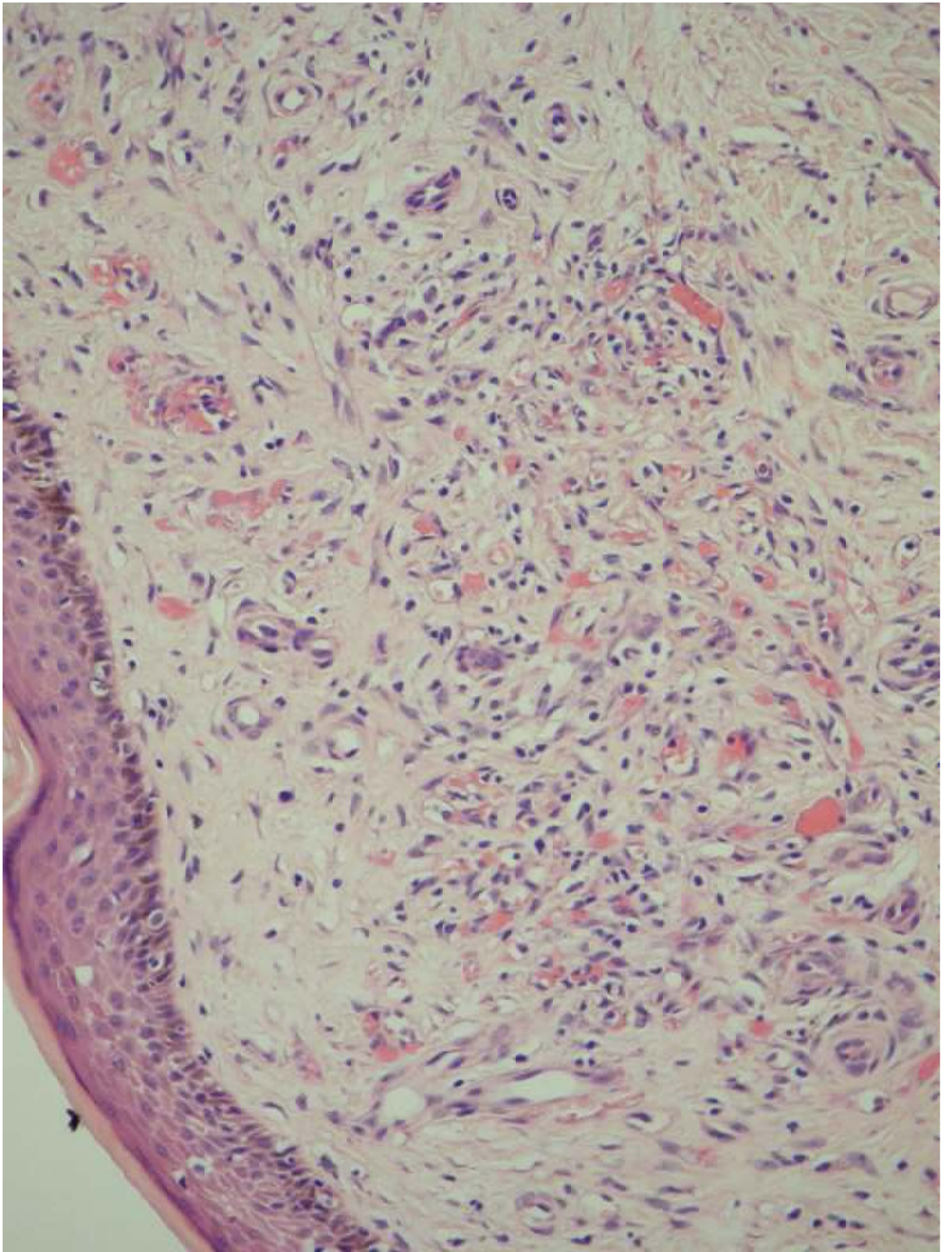
Sápi Zoltán
SE I. Sz. Patológiai és
Kísérleti Rákkutató Intézet

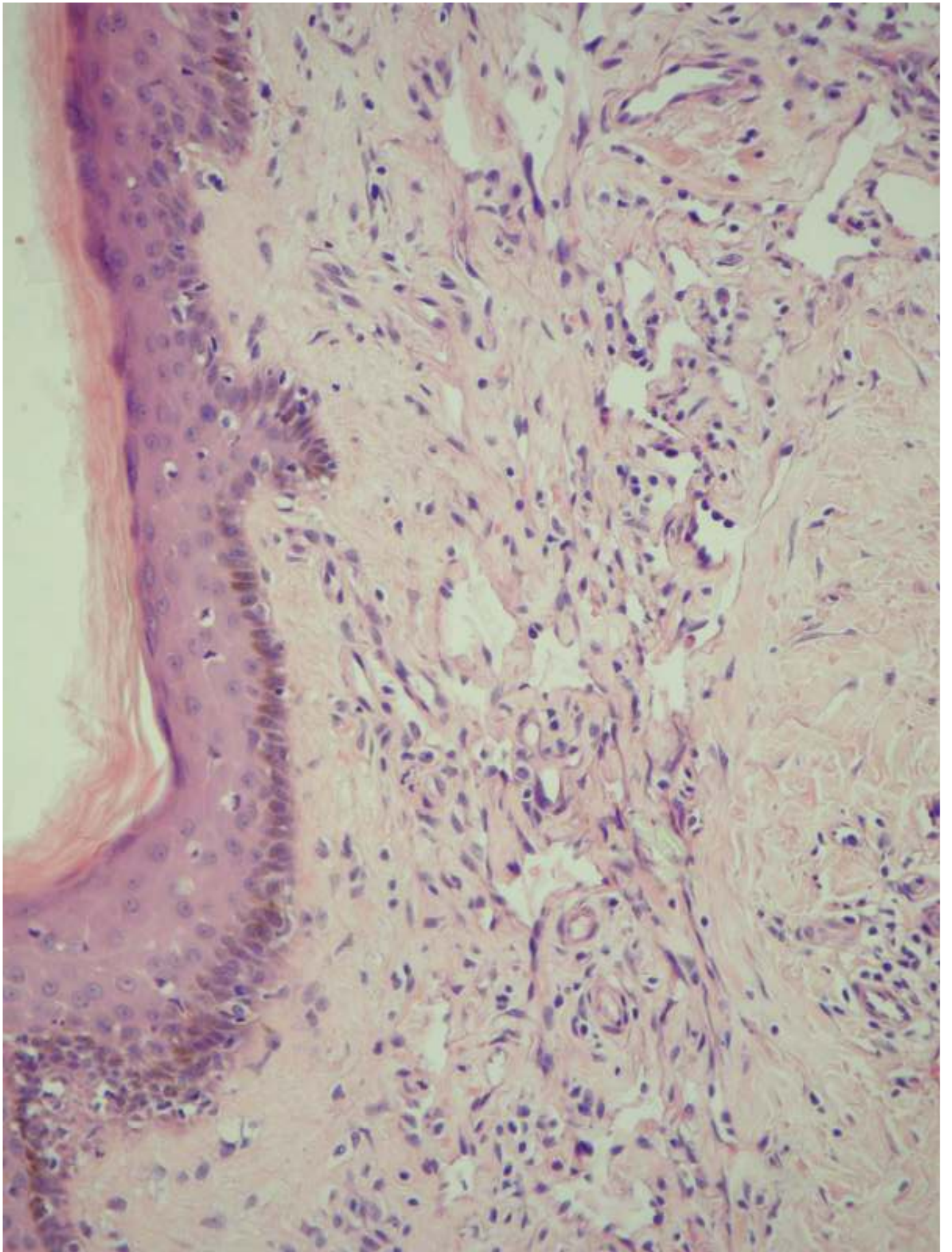


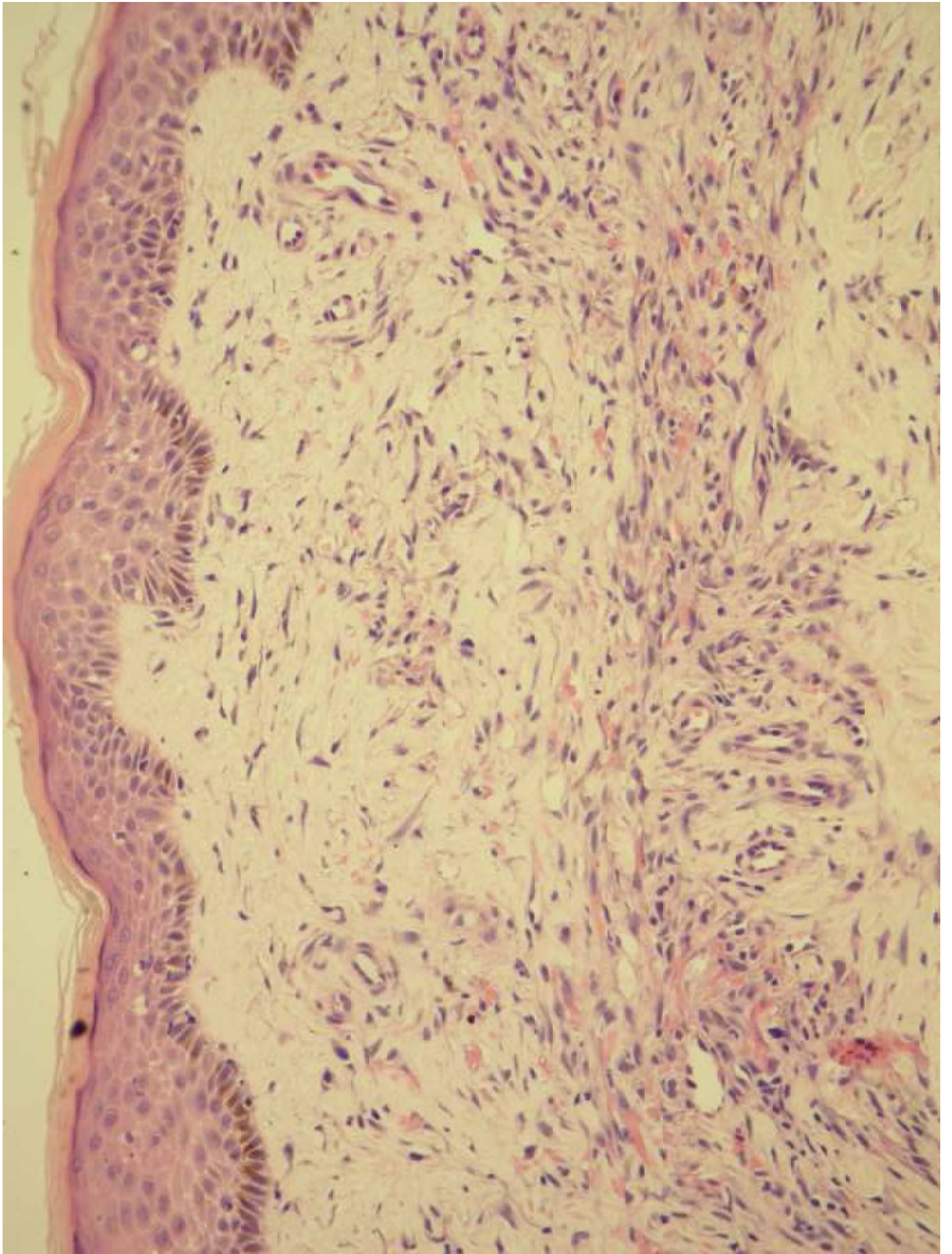
72 éves férfi. Korábban a jobb lábszárról kimetszett terime.
Szövetteni diagnózis: Stasis melletti reaktív érproliferáció.
A korábbi elváltozás melletti újabb biopszia.
Klinikai diagnózis: Reaktív érproliferáció, Kaposi sarcoma.?

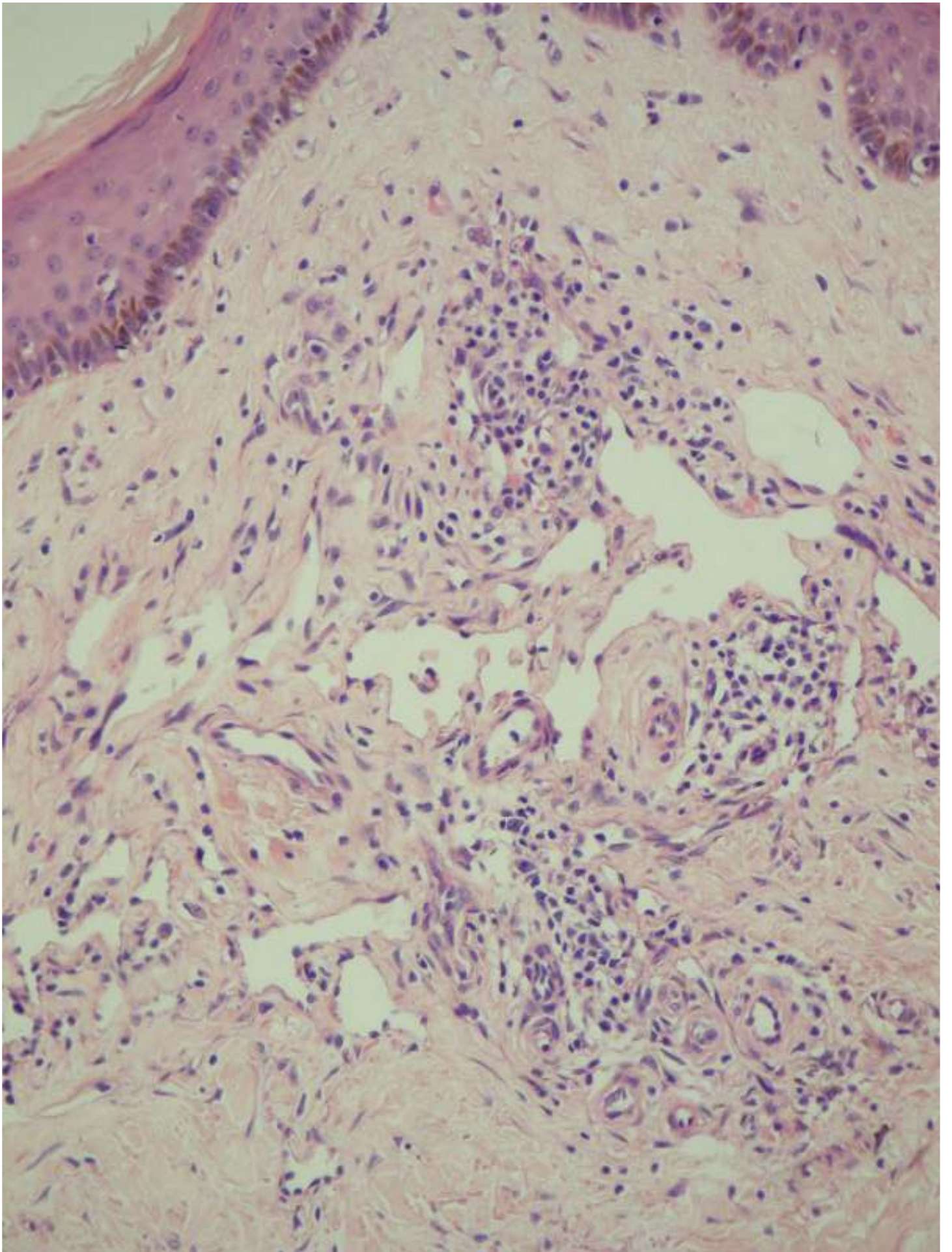


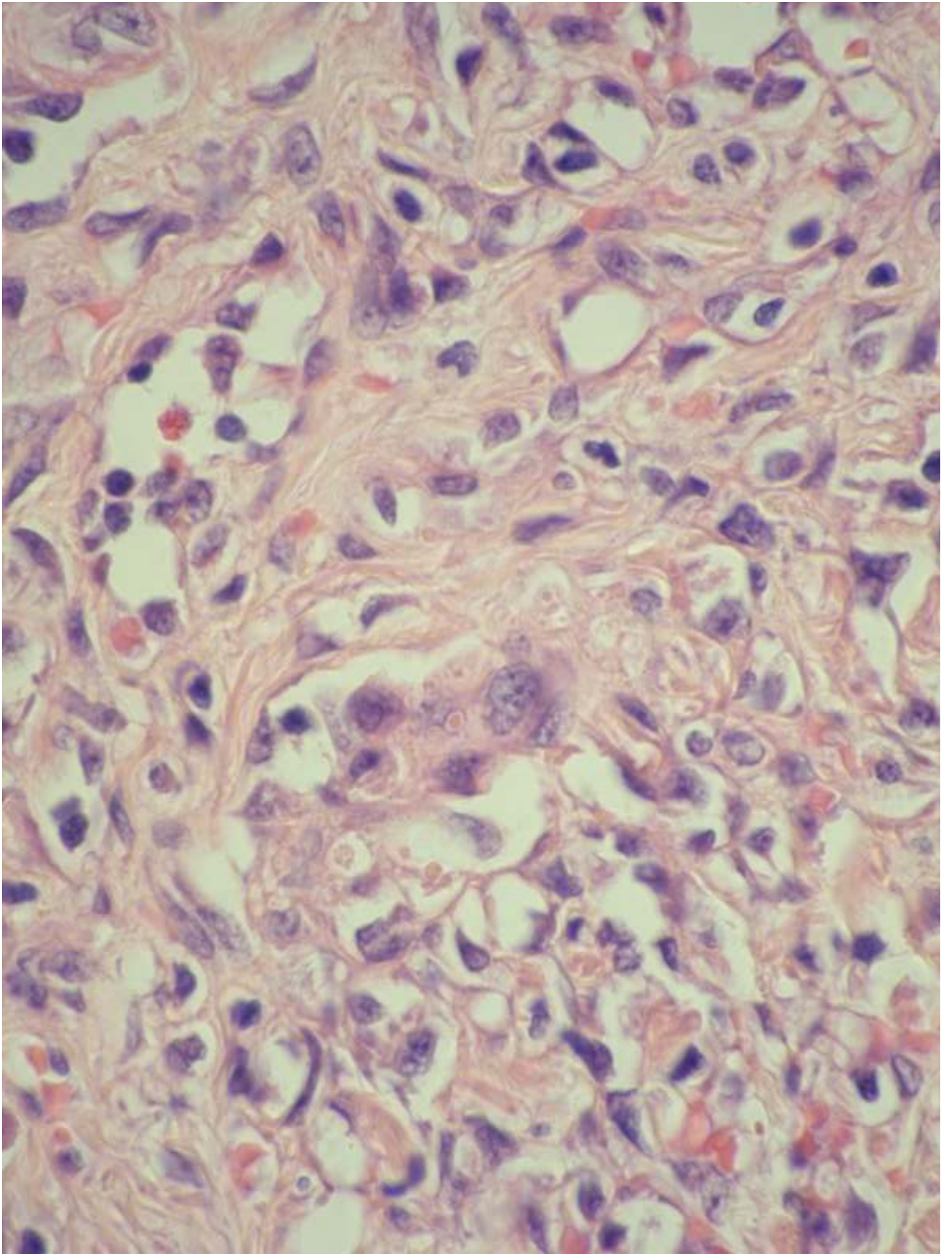


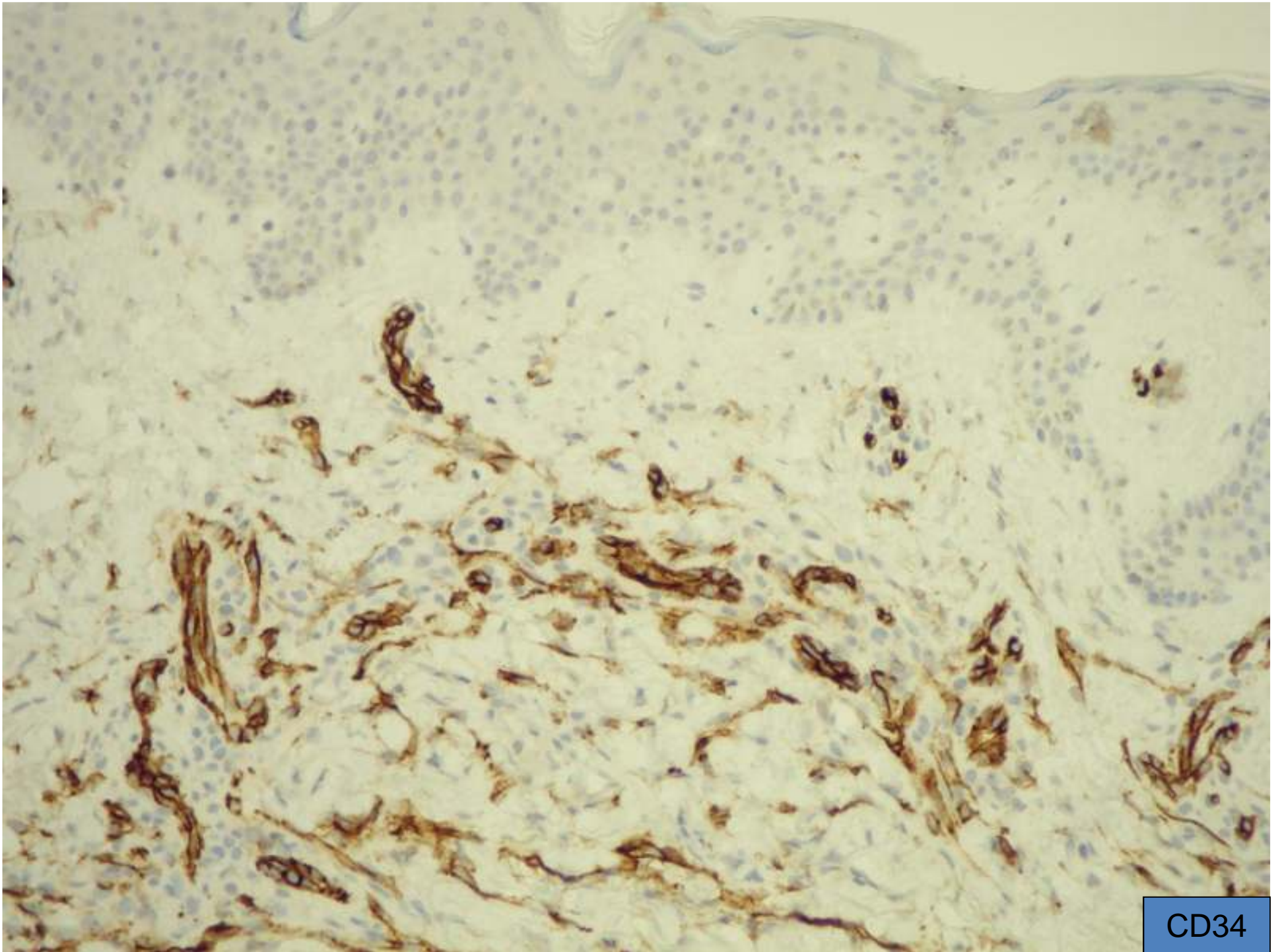




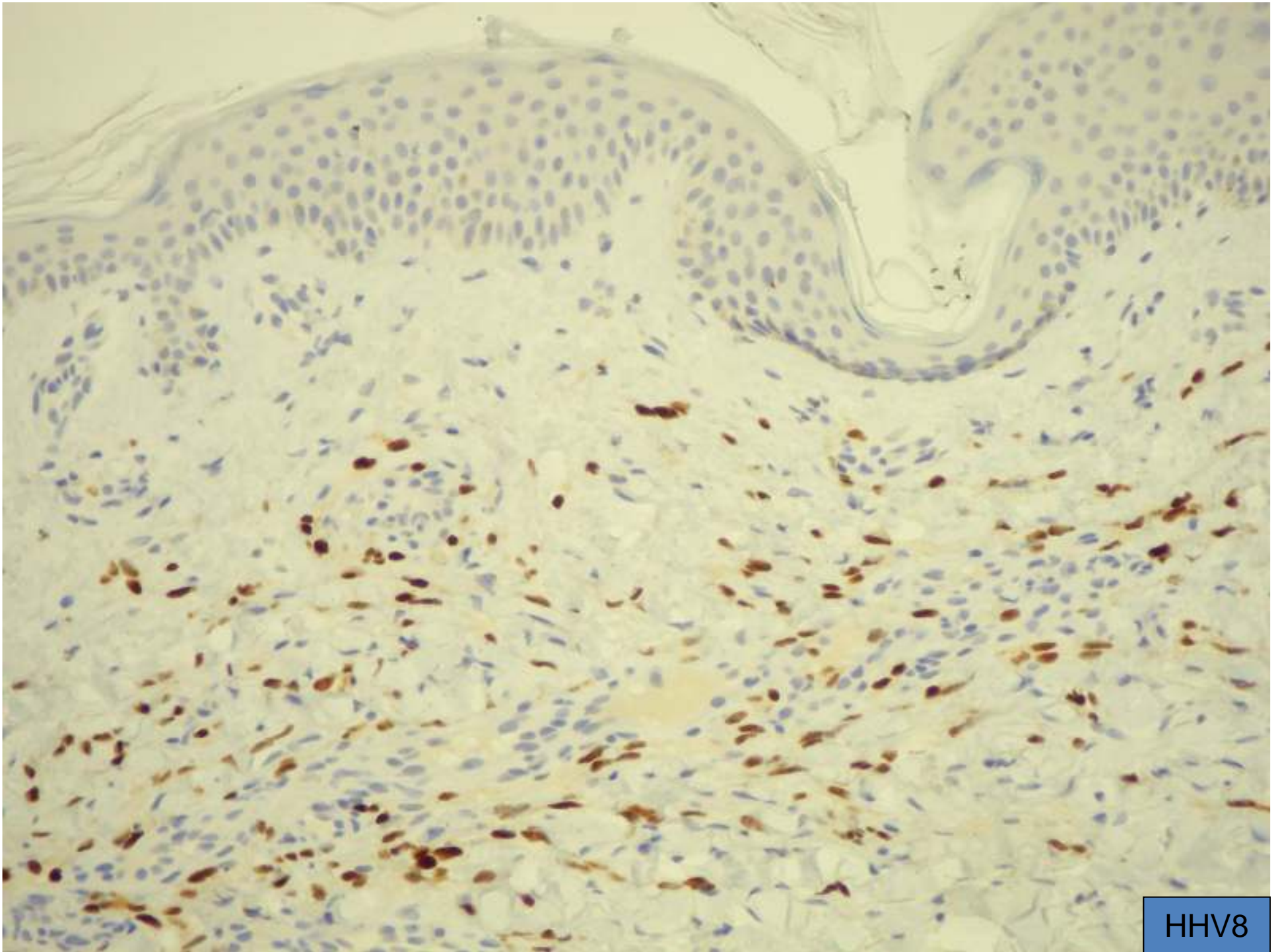








CD34

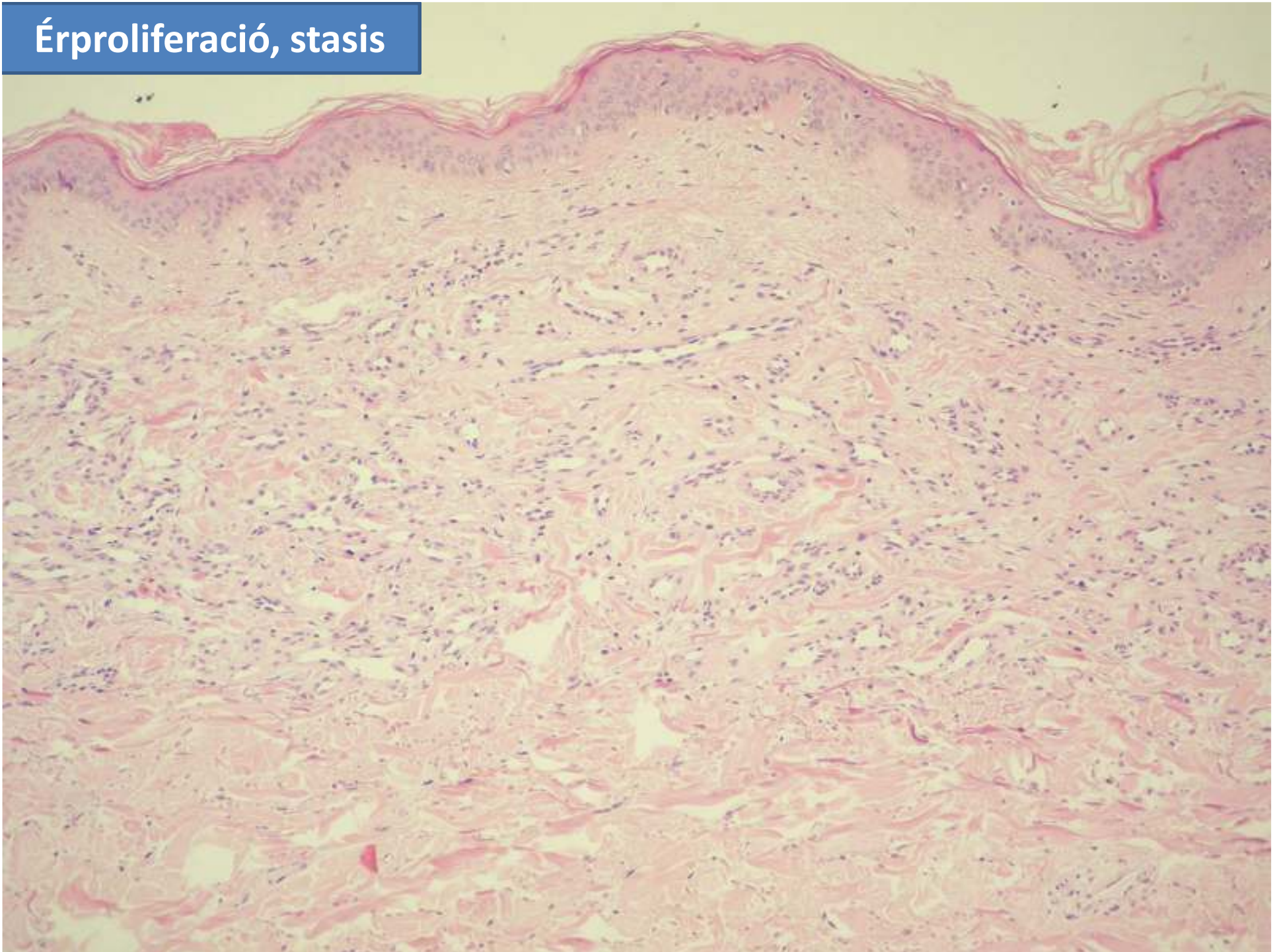


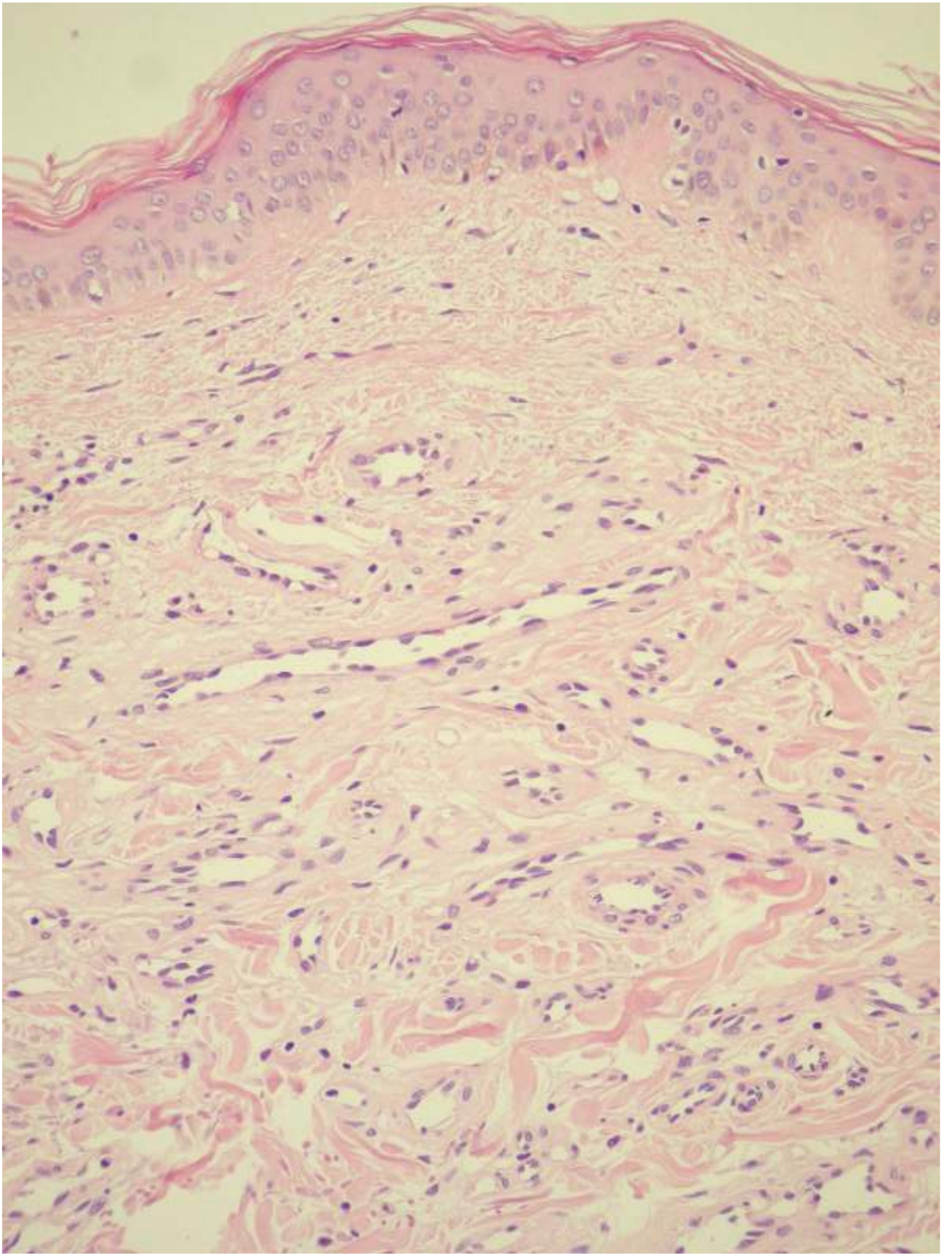
HHV8

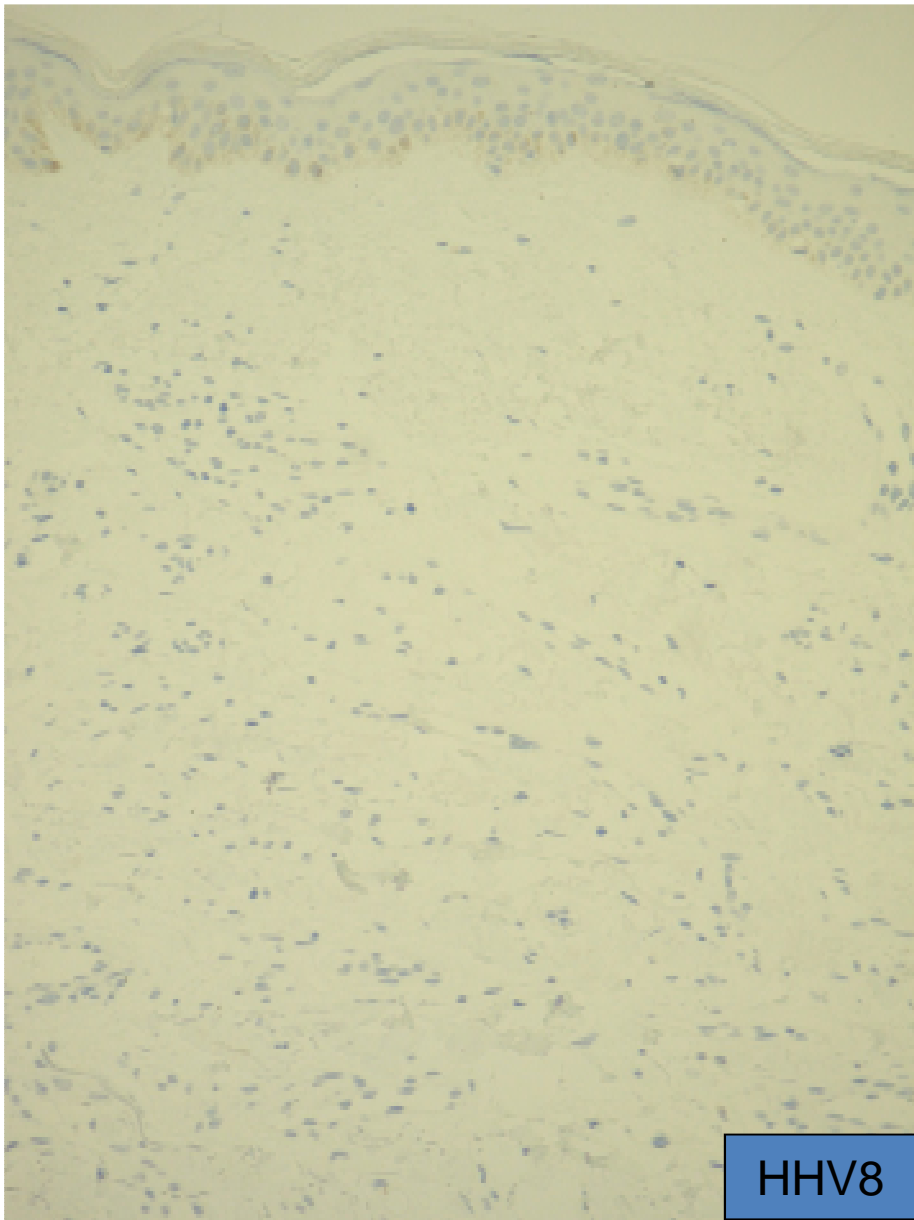
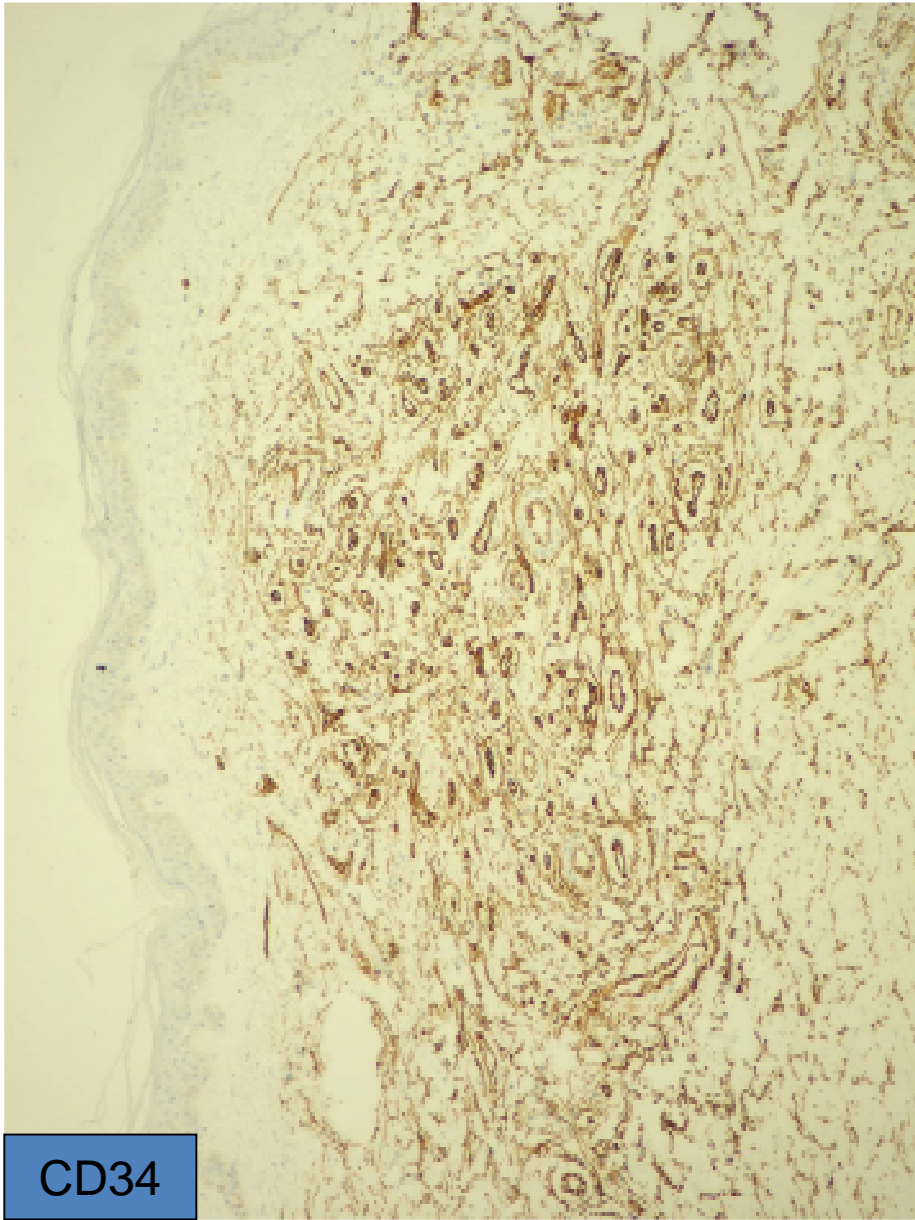
KAPOSI SARCOMA

- Korai fázis: nem karakteriszticus vékony erek proliferációja, papillaris dermis nem érintett
- Patch fázis: kitágult érproliferáció, extravasalis vörösvértestek, haemosiderin pigment, meglévő erek az új erekbe türemkednek, lymphocyták, plasmasejtek
- Plaque fázis: extenziv patch fázis + hyalin globulusok
- Nodularis fázis: fibrosarcoma-szerű kép; cytoplasmában hyalin globulusok
- CD-34, ERG, D2-40 +, CD-31 kevésbé +!, **HHV8+!!!** (immun, RNS in situ hybridizáció, PCR) (vírus indukált vascularis proliferáció)
- Ritka variánsok: anaplasticus, intravascularis, lymphangioma-like
- Prognózis: sokkal jobb, mint az angiosarcomáé

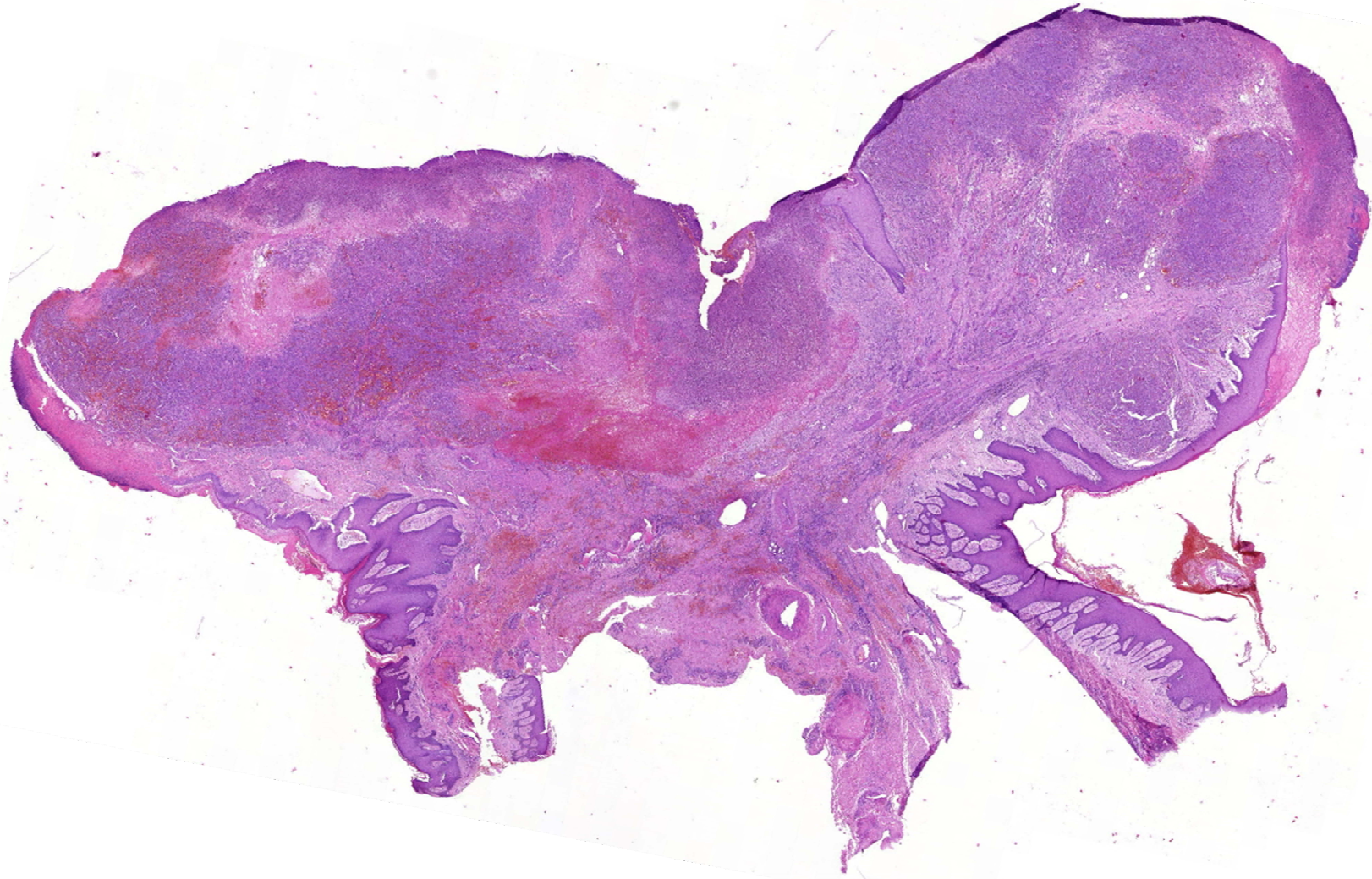Érproliferáció, stasis

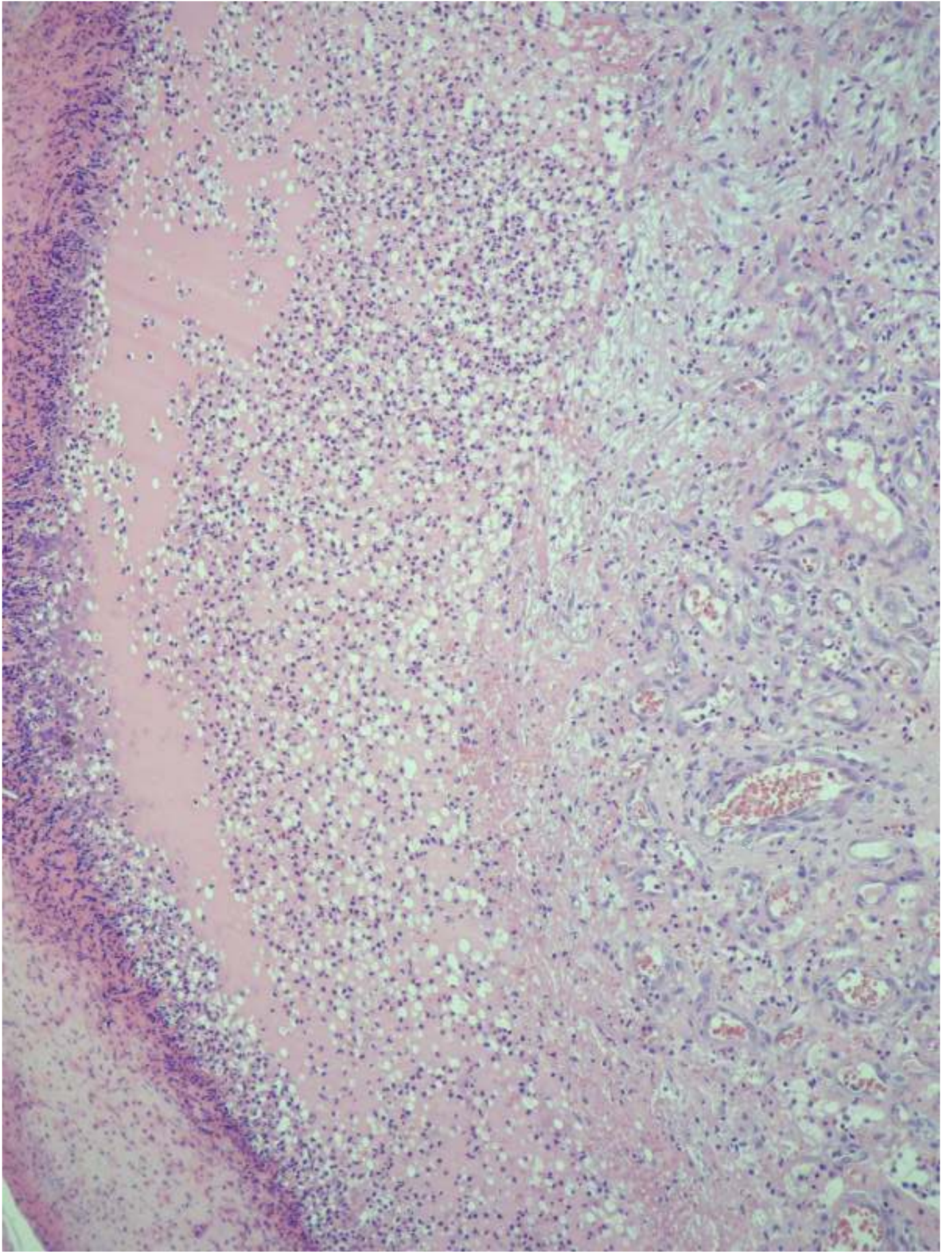


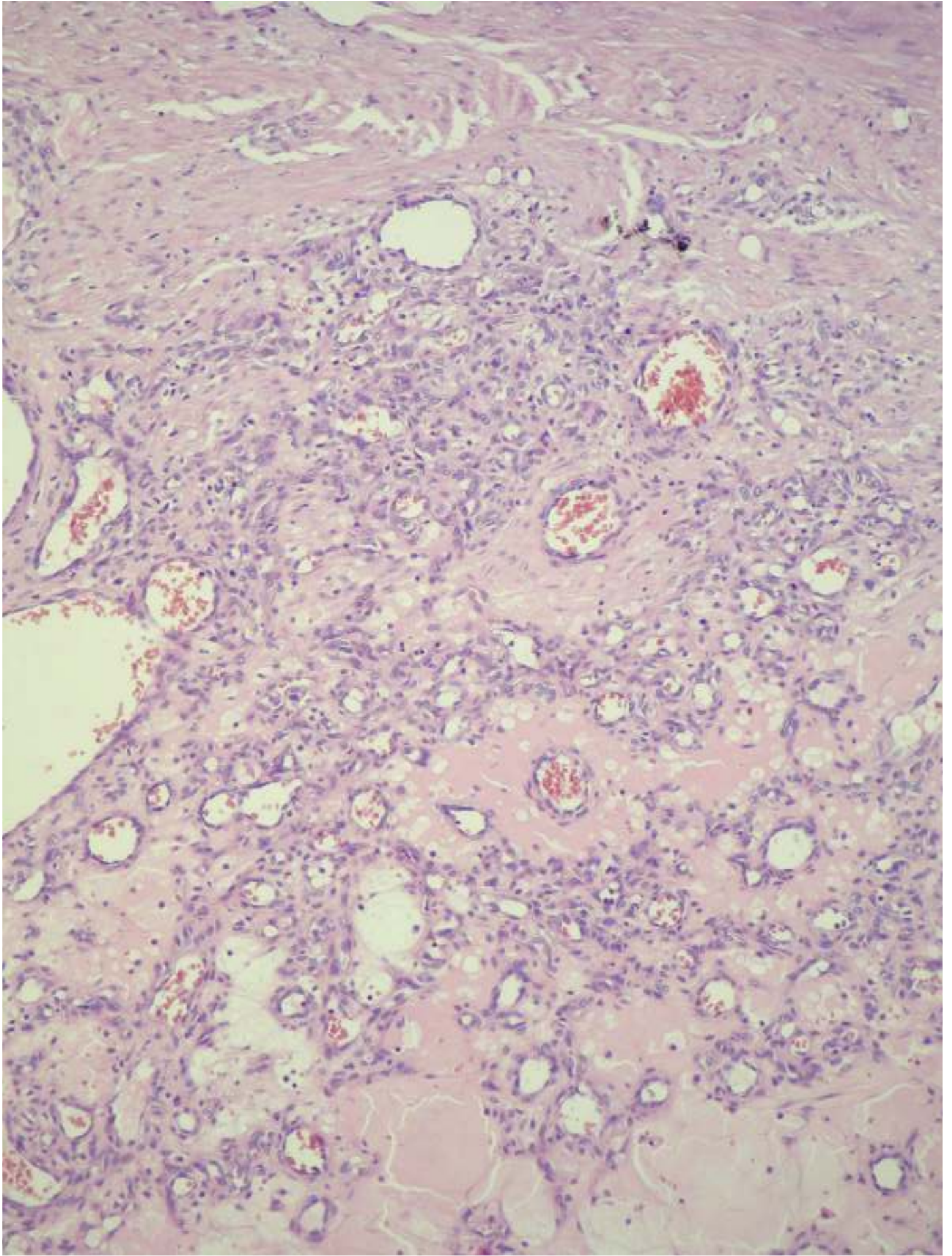


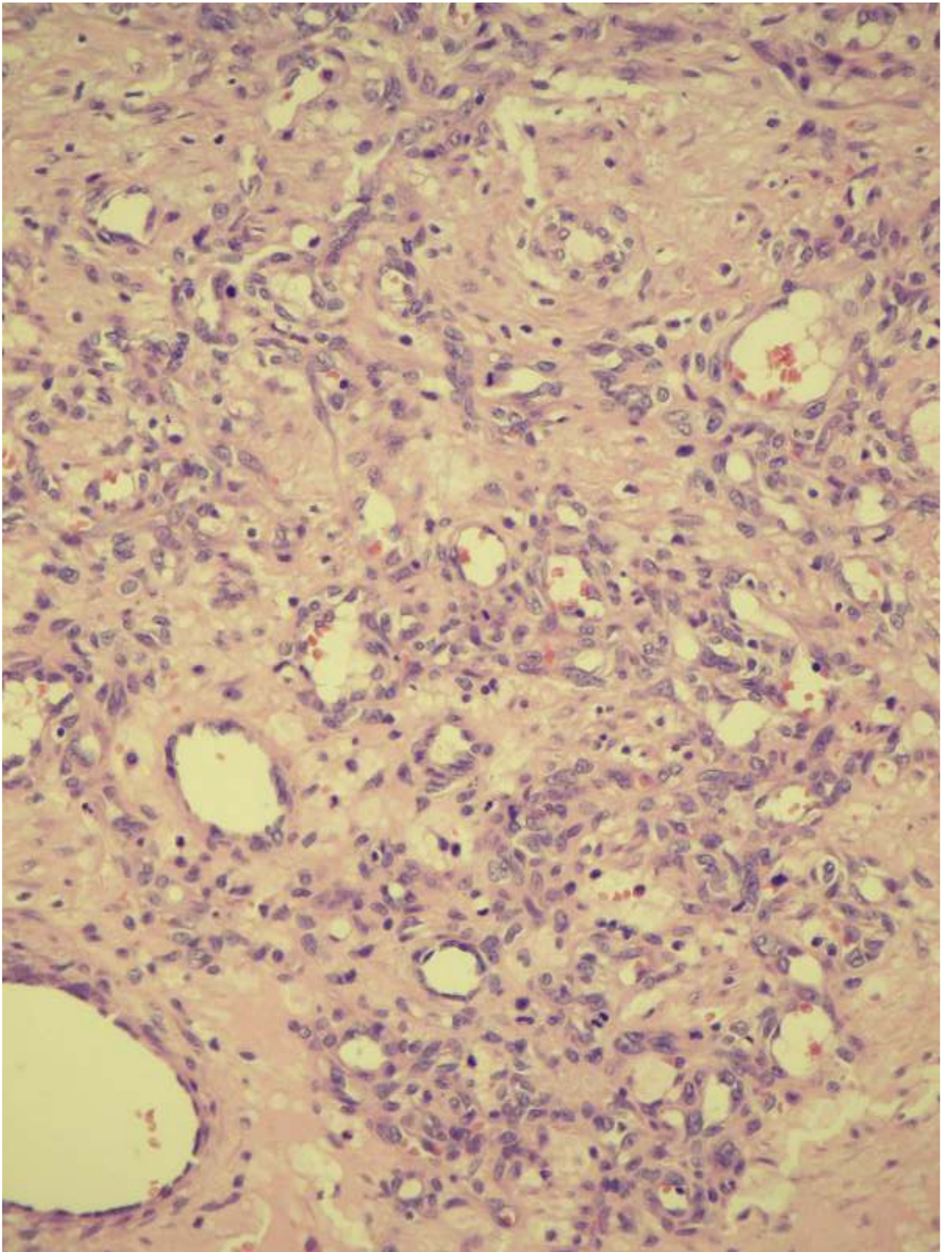


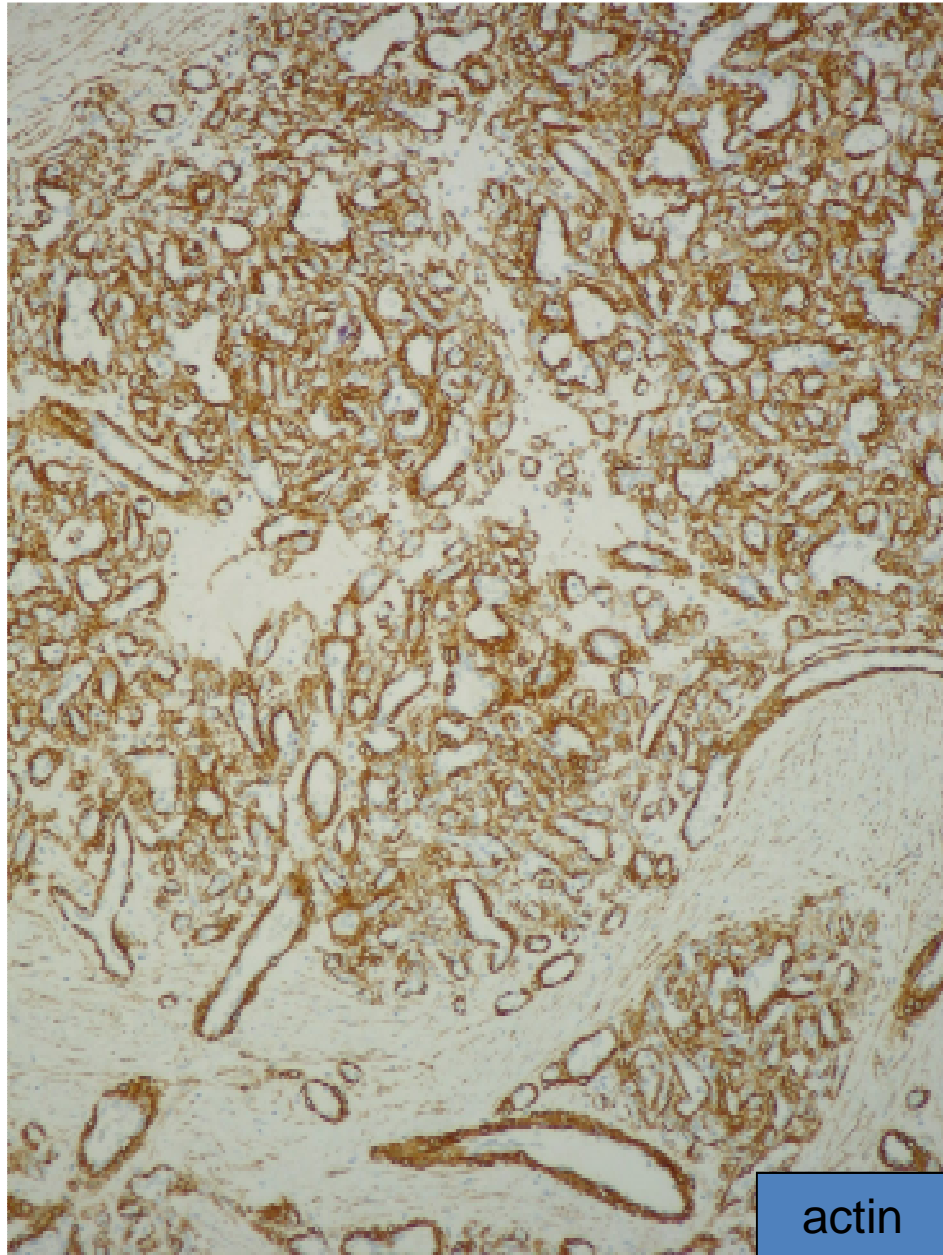
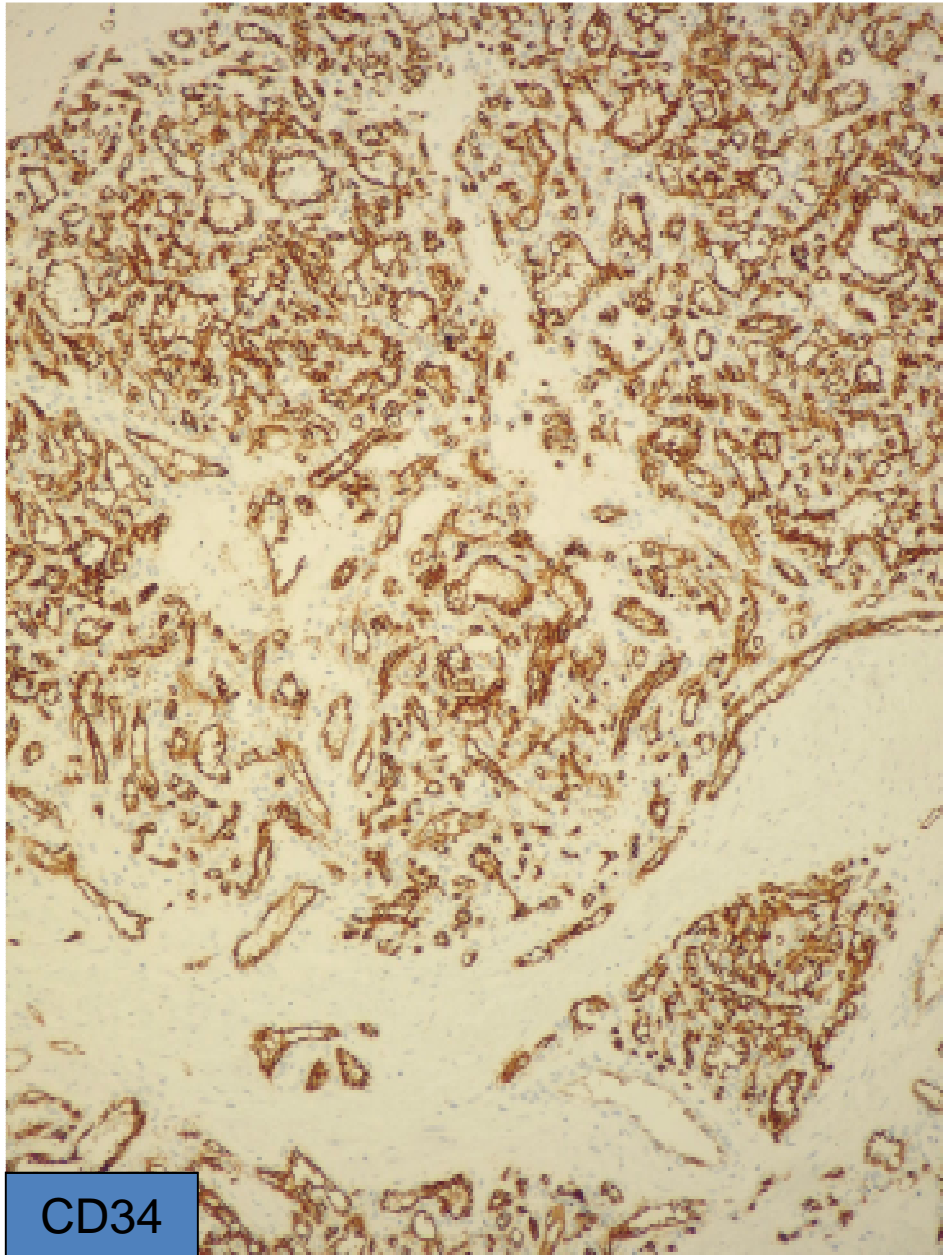
Pyogen granuloma

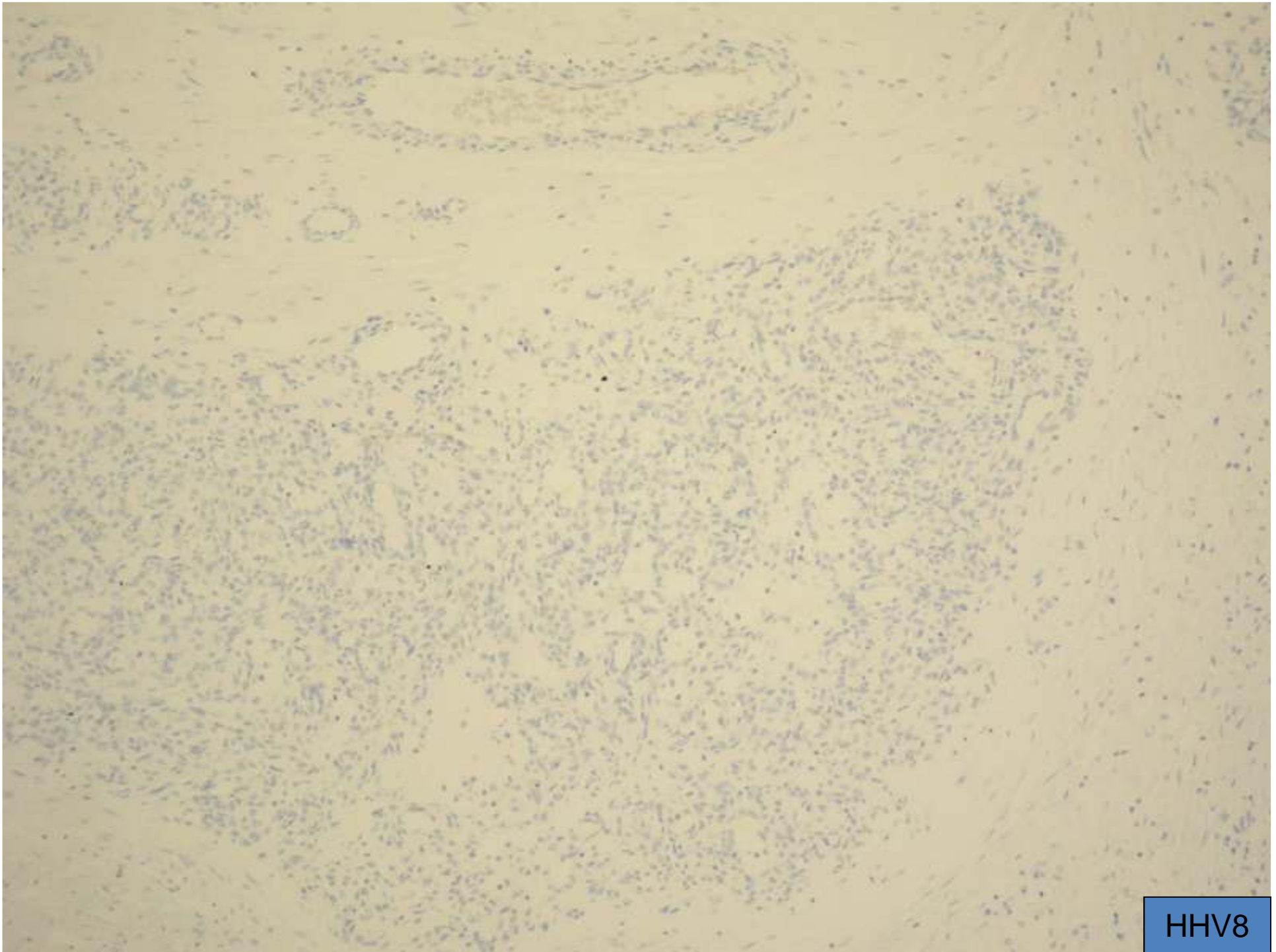






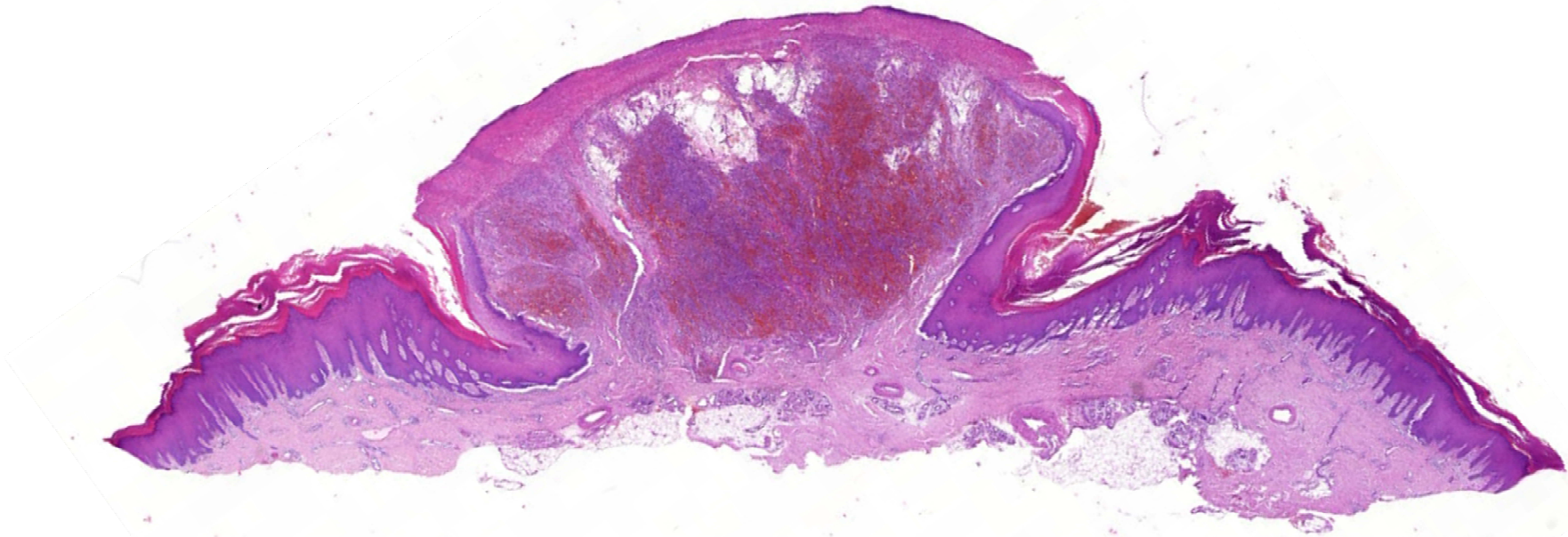


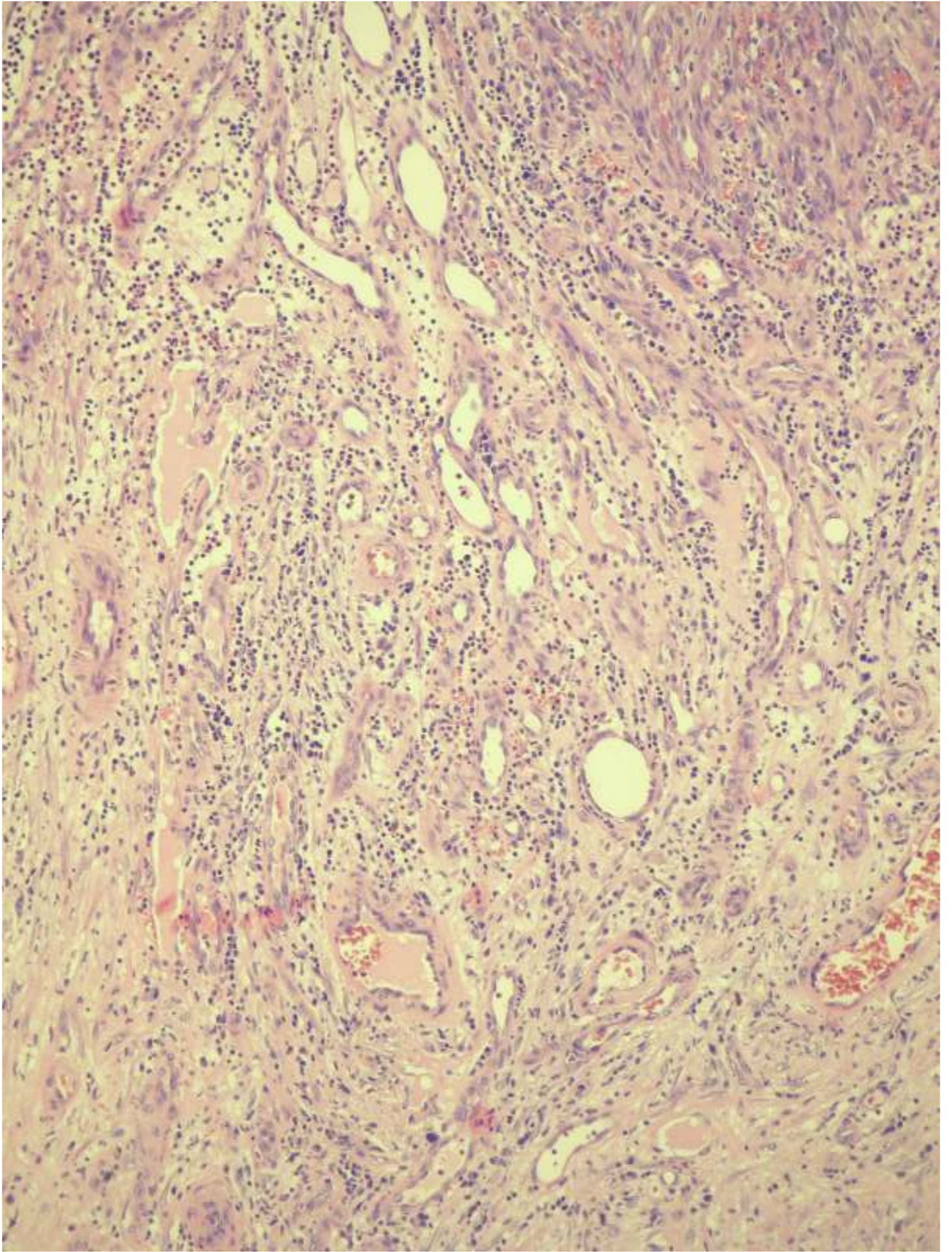


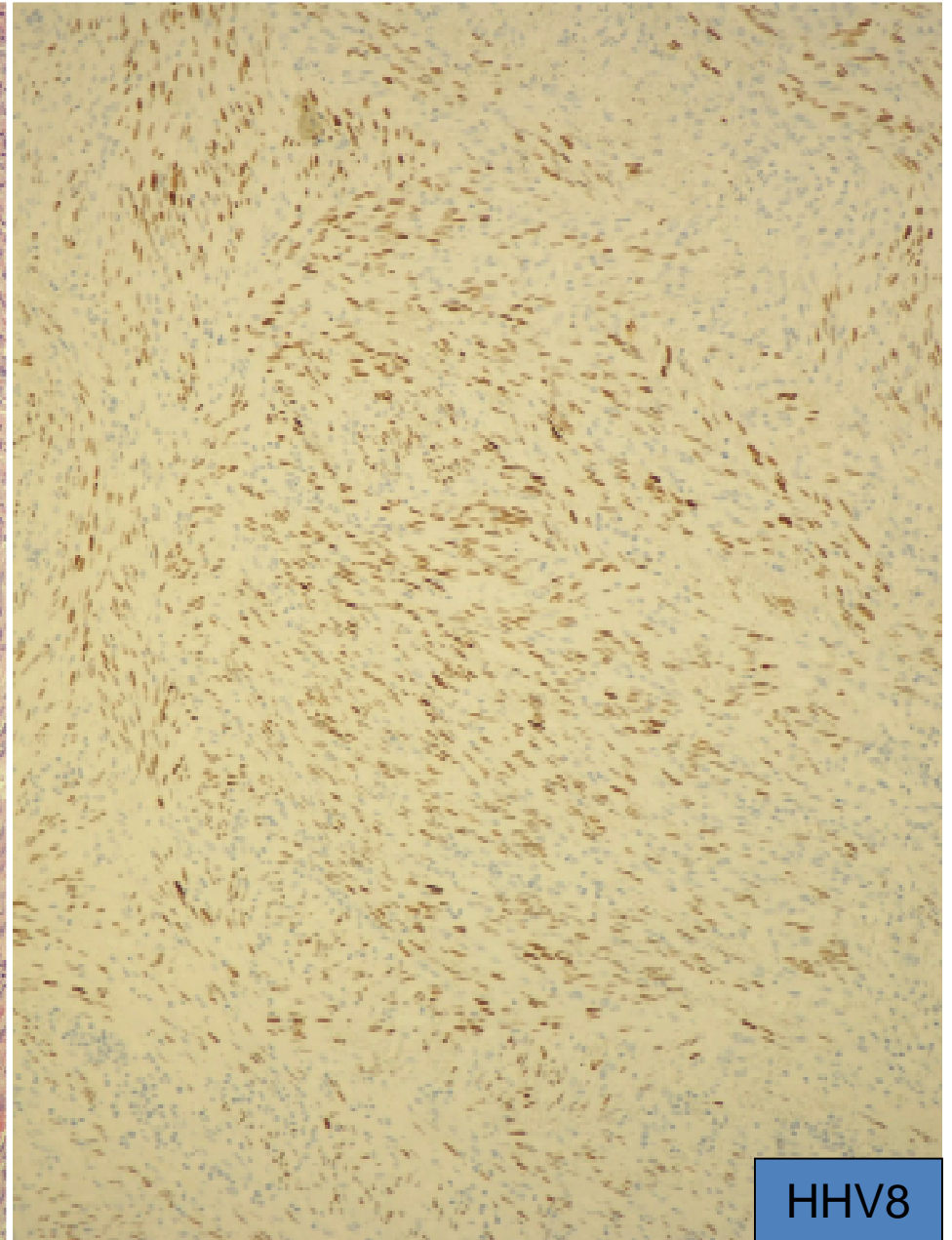
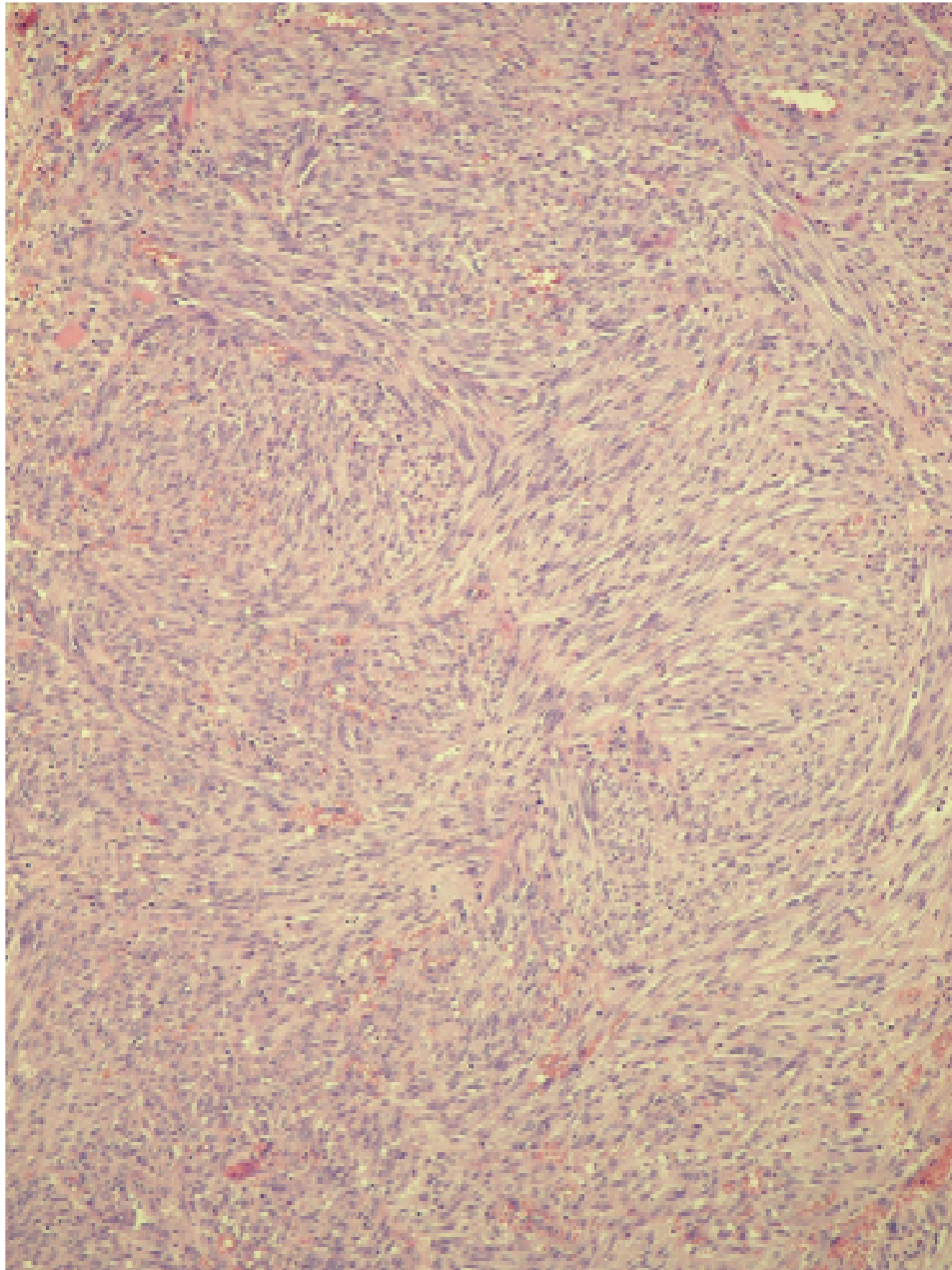


HHV8

Kaposi, pyogen granuloma like

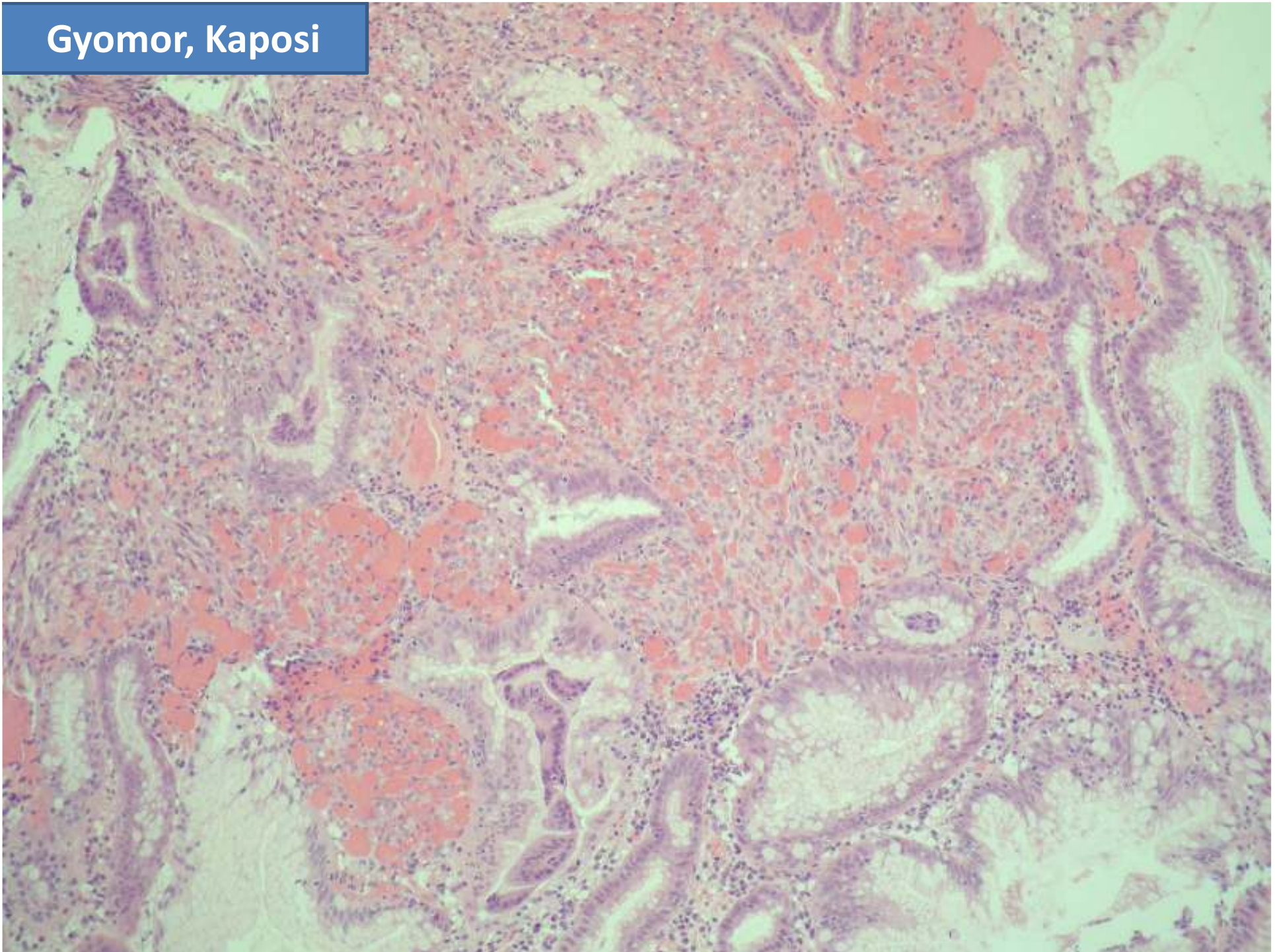


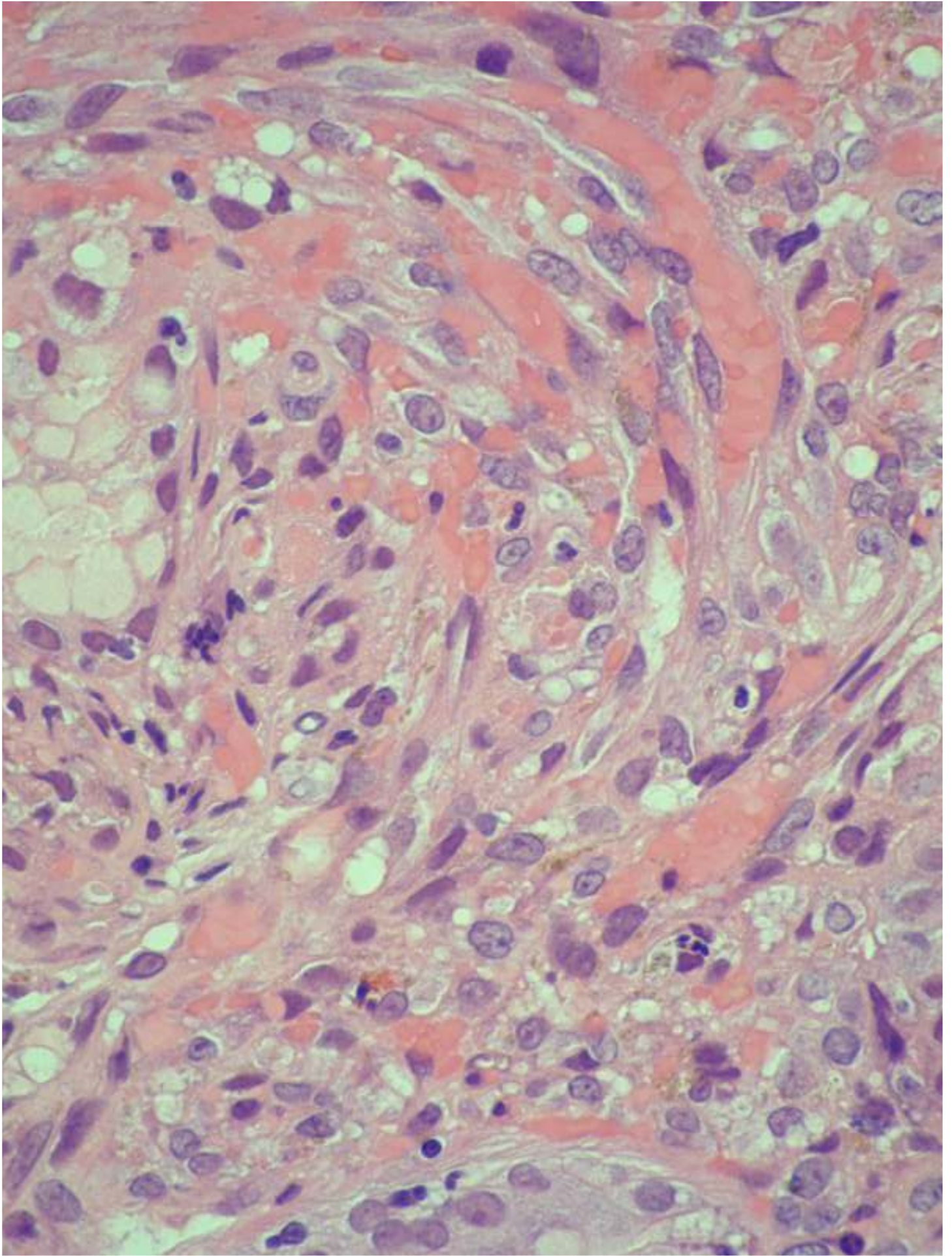


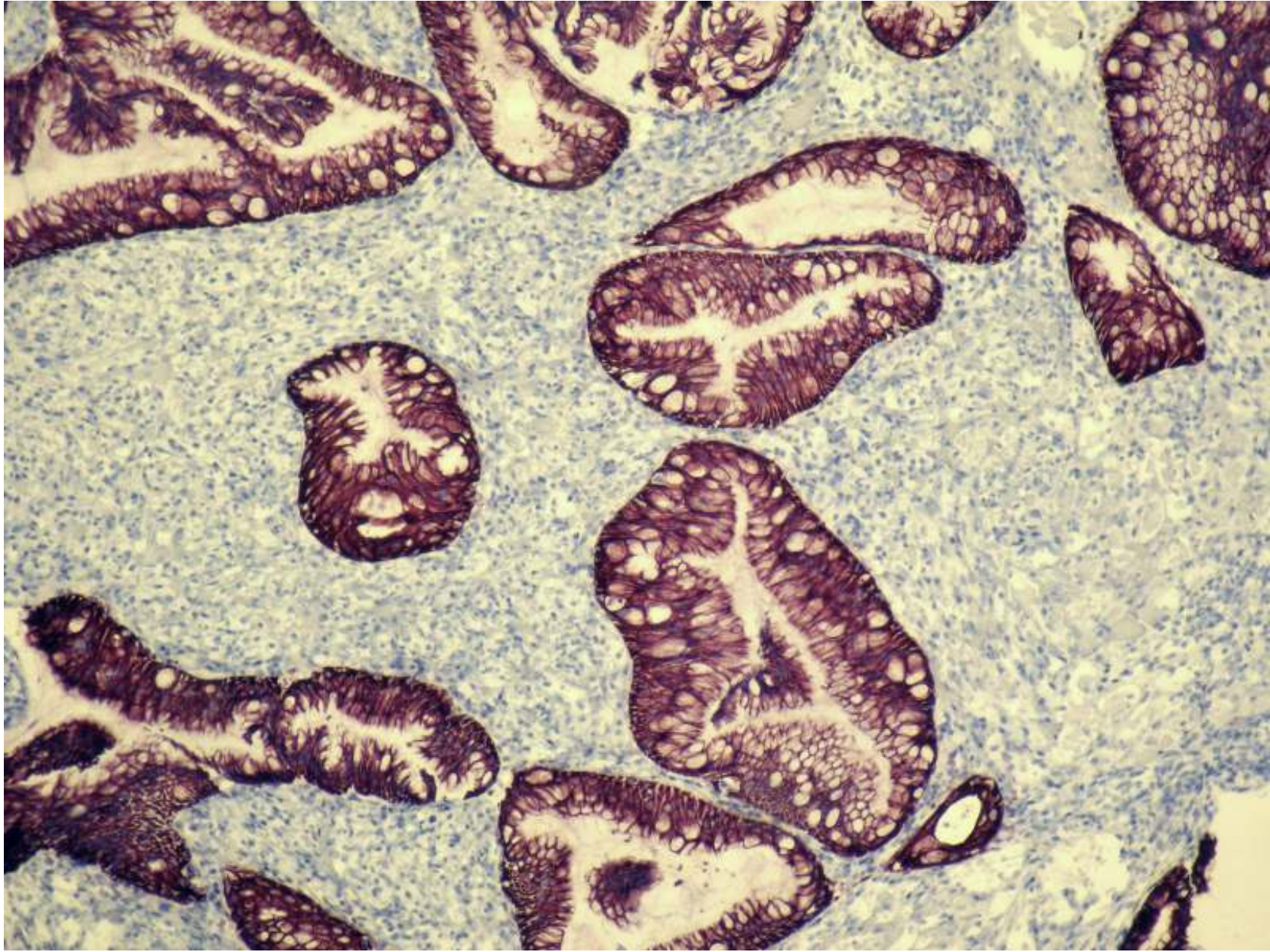


HHV8

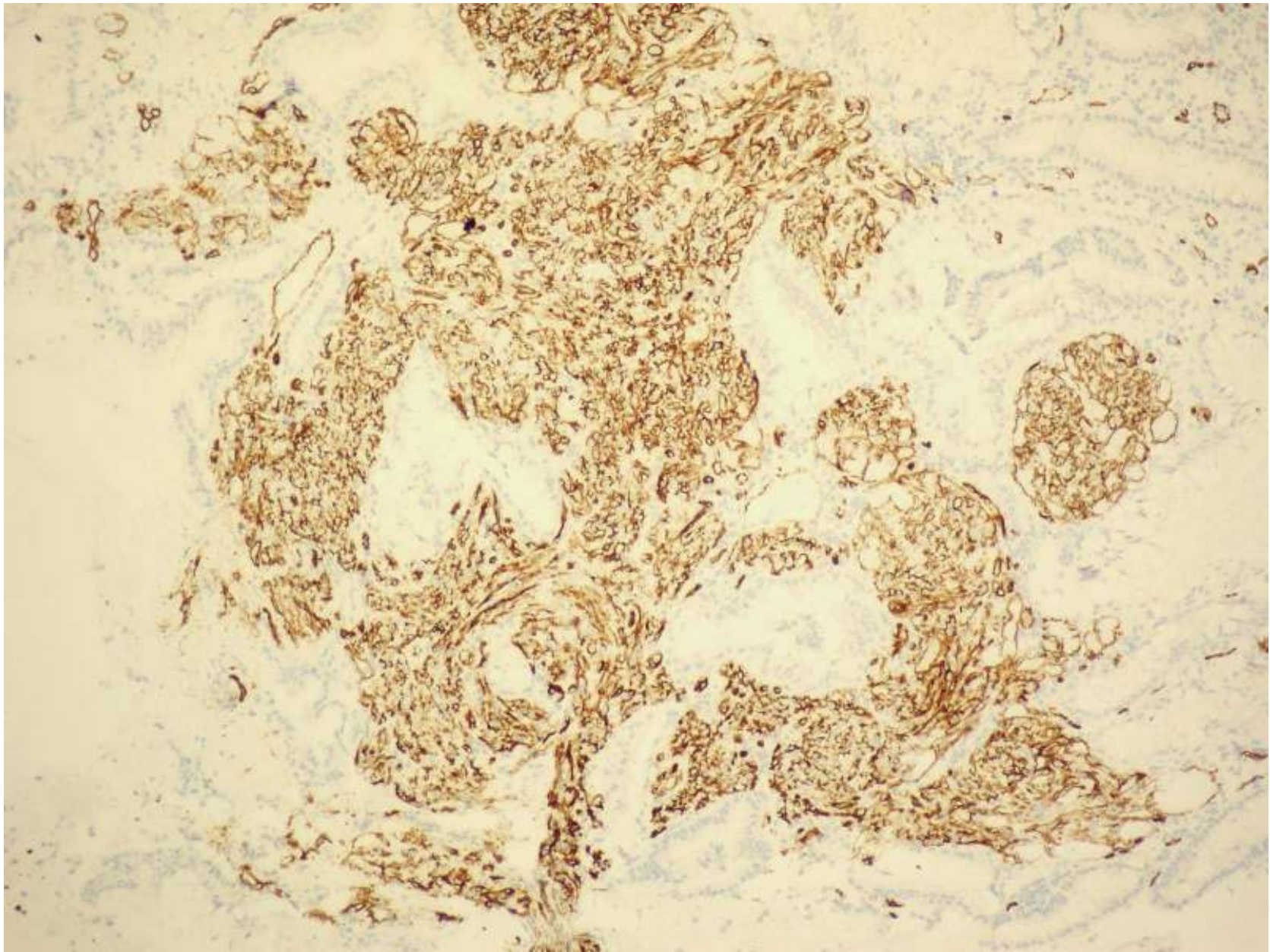
Gyomor, Kaposi



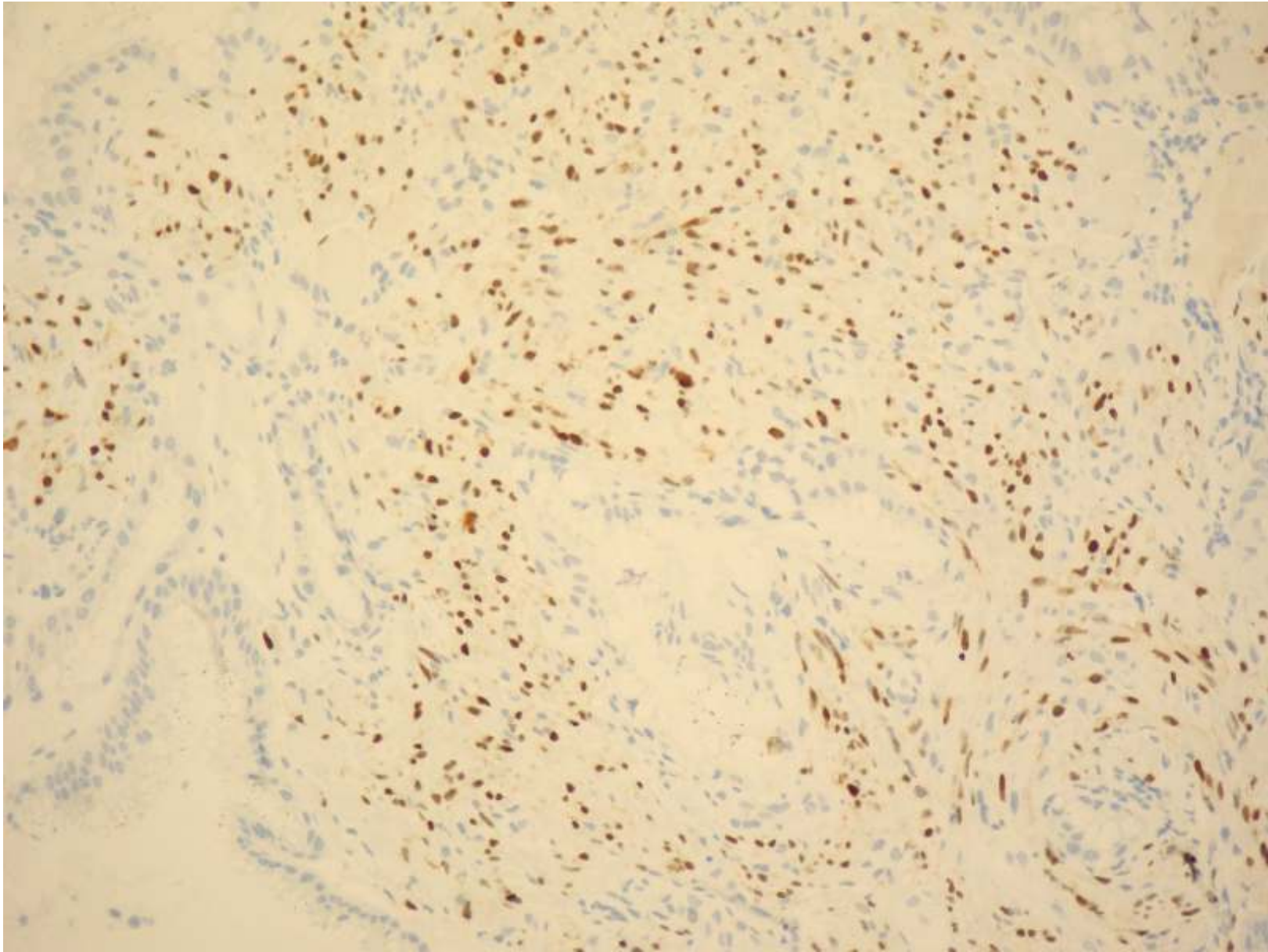




Keratin



CD34



HHV-8

