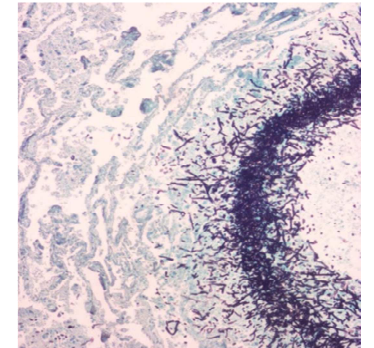
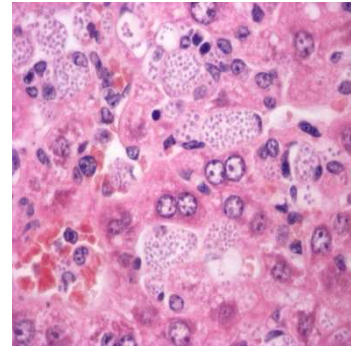
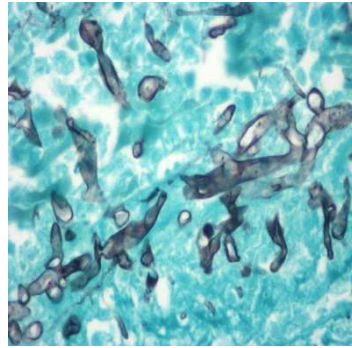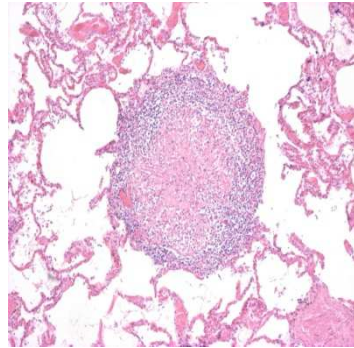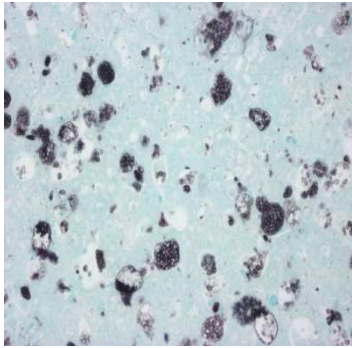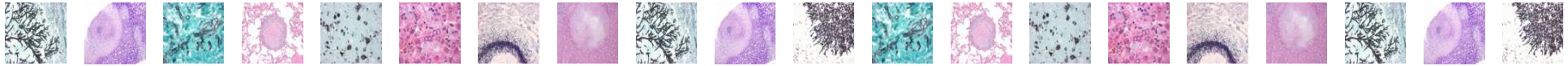
Opportunista infekciók

Csomor Judit

Patológus Kongresszus

2011. Siófok



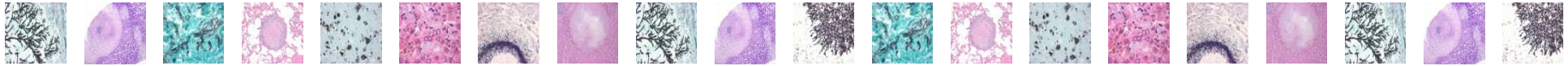


Opportunista infekciók

Immundeficiens betegek

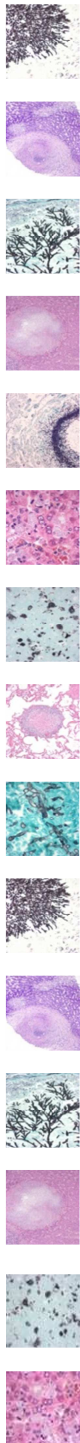
Fertőzések

Alacsony virulenciájú, ép immunitás mellett nem patogén vagy csak lokális betegséget okozó – opportunista mikróbák – súlyos betegséget okoznak.



Oportunista kórokozók

Baktérium	Vírus	Gomba	Protozoon
MACI Rhodococcus MAC Clostridium difficile Nocardia	HSV CMV HBV HCV EBV BK	Candida Aspergillus Cryptococcus Mucor Pneumocystis	Toxoplasma Giardia
		Histoplasma capsulatum Torulopsis Penicillium	Leishmania



granulocytopenia	leukémia, kemoterápia toxinok AIDS	candida aspergillus más gomba
neutrophil chemotaxis	cukorbetegség alkoholizmus szteroid uraemia Hodgkin ly	candida
neutrophil killing	CGD	candida, aspergillus
B-sejt defektus	agammaglobulinémia enteropathia myeloma splenectomia	giardia
T-sejt defektus	AIDS vírusinfekciók szteroid szarkoidosis transzplantáció	MAC, listeria, legionella HSV, VZV, CMV, EBV pneumocystis, candida, cryptococcus
barrier sérülés	katéter antibiotikum terápia	Clostridium difficile



Immundeficiencia - infekció

Ép

heveny felső légúti vírus fertőzés

májzsugorodás

diabetes

splenectomia

CLL

HIV infekció

rövid szteroid kezelés

időszakos neutropenia

AIDS

citosztatikus kezelés (CHOP)

szolid szervtranszplantáció

Akut leukémia, tartós súlyos neutropenia

allogén csontvelő transzplantáció

relabáló, rezisztens leukémia

herpes labialis, herpes zoster

meningitis, peritonitis, lobaris pneumonia

erysipelas, fasciitis, rhinocerebralis mucormycosis

meningitis

herpes, PCP, TBC

bacillaris angiomatosis, TBC, herpes, szifilisz

candidiasis

Gram + és Gram - tüdőgyulladás

AIDS meghatározó betegségek

bakt. tüdőgyulladás, szepszis

PCP, CMV, EBV lymphoproliferativ b.

bakt. és gomba

szepszis

bakt. és gomba

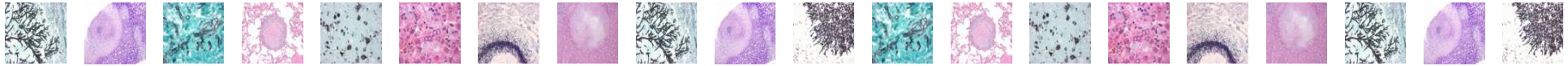
szepszis, CMV,

toxoplasma

bakt. és gomba

szepszis



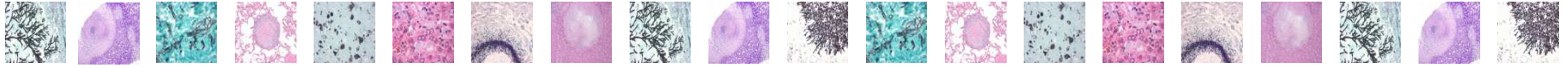


Szolid szervtranszplantáció

<4 hét	1-12 hónap	> 12 hónap
Sebészeti beavatkozás Graft védelem	Kilökődés elleni intenzív immunszupresszió	Kilökődés elleni csökkentett dózisú immunszupresszió
Nosocomiális vagy donor eredetű inf.	Opportunista kórokozók Endogén reinfekció	Közösségben szerzett inf. Endogén reinf.
MRSA, candida, VRE, aspergillus, enterobacteriumok, clostridium diff.	HSV, CMV, HBV, HCV, EBV, listeria, MB, BK, pneumocystis, toxoplasma	Bakterialis és vírus pneumonia, CMV colitis, Urogenitális inf.

Csontvelő transzplantáció

aplasia	GVHD kezelés	GVHD kezelés
---------	--------------	--------------



„Metamorphosis”

purulens



histiocyter / vérzéses necrosis

granulomatosus

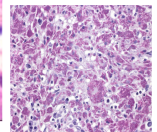
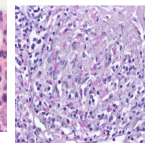
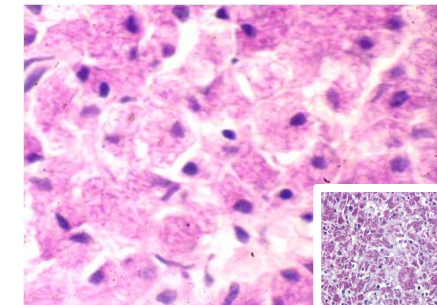
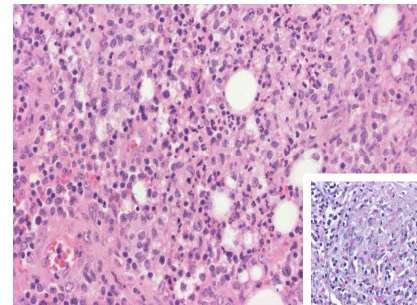
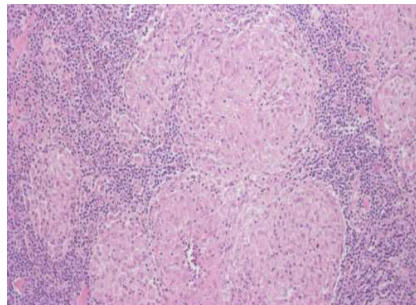
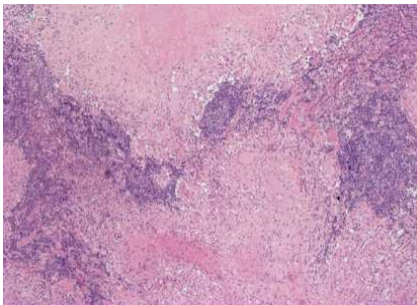
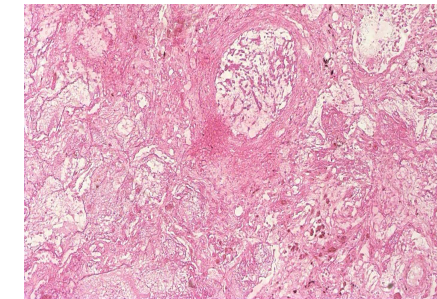
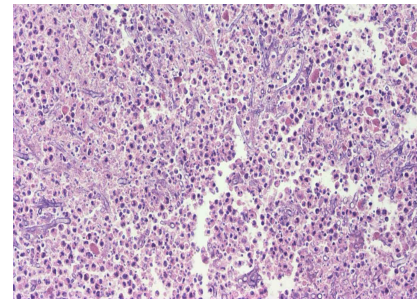
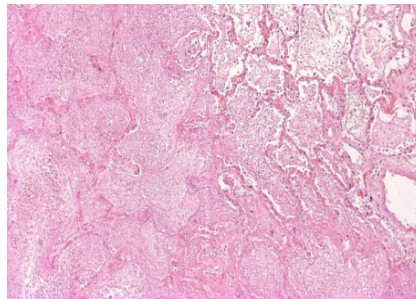
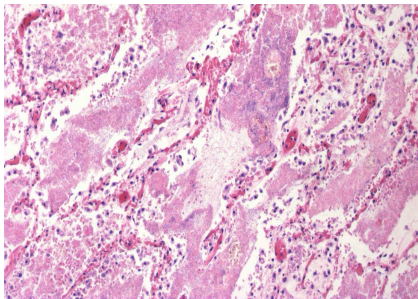
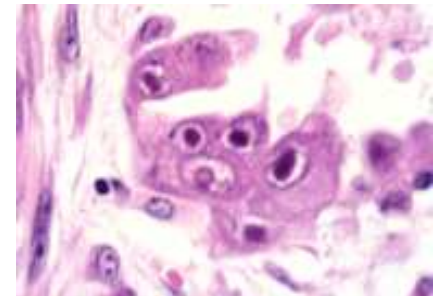
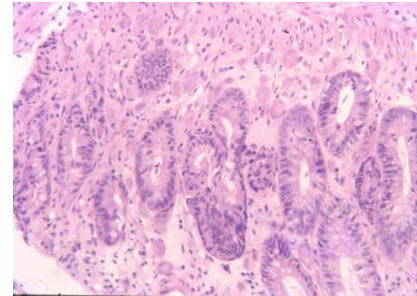
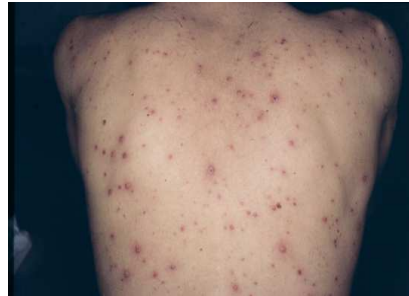
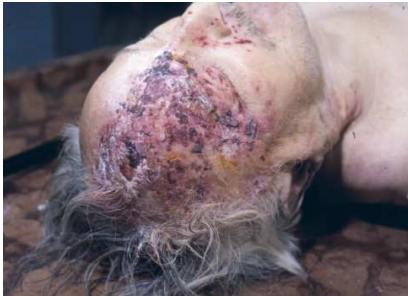
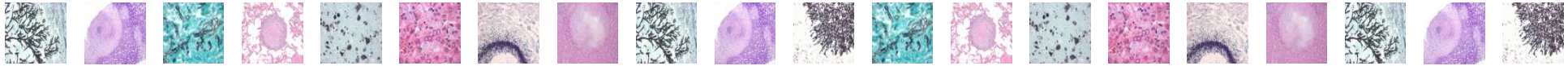
histiocyter

areaktív



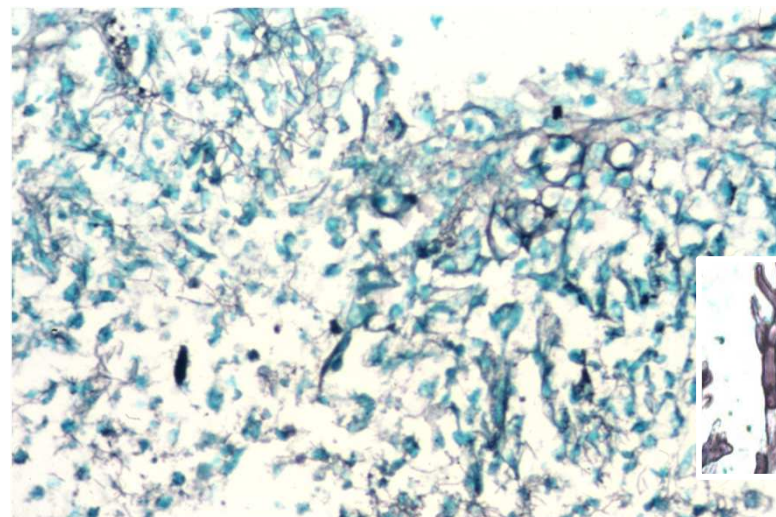
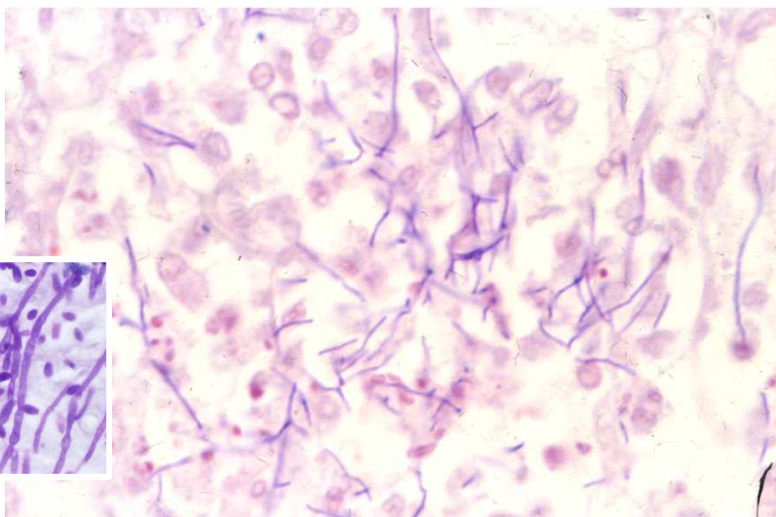
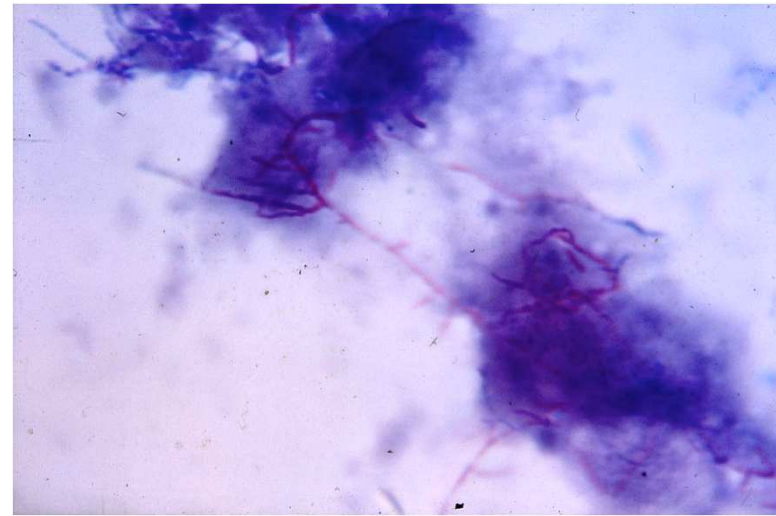
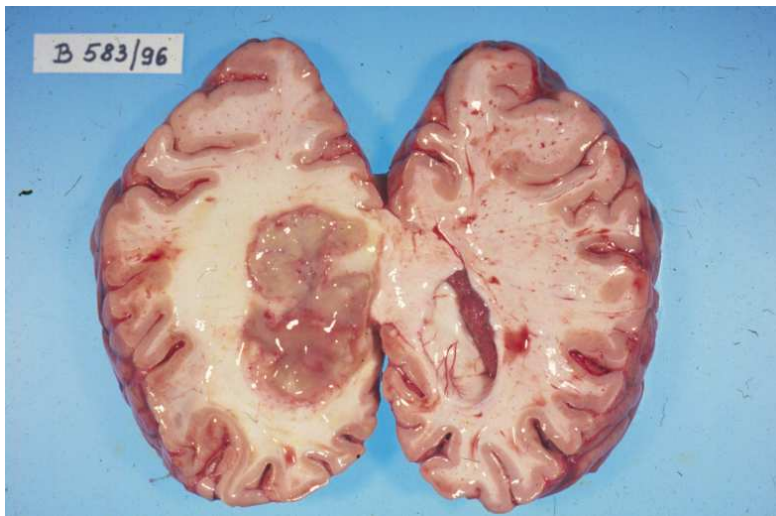
0 reakció / tömeges víruszárvány / necrosis

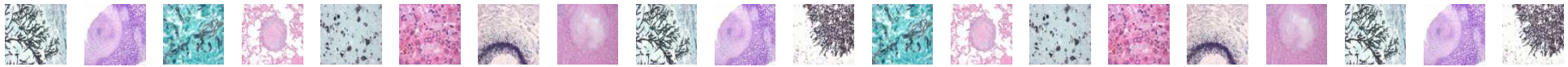




Nocardia asteroides

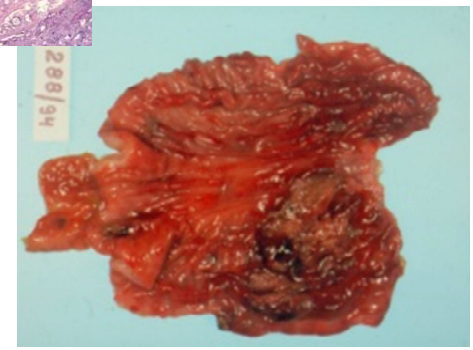
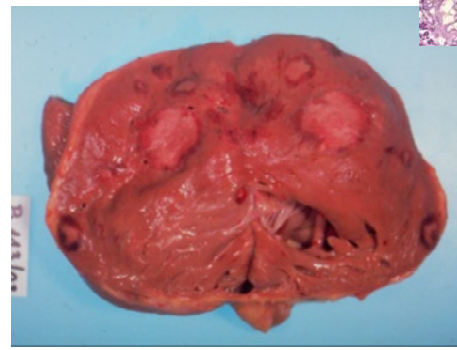
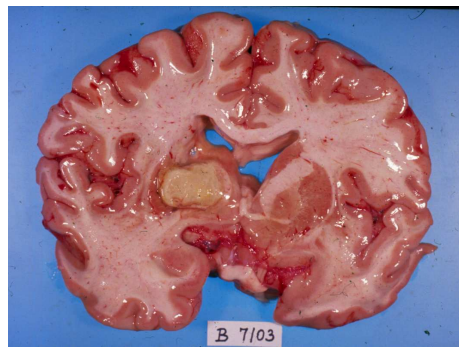
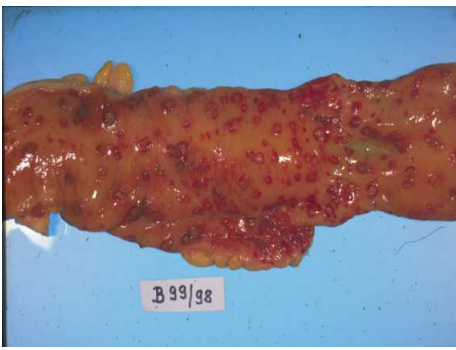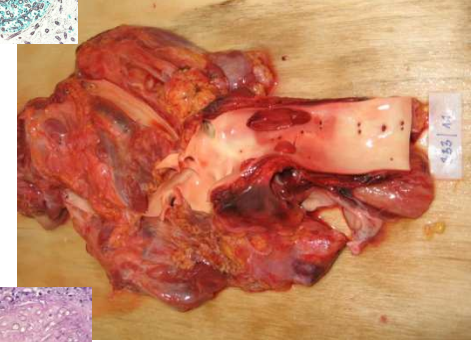
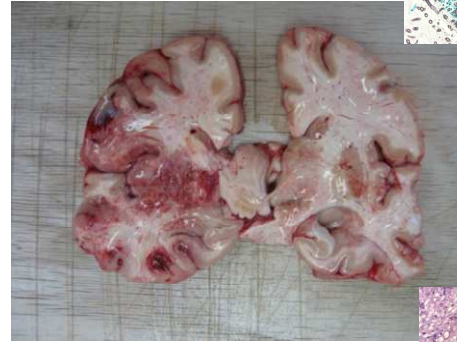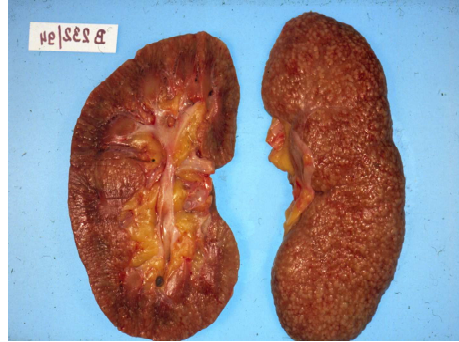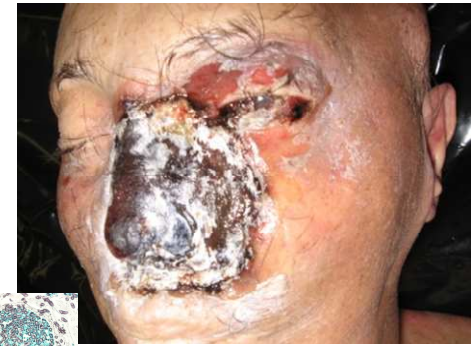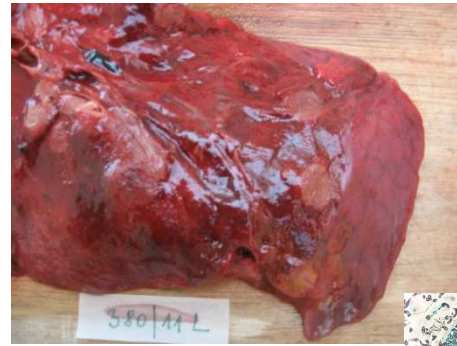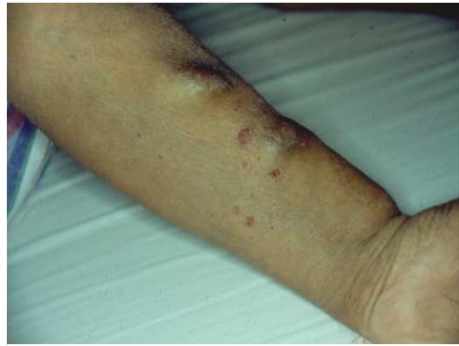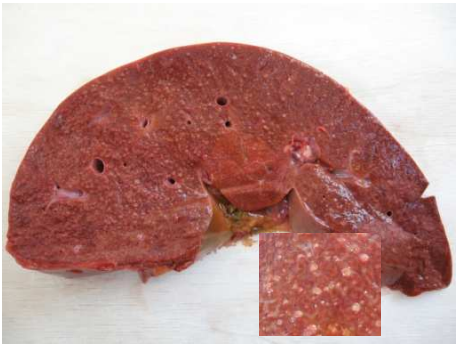
HE alig látszik, gyengén Gram +, gyengén Z-N +, gyengén PAS +, ezüstözhető baktérium

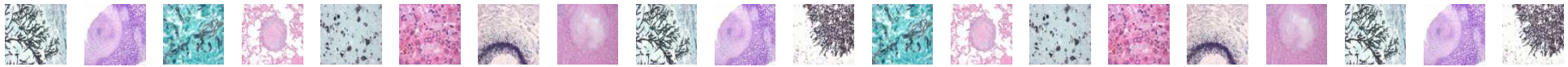




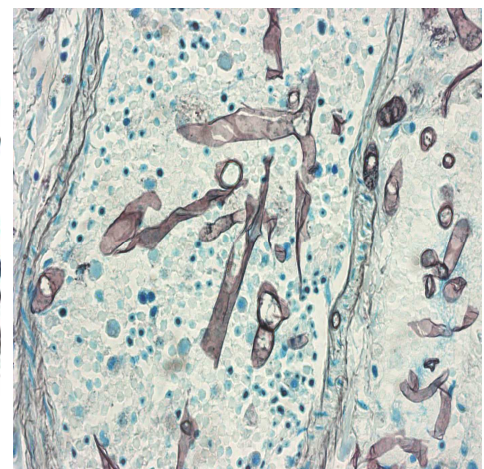
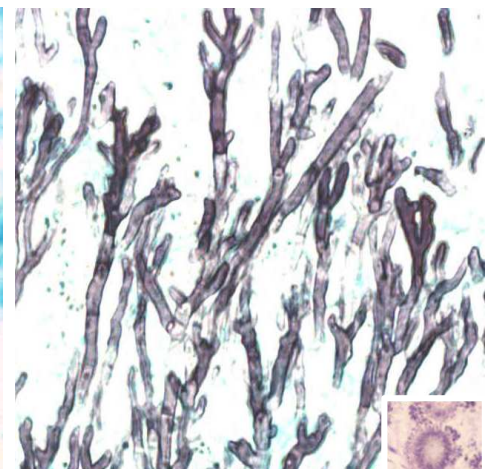
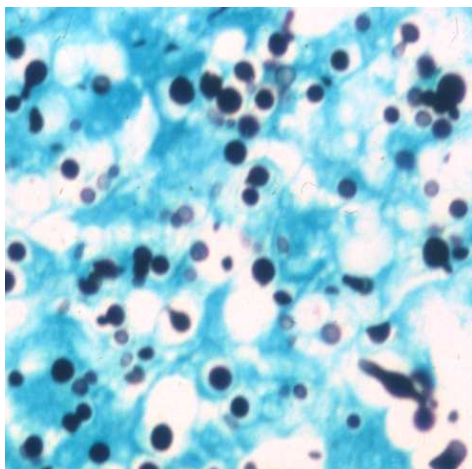
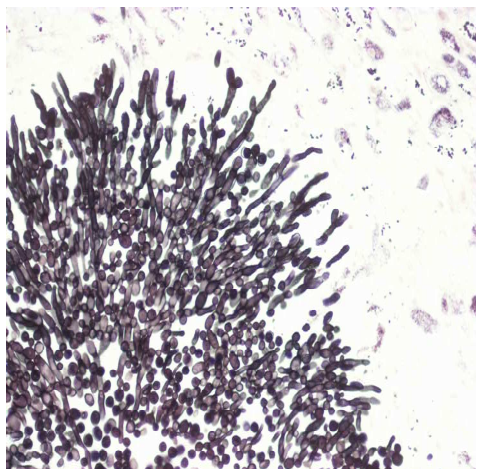
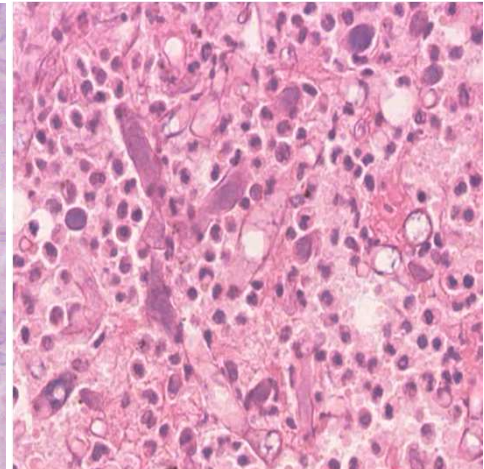
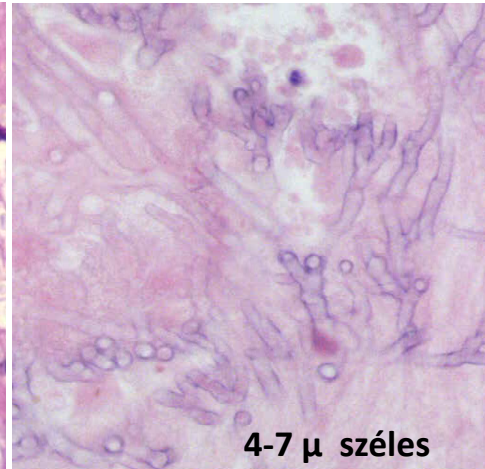
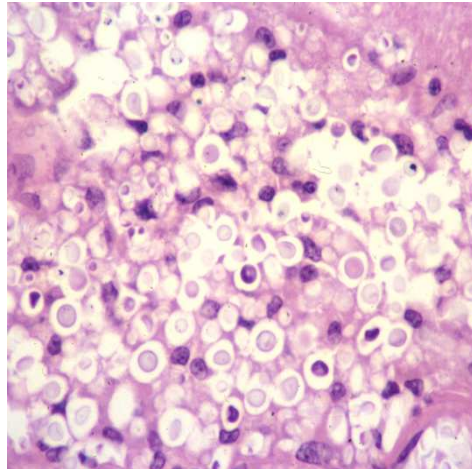
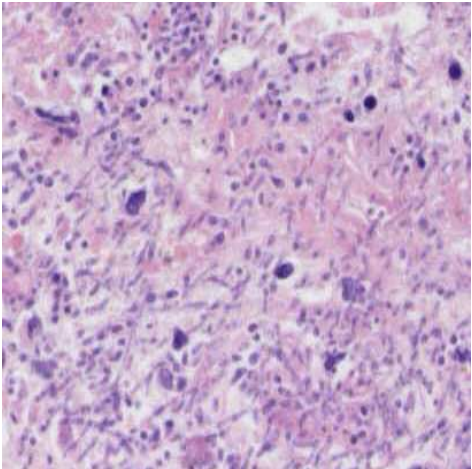
sarjadzó
↔
fonalas

candida
cryptococcus
nonmucor
mucor

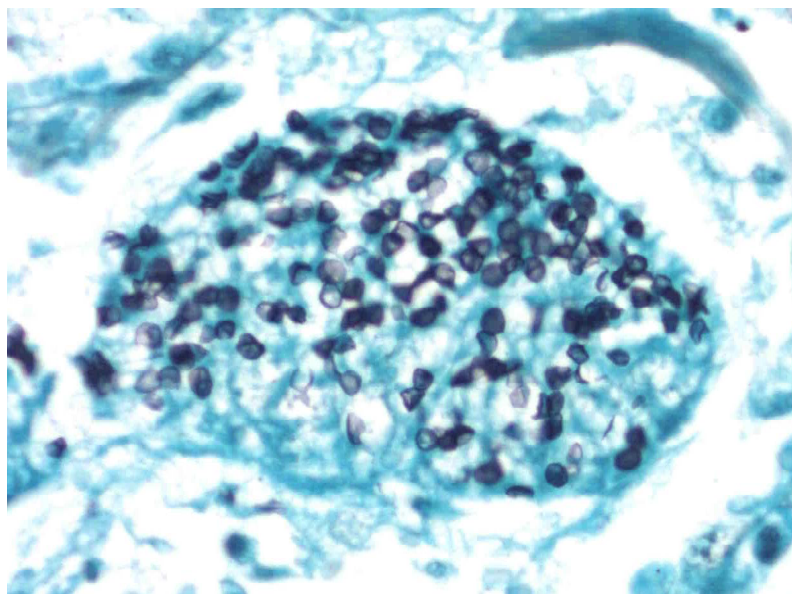
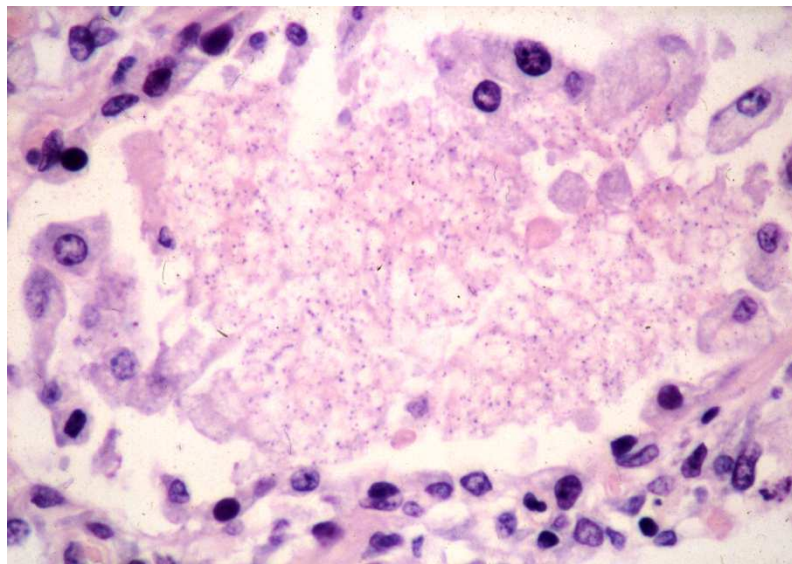
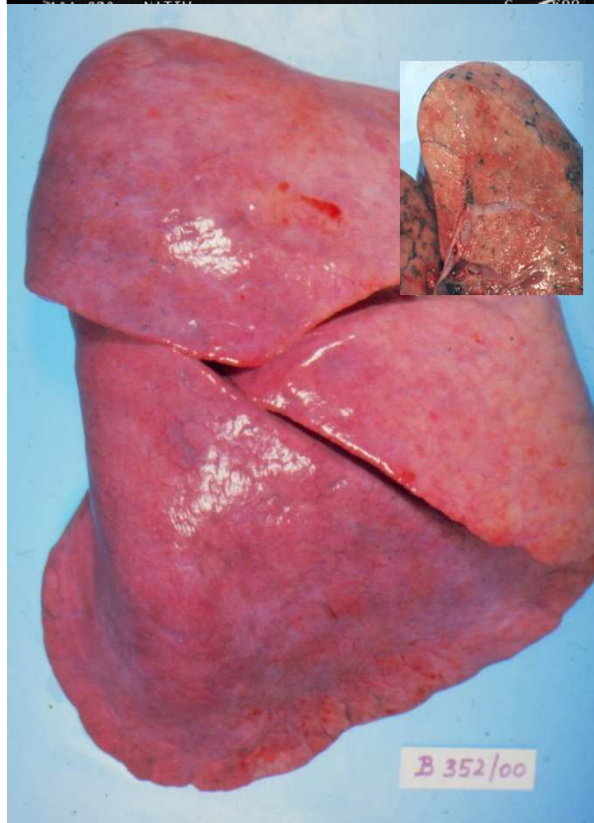
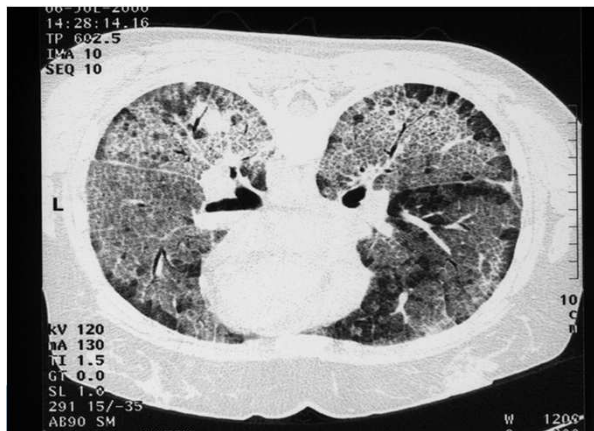




sarjadzó **fonalas**
candida **cryptococcus** ↔ **nonmucor** **mucor**



Pneumocystis jiroveci



HE alig
látszik

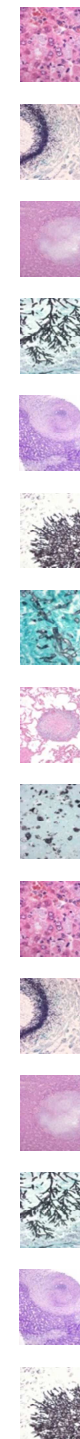Giemsa alig
látszik

Grocott +

PAS –

Cysta 6-8 μ

Interstitialis
pneumonia



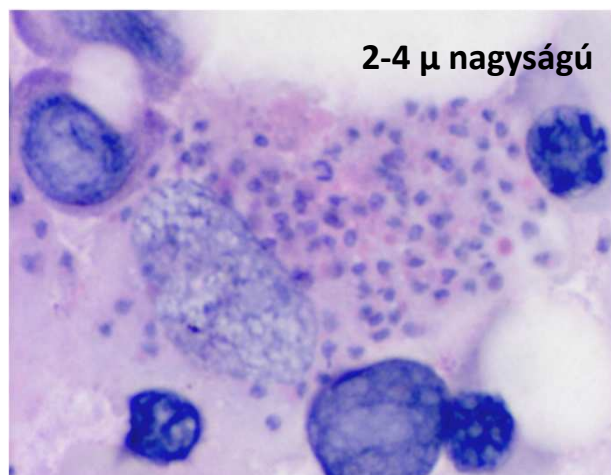


Intracellularis opportunista kórokozók

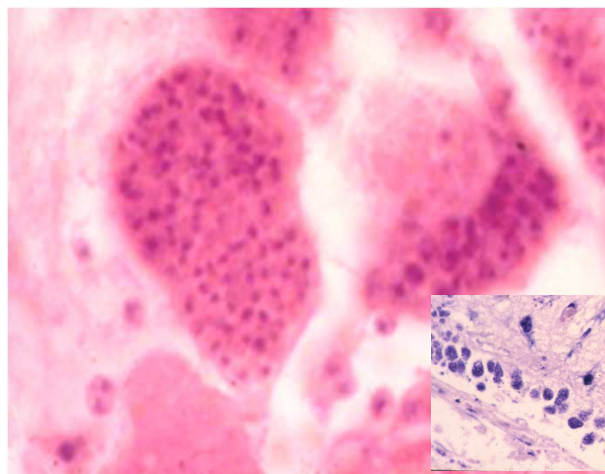
Leishmania donovani

Toxoplasma gondii

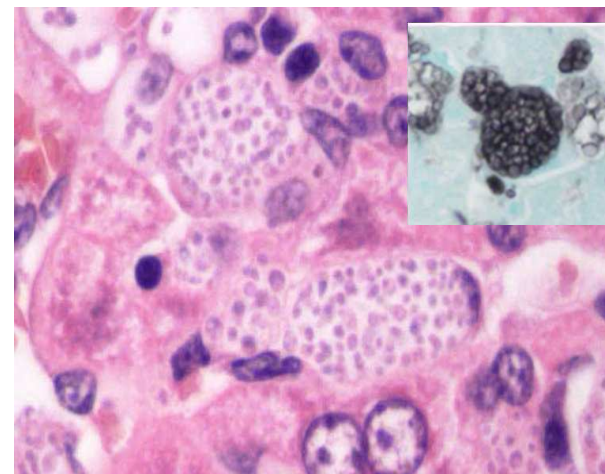
Histoplasma capsulátum



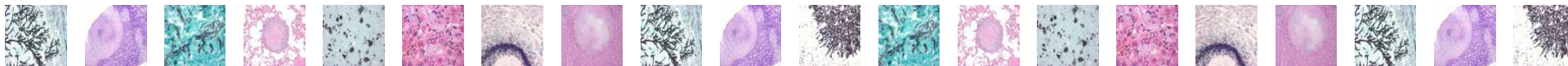
HE +
 Giemsa +
 PAS -
 Grocott -
 Kinetoplast
 Hepato-splenomegalia



HE +
 Giemsa +
 PAS -
 Grocott -
 Extracellularisan is van
 Agy – gócos
 necrosis/encephalitis



HE +
 Giemsa +
 PAS +
 Grocott +
 Hepato-splenomegalia

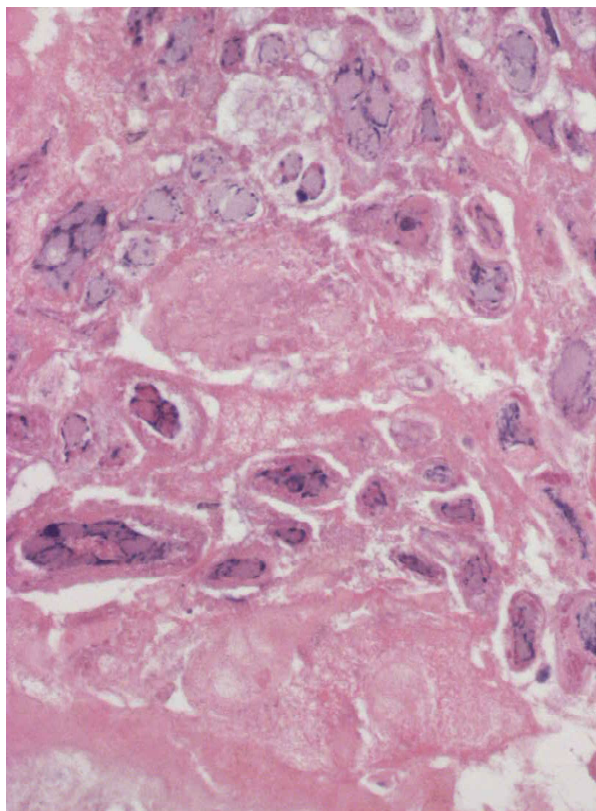


Vírus zárványok

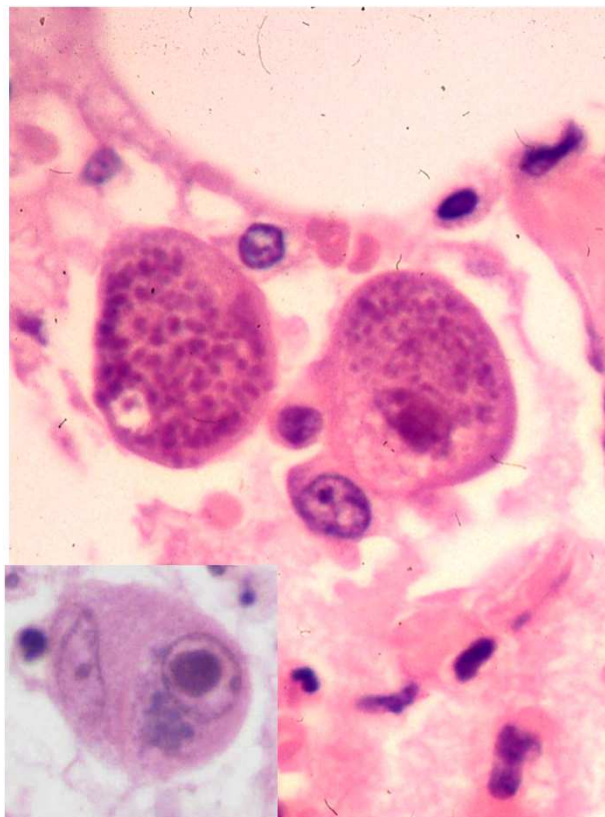
Herpes simplex

Cytomegalovírus

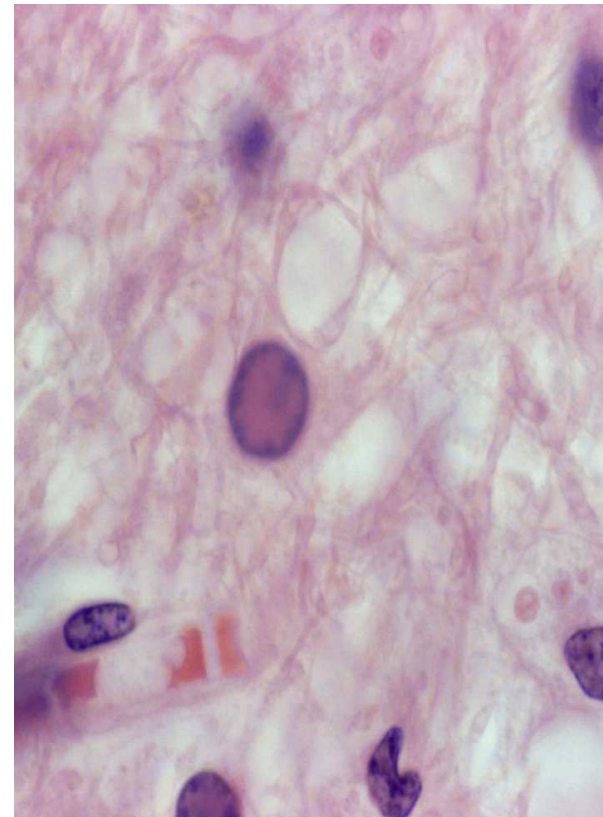
JC-BK polyomavírus



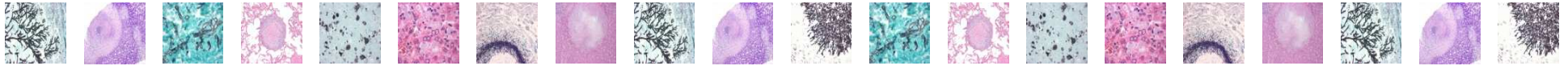
bőr
generalizált



tüdő
colitis



leukoencephalopathia
haem. cystitis



„Metamorphosis” – immun rekonstrukciós szindróma

