

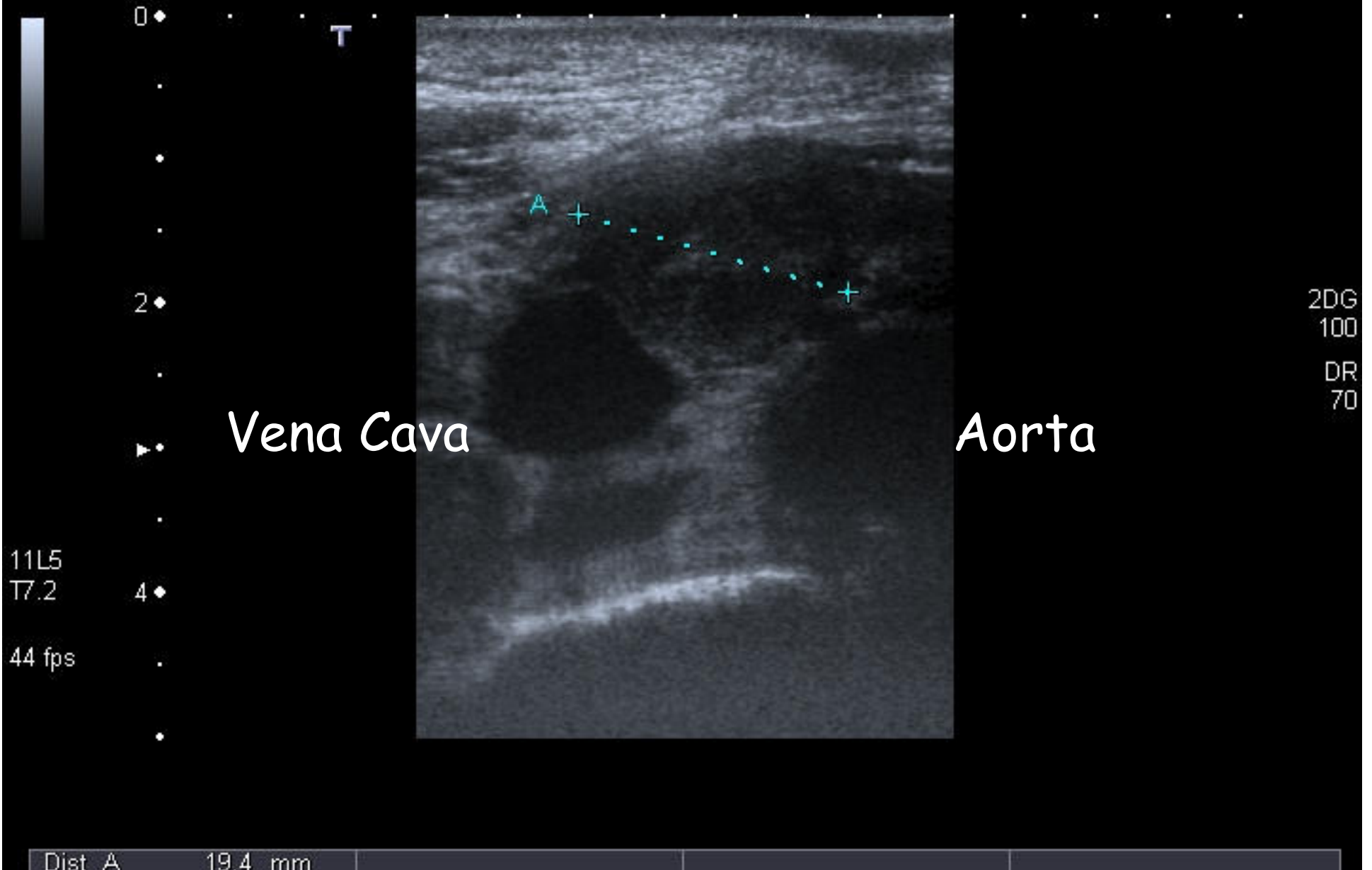
Retroperitoneális terime: aspirációs cytológiai vonatkozások



Székely Eszter
Járay Balázs
Istók Roland
Székely Tamás

S.E. II. Path. Int.

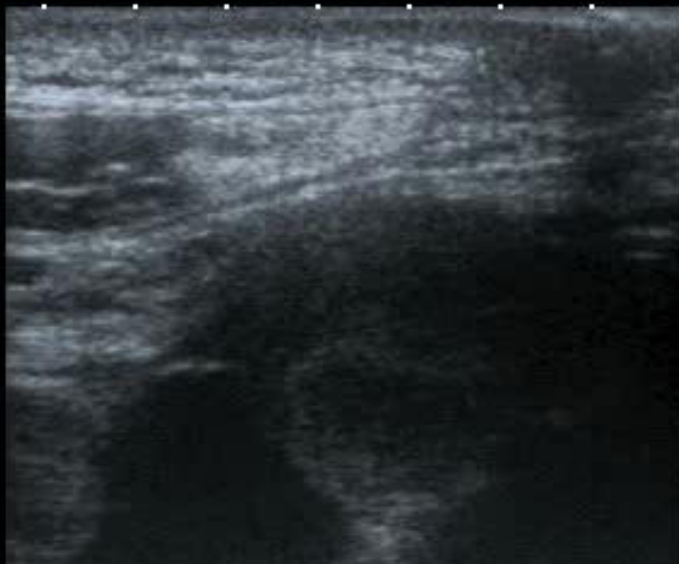Hol van a laesio ?



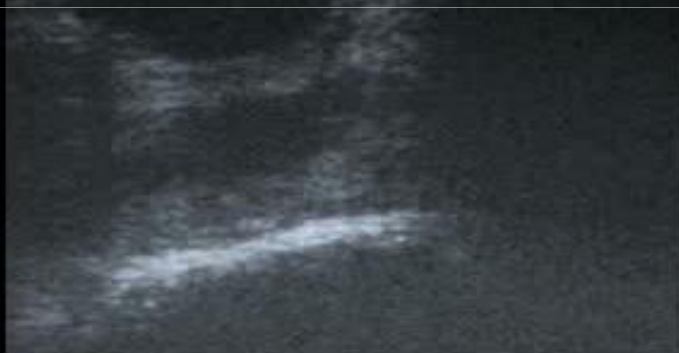

0 ◆

T



2 ◆



11L5
T7.2

4 ◆

44 fps

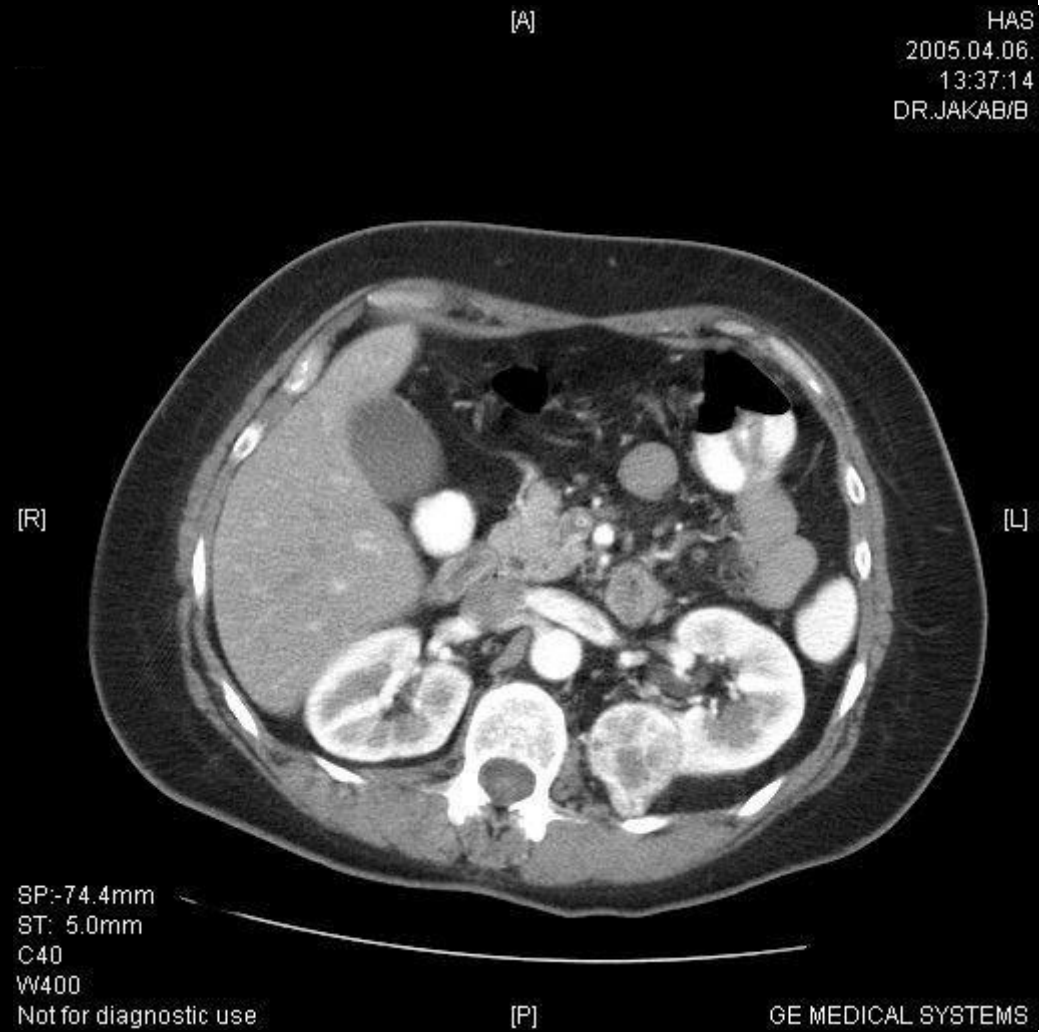
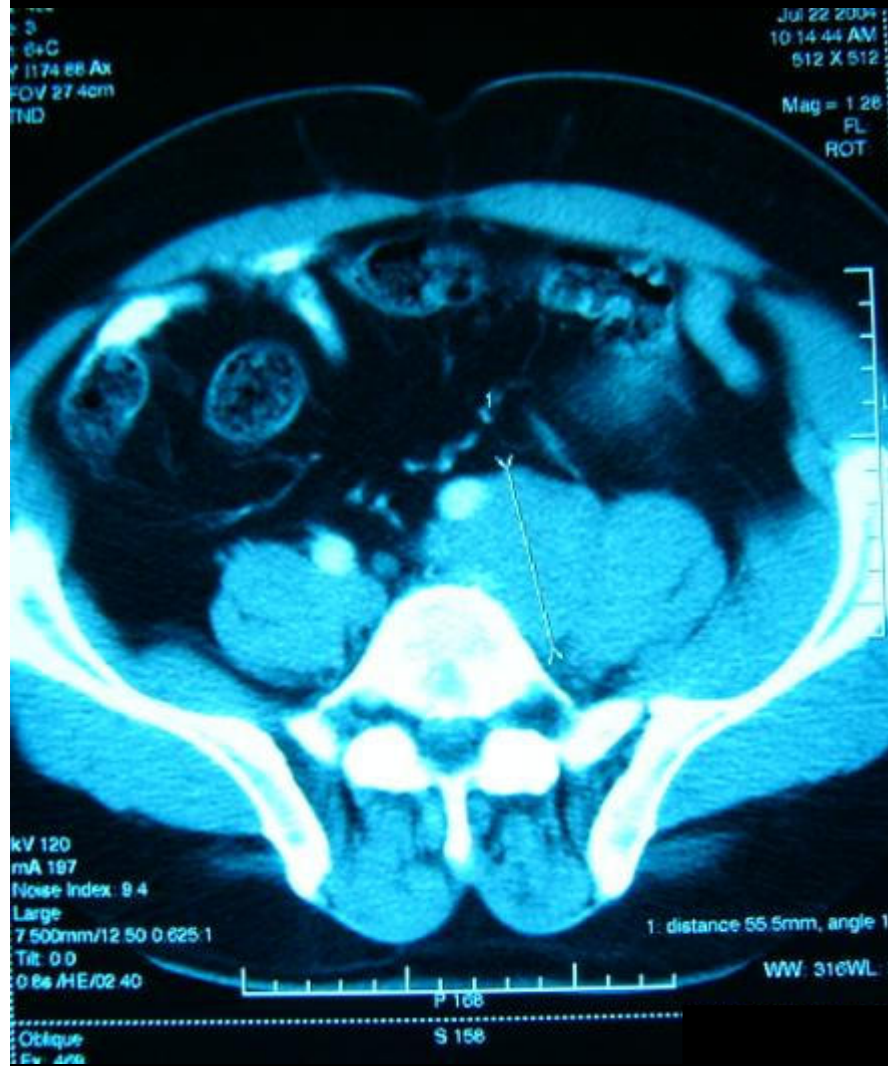MI:0.9

2DG
100

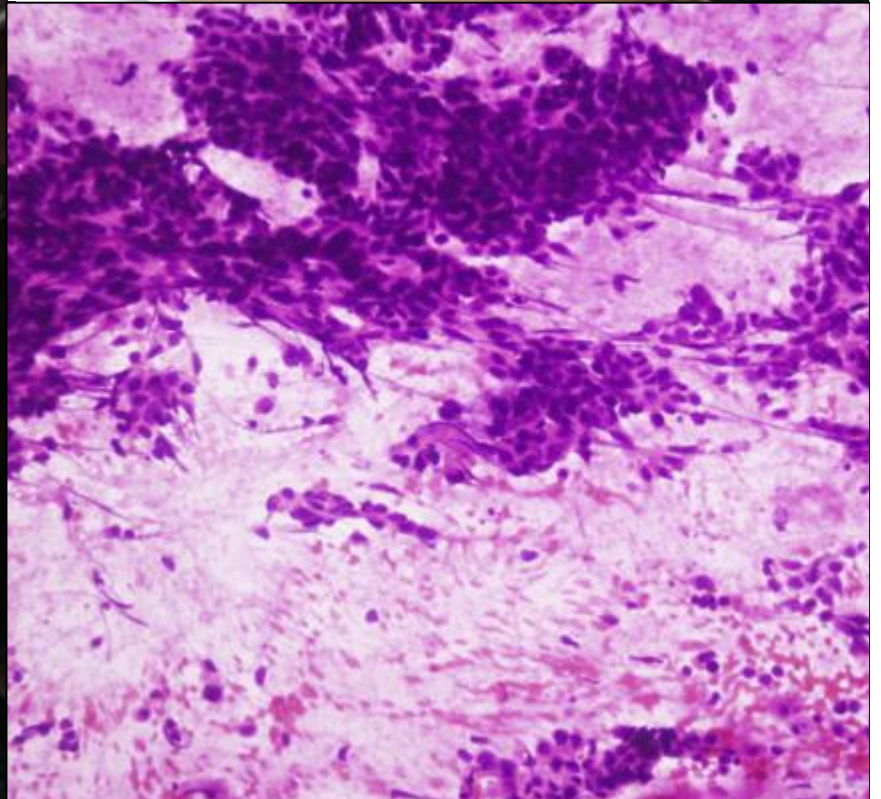
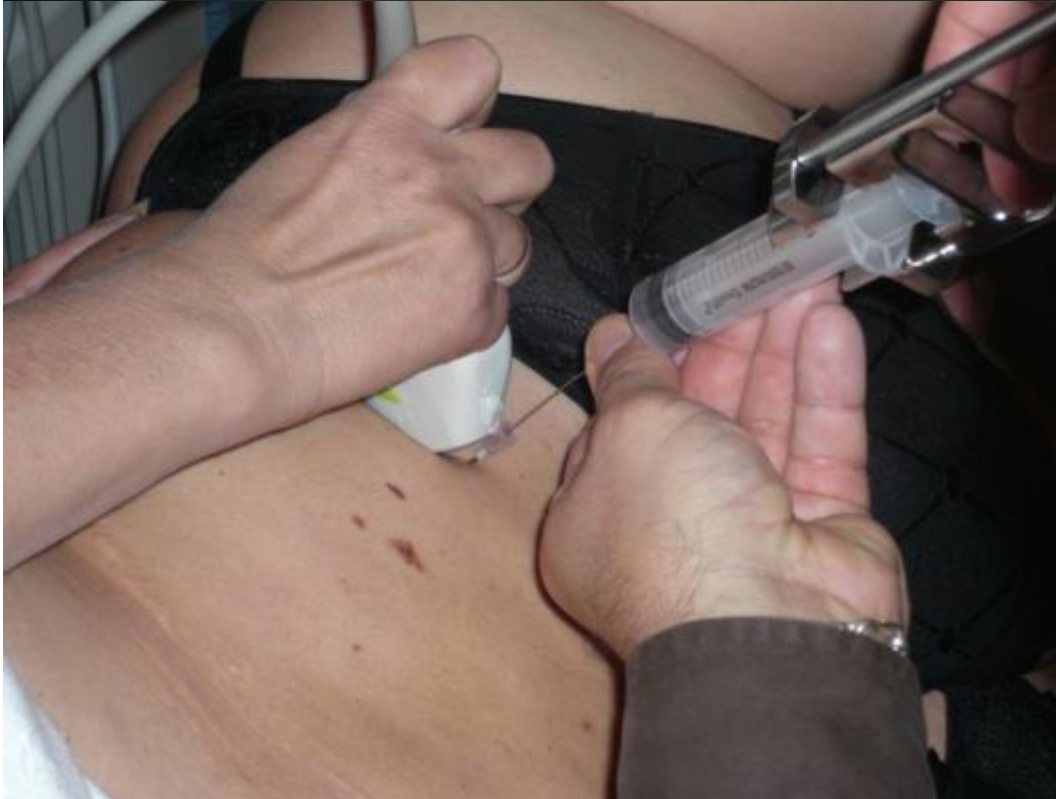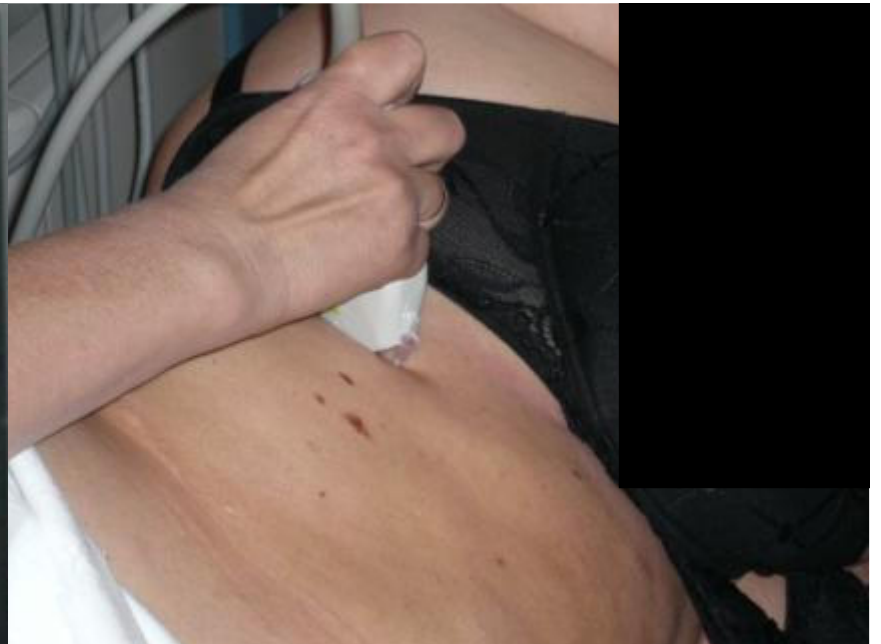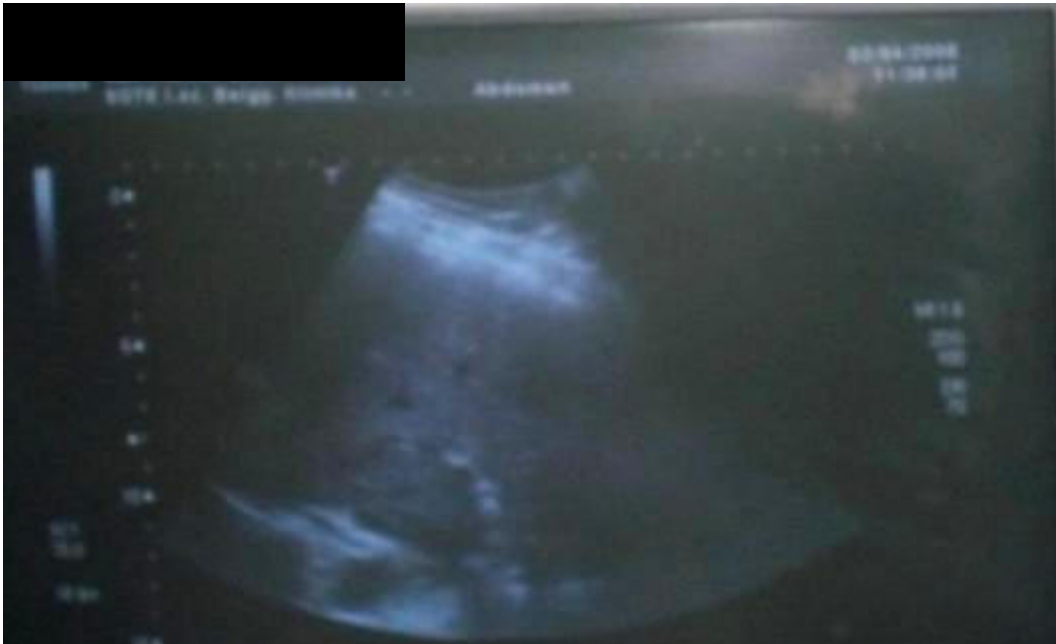DR
70



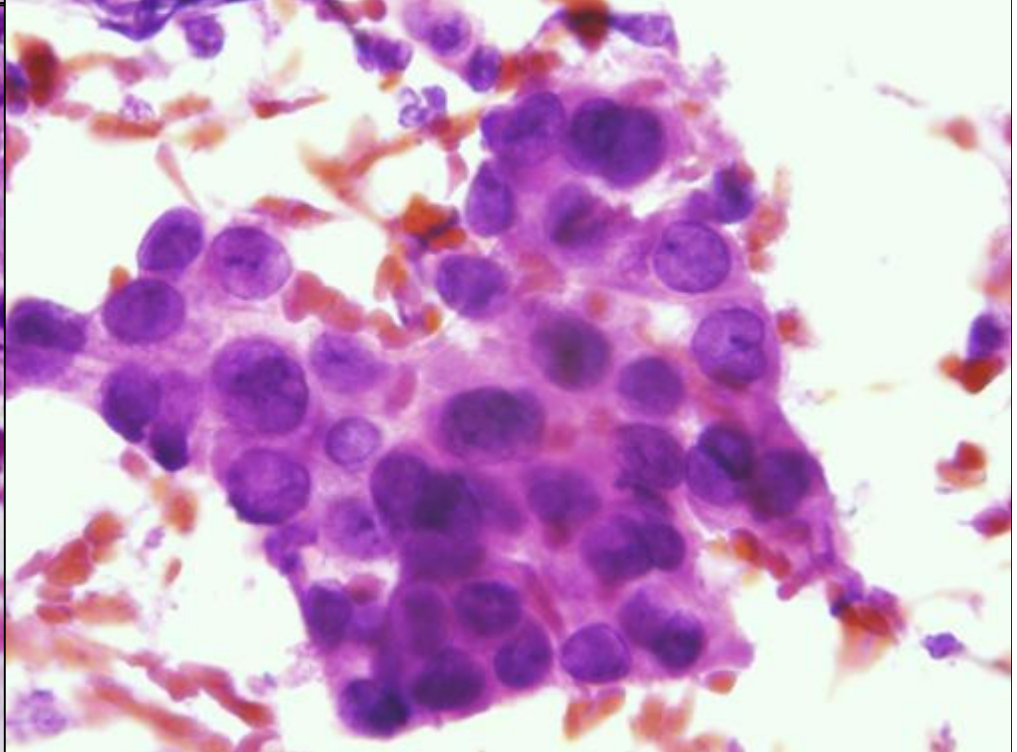
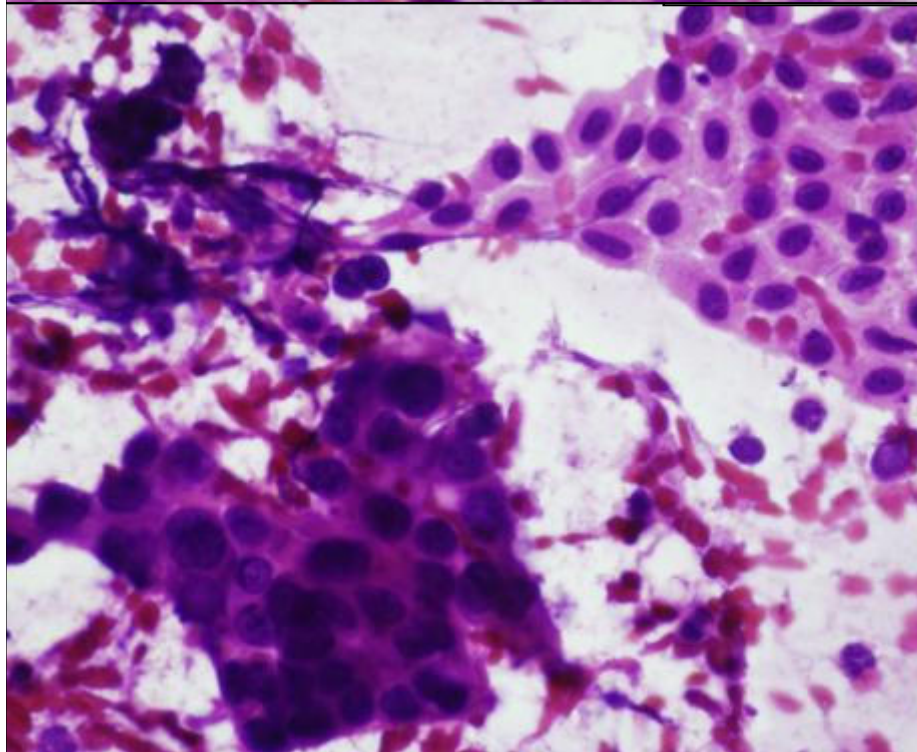
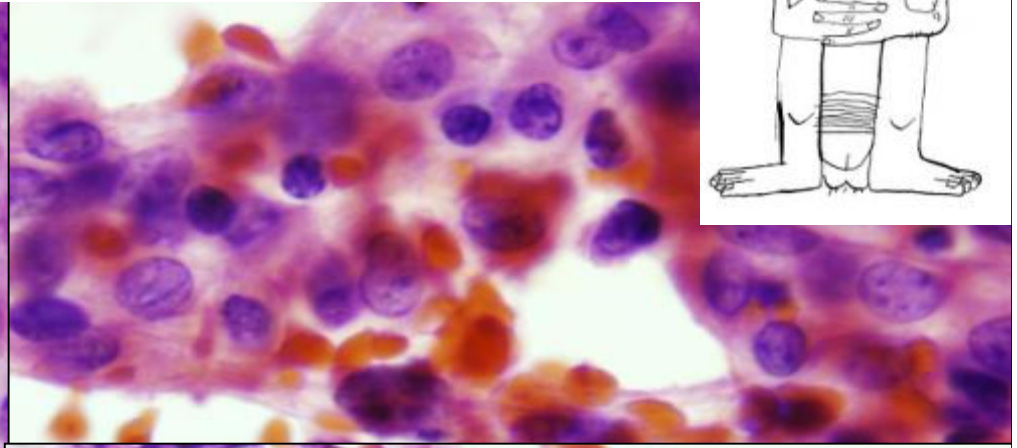
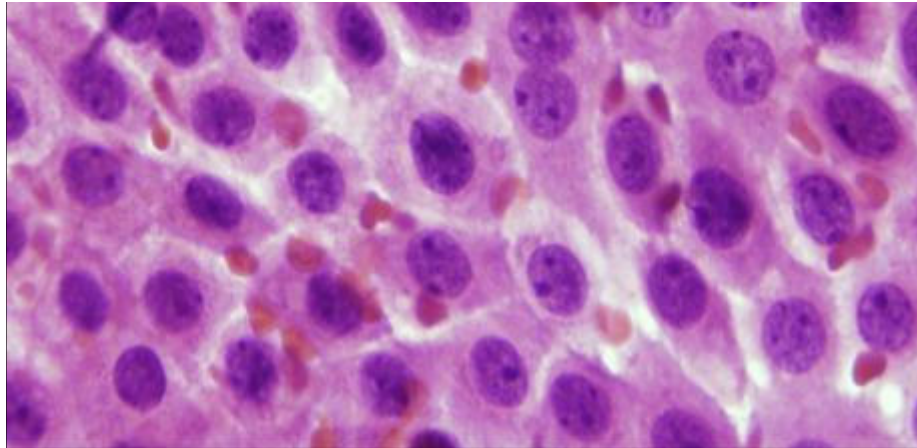

MÉLYSÉG







A mesothel, mint mumus



Minimum feltételek

Megfelelő UH készülék

Jól behatárolható elváltozás (-)

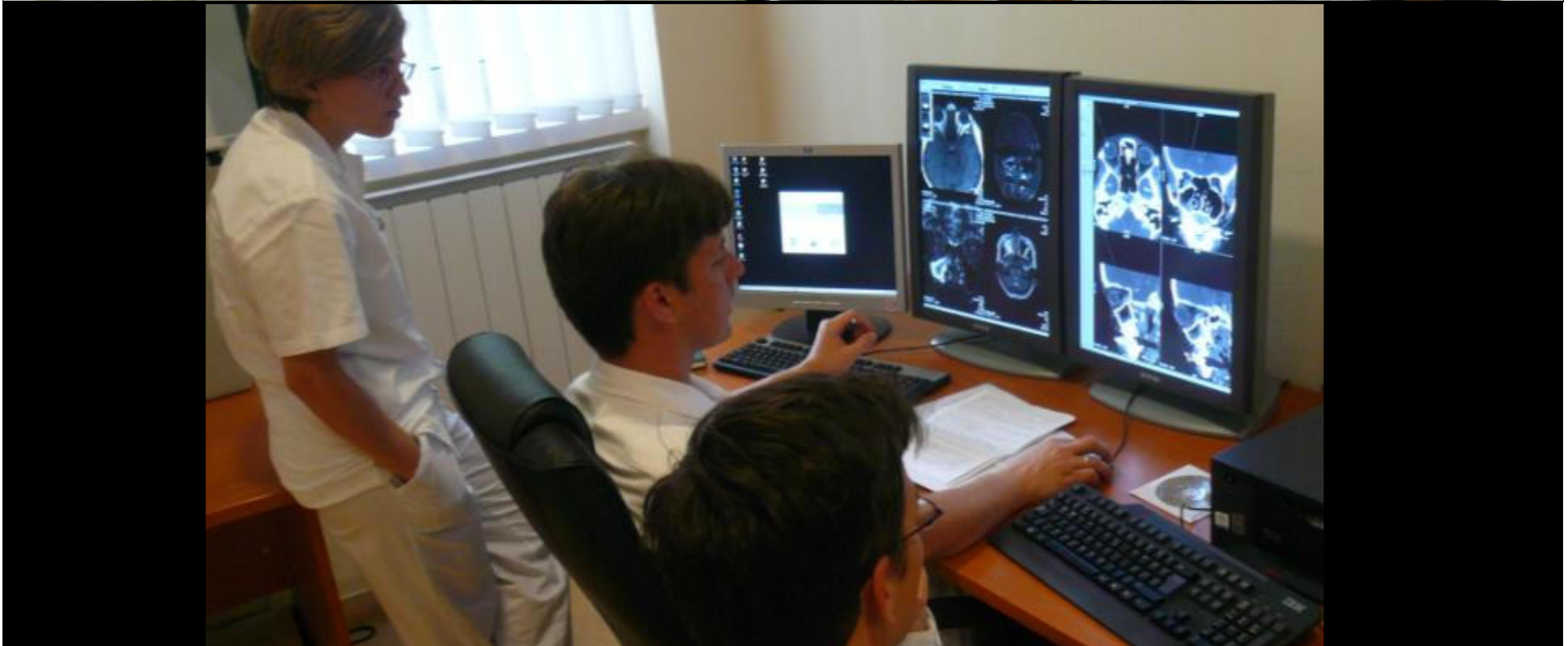Prothrombin szint $\geq 70\%$

Kooperáló beteg

Minimum feltételek

Kell egy csapat

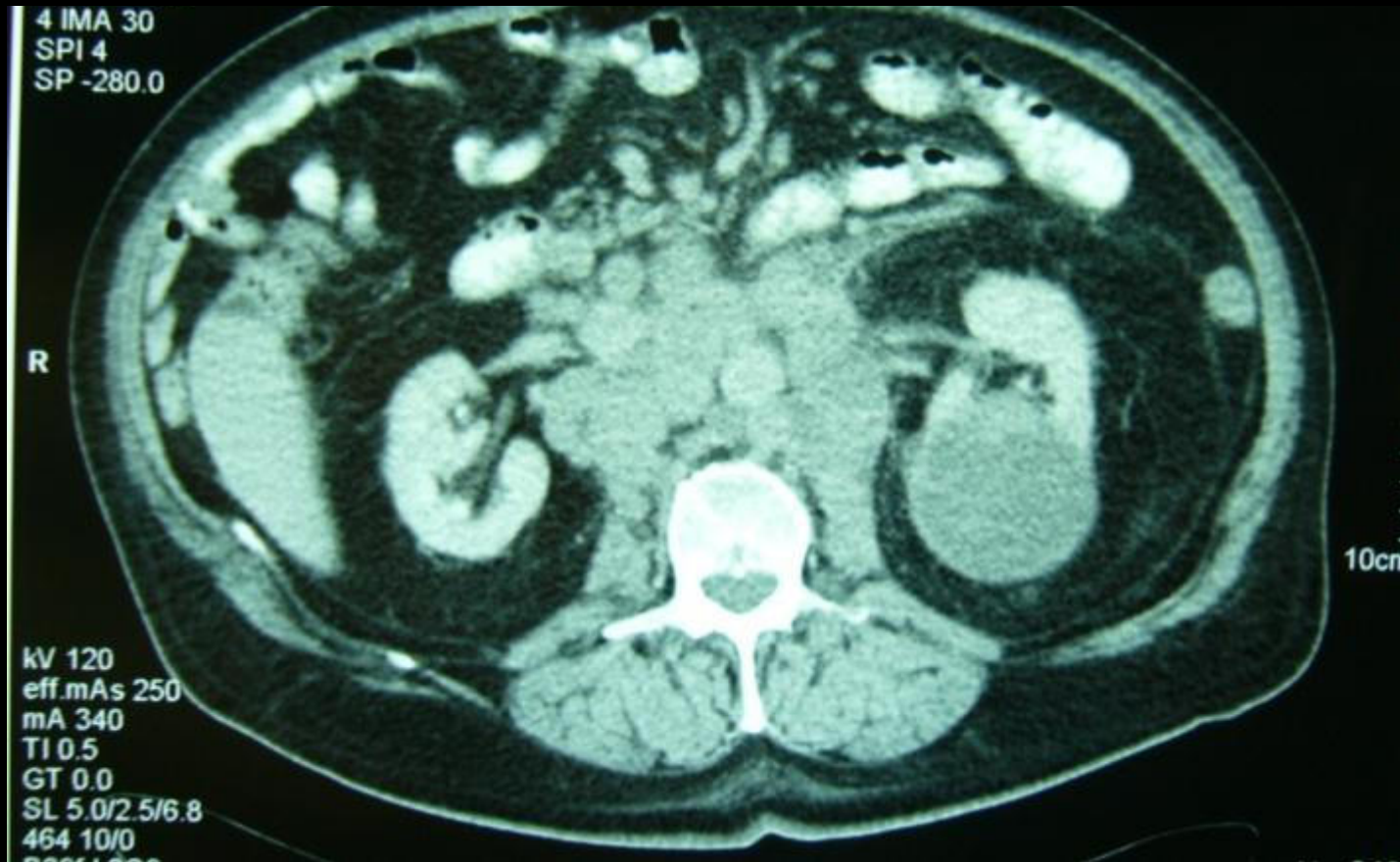

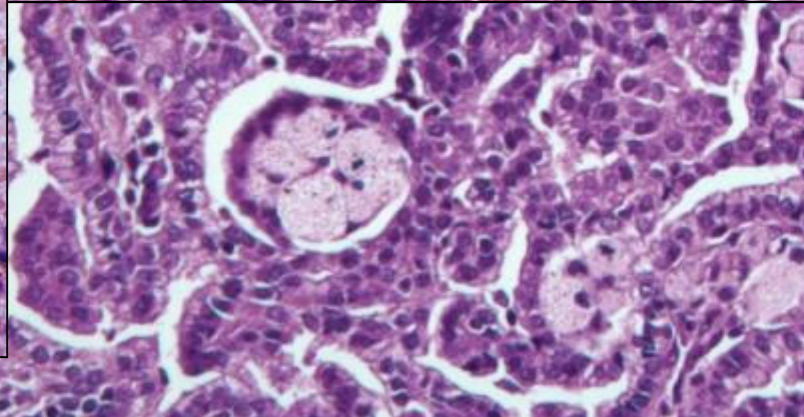
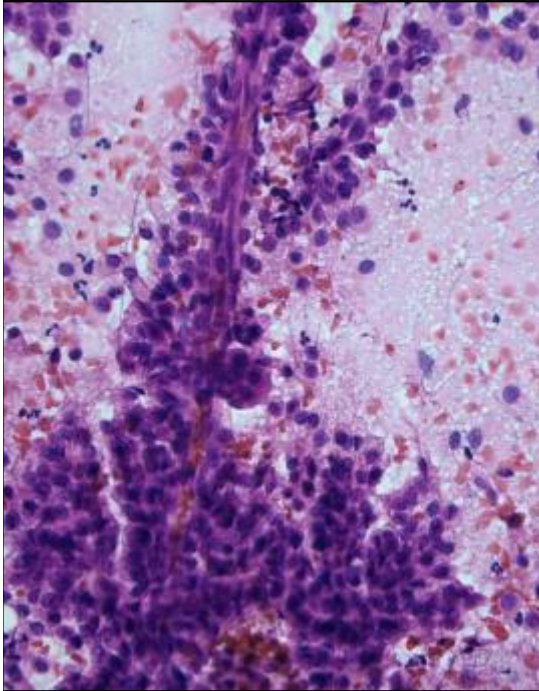
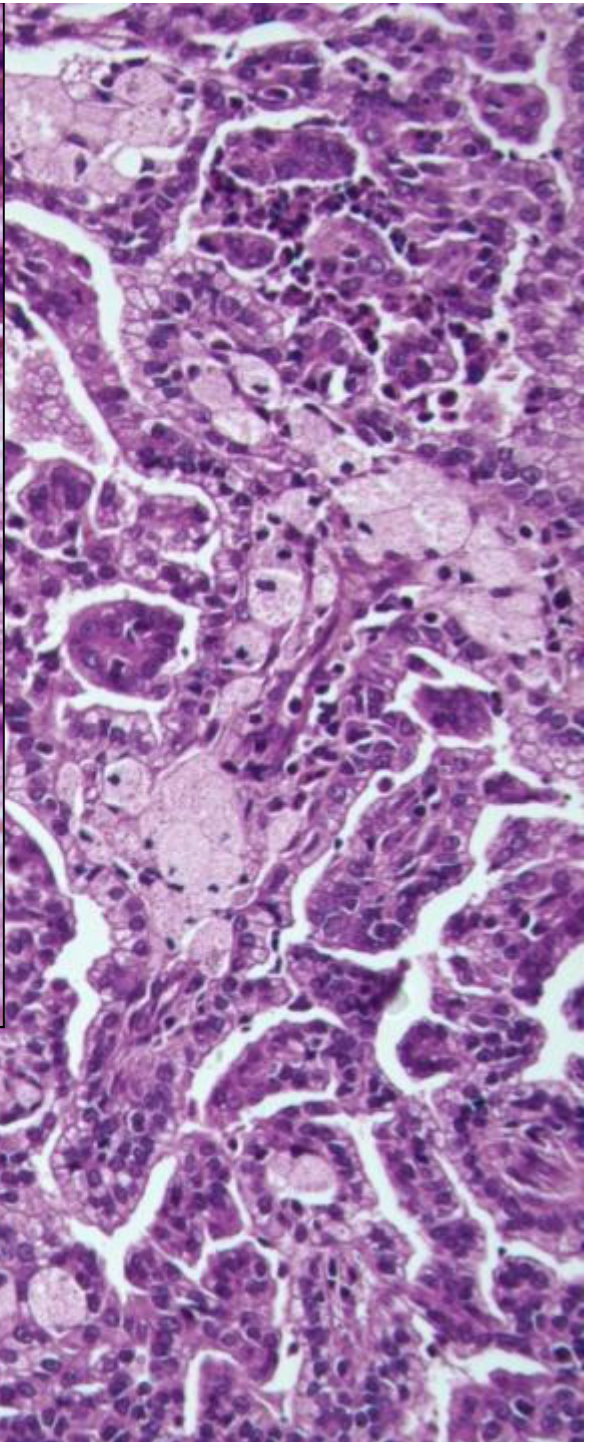
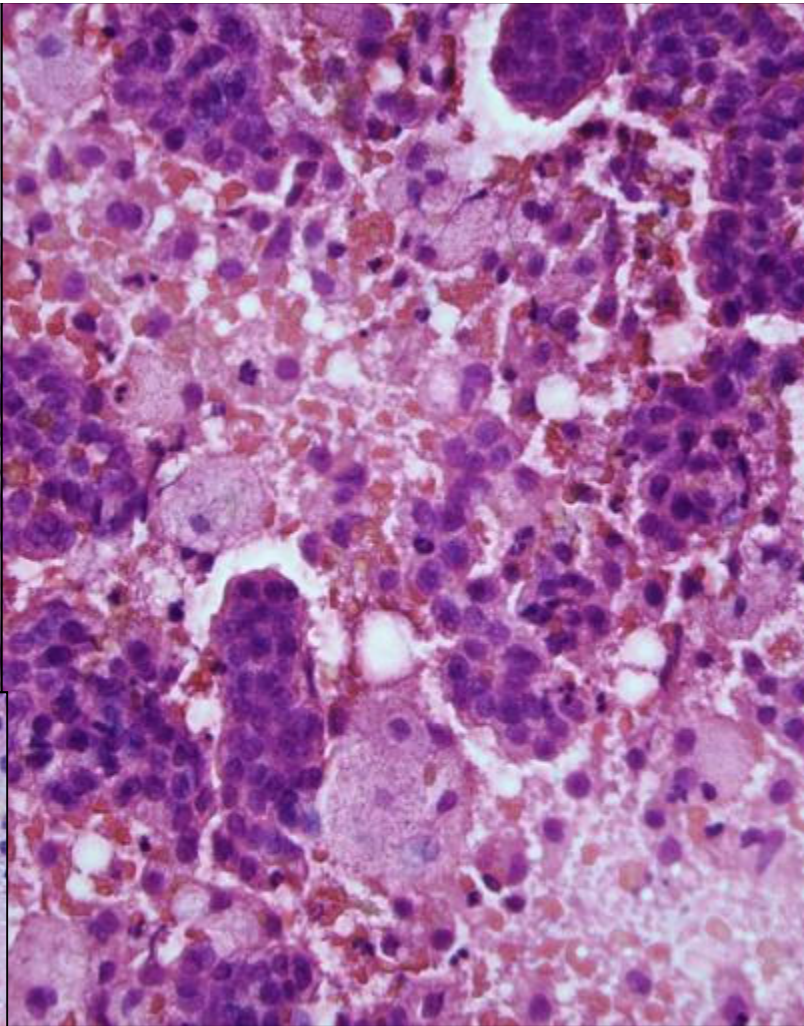
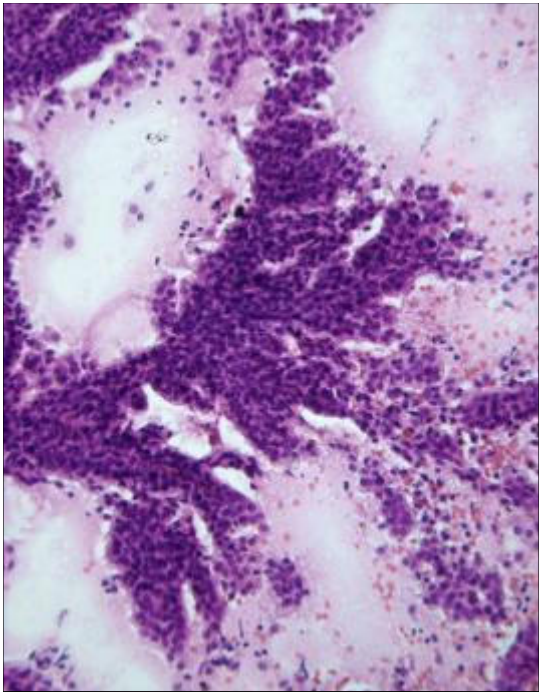


A mintavétel indikációi

- Véletlenül felfedezett terime
- Daganatos beteg újonnan megjelent laesiója
 - rec.,met.?
 - 2. primer?

Mi a veszélye annak, ha a markáns radiológiai leletben bízva nem történik mintavétel?





retroperitoneal lesion fine needle aspiration biopsy


38 találat

- sensitivity, specificity, and accuracy were 86%, 100%, and 91%,

respectively



A mintavétel mivel történjen?



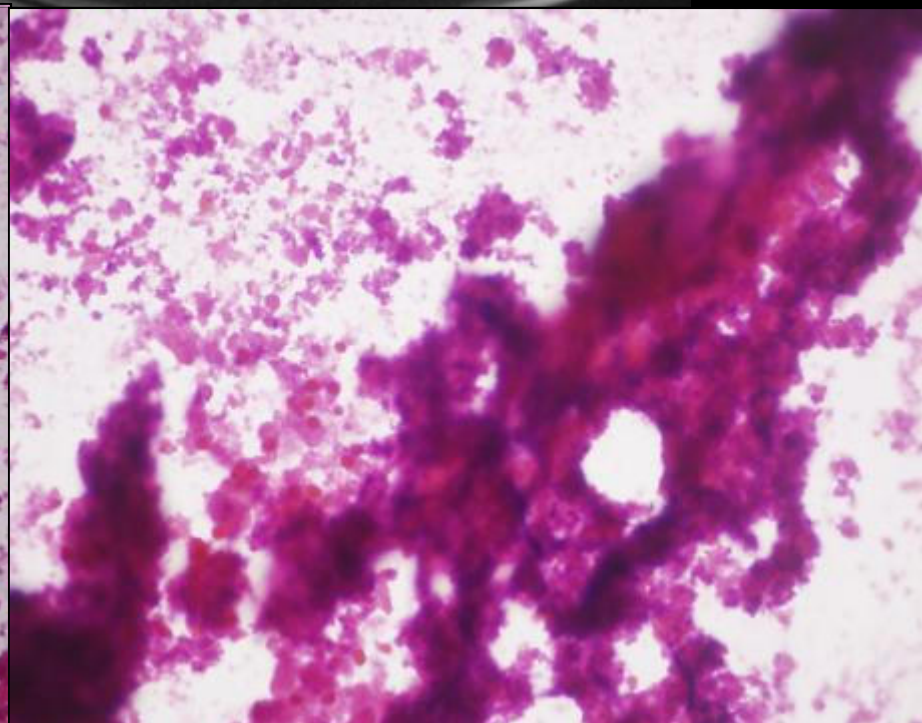
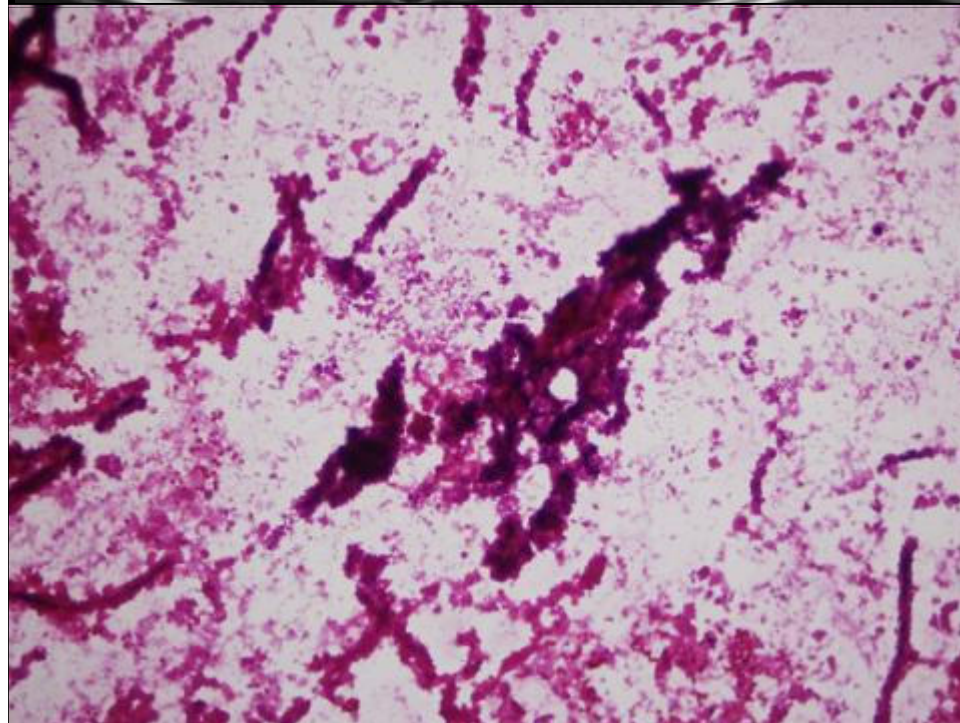
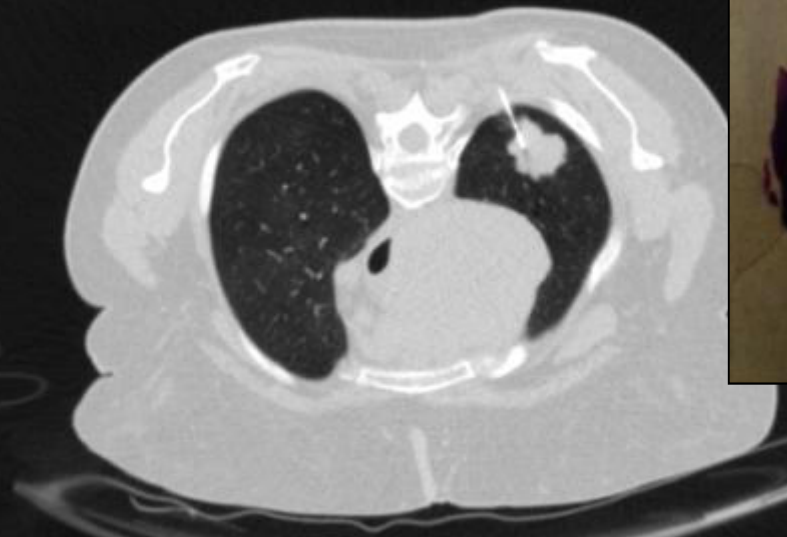
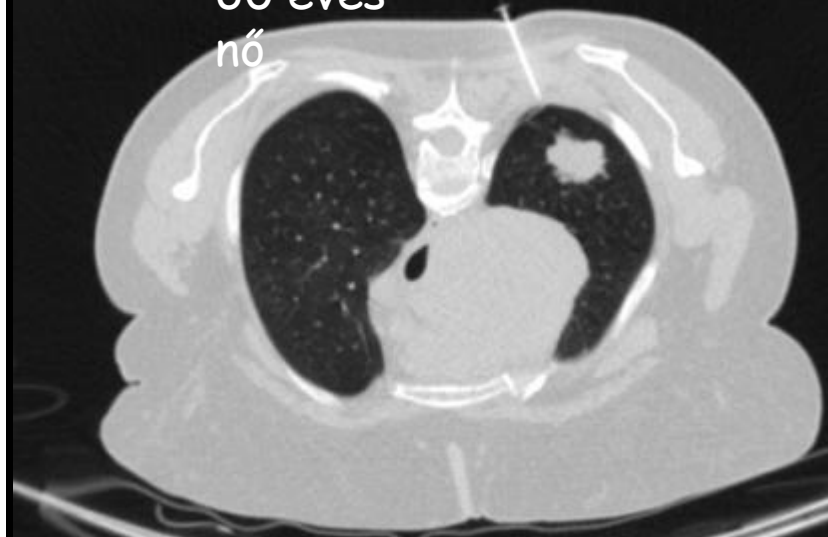CT?



UH?

A CT vezérelt szűrés

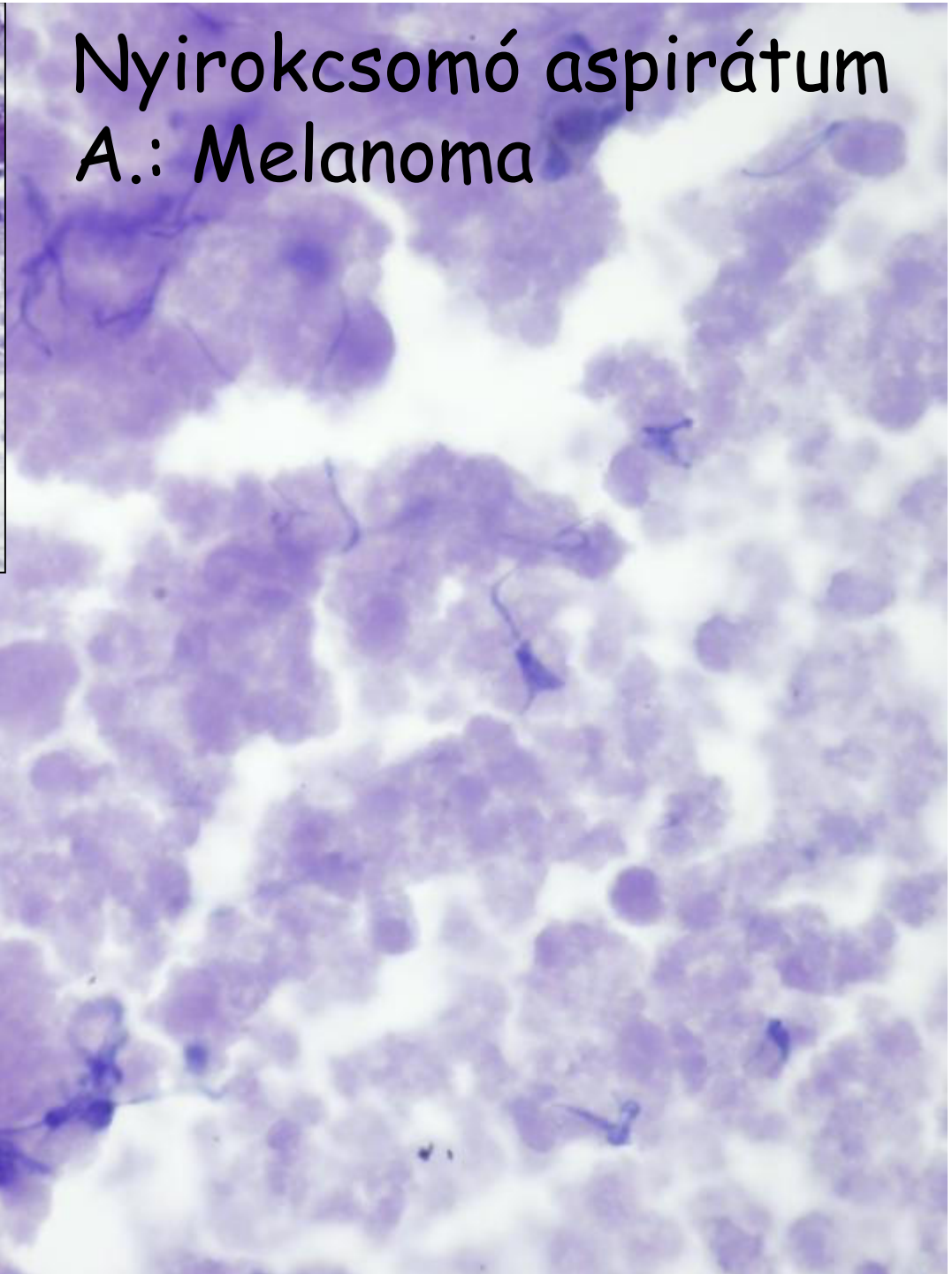
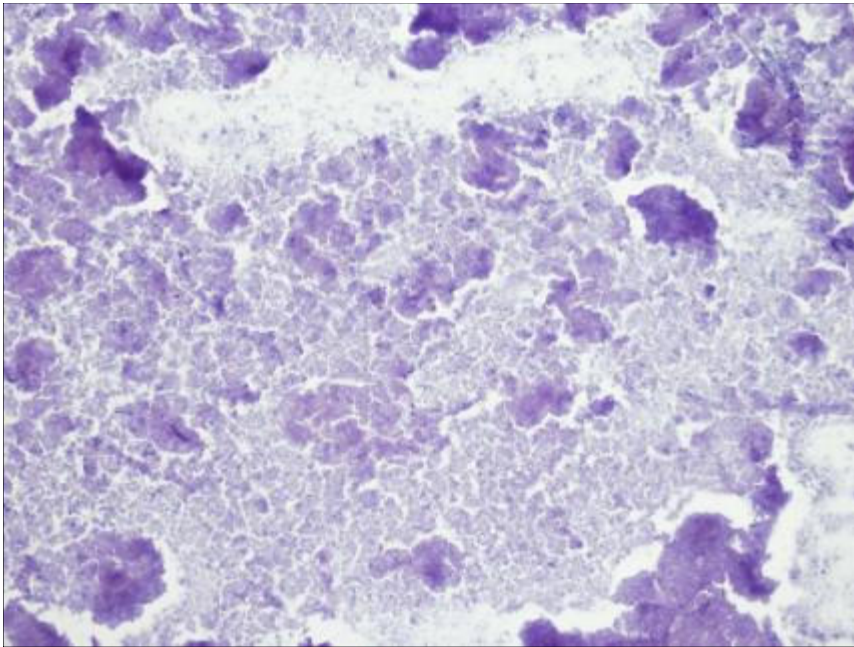
60 éves
nő





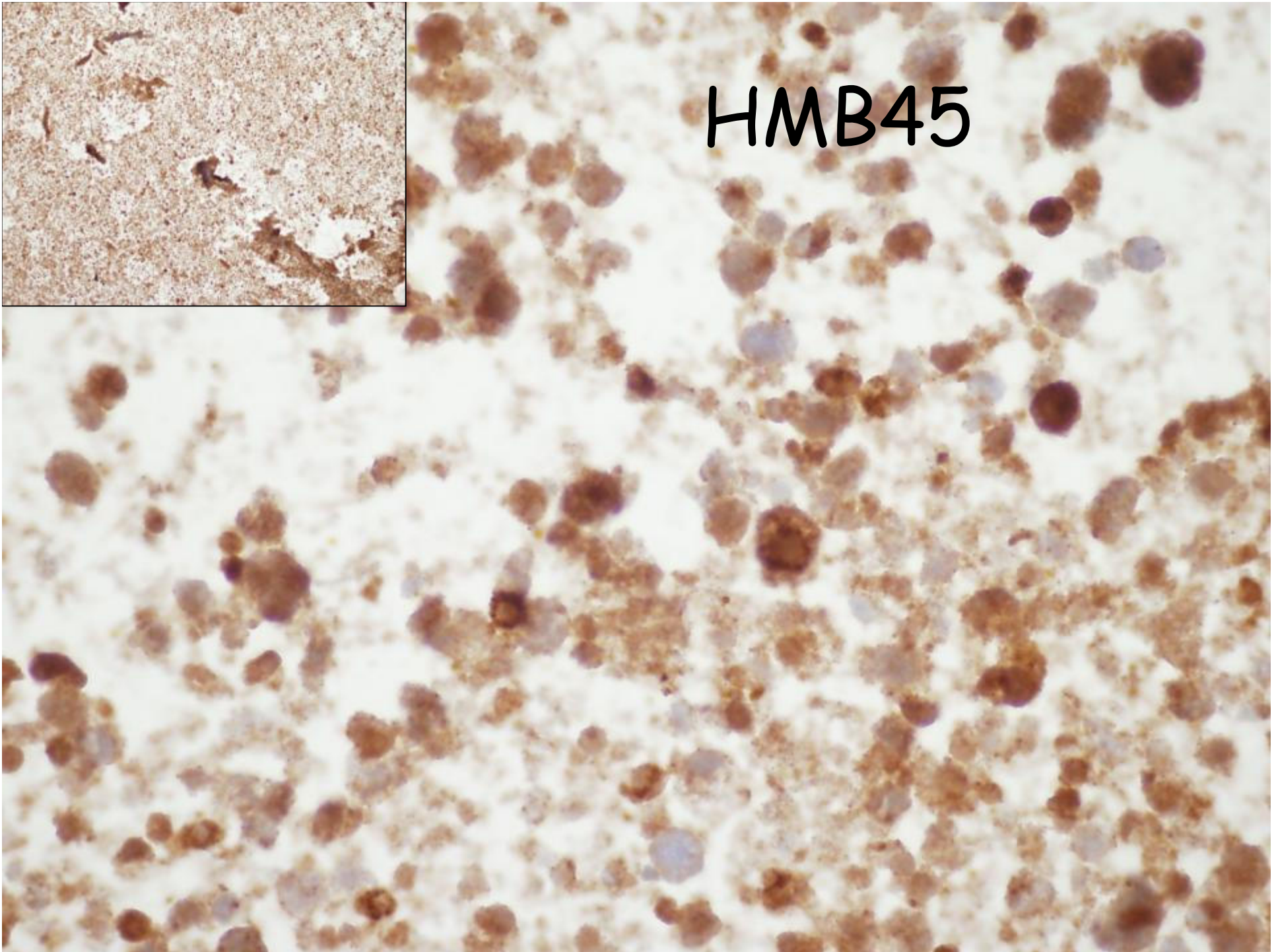
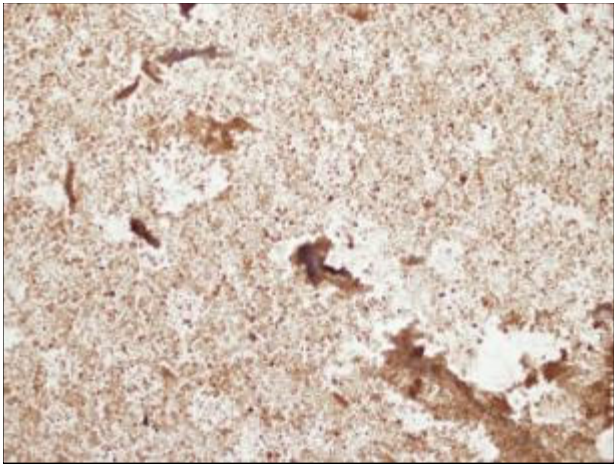
Nyirokcsomó aspirátum

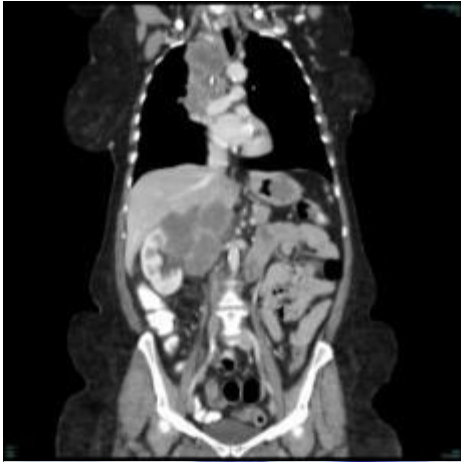A.: Melanoma



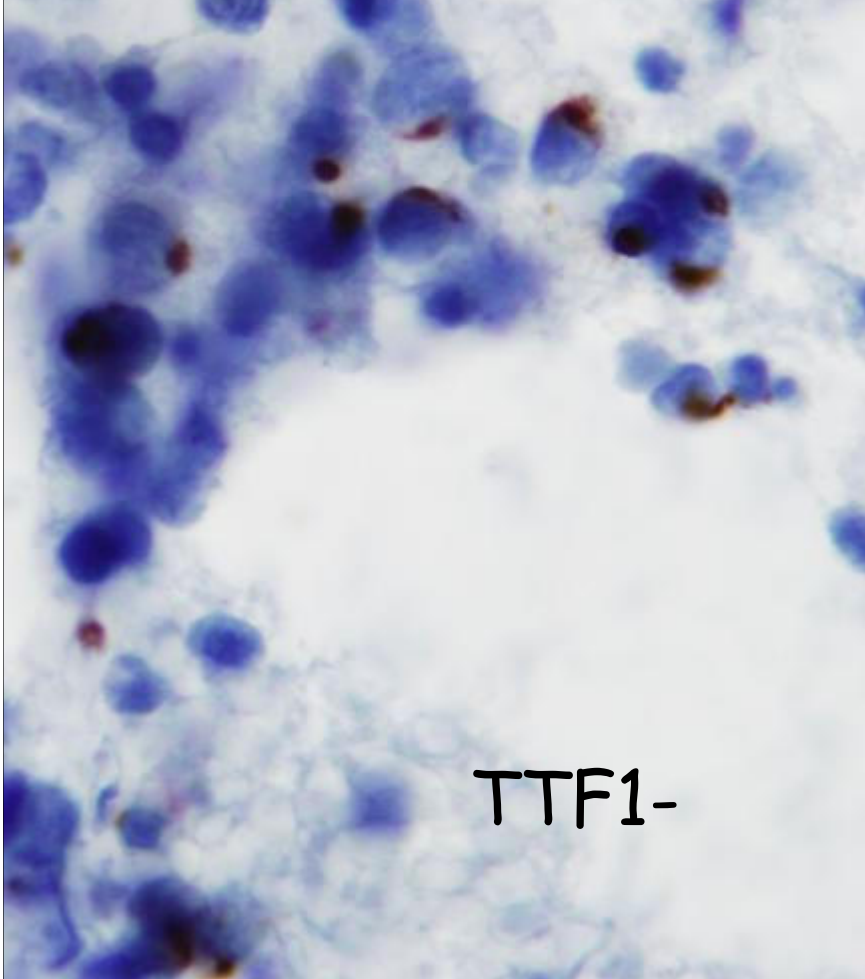
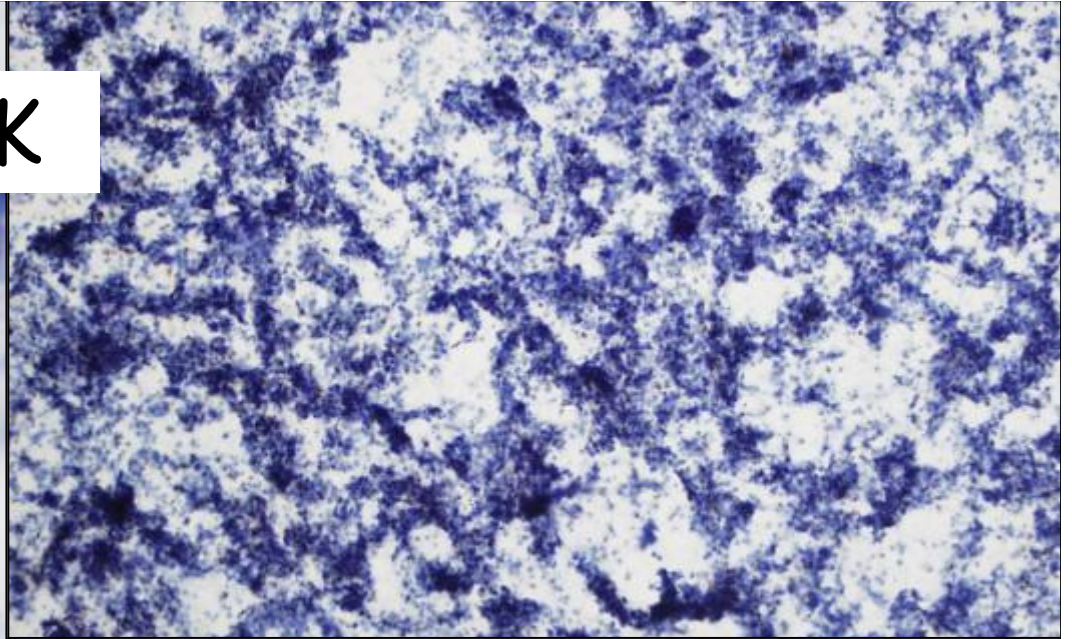
CK

HMB45

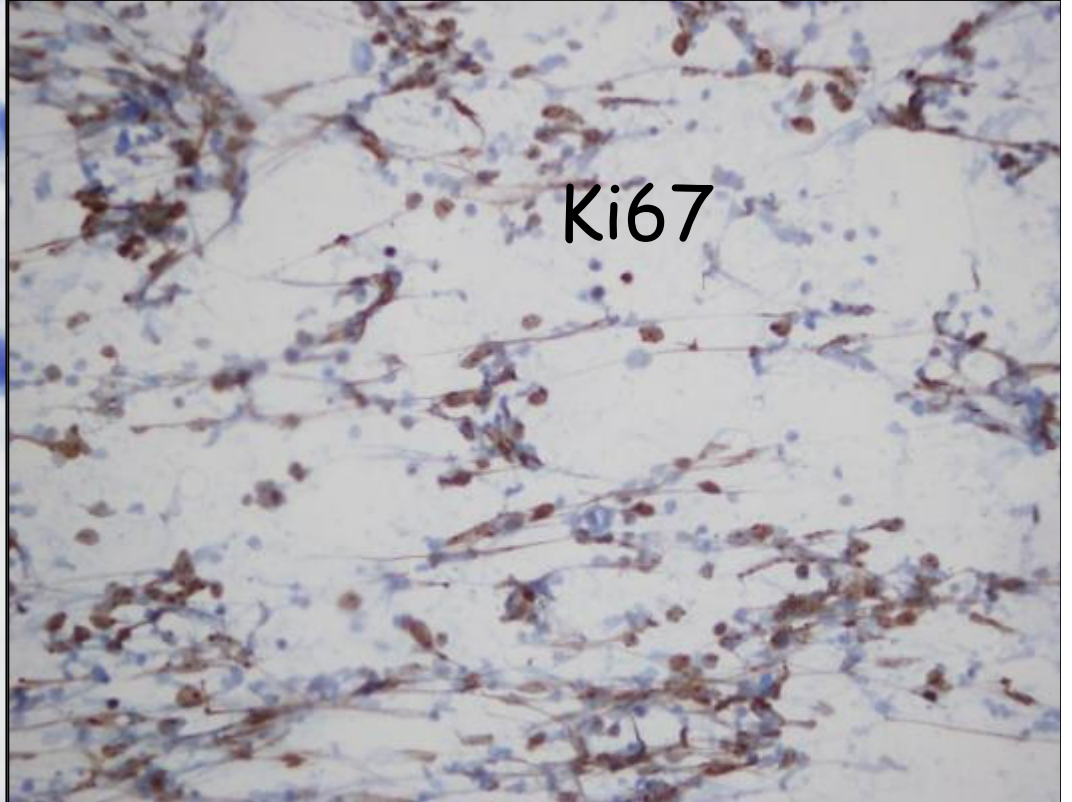




CK



TTF1-

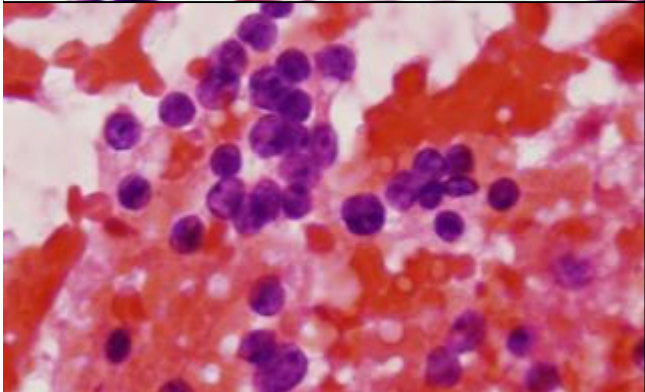
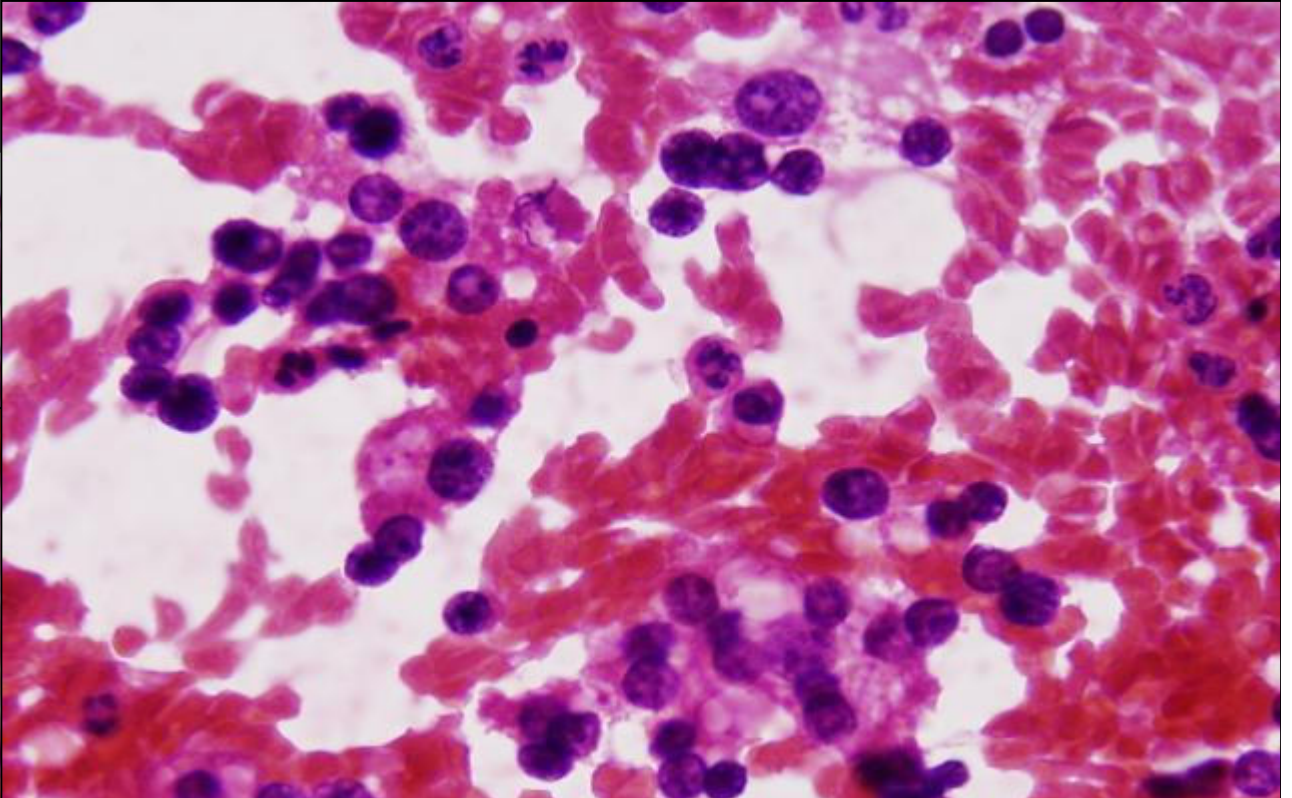
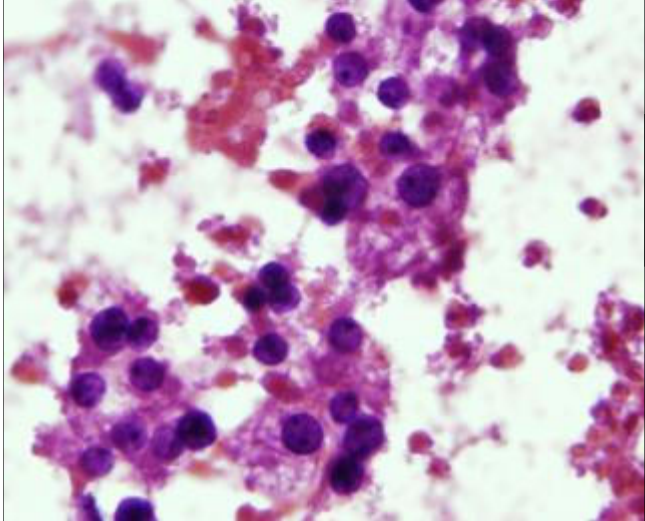
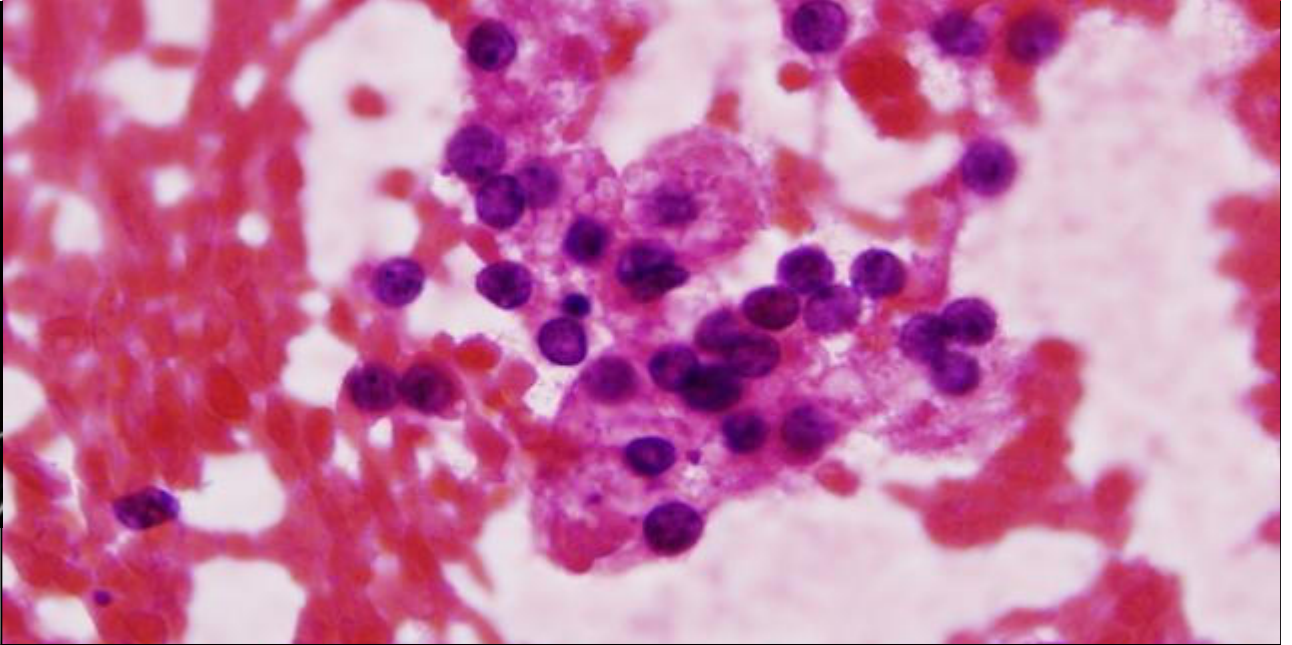
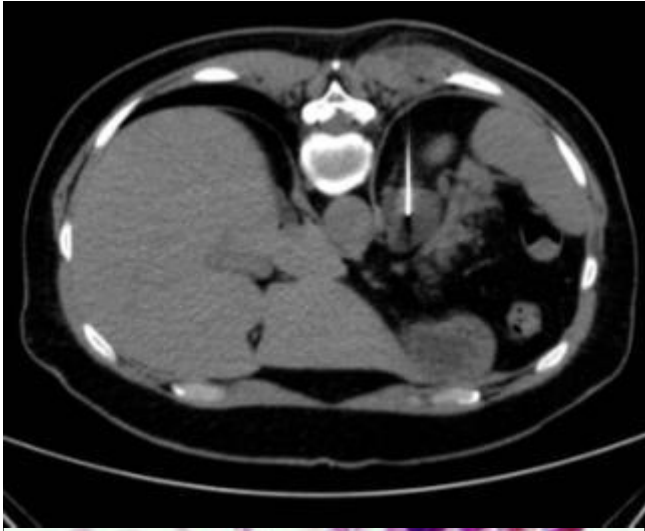


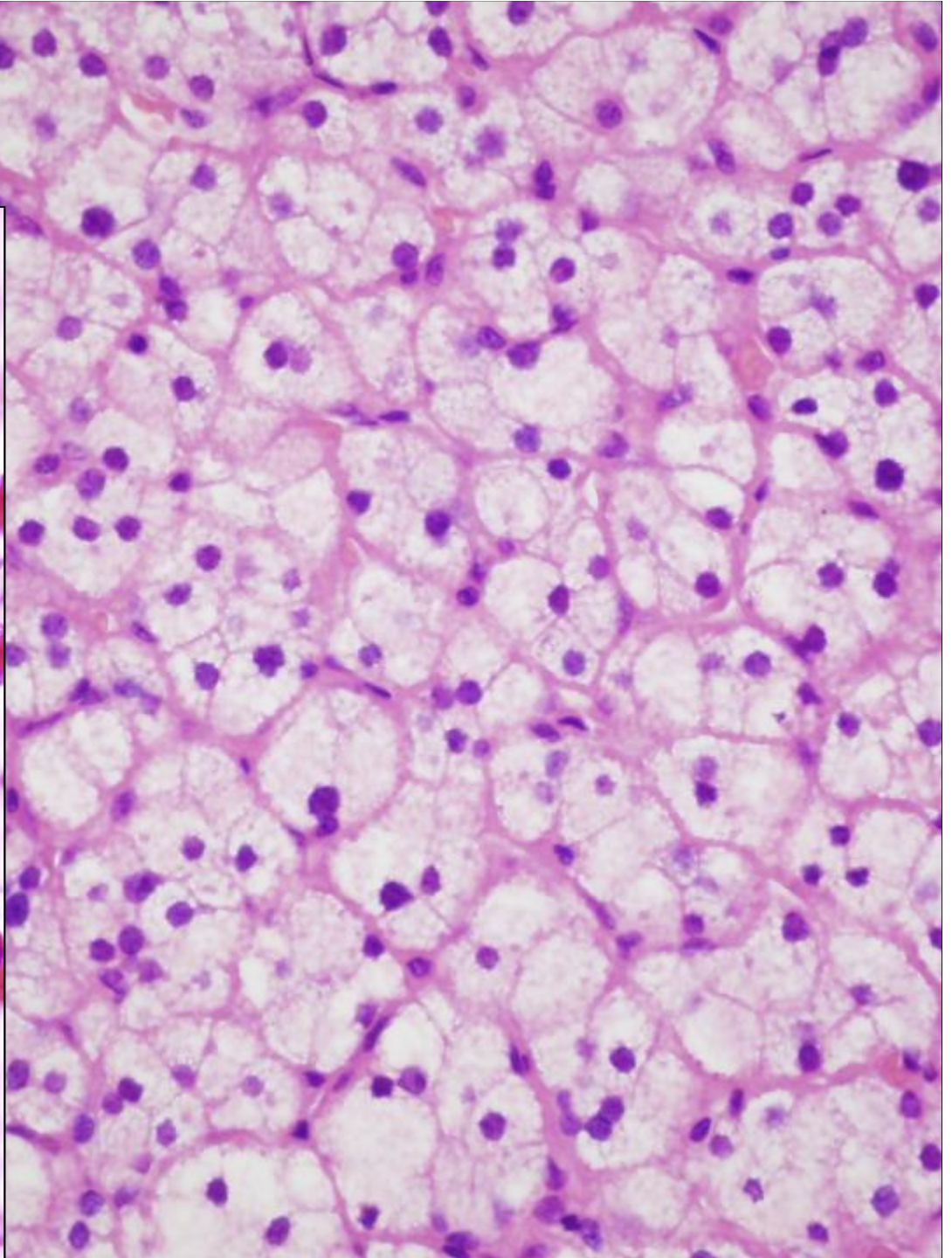
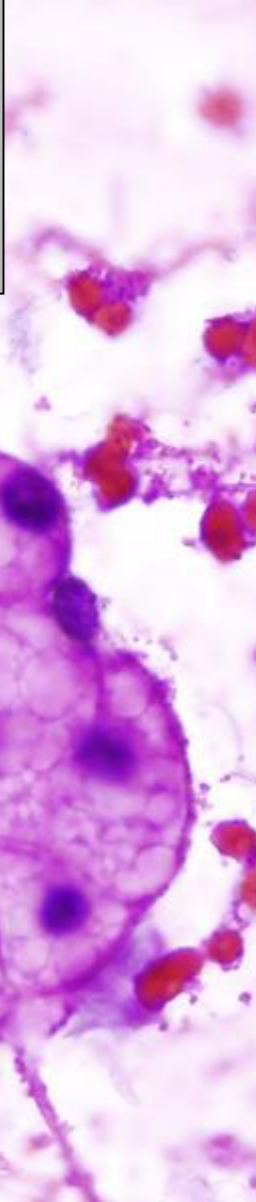
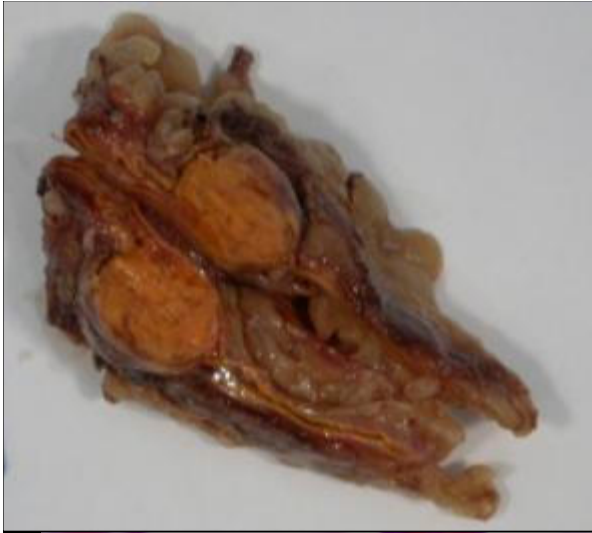Ki67

Az óvatosság veszélyei



Az IC reakciók értékelése nagyon körültekintően kell történjen!

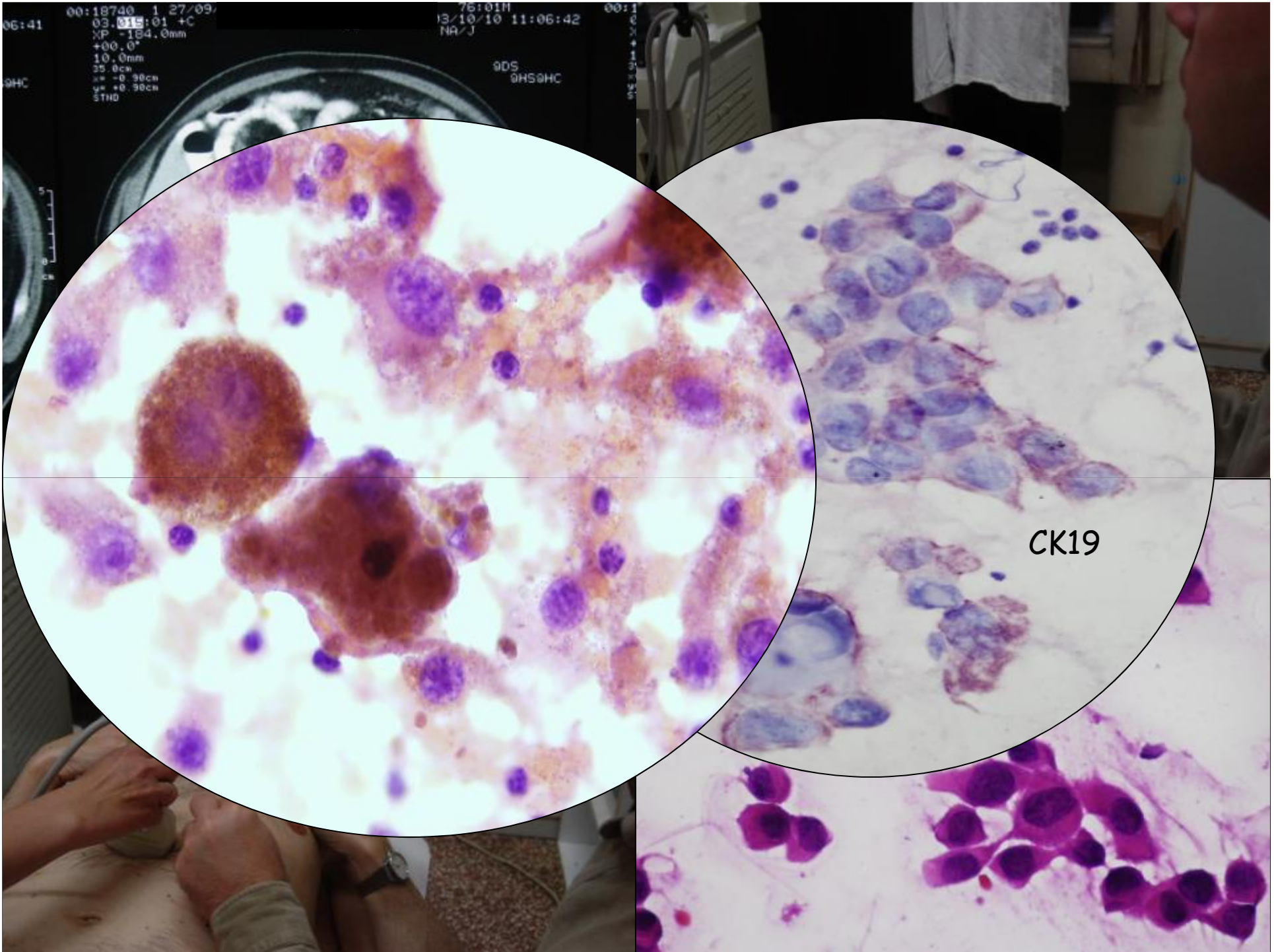



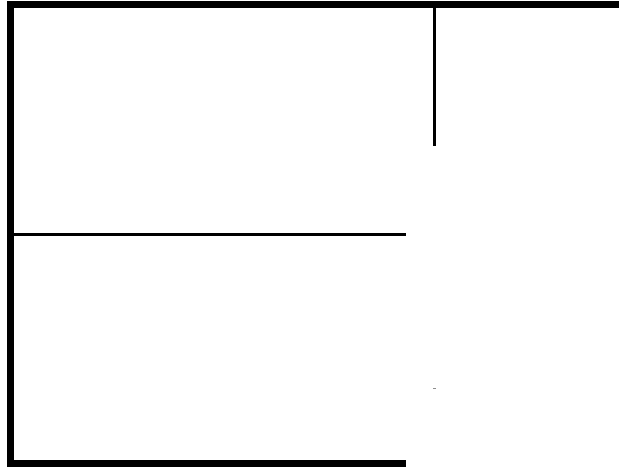



A retrop. mintavétel indikációi

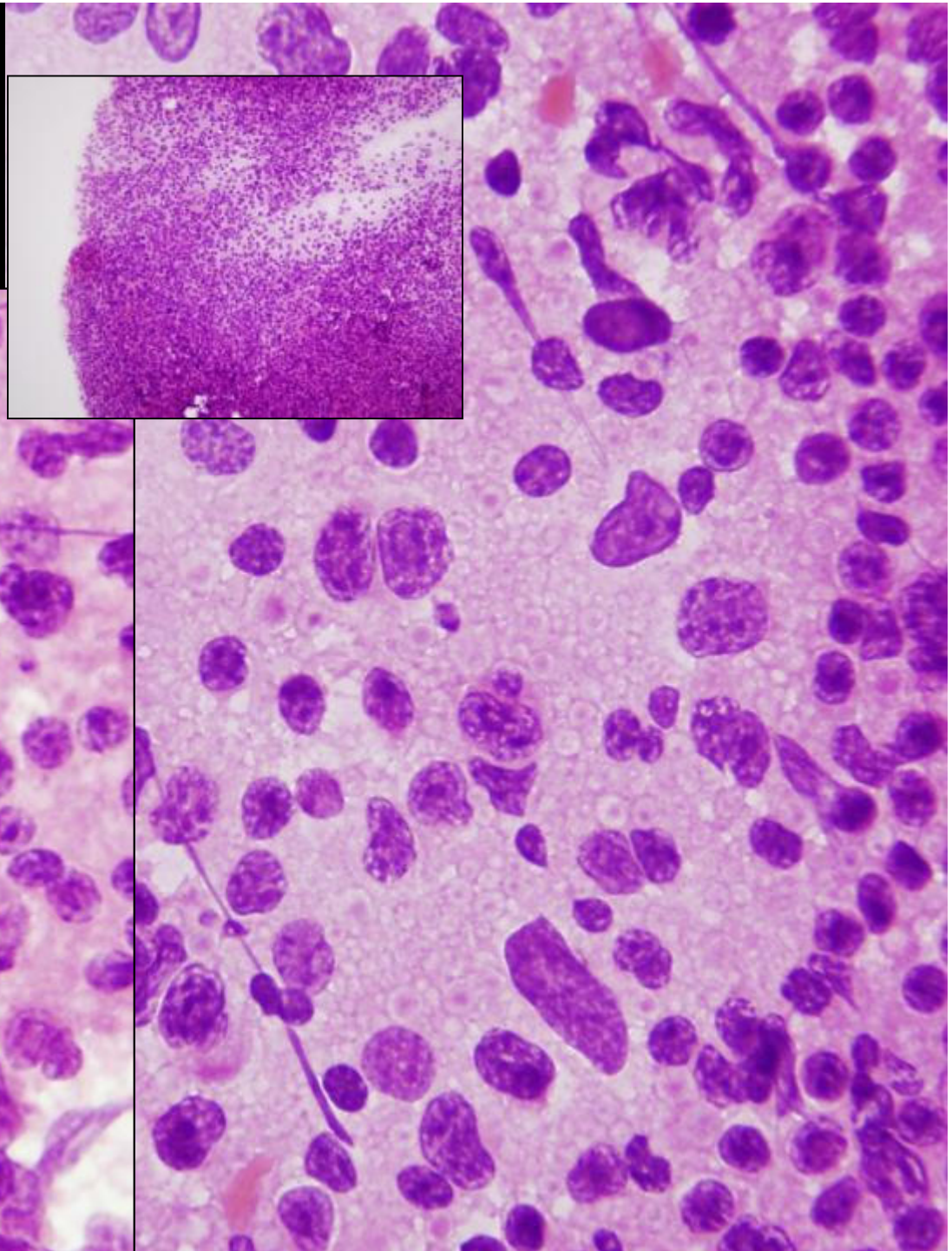
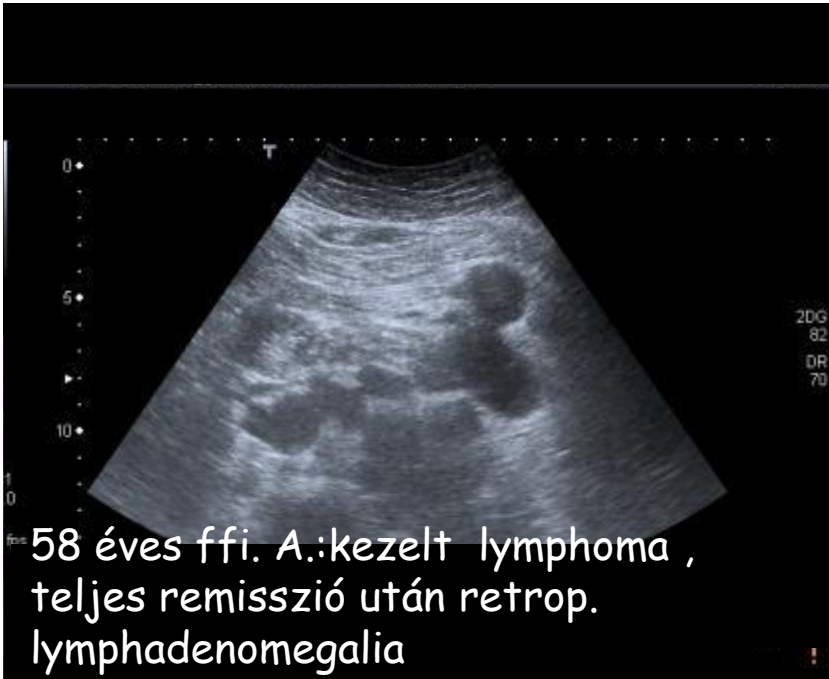- Primer tumor keresés

- Daganatos beteg újonnan megjelent laesiója - rec.,
 - met.?
 - 2. primer?





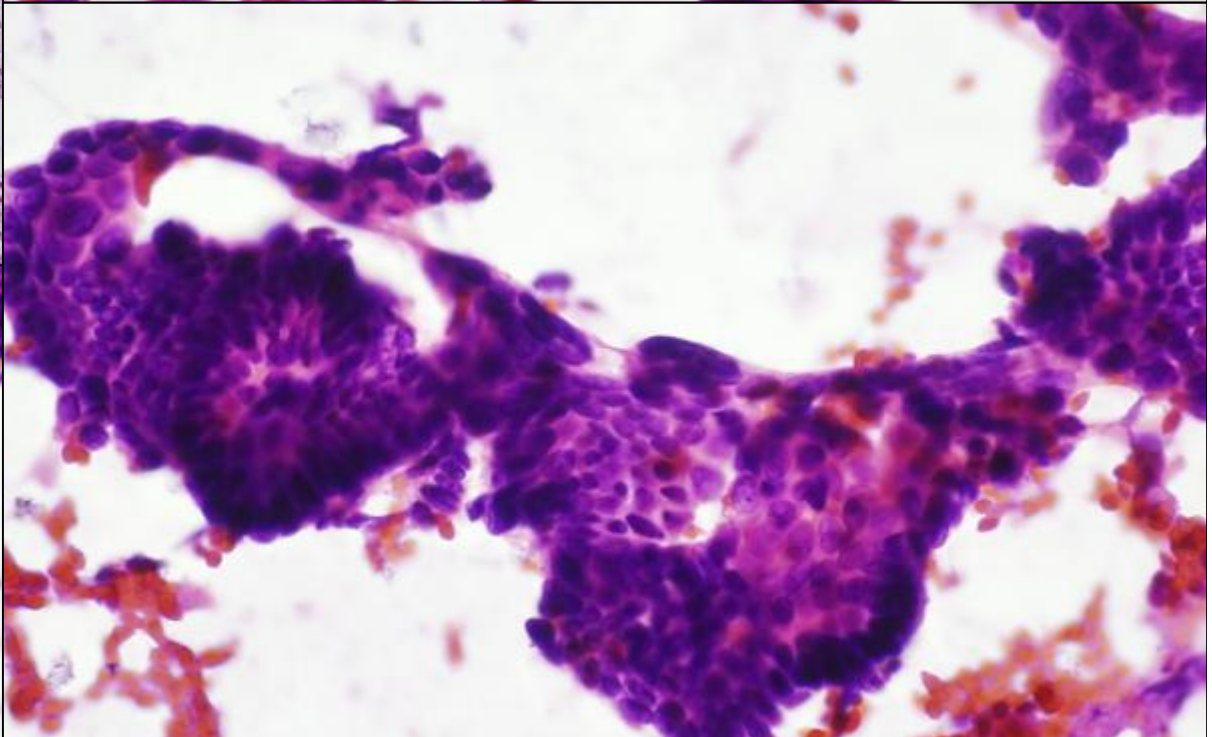
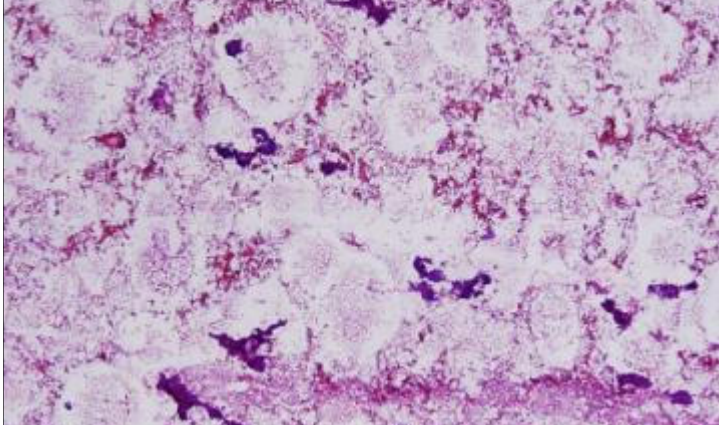
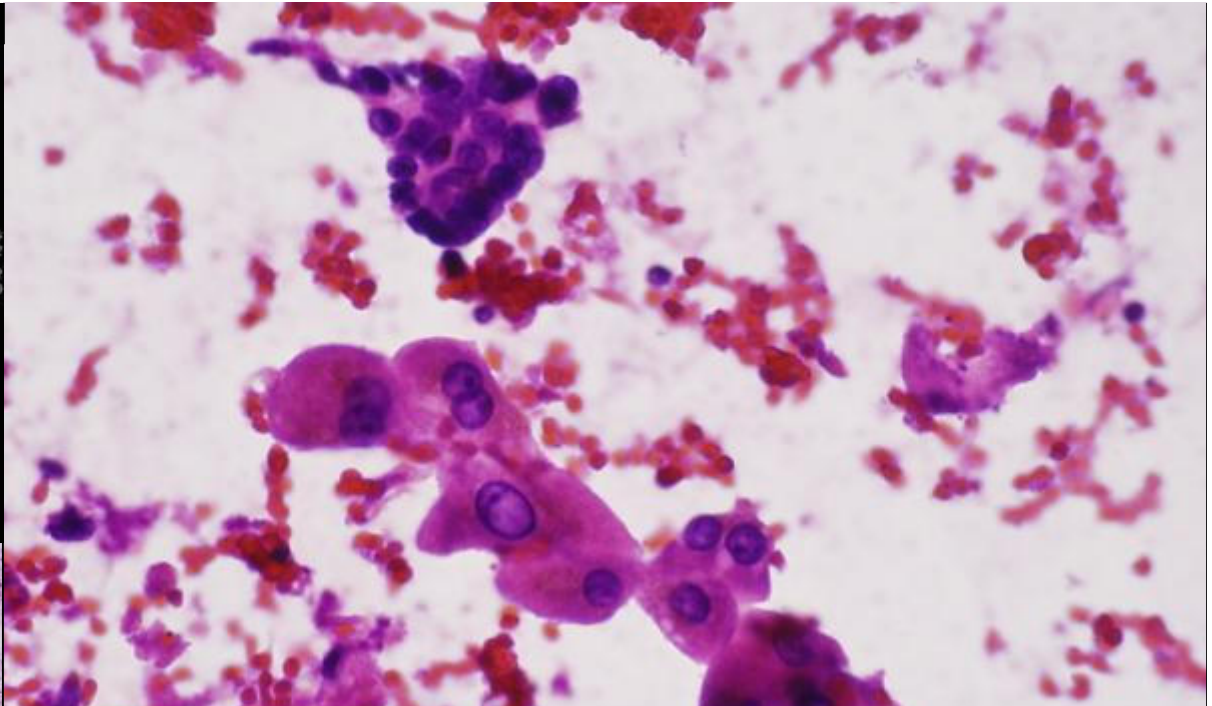
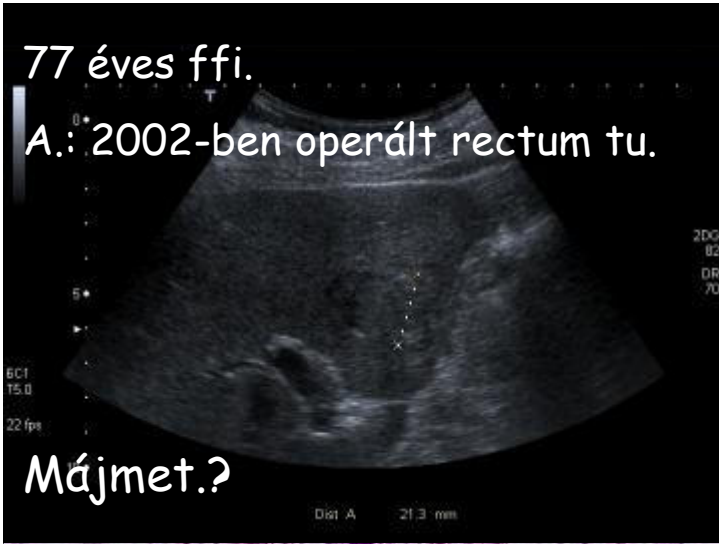


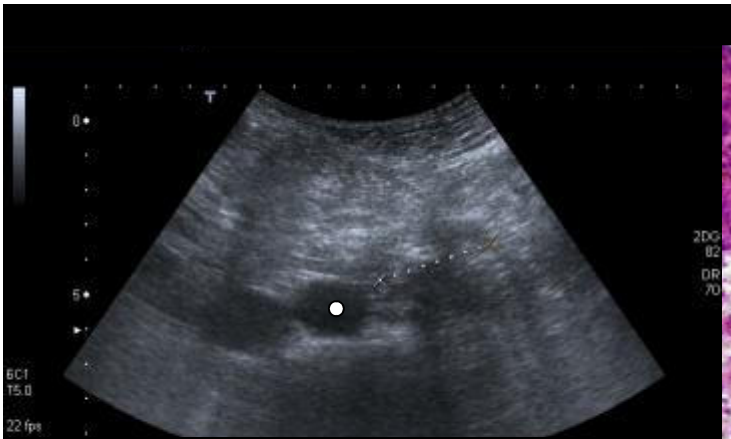

77 éves ffi.

A.: 2002-ben operált rectum tu.

Májmet.?

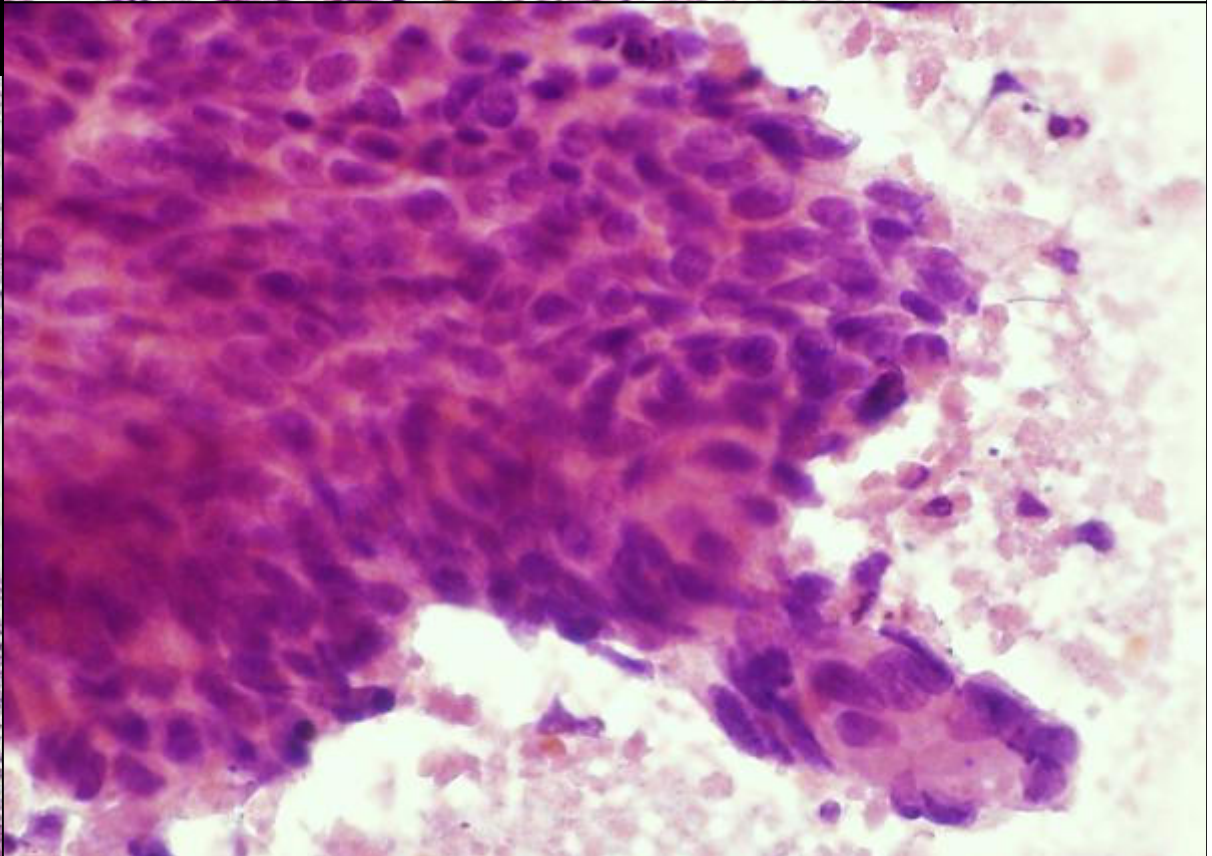
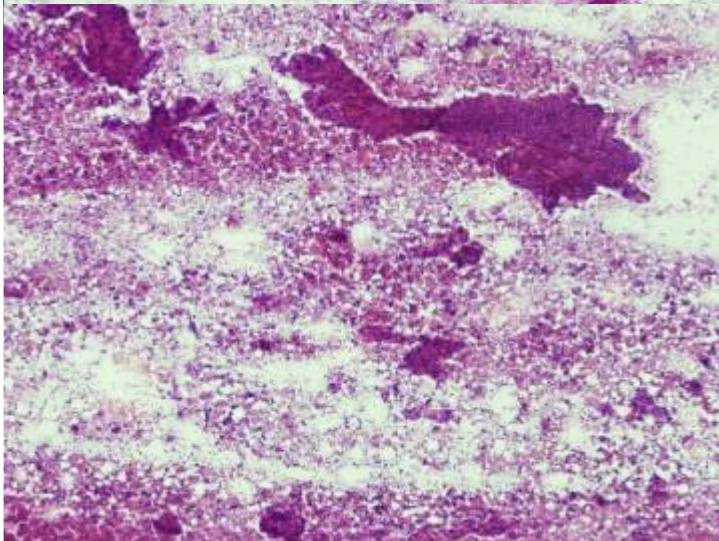
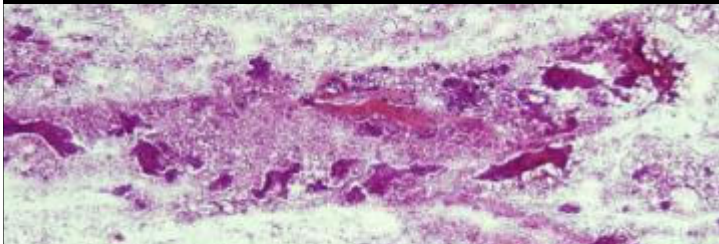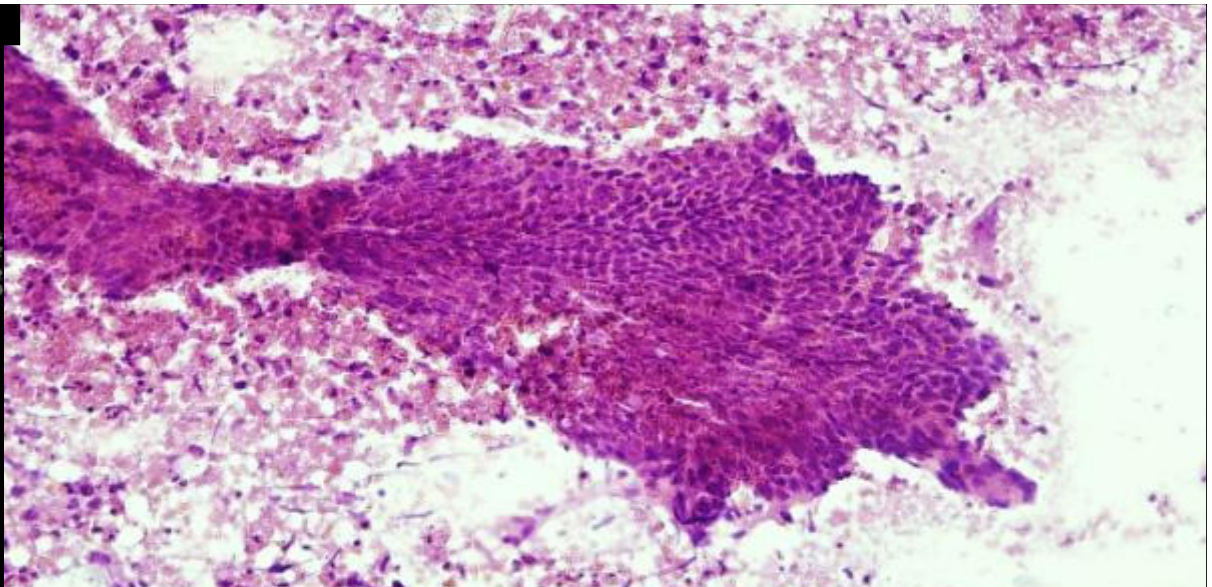




77 éves ffi.

A.: 2002-ben operált rectum tu.

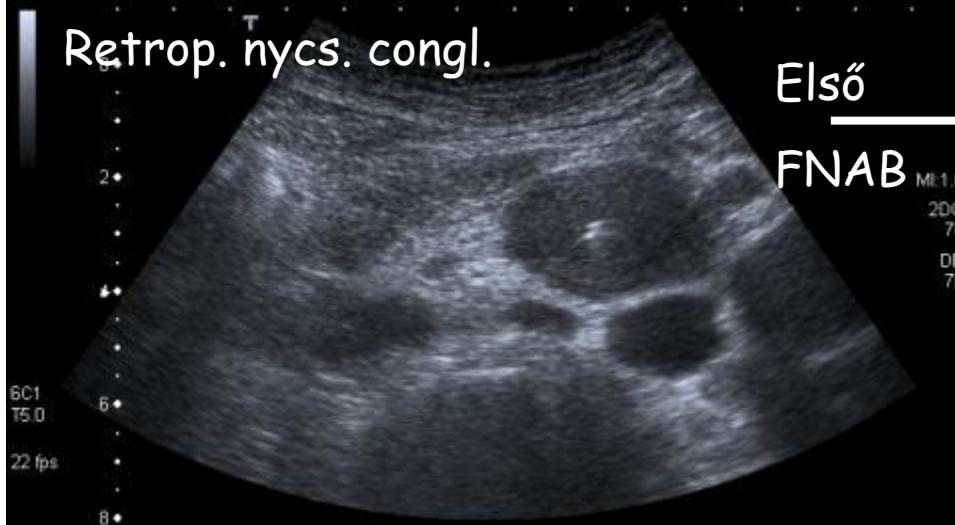
Retrop. rec. gyanú képalkotóval



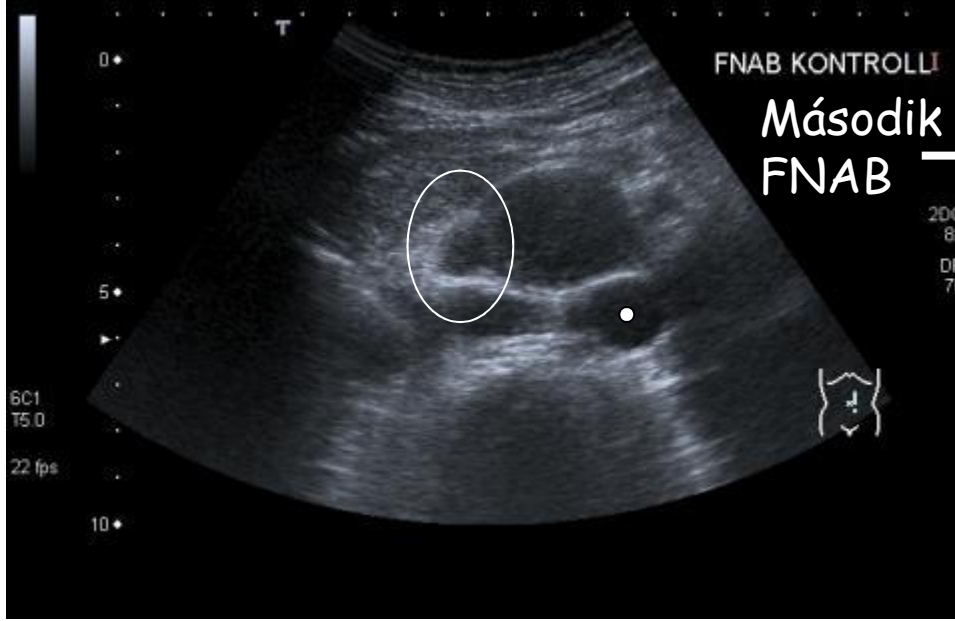
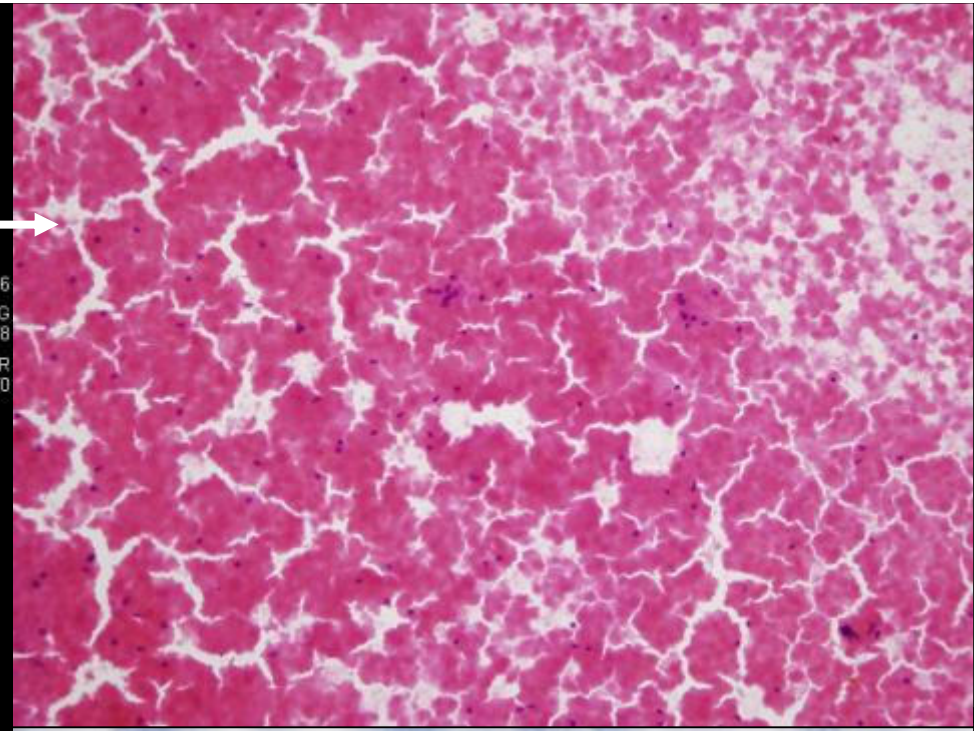


45 éves ffi. A.: hereműtét tu. miatt.

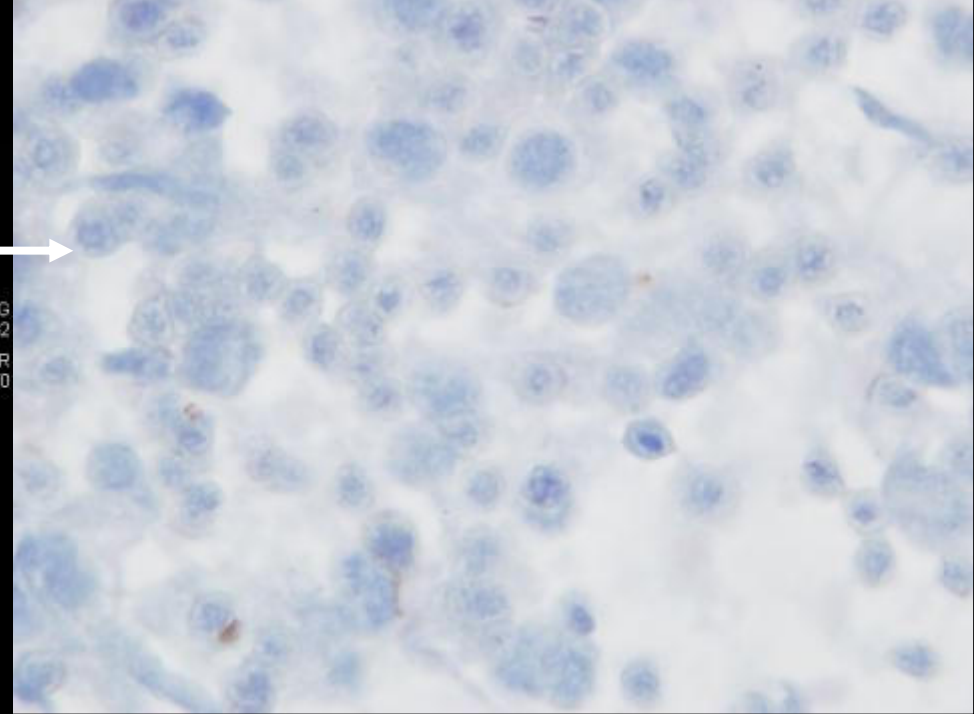
Retrop. nyacs. congl.

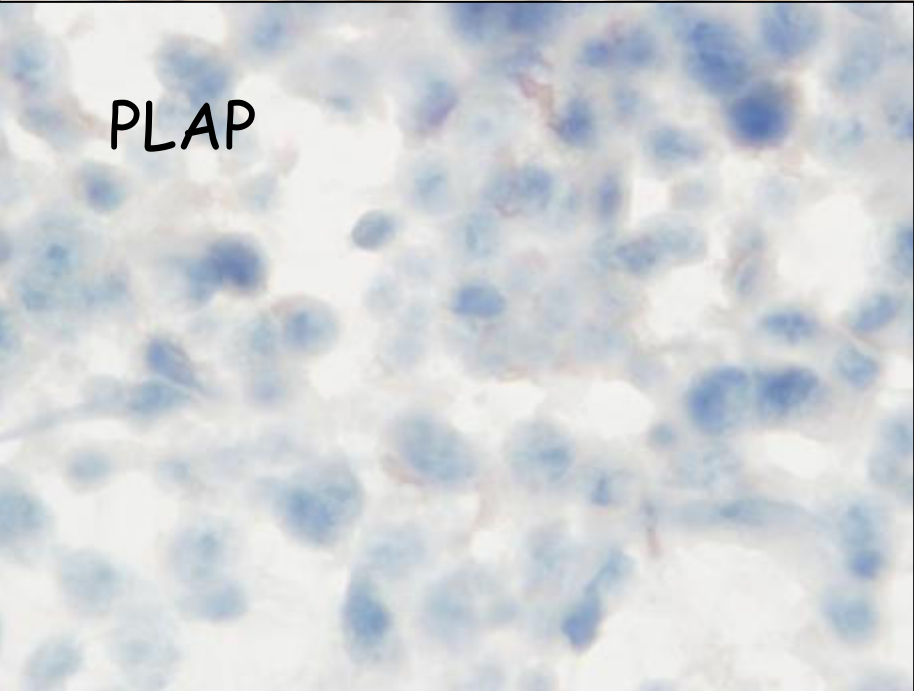
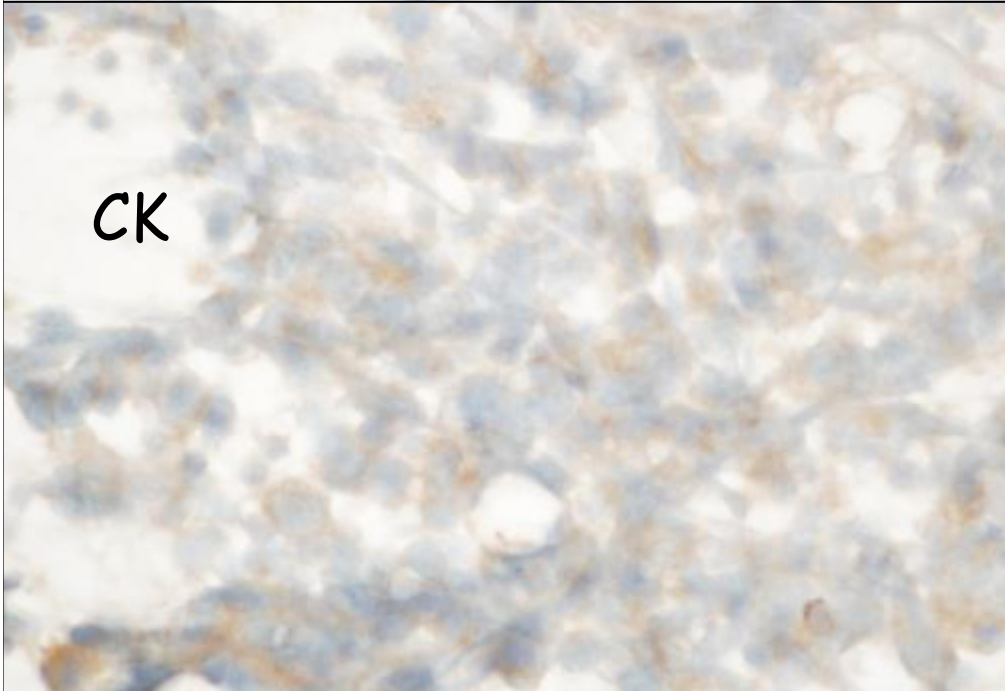
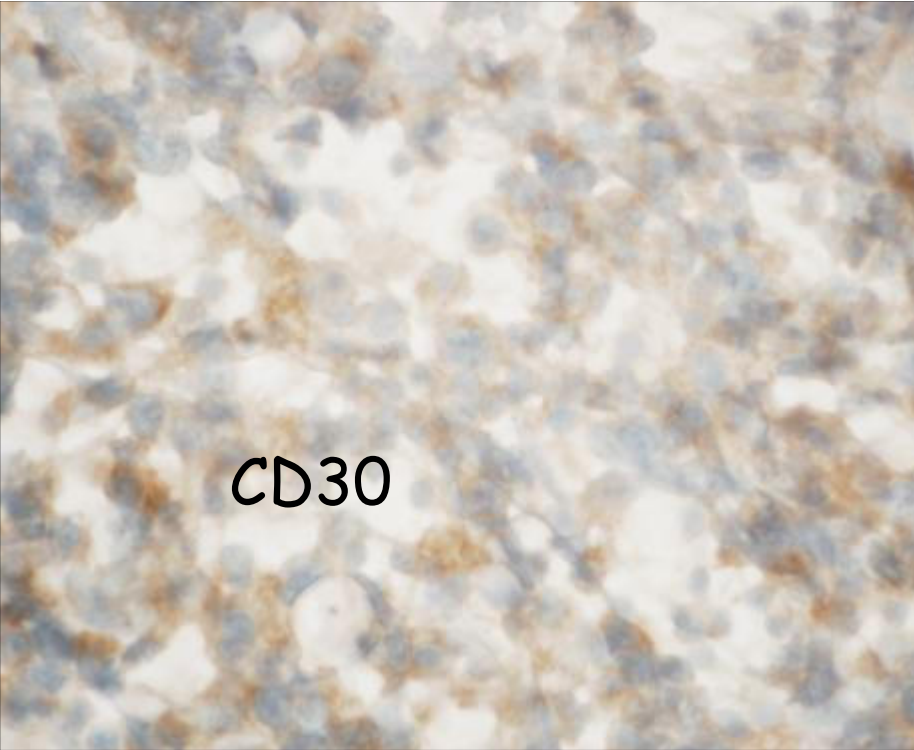
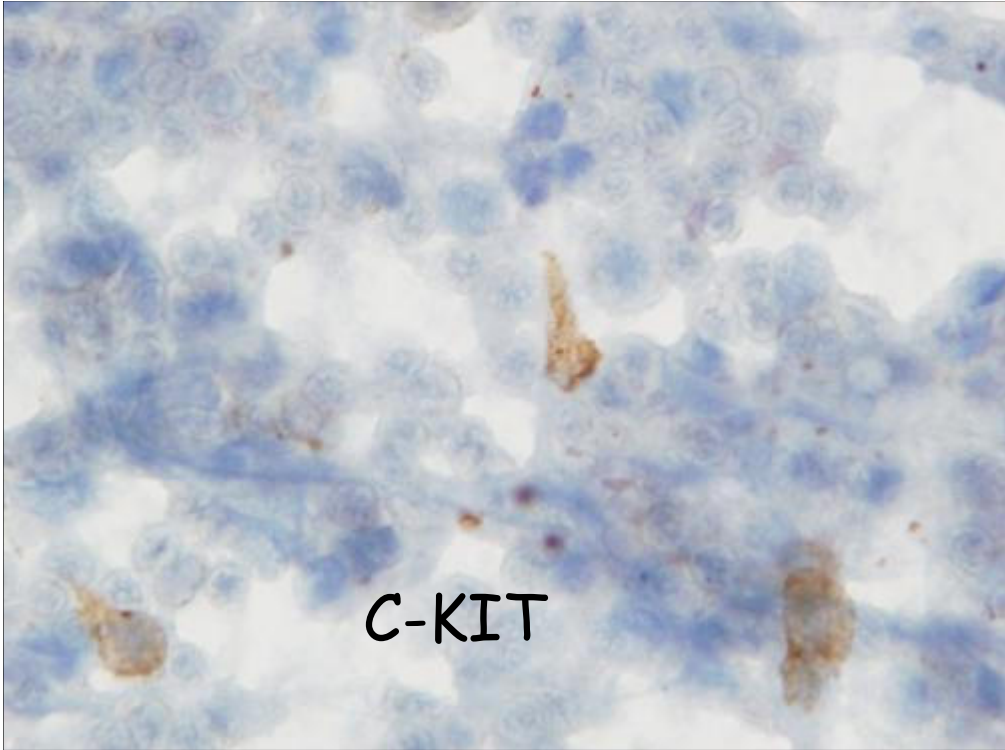


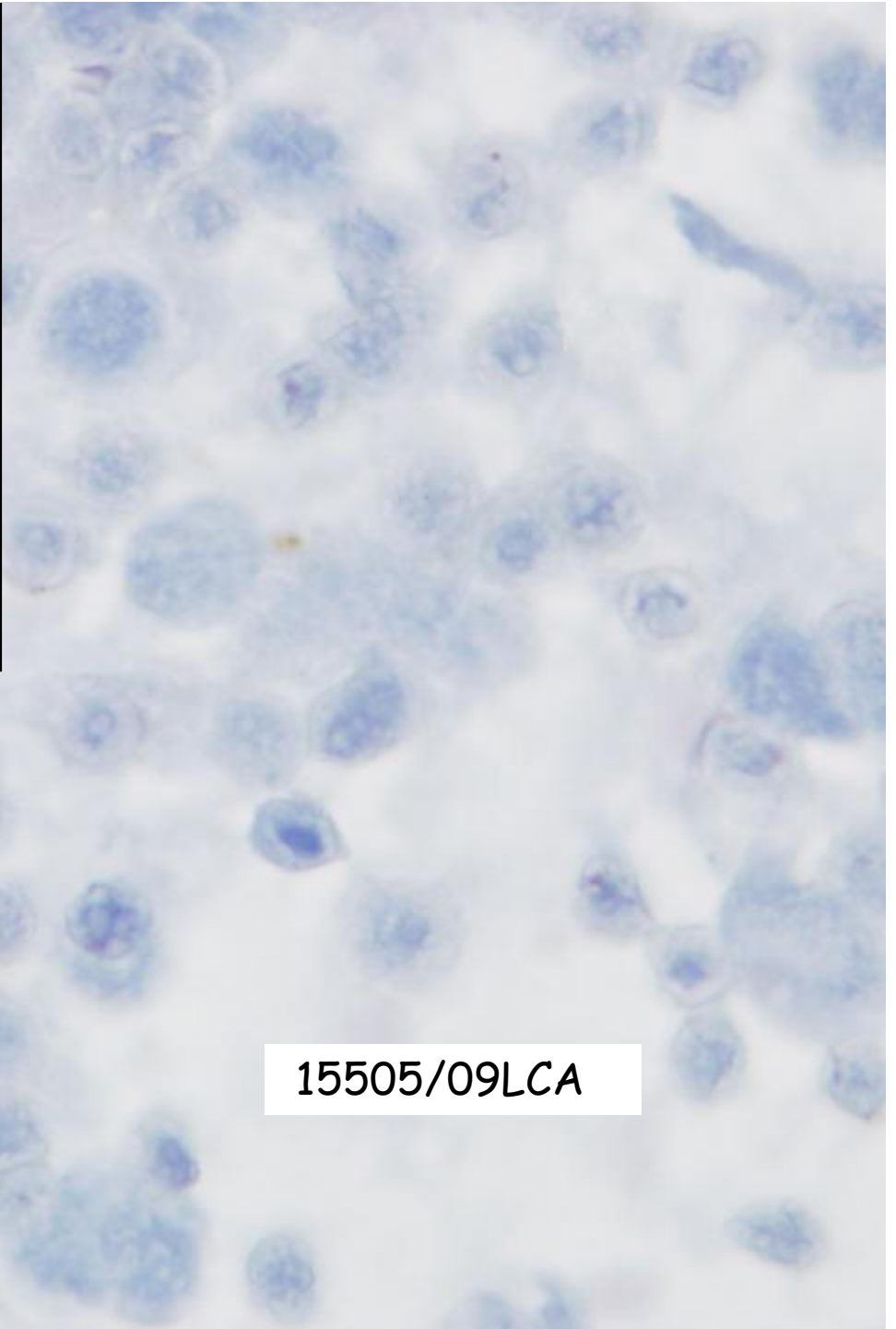
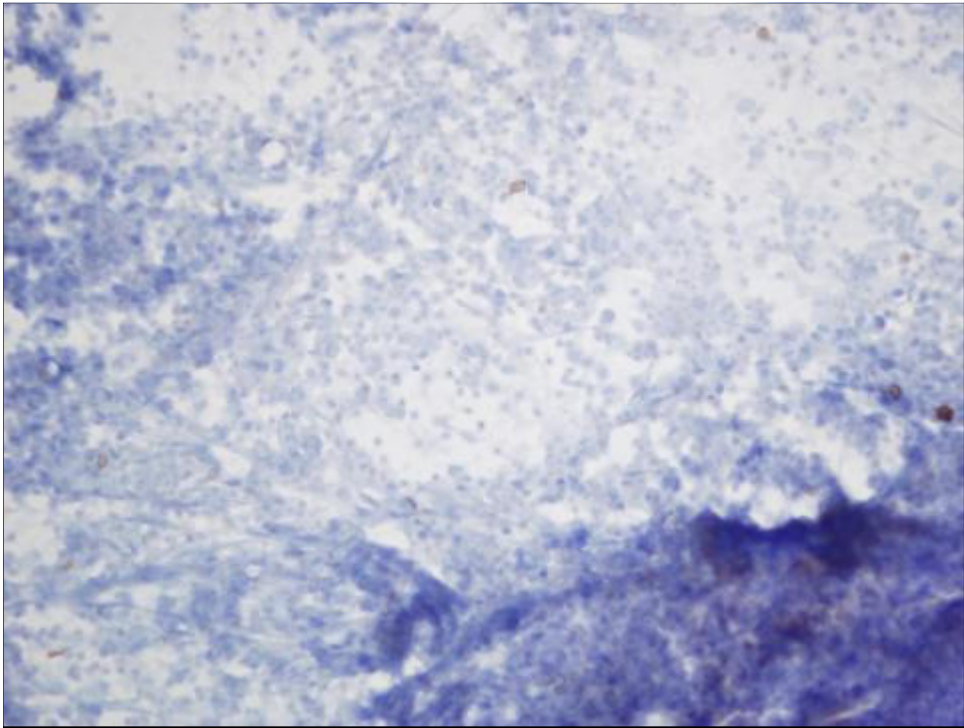
Első
FNAB



FNAB KONTROLLI
Második
FNAB

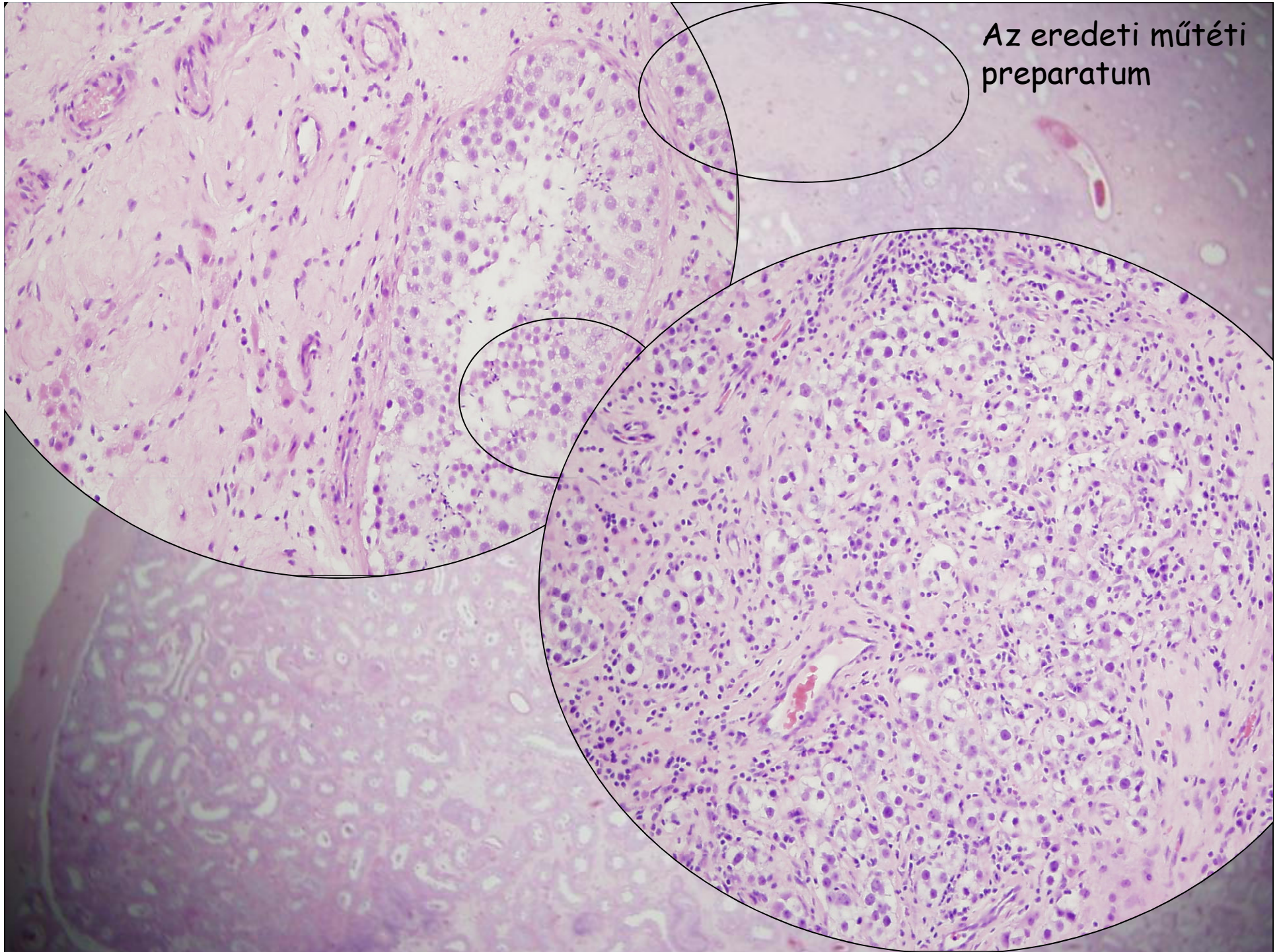


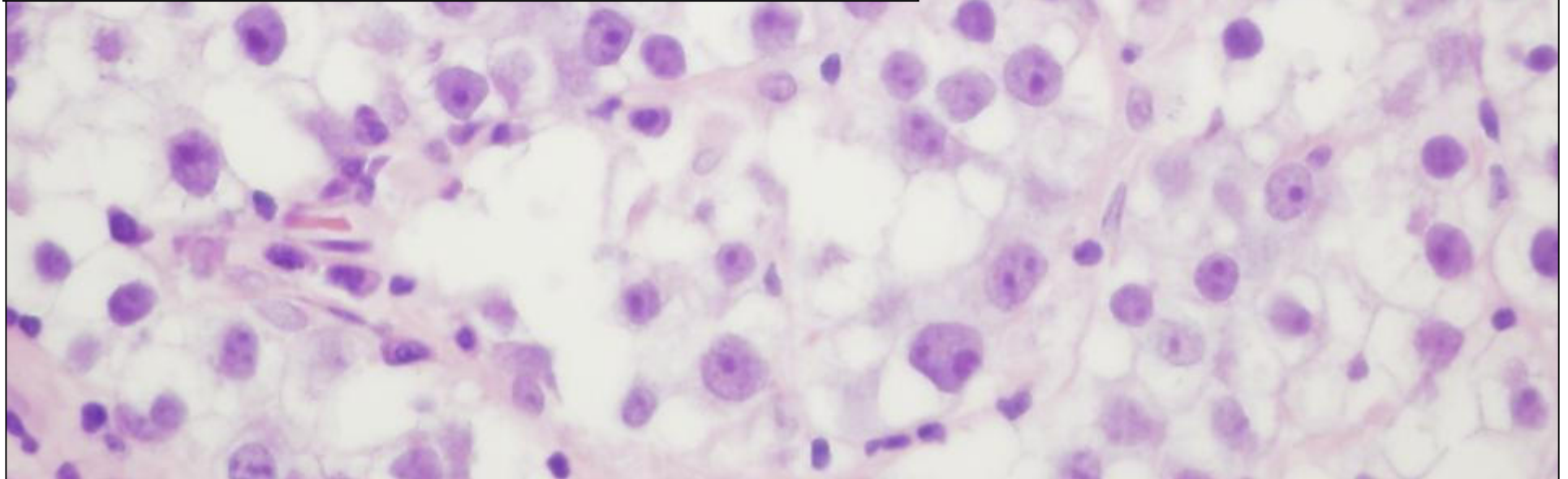
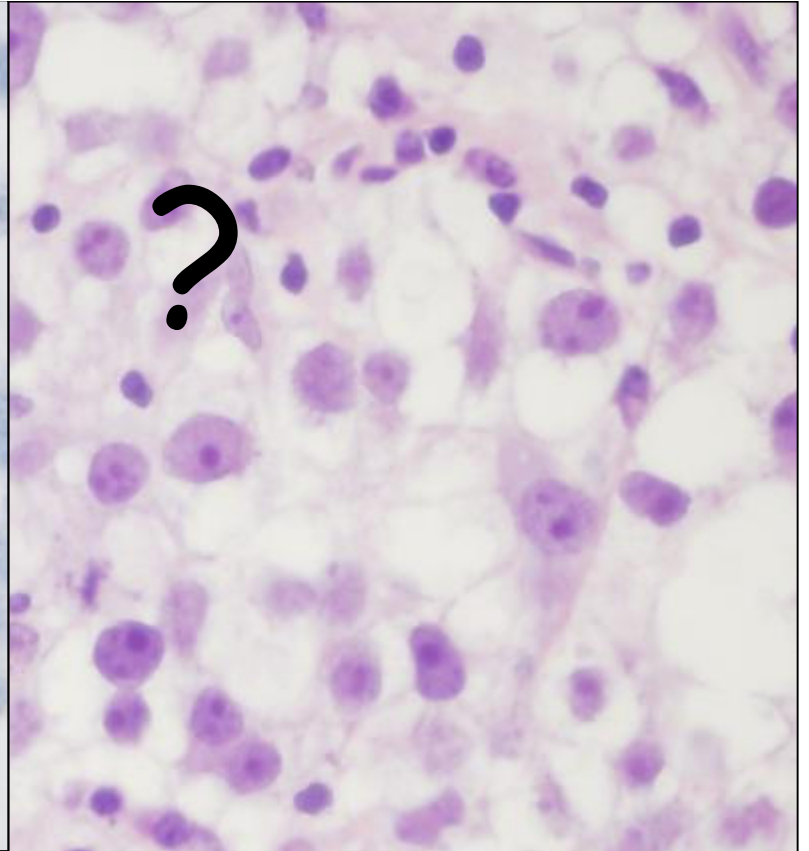
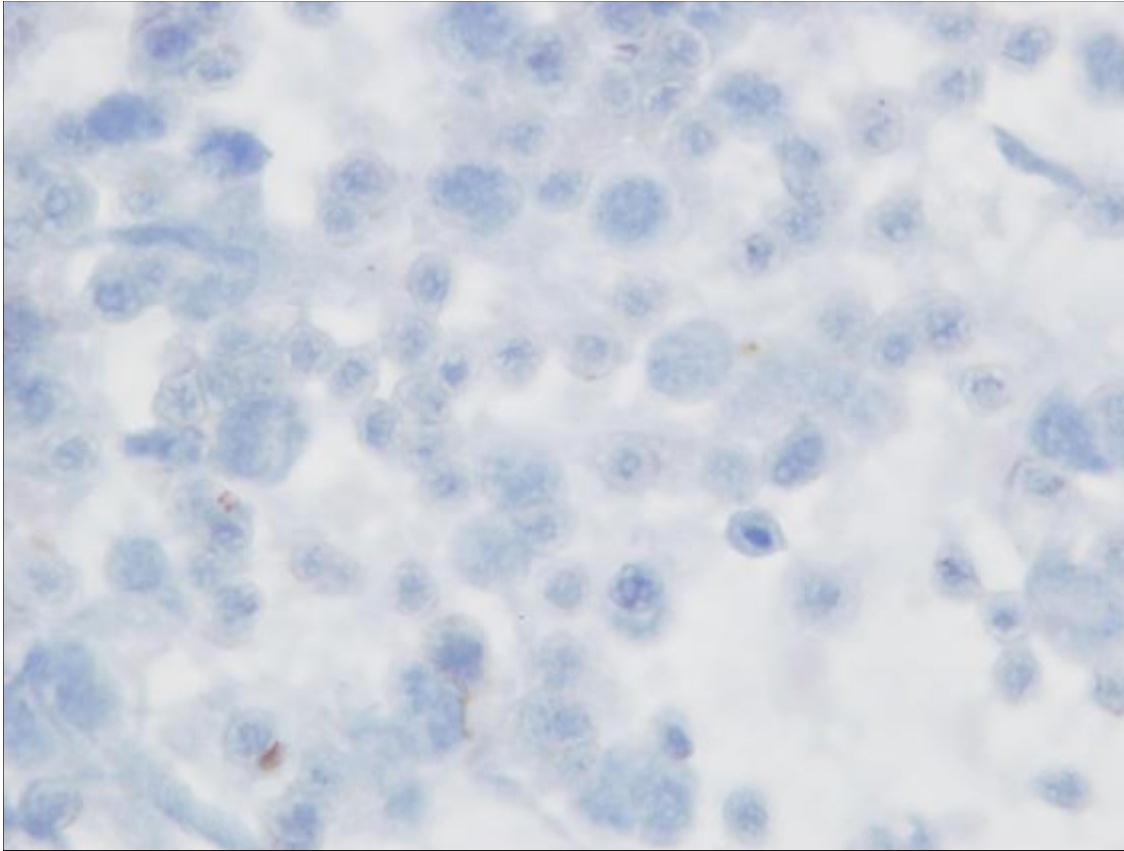




15505/09LCA

Az eredeti műtéti
preparatum





A retrop. mintavétel indikációi

■ Primer tumor keresés

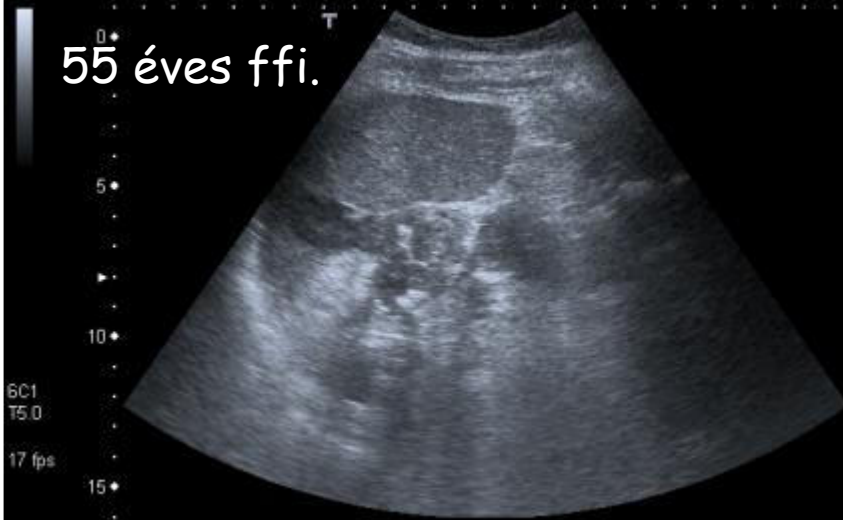- A cytológiai kép megfelel a klinikai feltételezésnek
- A cytológiai kép egészen mást mutat, mint a korábbi vizsgálatoktól várnánk

■ Daganatos beteg újonnan megjelent laesiója - rec.,

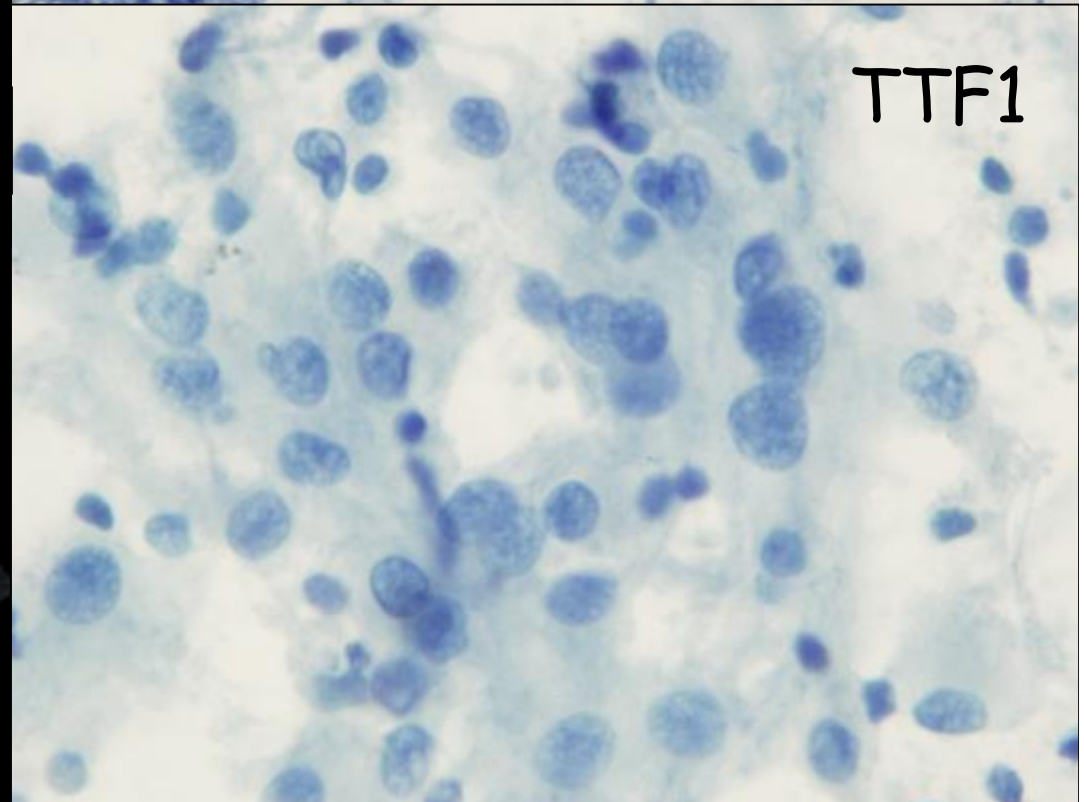
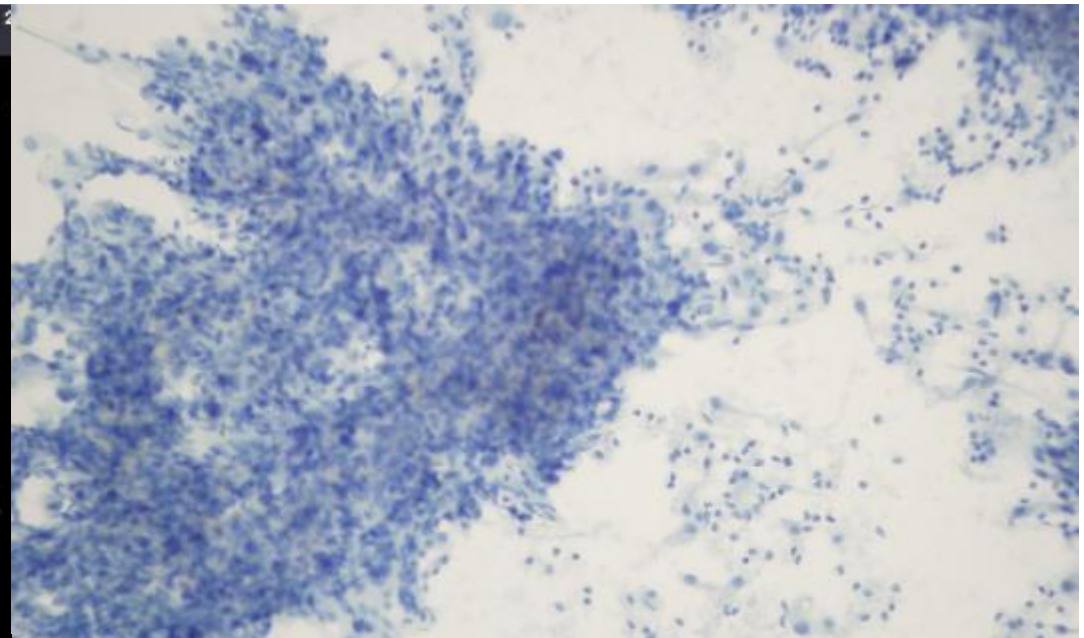
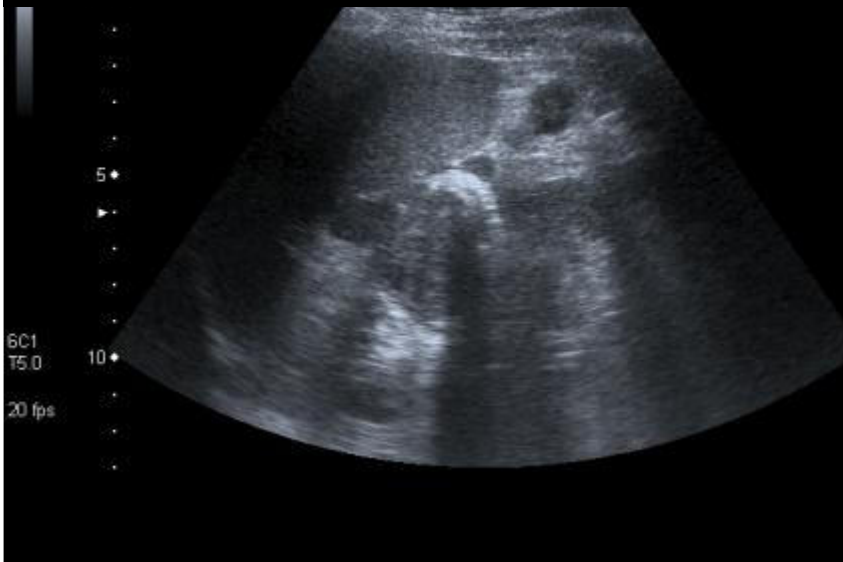- met.?
- 2. primer?

9969/10

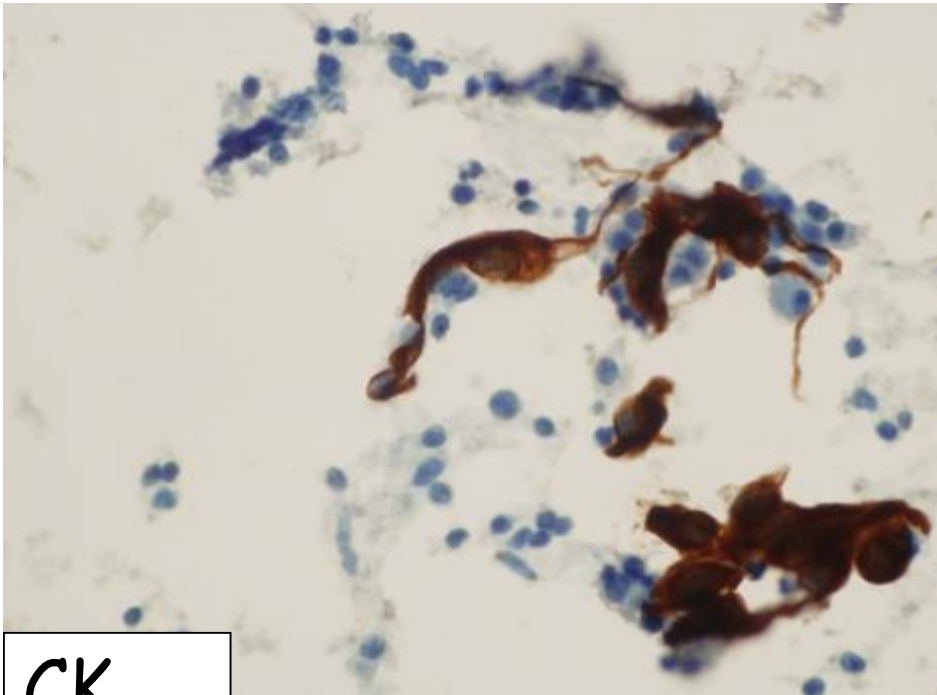
55 éves ffi.



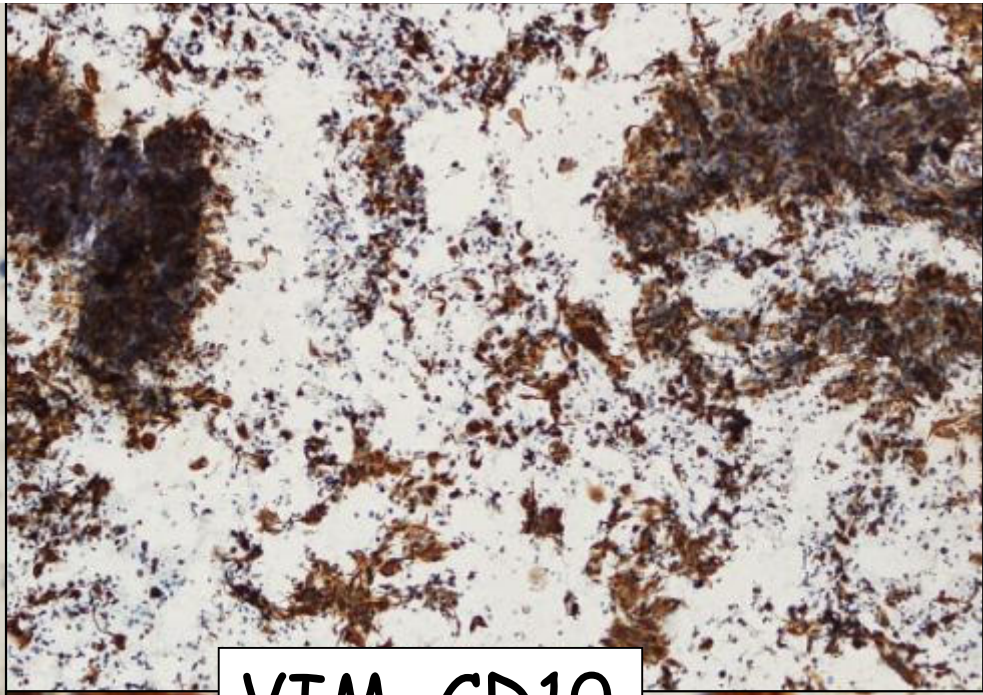
A bal vese felső pólusától nehezen differenciálható, több cm Ø-jű vegyes echoszerkezetű képlet. Mplx máj, ill. tüdő met.



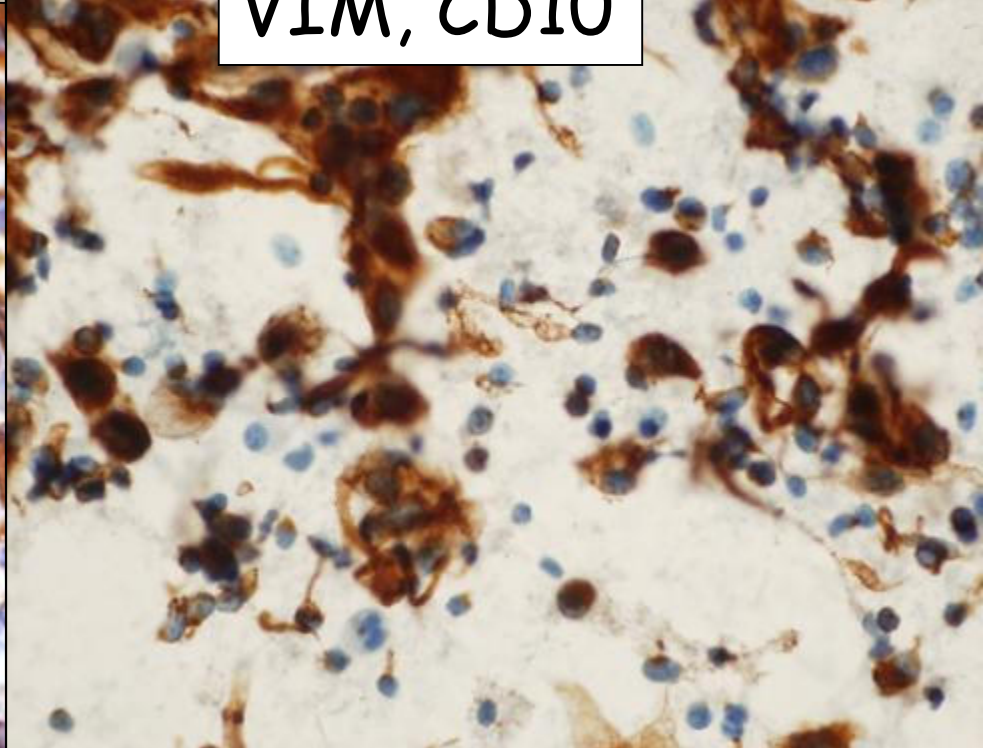
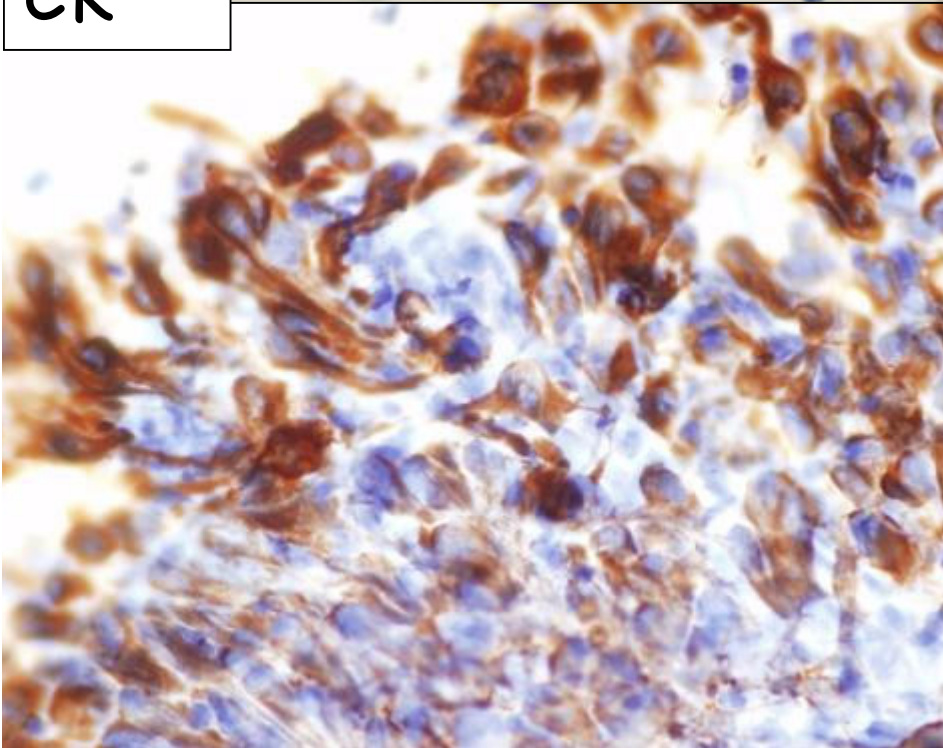
TTF1

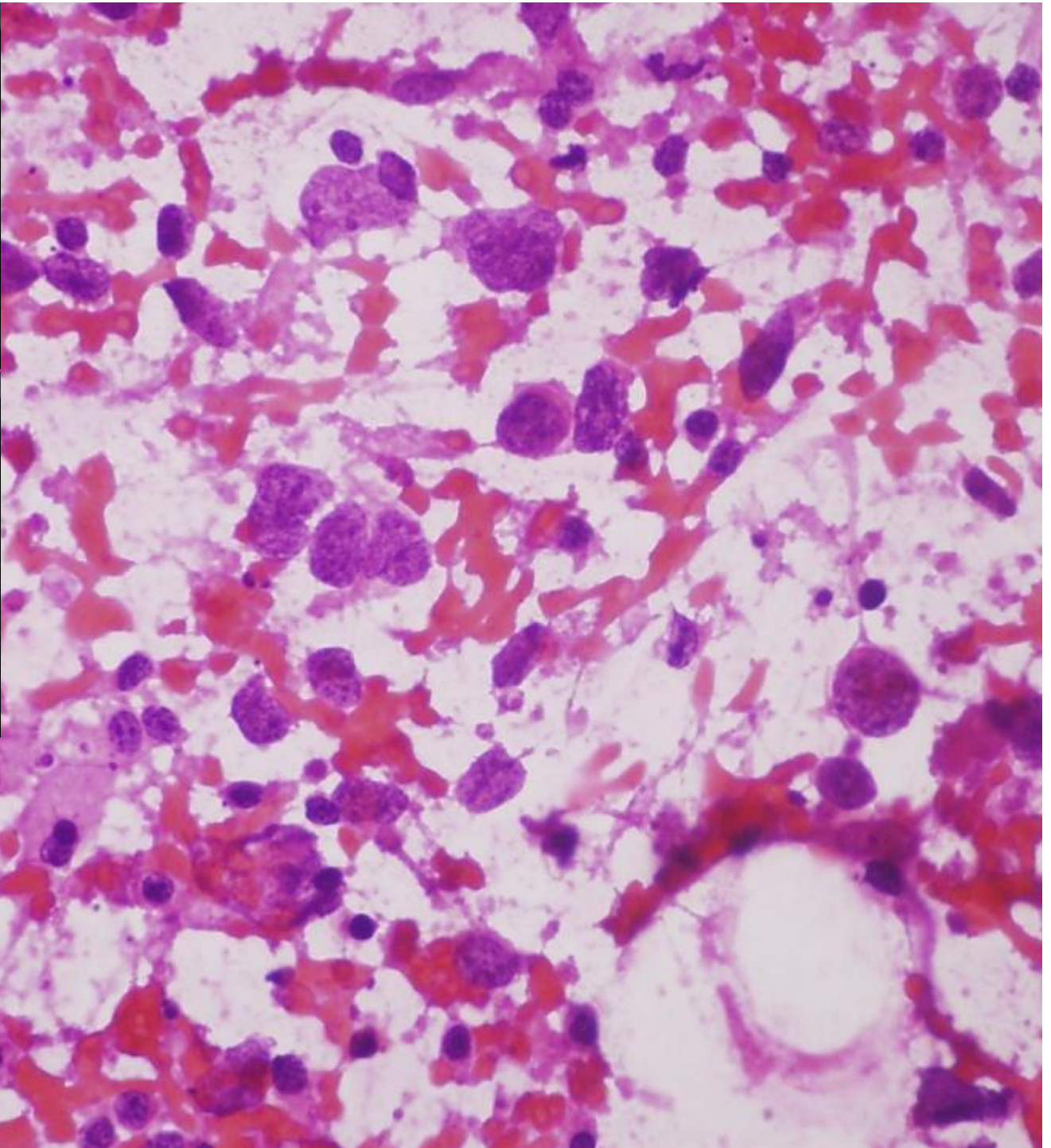
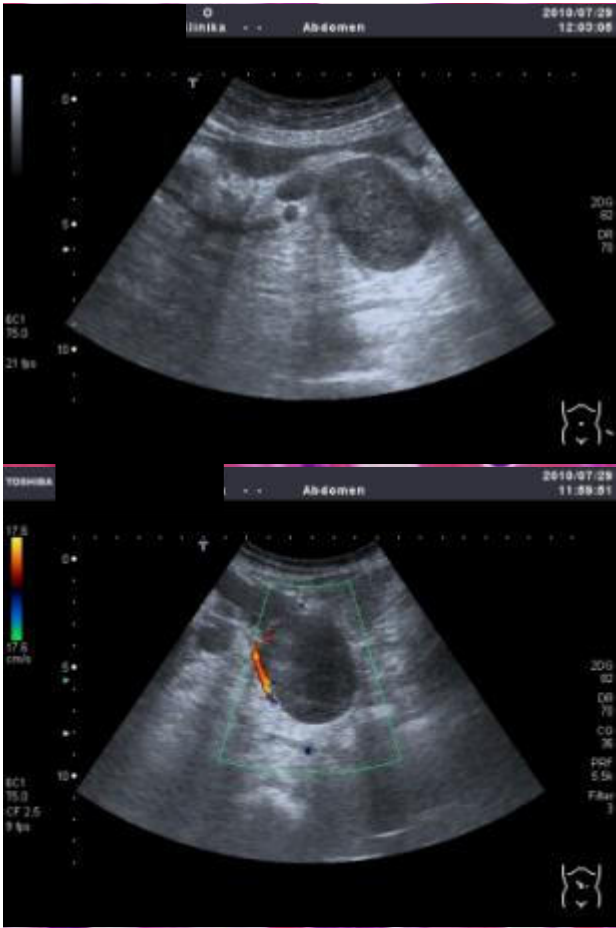

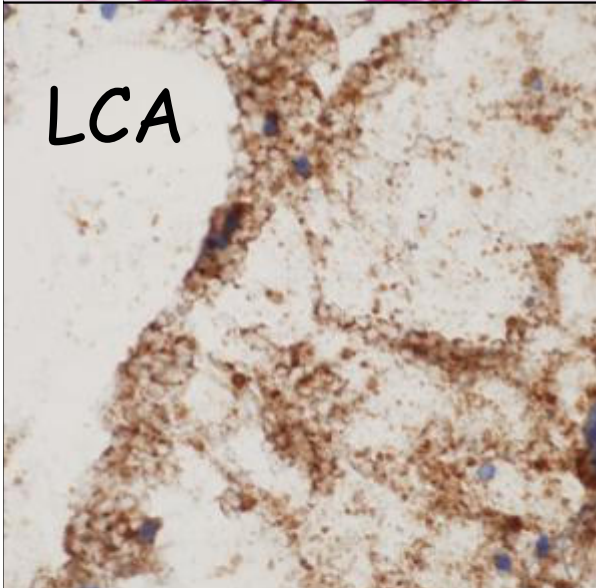
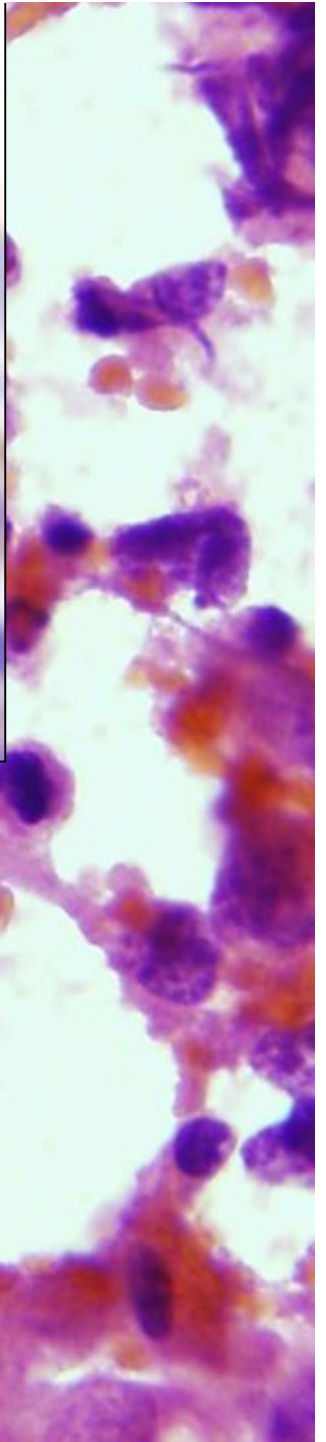
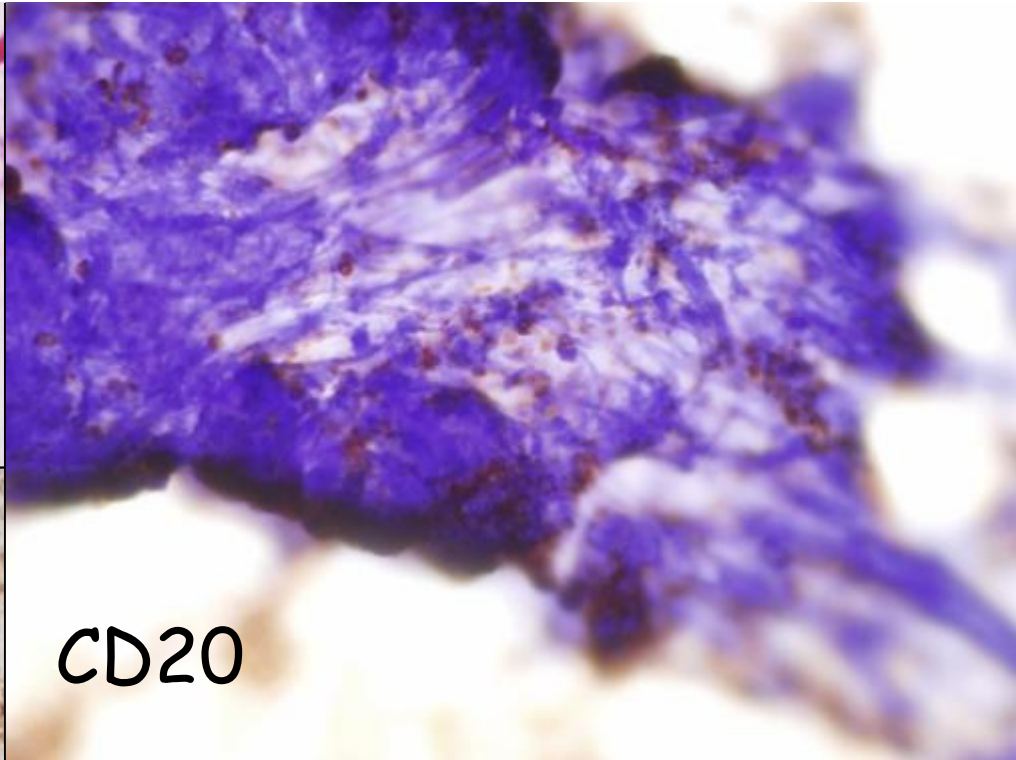
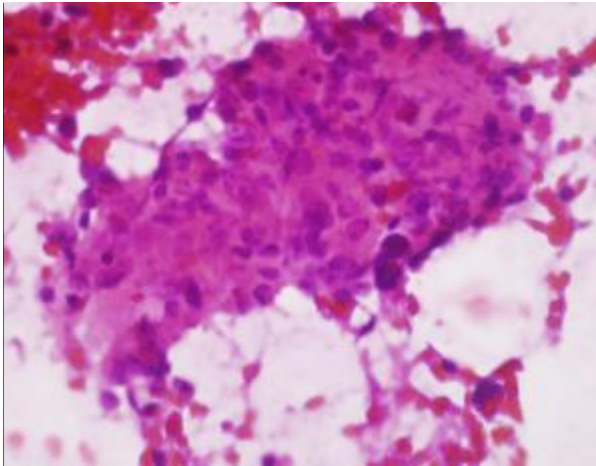
CK



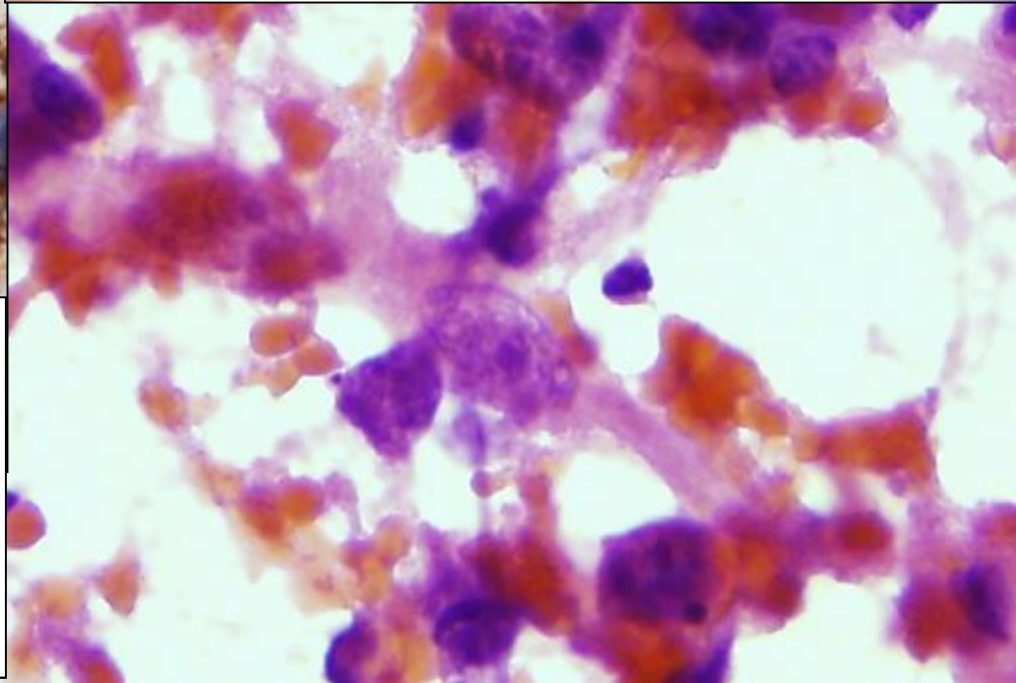
VIM, CD10





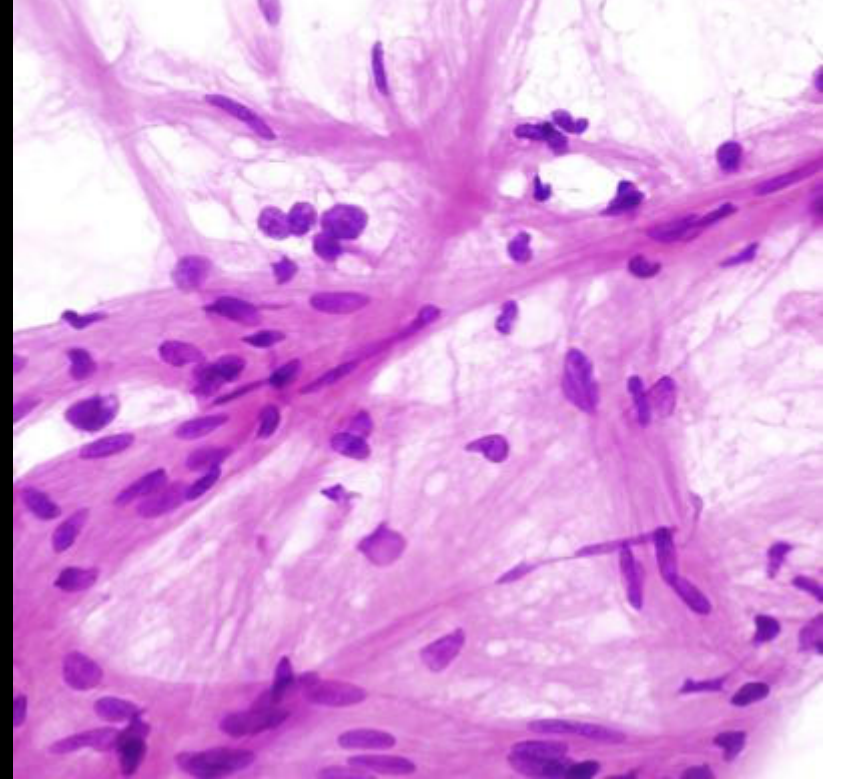
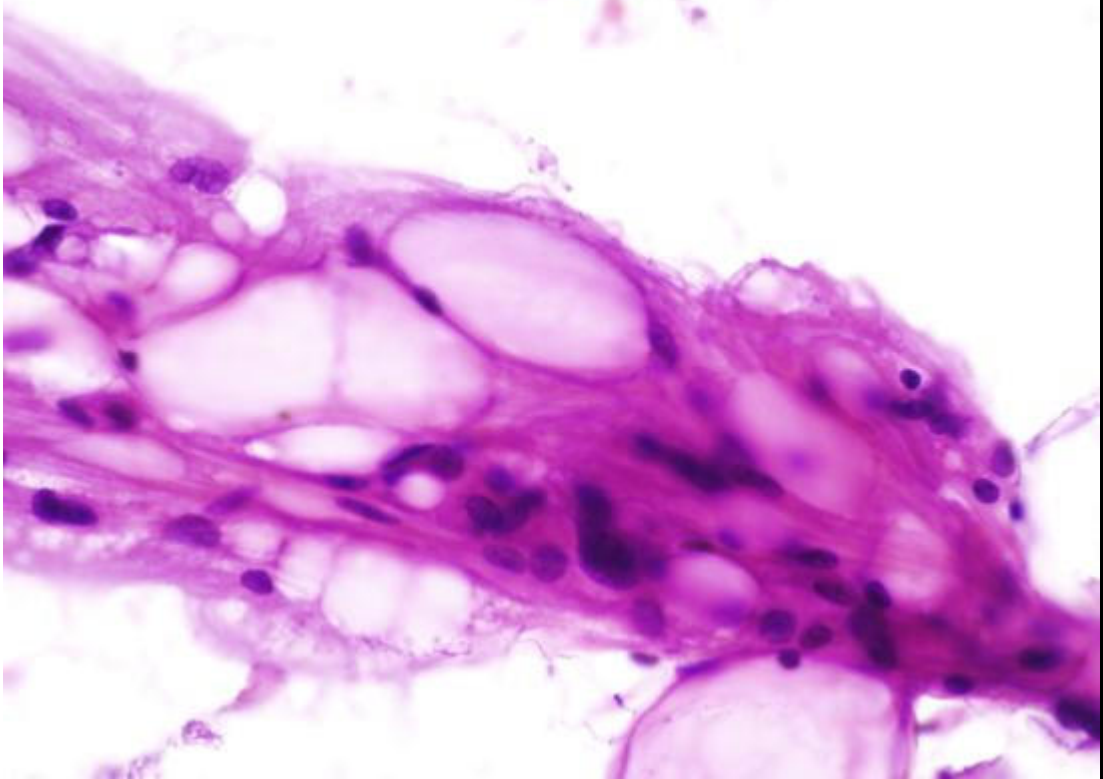
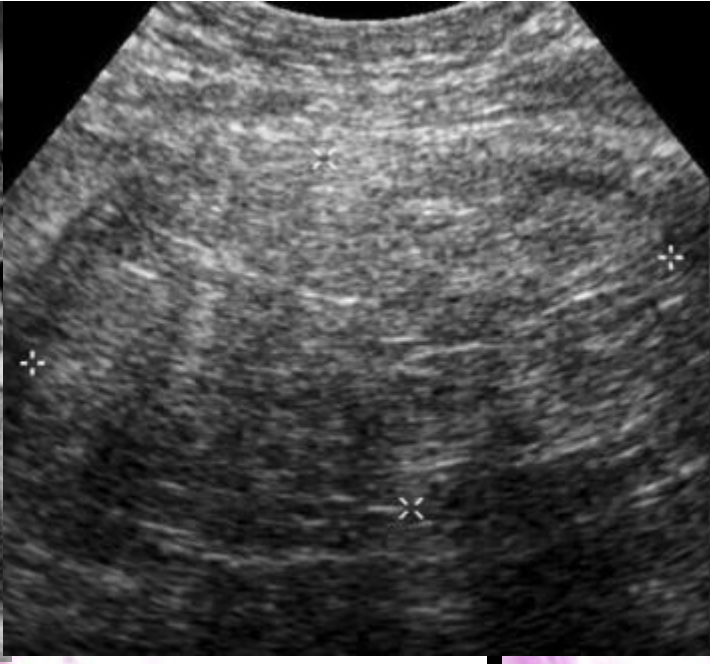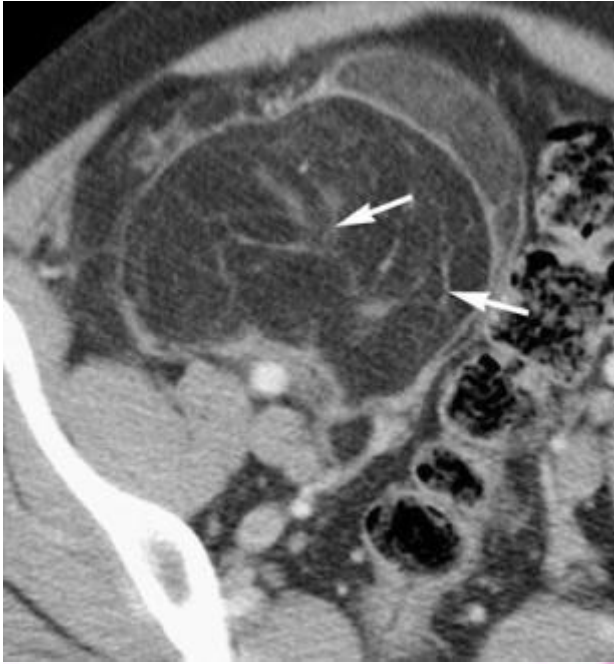


LCA



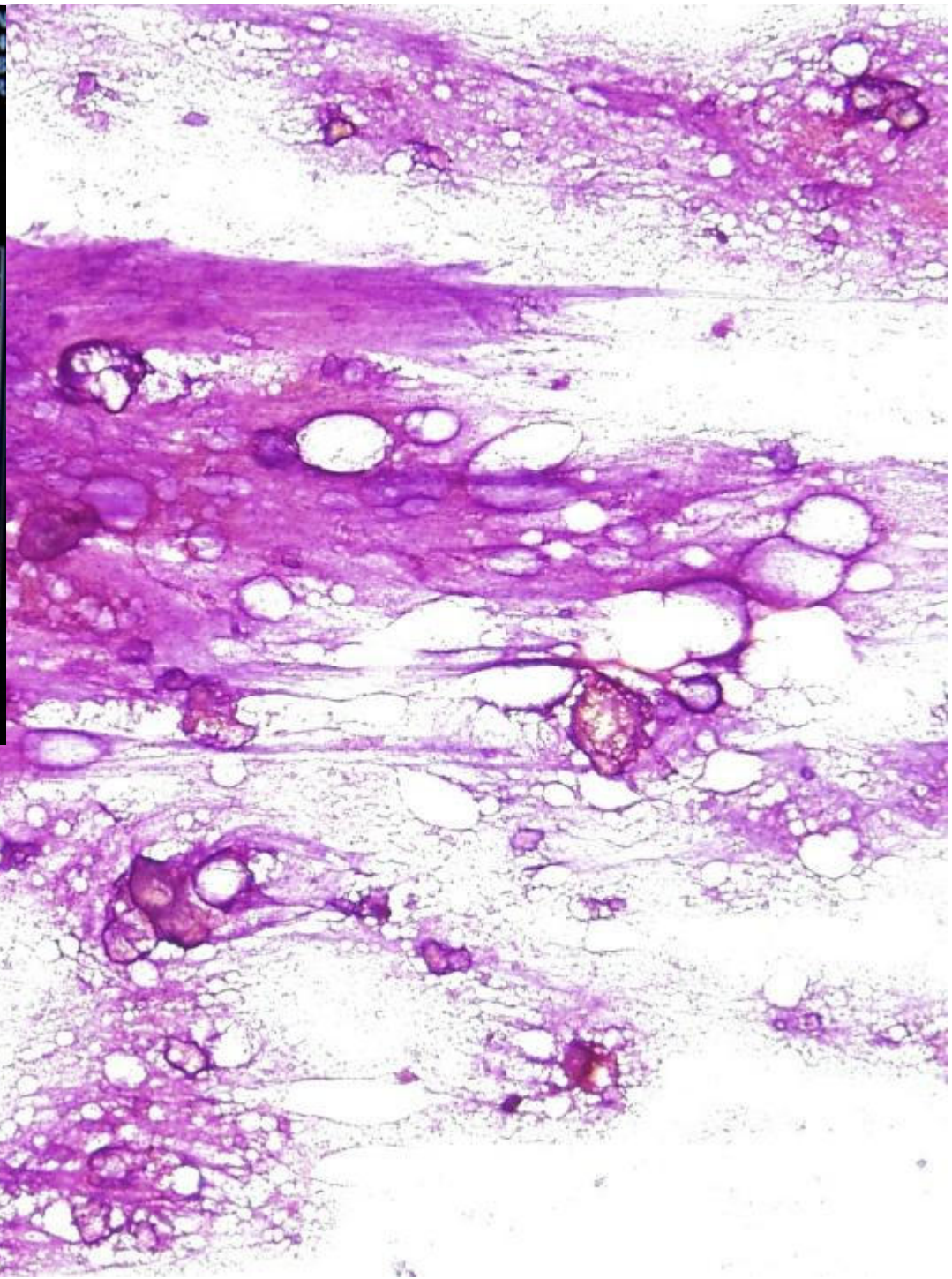
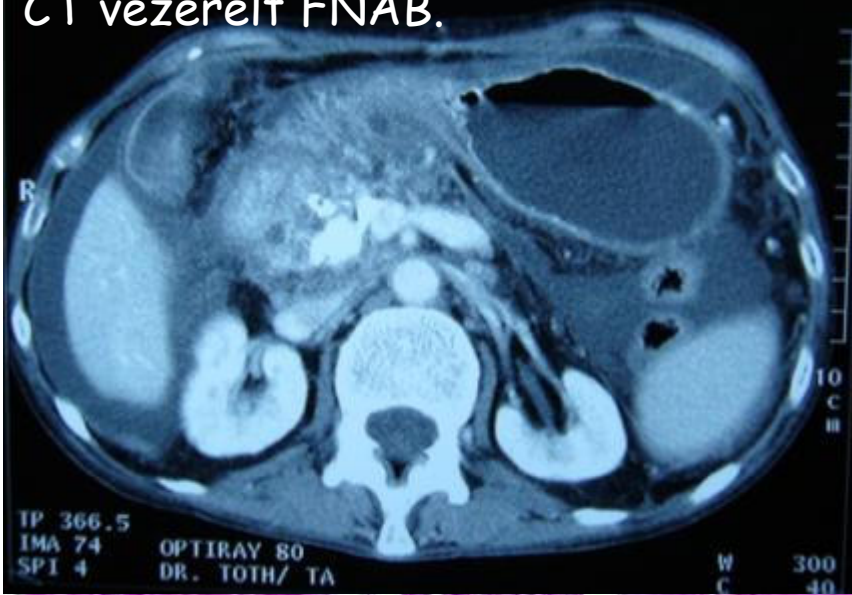
CD20

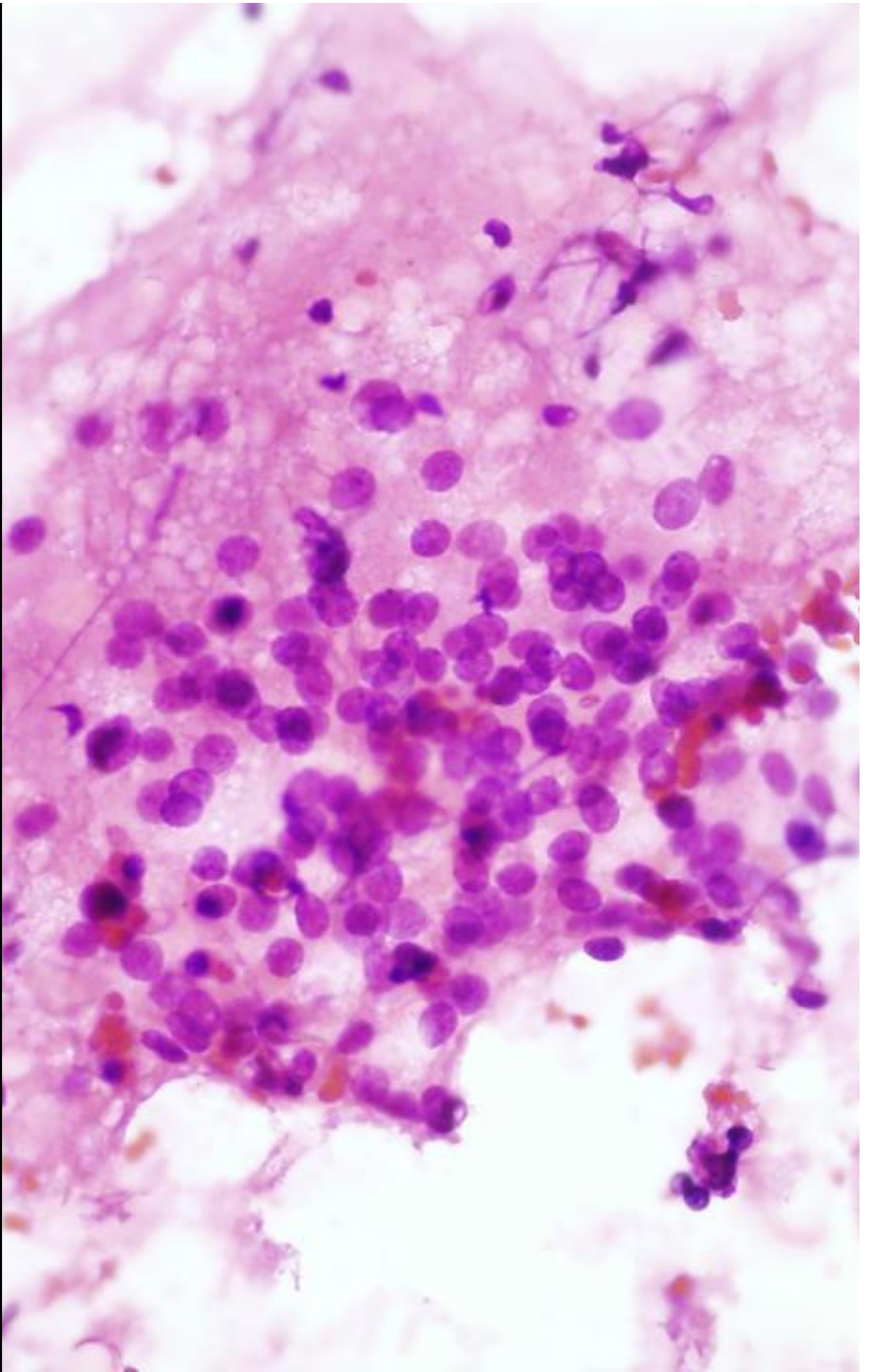
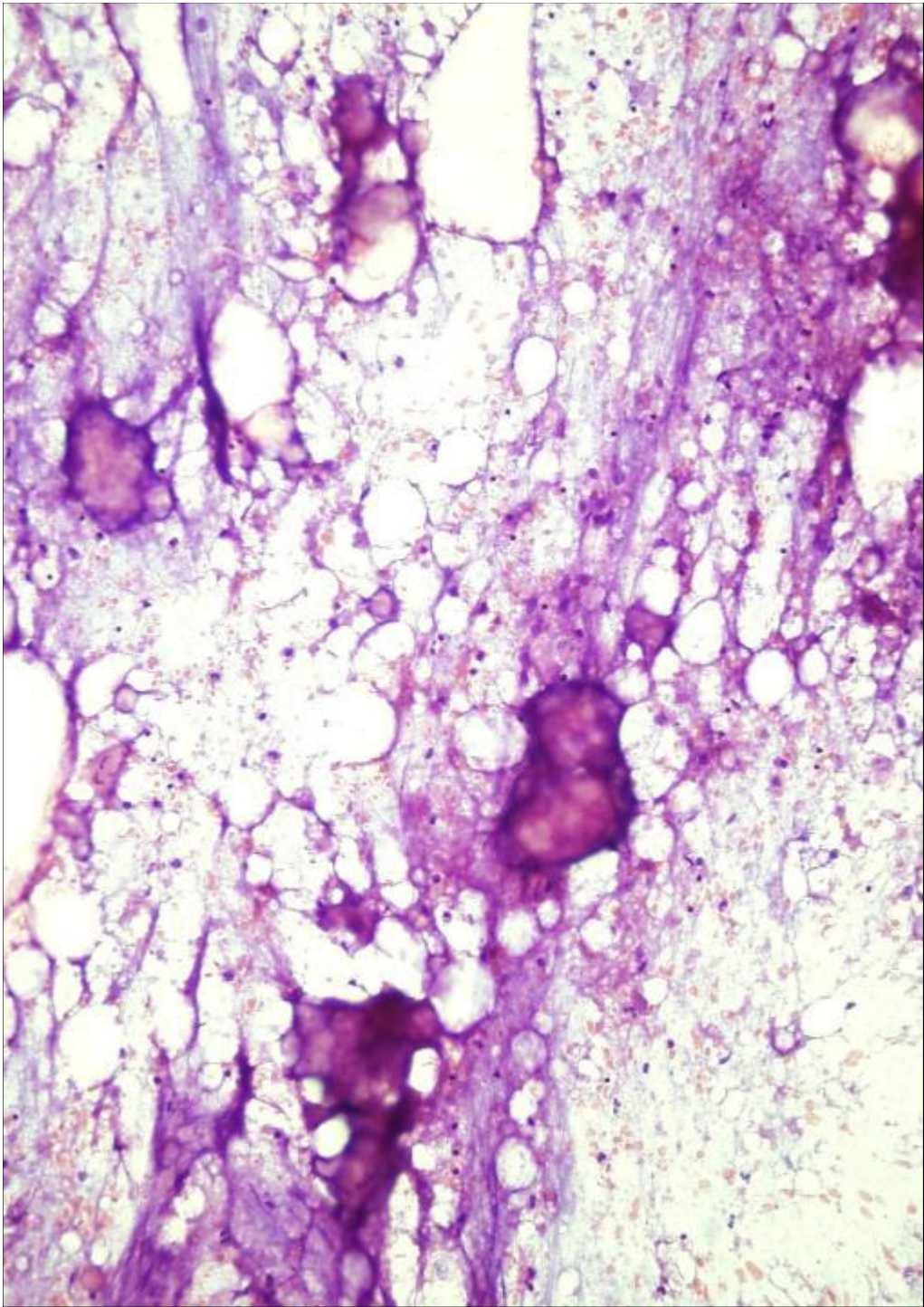
CK	-
CD30	-
Ki67	90%

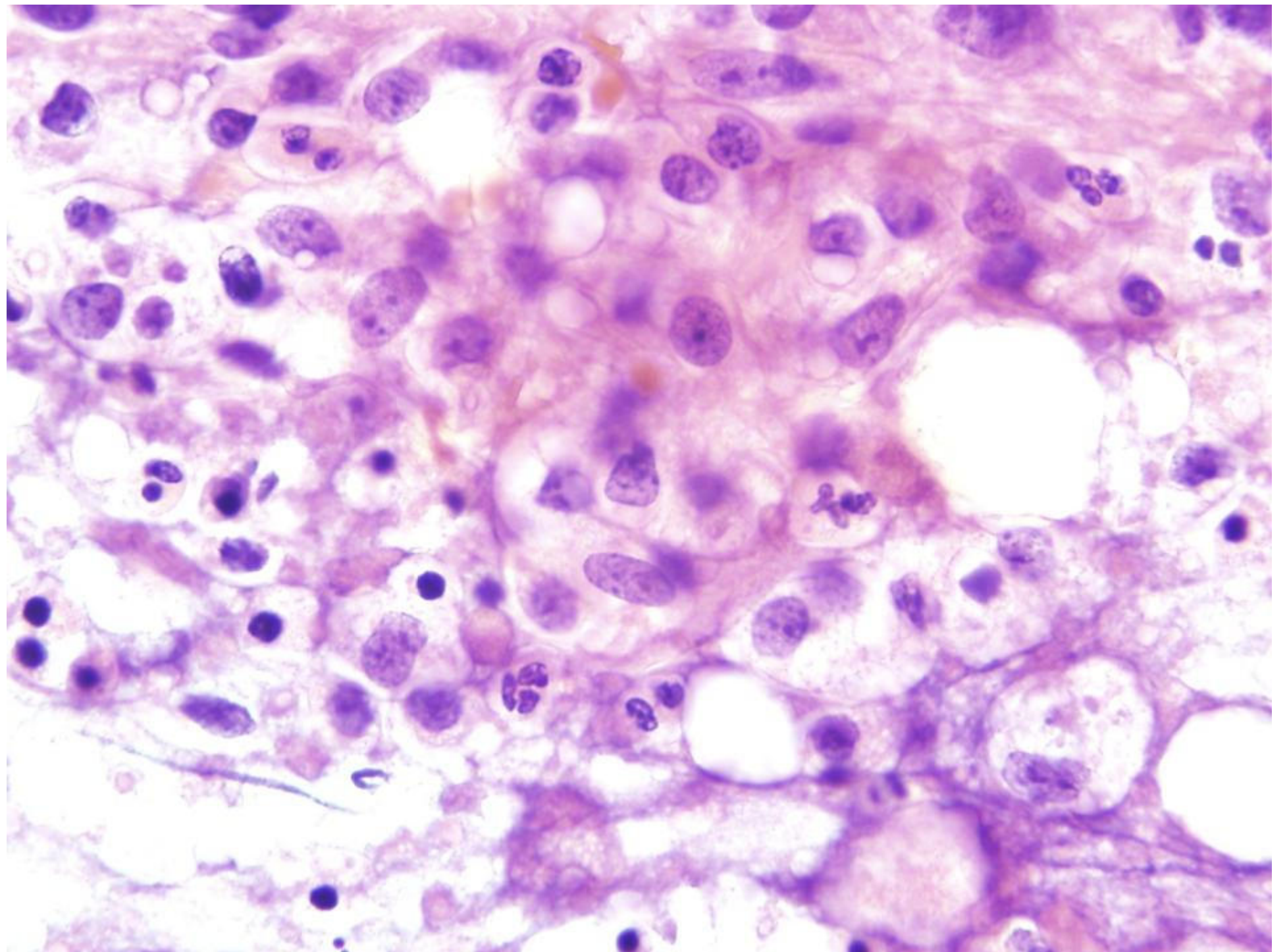


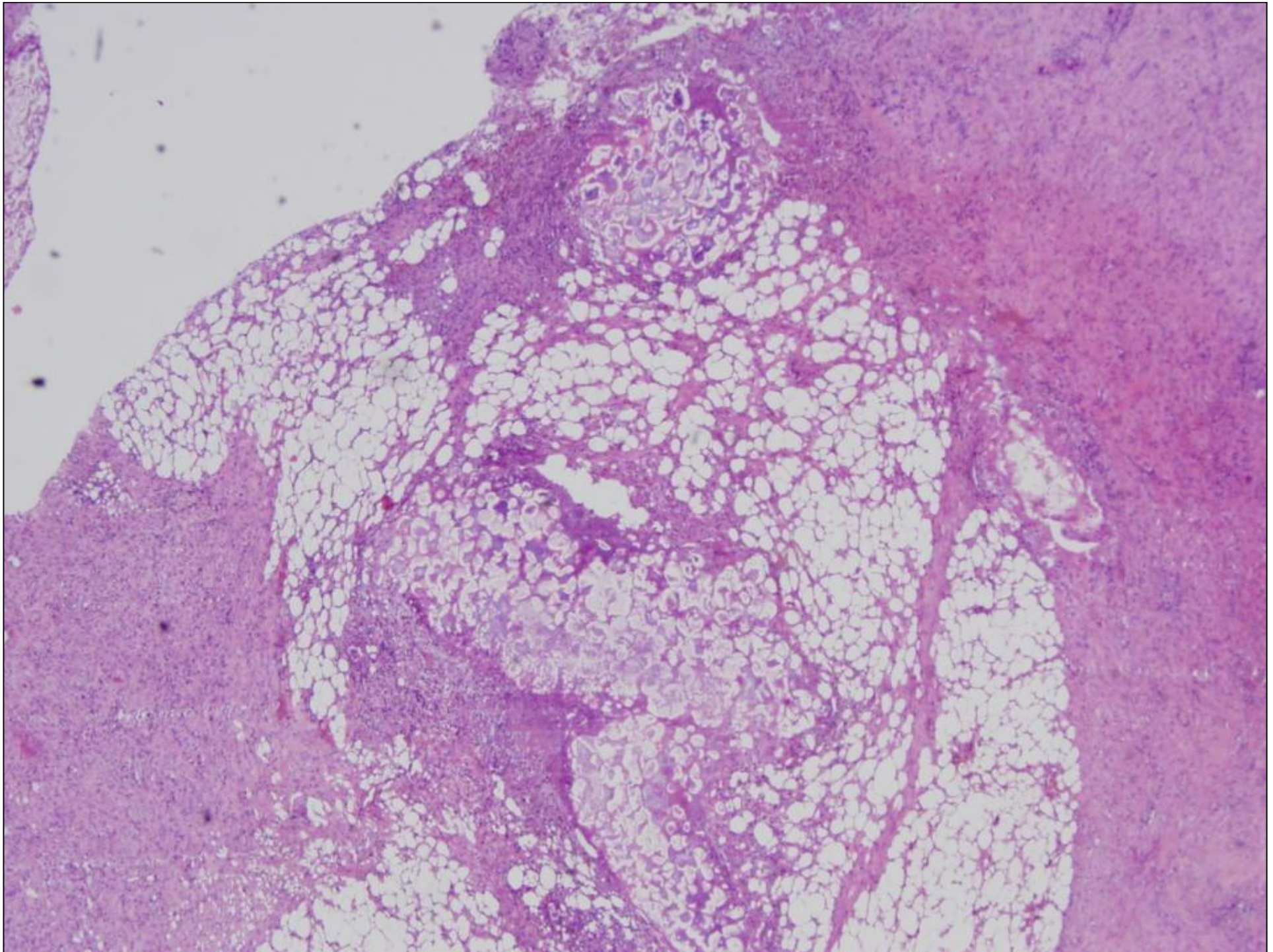
SE-AOK RAD.ONKOT.KLIN
SOMATOM PLUS 4
VC10B
K-SP-CR
27-MAR-1950
08:46:00
11:20:55.55
54 éves nő. A.: sigilloc. Cc. (???)

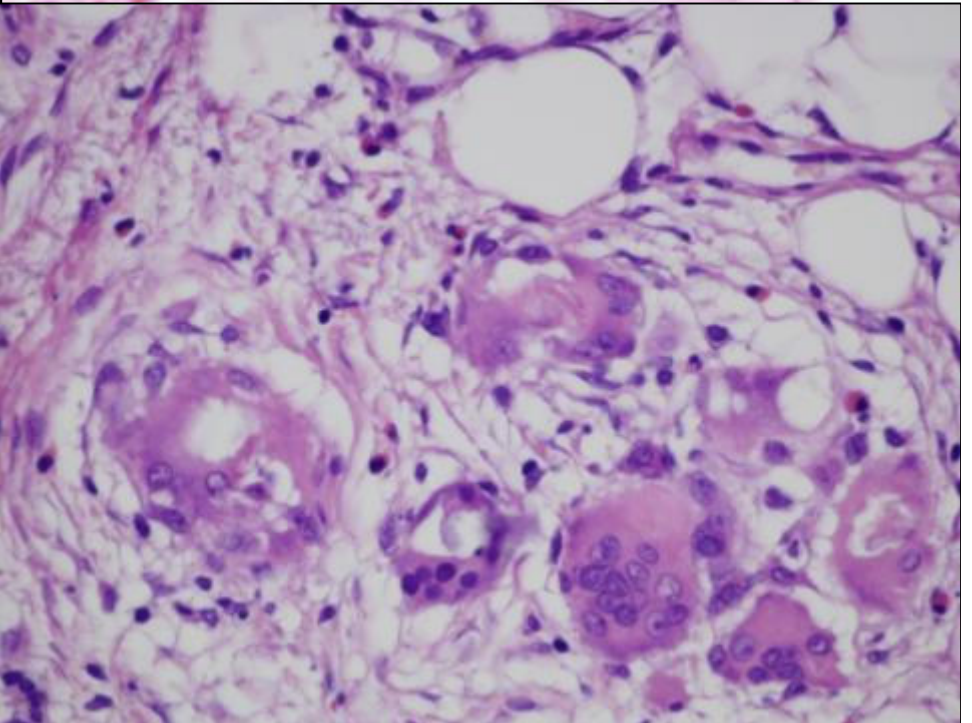
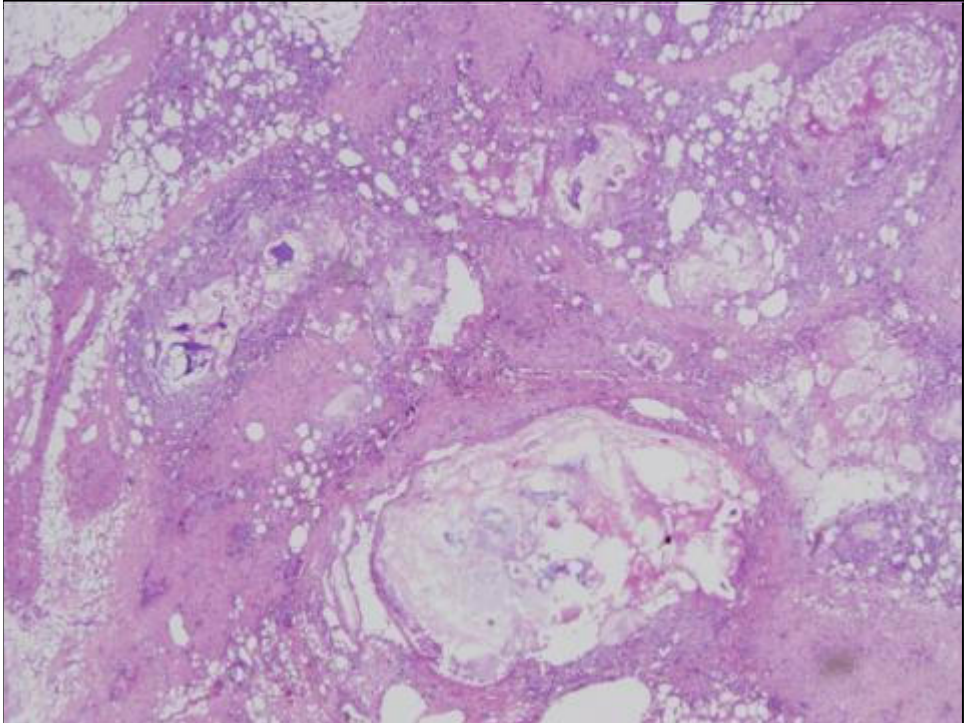
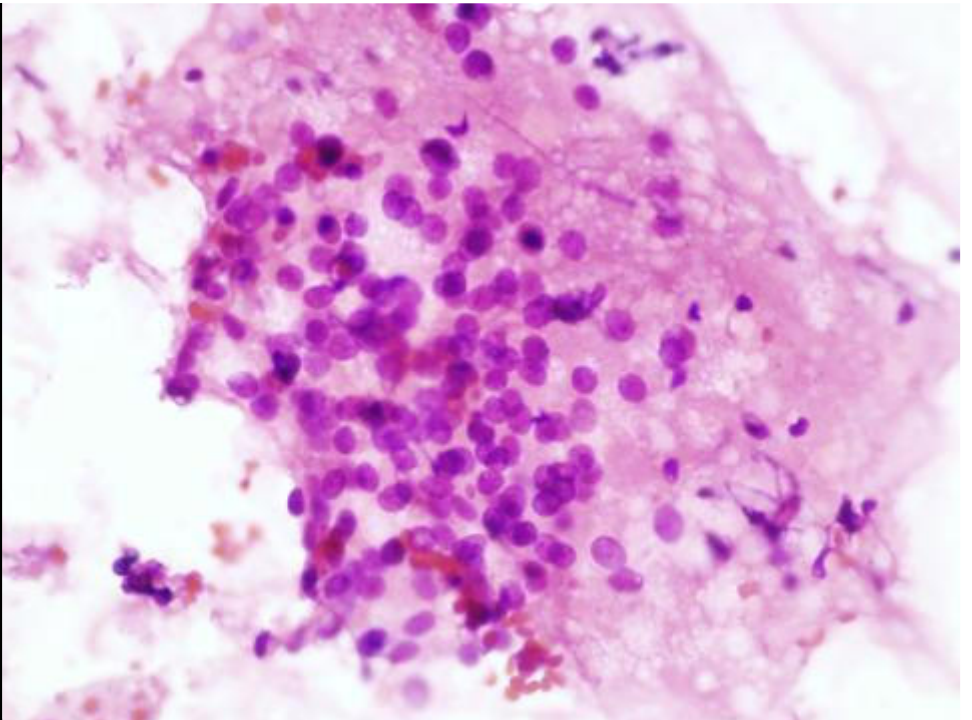
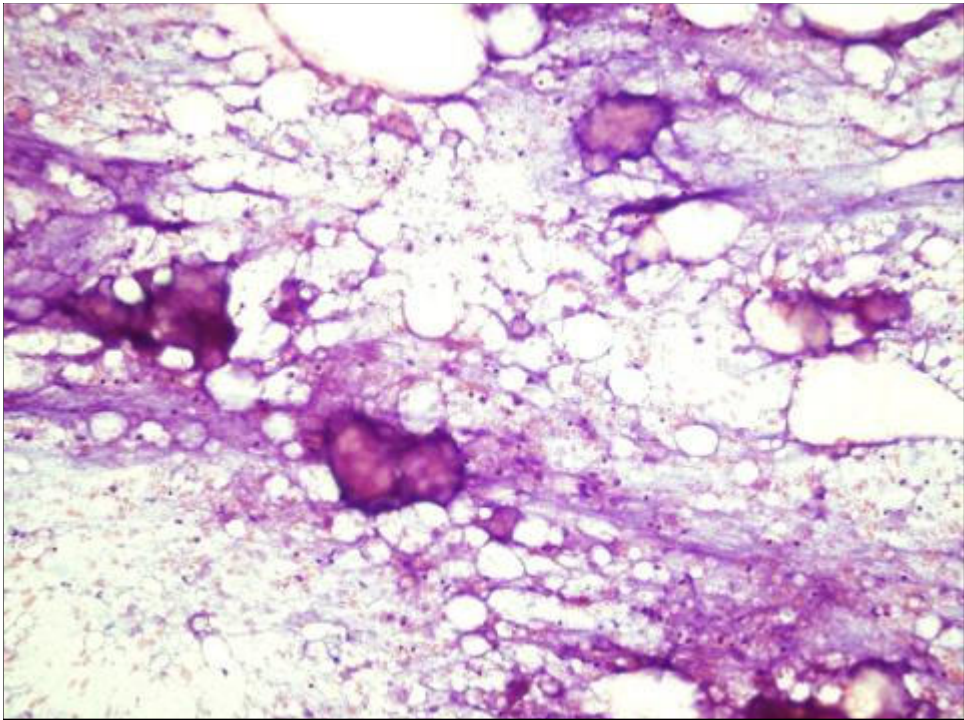
A pancreas elmosódott szerkezetű.
CT vezérelt FNAB.

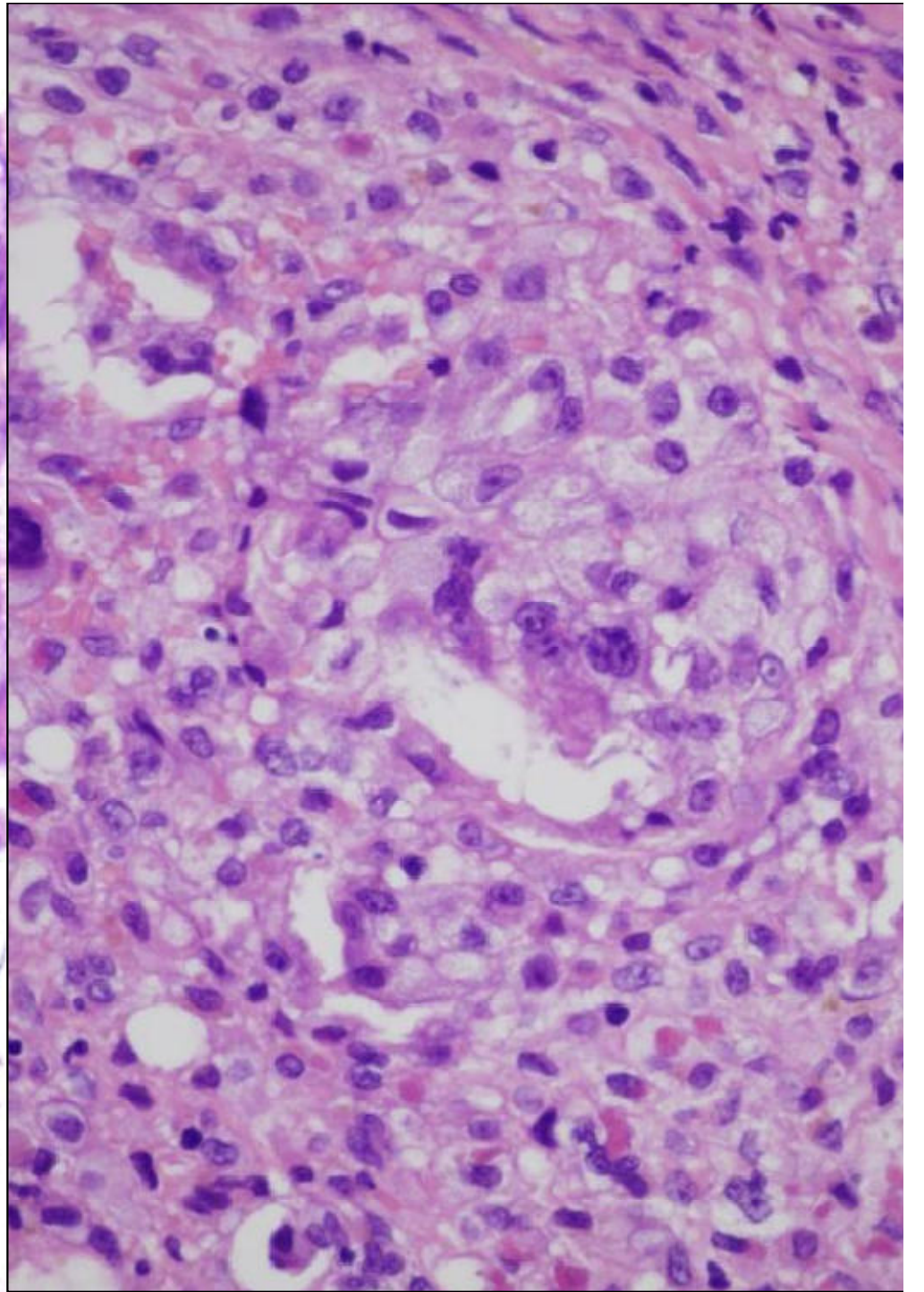
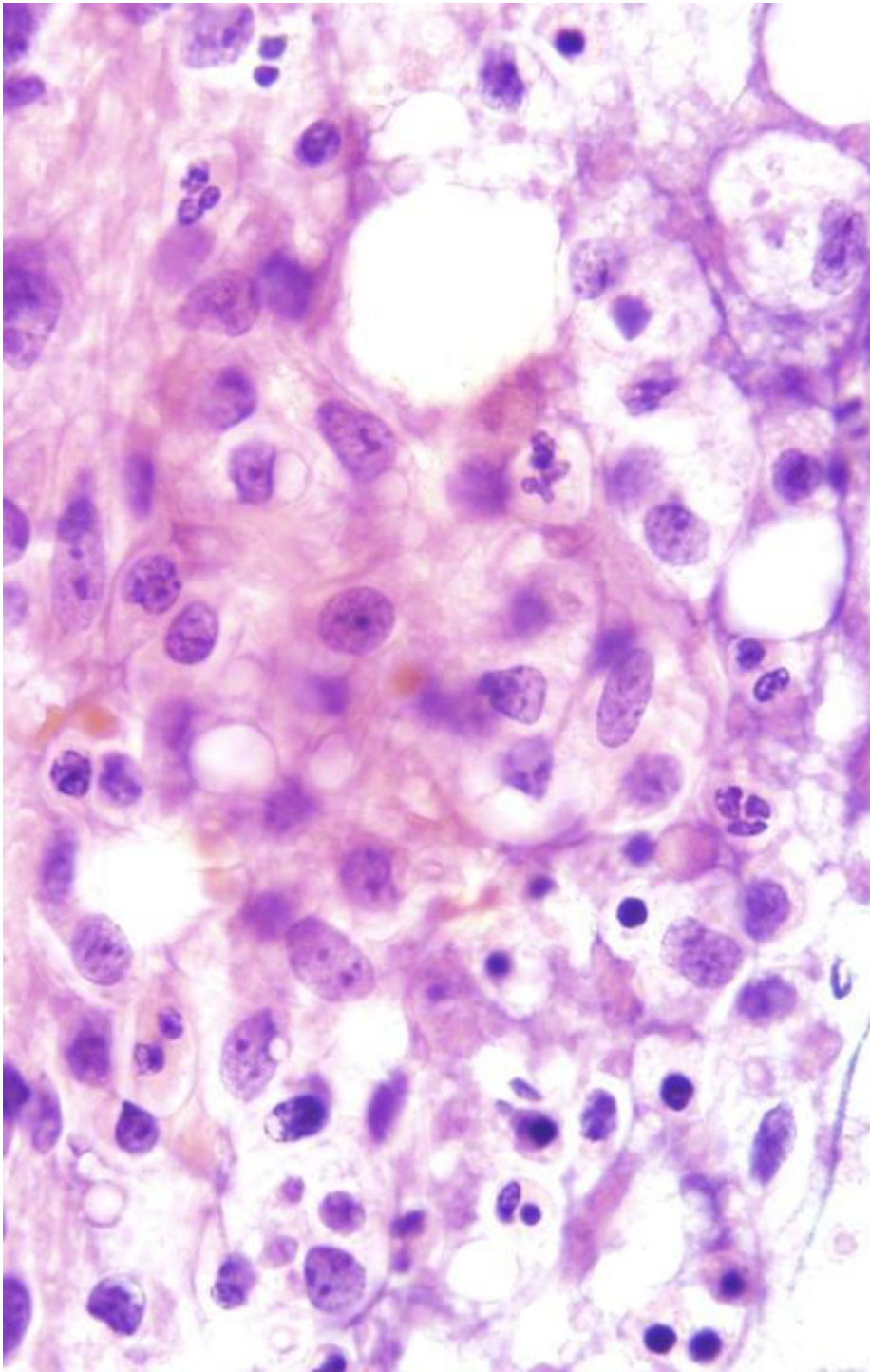


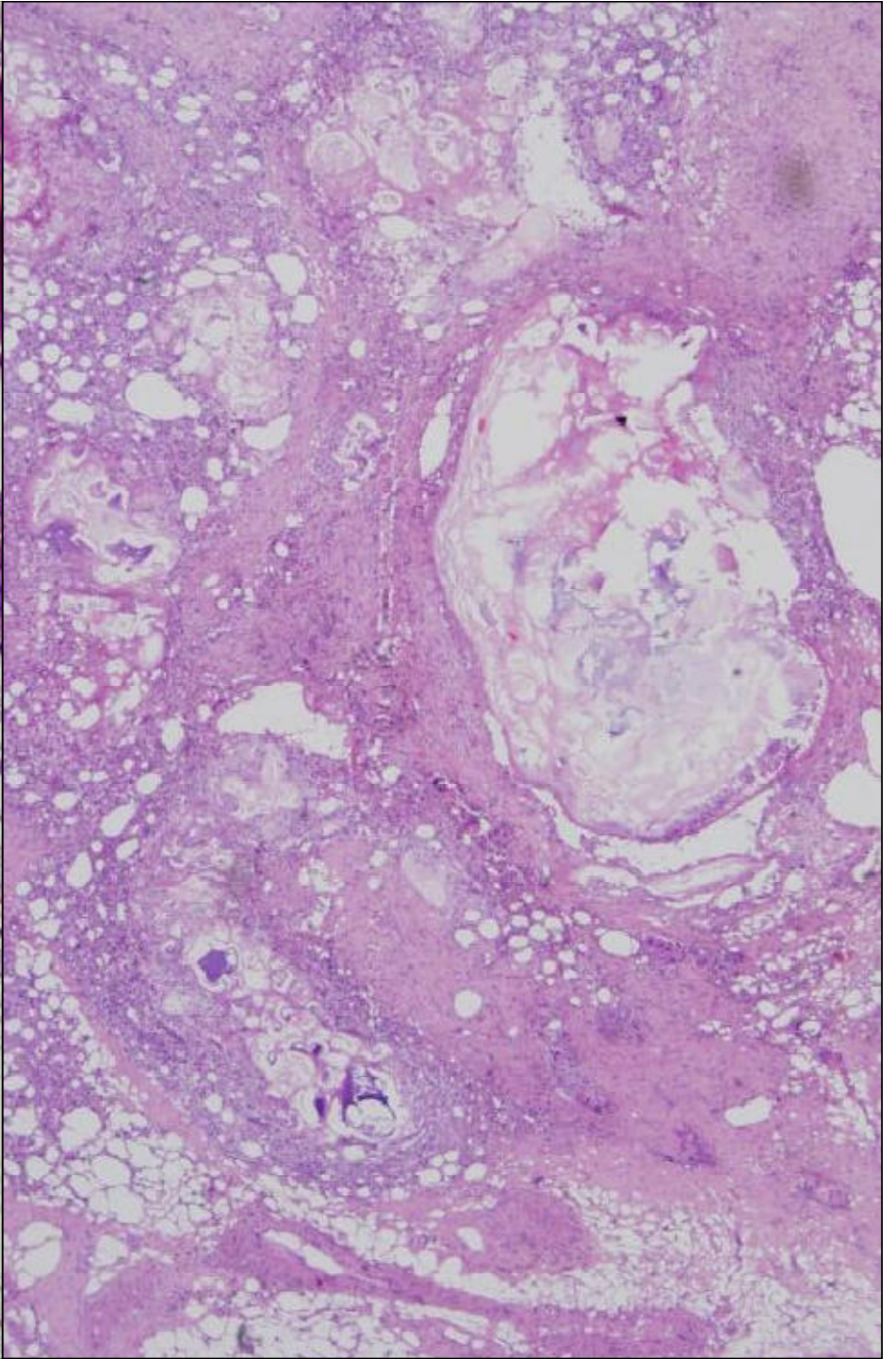
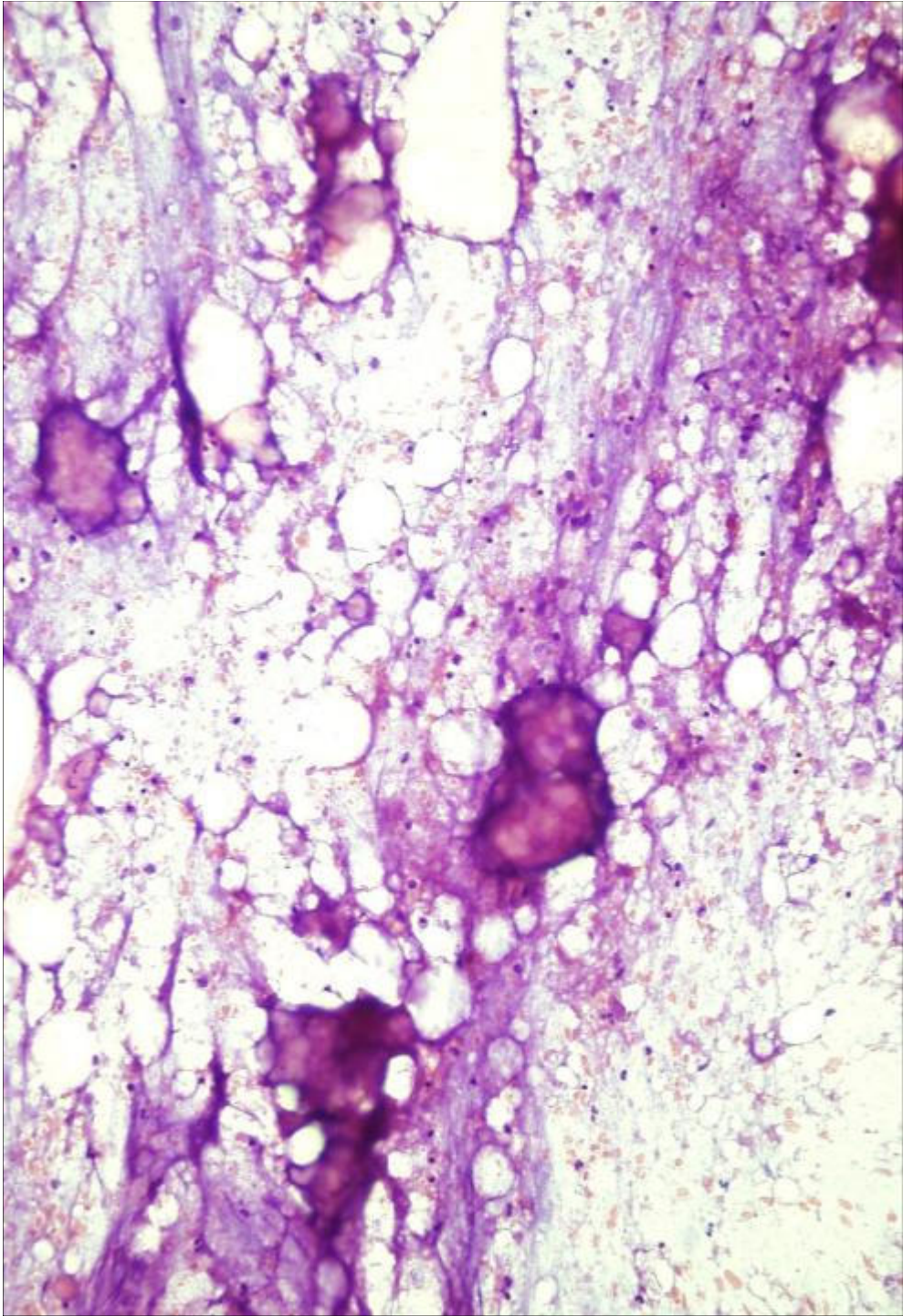


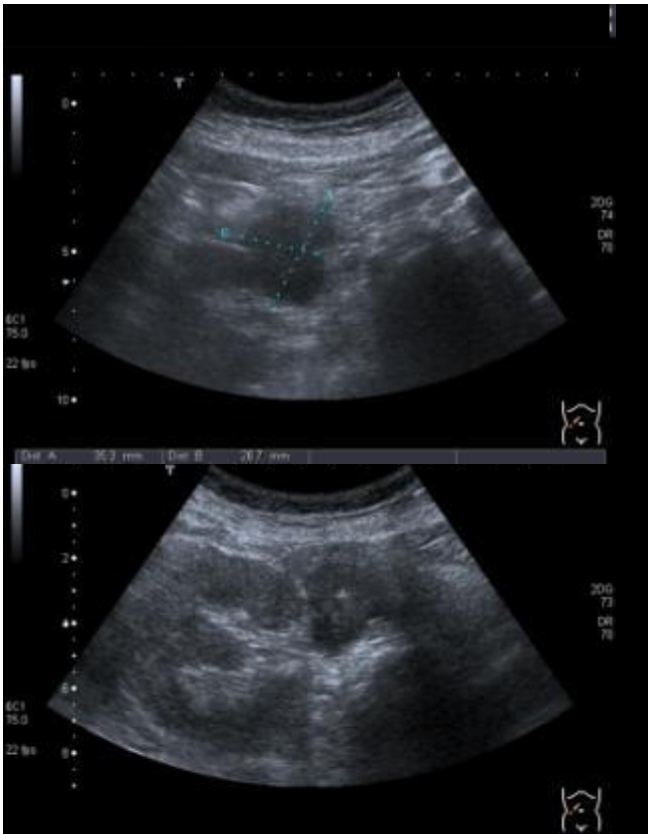












67 éves nő

Pancreas tu?

A pancreas fej
mögött (!!)

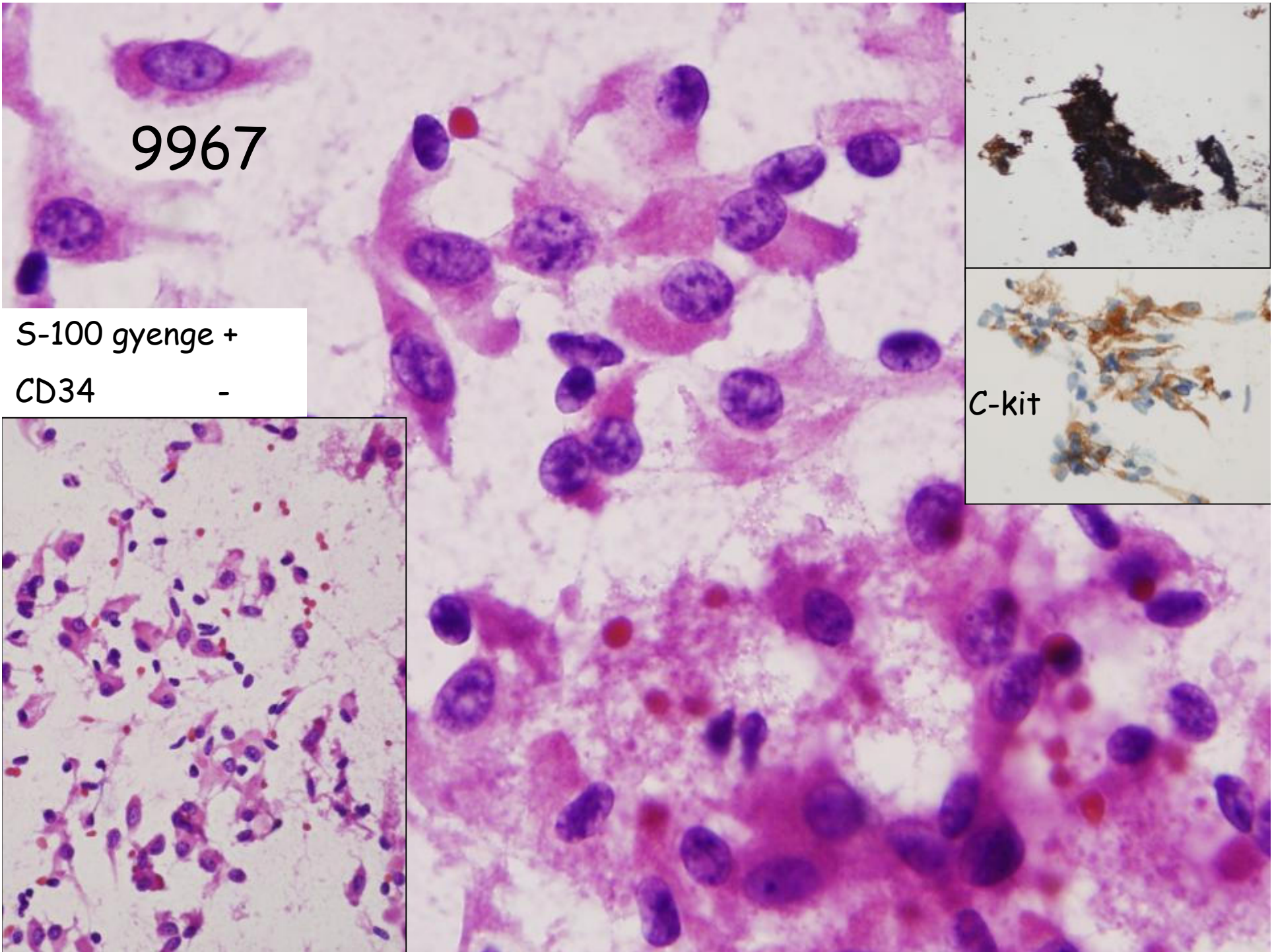
35 mm Ø-jű
echoszegény képlet

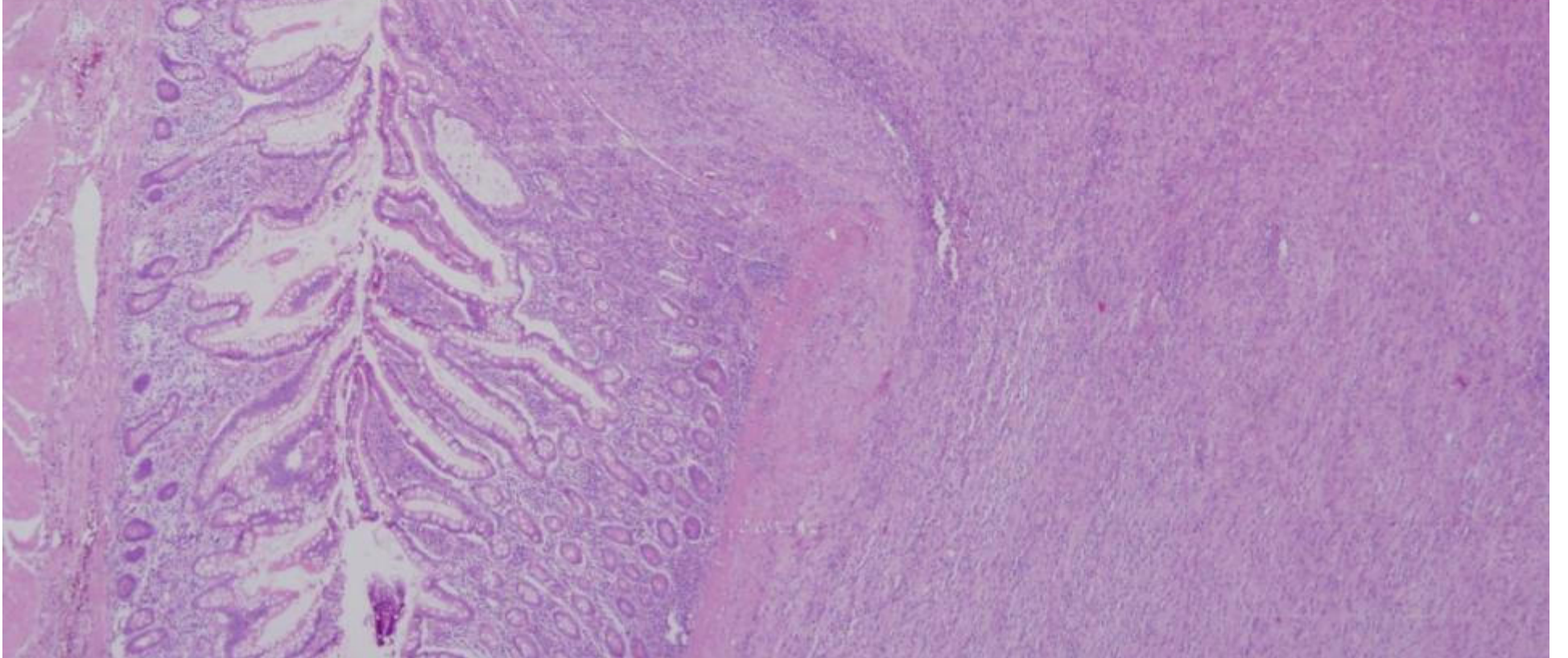


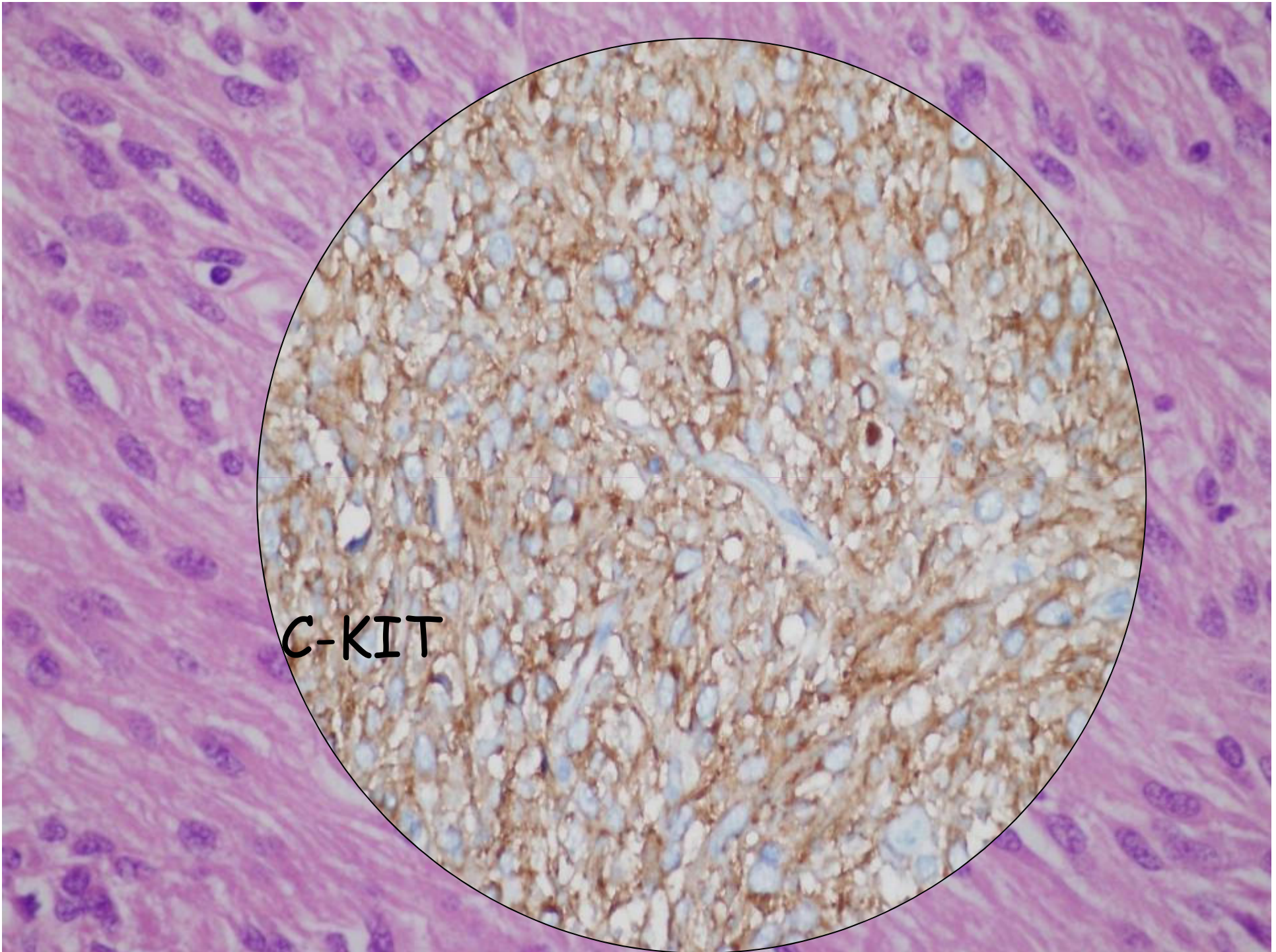
9967

S-100 gyenge +
CD34 -

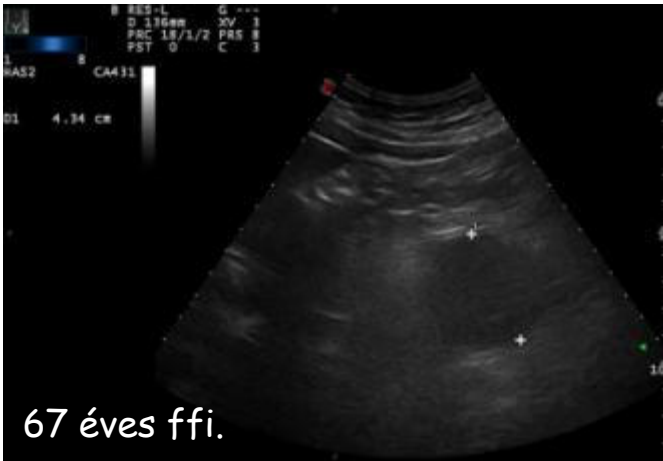C-kit





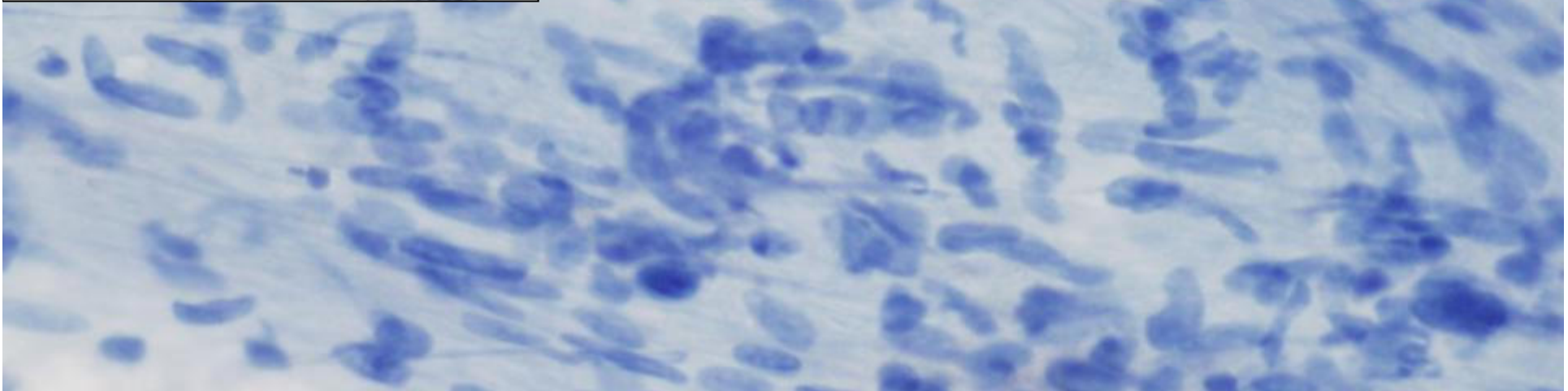
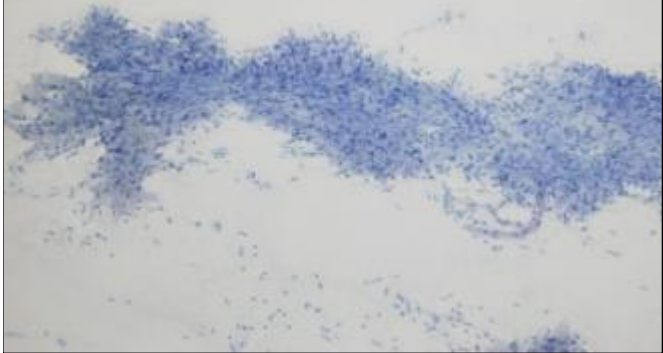


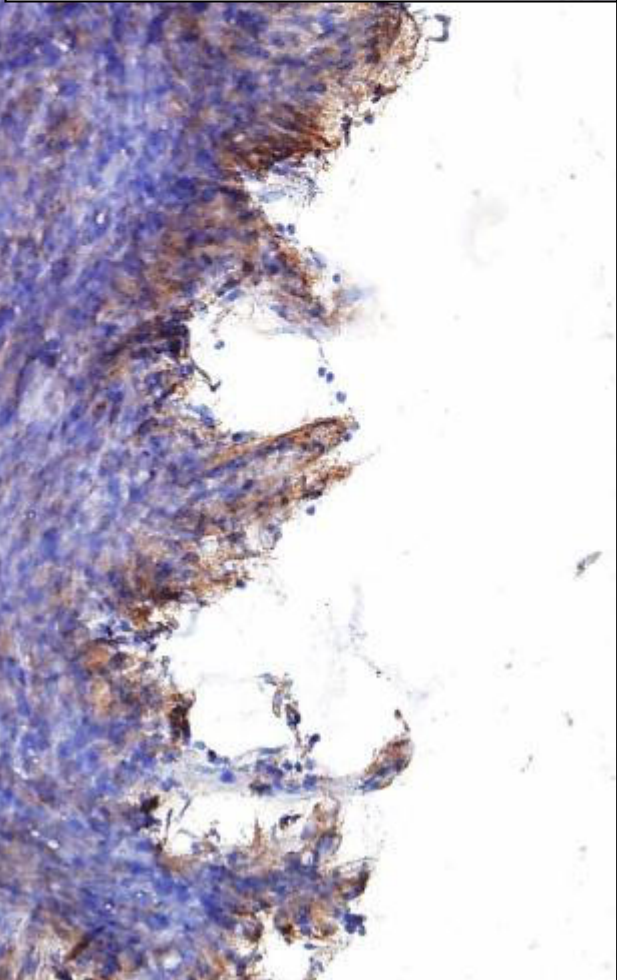
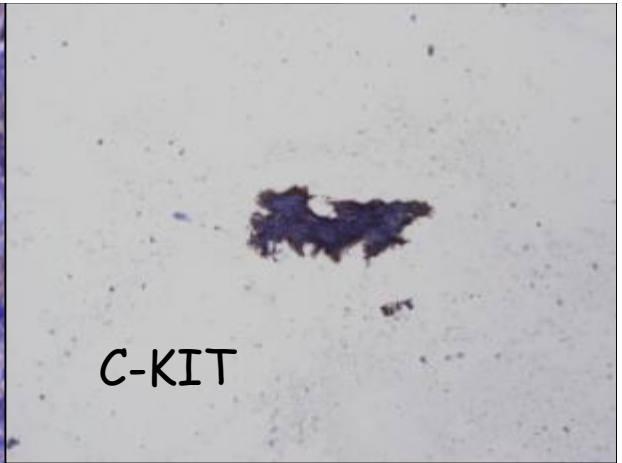
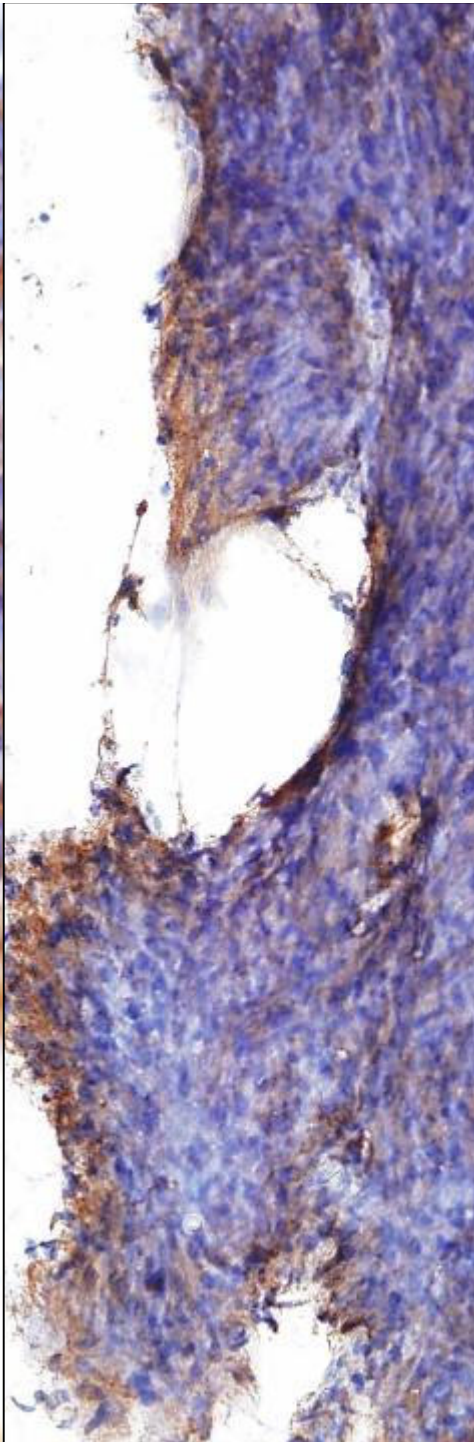
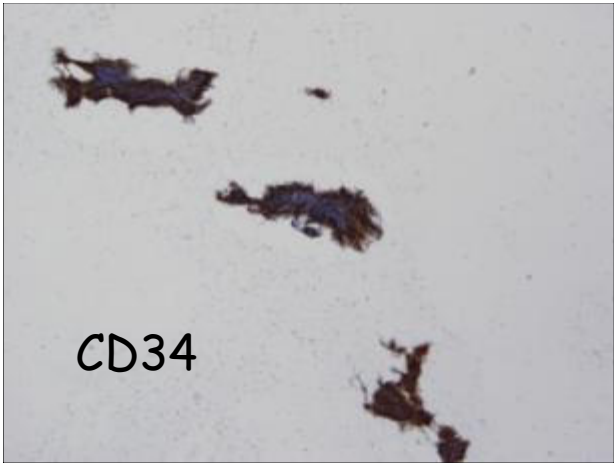
C-KIT

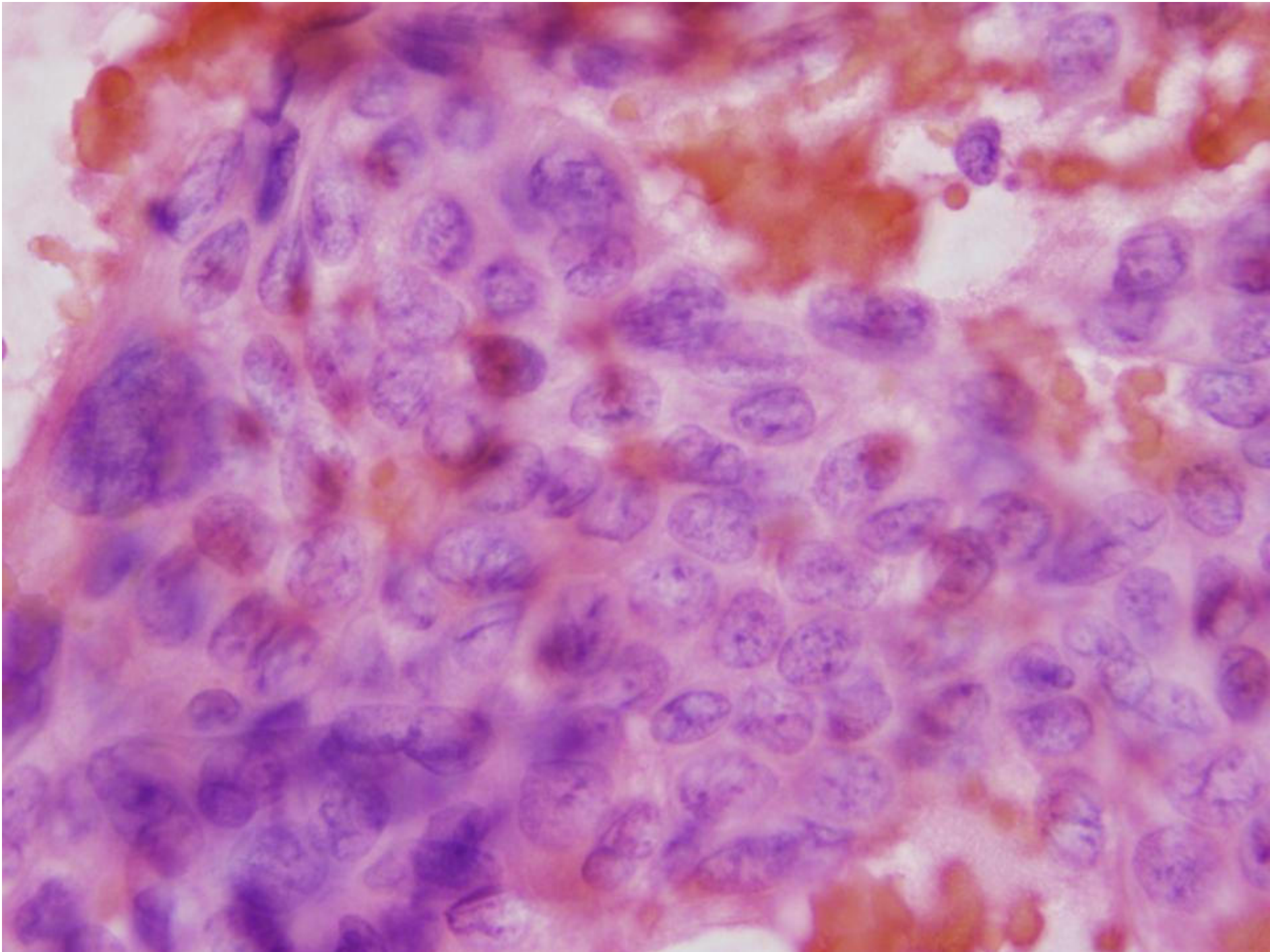


67 éves ffi.

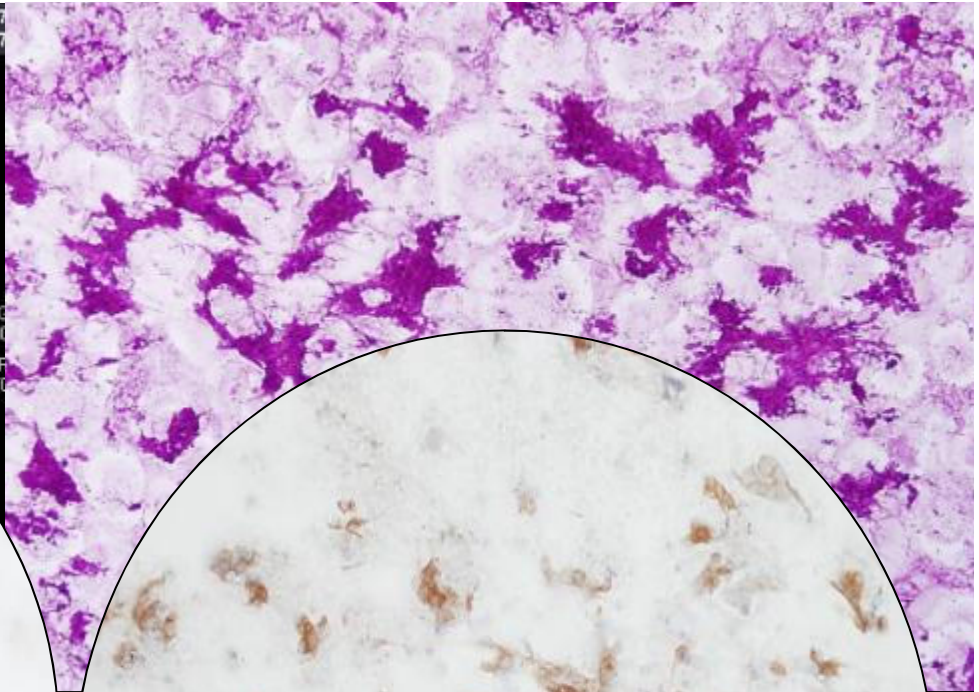
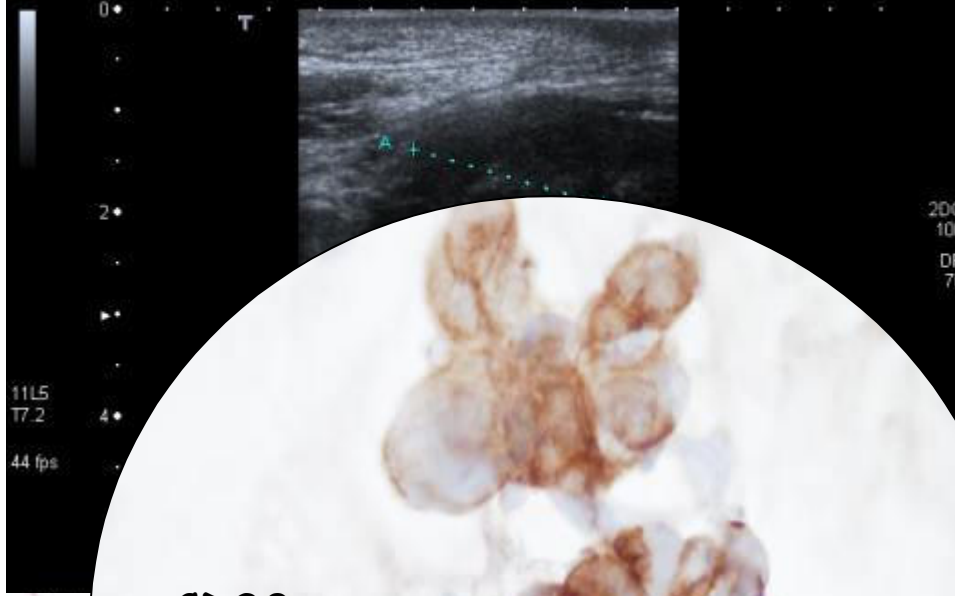
FNAB a gyomor melletti 45 mm Ø-jű echoszegény képletből.



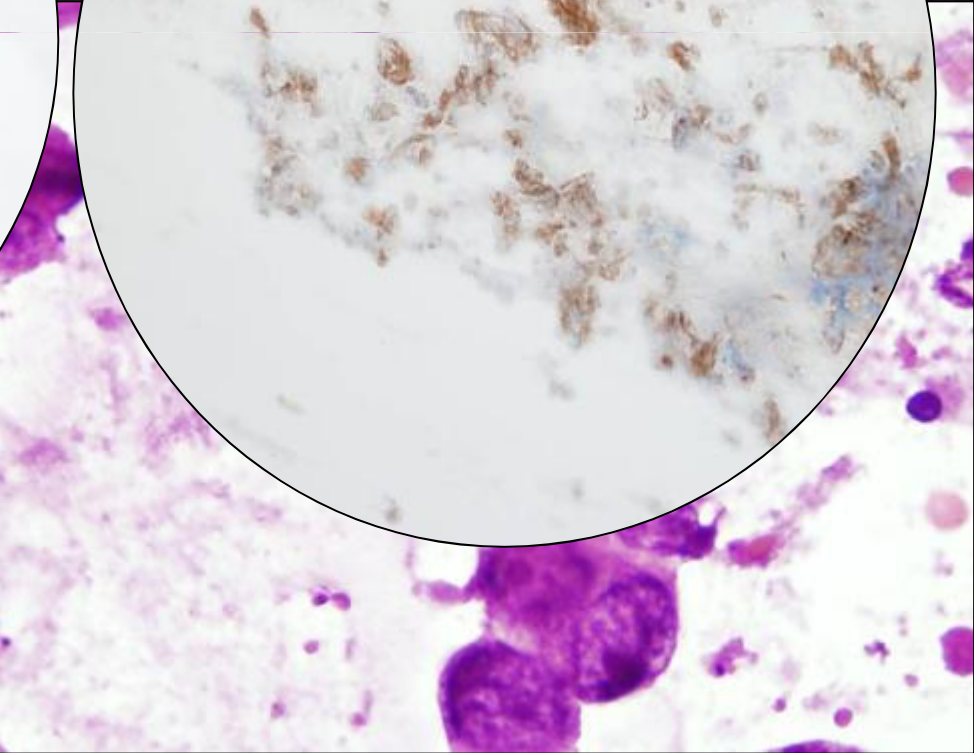
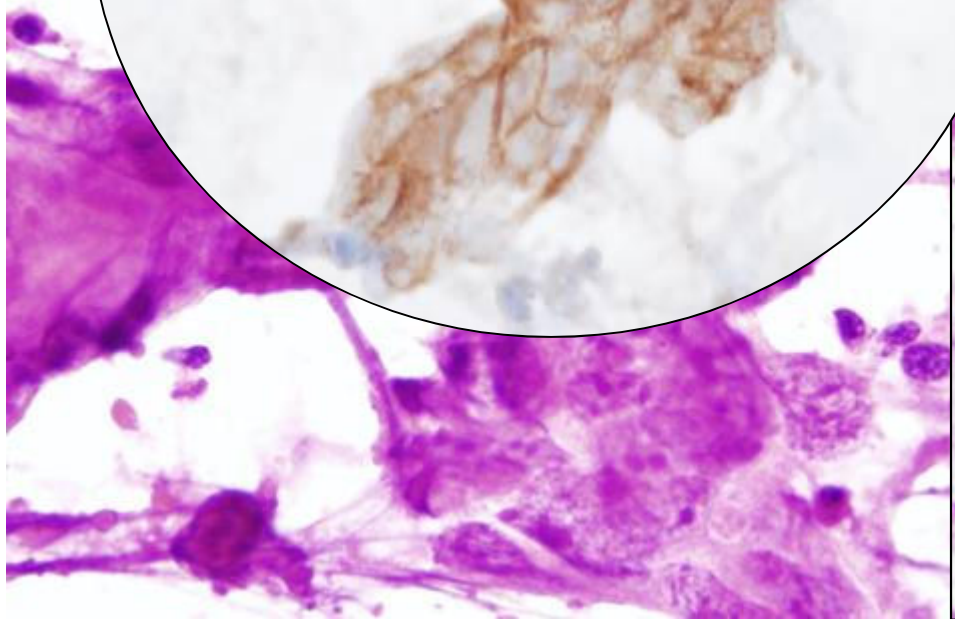
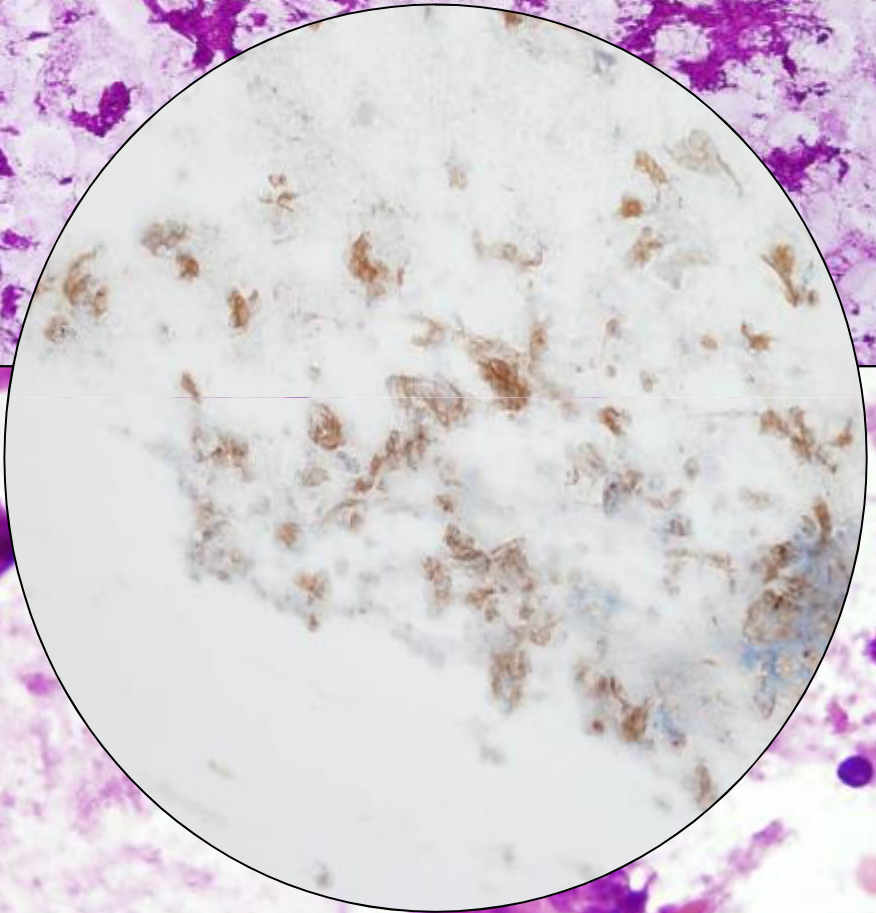
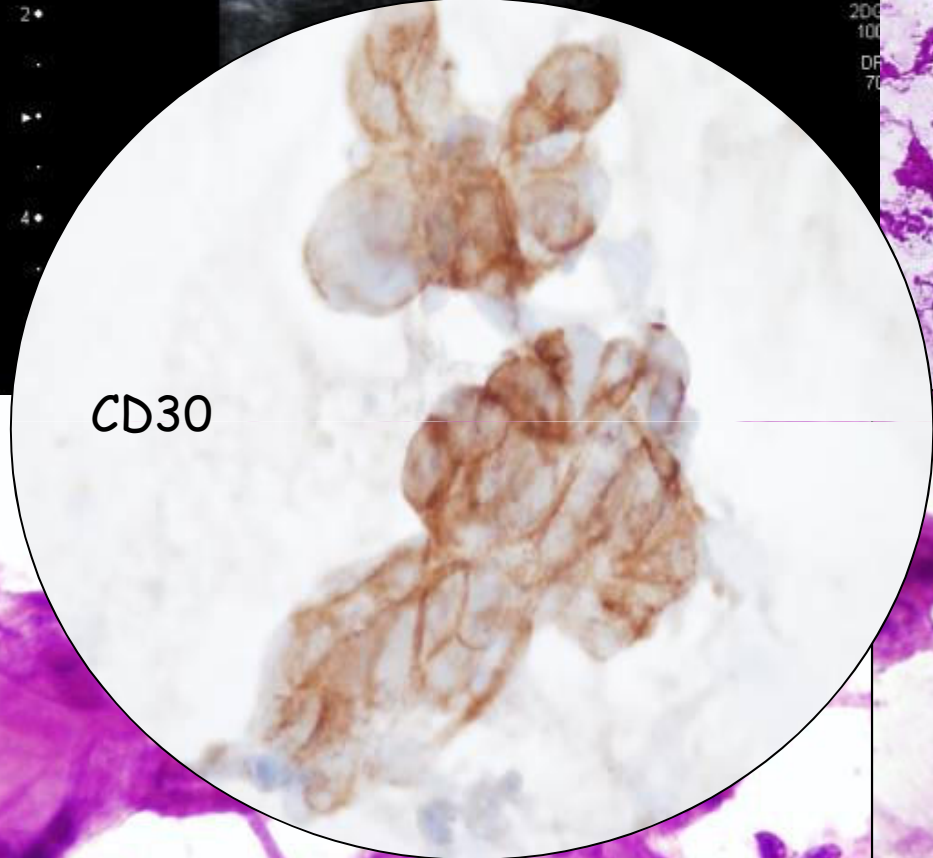





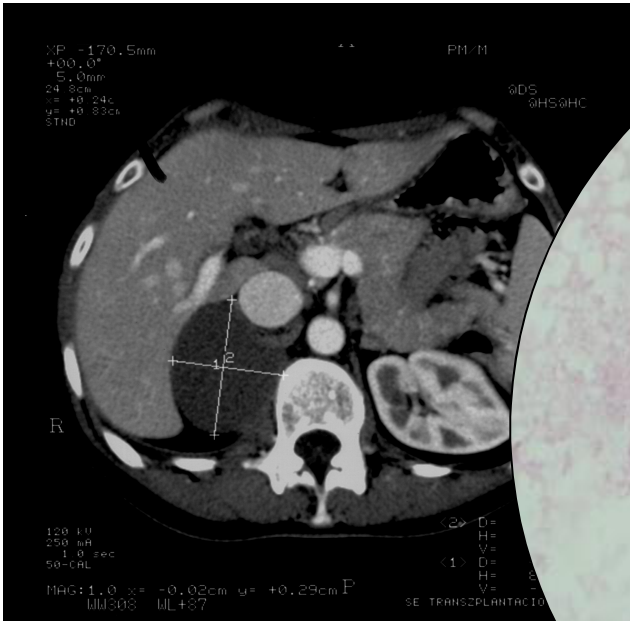
2465/07



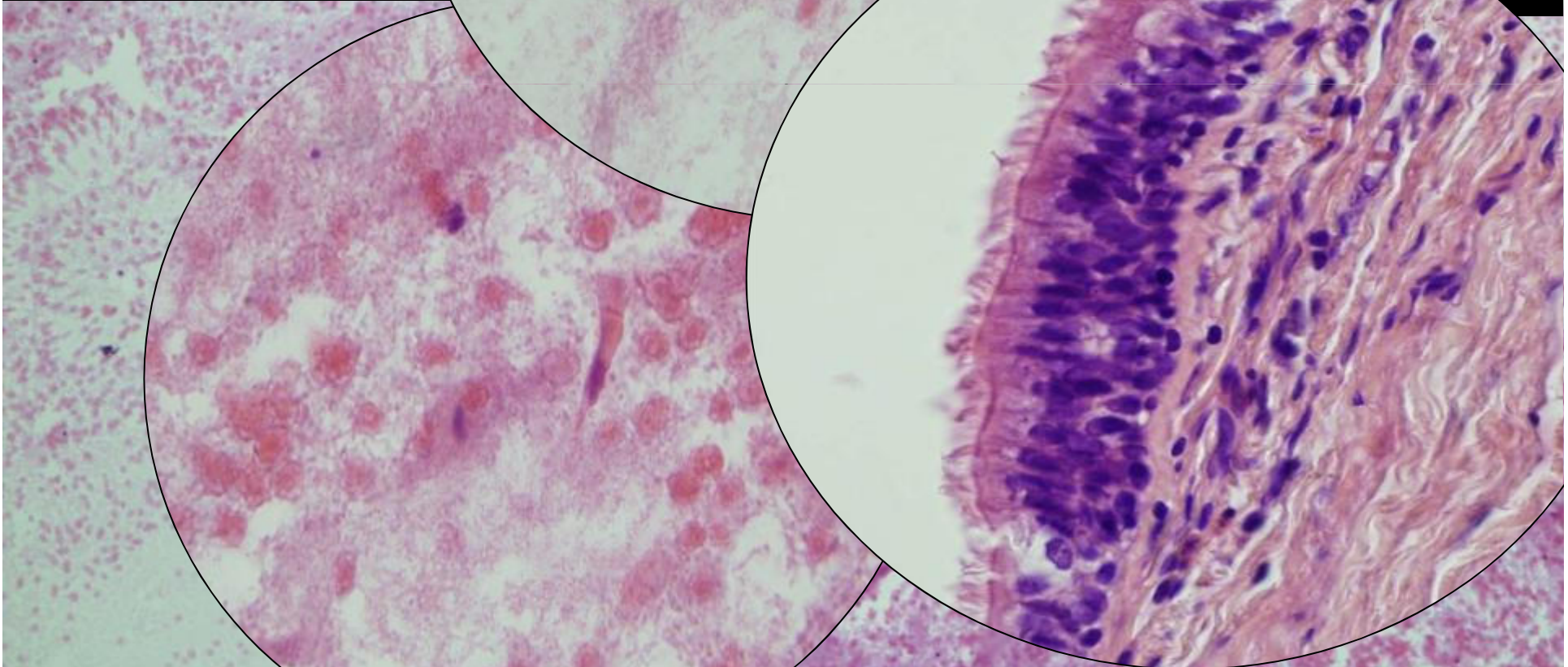
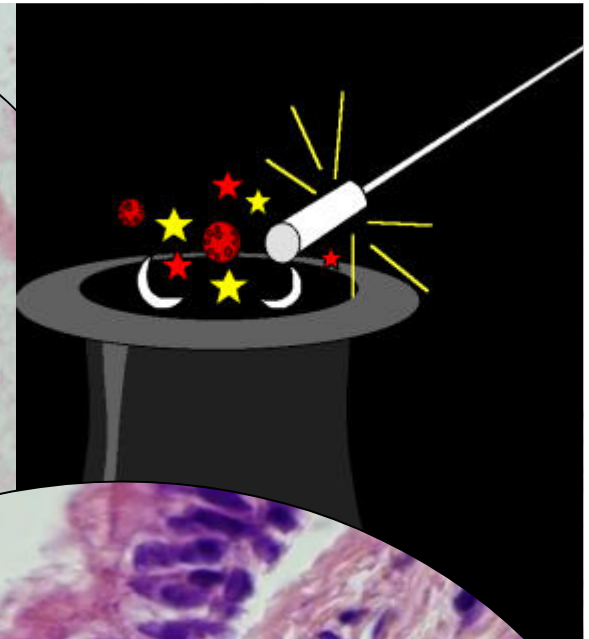
CD30







46 éves nő. Mal. Gyanús képlet
a jobb MV régióban.



Bölcs tanácsok.....

