

MOLECULAR PATHOLOGY AND BIOMARKER TESTING IN DIFERENT TYPES OF OVARIAN CARCINOMA

Xavier Matias-Guiu, MD, PhD

Hospital U Arnau de Vilanova, Univ Lleida.
IRBLLEIDA, Hospital U de Bellvitge, IDIBELL

HGSC

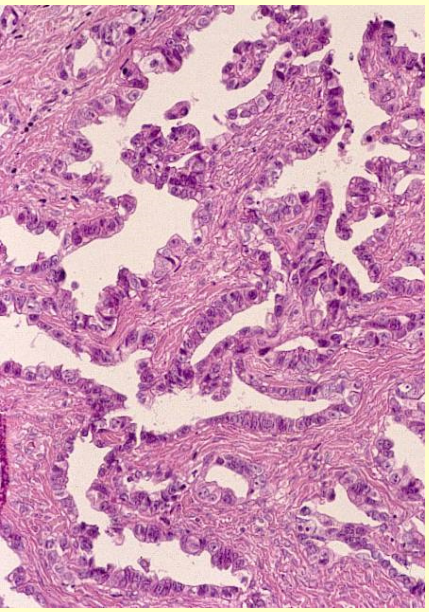

LGSC

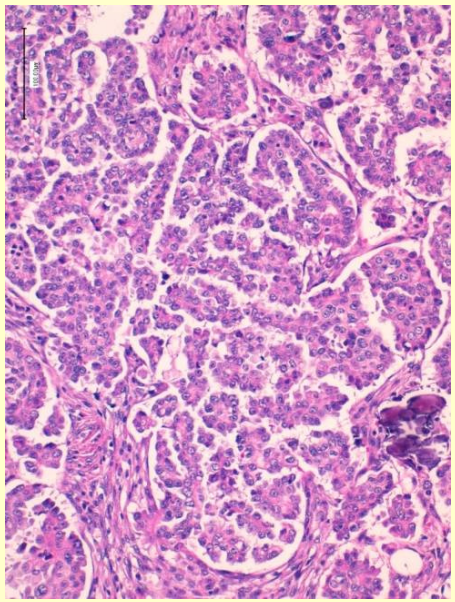

END

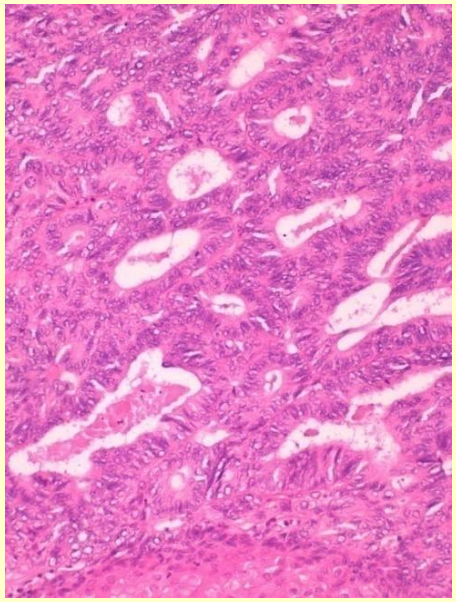

CLEAR C

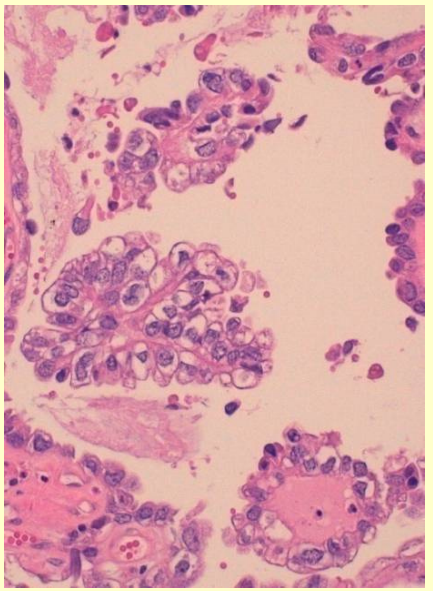

MUC

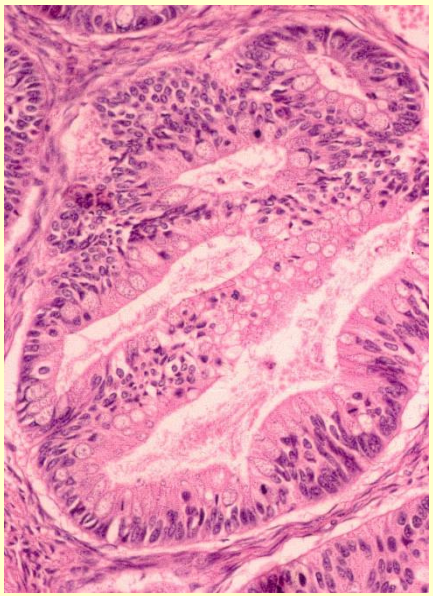

OVARIAN CANCER

High grade serous Ca	**70%**
Low grade serous Ca	**5%**
Endometrioid Ca	**10%**
Clear Cell Ca	**10%**
Mucinous Ca	**3%**

Sero-Mucinous, Brenner, other tumors

OVARIAN CANCER

High grade serous Ca	**70%**
Low grade serous Ca	**5%**
Endometrioid Ca	**10%**
Clear Cell Ca	**10%**
Mucinous Ca	**3%**

Sero-Mucinous, Brenner, other tumors

HIGH GRADE SEROUS OVARIAN CANCER

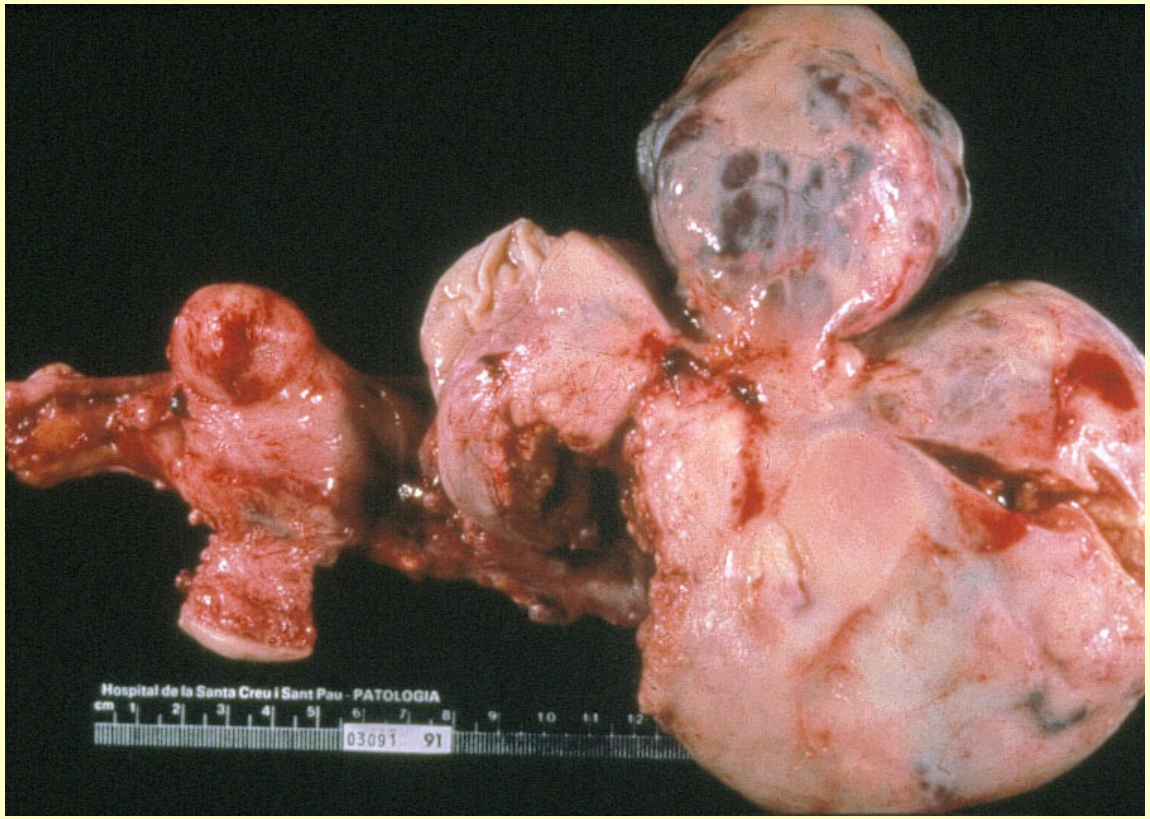

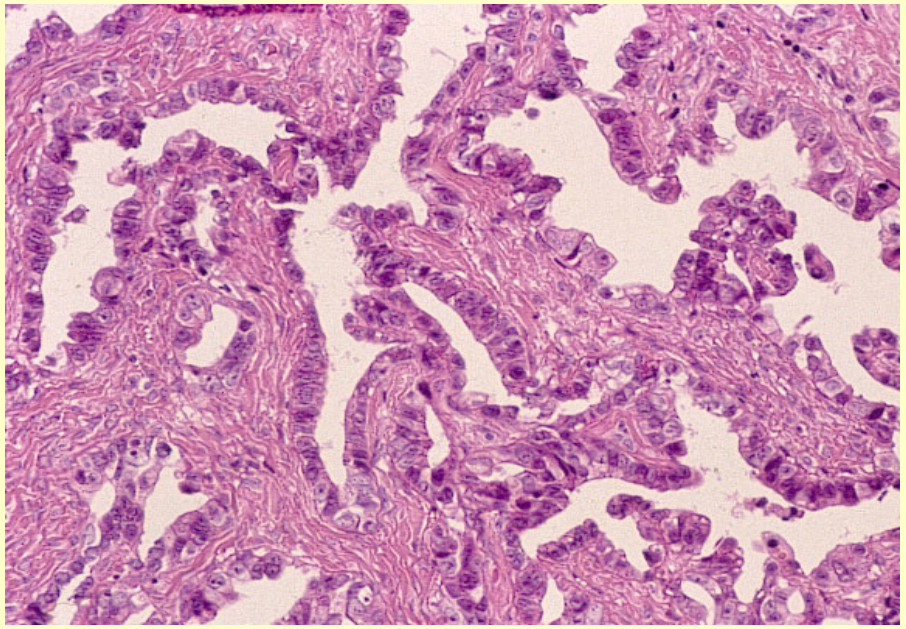

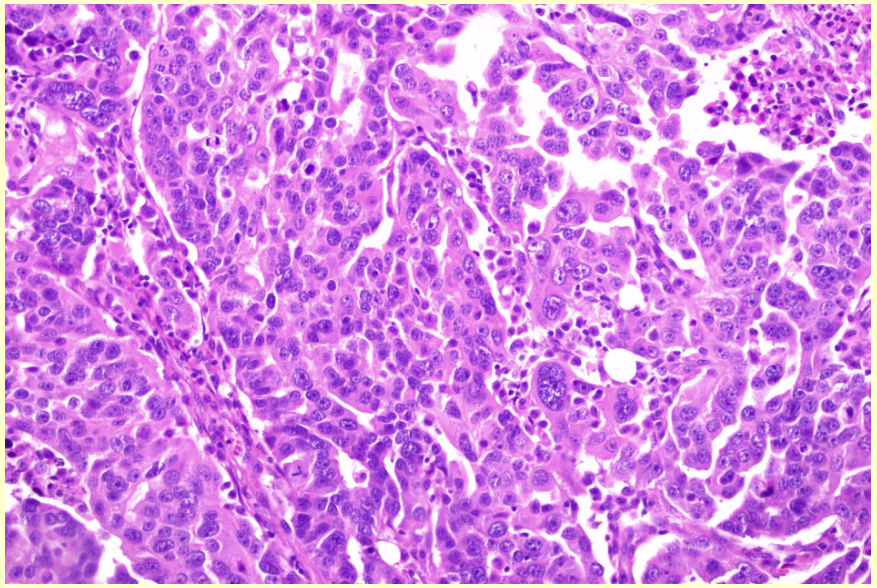

Journal of Pathology
J Pathol 2010; **221**: 49–56
Published online 3 February 2010 in Wiley InterScience
(www.interscience.wiley.com) DOI: 10.1002/path.2696

ORIGINAL PAPER

Driver mutations in *TP53* are ubiquitous in high grade serous carcinoma of the ovary

Ahmed Ashour Ahmed,[1,2] Dariush Etemadmoghadam,[3] Jillian Temple,[1,2] Andy G Lynch,[2] Mohamed Riad,[4] Australian Ovarian Cancer Study Group, Raghwa Sharma,[5] Colin Stewart,[6] Sian Fereday,[3] Carlos Caldas,[2,7] Anna deFazio,[8] David Bowtell[3,9]* and James D Brenton[1,2]*

Table 3. The type of *TP53* mutation does not influence progression-free survival

Index category (*n*)	Comparison (*n*)	Hazard ratio	CI	Log-rank *p* value
Mutant (120)	Wild type (7)	1.4	0.6–3.1	0.5
Not missense (52)	Missense (68)	0.9	0.6–1.4	0.8
DBM (44)	NDBM (24)	1	0.6–1.7	1

DBM = DNA binding mutations; NDBM = non-DNA binding mutations.

Table 4. The type of *TP53* mutation does not influence overall survival

Index category (*n*)	Comparison (*n*)	Hazard ratio	CI	Log-rank *p* value
Mutant (120)	Wild type (7)	1.7	0.6–4.6	0.3
Not missense (52)	Missense (68)	1	0.7–1.6	1
DBM (44)	NDBM (24)	1.3	0.7–2.4	0.4

DBM = DNA binding mutations; NDBM = non-DNA binding mutations.

Integrated genomic analyses of ovarian carcinoma

The Cancer Genome Atlas Research Network*

Here we report that high-grade serous ovarian cancer is characterized by *TP53* mutations in almost all tumours (96%)

International Journal of Gynecological Pathology
35:48–55, Lippincott Williams & Wilkins, Baltimore
© 2015 International Society of Gynecological Pathologists

Original Article

Molecular Alterations of *TP53* are a Defining Feature of Ovarian High-Grade Serous Carcinoma: A Rereview of Cases Lacking *TP53* Mutations in The Cancer Genome Atlas Ovarian Study

Russell Vang, M.D., Douglas A. Levine, M.D., Robert A. Soslow, M.D., Charles Zaloudek, M.D., Ie-Ming Shih, M.D., Ph.D., and Robert J. Kurman, M.D.

TABLE 1. *Rereview diagnoses and molecular data for TP53 wild-type high-grade serous carcinomas from the TCGA study*

		Rereview pathologist					Molecular data from the TCGA(6)			
Case	TCGA*	*A*	*B*	*C*	*D*	*E*	*TP53* HD†	*BRCA*‡	No. Muts§	CNA (%)‖
1	09-2056	LGSC	HG Endo	LGSC	HGSC	HGSC	–	–	68	46
2	10-0933	Met	HG Endo	HG Endo	Met	Met	–	–	33	47
3	13-0727	HGSC¶	HGSC¶	HGSC¶	HGSC	HGSC	–	–	21	22
4	13-0755	CCC	LG/HGSC#	CCC	HGSC	HGSC	–	–	73	18
5	13-1408	HGSC	HGSC	HGSC	HGSC	HGSC	+	+	78	31
6	13-1477	LGSC	LGSC	LGSC	LGSC	LGSC	–	–	42	9
7	24-1544	Met	Met	Met	HGSC	HGSC	–	–	17	31
8	24-1565	HG Endo	HG Endo	HG Endo	HG Endo	HG Endo	–	–	25	9
9	24-2038	APST	APST	APST	APST	APST	–	–	10	11
10	25-1316	LGSC	HG Endo	LGSC	HGSC	HGSC	–	–	13	30
11	25-1328	LGSC	LGSC	LGSC	LGSC	LGSC	–	–	10	NA
12	25-2042	CCC	Adeno, NOS	HGSC	HGSC	HGSC	–	–	56	19
13	25-2408	LGSC	LGSC	LGSC	LGSC	LGSC	–	–	13	9
14	61-2095	LGSC	LGSC	LGSC	LGSC	LGSC	–	–	109	1

¶HGSC with LGSC architecture.

†Homozygous deletion of *TP53*.

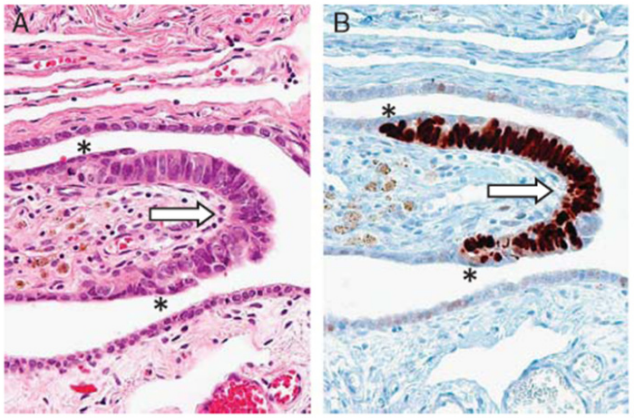

Journal of Pathology
J Pathol 2018; **246:** 344–351
Published online 27 September 2018 in Wiley Online Library (wileyonlinelibrary.com) DOI: 10.1002/path.5145

ORIGINAL PAPER

Evidence for lineage continuity between early serous proliferations (ESPs) in the Fallopian tube and disseminated high-grade serous carcinomas

Thing Rinda Soong[1], Brooke E Howitt[2], Alexander Miron[3], Neil S Horowitz[4], Frank Campbell[3], Colleen M Feltmate[4], Michael G Muto[4], Ross S Berkowitz[4], Marisa R Nucci[1], Wa Xian[5] and Christopher P Crum[1]*

Table 3. Correlation of *TP53* mutations detected in ESPs with synchronous HGSCs

Case	Multiple foci	P53 IHC	*TP53* mutation	Average coverage	Average allele frequency (%)	Identical mutation at multiple foci	Sample site	P53 IHC	*TP53* mutation	Mutation	Average coverage	Average allele frequency (%)	Identical *TP53* mutation in ESPs and synchronous HGSCs
1*	Yes	+	c.743G > A	131	20	Yes	Primary	+	c.743G > A	Missense	1181	38	Yes
2	No	ID	c.279delG	2706	12	NA	Primary	N	c.279delG	Indel	4437	39	Yes
3	No	N	c.112C > T	3612	10	NA	Primary	N	c.112C > T	Nonsense	4818	6	Yes
4	No	ID	c.919 + 1G > T	366	5	NA	Primary	N	c.919 + 1G > T	Indel	39 193	50	Yes
5	No	+	c.578A > G	18 708	7	NA	Primary	+	c.754_762delCTCACCATC	indel	1435	67	No
6	Yes	+	c.452C > G	4027	21	No	Primary	+	c.394A > G	Missense	5251	70	No
		+	c.643A > G	2074	18								No
		+	c.394A > G	8544	1								Yes
7	No	ID	c.273_279delGCCCCTG	13	15	NA	Primary	N	c.273_279delGCCCCTG	Indel	8365	76	Yes
8	No	N	c.916C > T	2097	19	NA	Primary	+	c.455C > G	Missense	4718	33	No
9	No	ID	c.452C > G	7535	2	NA	Primary	+	c.452C > G	Missense	7417	30	Yes
10	No	ID	c.586C > T	1146	2	NA	Primary	N	c.586C > T	Nonsense	7891	72	Yes
11	No	+	c.476C > T	7301	0.7	NA	Primary	+	c.476C > T	Missense	6109	30	Yes
12	No	ID	c.216delC	2870	0.7	NA	Primary	+	c.818G > A	Missense	915	98	No

+: positive; N: null staining suggesting null mutation; ID: indeterminate; Indel: insertion or deletion.
*Case 1 revealed occult contralateral STIC and ESP in serial sections, which share identical *TP53* mutation to synchronous HGSC.
†The case with p53-positive ESP but insufficient DNA reads for assessment of *TP53* mutation is not included in this table.

HGSC – Pathogenetic Model

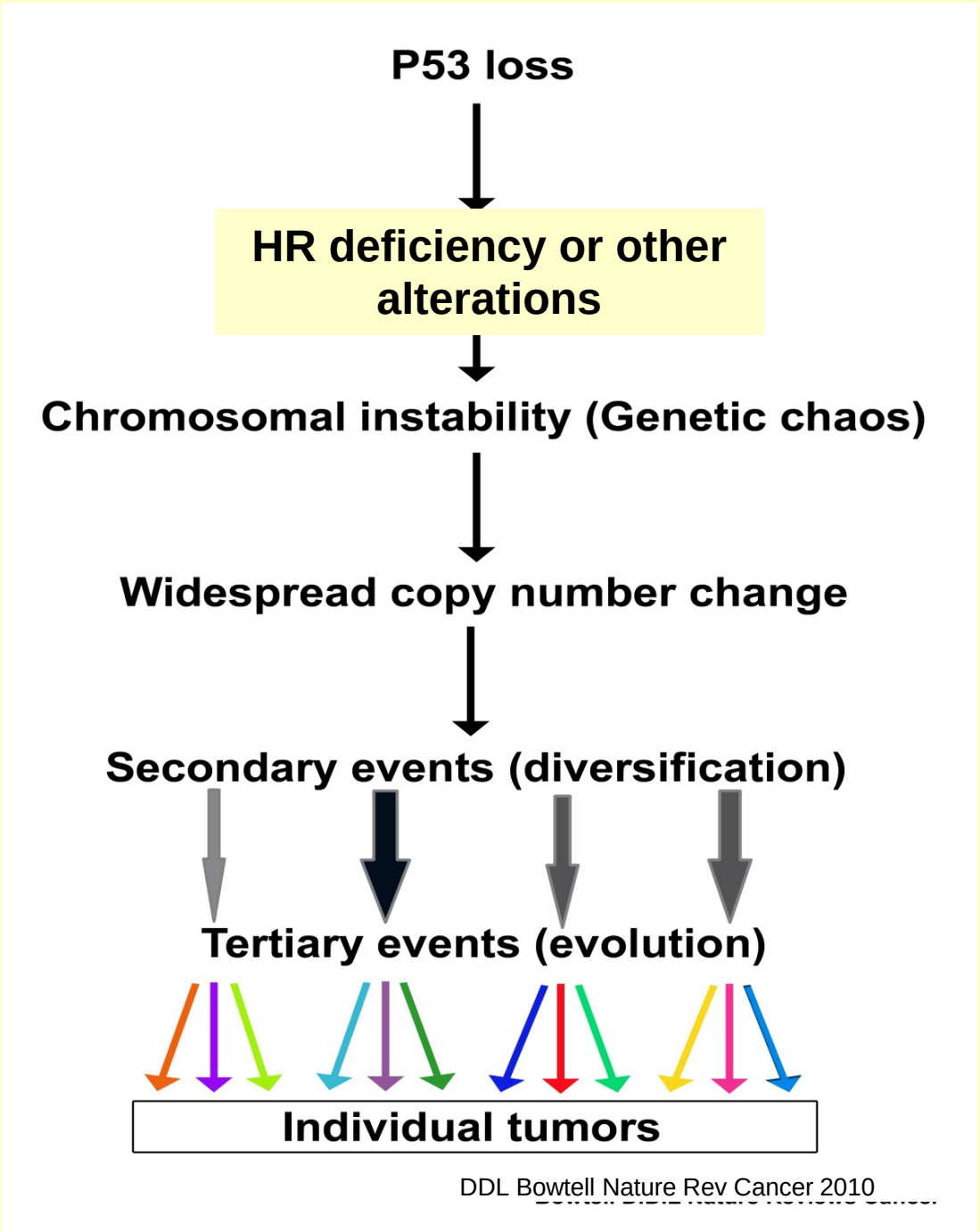

DDL Bowtell Nature Rev Cancer 2010

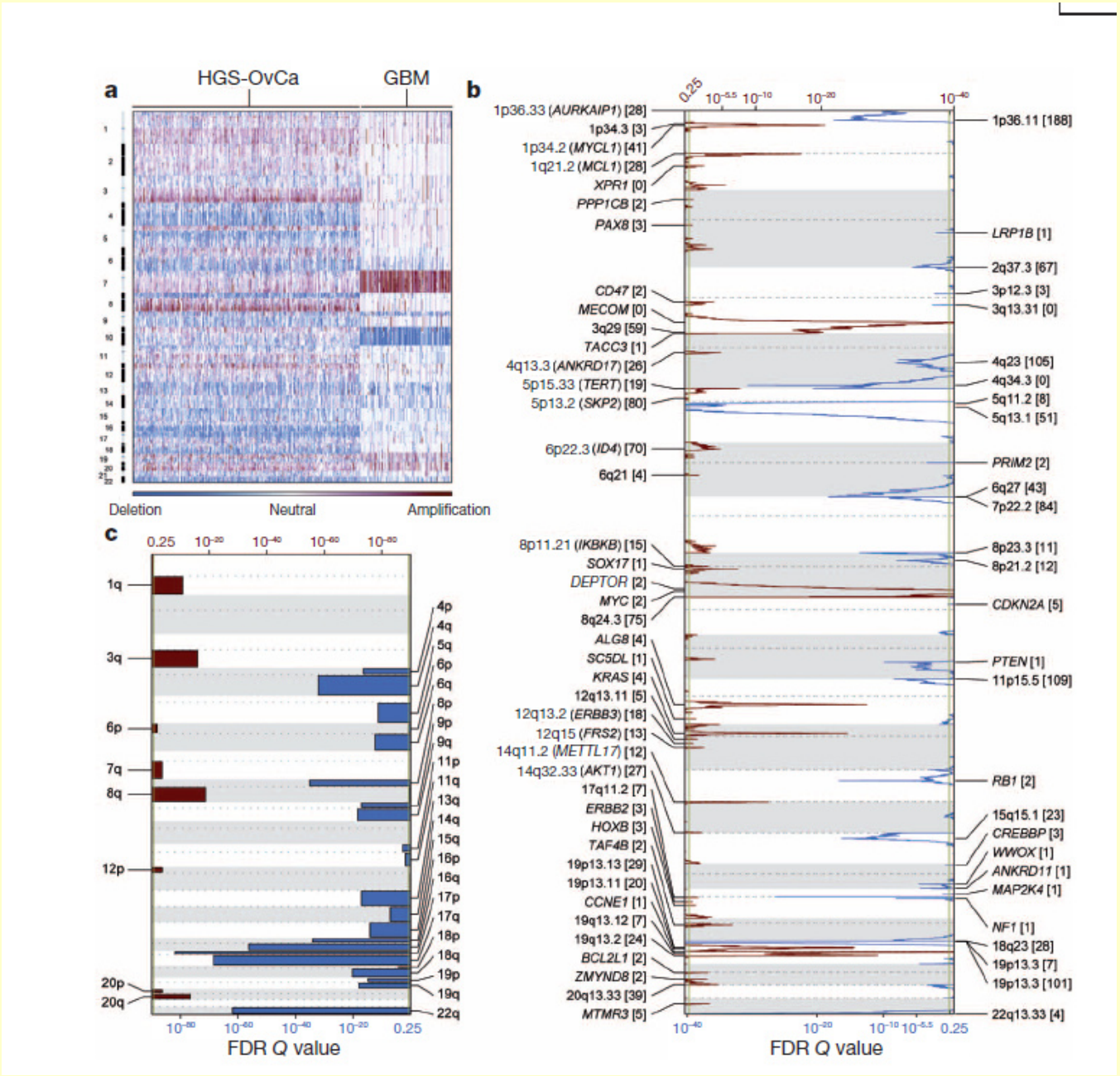

Genome copy number abnormalities.

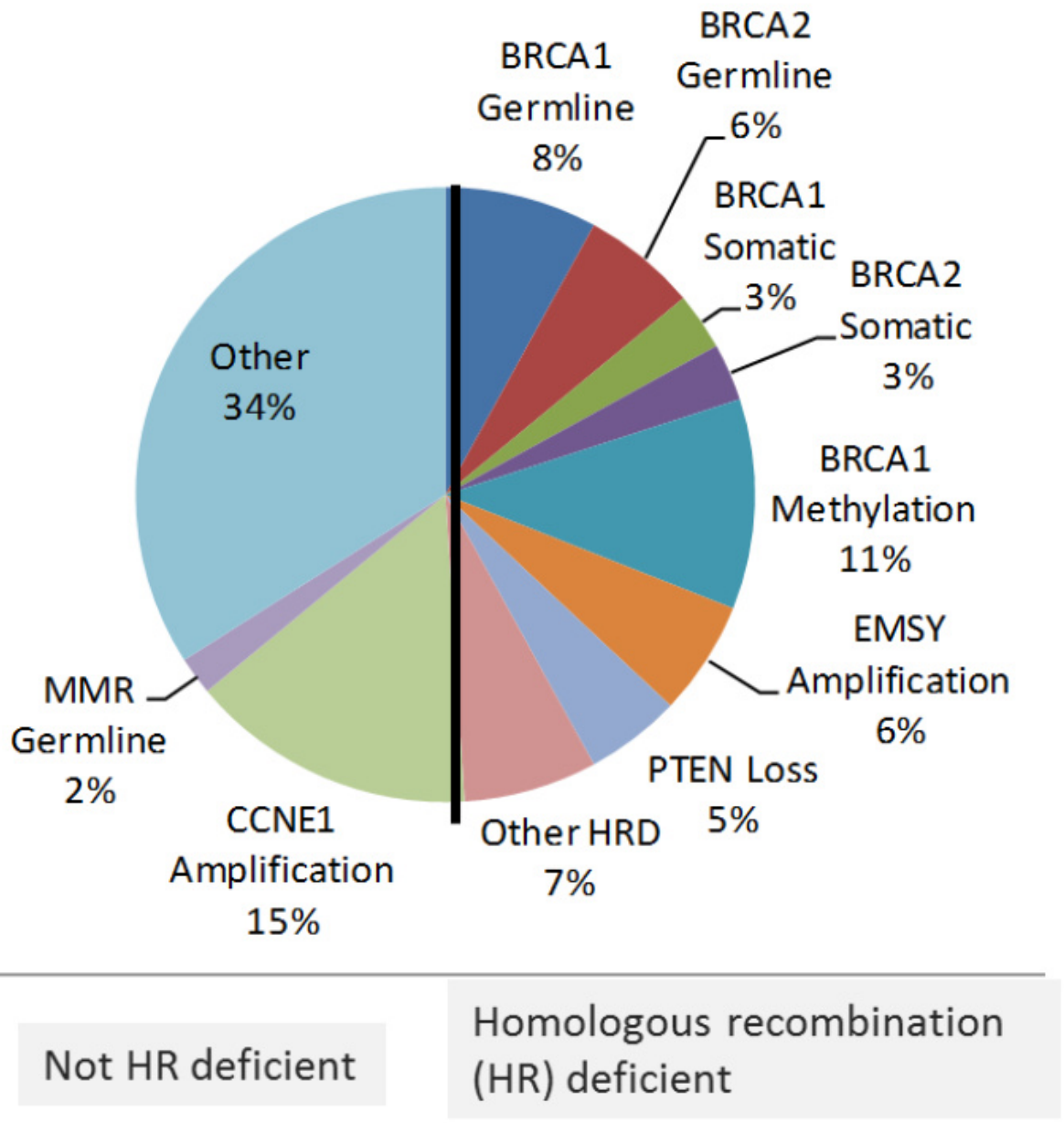
BRCA1
Germline
8%
BRCA2
Germline
6%
BRCA1
Somatic
3%
BRCA2
Somatic
3%
BRCA1
Methylation
11%
EMSY
Amplification
6%
PTEN Loss
5%
Other HRD
7%
CCNE1
Amplification
15%
MMR
Germline
2%
Other
34%
Not HR deficient
Homologous recombination
(HR) deficient

Double Strand Break Repair

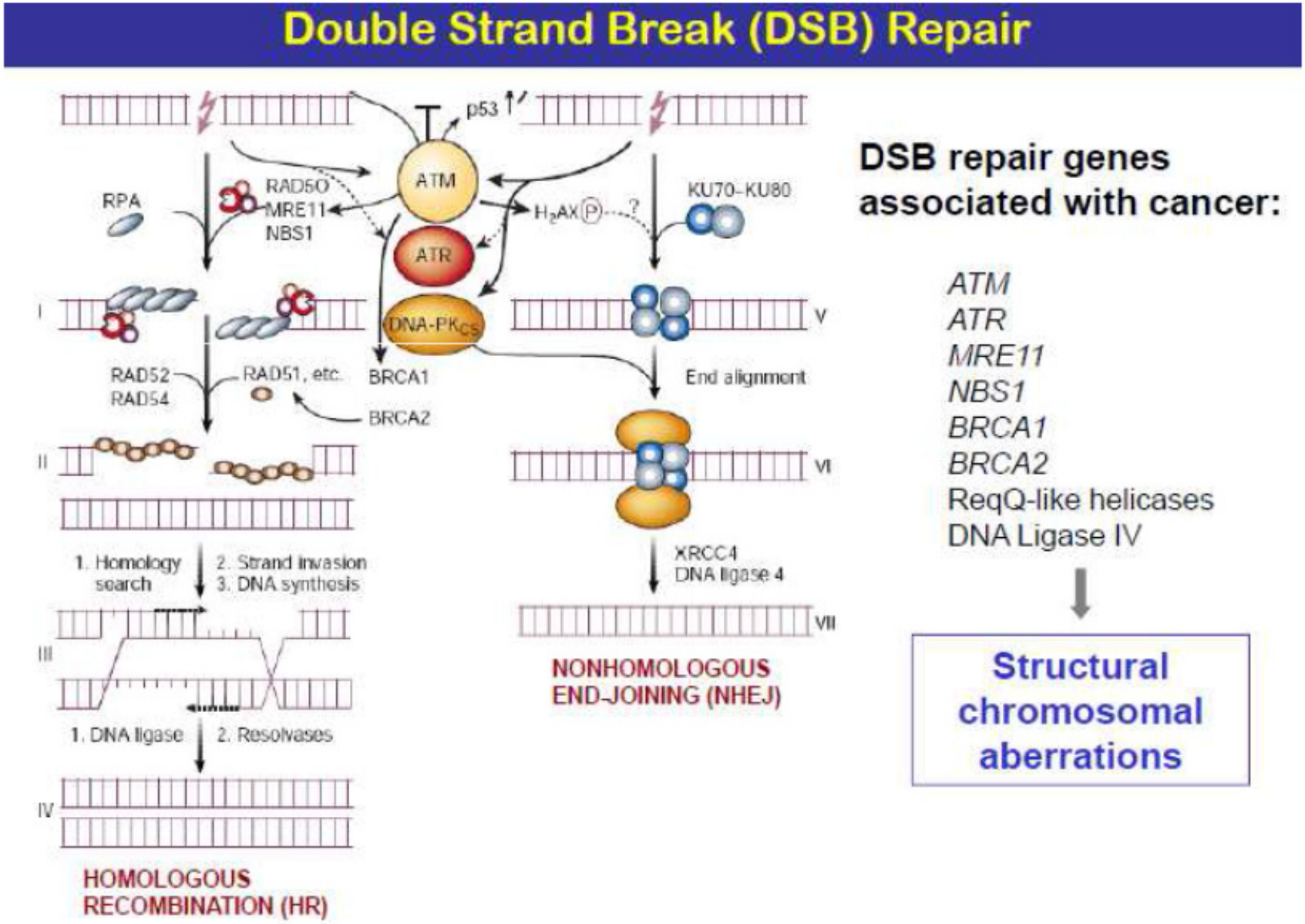

Molecular Mechanisms of Platinum resistance in ovarian cancer

- Balance between DNA damage and DNA repair
  - Nucleotide Excision repair (ERCC1)
  - DNA mismatch repair
  - Homologous recombination

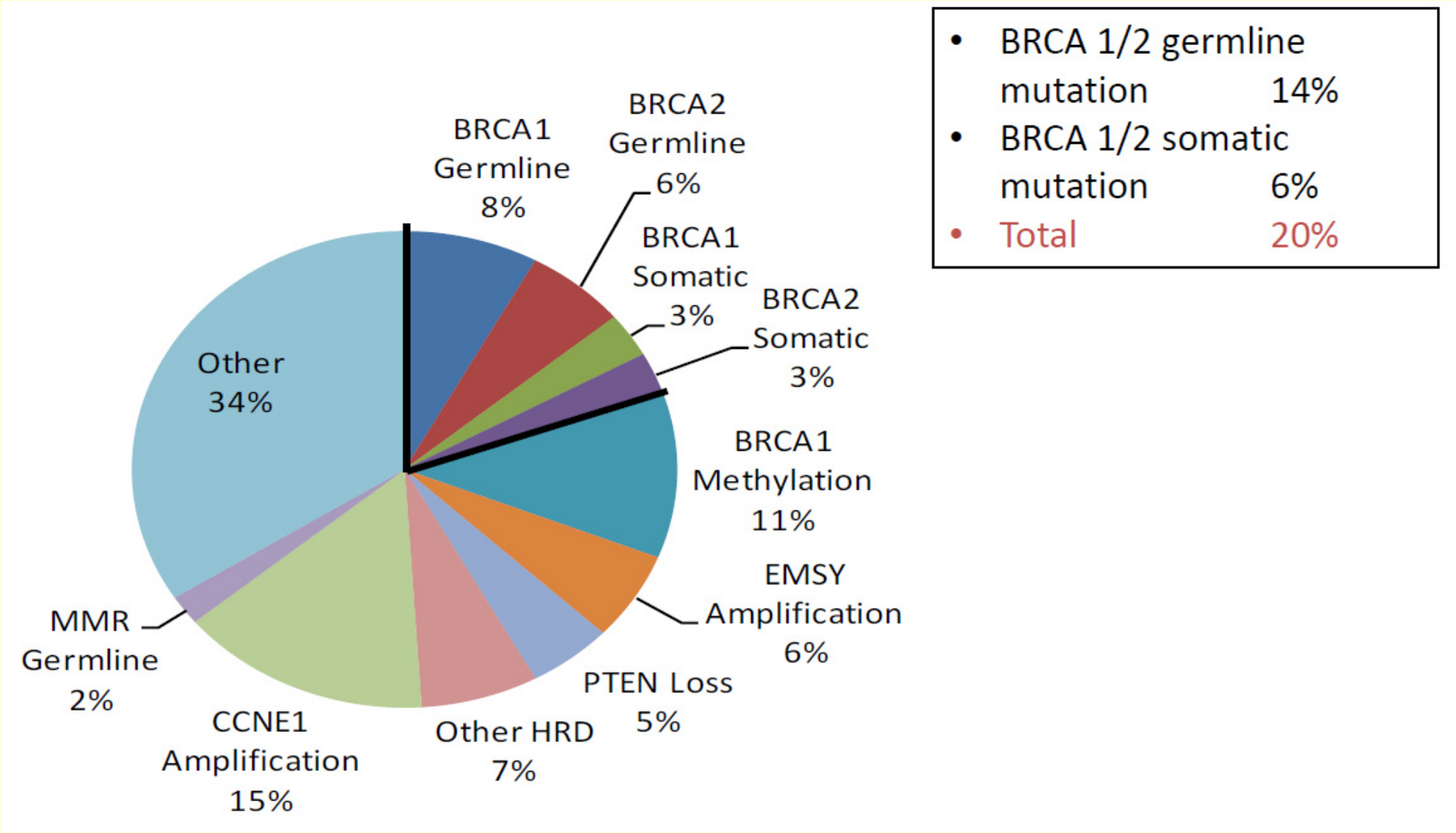
BRCA1 Germline 8%
BRCA2 Germline 6%
BRCA1 Somatic 3%
BRCA2 Somatic 3%
BRCA1 Methylation 11%
EMSY Amplification 6%
PTEN Loss 5%
Other HRD 7%
CCNE1 Amplification 15%
MMR Germline 2%
Other 34%
• BRCA 1/2 germline mutation 14%
• BRCA 1/2 somatic mutation 6%
• Total 20%

High grade ovarian serous carcinoma

- **Familial (BRCA-1; BRCA-2)**
- **Sporadic**

Germ-line dominant DNA repair gene mutation

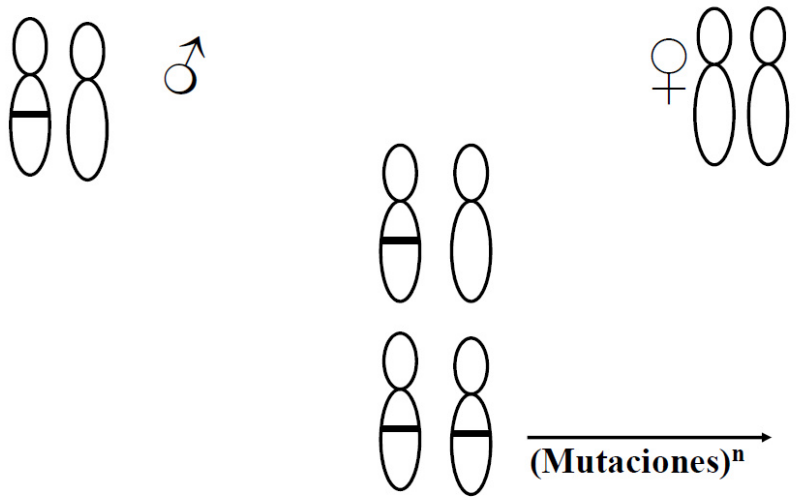

Somatic DNA repair gene mutation

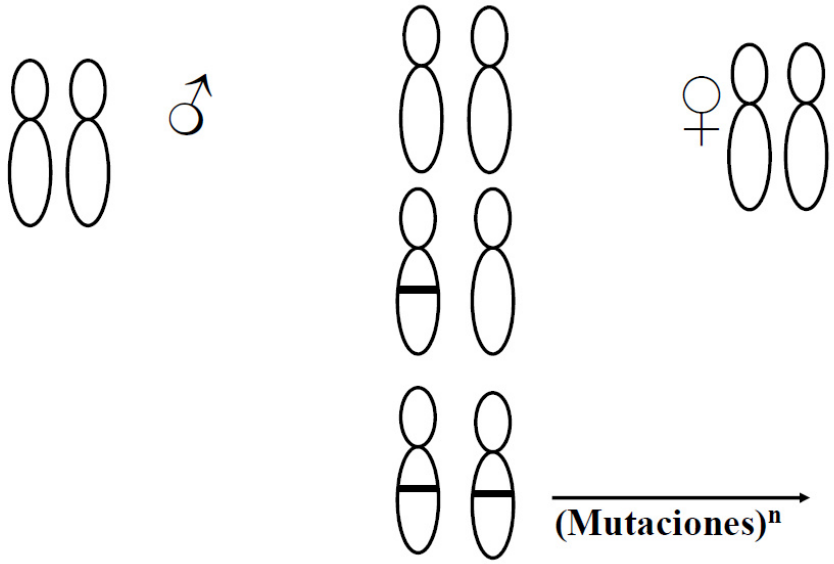


Hospital de la Santa Creu i Sant Pau - PATOLOGIA
98 B 3573

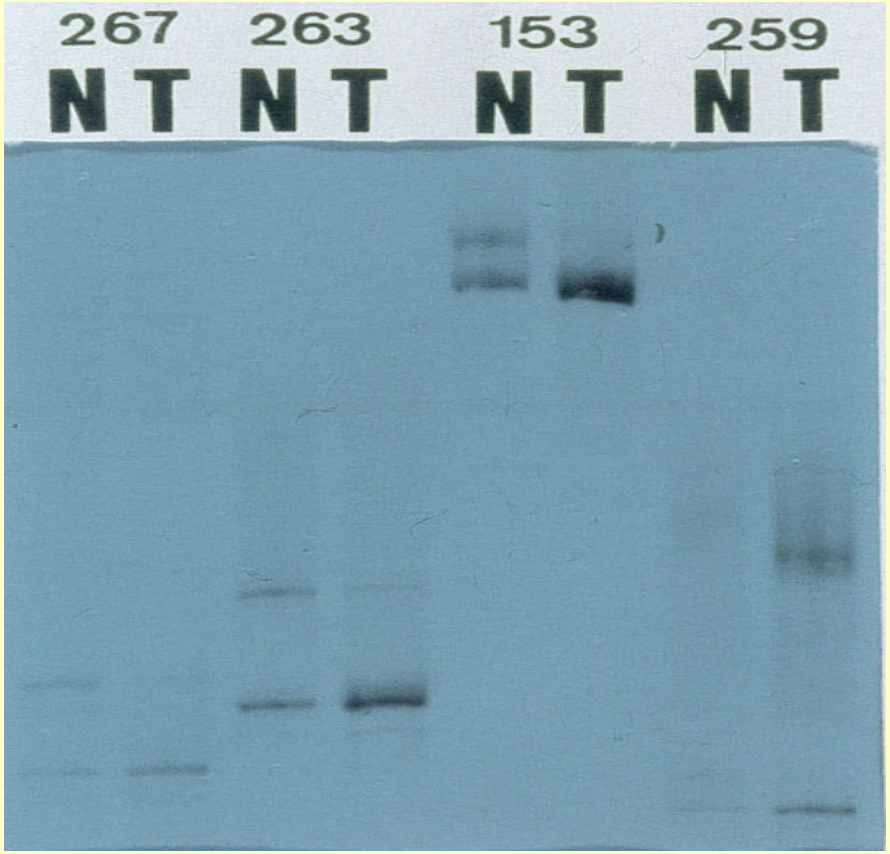
267
263
153
259
N T N T N T N T

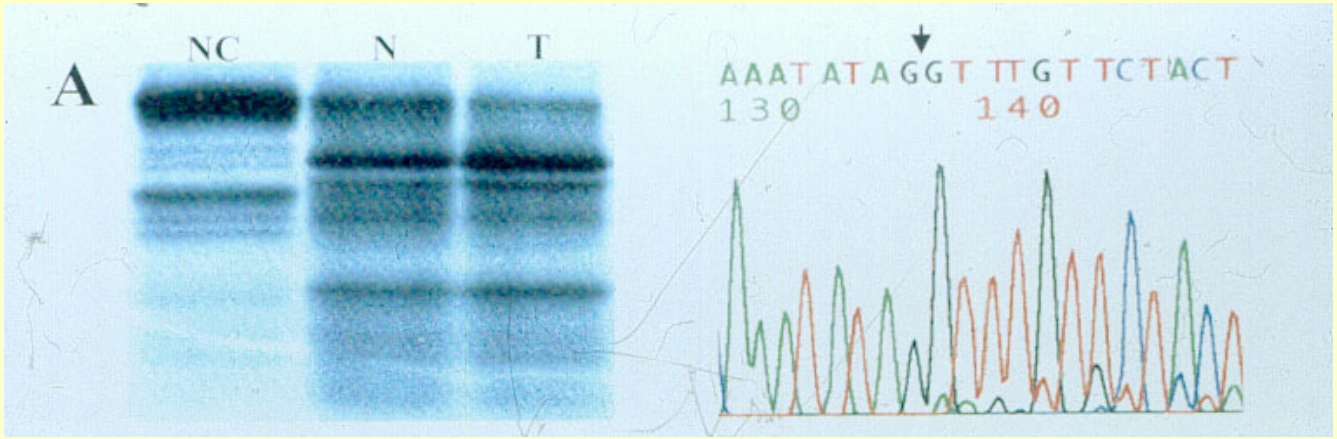
A
NC
N
T
AAATATAGGTTTGTTCTACT
130
140

Long-Term Ovarian Cancer Survival Associated With Mutation in BRCA1 or BRCA2

John R. McLaughlin, Barry Rosen, Joel Moody, Tuya Pal, Isabel Fan, Patricia A. Shaw, Harvey A. Risch, Thomas A. Sellers, Ping Sun, Steven A. Narod

J Natl Cancer Inst 2013;105:141–148

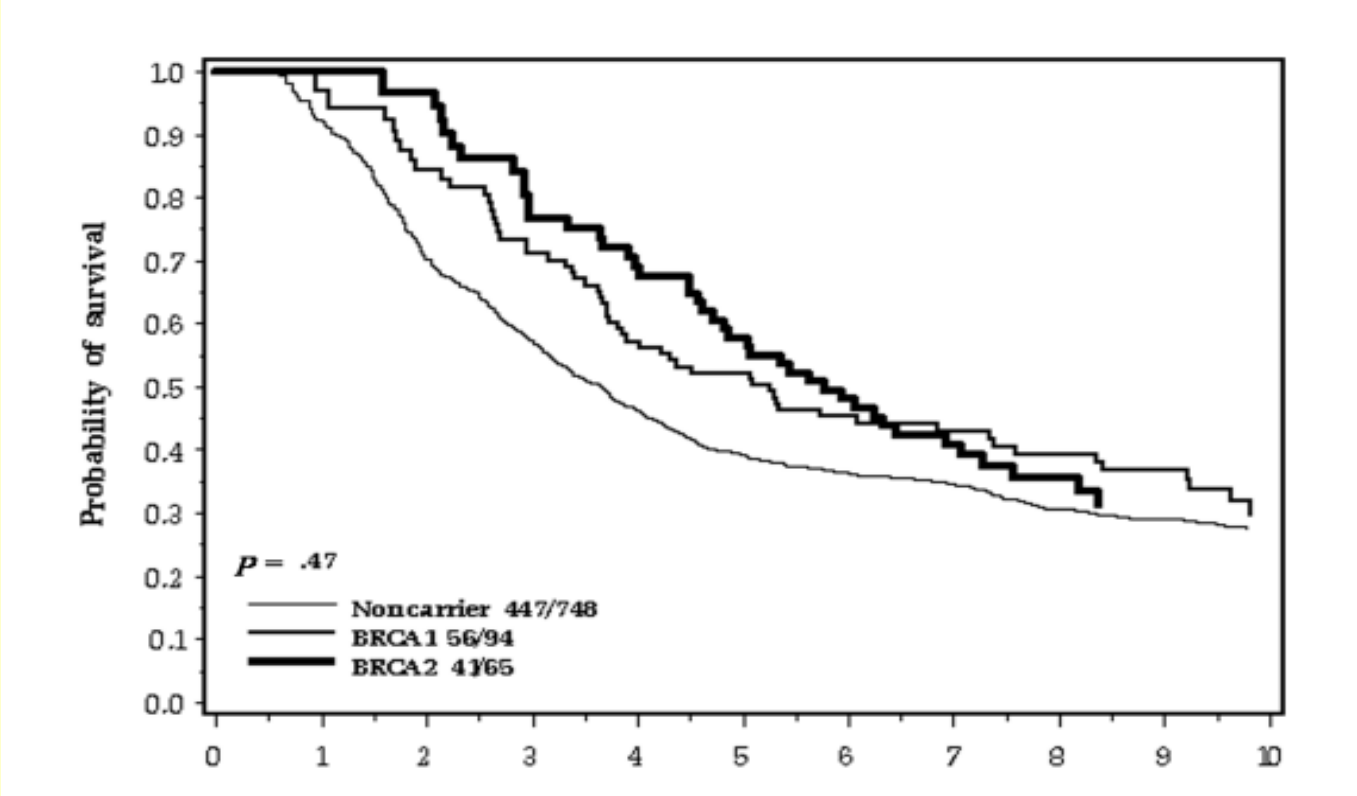

Chemosensitivity and outcome of *BRCA1*- and *BRCA2*-associated ovarian cancer patients after first-line chemotherapy compared with sporadic ovarian cancer patients

P. M. L. H. Vencken[1], M. Kriege[2], D. Hoogwerf[2], S. Beugelink[2], M. E. L. van der Burg[3], M. J. Hooning[2], E. M. Berns[3], A. Jager[2], M. Collée[4], C. W. Burger[1] & C. Seynaeve[2*]

Annals of Oncology 22: 1346–1352, 2011

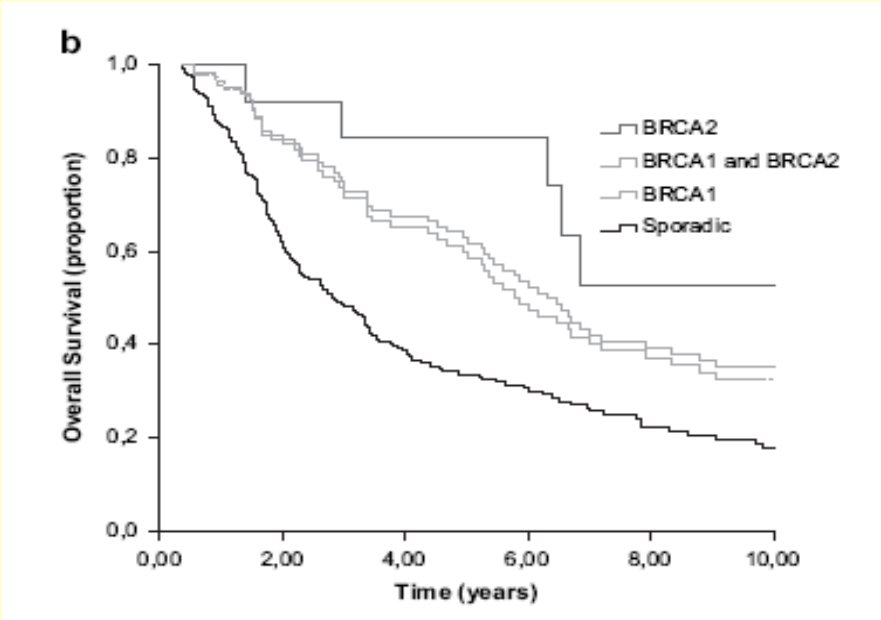

OPEN ACCESS Freely available online

PLOS | ONE

The Role of BRCA Status on the Prognosis of Patients with Epithelial Ovarian Cancer: A Systematic Review of the Literature with a Meta-Analysis

Chaoyang Sun, Na Li, Dong Ding, Danhui Weng, Li Meng, Gang Chen*, Ding Ma*

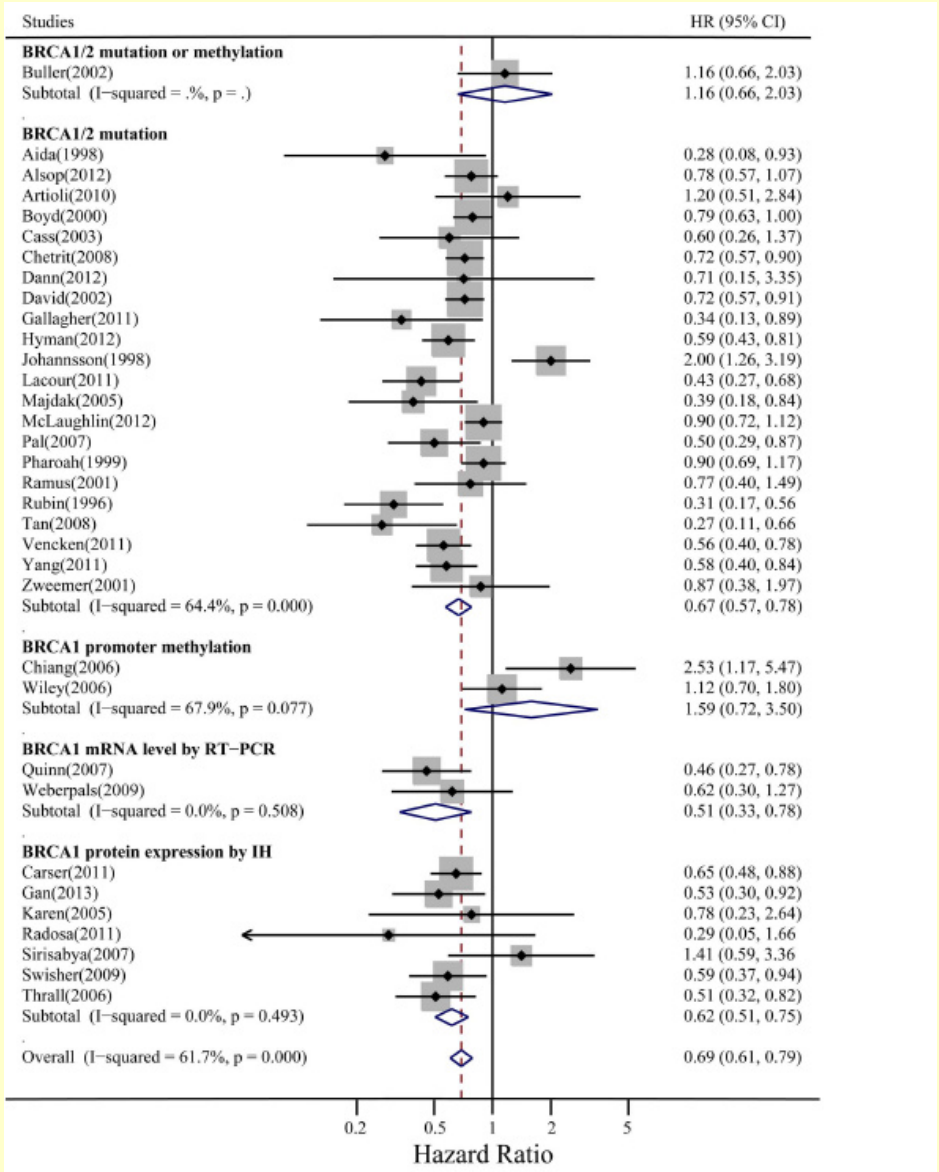

Figure 2. Summary hazard ratios (HRs) and 95% confidence intervals (CIs) of epithelial ovarian cancer OS for BRCA dysfunction status. Horizontal lines represent 95% CIs; diamonds represent summary estimates with corresponding 95% CIs. Test for heterogeneity: $P = .000$, $I^2 = 61.7\%$. A random-effects model was used for analysis.

doi:10.1371/journal.pone.0095285.g002

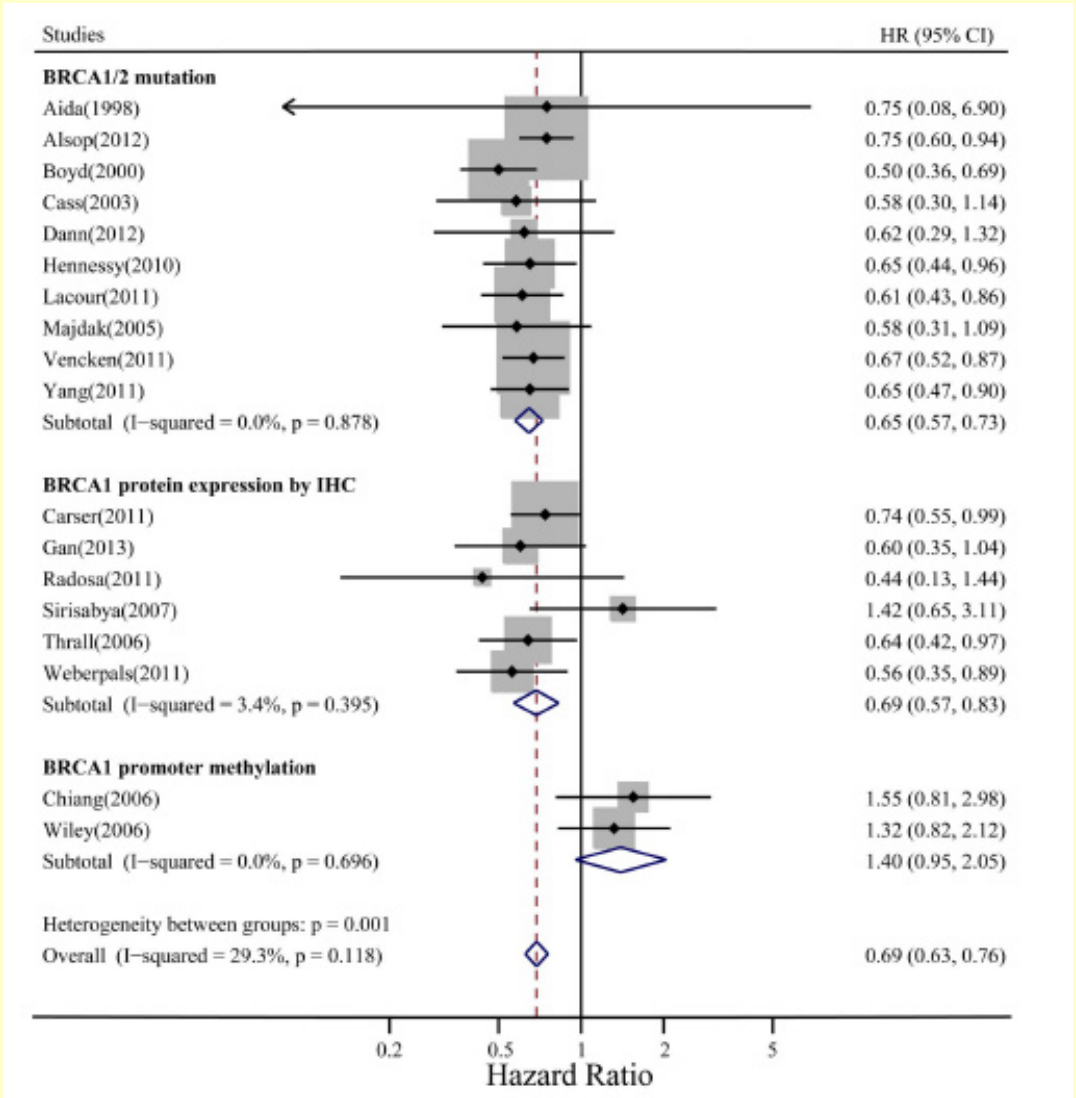

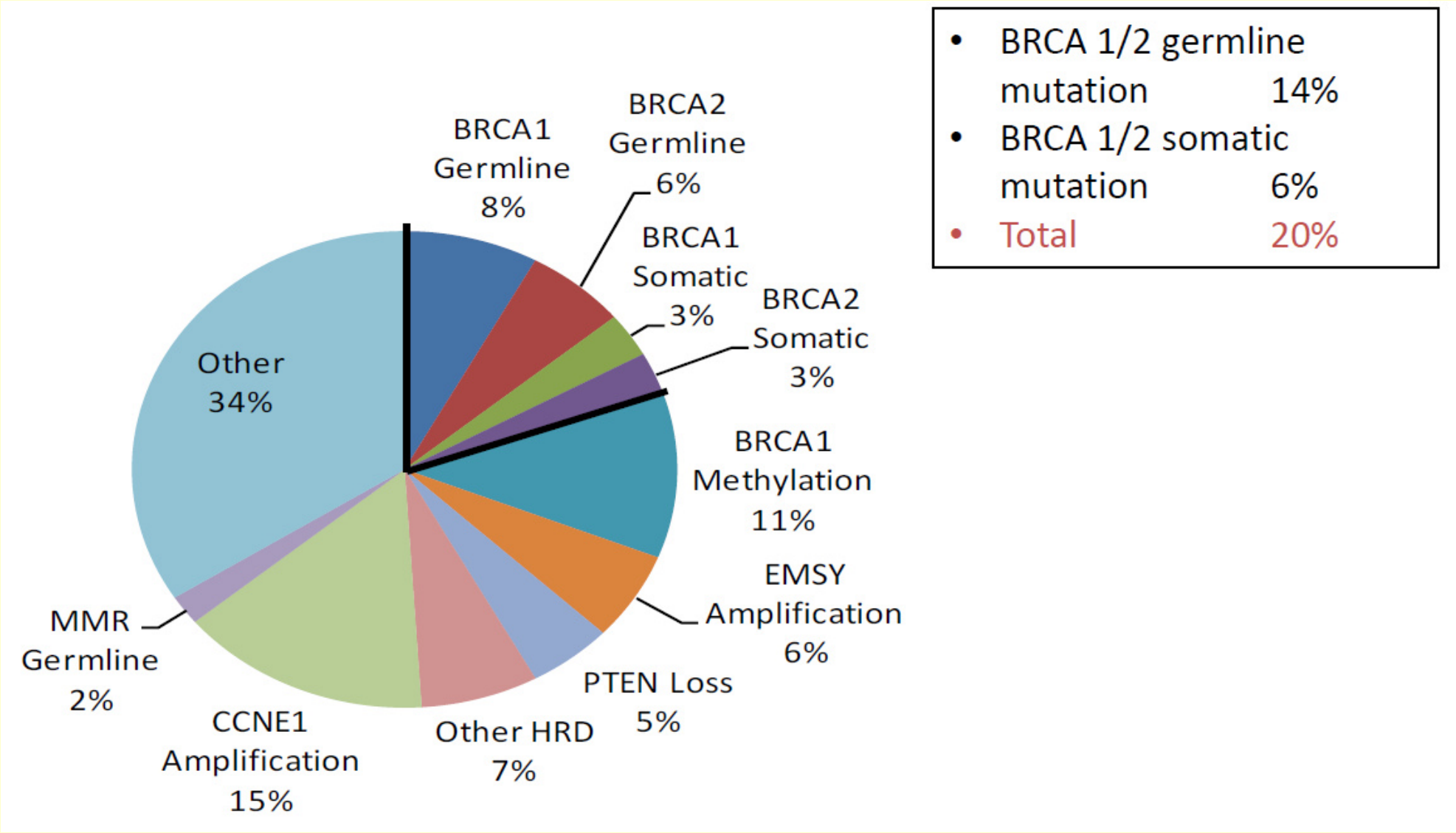
BRCA1 Germline 8%
BRCA2 Germline 6%
BRCA1 Somatic 3%
BRCA2 Somatic 3%
BRCA1 Methylation 11%
EMSY Amplification 6%
PTEN Loss 5%
Other HRD 7%
CCNE1 Amplification 15%
MMR Germline 2%
Other 34%
• BRCA 1/2 germline mutation 14%
• BRCA 1/2 somatic mutation 6%
• Total 20%

Promoter Hypermethylation and BRCA1 Inactivation in Sporadic Breast and Ovarian Tumors

Manel Esteller, Jose Maria Silva, Gemma Dominguez, Felix Bonilla, Xavier Matias-Guiu, Enrique Lerma, Elena Bussaglia, Jaime Prat, I. Clara Harkes, Elizabeth A. Repasky, Edward Gabrielson, Mieke Schutte, Stephen B. Baylin, James G. Herman

Journal of the National Cancer Institute, Vol. 92, No. 7, April 5, 2000

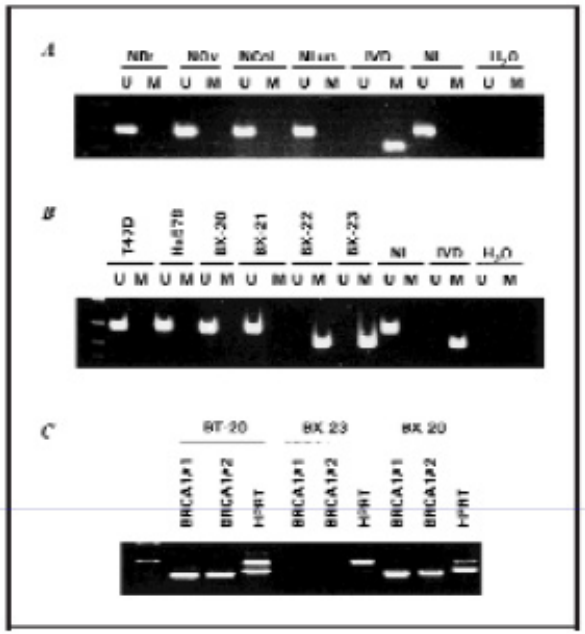

Fig. 1. Panel A: Analysis by methylation-specific polymerase chain reaction (MSP PCR) of the promoter region of BRCA1 in normal tissues: breast (NBr), ovary (NOv), colon (NCol), and lung (NLun). **Panel B:** MSP of BRCA1 in breast cancer cell lines (T47D and Hs578) and xenografts (BX-20, BX-21, BX-22, and BX-23). The presence of a visible PCR product in those lanes marked U indicates the presence of unmethylated genes of BRCA1; the presence of a product in those lanes marked M indicates the presence of methylated genes. *In vitro* methylated DNA (IVD) was used as a positive control for methylated BRCA1 alleles. DNA from normal lymphocytes (NL) was used as a negative control for methylated BRCA1 alleles. An MSP study demonstrates complete BRCA1 methylation in two xenografts (BX-22 and BX-23). **Panel C:** The pattern of expression determined by reverse transcription–PCR of the BRCA1 transcript in breast cancer xenografts and cell lines by use of two sets of primers. HPRT (hypoxanthine phosphoribosyltransferase) expression demonstrates relatively equal amounts of initial messenger RNA. A xenograft fully methylated at BRCA1 (BX-23) demonstrates diminished BRCA1 expression, while an unmethylated cell line (BT-20) and an unmethylated xenograft (BX-20) highly express the BRCA1 transcript.

tumors, there was no association of BRCA1 methylation with the presence of lymph node metastasis ($P = .72$), estrogen receptor status ($P = .47$), or progesterone receptor status ($P = .44$). The presence of BRCA1 methylation was not related to the abnormal methylation of GSTP1 ($P = 1.00$), which had been previously demonstrated in a subset of these tumors *(15)*.

Two particular histologic subtypes of breast carcinoma, medullary and mucinous carcinomas, appear on the basis of earlier studies *(31–33)* to be overrepresented in BRCA1-inherited breast tumors. Among the unselected sporadic breast tumors described above, we found that, while most (nine of 11) of the tumors with methylation were of ductal origin, the other two methylated tumors consisted of

BRCA1 promoter methylation predicts adverse ovarian cancer prognosis ☆

Jing Wang Chiang, Beth Y. Karlan *, Ilana Cass, Rae Lynn Baldwin

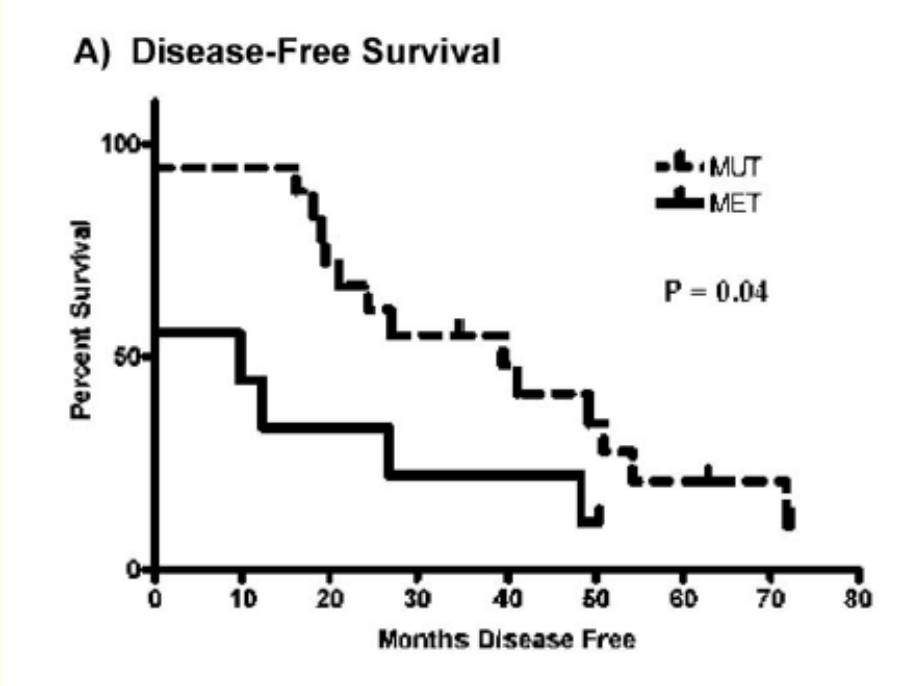

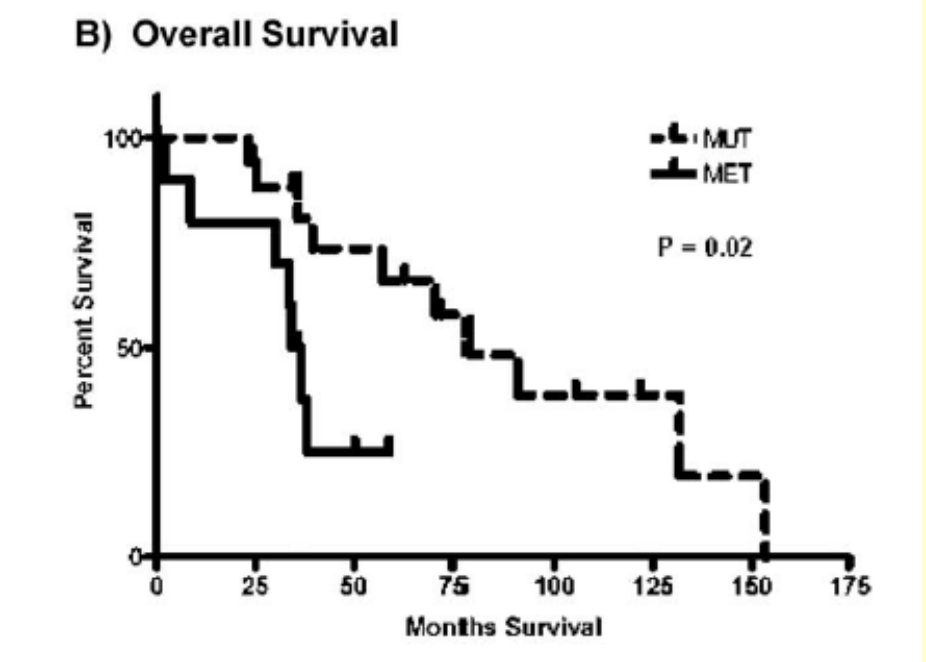

Secondary *BRCA1* Mutations in *BRCA1*-Mutated Ovarian Carcinomas with Platinum Resistance

Elizabeth M. Swisher,[1,2] Wataru Sakai,[3,4] Beth Y. Karlan,[5] Kaitlyn Wurz,[1,2] Nicole Urban,[4] and Toshiyasu Taniguchi[3,4]

Cancer Res 2008;68(8):2581–6

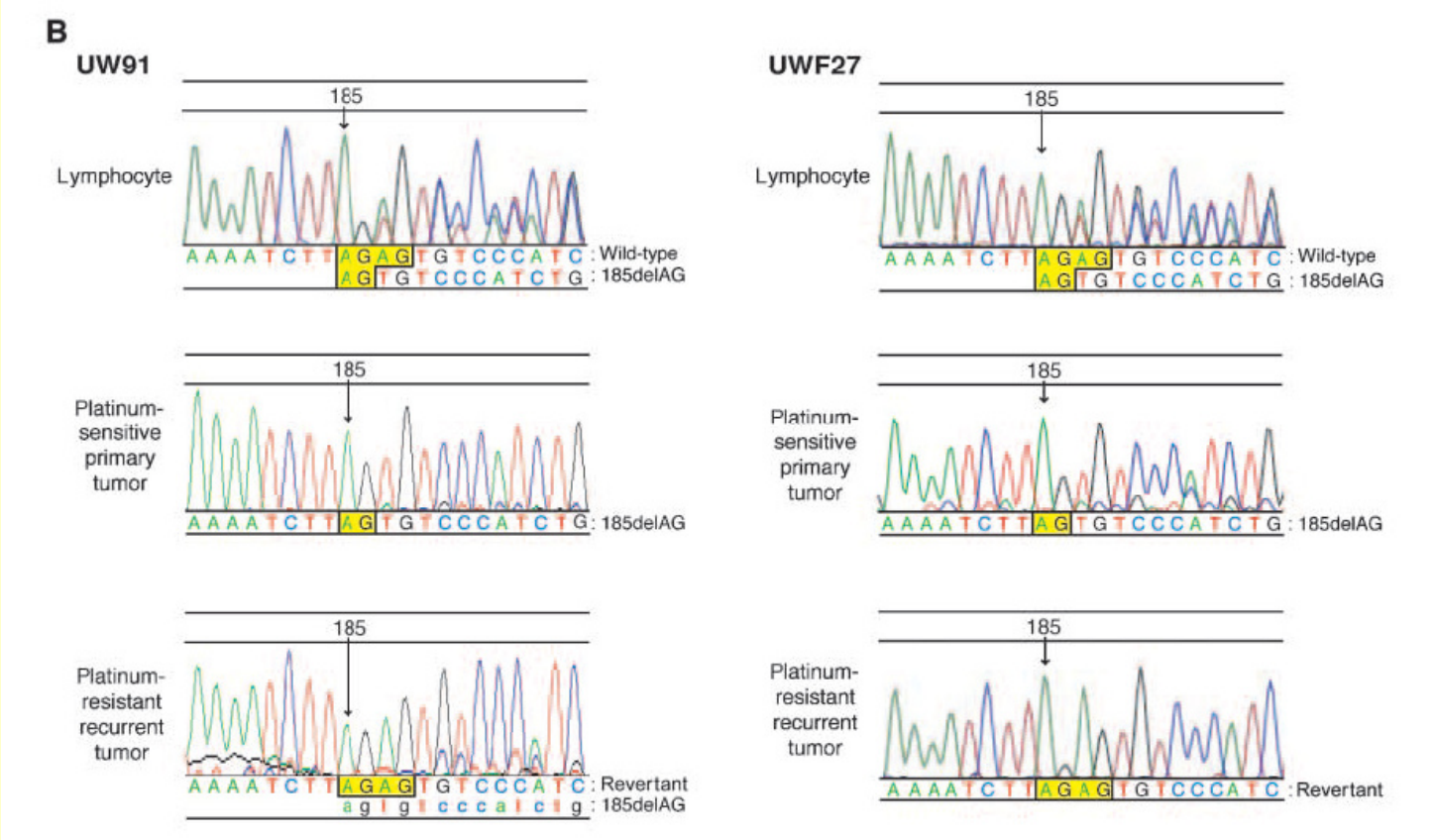

Morphologic patterns associated with *BRCA1* and *BRCA2* genotype in ovarian carcinoma

Robert A Soslow[1], Guangming Han[2], Kay J Park[1], Karuna Garg[1], Narciso Olvera[1], David R Spriggs[3], Noah D Kauff[3,4] and Douglas A Levine[5]

Modern Pathology (2012) **25**, 625–636;

Table 1 Summary of morphologic characteristics of the training set organized by genotype

	Tumor-infiltrating lymphocytes per high-power field, median (range)	*Mitotic index, median (range)*	*Solid, pseudoendometrioid, and transitional cell carcinoma-like (SET) features*	*Necrosis*	*Nuclear pleomorphism*	*Fallopian tube involvement*
BRCA1 germline ($n=4$)	31 (10–69)	52 (40–71)	2/4	3/4	2/4	1/1
BRCA1 somatic ($n=6$)	29 (5–62)	64 (19–105)	4/6	3/6	3/6	5/5
BRCA1 methylated ($n=13$)	52 (13–88)	60 (17–102)	10/13	7/13	7/13	4/5
BRCA2 germline ($n=4$)	19 (5–43)	62 (8–126)	4/4	4/4	4/4	3/3
BRCA2 somatic ($n=4$)	16 (12–60)	35 (12–60)	2/4	0/4	3/4	2/2
BRCA unassociated ($n=12$)	29 (2–140)	37 (15–94)	2/12	2/12	3/12	6/10
P-value[a]	0.034[b]	0.012[b]	0.0045	0.034	0.16	0.65
Overall ($n=43$)	36 (mean) 29 (median)	53 (mean) 51 (median)	24/43	19/43	21/43	21/26

Available online at www.sciencedirect.com

SCIENCE DIRECT®

Gynecologic Oncology 97 (2005) 195–199

Gynecologic Oncology

www.elsevier.com/locate/ygyno

Survival benefit for patients with advanced-stage transitional cell carcinomas vs. other subtypes of ovarian carcinoma after chemotherapy with platinum and paclitaxel

Friedrich Kommoss[a,*], Stefan Kommoss[a], Dietmar Schmidt[a], Marcus J. Trunk[b], Jacobus Pfisterer[c], Andreas du Bois[d]
for the Arbeitsgemeinschaft Gynaekologische Onkologie Studiengruppe Ovarialkarzinom (AGO-OVAR)

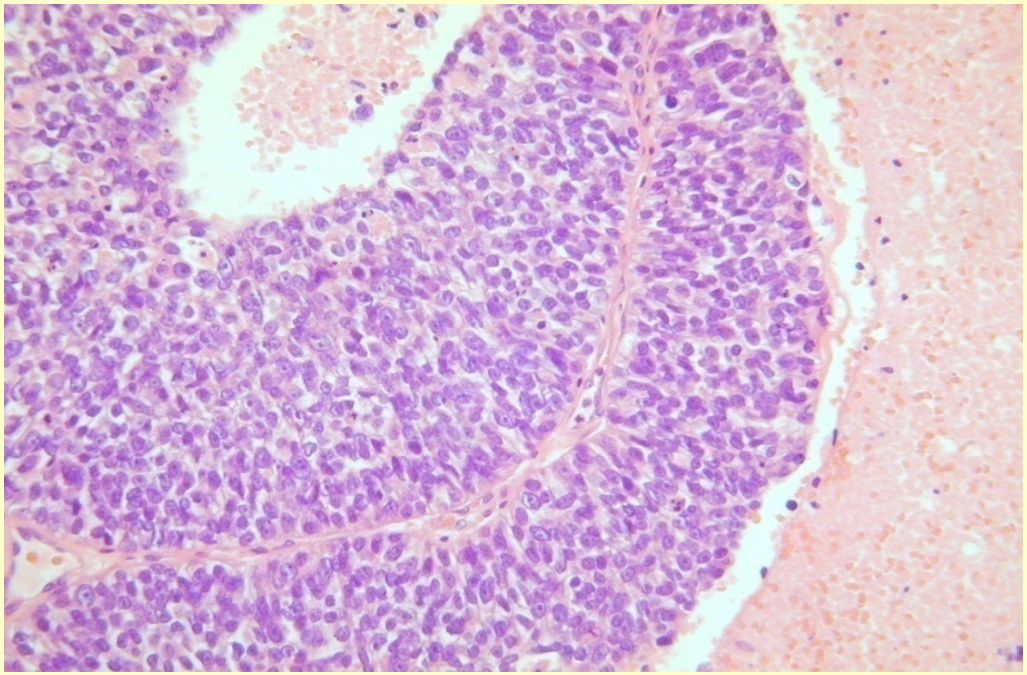

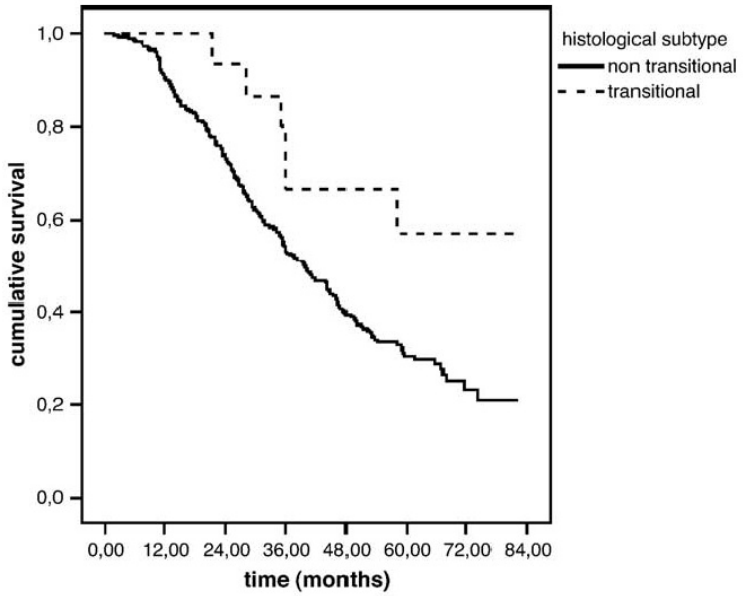

Fig. 3. Survival of patients with TCCs as compared to non-TCCs of the ovary.

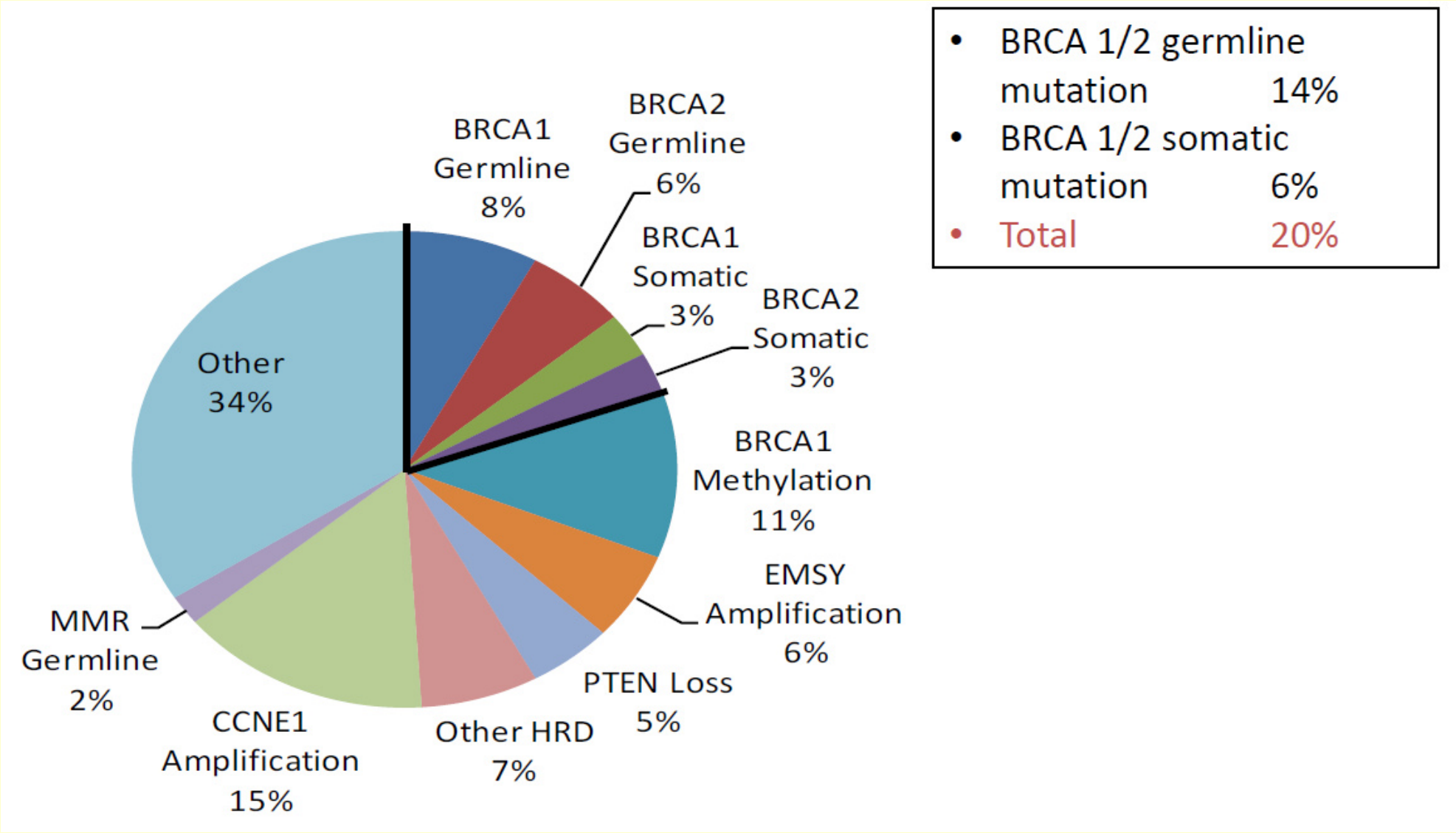
BRCA1 Germline 8%
BRCA2 Germline 6%
BRCA1 Somatic 3%
BRCA2 Somatic 3%
BRCA1 Methylation 11%
EMSY Amplification 6%
PTEN Loss 5%
Other HRD 7%
CCNE1 Amplification 15%
MMR Germline 2%
Other 34%
• BRCA 1/2 germline mutation 14%
• BRCA 1/2 somatic mutation 6%
• Total 20%

Biomarkers of Homologous recombination deficiency in ovarian cancer

- Germ-line and somatic mutation analysis of BRCA-1 and BRCA-2

- Quantitative assessment of chromosomal aberrations:
  - Whole genome tumor Loss of Heterozygosity
  - Telomeric allelic imbalance score
  - Large-scale state transitions score

PARP (Poly ADP ribose polymerase) inhibitors in BRCA mutated HGSC

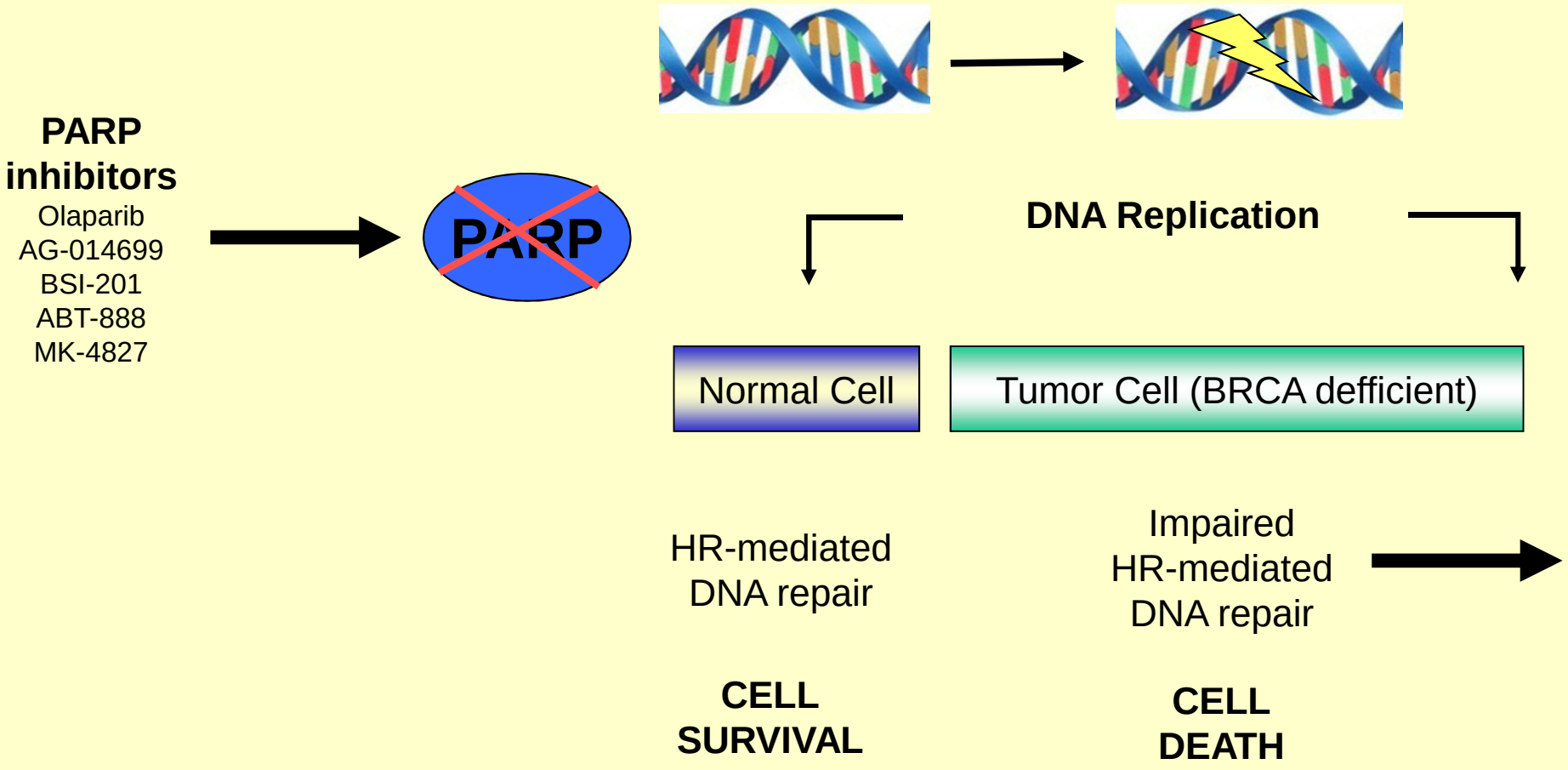

OVARIAN CANCER

High grade serous Ca	**70%**
Low grade serous Ca	**5%**
Endometrioid Ca	**10%**
Clear Cell Ca	**10%**
Mucinous Ca	**3%**

Sero-Mucinous, Brenner, other tumors

Solid mass in left pelvis (15x12x11 cm).

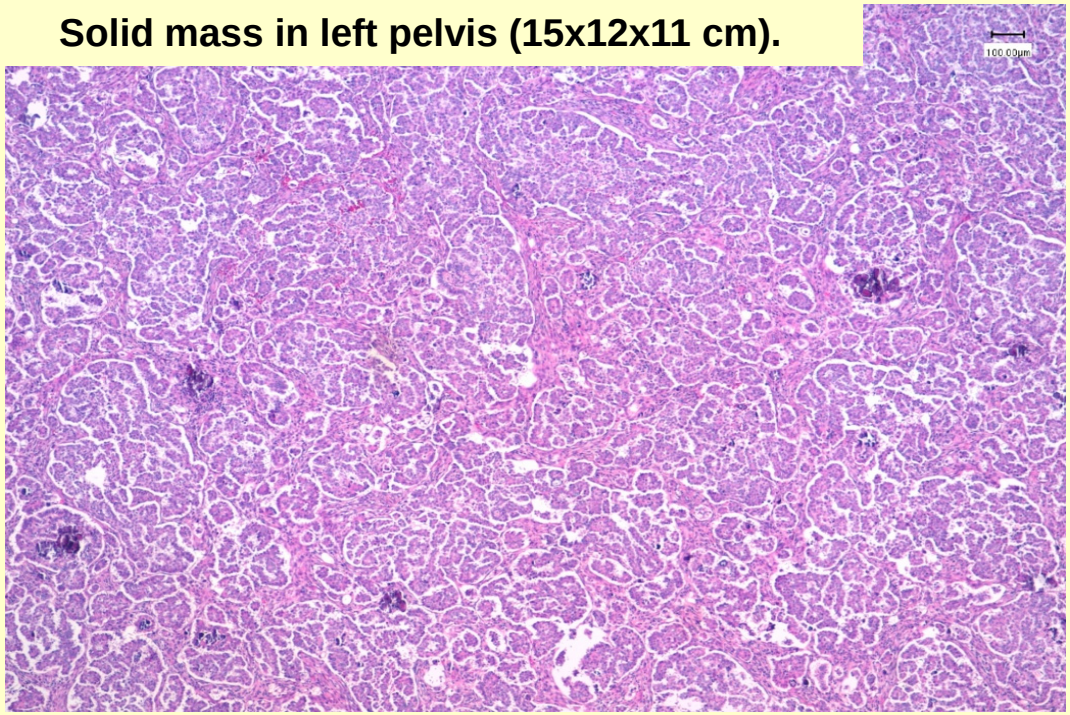

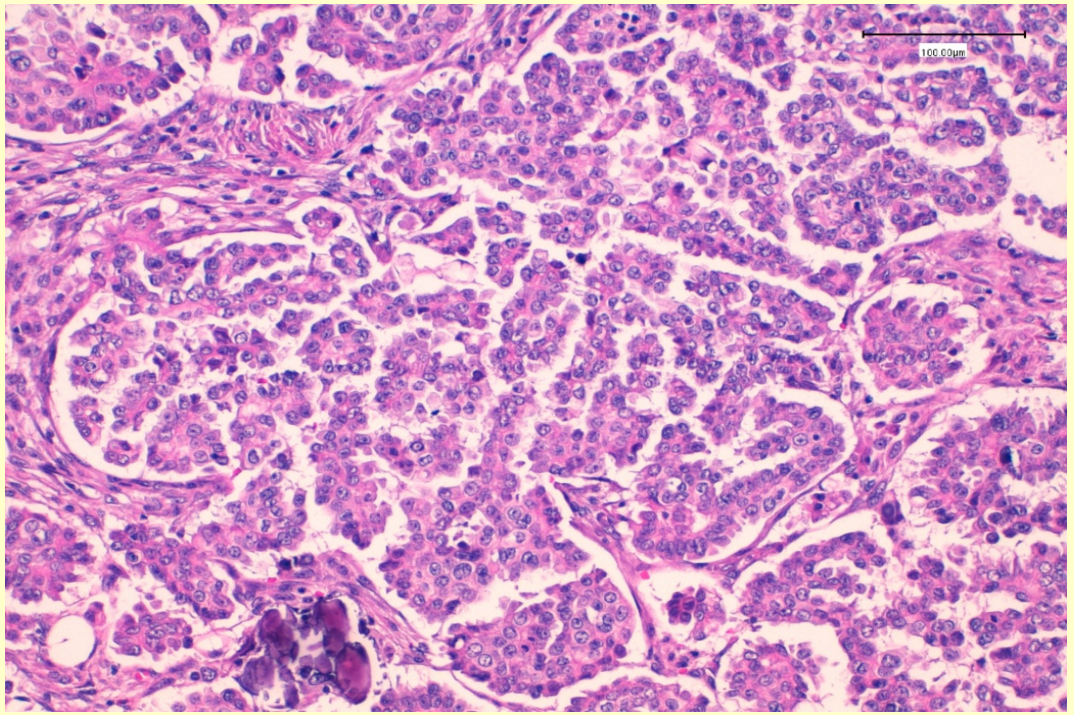

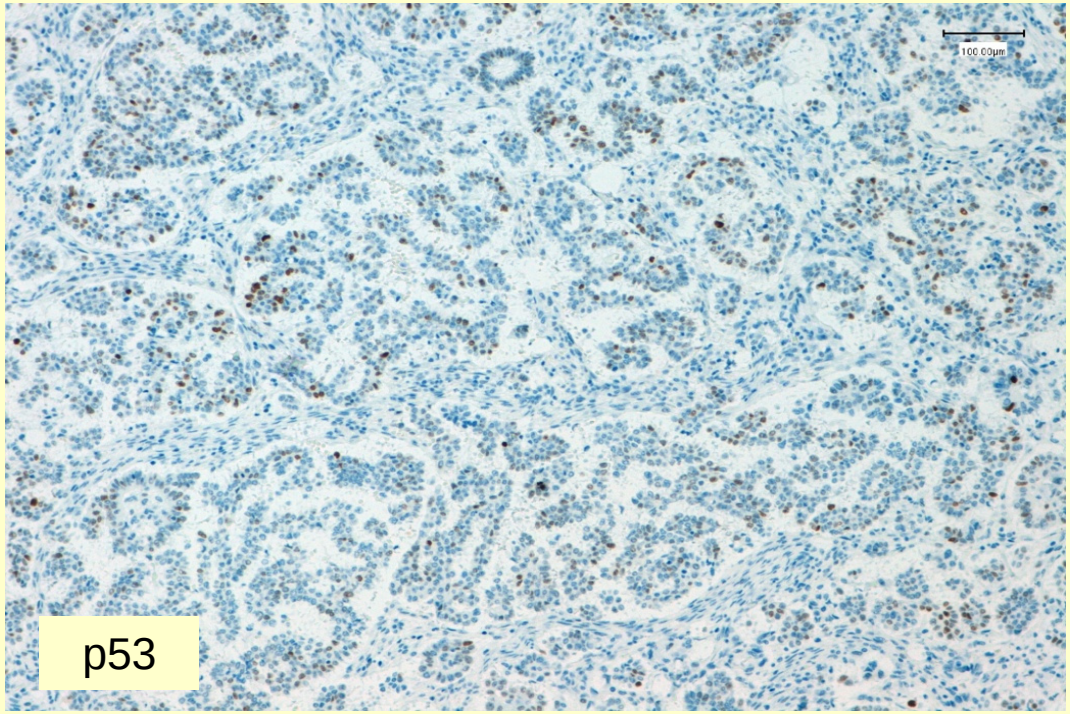

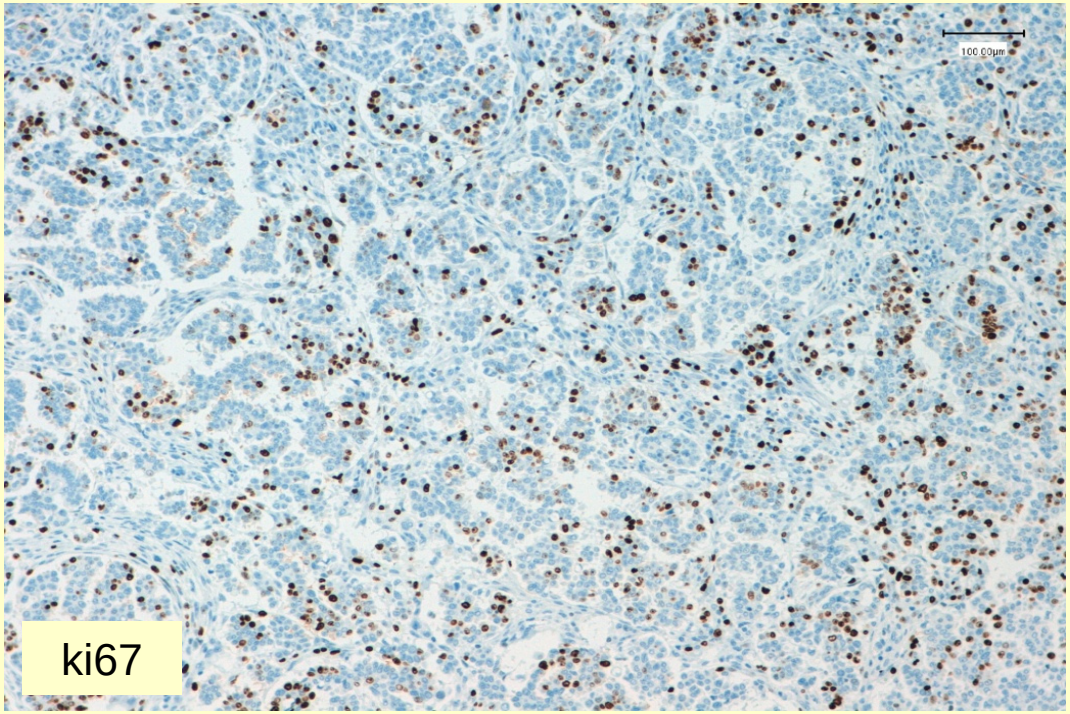

Mutational Analysis

Tumor Subtype	*BRAF* Mutation	*KRAS* Mutation
Serous Borderline Tumor	20-40%	40%
Low-grade SC	5%	20-40%
High-grade SC	0%	0-14%

www.impactjournals.com/oncotarget/ Oncotarget, Vol. 6, No. 35

Molecular profiling of low grade serous ovarian tumours identifies novel candidate driver genes

Sally M. Hunter[1], Michael S. Anglesio[4], Georgina L. Ryland[1], Raghwa Sharma[5], Yoke-Eng Chiew[6,7], Simone M. Rowley[1], Maria A. Doyle[8], Jason Li[8], C. Blake Gilks[4,9], Phillip Moss[10,15], Prue E. Allan[10], Andrew N. Stephens[11,12,13], David G. Huntsman[4], Anna deFazio[6,7], David D. Bowtell[1,2,3], Australian Ovarian Cancer Study Group[1,14], Kylie L. Gorringe[1,2,3,*], Ian G. Campbell[1,2,3,*]

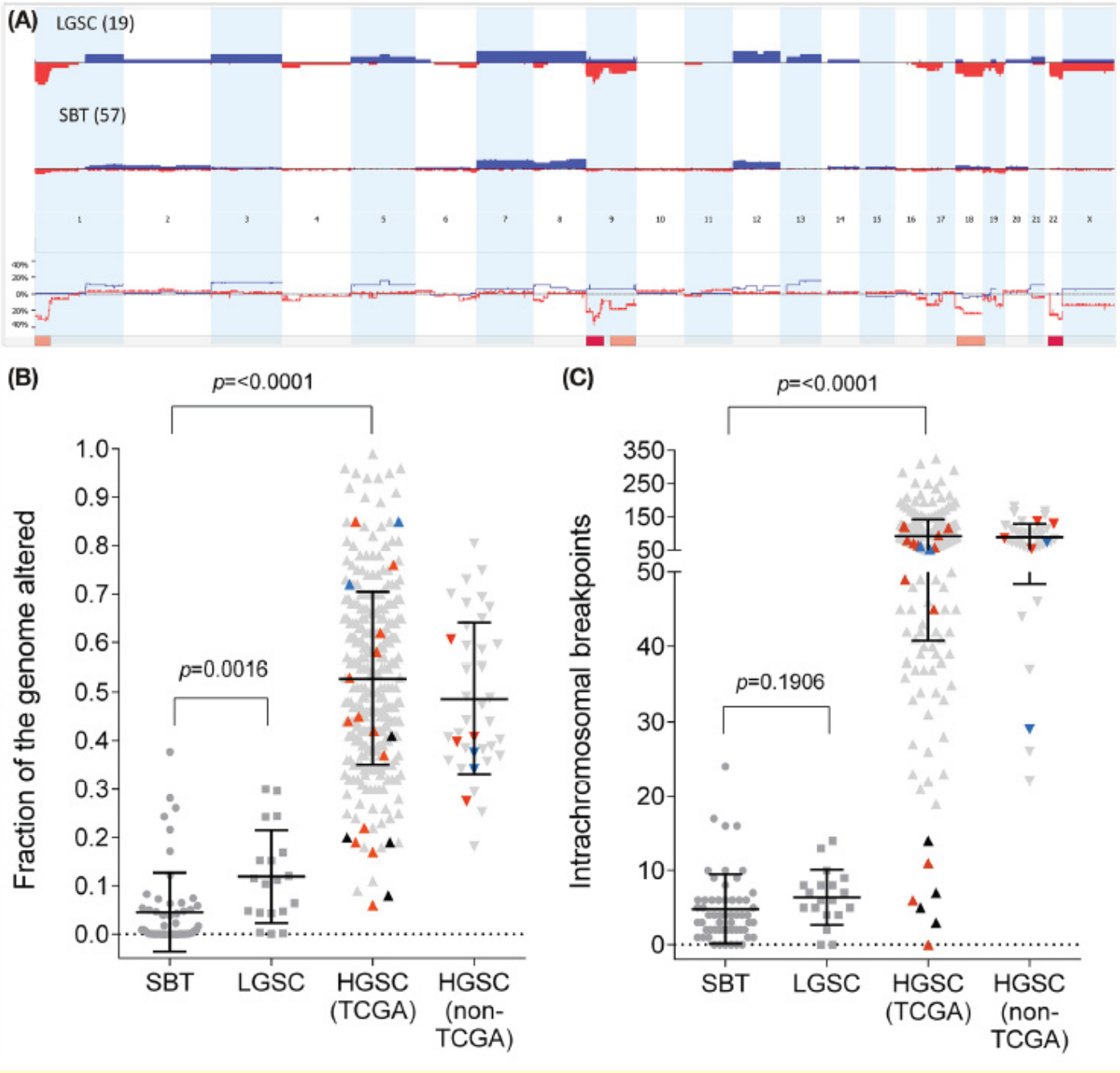
(A)
LGSC (19)
SBT (57)
(B)
p=<0.0001
p=0.0016
Fraction of the genome altered
SBT
LGSC
HGSC (TCGA)
HGSC (non-TCGA)
(C)
p=<0.0001
p=0.1906
Intrachromosomal breakpoints
SBT
LGSC
HGSC (TCGA)
HGSC (non-TCGA)

Mutation	SBT (*n* = 57)	LGSC (*n* = 19)
KRAS	21 (36.8%)	4 (21%)
BRAF (V600E)	22 (38.6%)	3 (16%)
BRAF (non-V600E)	2 (3.5%)	0
HRAS	1 (1.8%)	0
NRAS	**0**	**5 (26%)**
ERBB2 (exon 20)	3 (5.3%)	0
TP53	0	0
WT	10 (17.5%)	8 (42%)

Histopathology 2019, 74, 638–650. DOI: 10.1111/his.13796

Somatic genetic alterations in synchronous and metachronous low-grade serous tumours and high-grade carcinomas of the adnexa

Rajmohan Murali,[1] Pier Selenica,[1] David N Brown,[1] R Keira Cheetham,[2] Raghu Chandramohan,[1] Nidia L Claros,[3] Nancy Bouvier,[3] Donavan T Cheng,[4] Robert A Soslow,[1] Britta Weigelt[1] & W Glenn McCluggage[5]

Table 1. Clinicopathological features of low-grade serous tumours and high-grade serous carcinomas (HGSCs)

Case ID	Age at diagnosis (years)	FIGO stage at diagnosis	Low-grade tumour	High-grade carcinoma	Salient histopathological features	Outcome
Case 1	35	IIIC	LGSC	HGSC	Areas of LGSC and HGSC involving both ovaries, with HGSC involving the omentum, uterine serosa, and appendiceal serosa (Figure 1) Fallopian tubes unremarkable	Deceased 20 months after diagnosis
Case 2	52 (SBT, LGSC) 57 (HGSC)	IIIC	SBT, LGSC	HGSC*	Ovaries containing SBT showing microinvasion, and foci of solid proliferation amounting to LGSC; LGSC also involving the omentum Fallopian tubes unremarkable. Recurrent paravertebral and para-aortic tumour masses composed of HGSC (Figure 2)	Recurrence as HGSC 60 months after diagnosis of SBT + LGSC Deceased 67 months after diagnosis
Case 3	82	NK	SBT, LGSC	PDC	Ovary containing SBT, invasive LGSC, and areas of PDC; the last of these was diffusely cytokeratin-positive (Figure 3)	Lost to follow-up
Case 4	41	IIIC	SBT, LGSC	HGSC	Bilateral ovaries containing SBT and LGSC; in addition, areas of HGSC were present (Figure 4) Omentum with LGSC and HGSC Fallopian tubes unremarkable	Deceased 3.5 months after diagnosis
Case 5	67	IA	SBT	HGSC	SBT in both ovaries, with one ovary showing areas of intracystic non-invasive HGSC immediately adjacent to areas of SBT (Figure 5) Fallopian tubes unremarkable	Alive and well at 30 months after diagnosis

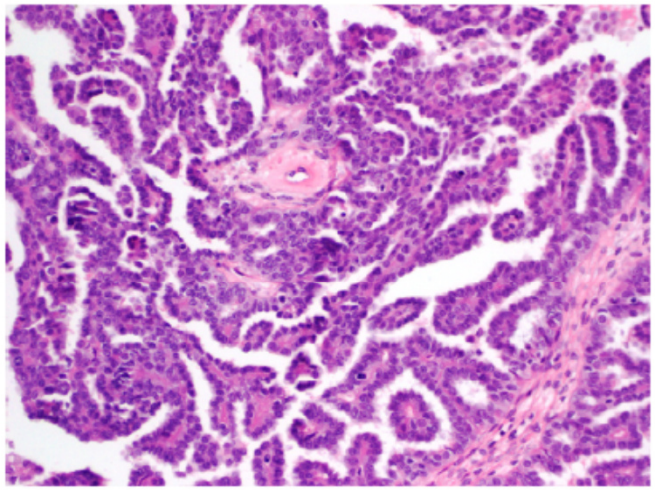

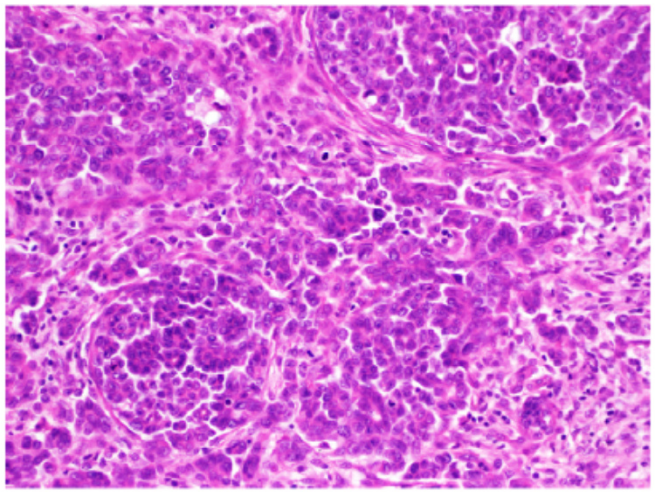

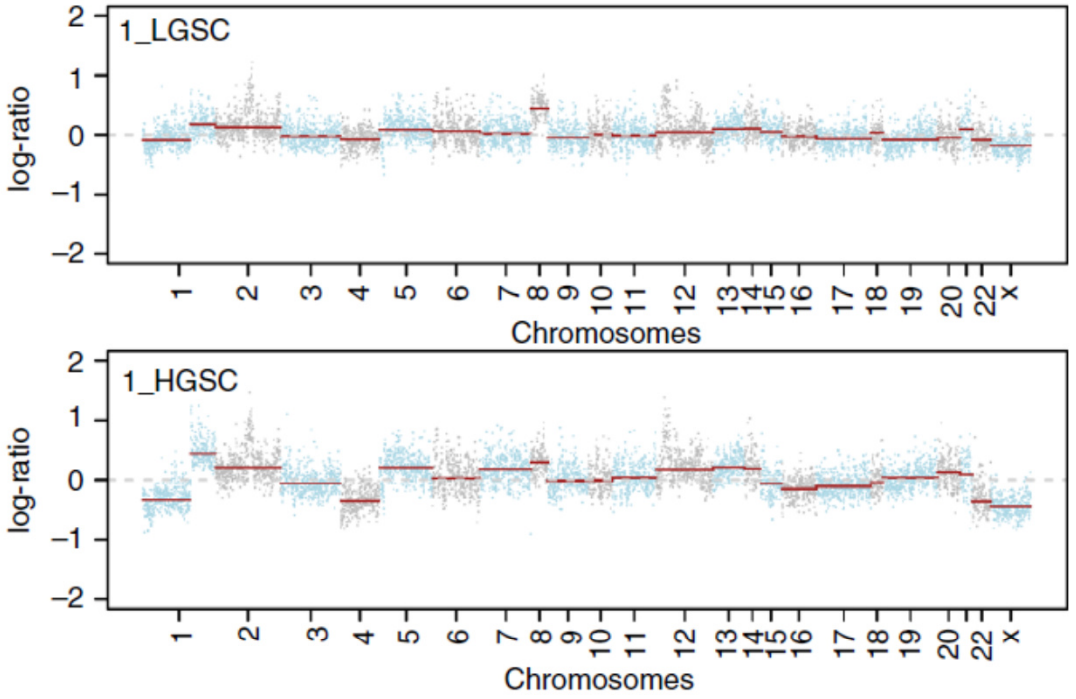
1_LGSC
log-ratio
2
1
0
−1
−2
1 2 3 4 5 6 7 8 9 10 11 12 13 14 15 16 17 18 19 20 22 x
Chromosomes
1_HGSC
log-ratio
2
1
0
−1
−2
1 2 3 4 5 6 7 8 9 10 11 12 13 14 15 16 17 18 19 20 22 x
Chromosomes

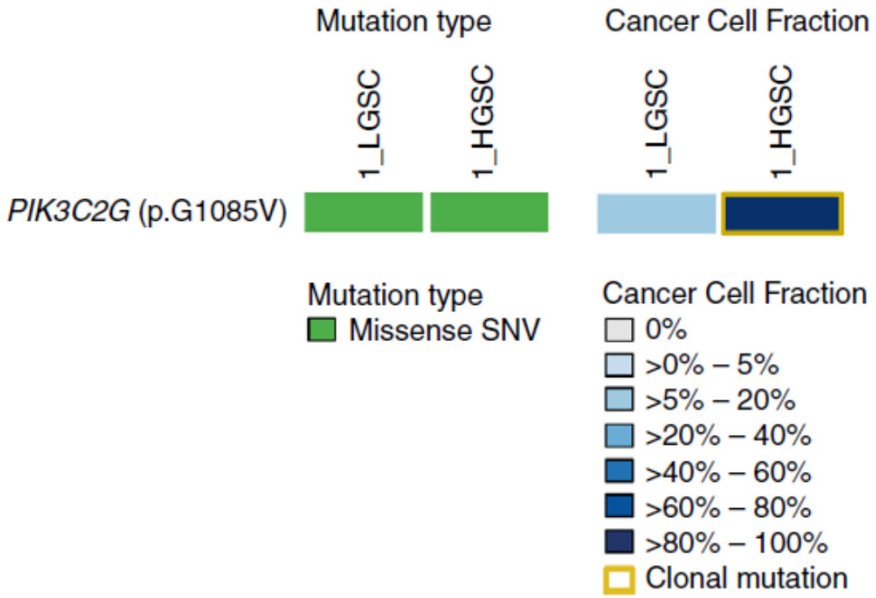
Mutation type
Cancer Cell Fraction
1_LGSC
1_HGSC
1_LGSC
1_HGSC
PIK3C2G (p.G1085V)
Mutation type
Missense SNV
Cancer Cell Fraction
0%
>0% – 5%
>5% – 20%
>20% – 40%
>40% – 60%
>60% – 80%
>80% – 100%
Clonal mutation

low-grade and high-grade tumours from a given case were related, and shared mutations and copy number alterations. Progression from low-grade to high-grade lesions was observed, and involved the acquisition of additional mutations and/or copy number alterations, or shifts from subclonal to clonal mutations. Only two (an HGSC and a PDC) of the five high-grade tumours investigated harboured *TP53* mutations, whereas *NRAS* and *KRAS* hotspot mutations were seen in two HGSCs and one HGSC, respectively.

Conclusions: Our results suggest that progression from SBT to HGSC may take place in a subset of cases, and that at least some of the rare HGSCs lacking *TP53* mutations may be derived from a low-grade serous precursor.

OVARIAN CANCER

High grade serous Ca	70%
Low grade serous Ca	5%
Endometrioid Ca	10%
Clear Cell Ca	10%
Mucinous Ca	3%
Sero-Mucinous, Brenner, other tumors	

MOLECULAR FEATURES OF ENDOMETRIOID CARCINOMA

ENDOMETRIUM

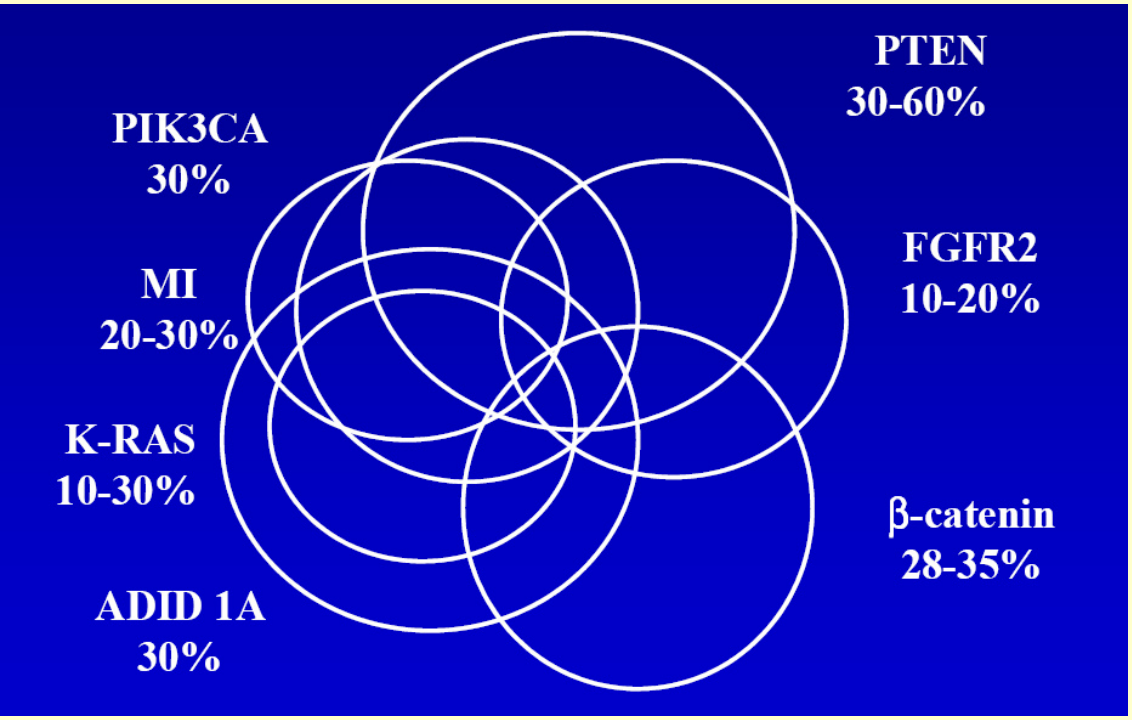

OVARY

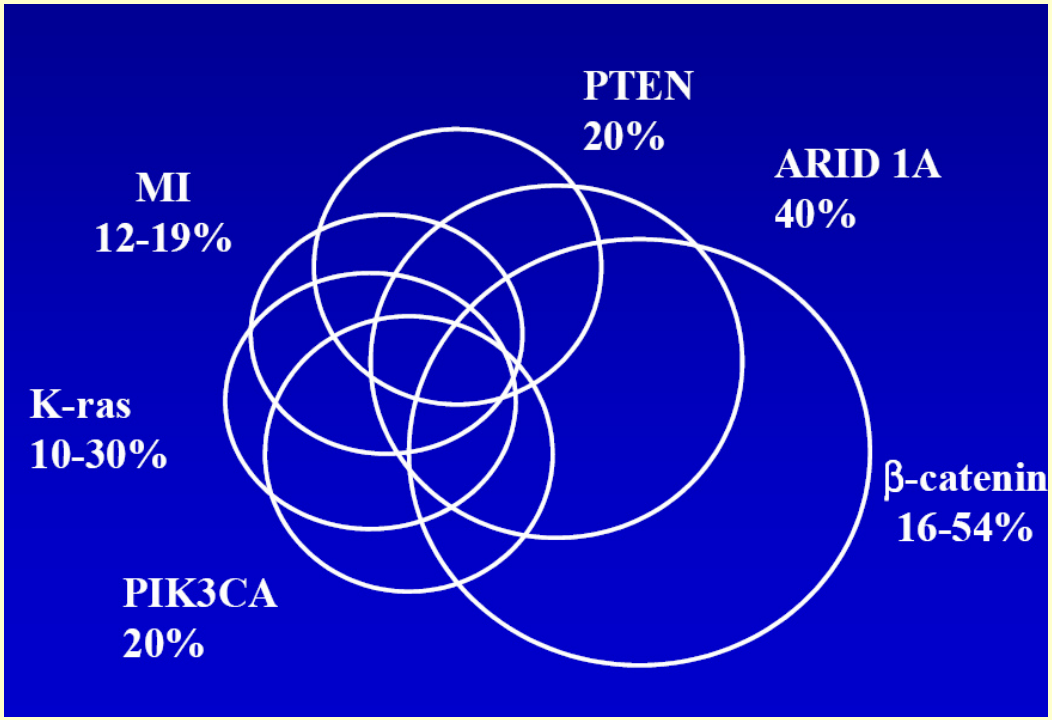

OVARIAN CANCER

High grade serous Ca	70%
Low grade serous Ca	5%
Endometrioid Ca	10%
Clear Cell Ca	10%
Mucinous Ca	3%
Sero-Mucinous, Brenner, other tumors	

MOLECULAR FEATURES OF CLEAR CELL CARCINOMA OF THE OVARY

Mutations

- ARID1A, 50%
- PIK3CA, 40%
- PPP2R1A, 7%
- PTEN, 15%
- POLE, 4%

Amplification/overexpression

- PPM1D, 10%
- EBB2,
- HNF1β
- MET

OVARIAN CANCER

High grade serous Ca	**70%**
Low grade serous Ca	**5%**
Endometrioid Ca	**10%**
Clear Cell Ca	**10%**
Mucinous Ca	**3%**

Sero-Mucinous, Brenner, other tumors

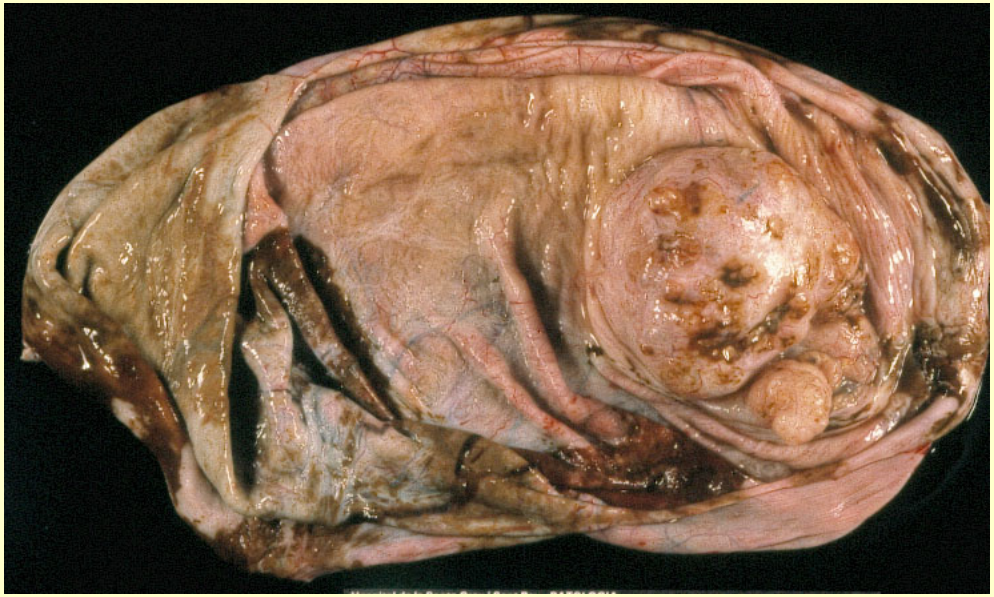

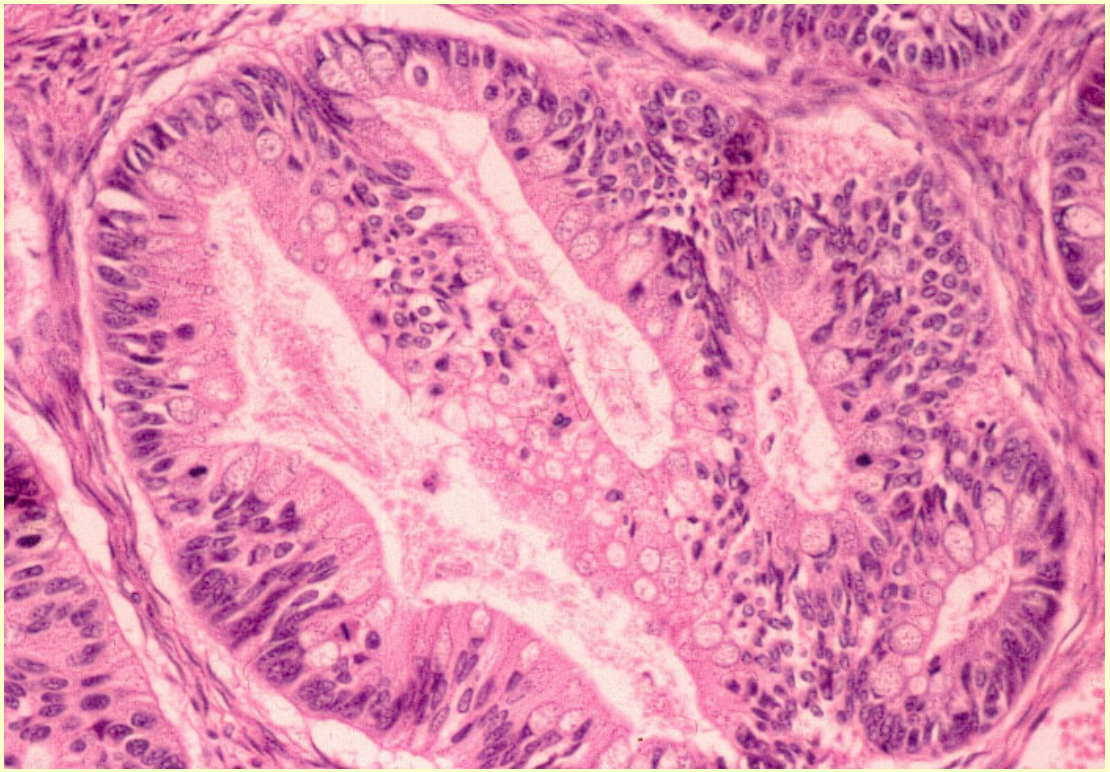

Epithelial Ovarian Tumors

K-ras Mutations (12, 13)

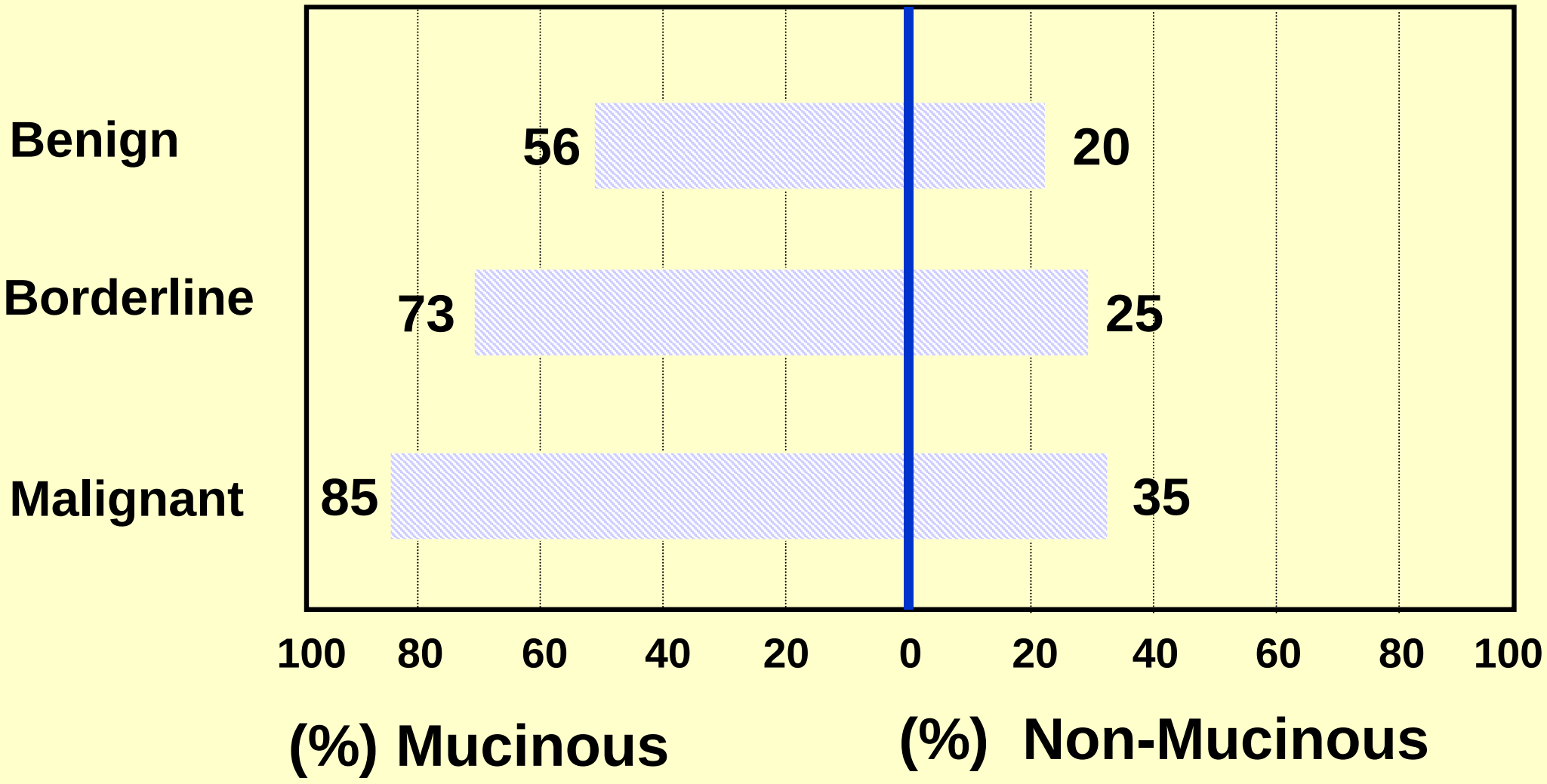

Cuatrecasas M, et al. Cancer 1997

C-erb B2



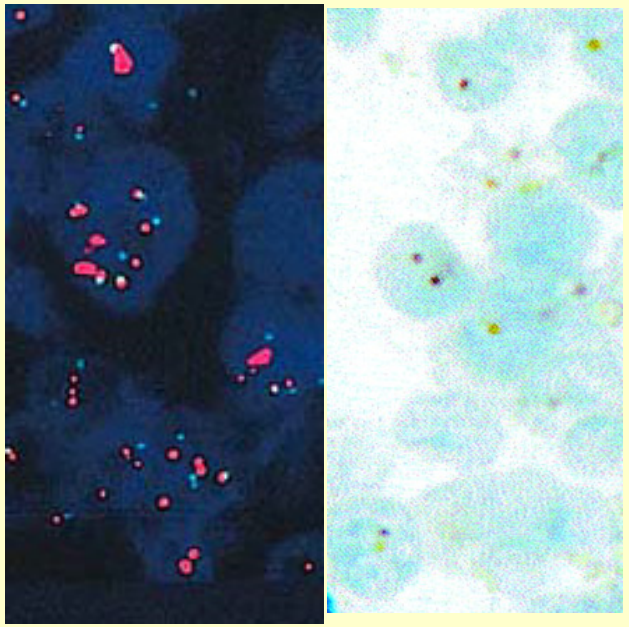

Ryland *et al. Genome Medicine* (2015) 7:87
DOI 10.1186/s13073-015-0210-y

Genome Medicine

RESEARCH Open Access

Mutational landscape of mucinous ovarian carcinoma and its neoplastic precursors

Georgina L. Ryland[1], Sally M. Hunter[1], Maria A. Doyle[2], Franco Caramia[2], Jason Li[2], Simone M. Rowley[1], Michael Christie[3], Prue E. Allan[4], Andrew N. Stephens[5,6,7], David D L Bowtell[8,9,10], Australian Ovarian Cancer Study Group, Ian G. Campbell[1,9,11] and Kylie L. Gorringe[1,9,11*]

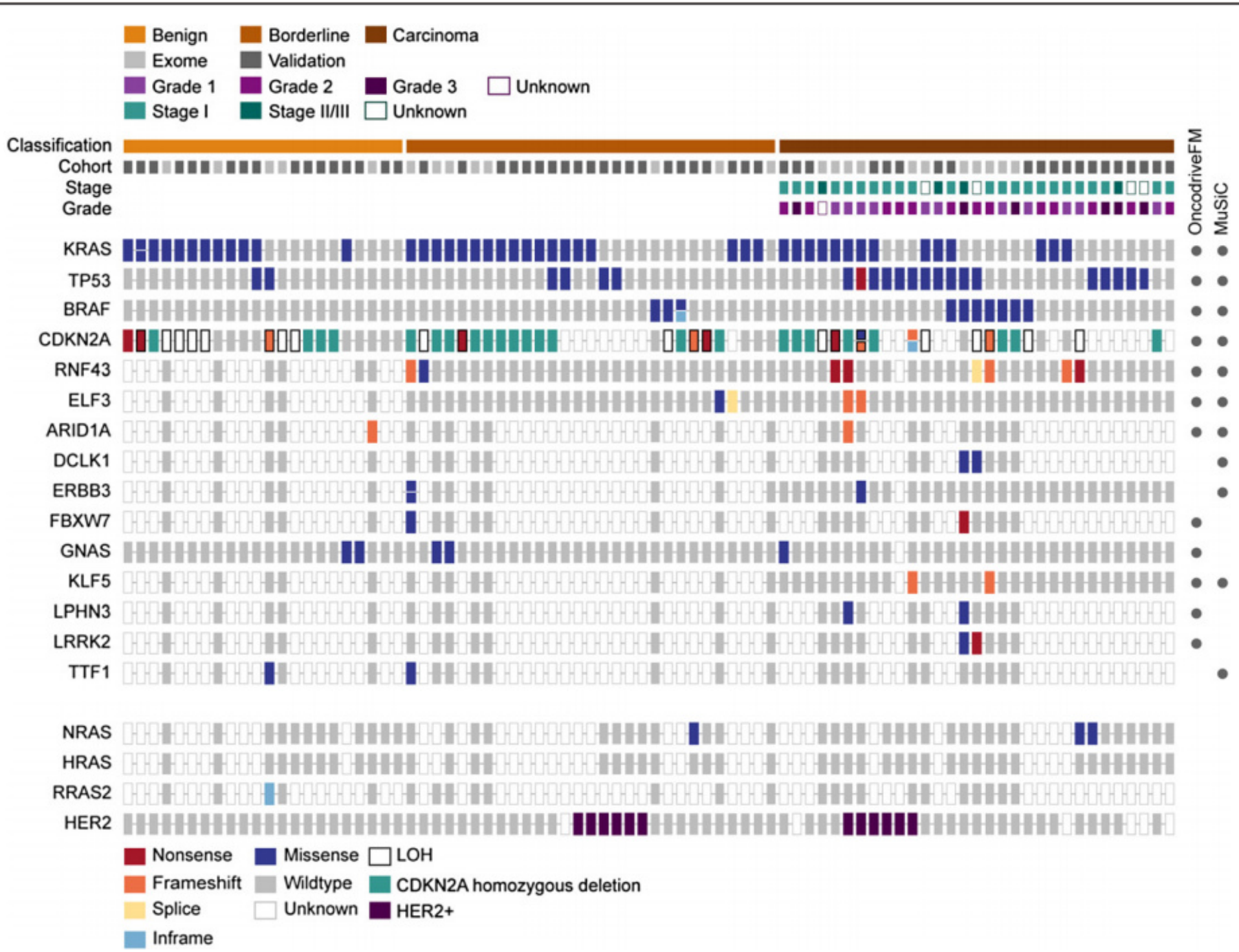
Benign
Borderline
Carcinoma
Exome
Validation
Grade 1
Grade 2
Grade 3
Unknown
Stage I
Stage II/III
Unknown
Classification
Cohort
Stage
Grade
OncodriveFM
MuSiC
KRAS
TP53
BRAF
CDKN2A
RNF43
ELF3
ARID1A
DCLK1
ERBB3
FBXW7
GNAS
KLF5
LPHN3
LRRK2
TTF1
NRAS
HRAS
RRAS2
HER2
Nonsense
Missense
LOH
Frameshift
Wildtype
CDKN2A homozygous deletion
Splice
Unknown
HER2+
Inframe

Massively parallel sequencing analysis of mucinous ovarian carcinomas: genomic profiling and differential diagnoses

Jennifer J. Mueller [a,1], Brooke A. Schlappe [a,1], Rahul Kumar [b], Narciso Olvera [a,2], Fanny Dao [a,2], Nadeem Abu-Rustum [a], Carol Aghajanian [c], Deborah DeLair [b], Yaser R. Hussein [b], Robert A. Soslow [b], Douglas A. Levine [a,2], Britta Weigelt [b,*]

Gynecologic Oncology 150 (2018) 127–135

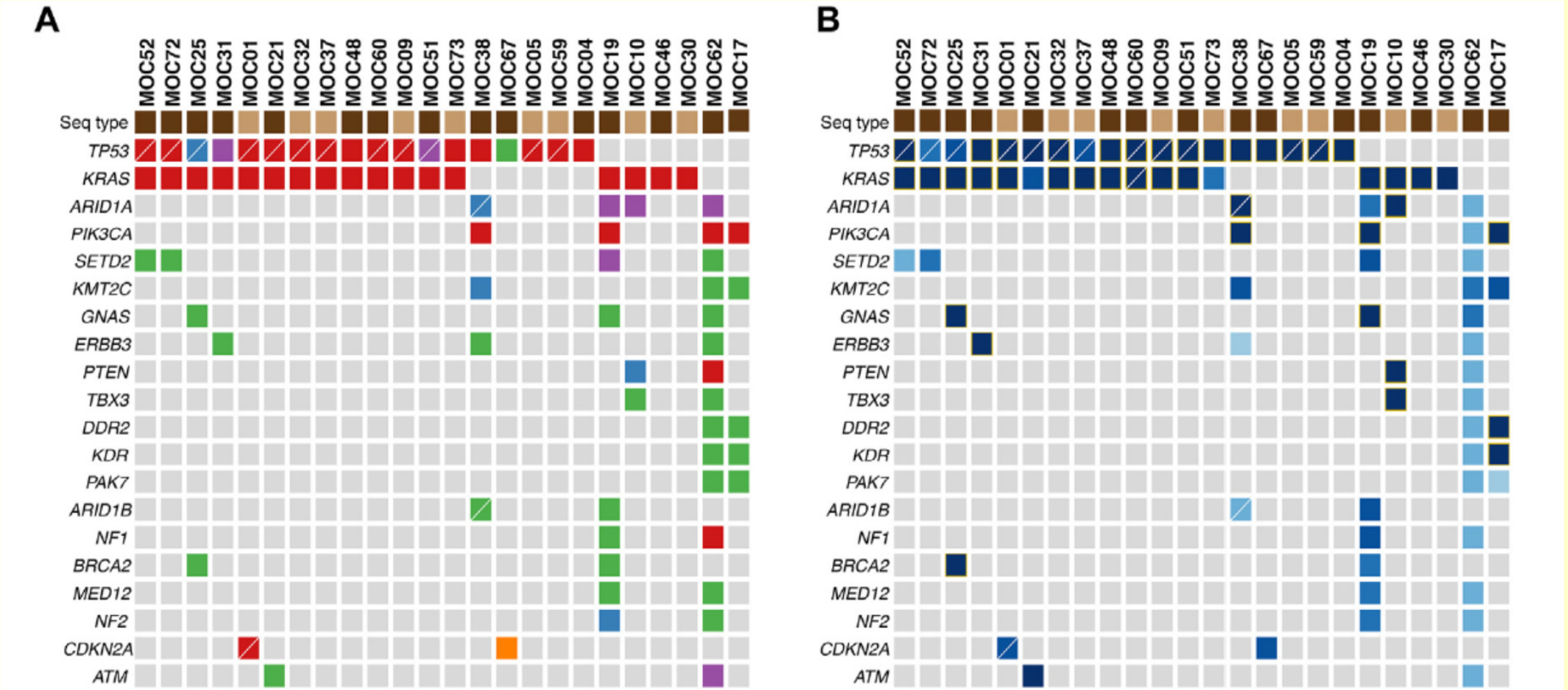

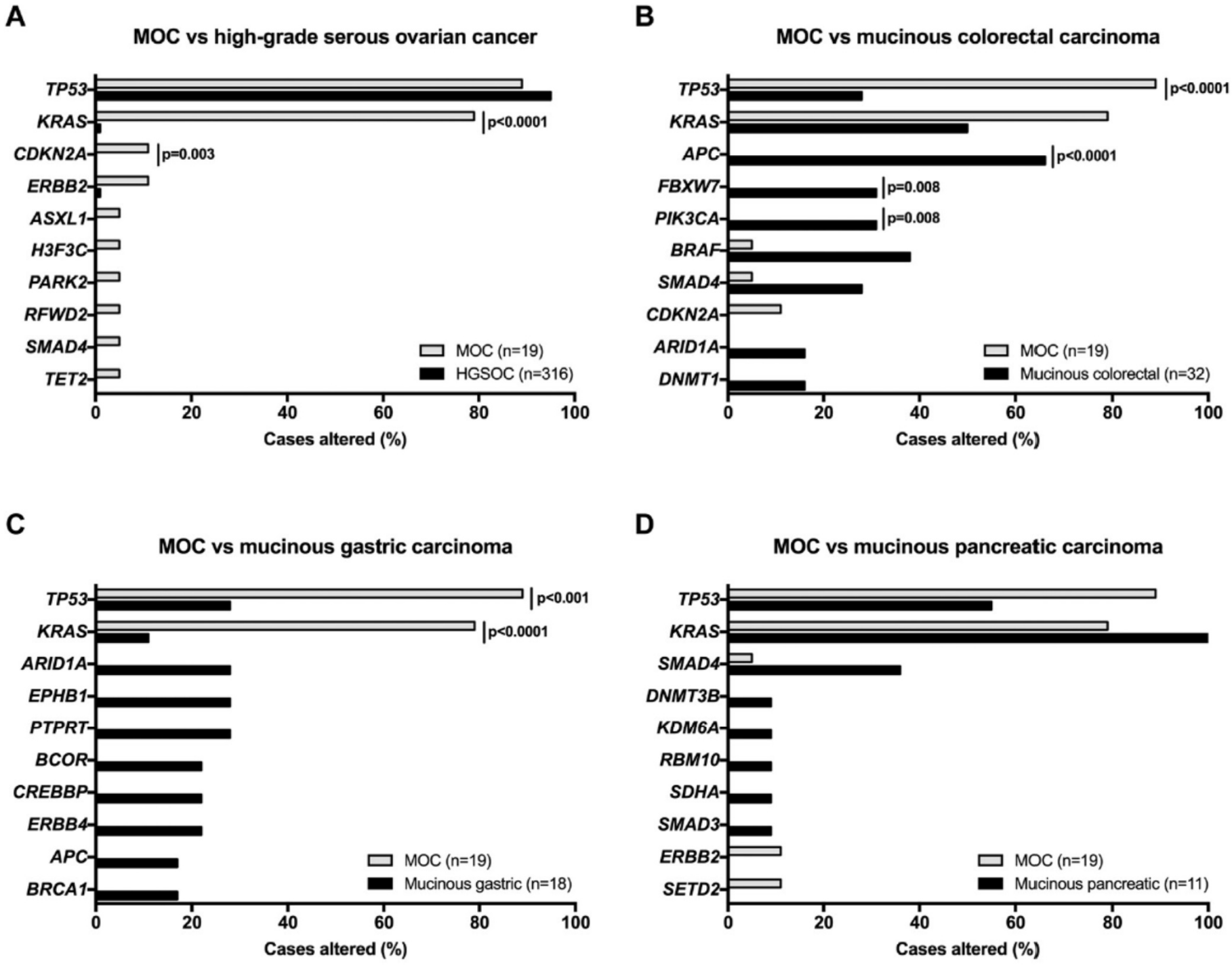
A
MOC vs high-grade serous ovarian cancer
TP53
KRAS
CDKN2A
ERBB2
ASXL1
H3F3C
PARK2
RFWD2
SMAD4
TET2
p<0.0001
p=0.003
MOC (n=19)
HGSOC (n=316)
0
20
40
60
80
100
Cases altered (%)
B
MOC vs mucinous colorectal carcinoma
TP53
KRAS
APC
FBXW7
PIK3CA
BRAF
SMAD4
CDKN2A
ARID1A
DNMT1
p<0.0001
p<0.0001
p=0.008
p=0.008
MOC (n=19)
Mucinous colorectal (n=32)
0
20
40
60
80
100
Cases altered (%)
C
MOC vs mucinous gastric carcinoma
TP53
KRAS
ARID1A
EPHB1
PTPRT
BCOR
CREBBP
ERBB4
APC
BRCA1
p<0.001
p<0.0001
MOC (n=19)
Mucinous gastric (n=18)
0
20
40
60
80
100
Cases altered (%)
D
MOC vs mucinous pancreatic carcinoma
TP53
KRAS
SMAD4
DNMT3B
KDM6A
RBM10
SDHA
SMAD3
ERBB2
SETD2
MOC (n=19)
Mucinous pancreatic (n=11)
0
20
40
60
80
100
Cases altered (%)

Simultaneous endometrioid carcinomas of the endometrium and the ovaries

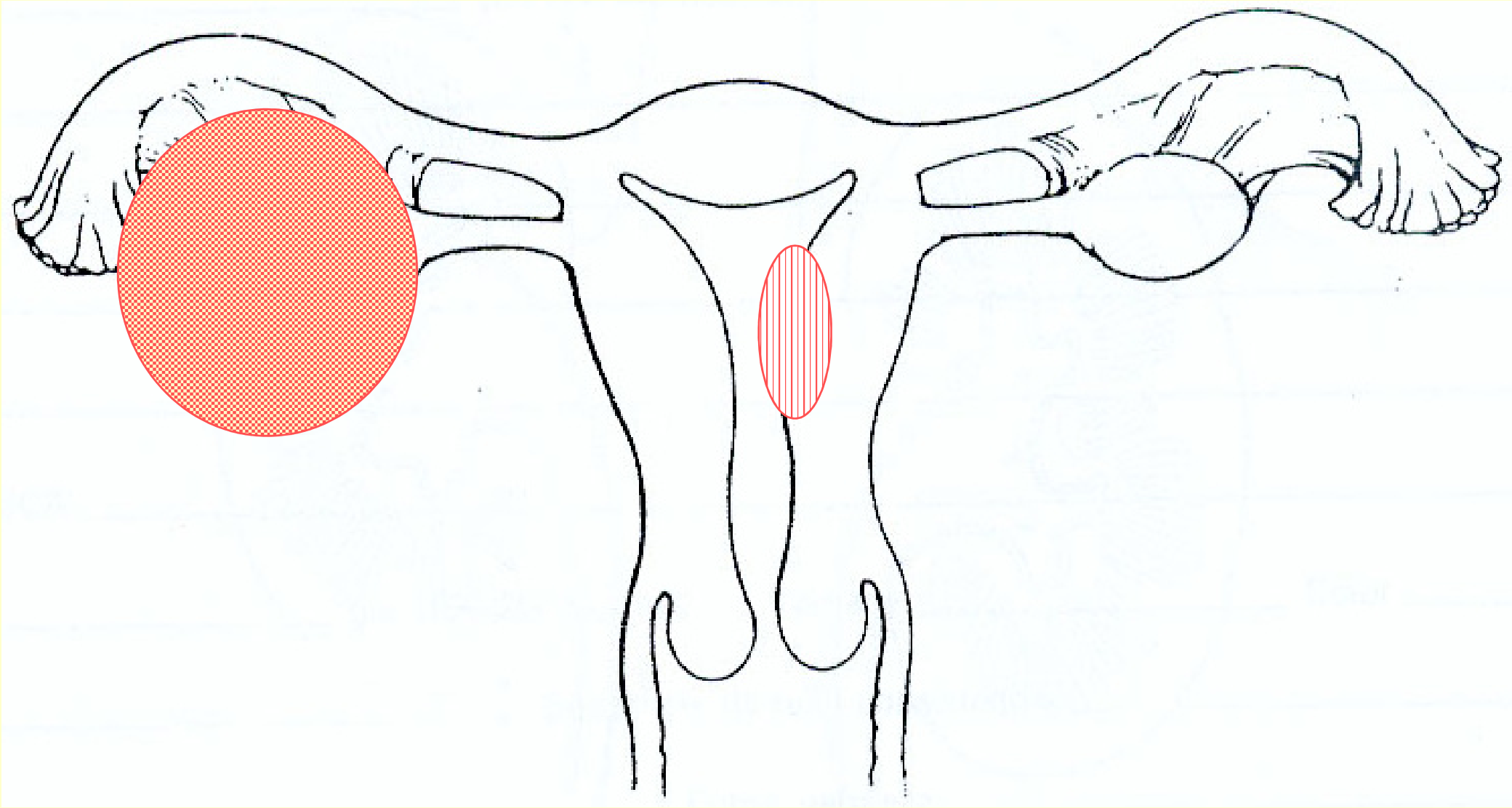

Simultaneous endometrioid carcinomas of the endometrium and the ovaries (Criteria)

- Tumor sizes
- Histological grades
- Bilaterality
- Pattern of tumor growth
- Tubal, myometrial, vascular invasion
- Presence of endometriosis

MOLECULAR FEATURES OF ENDOMETRIOID CARCINOMA

ENDOMETRIUM

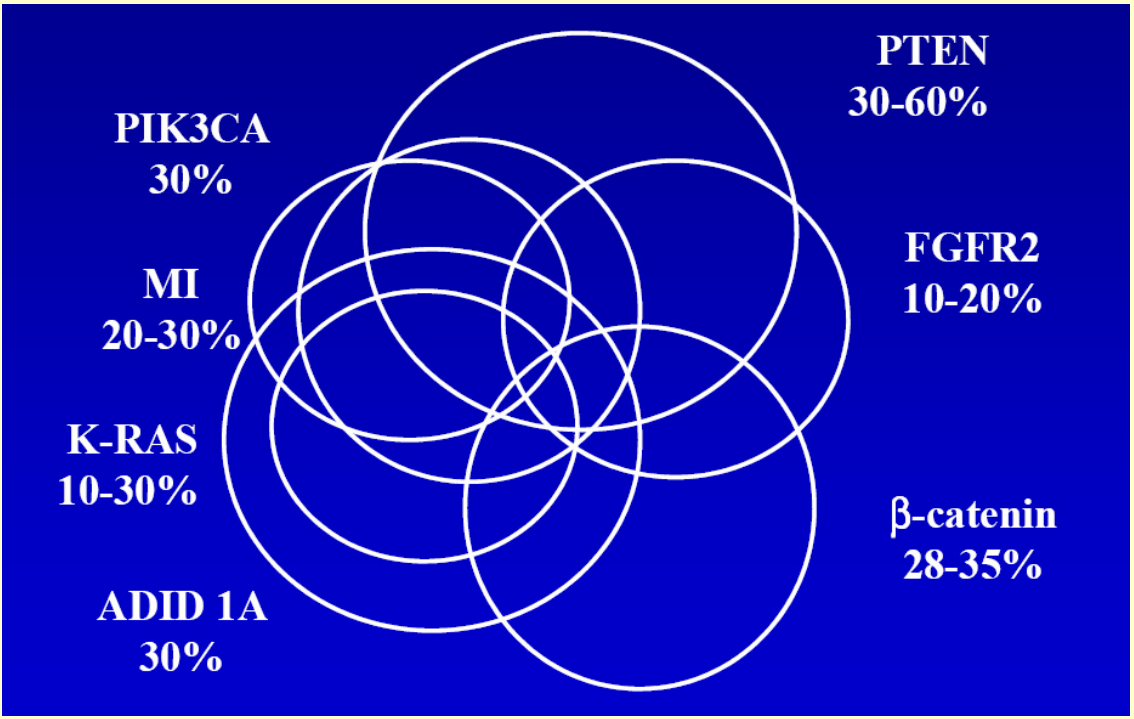

OVARY

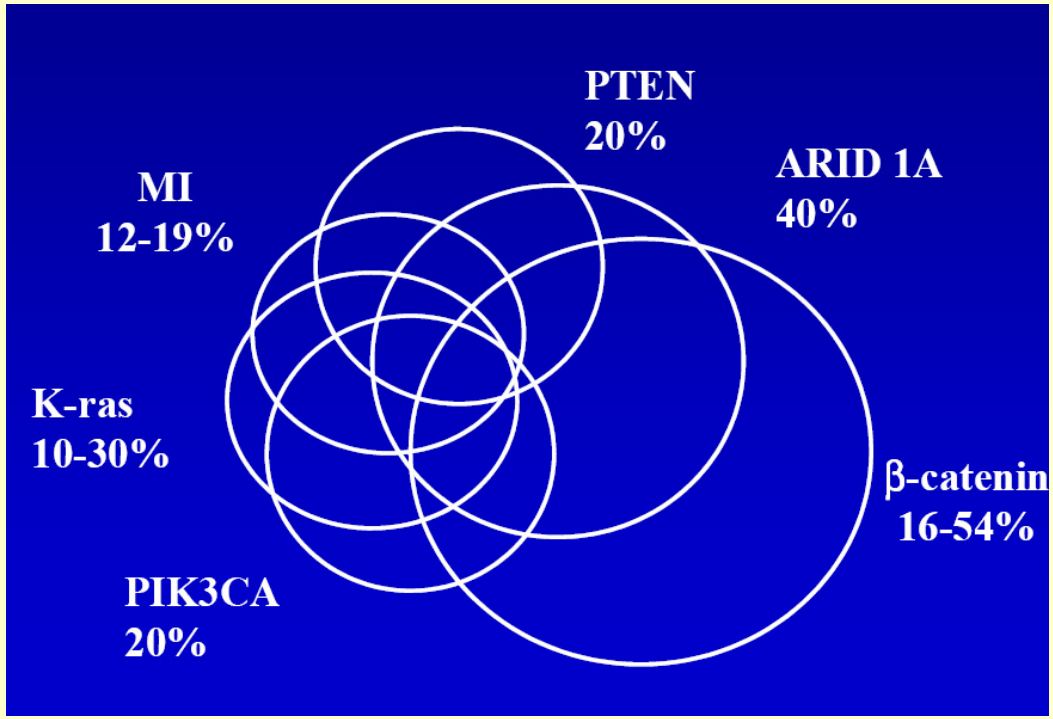

Independent Primary Endometrioid Carcinomas of Uterus and Ovary

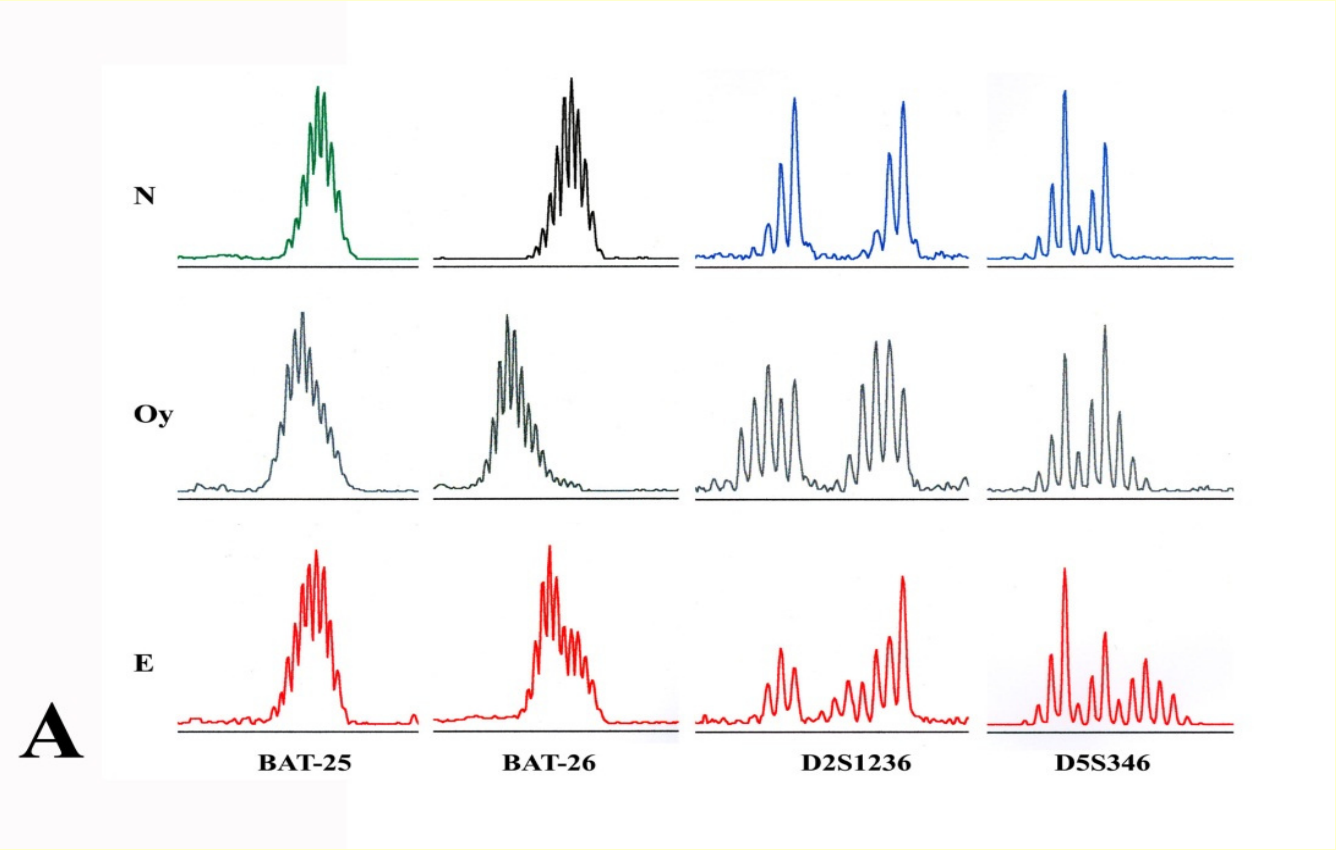

Metastatic Carcinoma

(Identical MI pattern - AWT at 3 y)

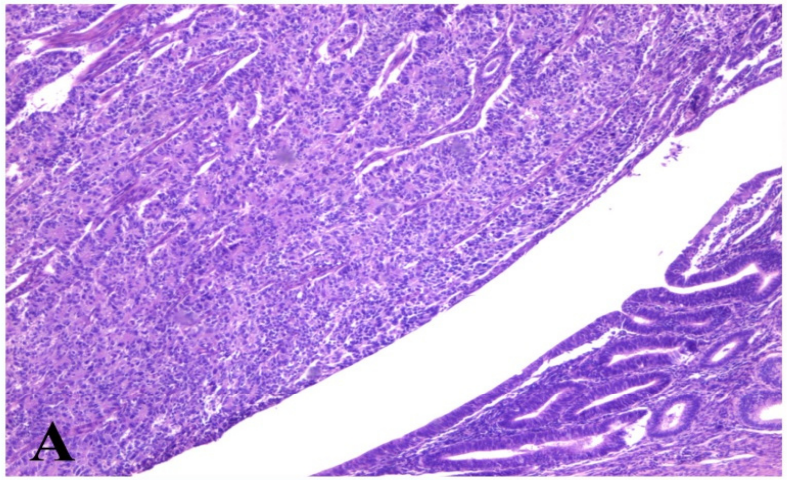

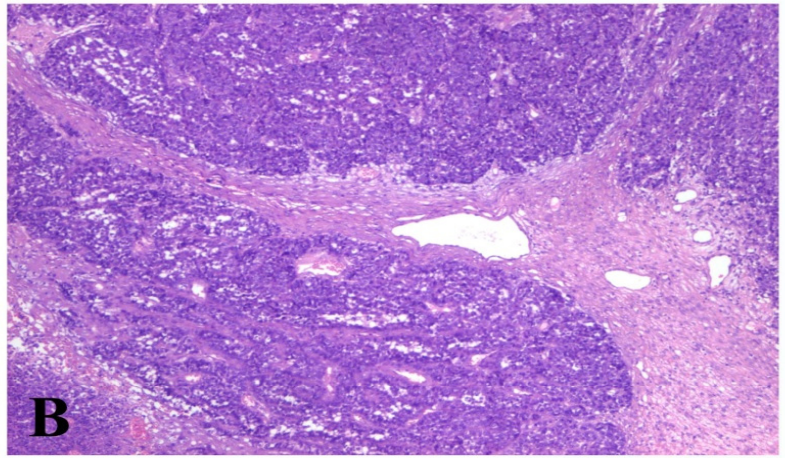

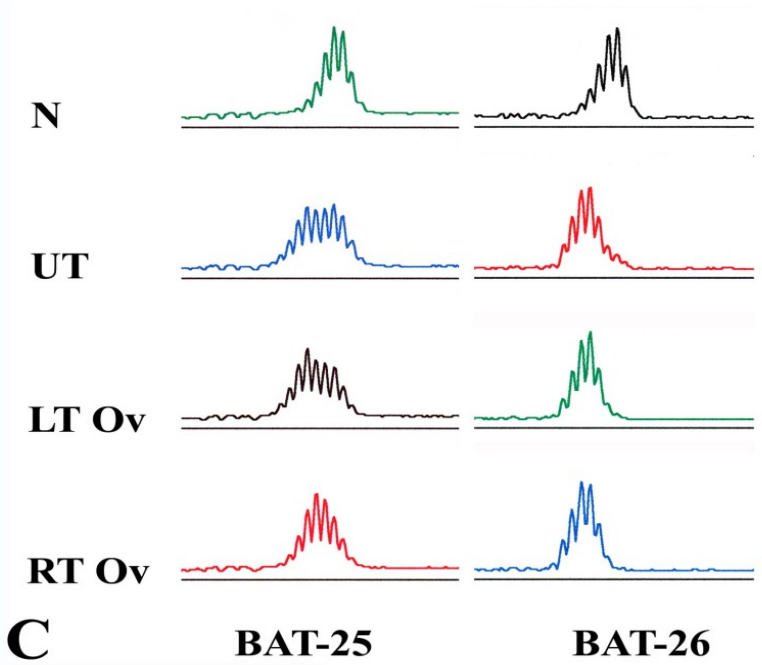

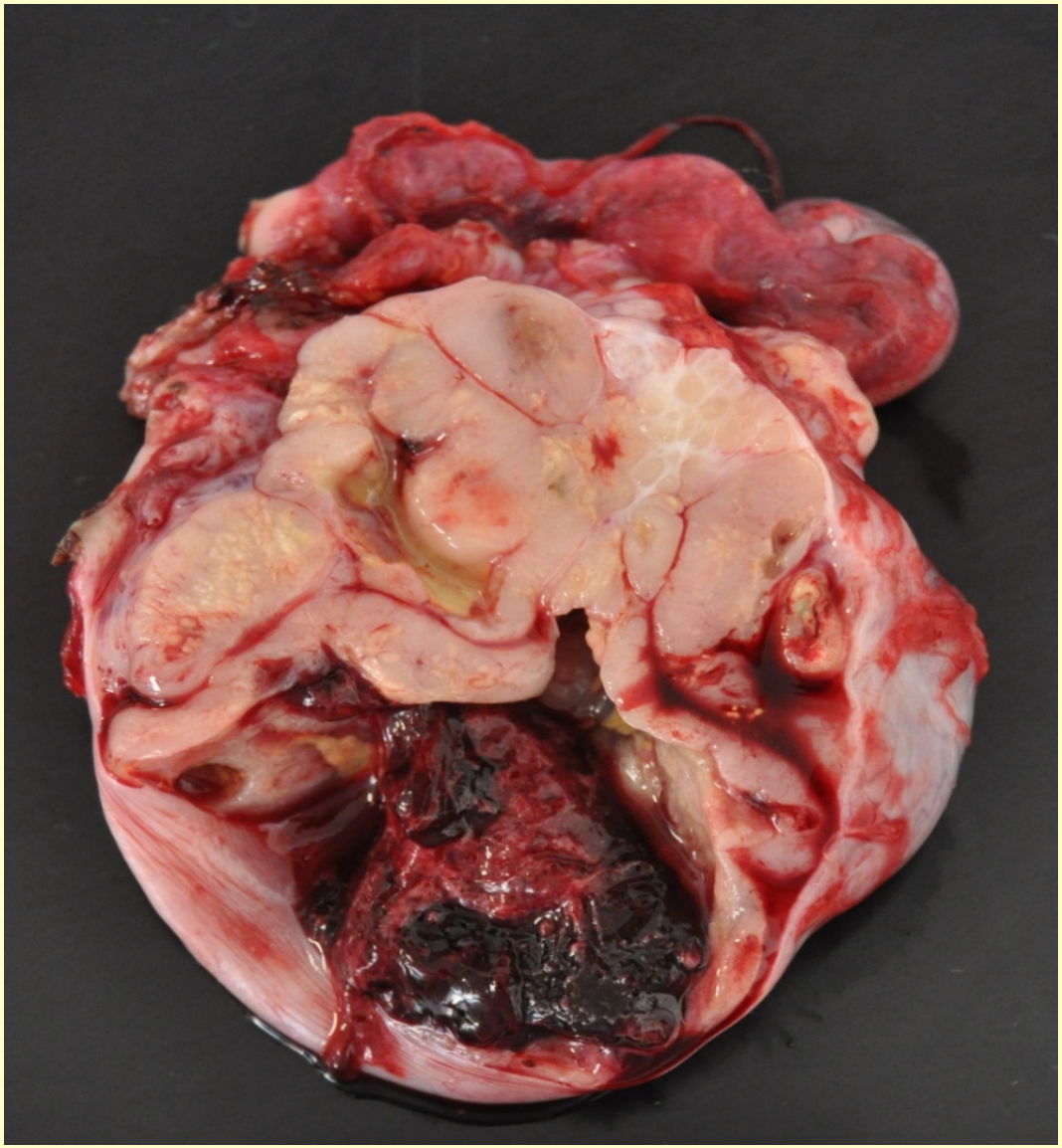



CTNNB1 S33Y
TCT-TAT

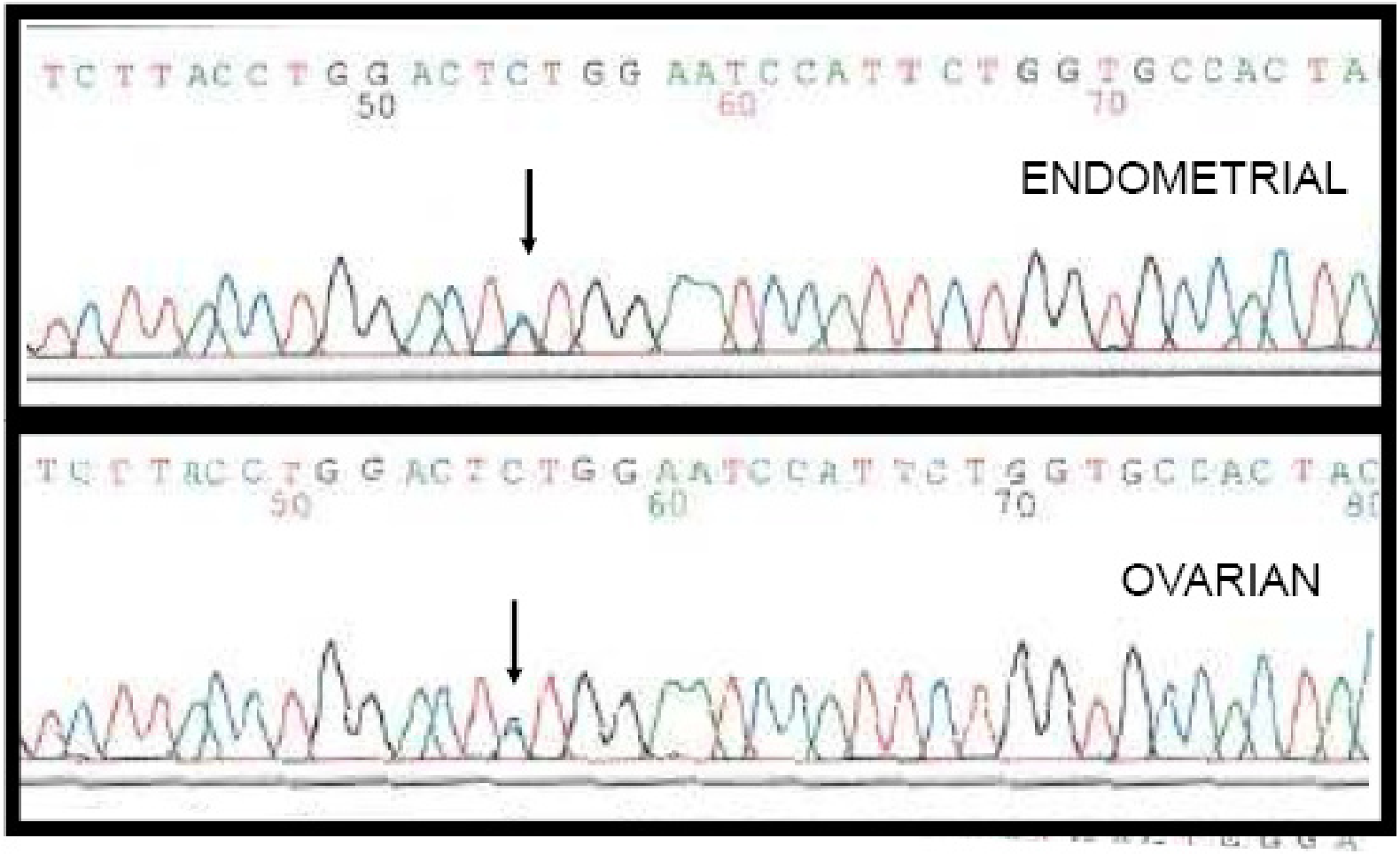

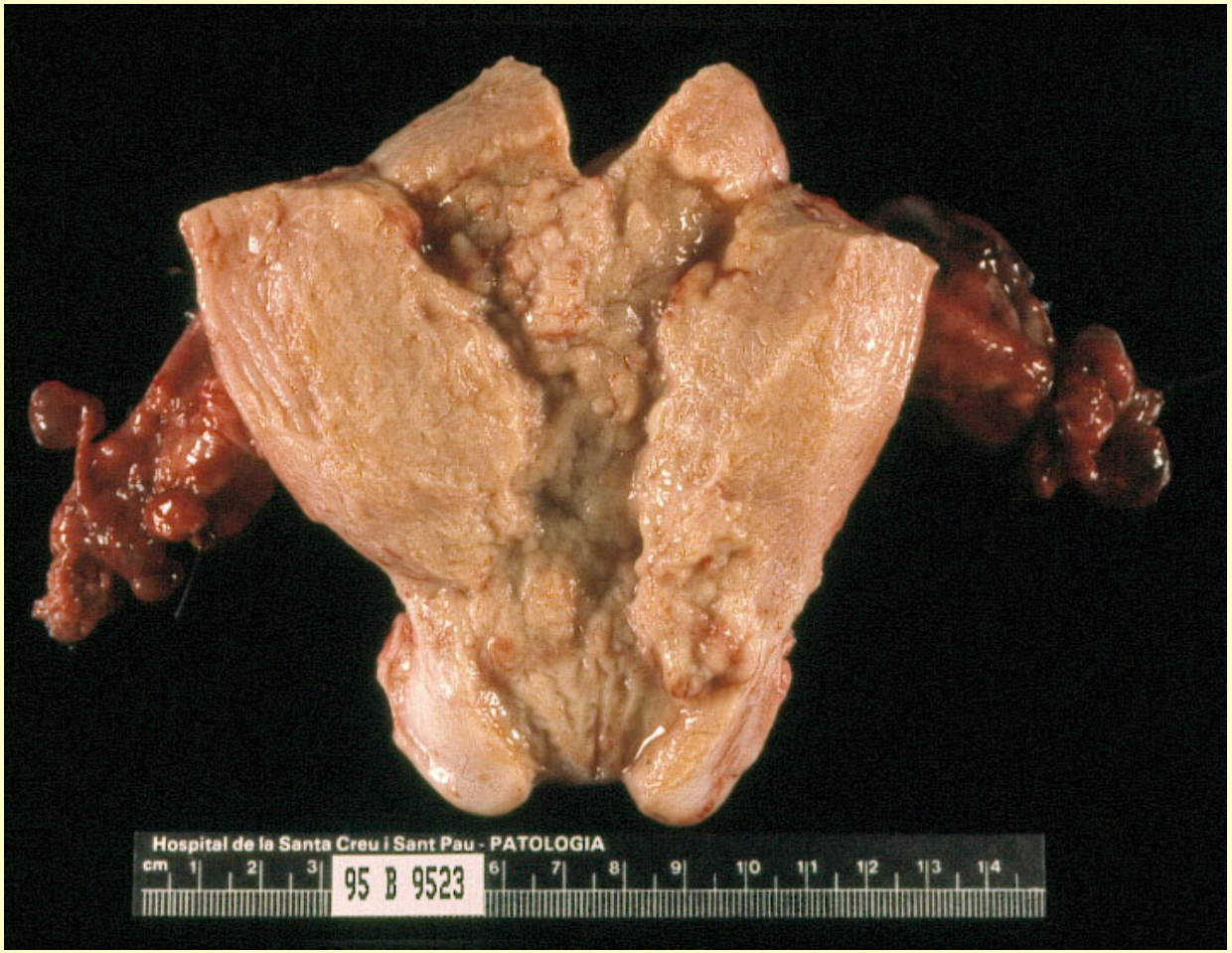
Hospital de la Santa Creu i Sant Pau - PATOLOGIA
95 B 9523

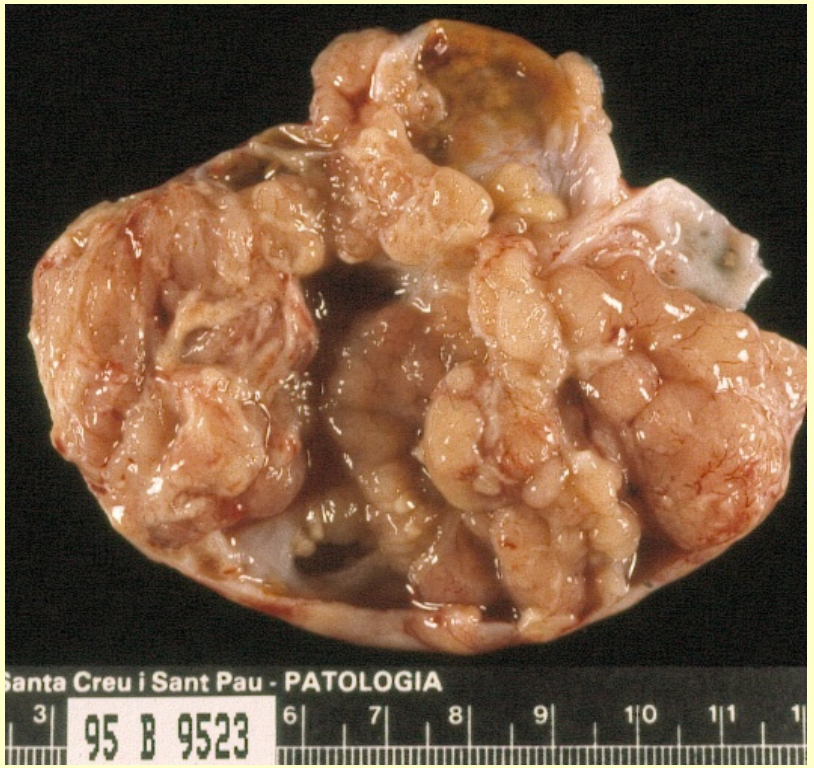
Santa Creu i Sant Pau - PATOLOGIA
95 B 9523

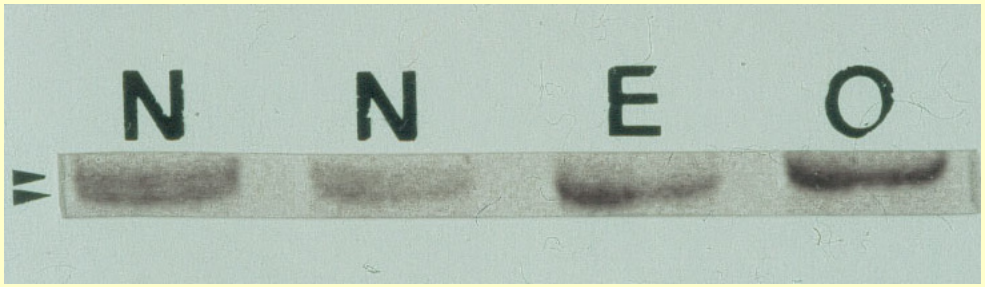
N
N
E
O


BAT-26
N
E
O

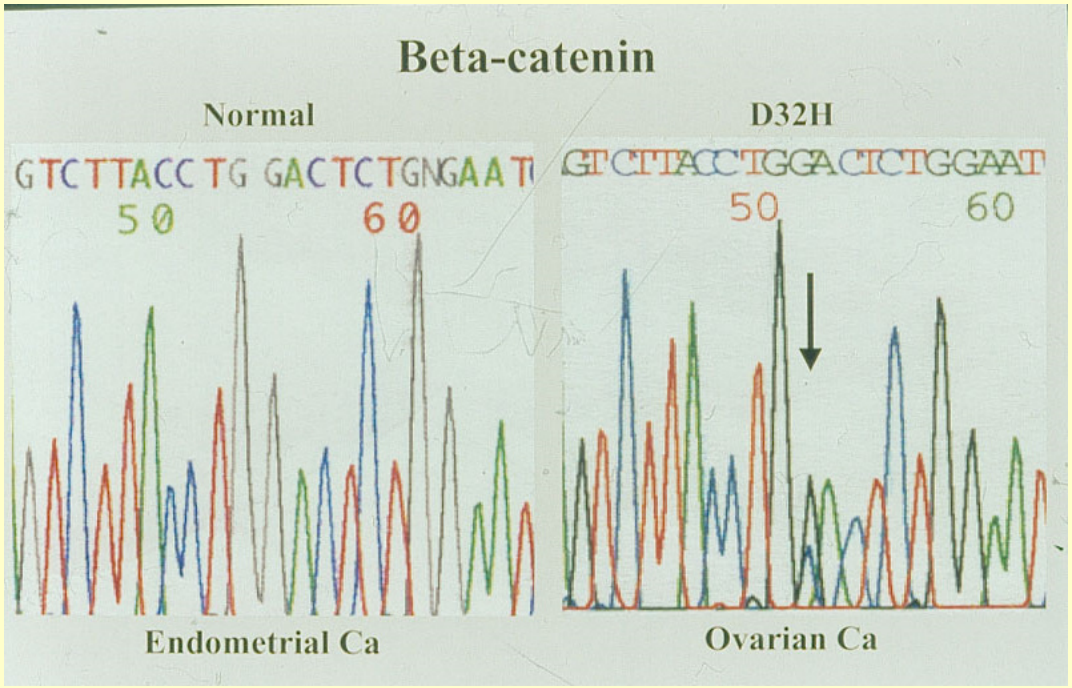
Beta-catenin
Normal
D32H
GTCTTACCTG GACTCTGNGAAT
50
60
GTCTTACCTGGACTCTGGAAT
50
60
Endometrial Ca
Ovarian Ca

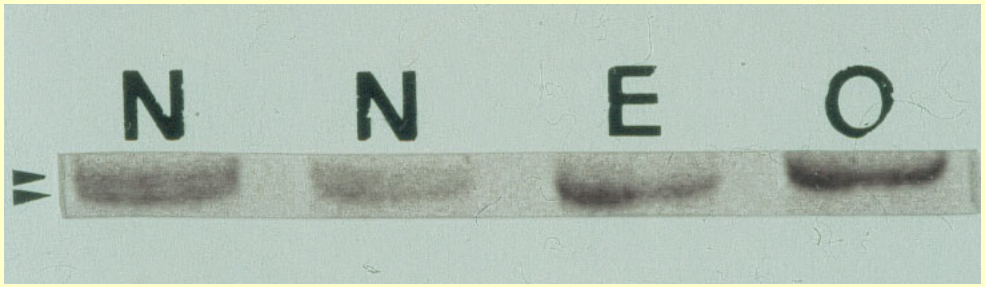
N N E O

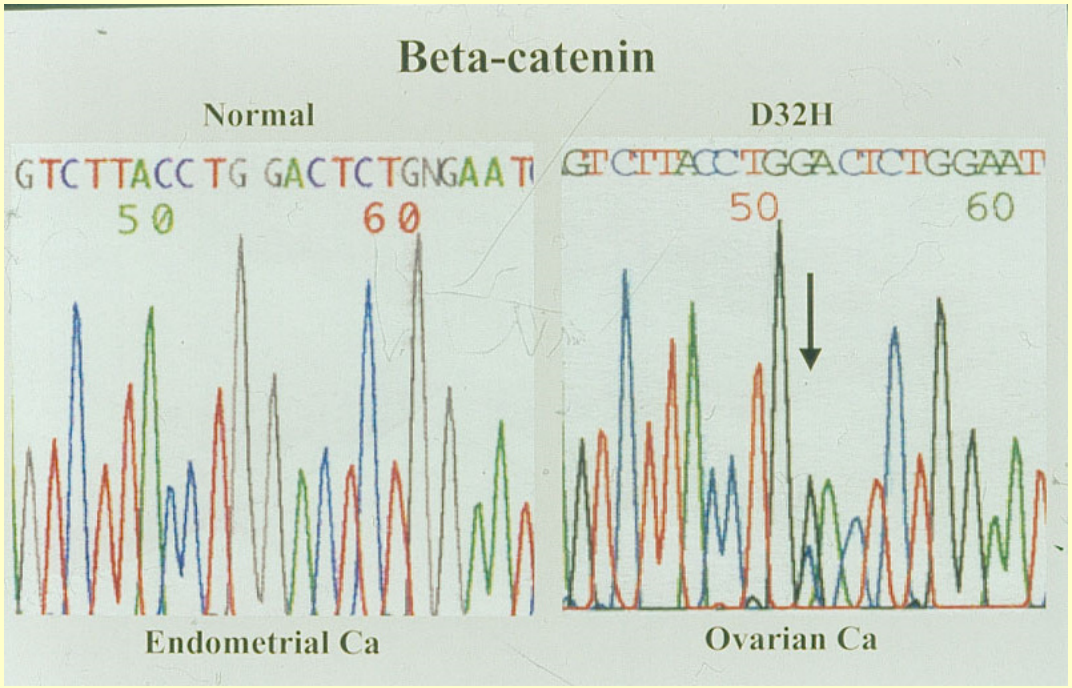
Beta-catenin
Normal
D32H
GTCTTACCTG GACTCTGNGAAT
50 60
GTCTTACCTGGACTCTGGAAT
50 60
Endometrial Ca
Ovarian Ca


BAT-26
N E O

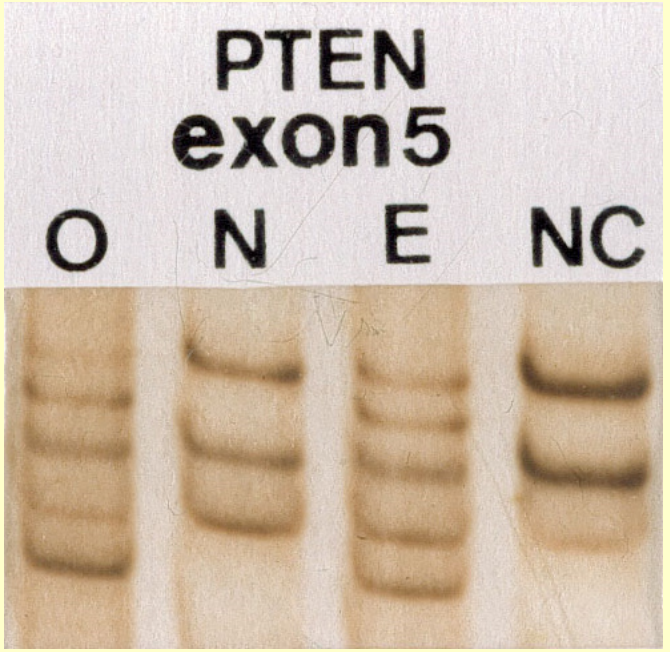
PTEN
exon5
O N E NC

BRIEF COMMUNICATION

Massively Parallel Sequencing-Based Clonality Analysis of Synchronous Endometrioid Endometrial and Ovarian Carcinomas

Anne M. Schultheis*, Charlotte K. Y. Ng*, Maria R. De Filippo, Salvatore Piscuoglio, Gabriel S. Macedo, Sonia Gatius, Belen Perez Mies, Robert A. Soslow, Raymond S. Lim, Agnes Viale, Kety H. Huberman, Jose C. Palacios, Jorge S. Reis-Filho, Xavier Matias-Guiu, Britta Weigelt

JNCI J Natl Cancer Inst, 2016, Vol. 108, No. 6

. We subjected sporadic synchronous EECs/EOCs from five patients to whole-exome massively parallel sequencing, which revealed that the EEC and EOC of each case displayed strikingly similar repertoires of somatic mutations and gene copy number alterations. Despite the presence of mutations restricted to the EEC or EOC in each case, we observed that the mutational processes that shaped their respective genomes were consistent. High-depth targeted massively parallel sequencing of sporadic synchronous EECs/EOCs from 17 additional patients confirmed that these lesions are clonally related. In an additional Lynch Syndrome case, however, the EEC and EOC were found to constitute independent cancers lacking somatic mutations in common. Taken together, sporadic synchronous EECs/EOCs are clonally related and likely constitute dissemination from one site to the other.

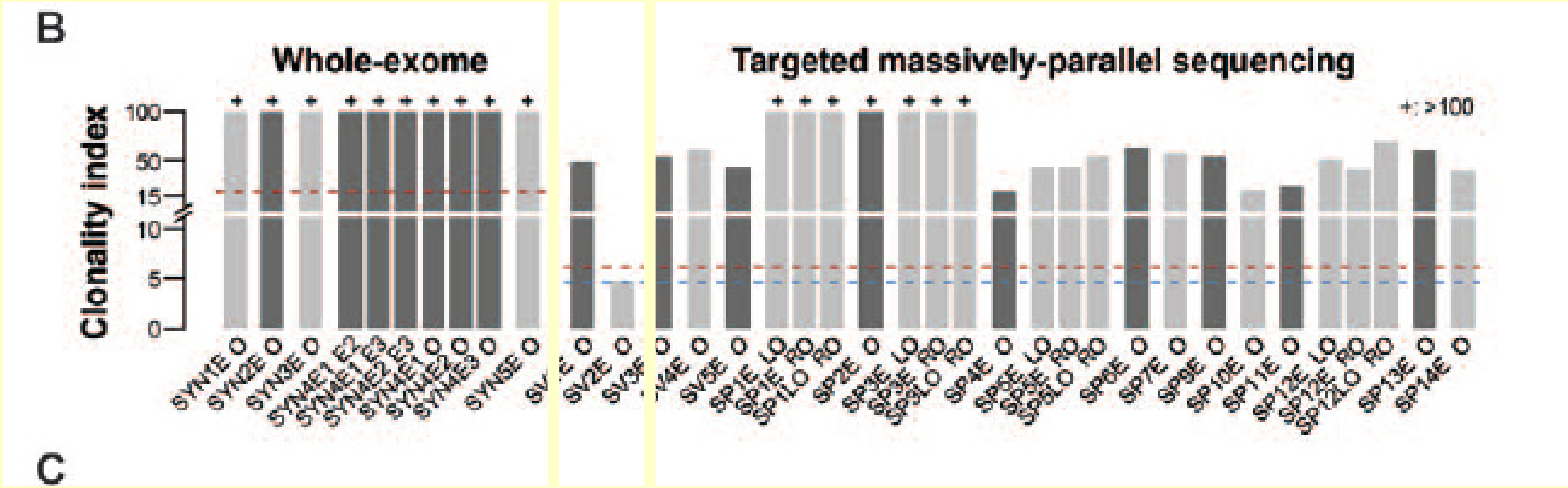
B
Whole-exome
Targeted massively-parallel sequencing
Clonality index
100
50
15
10
5
0
+: >100
SYN1E
SYN2E
SYN3E
SYN4E1 E2
SYN4E1 E3
SYN4E2 E3
SYN4E1
SYN4E2
SYN4E3
SYN5E
SV2E
SV3E
SV5E
SP1E
SP1E LO
SP1L O
SP1E RO
SP1L RO
SP2E
SP3E
SP3E LO
SP3L O
SP3E RO
SP3L RO
SP4E
SP5E
SP5E LO
SP5L O
SP5E RO
SP5L RO
SP6E
SP7E
SP9E
SP10E
SP11E
SP12E
SP12E LO
SP12L O
SP12E RO
SP12L RO
SP13E
SP14E
C

Simultaneous endometrioid carcinomas of the endometrium and the ovaries (unsolved issues)

- Why some ovarian metastasis are associated with bad prognosis and others are associated with indolent behaviour ?

Simultaneous endometrioid carcinomas of the endometrium and the ovaries (unsolved issues)

Aggressiveness may be related to :

- The precise step of endometrial tumorigenesis in which the ovarian metastasis develops.

- The metastatic pathway used (hematogenous versus transtubal)

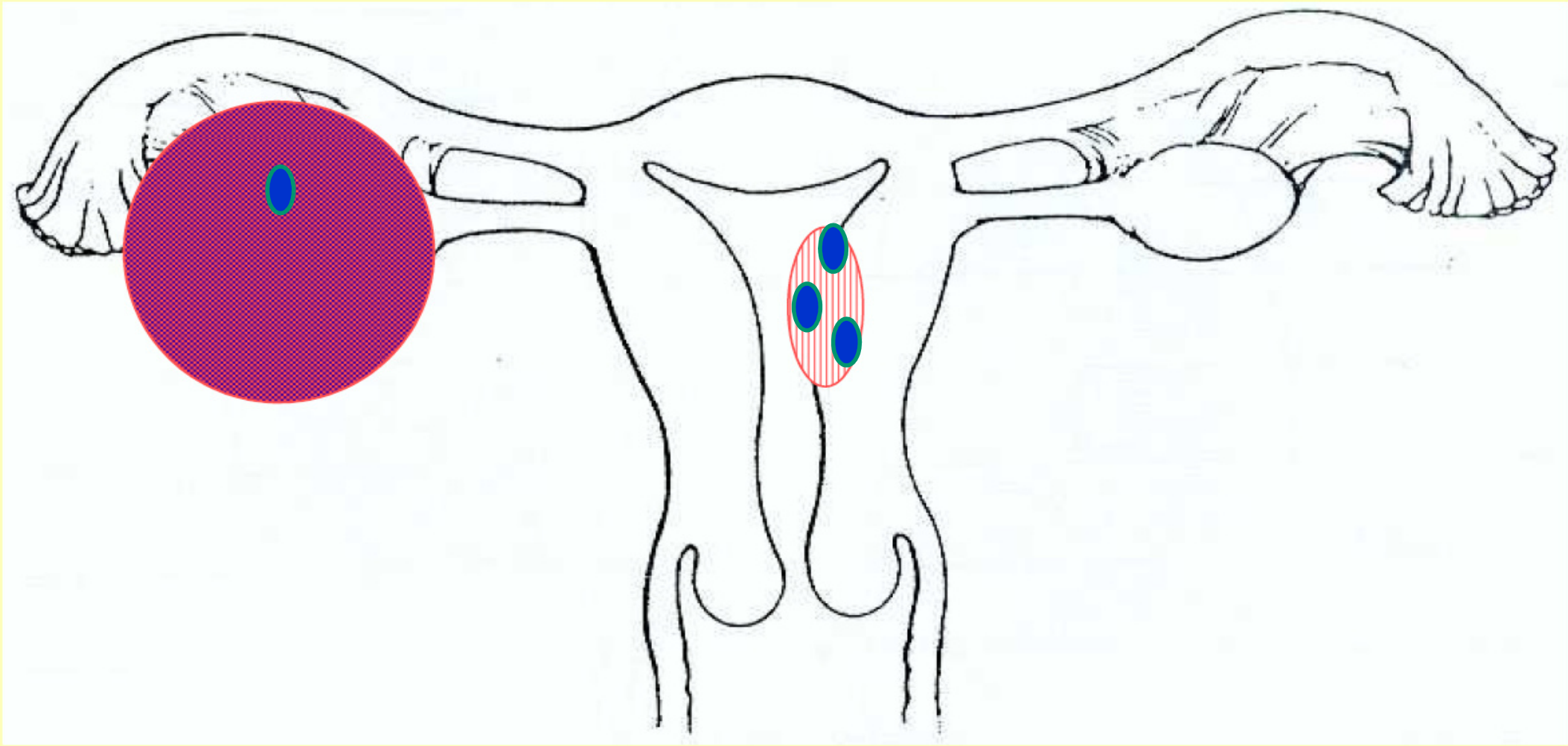

		Non-synonymous Mutations	
Case 4		Total	Passenger
Shared		110	20
Private	endometrial1	270	53
	endometrial2	113	28
	endometrial3	152	28
	ovarian	232	44
Total		877	173

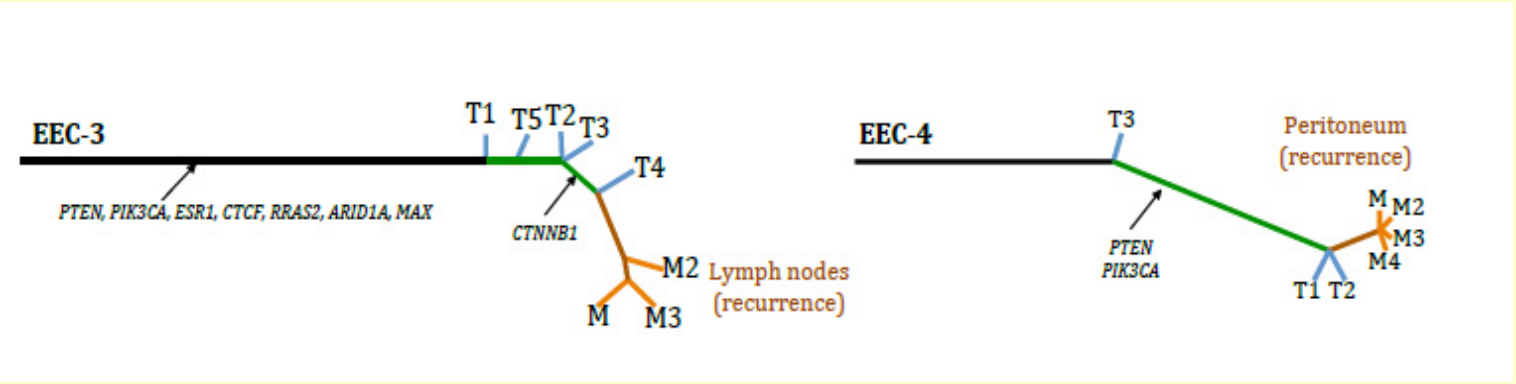
EEC-3
T1
T5
T2
T3
T4
PTEN, PIK3CA, ESR1, CTCF, RRAS2, ARID1A, MAX
CTNNB1
M2
Lymph nodes
(recurrence)
M
M3

EEC-4
T3
Peritoneum
(recurrence)
M
M2
M3
M4
PTEN
PIK3CA
T1
T2

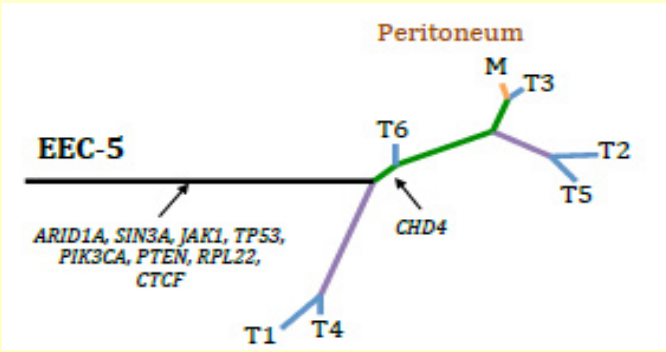
Peritoneum
M
T3
EEC-5
T6
T2
T5
ARID1A, SIN3A, JAK1, TP53,
PIK3CA, PTEN, RPL22,
CTCF
CHD4
T1
T4

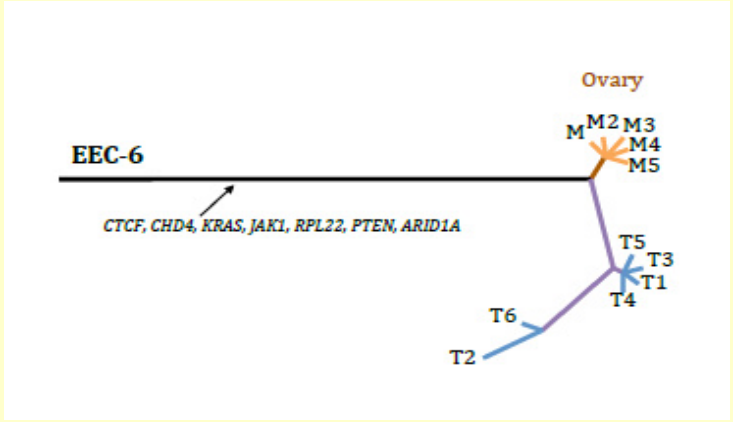
Ovary
EEC-6
M
M2
M3
M4
M5
CTCF, CHD4, KRAS, JAK1, RPL22, PTEN, ARID1A
T5
T3
T1
T4
T6
T2

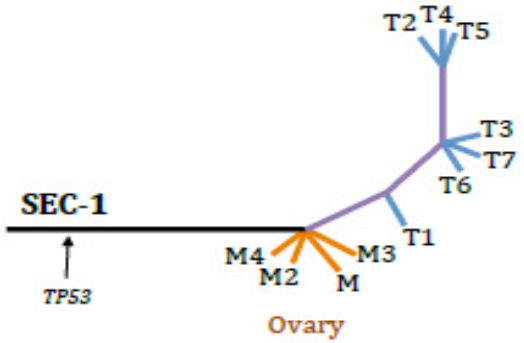
T2
T4
T5
T3
T7
T6
SEC-1
T1
M4
M2
M
M3
TP53
Ovary

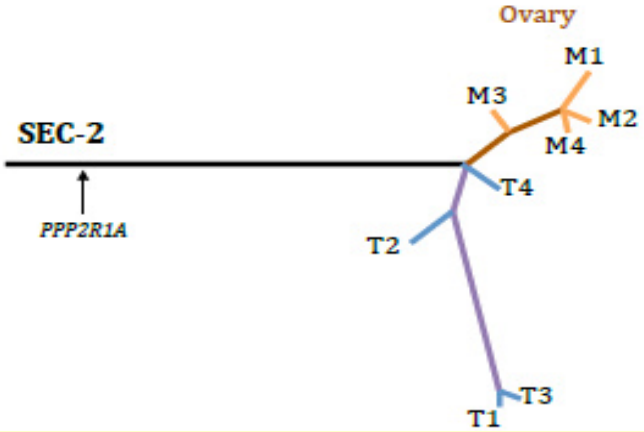
Ovary
M1
M3
M2
M4
SEC-2
T4
T2
PPP2R1A
T3
T1

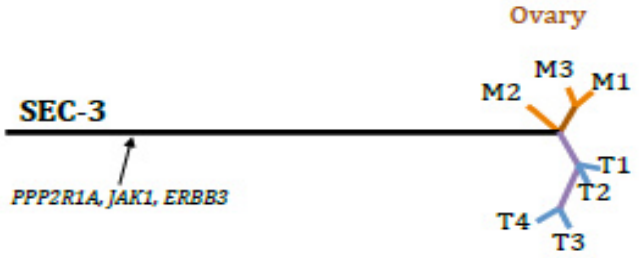
Ovary
M3
M1
M2
SEC-3
T1
T2
PPP2R1A, JAK1, ERBB3
T4
T3

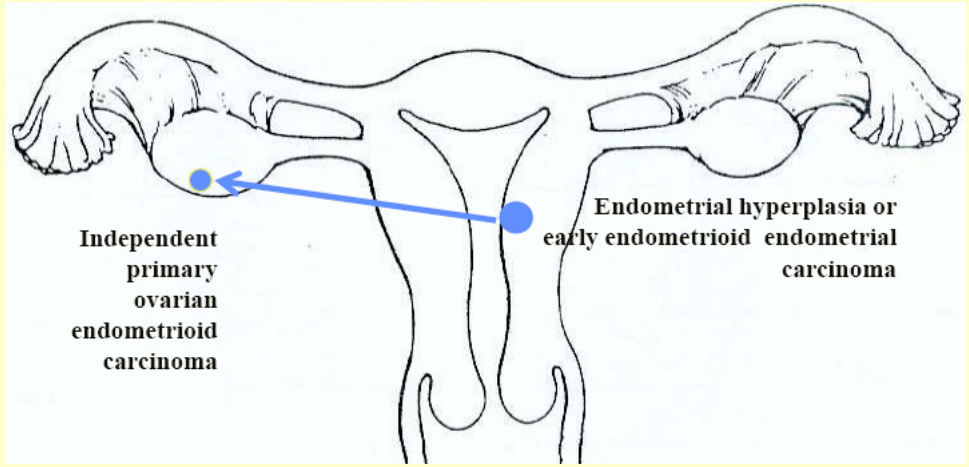
Independent primary ovarian endometrioid carcinoma
Endometrial hyperplasia or early endometrioid endometrial carcinoma

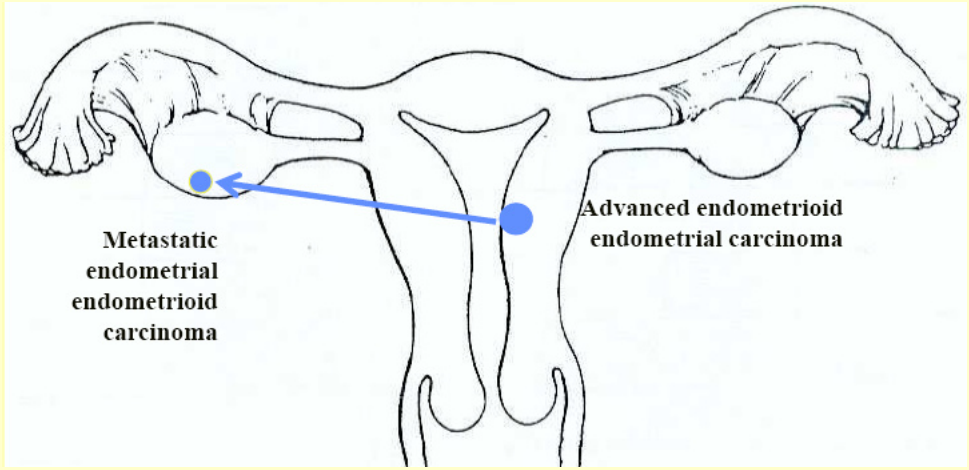
Metastatic endometrial endometrioid carcinoma
Advanced endometrioid endometrial carcinoma

Regardless of the biologic nature of the lesions, it is recommended to use Scully criteria to classify the lesions, because of its proven prognostic significance.

Simultaneous endometrioid carcinomas of the endometrium and the ovaries (Criteria)

- Tumor sizes
- Histological grades
- Bilaterality
- Pattern of tumor growth
- Tubal, myometrial, vascular invasion
- Presence of endometriosis



MOLECULAR PATHOLOGY AND BIOMARKER TESTING IN DIFERENT TYPES OF OVARIAN CARCINOMA

Xavier Matias-Guiu, MD, PhD

Hospital U Arnau de Vilanova, Univ Lleida.
IRBLLEIDA, Hospital U de Bellvitge, IDIBELL