

Slide seminar. Case 1.

Xavier Matias-Guiu, MD, PhD, Hospital U Arnau de Vilanova, Univ Lleida. IRBLLEIDA, Hospital U de Bellvitge, IDIBELL

Clinical History

- **51-year old woman with unremarcable familial and personal history. Vaginal bleeding**
- **Endometrial biopsy: High grade endometrial carcinoma, serous ca can not be excluded.**
- **Hysterectomy with bilateral salpingo-ophorectomy, sentinel biopsy and lymphadenectomy, peritoneal washings, omentectomy.**

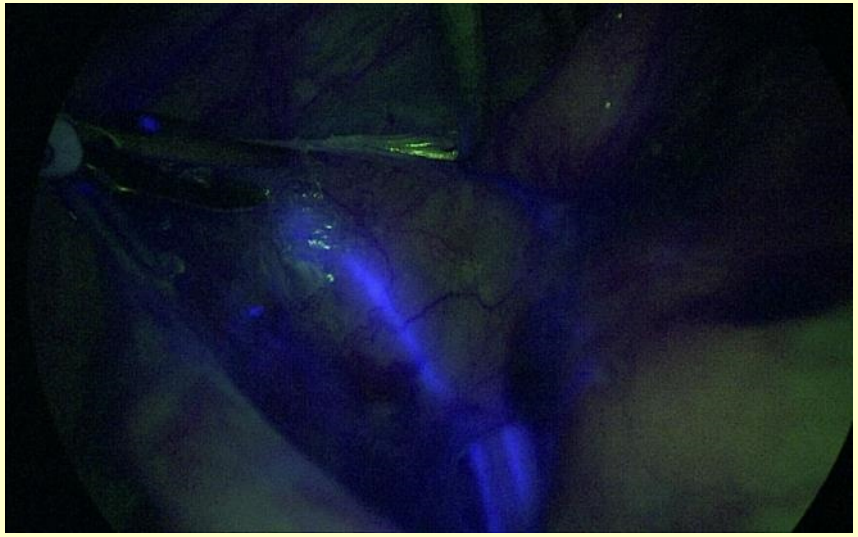

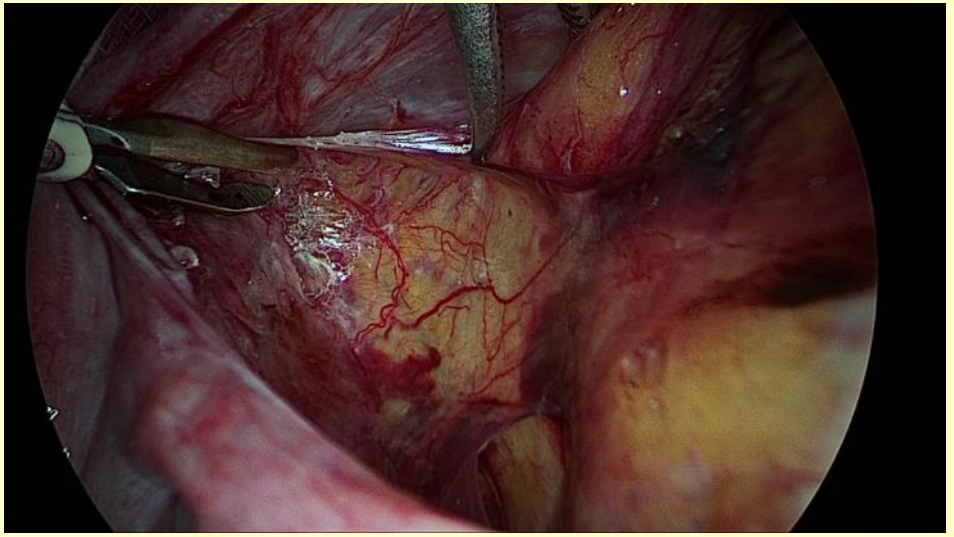

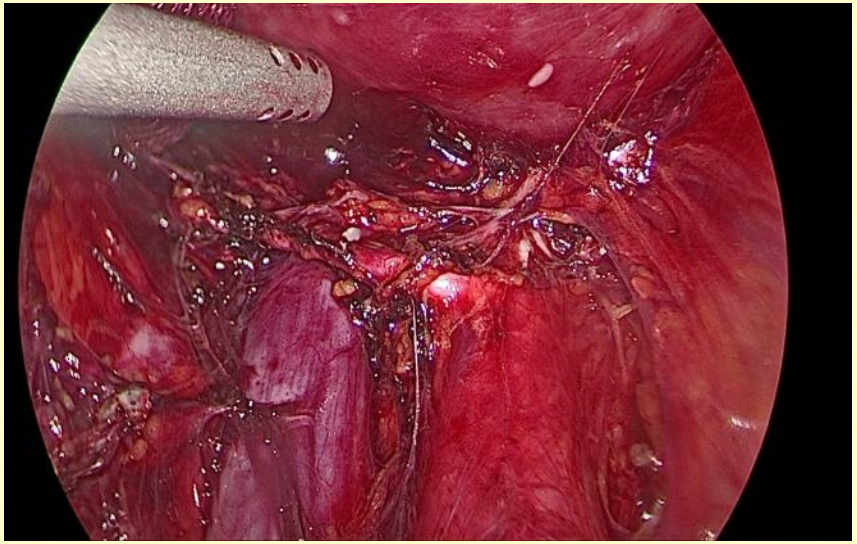

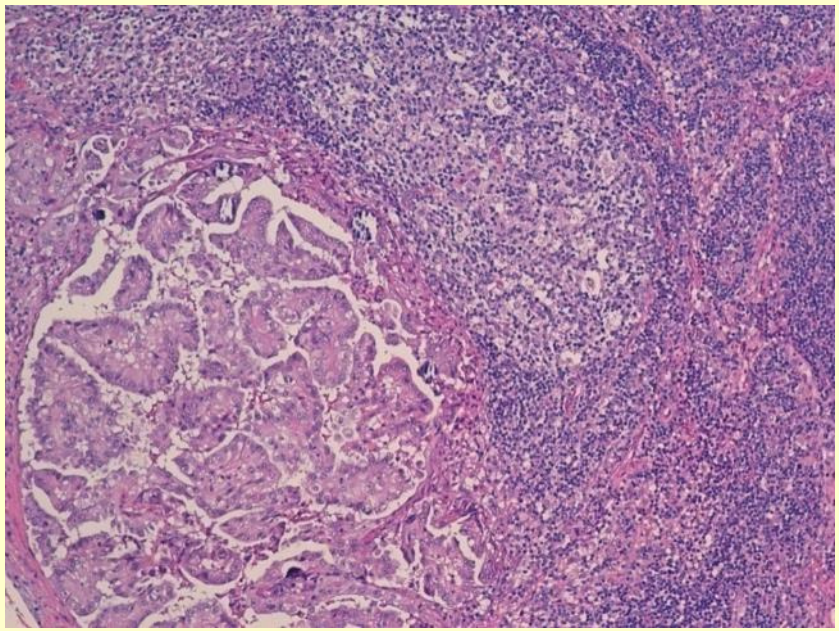

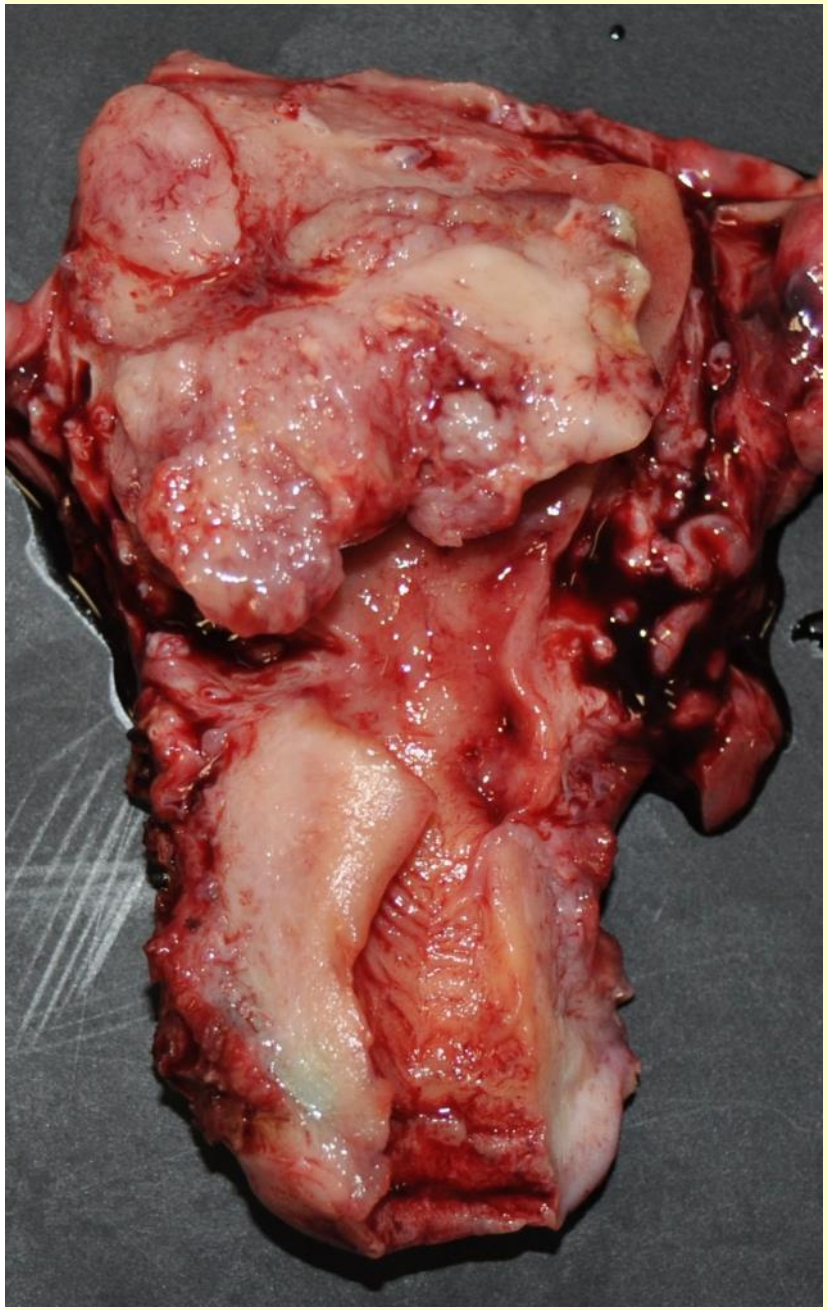

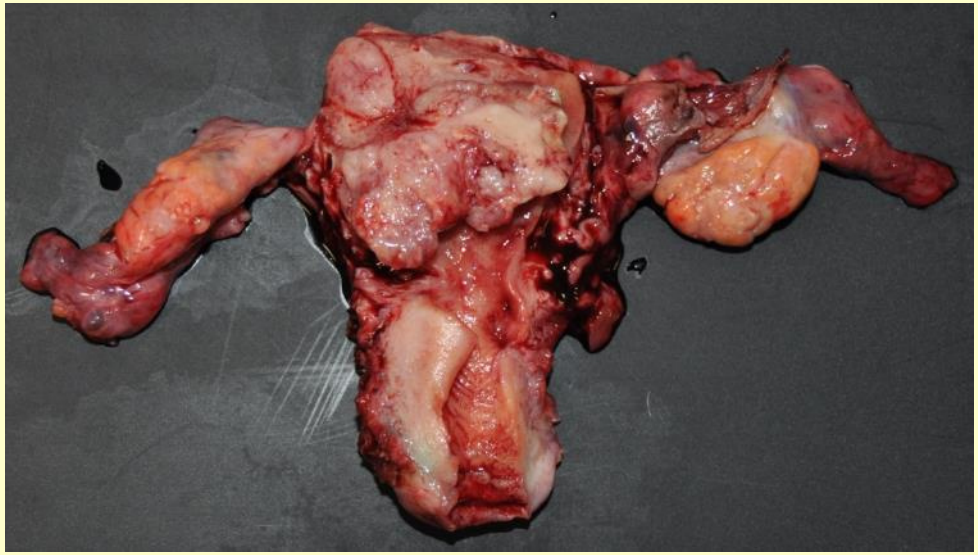

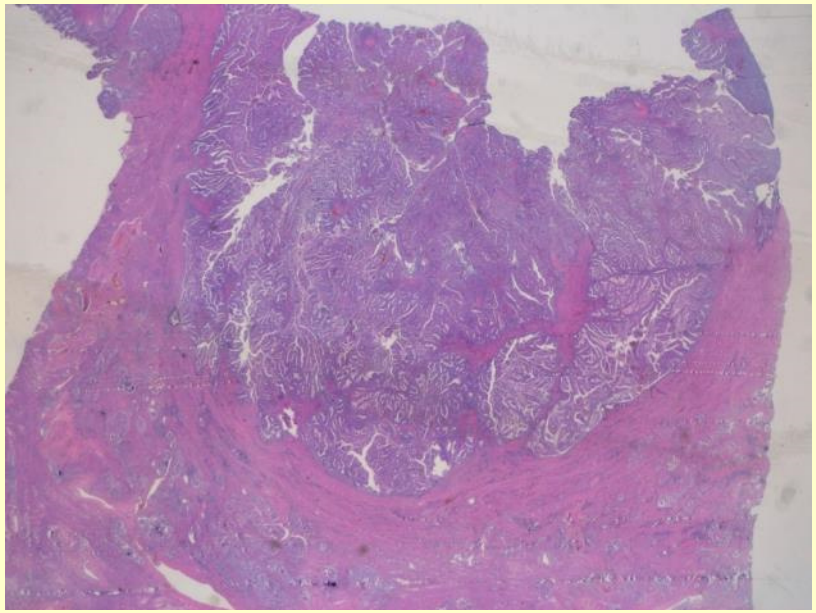

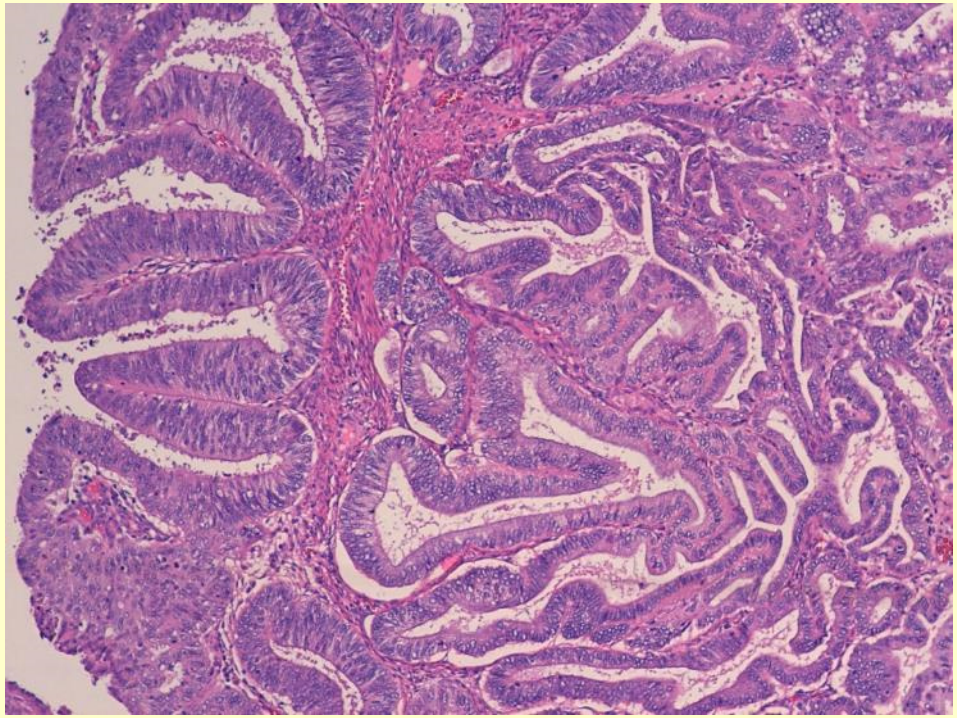

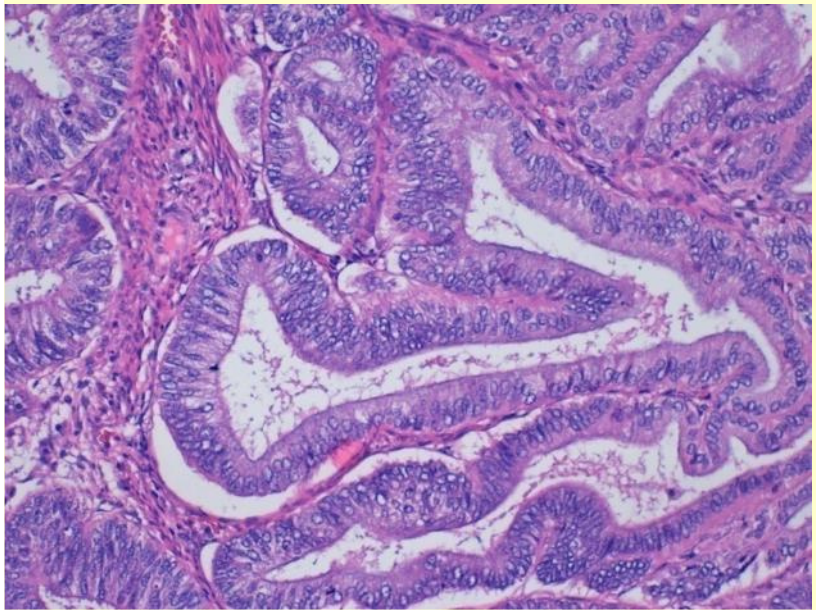

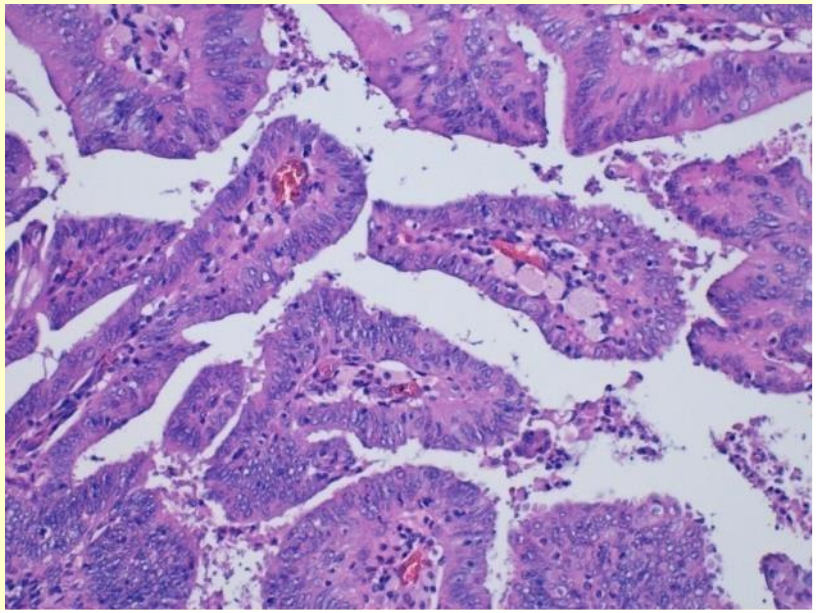

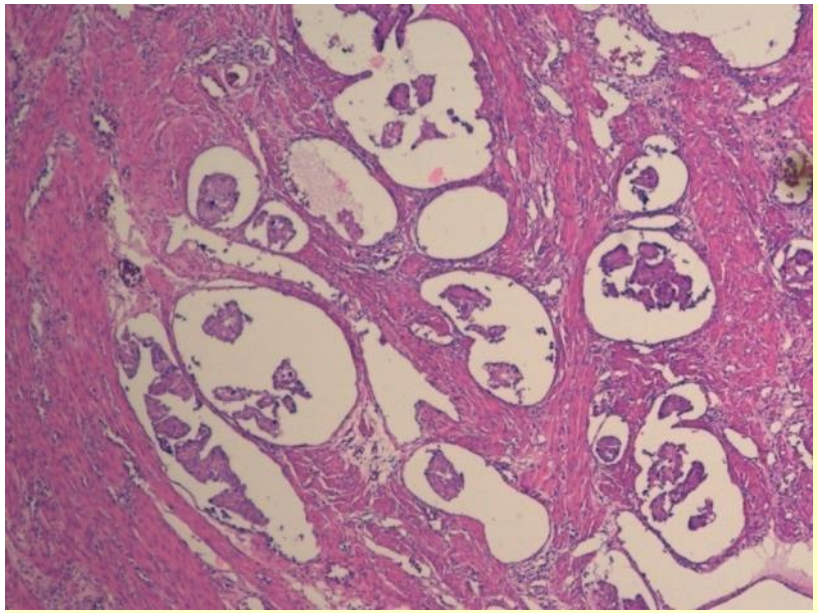

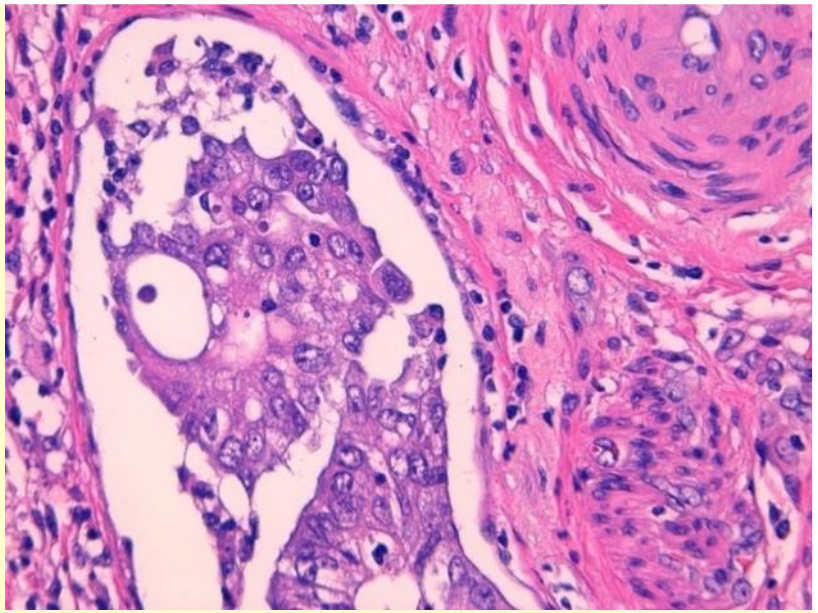

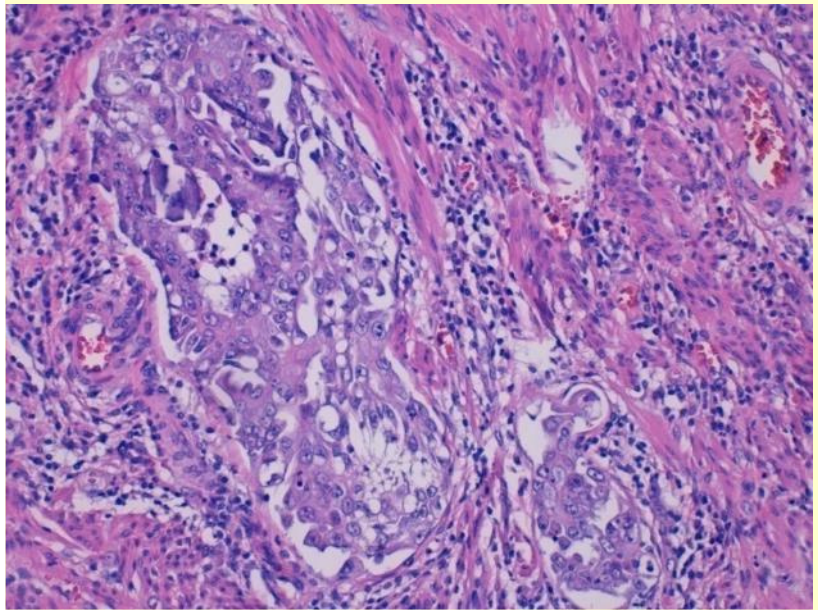

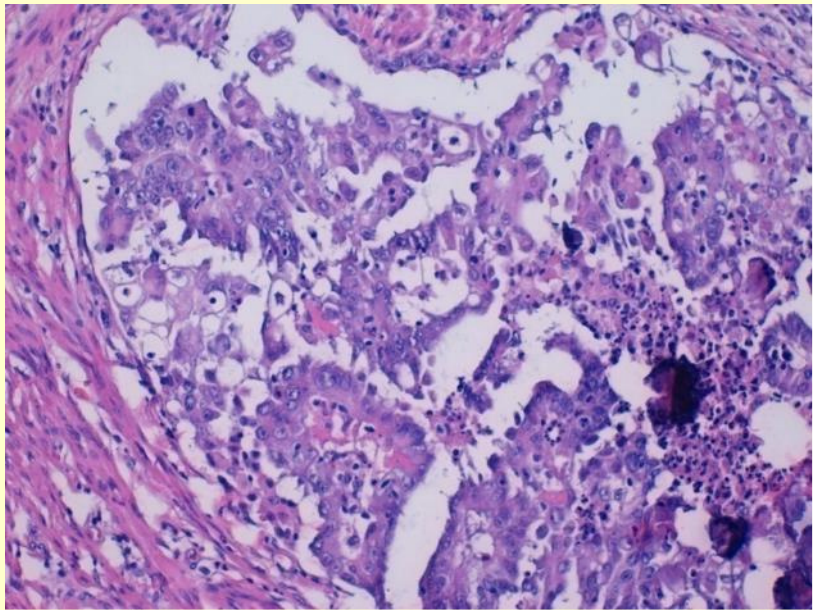

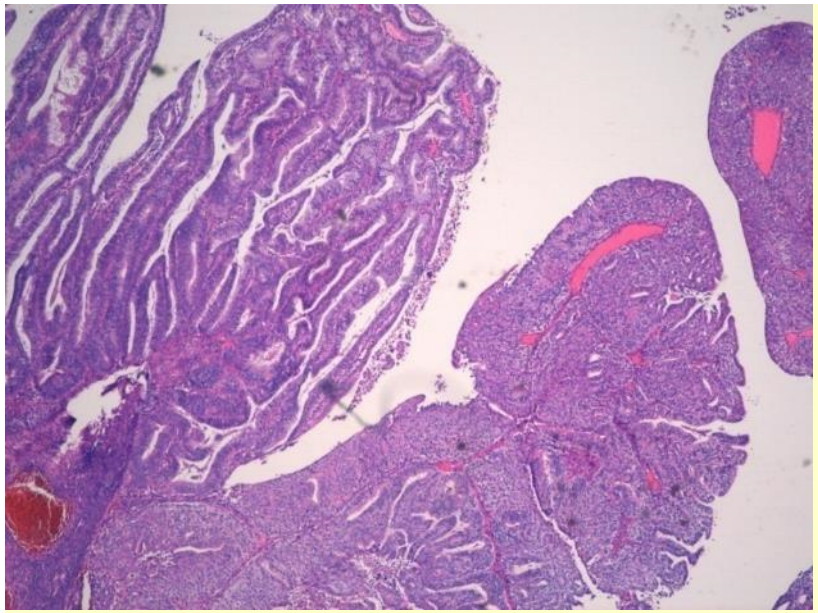

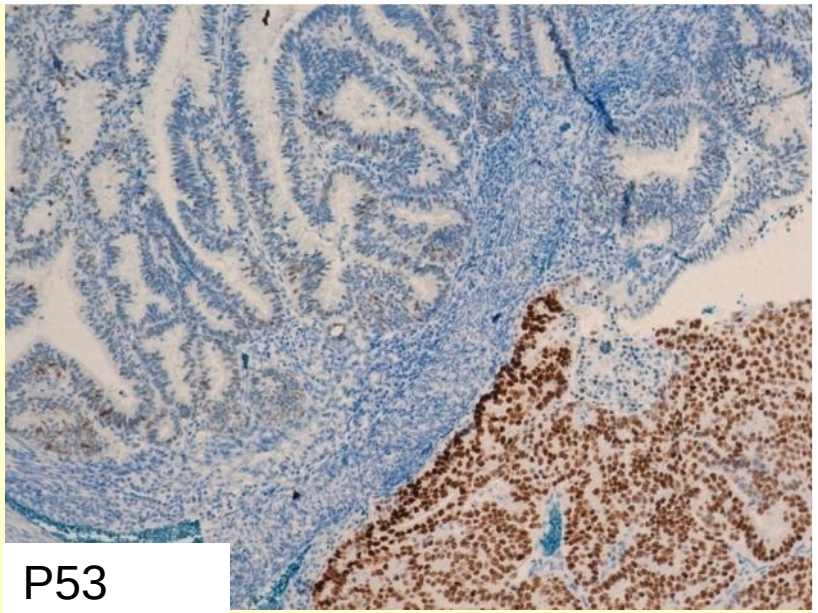

P53

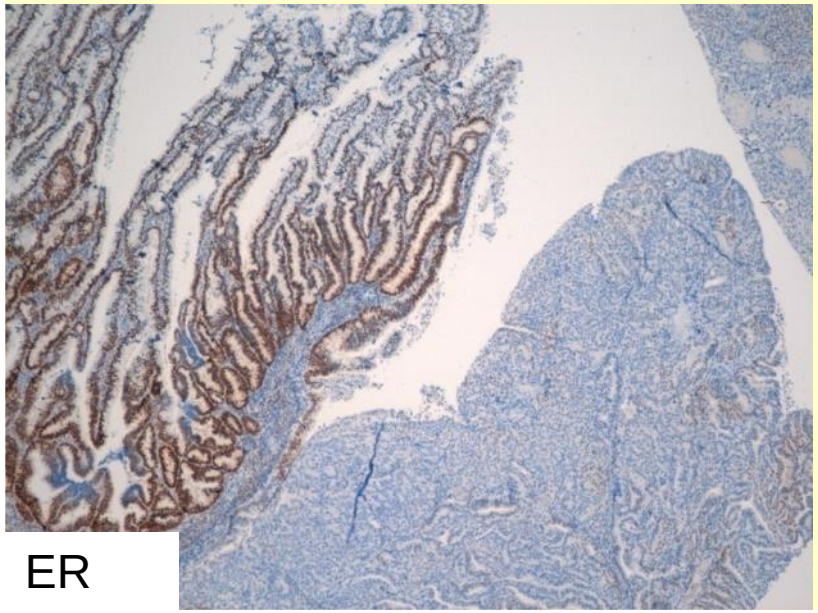

ER

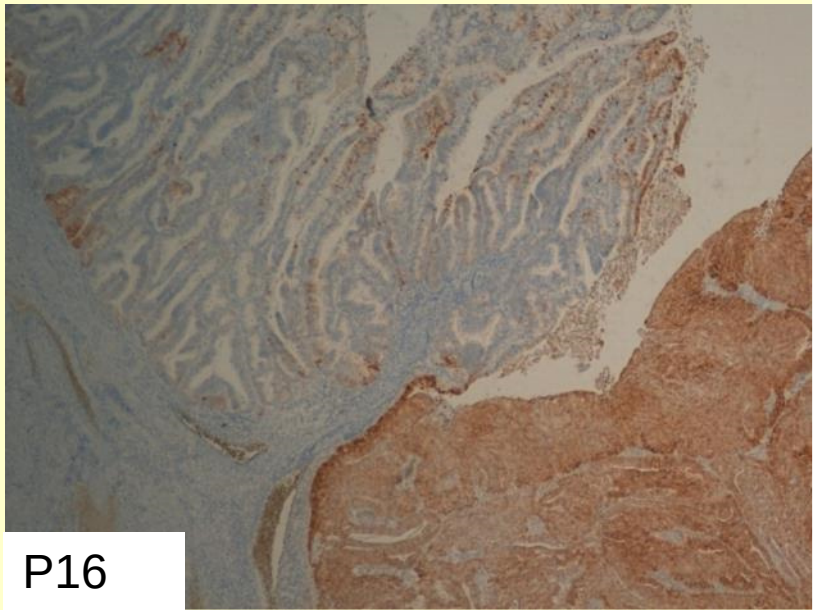

P16

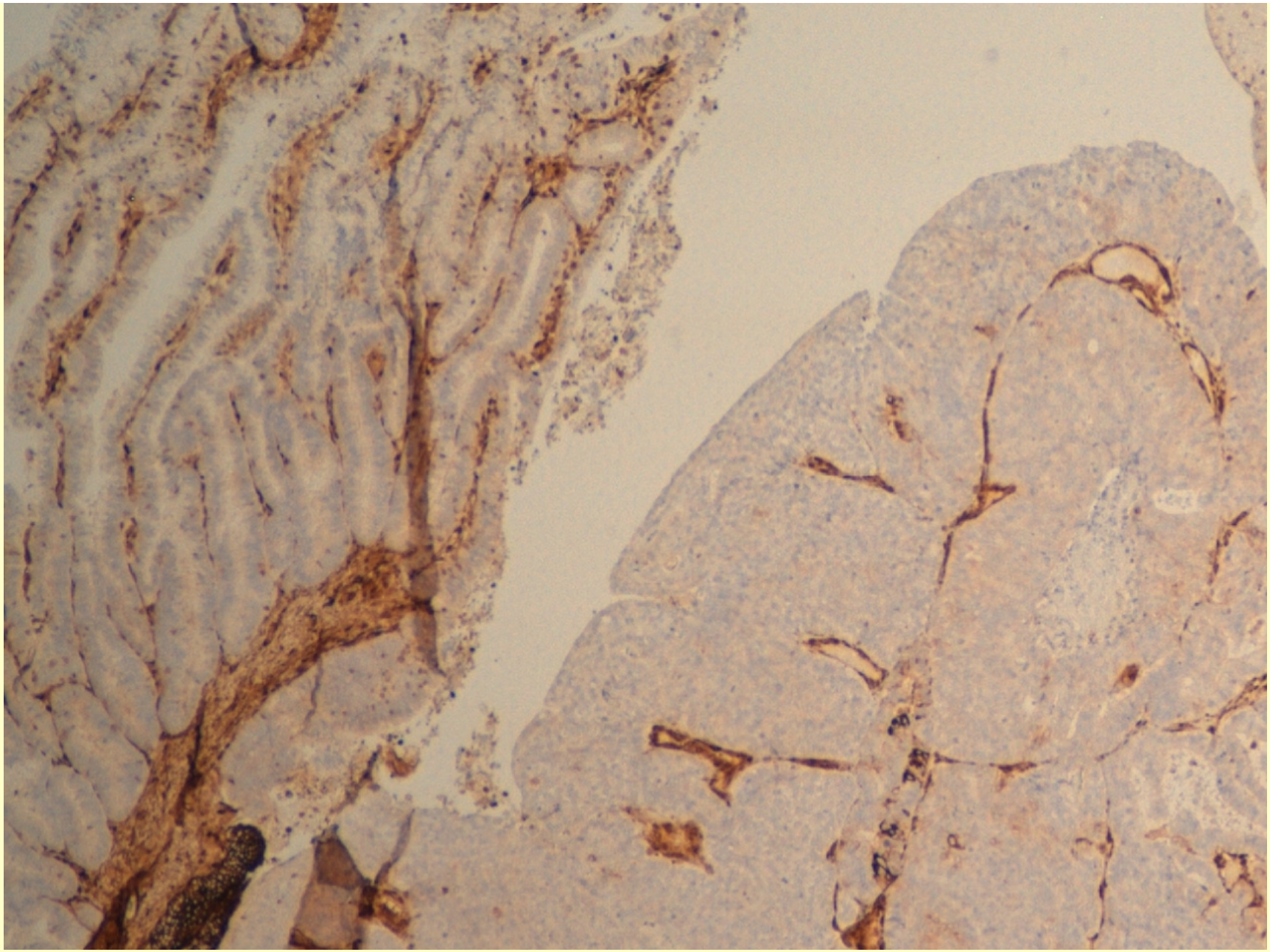

PTEN

Diagnosis

Mixed Endometrioid-Serous Carcinoma

Endometrial carcinoma (Histological Classification)

1- Endometrioid carcinoma, usual type
2- Endometrioid carcinoma variants
3- Mucinous adenocarcinoma
4- Serous carcinoma
5- Clear cell adenocarcinoma
6- Neuroendocrine carcinoma
7- Mixed carcinoma
8- Undifferentiated carcinoma

Carcinosarcoma

WHO 2014

MIXED ENDOMETRIOID-NON ENDOMETRIOID CARCINOMAS

- **Unfrequent**

- **Diagnosis should be made with caution and rigor, because some of them are just serous carcinomas with glandular pattern of growth.**

- **Proportion of the minor component has not been well established (5%, 10%, 25%)**

- **Vast majority clonal, some may be bi-clonal.**

- **Molecular and immunohistochemical features poorly understood.**

Differential Diagnosis

- **Endometrioid carcinomas with mixed conventional and papillary patterns**
- **Endometrioid carcinoma with surface changes**
- **High grade Endometrioid carcinomas with heterogeneous features (POLE-mutated, MSI)**
- **Serous carcinoma with mixed conventional and glandular patterns**

Endometrioid carcinoma with papillary pattern

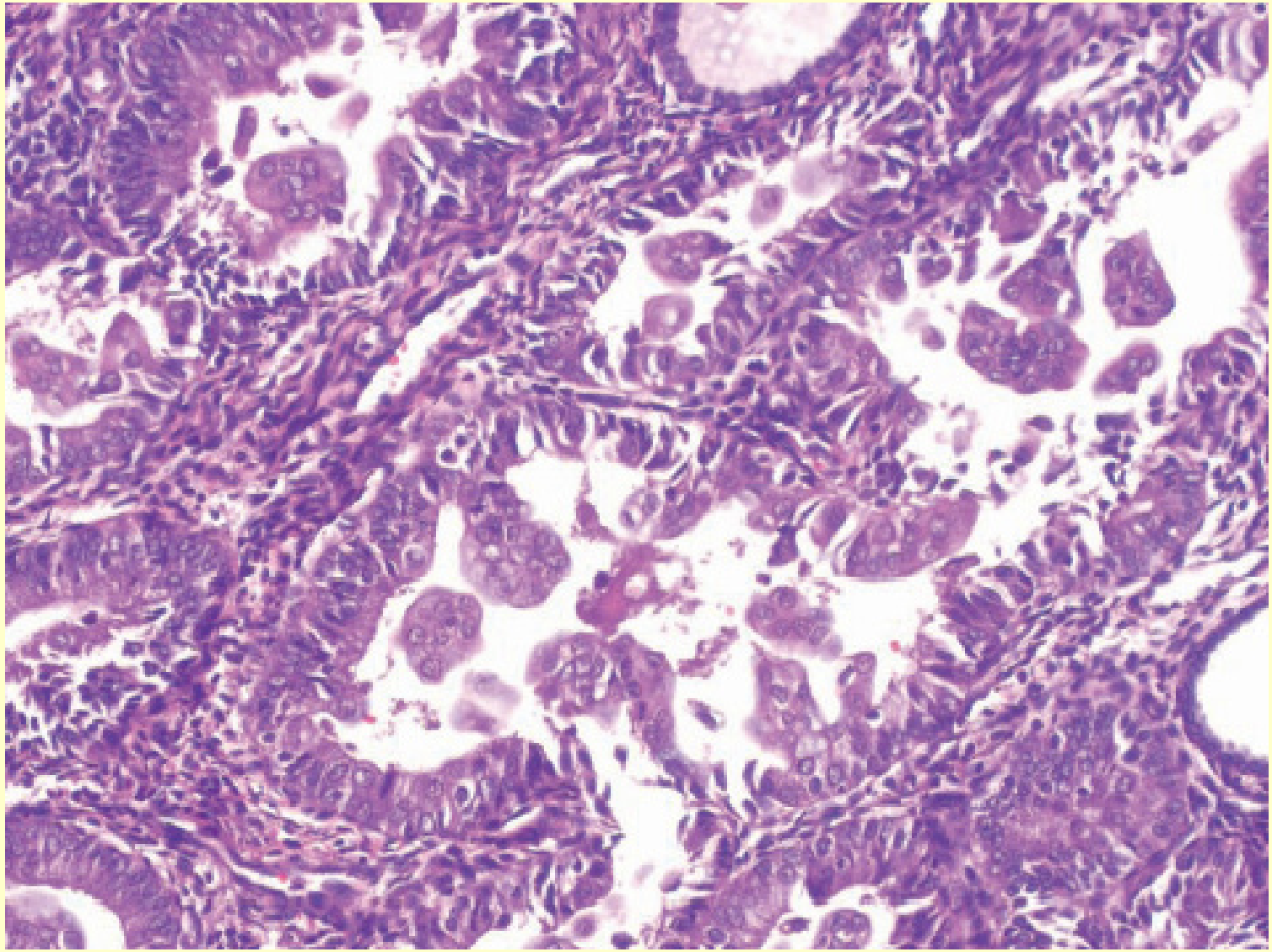

Singh *et al. Diagnostic Pathology* 2011, **6**:13
http://www.diagnosticpathology.org/content/6/1/13

DIAGNOSTIC PATHOLOGY

CASE REPORT Open Access

"Surface epithelial changes" in uterine endometrioid carcinoma mimicking micropapillary serous borderline tumor of ovary: report of two cases and review of the literature

Kamaljeet Singh[1], Rochelle A Simon[2], Cunxian Zhang[2], M Ruhul Quddus[2*]

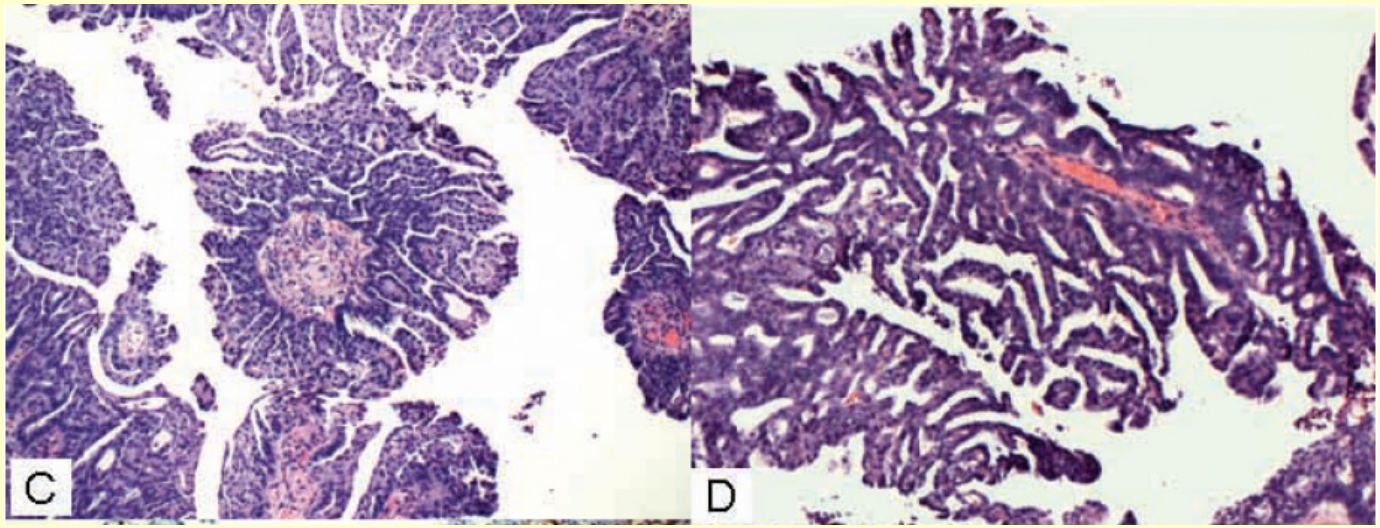

Endometrioid carcinoma with surface changes

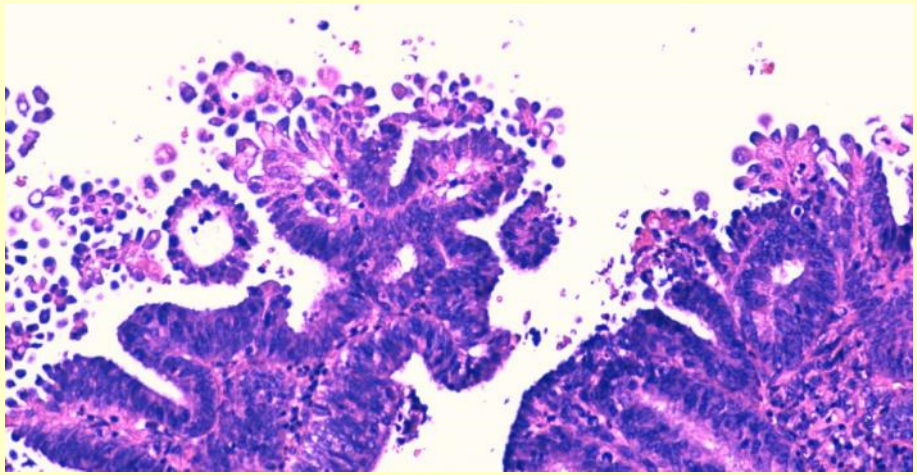

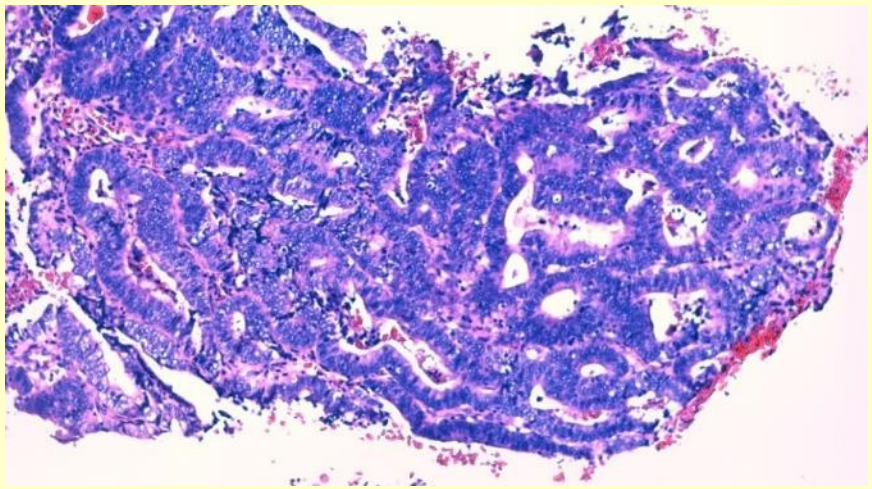

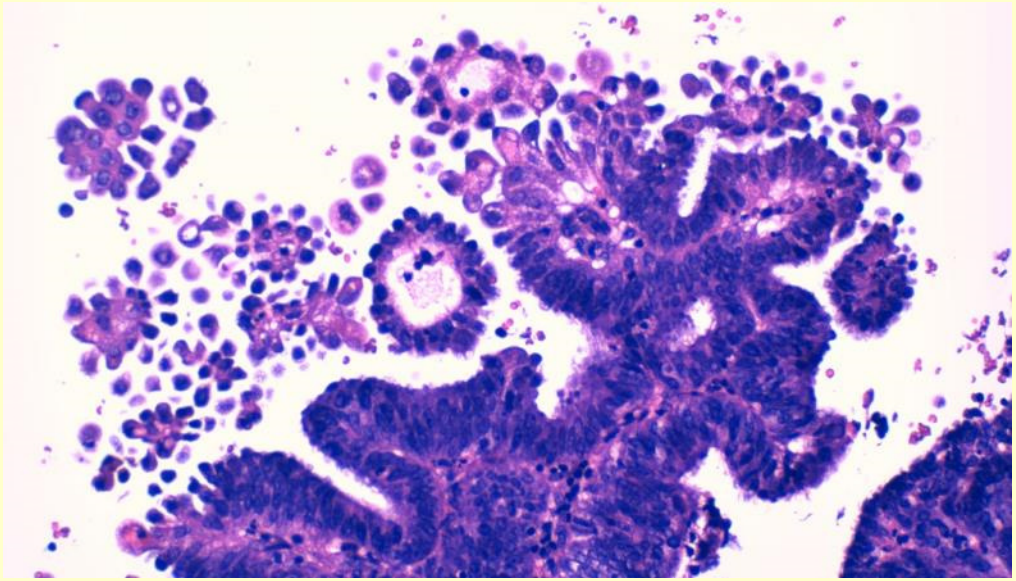

Heterogenous POLE-mutated EC

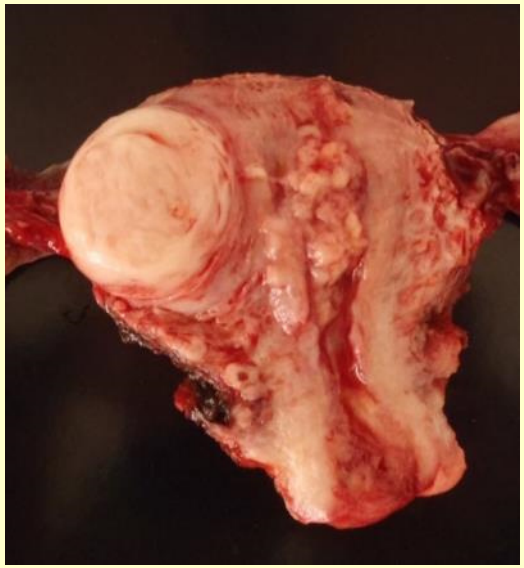

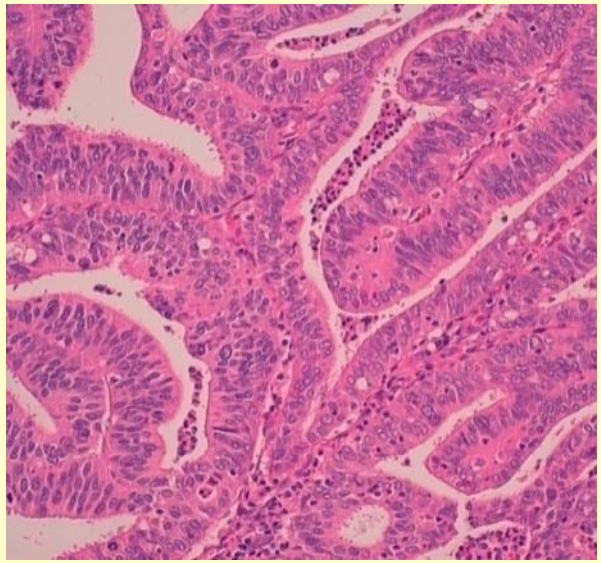

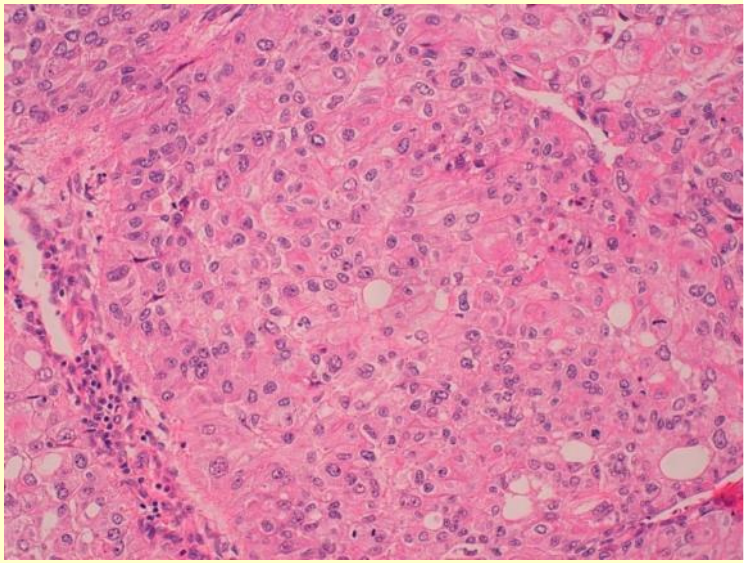

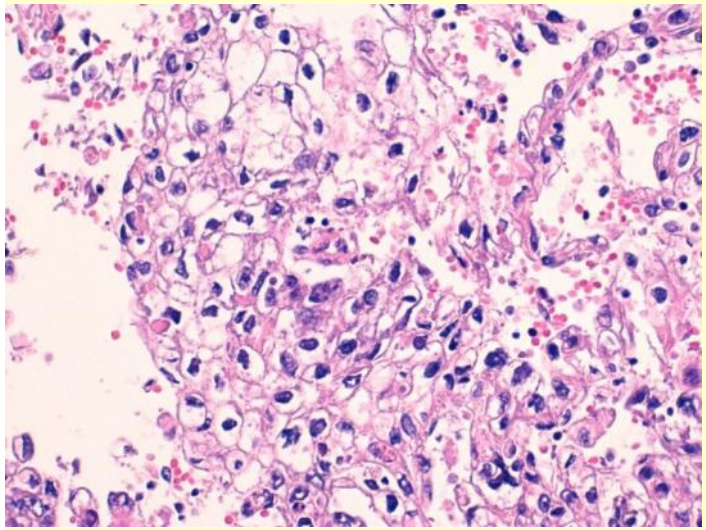

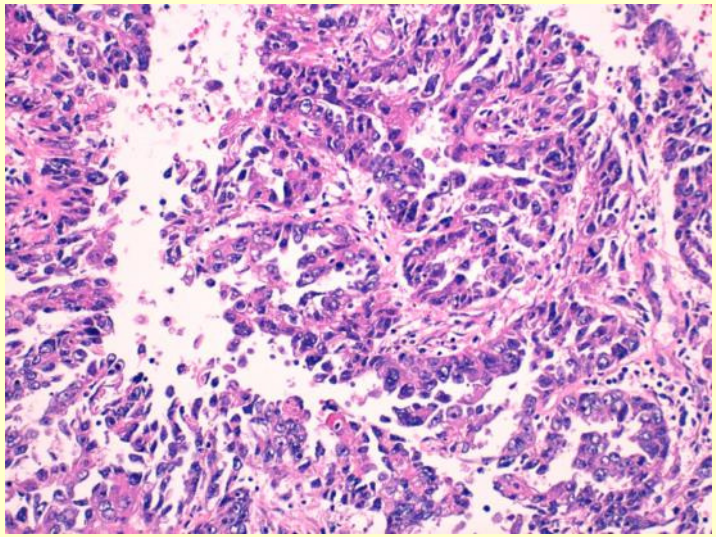

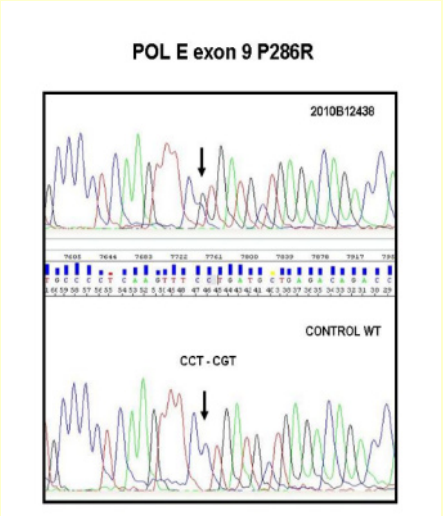

Serous carcinoma with glandular pattern
Discordant architecture/cytology

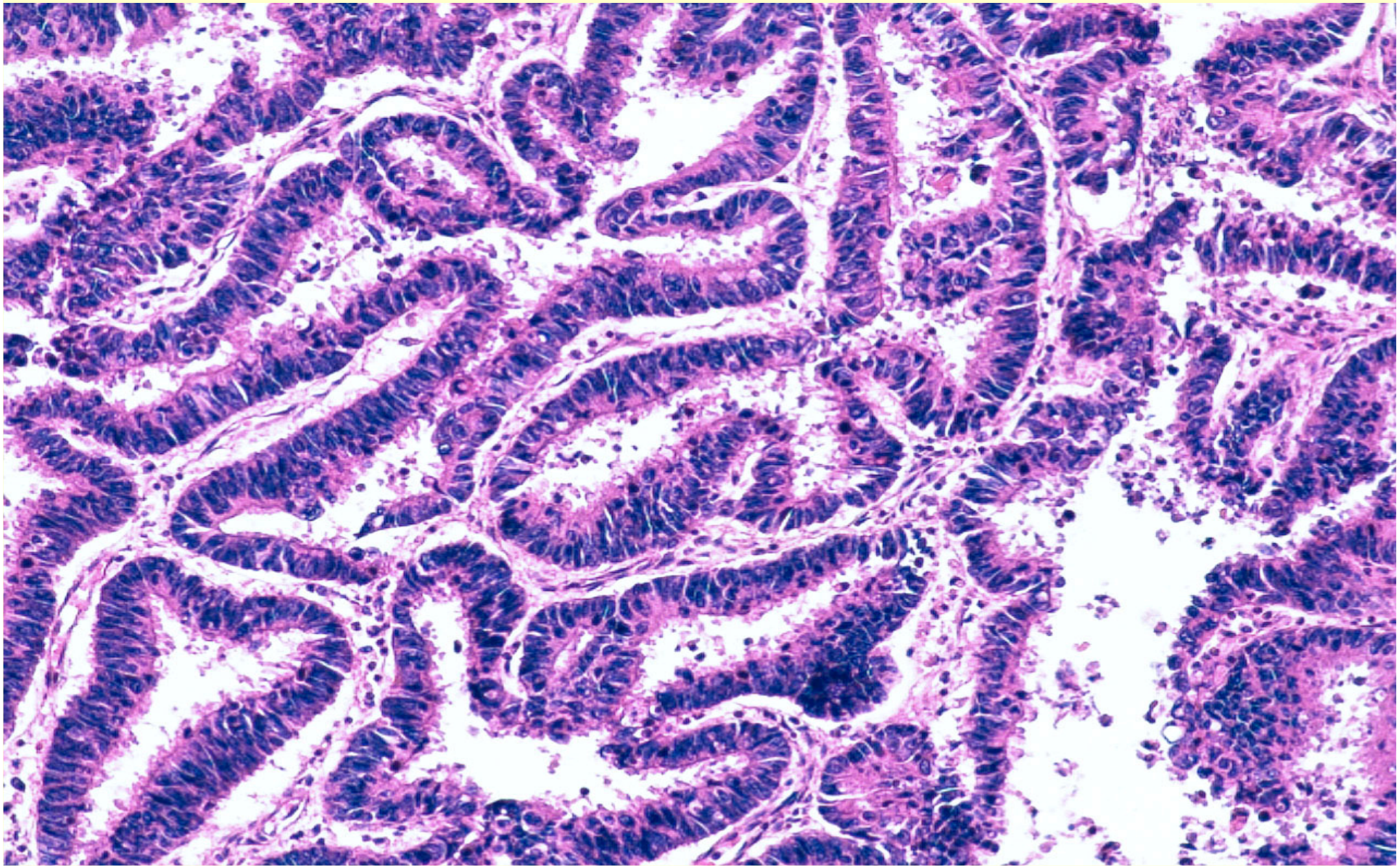

TUMOR HETEROGENEITY IN EC

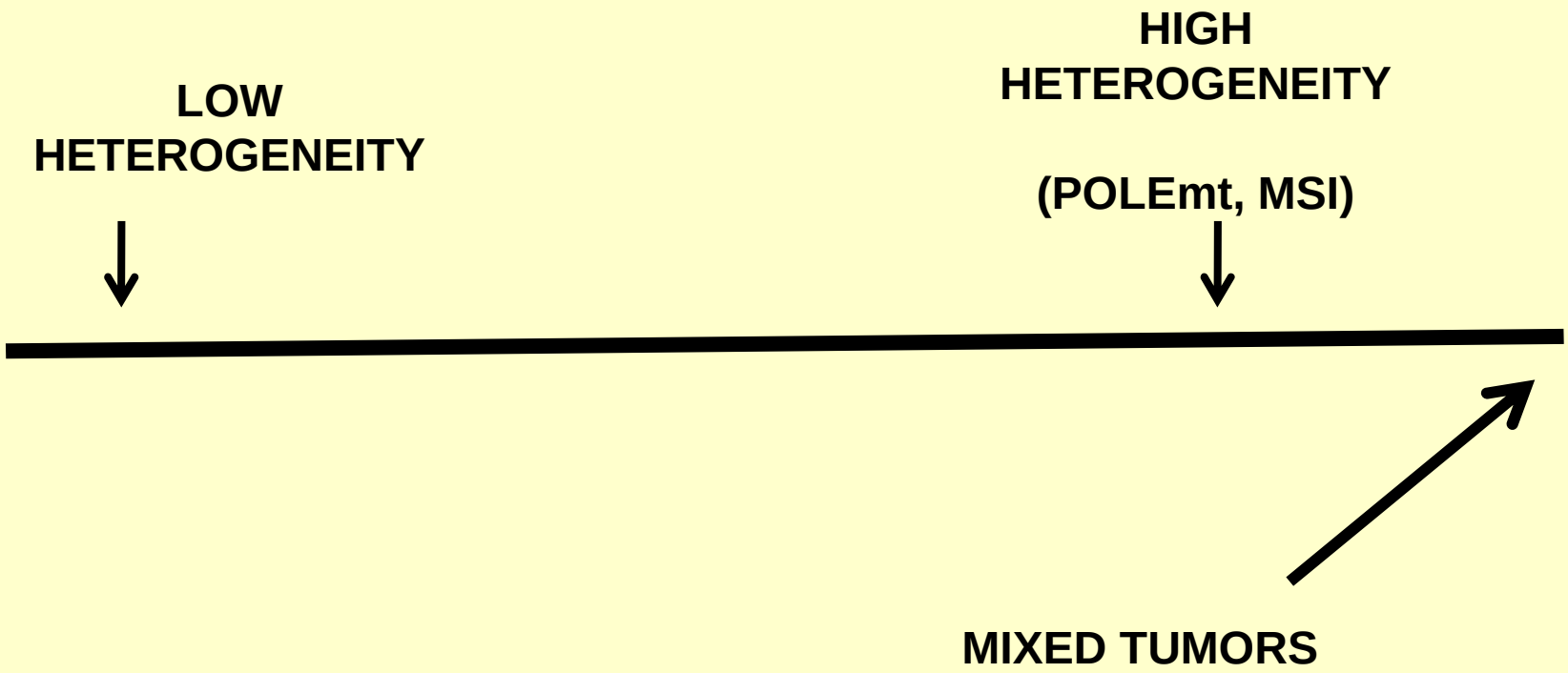

Virchows Arch (2015) 466:415–422
DOI 10.1007/s00428-015-1728-5

ORIGINAL ARTICLE

Mutation profile and clinical outcome of mixed endometrioid-serous endometrial carcinomas are different from that of pure endometrioid or serous carcinomas

L. Coenegrachts · D. A. Garcia-Dios · J. Depreeuw · M. Santacana · S. Gatius · M. Zikan · P. Moerman · L. Verbist · D. Lambrechts · Xavier Matias-Guiu · Frédéric Amant

Gene mutations in endometrioid endometrial carcinoma

GENE	FREQUENCY	GENE	FREQUENCY
PTEN *	77.7%	*MLL4*	9.1%
PIK3CA	53.1%	*BCOR*	8.0%
PIK3R1	37.1%	*ATR*	6.9%
CTNNB1	36.6%	*CCND1*	5.7%
ARID1A	35.4%	*SPOP*	5.7%
KRAS	24.6%	*SIN3A*	5.7%
CTCF	20.6%	*MKI67*	5.7%
RPL22	12.6%	*FBXW7*	5.1%
TP53	11.4%	*FOXA2*	5.1%
FGFR2	10.9%	*NRAS*	2.9%
ARID5B	10.9%		

***62/136 (45.5%) tumors with PTEN mutations has ≥ 2 mutations**

TCGA; Nature 2013

Gene mutations in serous endometrial carcinoma

GENE	FREQUENCY	GENE	FREQUENCY
TP53	90.7%	*PRPF18*	7%
PIK3CA	41.9%	*SPOP*	7%
FBXW7	30.2%	*CDH19*	7%
PPP2R1A	36.6%	*FGFR2*	7%
CHD4	16.3%	*ARID1A*	7%
GSMD3	11.6%	*FOXA2*	1.6%
COLA11	11.6%	*USP36*	4.6%

TCGA; Nature 2013

TAF1 (30%), ***EP300*** (8%), ***TSPYL2*** (6%), ***MAP3K4*** (6%) and ***ABCC9*** (6%).

Khun et al; J Natl Cancer Inst 2012.
Le Collo et al; Nat Genet 2012;
Zhao et al; PNAS 2013.

	EEC in mixed	Pure EEC	SC in mixed	Pure SC
KRAS	14.7%	17.0%	17.9%	8.6%
PTEN	11.8 %	19.6%	7.1%	2.9%
p53	8.8%	1.7%	14.3%	17.1%
PIK3CA	26.5%	13.5%	25.0%	14.3%

	EEC in mixed	Pure EEC	SC in mixed	Pure SC
KRAS	14.7%	17.0%	17.9%	8.6%
PTEN	11.8 %	19.6%	7.1%	2.9%
p53	8.8%	1.7%	14.3%	17.1%
PIK3CA	26.5%	13.5%	25.0%	14.3%

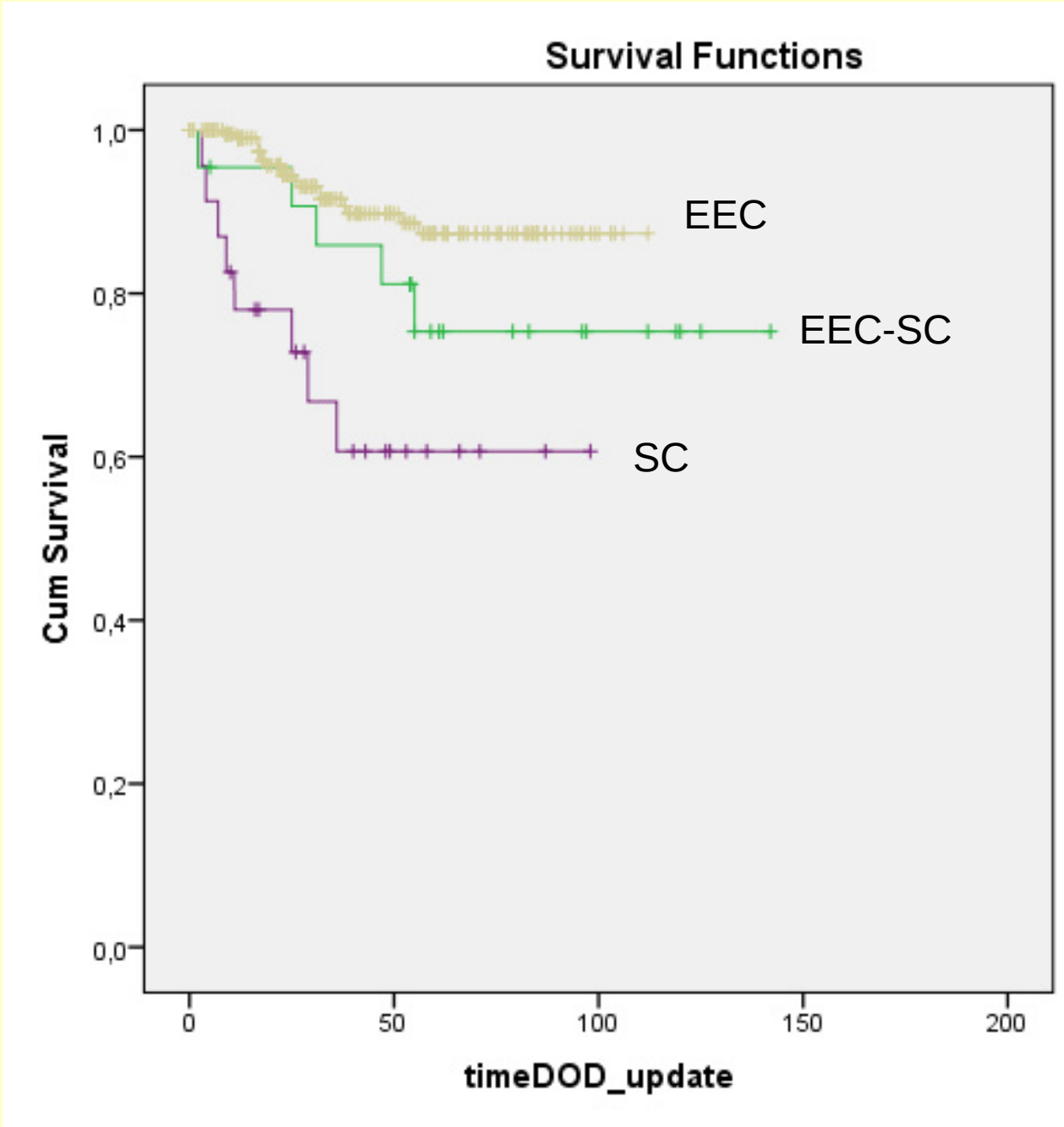
Survival Functions
1,0
0,8
0,6
0,4
0,2
0,0
Cum Survival
EEC
EEC-SC
SC
0
50
100
150
200
timeDOD_update

MIXED ENDOMETRIOID-NON ENDOMETRIOID CARCINOMAS

- **They are good examples to study tumor progression. Patient derixed orthoxenograft in immunocompromised mice may be an interesting tool.**

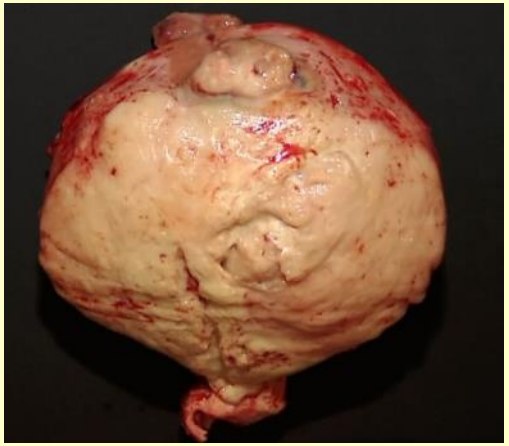

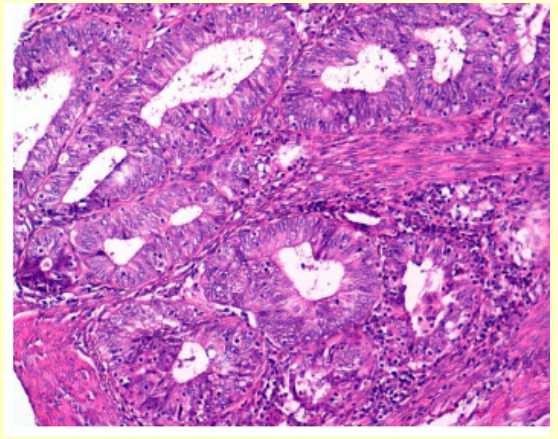

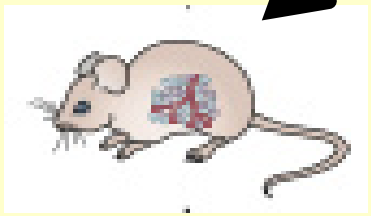

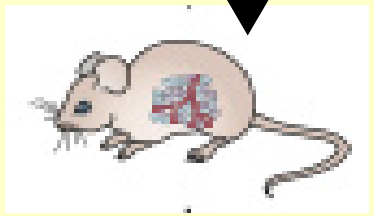

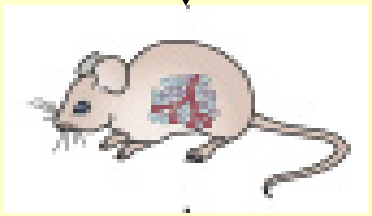

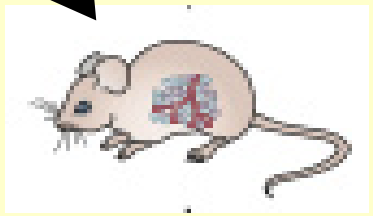

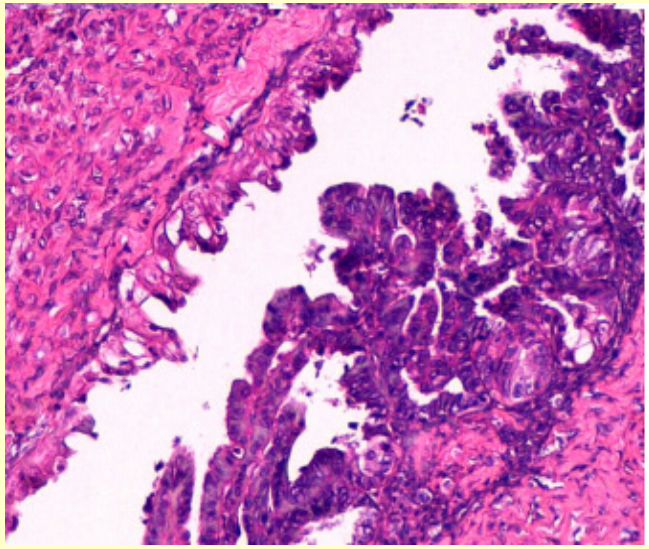

PRIMARY TUMOR EEC

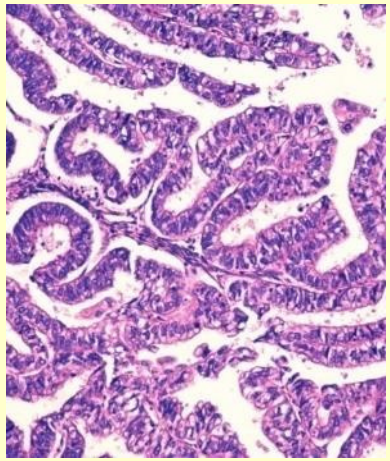
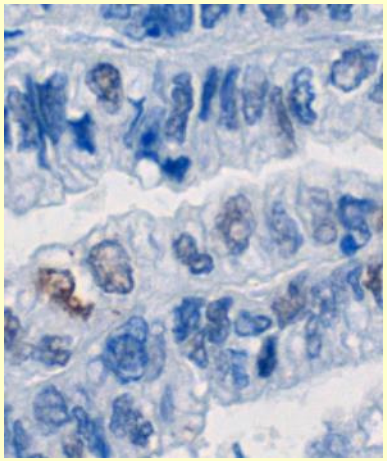
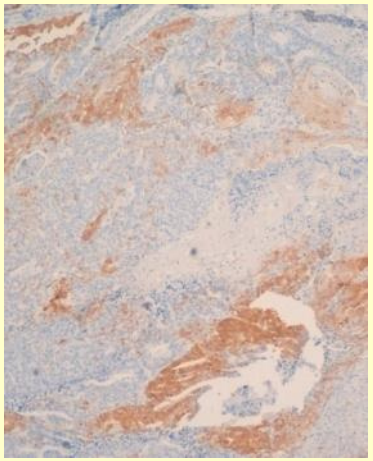
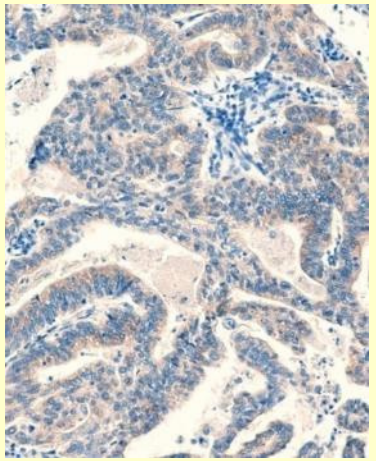
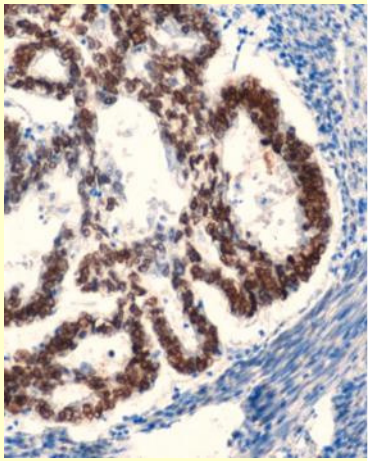

p53 p16 IMP2 ER

ORTHOXENOGRAFT TUMOR SC

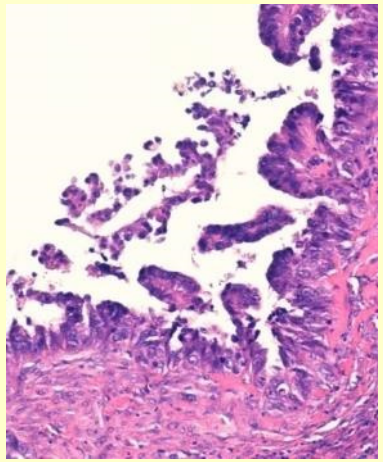
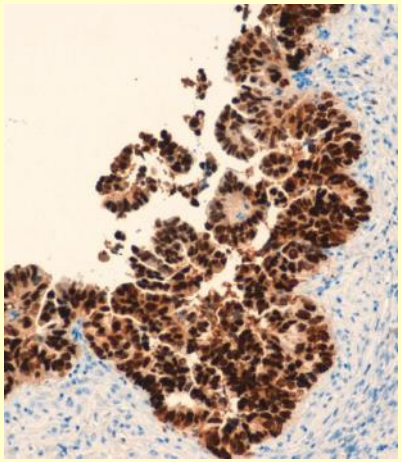
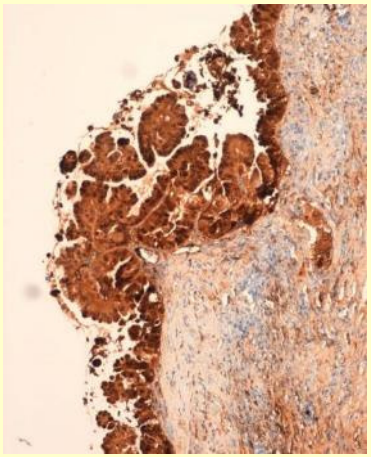
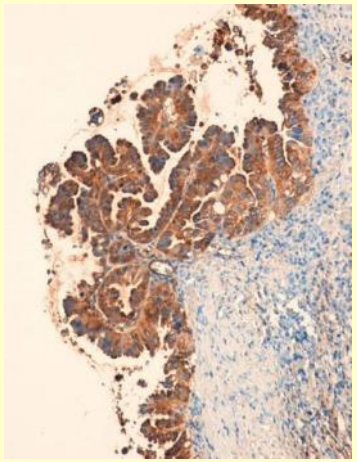
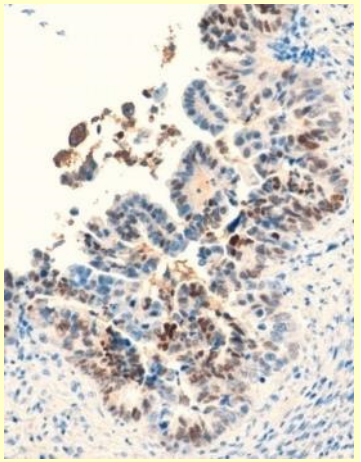

p53 p16 IMP2 ER

PDX tumor SC

Primary tumor EEC

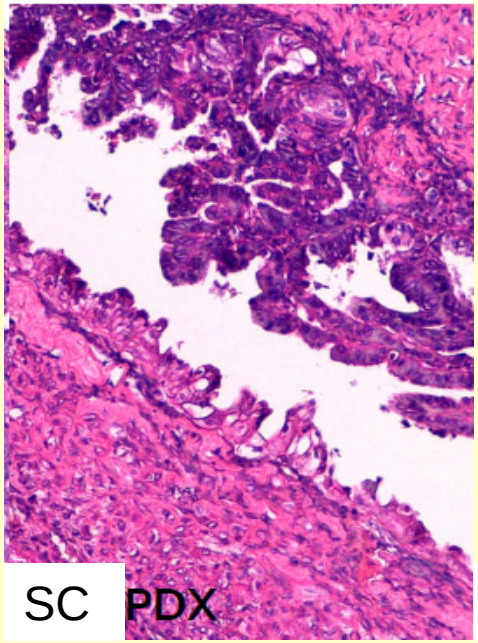

SC PDX

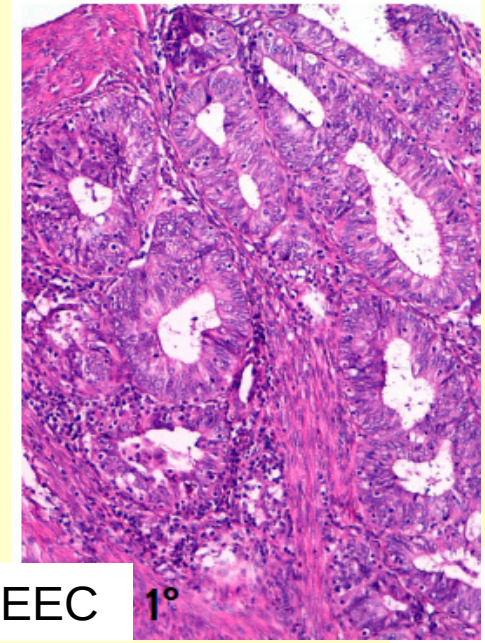

EEC 1°



Take Home messages

- **Be rigurous with the diagnosis of mixed tumors, and exclude mimics.**

- **Mixed Tumors are good examples to explore the mechanisms of tumor progression**



Slide seminar. Case 1.

Xavier Matias-Guiu, MD, PhD, Hospital U Arnau de Vilanova, Univ Lleida. IRBLLEIDA, Hospital U de Bellvitge, IDIBELL



Slide seminar. Case 2

Xavier Matias-Guiu,

Hospital U Arnau de Vilanova, University of Lleida, IRBLLEIDA

Hospital U de Bellvitge

Clinical History

- 52 year old woman
- Vaginal bleeding
- Endometrial Biopsy: Undifferentiated tumor.
- Histerectomy and bilateral salpingoophorectomy with pelvic and paraaortic lymphadenectomy

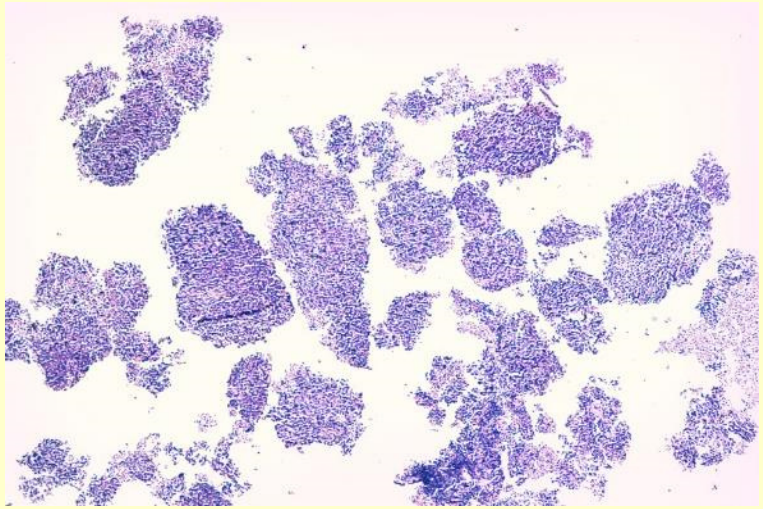

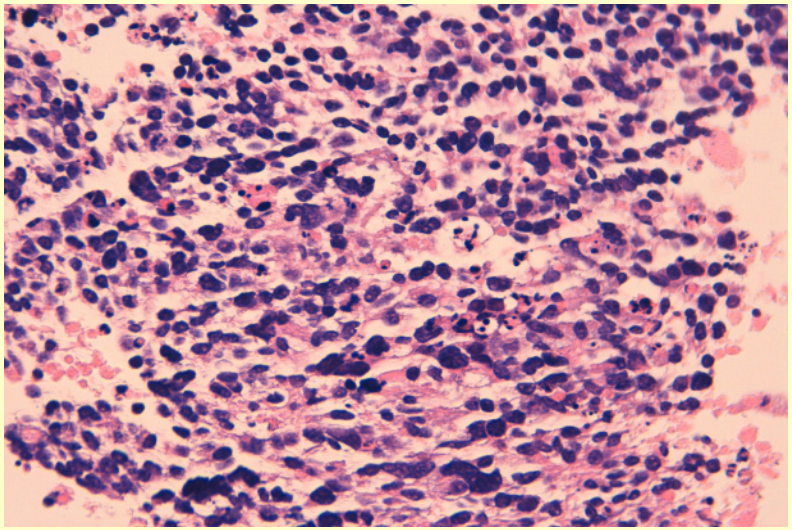

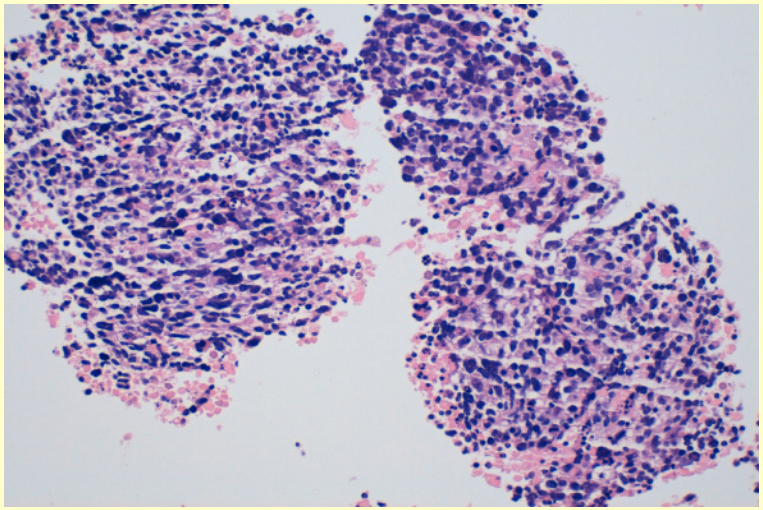

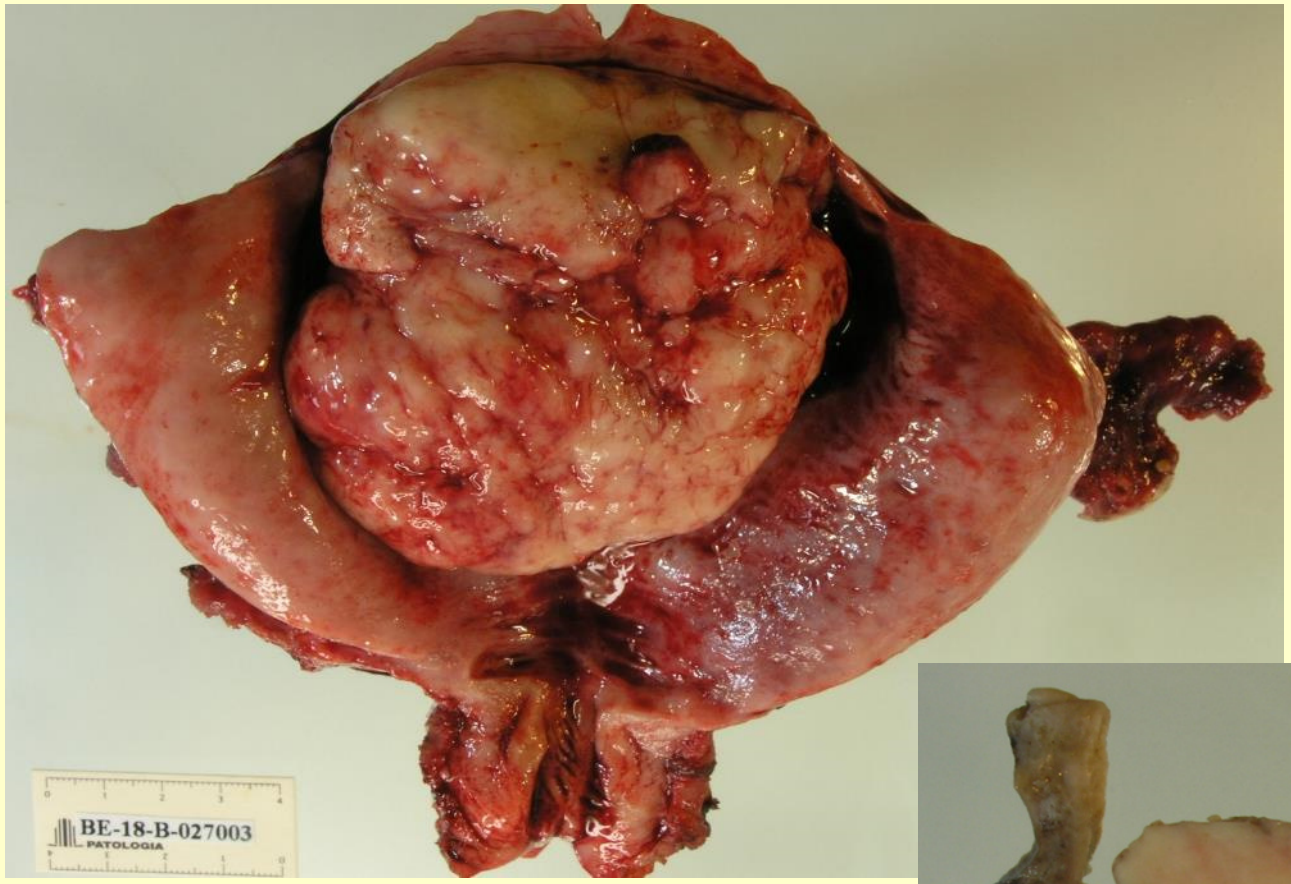
BE-18-B-027003
PATOLOGIA

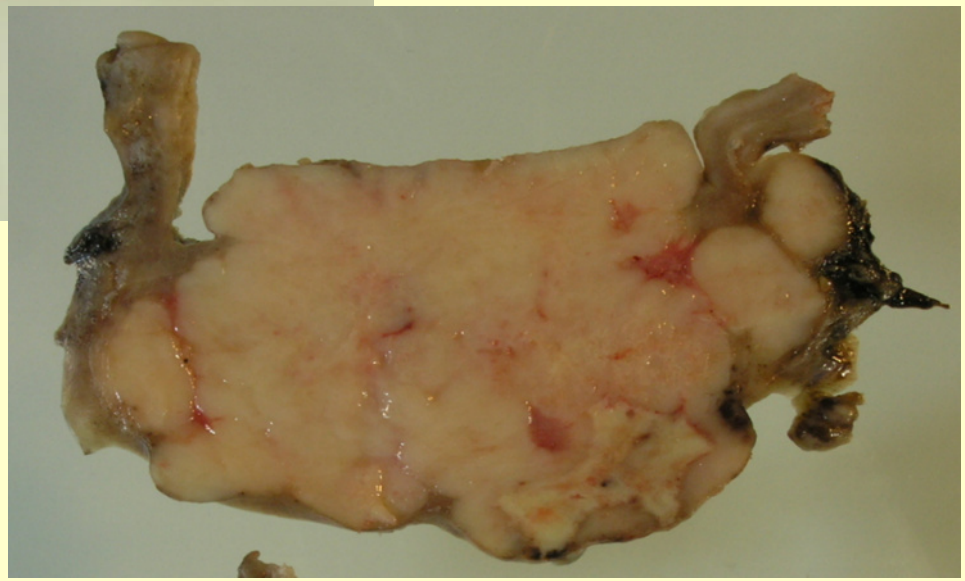

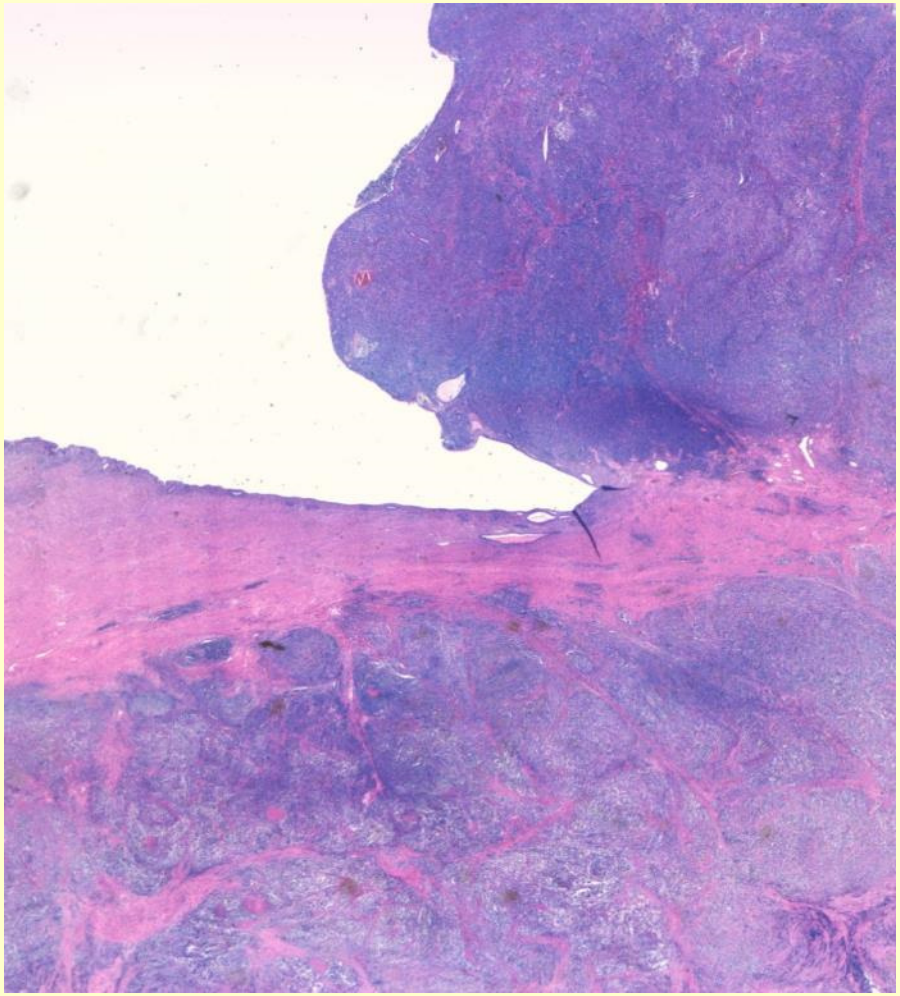

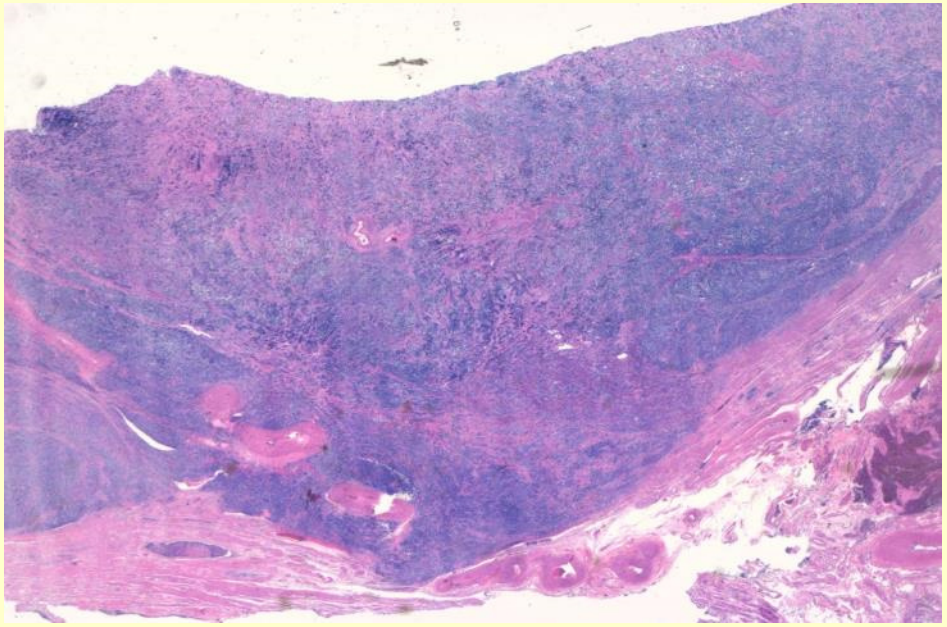

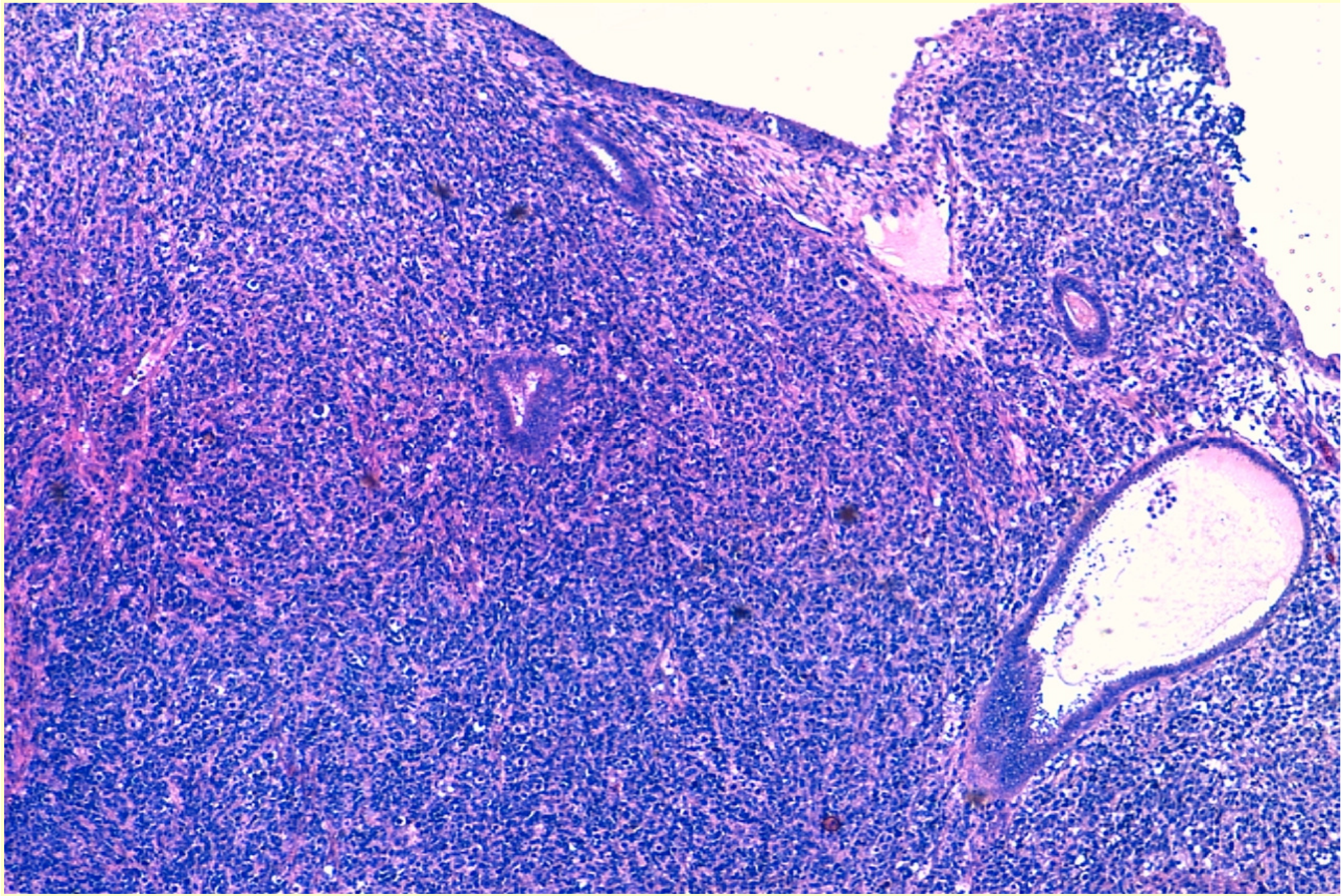

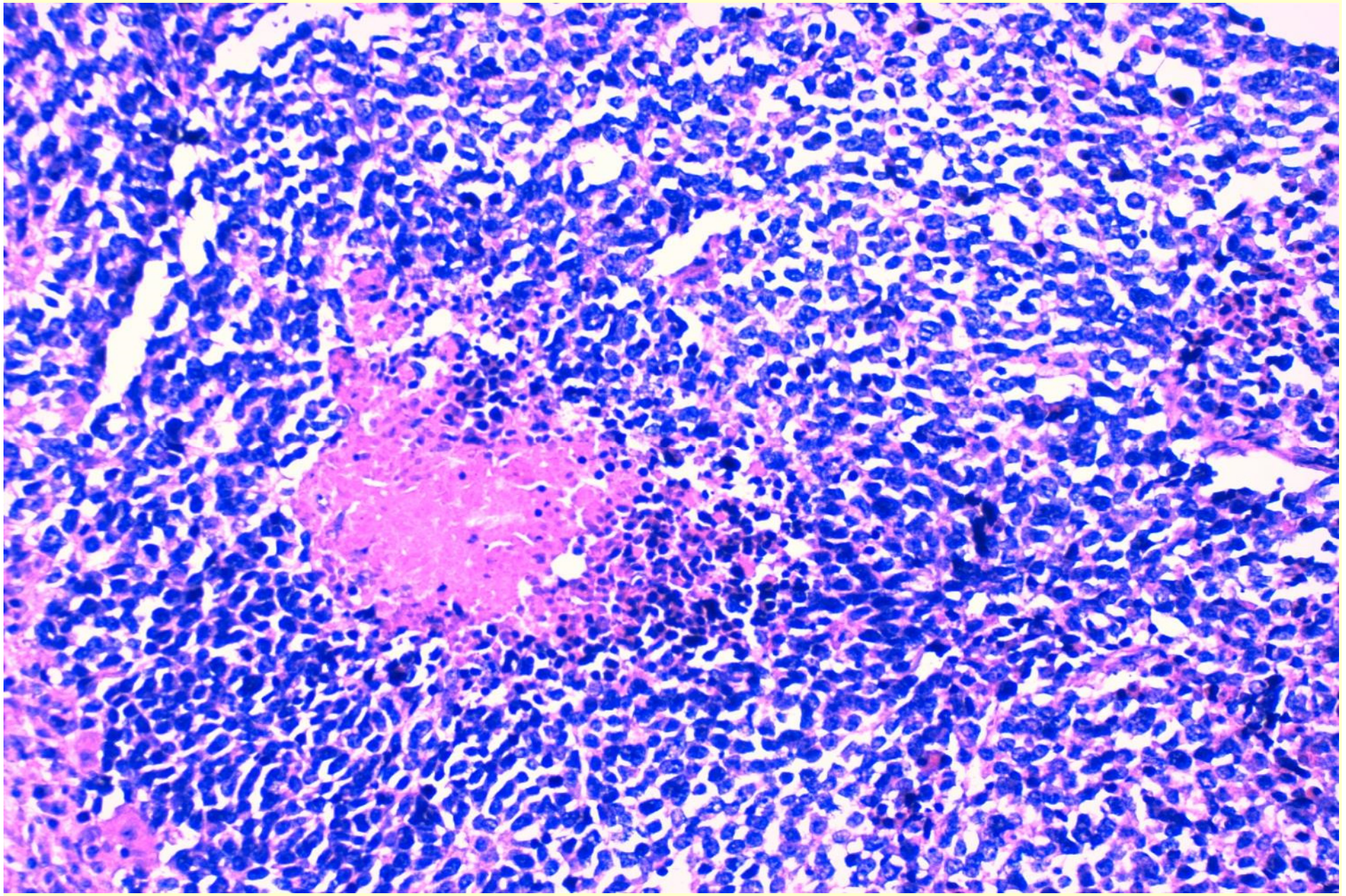

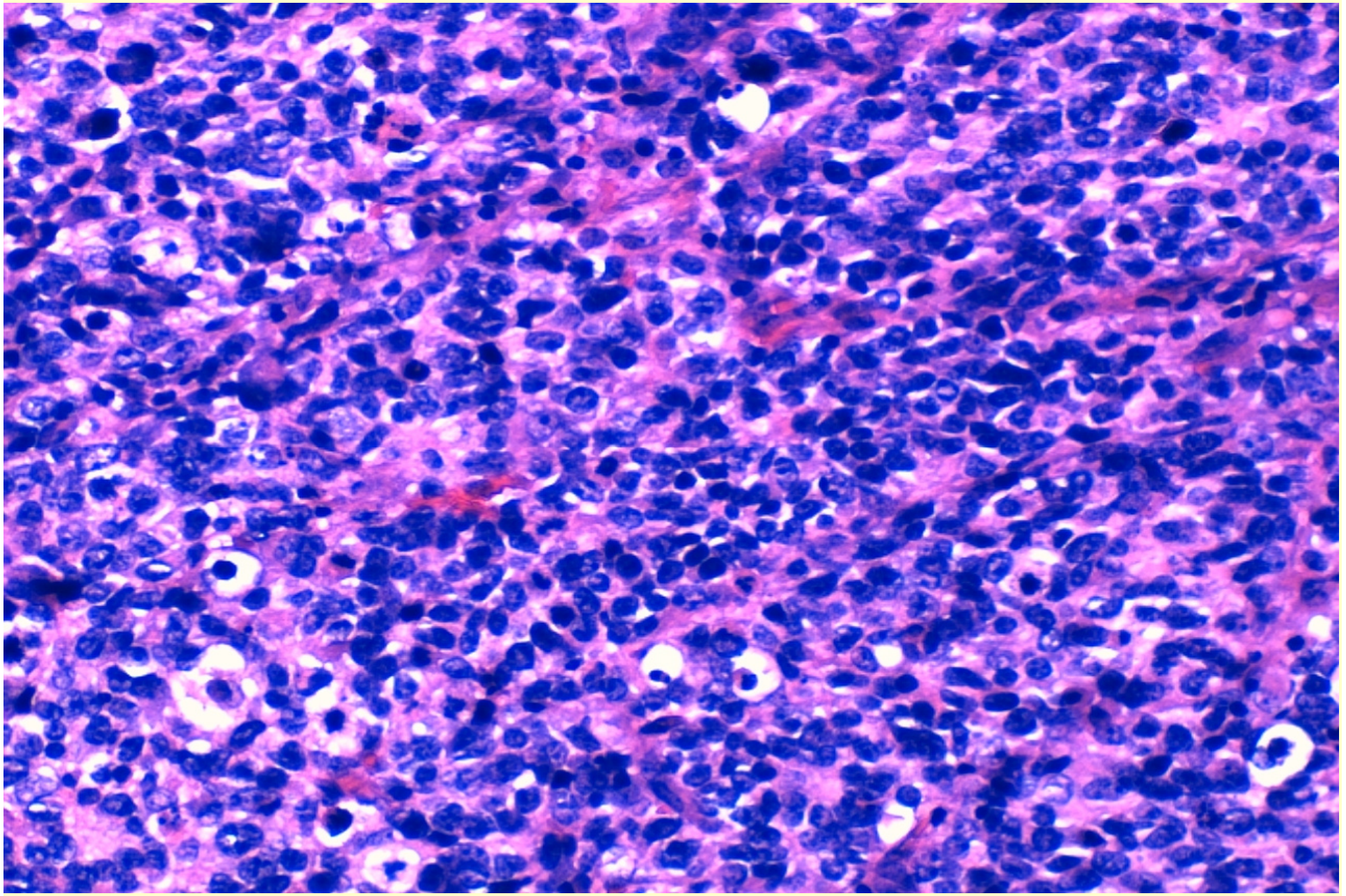

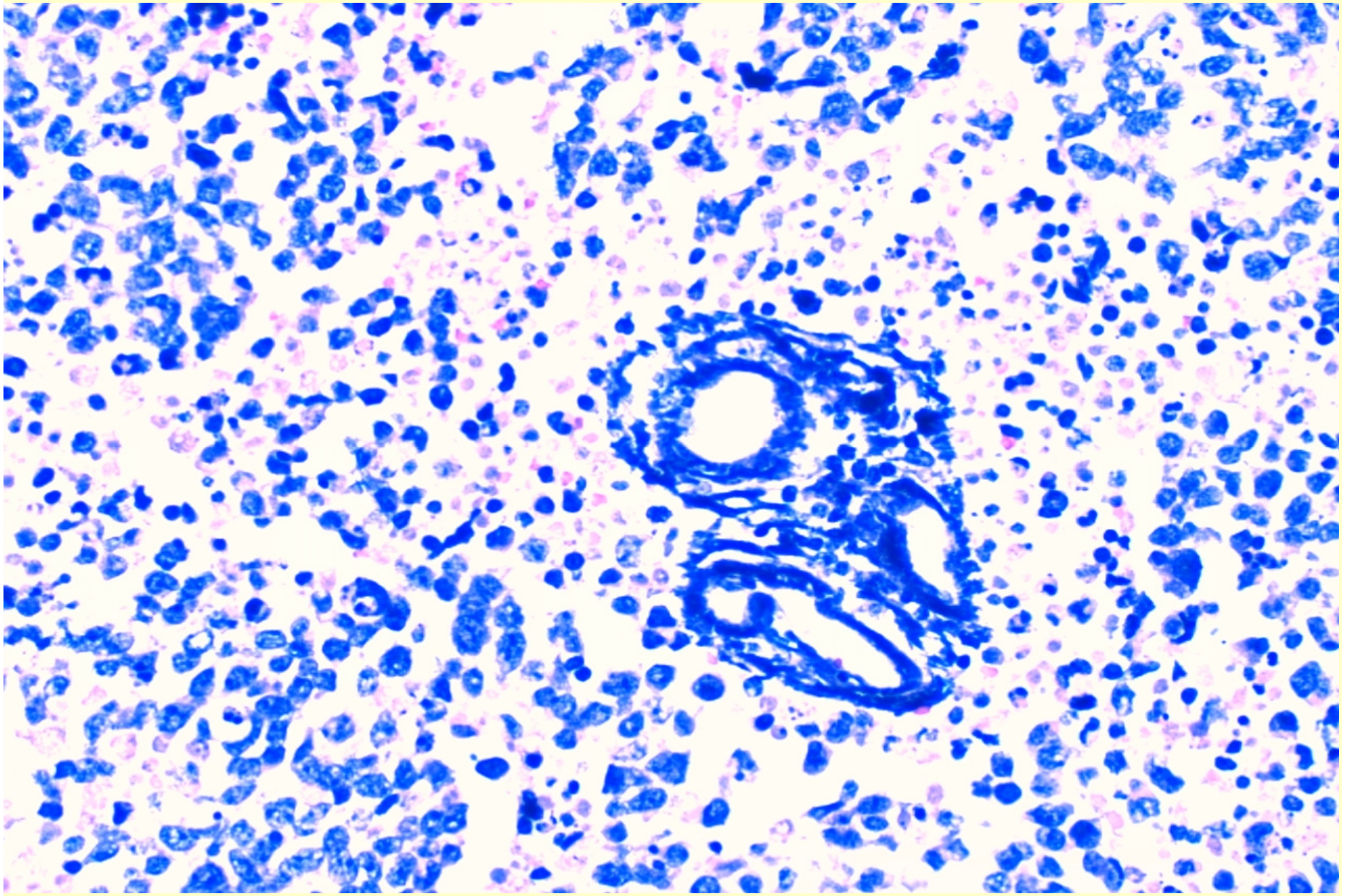

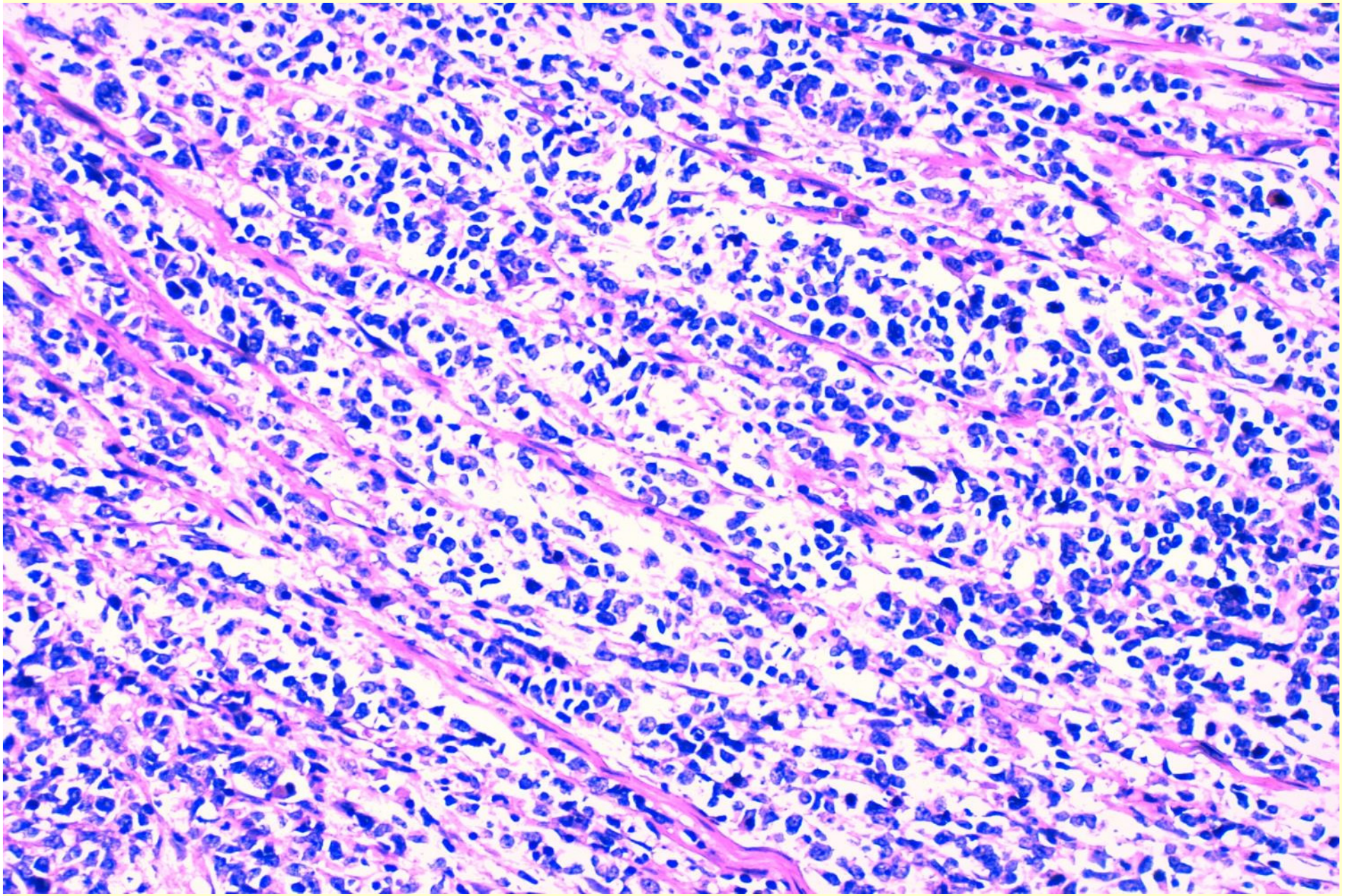

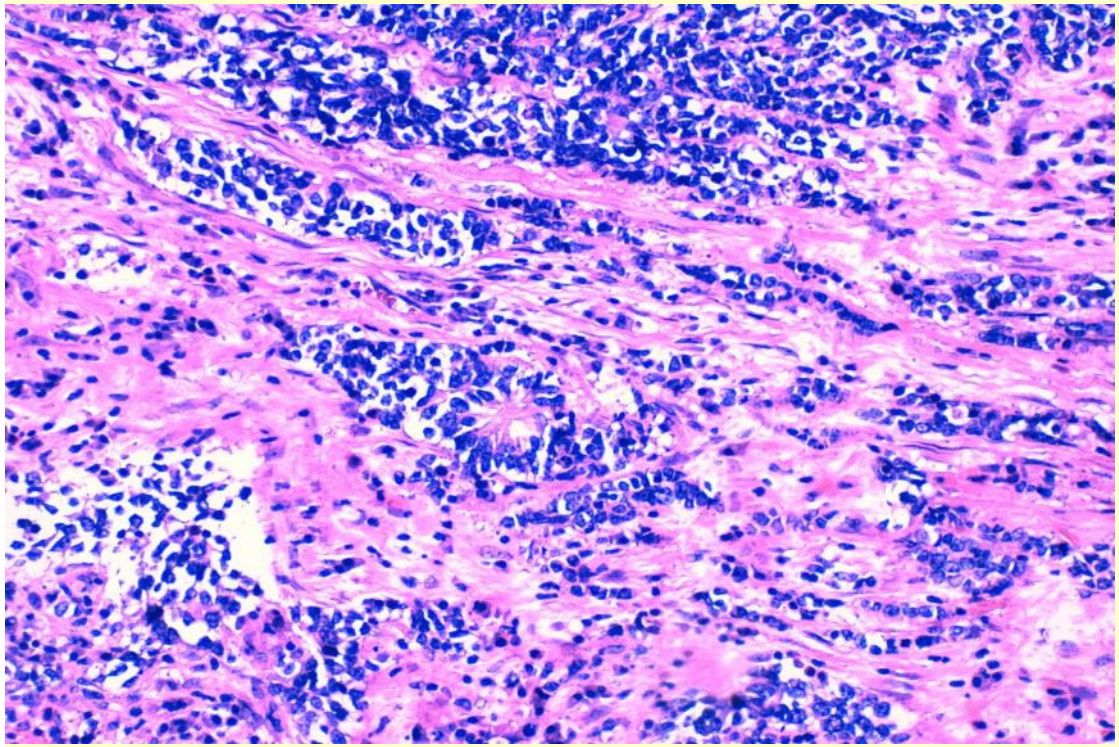

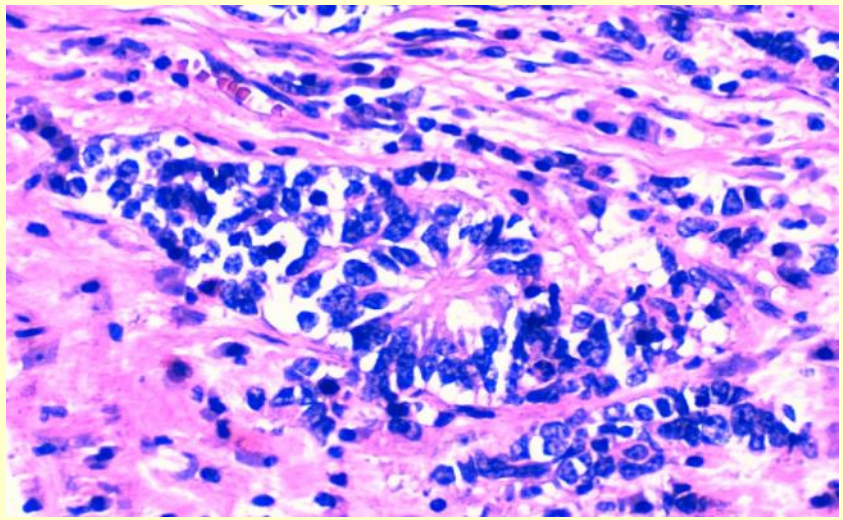

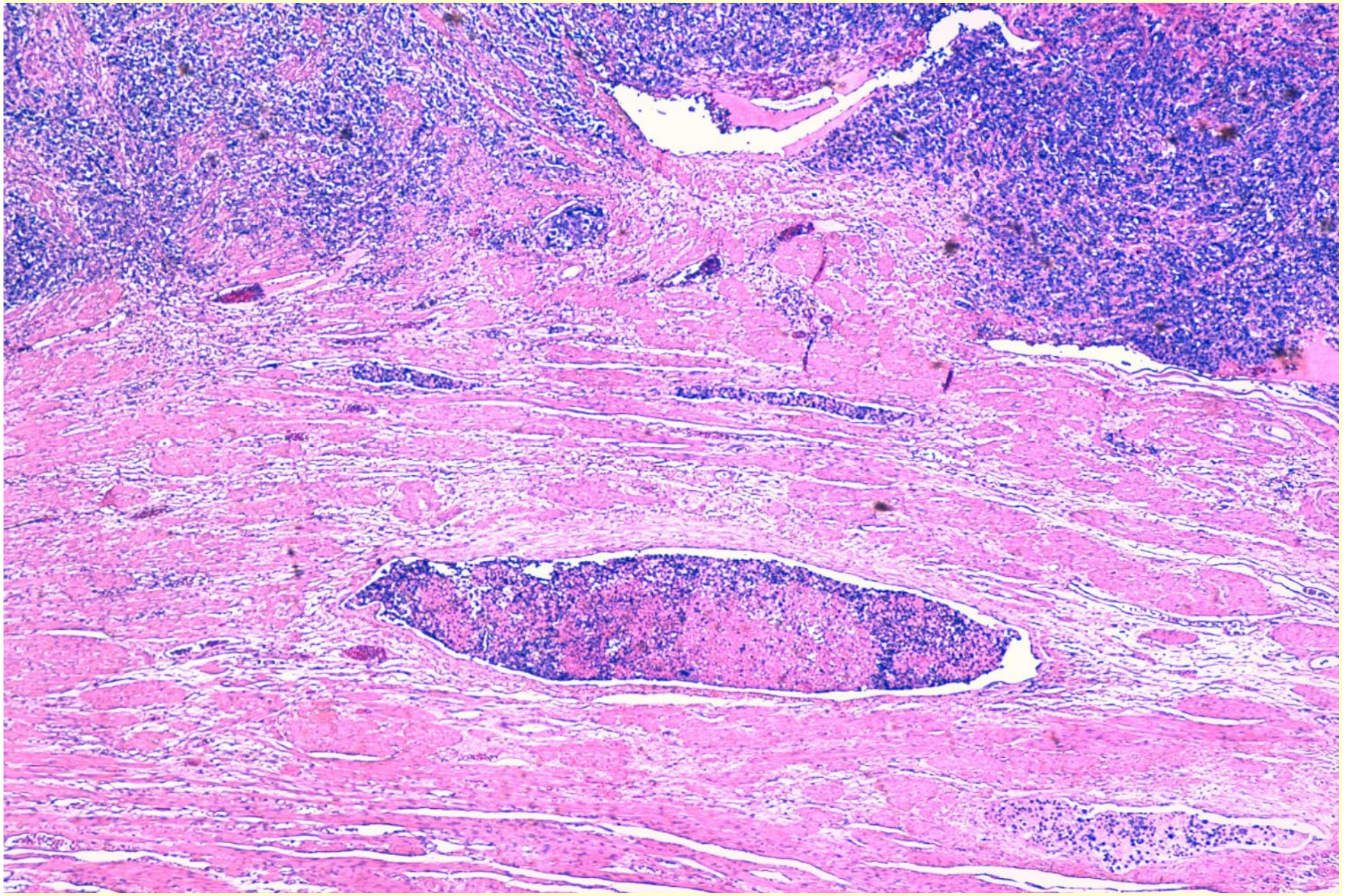

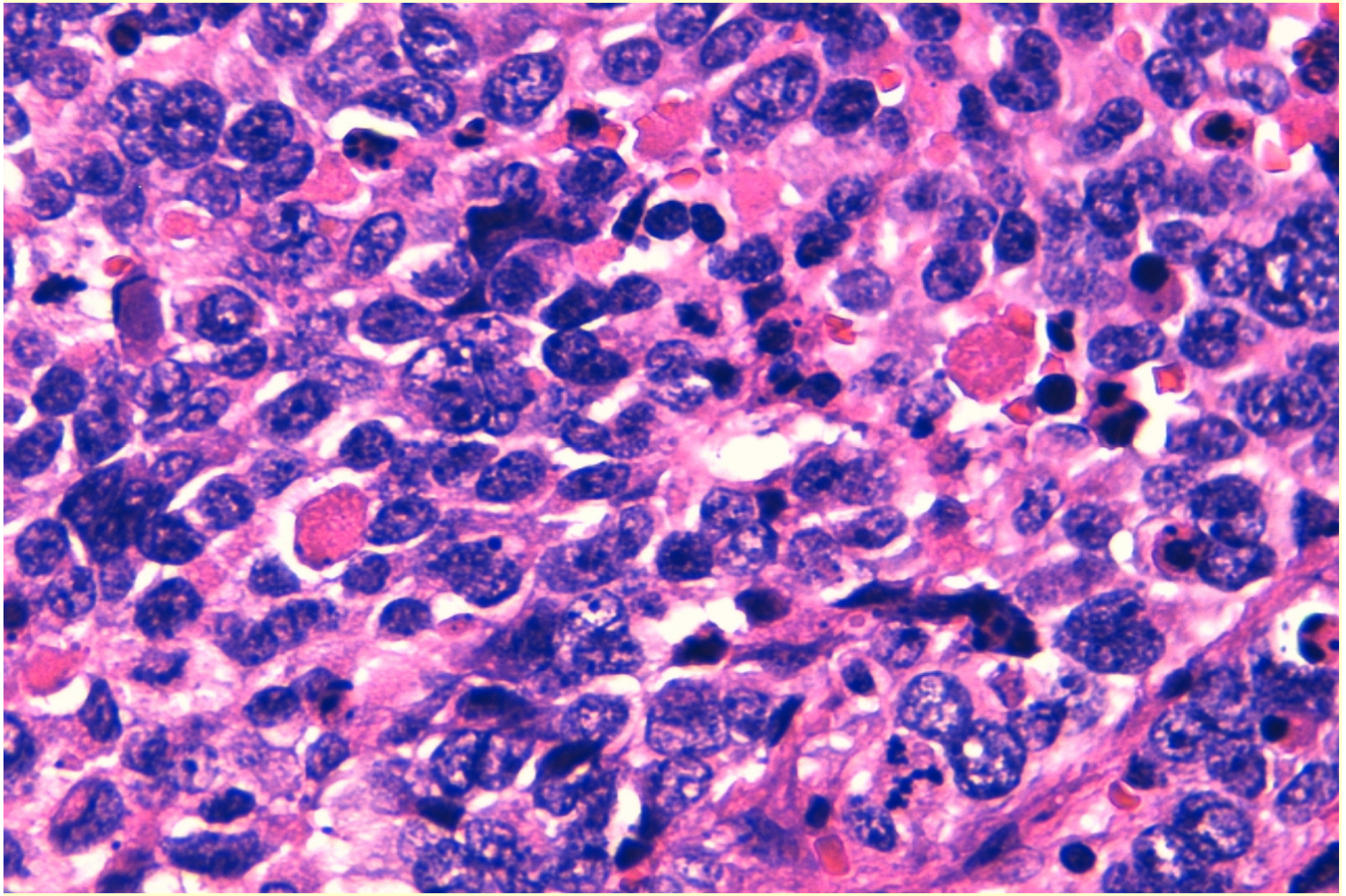

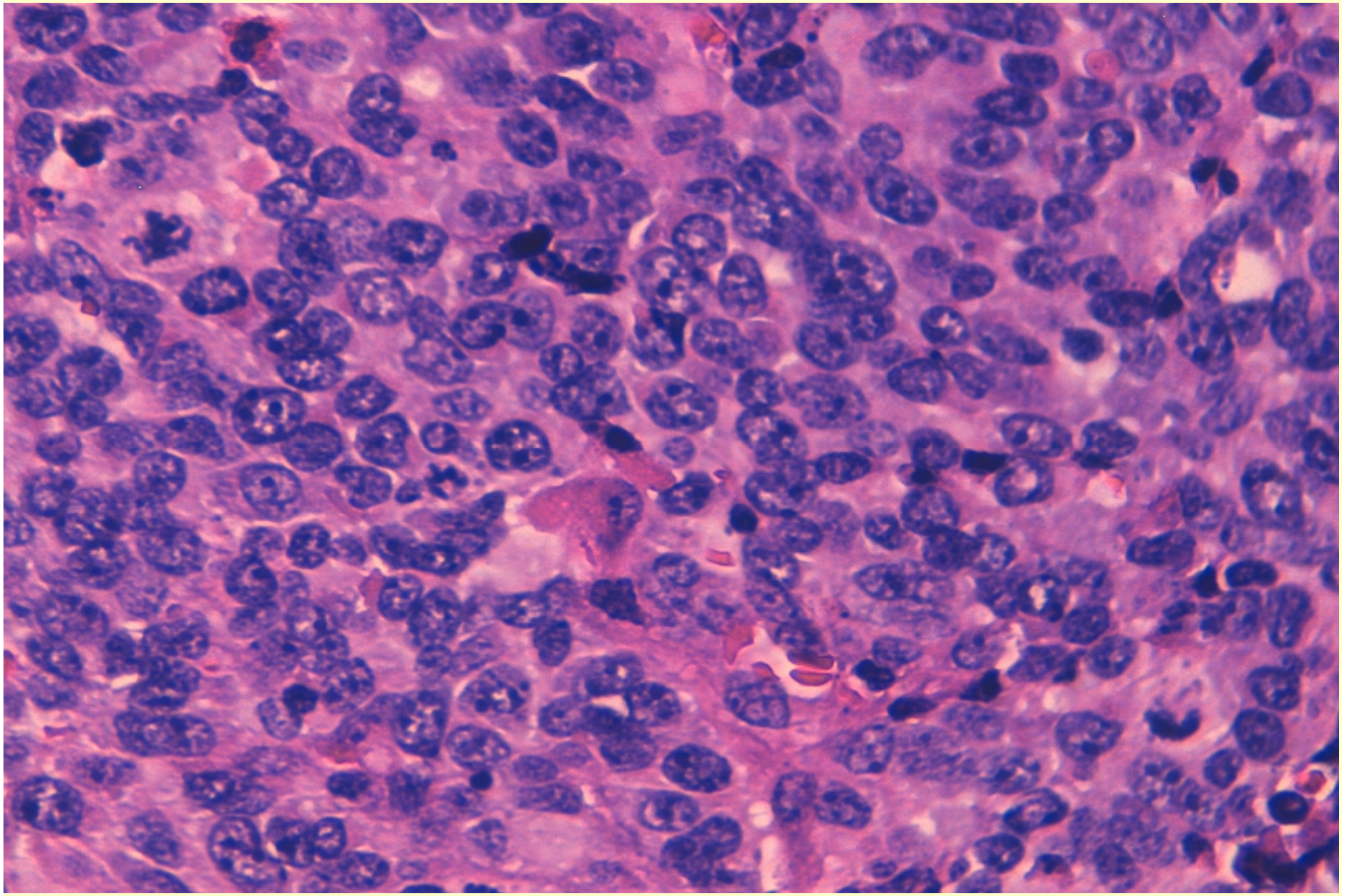

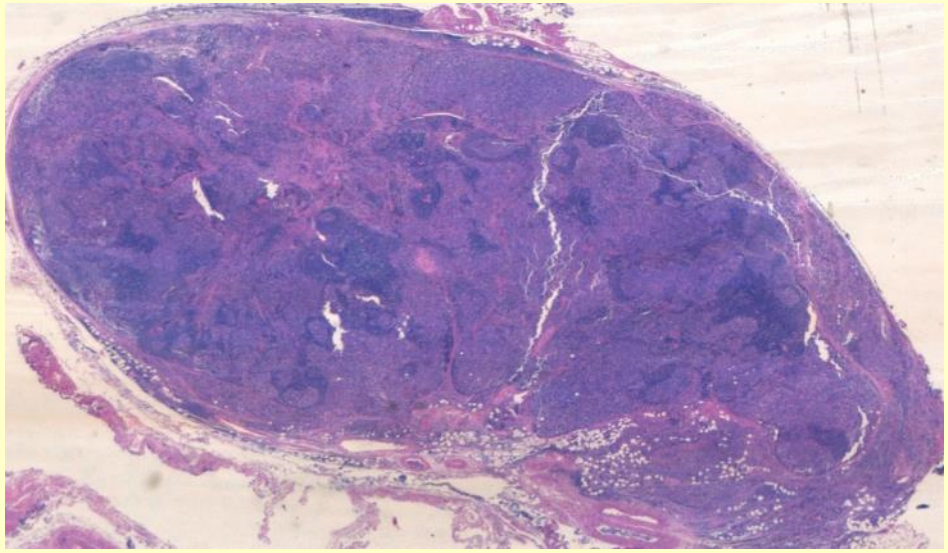

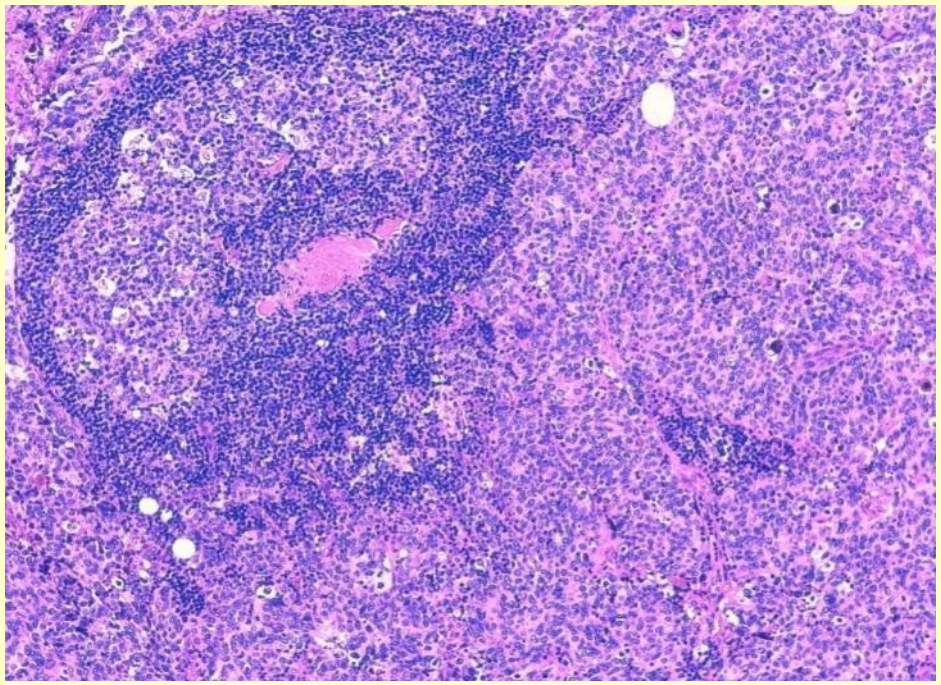

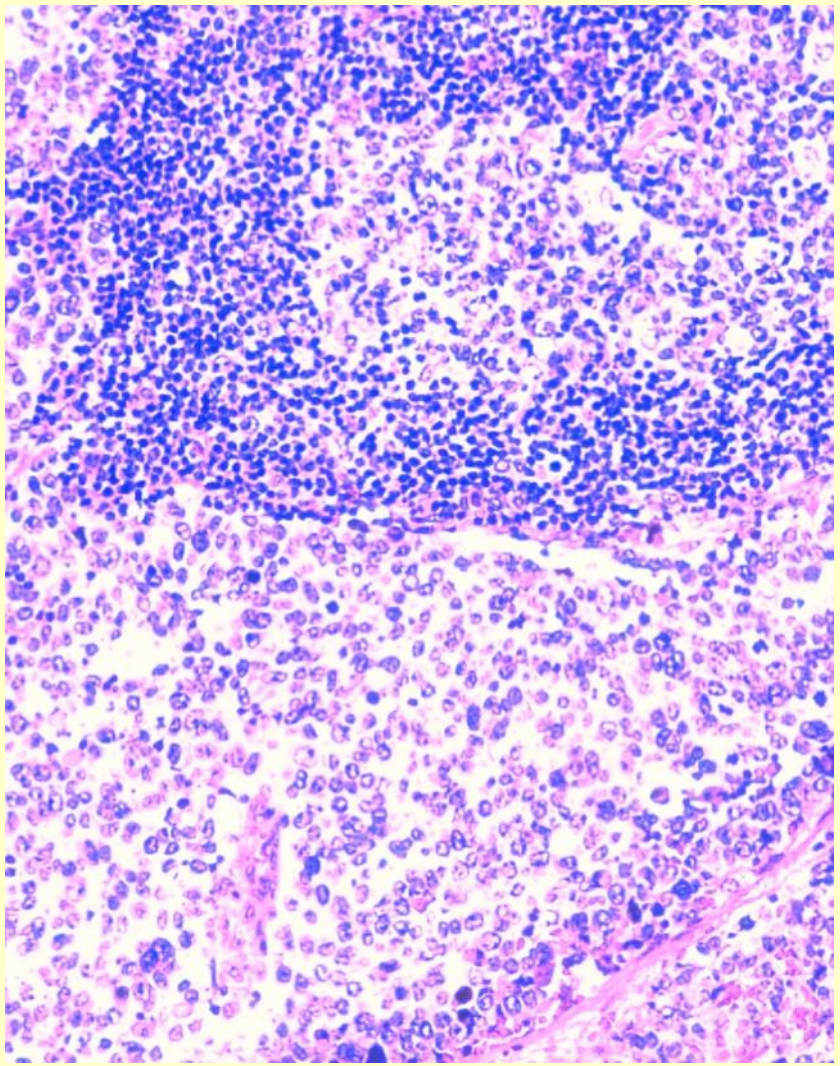

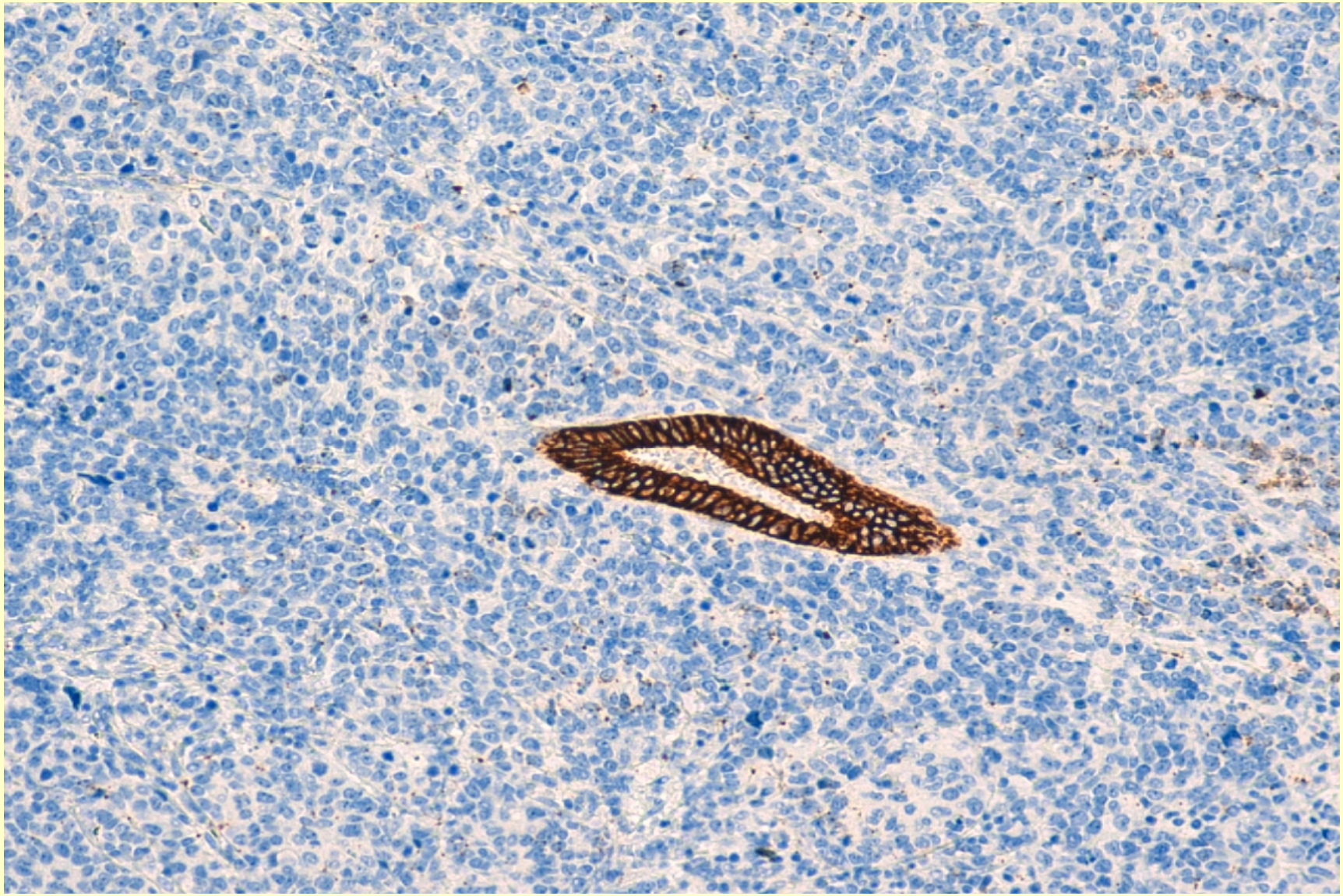

AE1-AE3

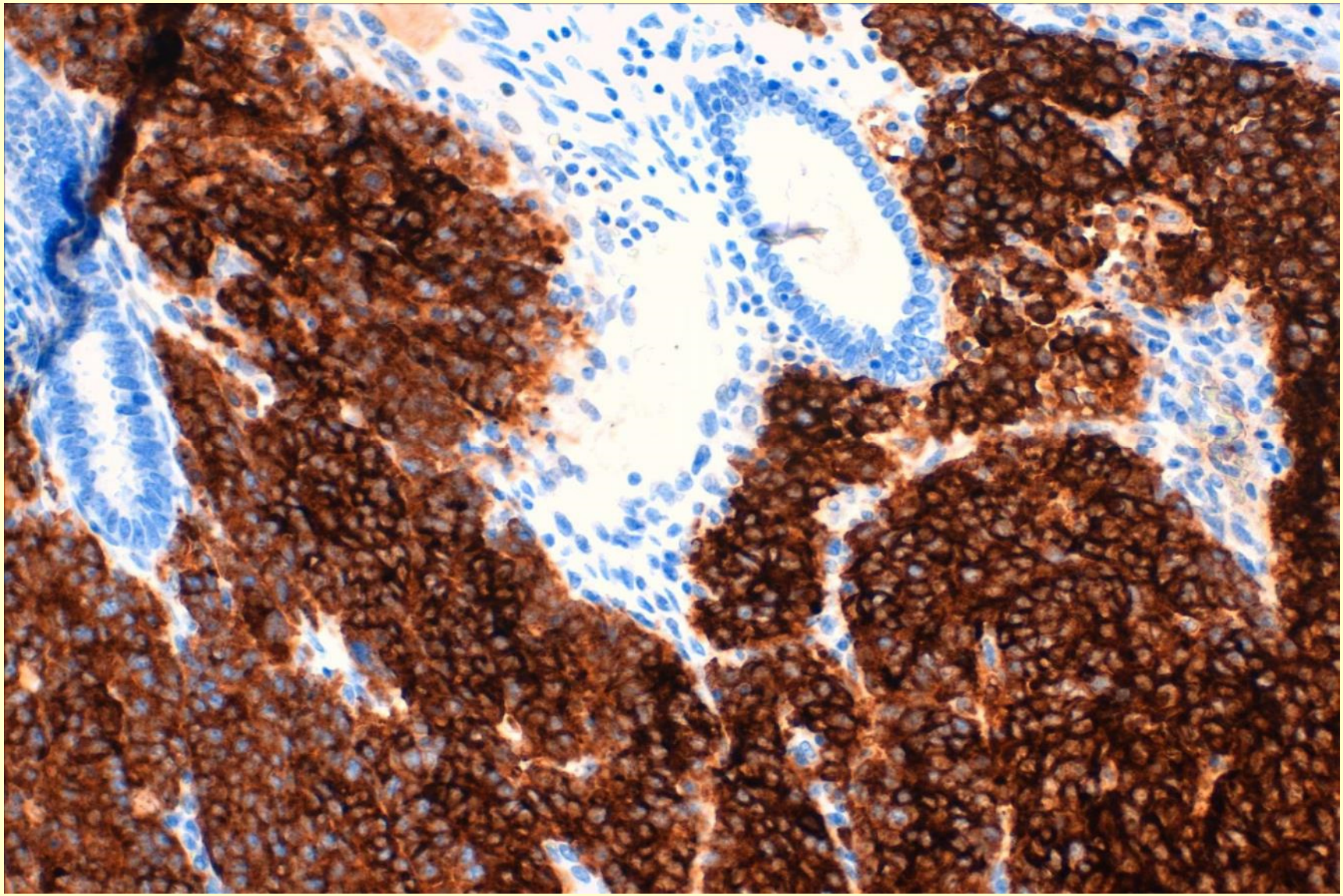

Synaptophysin

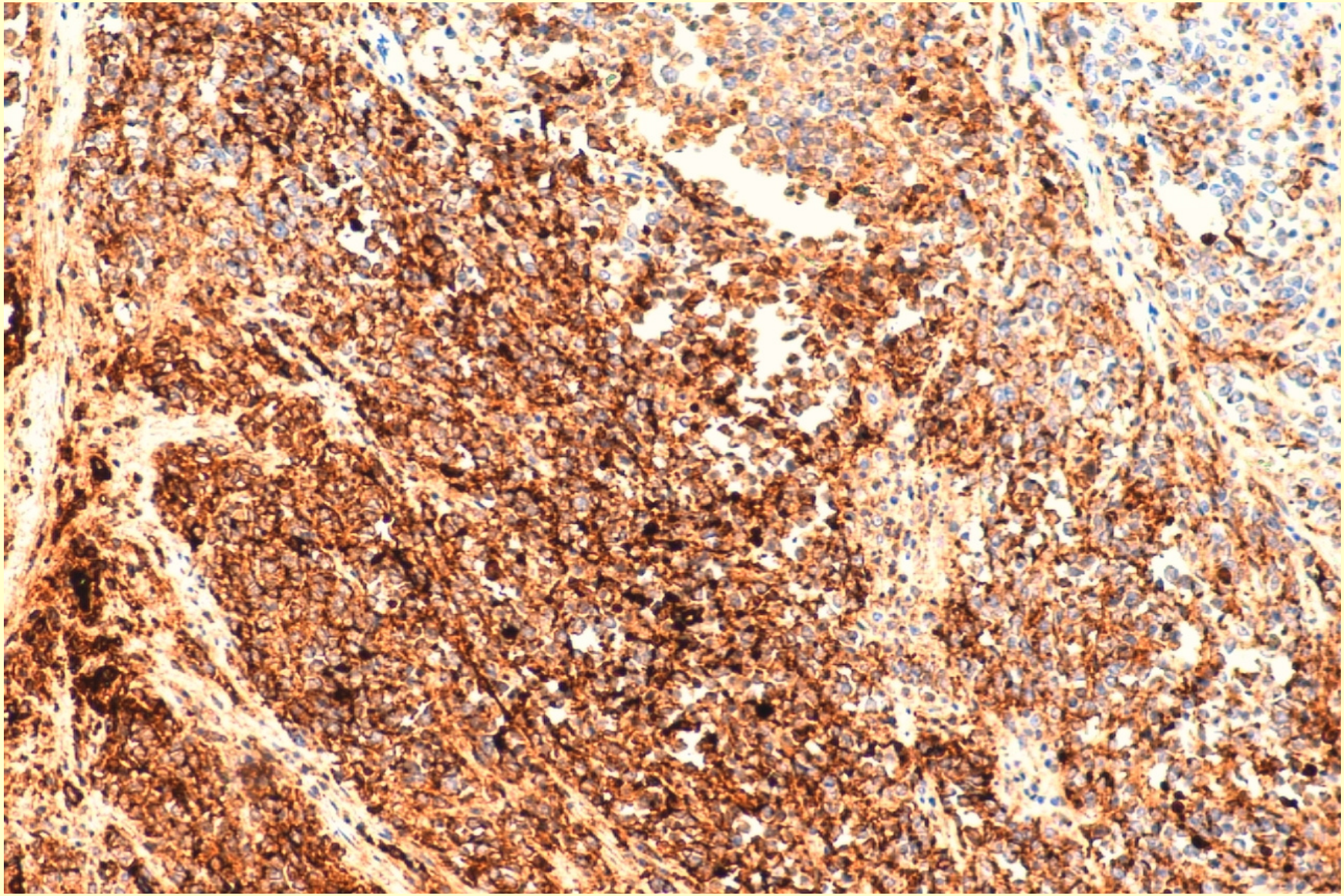

Chromogranin A

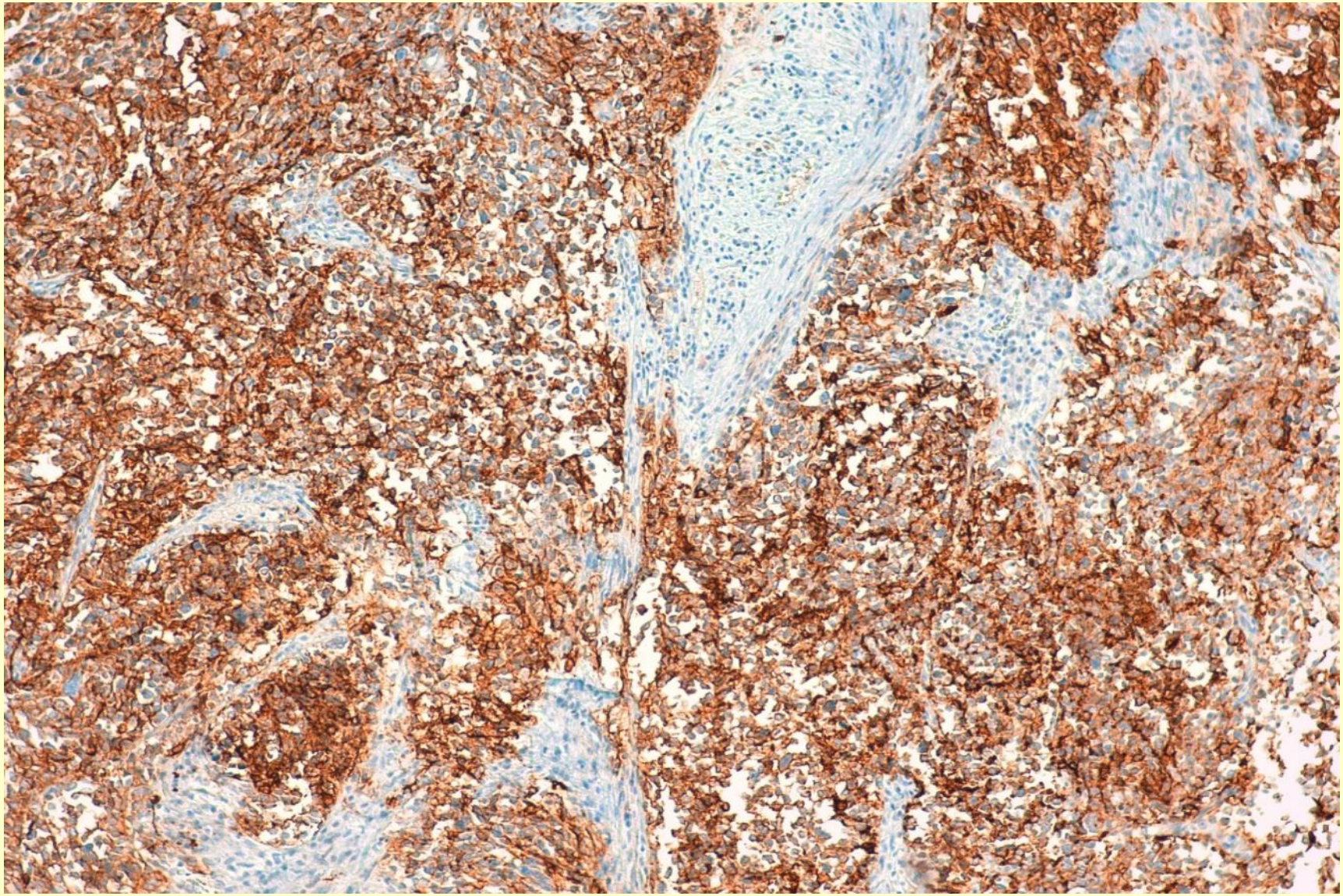

CD-56

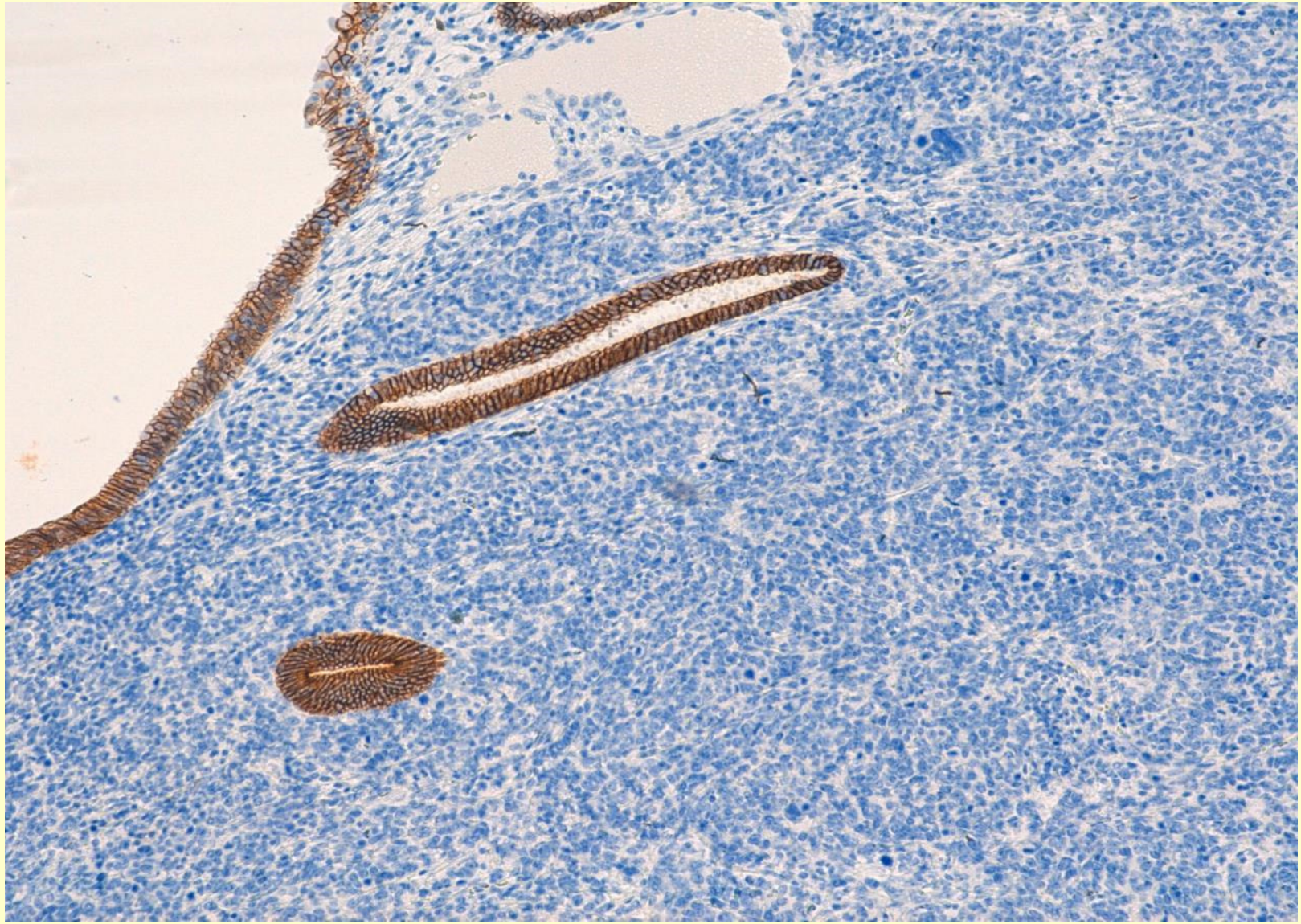

E-cadherin

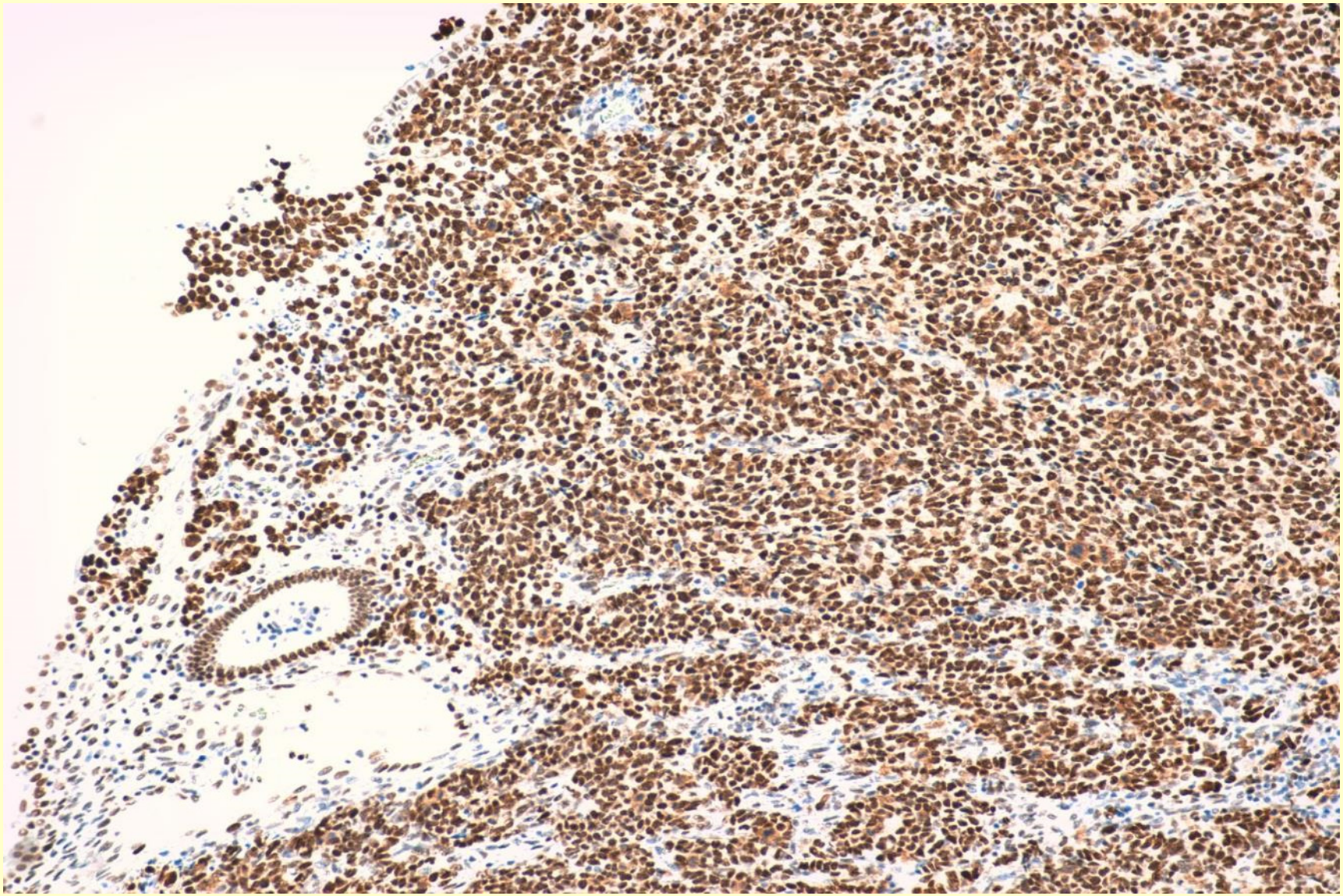

MSH-6

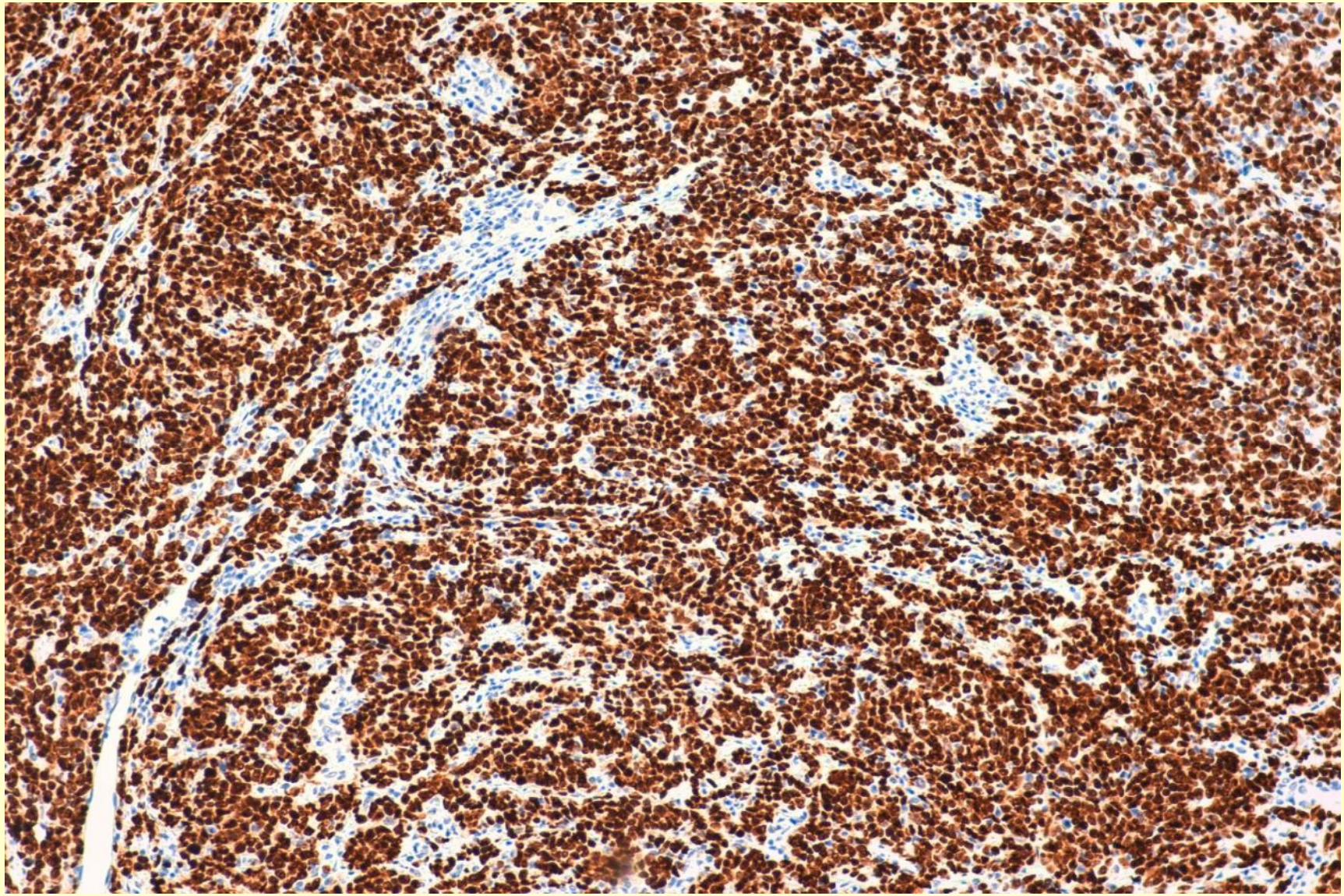

p53

Differential Diagnosis

- Undifferentiated Carcinoma
- Primitive Neuroectodermal Tumor
- Primary Large cell neuroendocrine carcinoma

Undifferentiated Carcinoma of the Endometrium

- 1 – 10% of endometrial carcinomas
- Solid sheets of epithelial cells
- Necrosis, mitosis
- 5-10% positive for keratins, positivity for EMA, negative for PAX8 and E-Cadherin
- Neuroendocrine differentiation allowed in <10% of cells.
- 50% present in advanced stage
- 75% of patients die of the disease

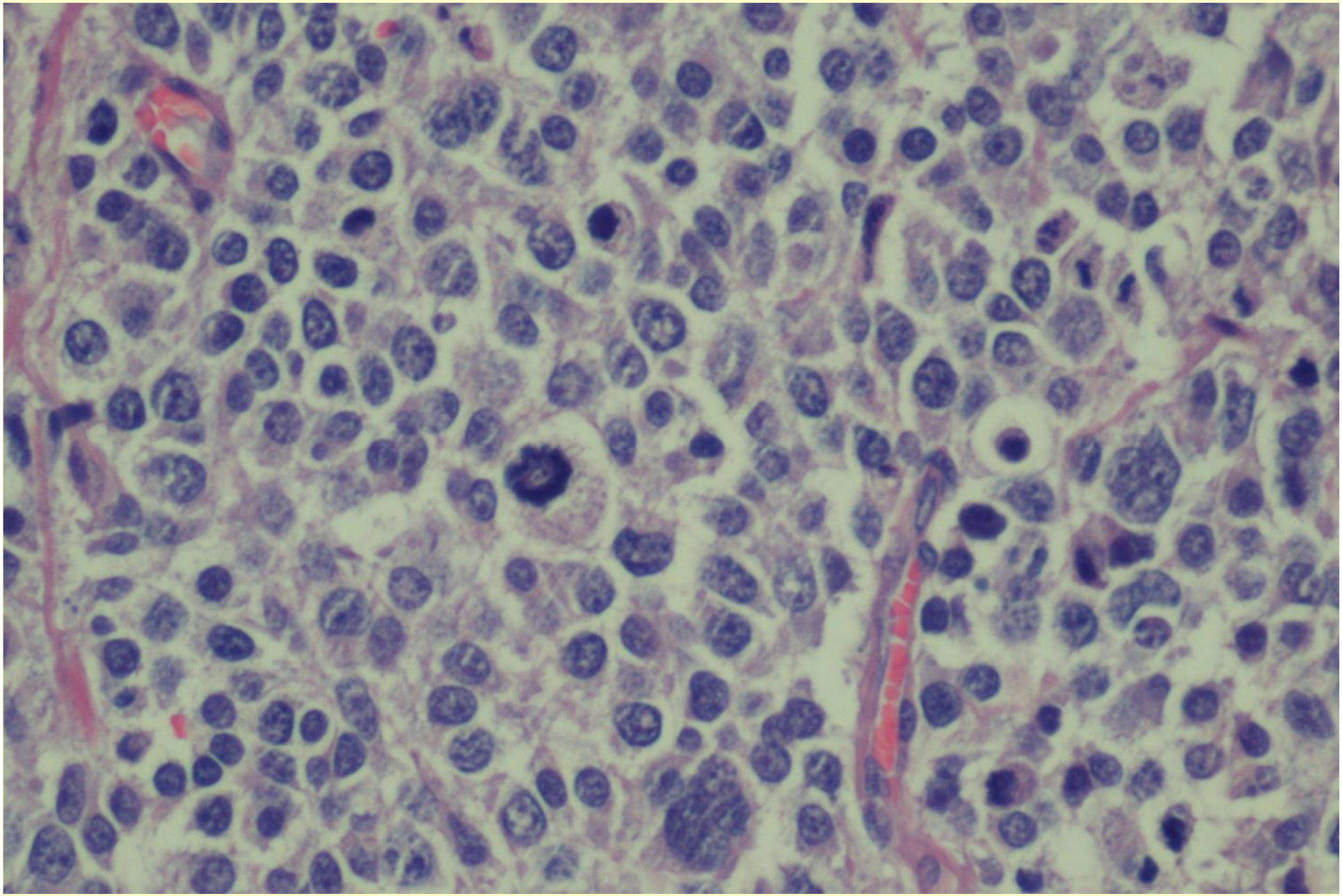

Primitive Neuroectodermal Tumor the Endometrium

- Unusual
- Small to medium sized densely packed primitive cells
- Medulloepitelioma or Meduloblastoma like areas
- Negative for keratins
- Positive for CD99
- Variable positivity for Synaptophysin and CD56, and negativity for Chromogranin A
- ESSR1 FISH positive in 1/8 cases

Primitive Neuroectodermal Tumors of the Female Genital Tract

A Morphologic, Immunohistochemical, and Molecular Study of 19 Cases

Sarah Chiang, MD, Matija Snuderl, MD,† Sakiko Kojiro-Sanada, MD,‡ Ariadna Quer Pi-Sunyer, MD,§ Dean Daya, MD,‖ Tohru Hayashi, MD,¶ Luisanna Bosincu, MD,# Fumihiro Ogawa, MD,** Andrew E. Rosenberg, MD,†† Lars-Christian Horn, MD, PhD,‡‡ Lu Wang, MD, PhD,* A. John Iafrate, MD, PhD,§§ and Esther Oliva, MD§§*

			Immunohistochemistry												
Case	**Diagnosis**	**Other Tumor**	**VIM**	**SYN**	**NSE**	**CD56**	**S100**	**CHR**	**NF**	**GFAP**	**CD99**	**Fli-1**	**CK**	**CD10**	***EWSR1* FISH**
11	cPNET Me		+	+	+	F+	–	–	–	–	+	–	–	–	–
12	cPNET Mb	EEC	F+	+	+	+	–	–	–	–	–	F+	–	–	–
13	cPNET Mb	EEC	F+	F+	–	–	F+	–	–	–	+	F+	F+	F+	–
14	cPNET Me	CS	+	–	–	+	–	–	–	–	F+	–	–	+	–
15	pPNET		+	–	–	–	–	–	–	–	+	+	–	–	+
16	cPNET Mb		+	+	+	+	F+	–	–	–	F+	F+	–	F+	–
17	cPNET Mb		+	–	–	+	–	–	–	–	+	F+	–	–	–
18	cPNET Mb		NP	NP	NP	NP	NP	NP	NP	NP	NP	NP	NP	NP	–

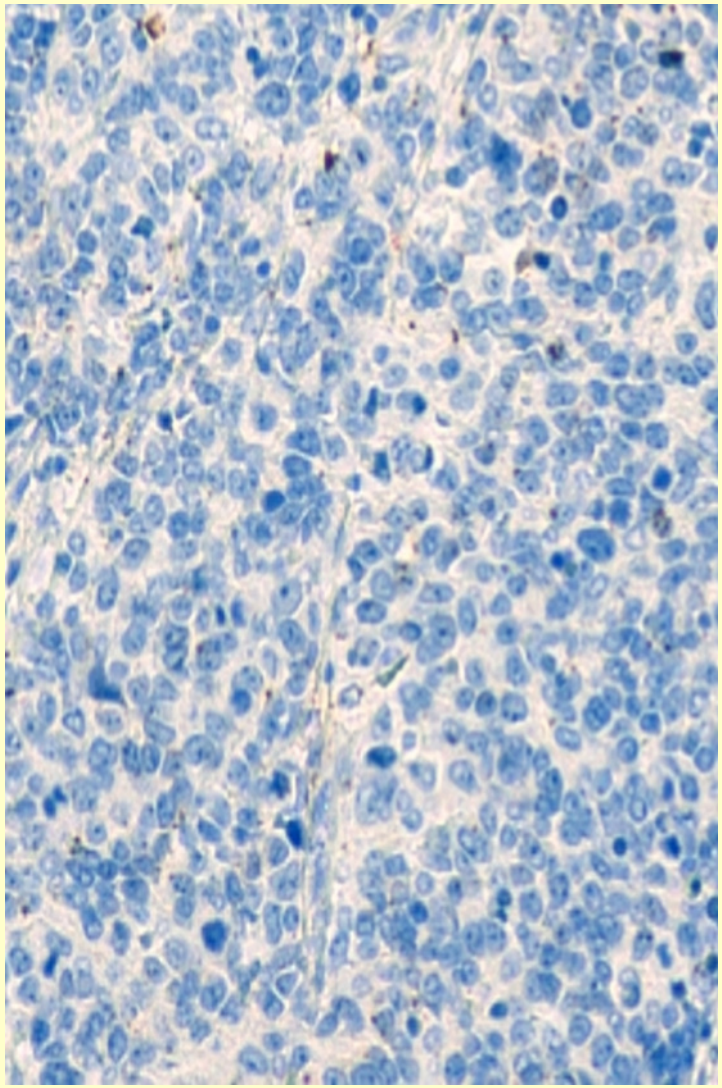

CD-99

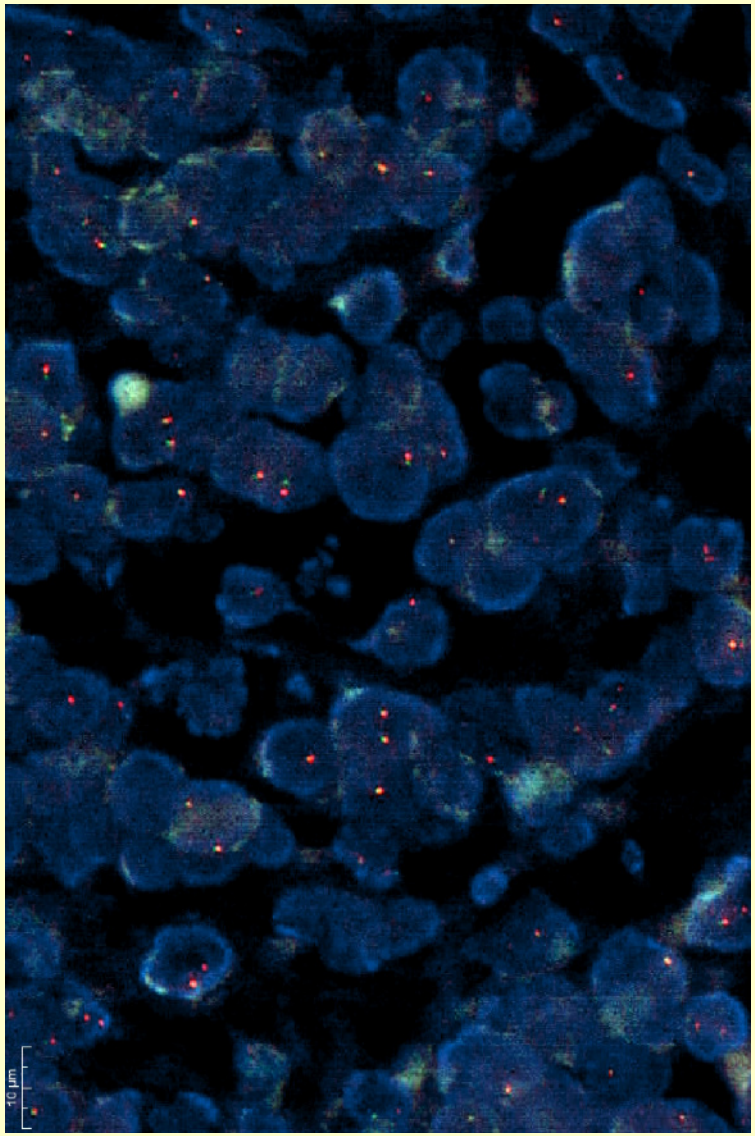

Negative EWSR1 FISH

Differential Diagnosis

- Undifferentiated Carcinoma
- Primitive Neuroectodermal Tumor
- Primary Large cell neuroendocrine carcinoma

WHO Classification of tumours of the uterine corpus

Neuroendocrine tumours

Definition
A diverse group of neoplasms that share a morphological neuroendocrine phenotype.

ICD-O codes

Low-grade neuroendocrine tumour	
Carcinoid tumour	8240/3
High-grade neuroendocrine carcinoma	
Small cell neuroendocrine carcinoma	8041/3
Large cell neuroendocrine carcinoma	8013/3

Immunohistochemistry

SCNEC may react for chromogranin A, synaptophysin, CD56, vimentin and cytokeratins (dot-like pattern).

To establish a diagnosis of LCNEC, a neuroendocrine growth pattern should be present in at least part of the tumour, with expression of one or more of the neuroendocrine markers chromogranin, CD56 (the latter is not very specific), synaptophysin in > 10% of the neoplastic cells.

Neuroendocrine Carcinoma of the Endometrium

- **Pure or mixed, most often with endometrioid carcinoma**
- **Large cell, small cell, mixed**
- **Positive for Synaptophysin, chromogranin A or CD56), and may be negative for keratins**
- **p16 and CD117 may be positive**
- **Mismatch repair deficiency in some cases**
- **Some overlap with undifferentiated ca**
- **50% of patients died of disease.**

Differential Diagnosis

- Undifferentiated Carcinoma
- Primitive Neuroectodermal Tumor
- Primary Large cell neuroendocrine carcinoma

Undiff Ca

Neuroend Ca

PNET

Variable association with endometrial carcinoma
Variable expression of neuroendocrine markers, and keratins
Variable mismatch repair deficiency

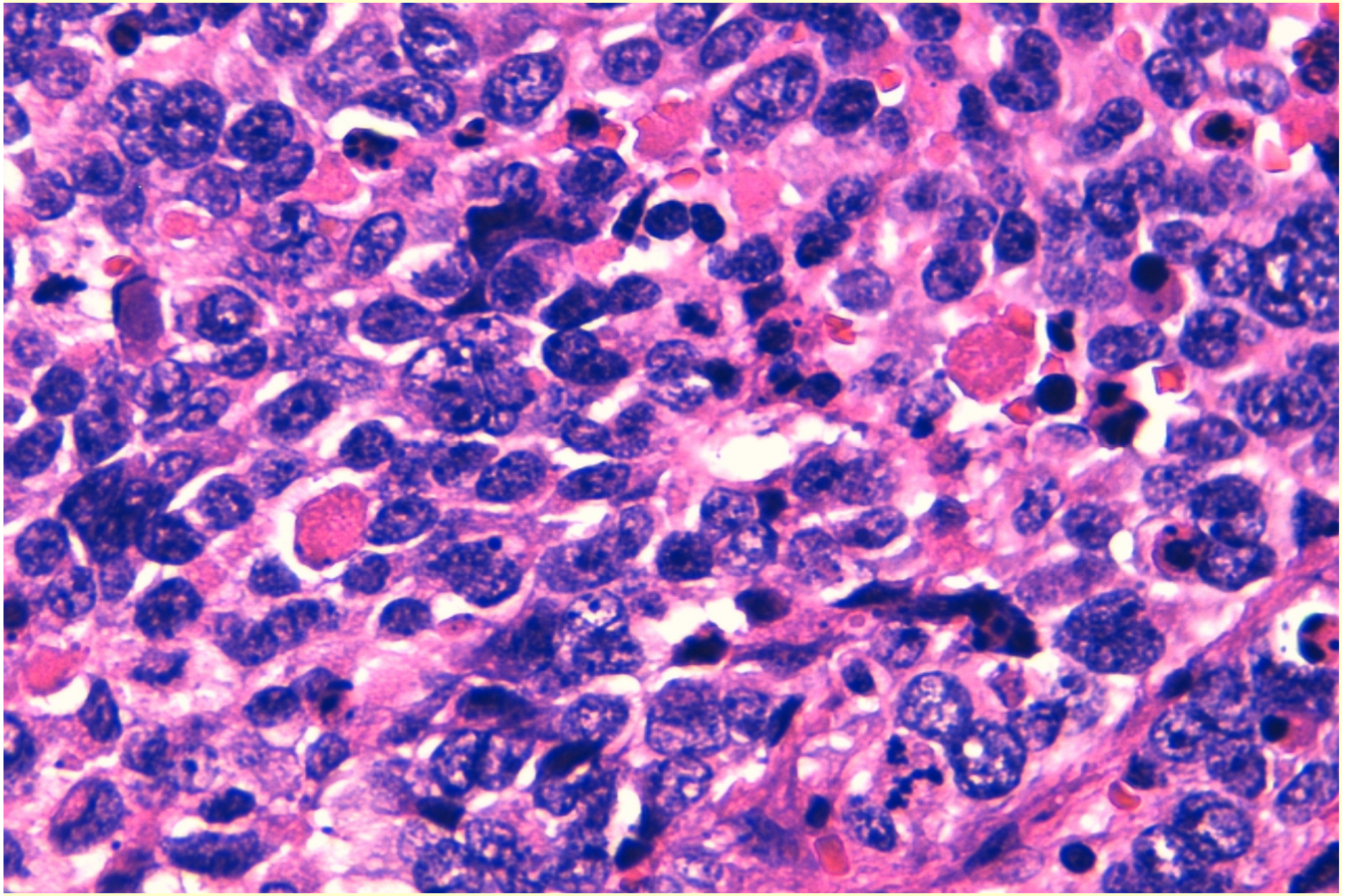

The American Journal of Surgical Pathology *24(2): 223–230, 2000*

© 2000 Lippincott Williams & Wilkins, Inc., Philadelphia

Small Cell Neuroendocrine Carcinoma With Skeletal Muscle Differentiation

Report of Three Cases

Vincenzo Eusebi, M.D., Stefania Damiani, M.D., Gianandrea Pasquinelli, M.D., Paolo Lorenzini, M.D., Victor E. Reuter, M.D., and Juan Rosai, M.D.

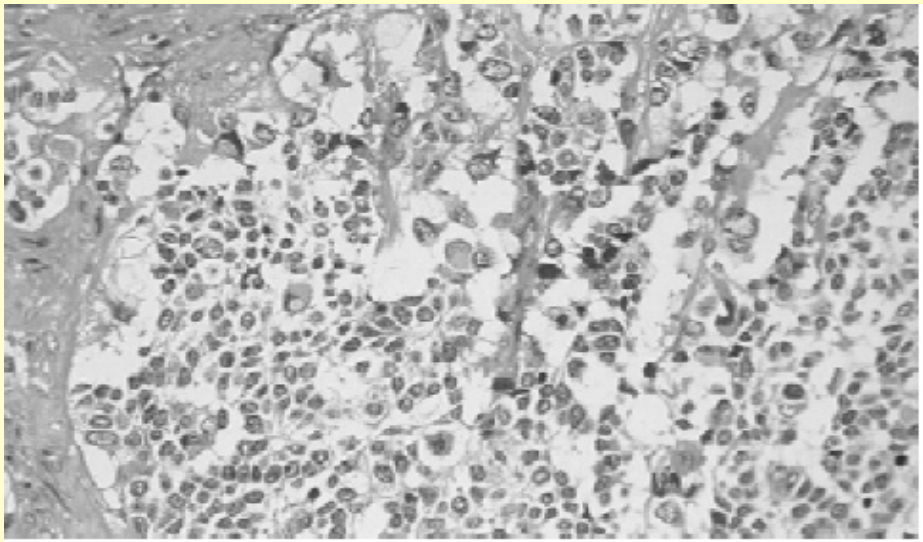

FIG. 5. Patient 1. Scattered rhabdomyoblastic (type B) cells are intermingled with small (type A) neoplastic elements. The cytoplasm of the former is abundant and eosinophilic.

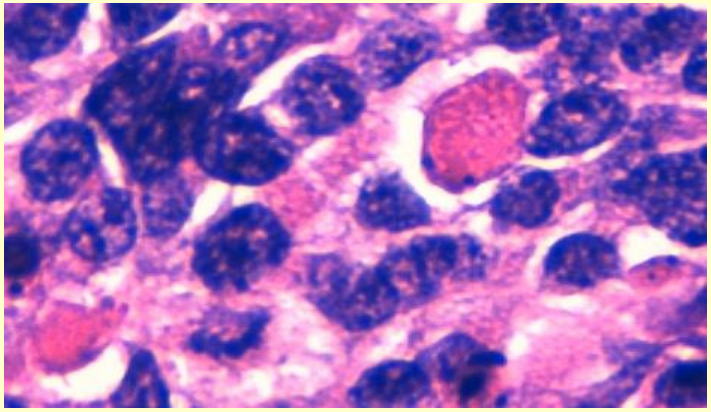

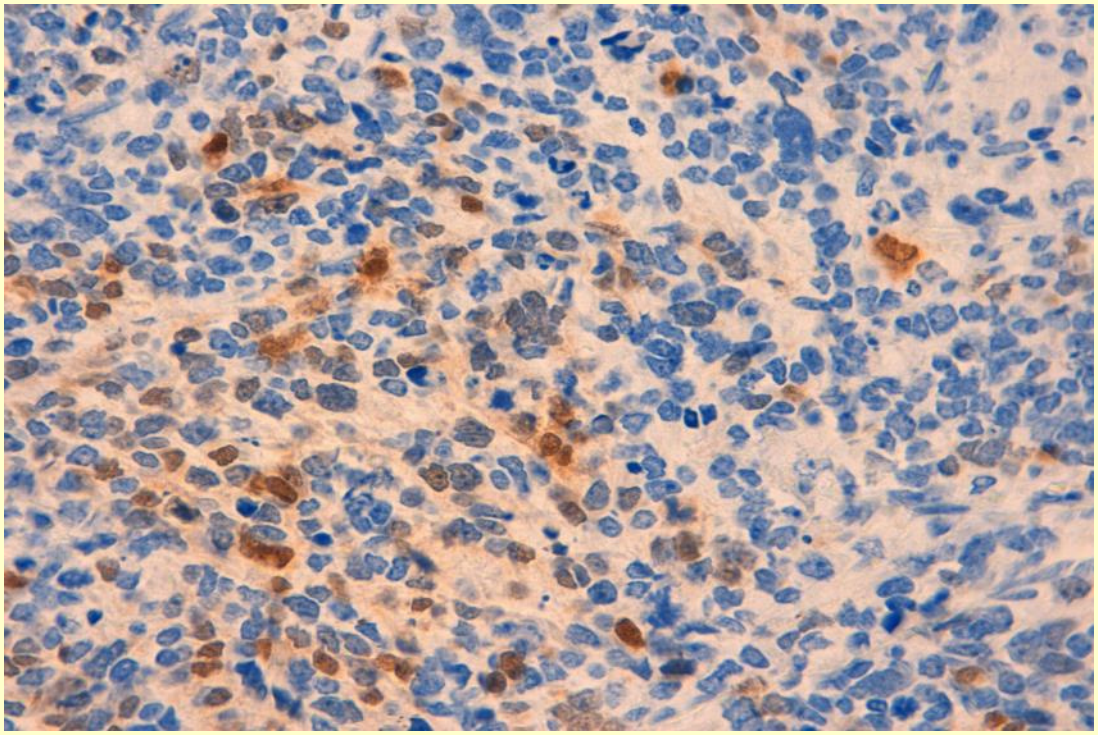

Myogenin

Diagnosis

Large cell neuroendocrine carcinoma of the endometrium with focal rhabdomyoblastic differentiation.



Slide seminar. Case 2

Xavier Matias-Guiu,

Hospital U Arnau de Vilanova, University of Lleida, IRBLLEIDA

Hospital U de Bellvitge