TECHNOLOGY TRANSFER IN DIAGNOSTIC PATHOLOGY
10TH CENTRAL EUROPEAN REGIONAL MEETING

Gynecological Pathology

ORGANIZED BY THE HUNGARIAN DIVISION OF THE INTERNATIONAL ACADEMY OF PATHOLOGY

CO-SPONSORED BY ISGyP

Visegrád, June 27-29, 2019

ENDOMETRIOSIS AND ASSOCIATED NEOPLASIA

Xavier Matias-Guiu, MD, PhD

Hospital U Arnau de Vilanova, Univ Lleida, IRBLLEIDA,

Hospital U de Bellvitge. IDIBELL, Spain

Endometriosis

- Endometrial tissue outside the uterine cavity
- May involve different organs (ovaries, peritoneum, appendix, rectum, bladder)
- May give rise to endometrial-related tumors

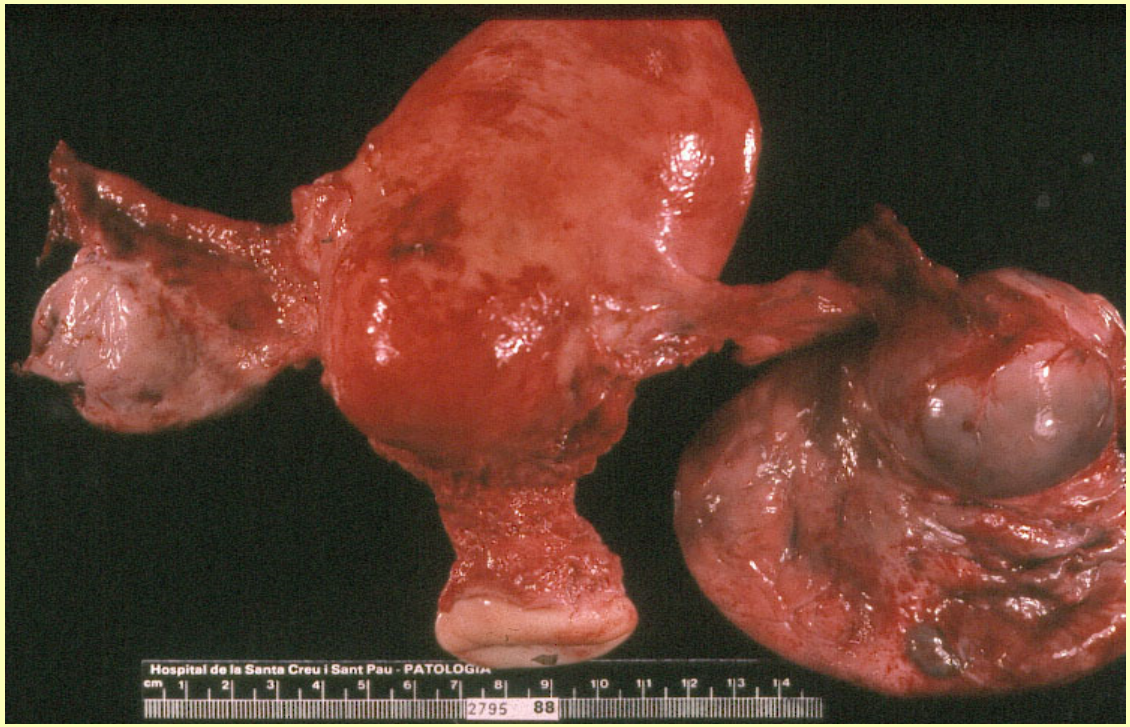
Hospital de la Santa Creu i Sant Pau - PATOLOGIA
cm 1 2 3 4 5 6 7 8 9 10 11 12 13 14
2795 88

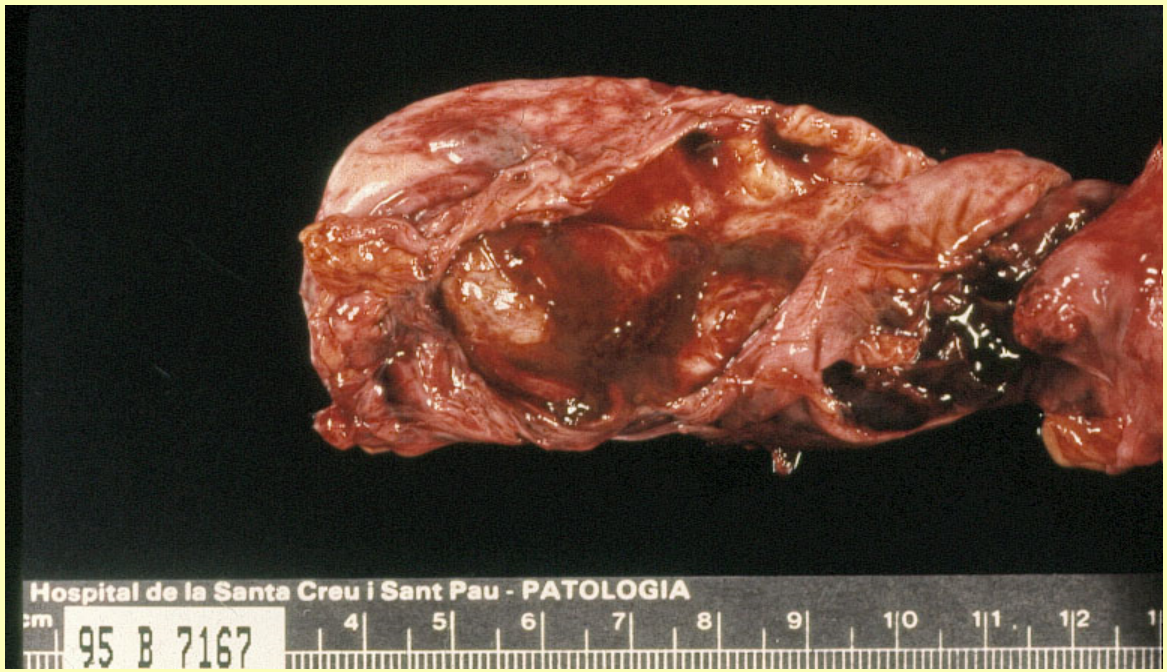
Hospital de la Santa Creu i Sant Pau - PATOLOGIA
95 B 7167
4 5 6 7 8 9 10 11 12

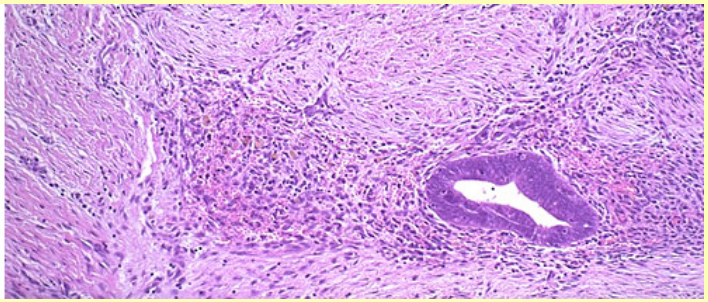

Polypoid Endometriosis

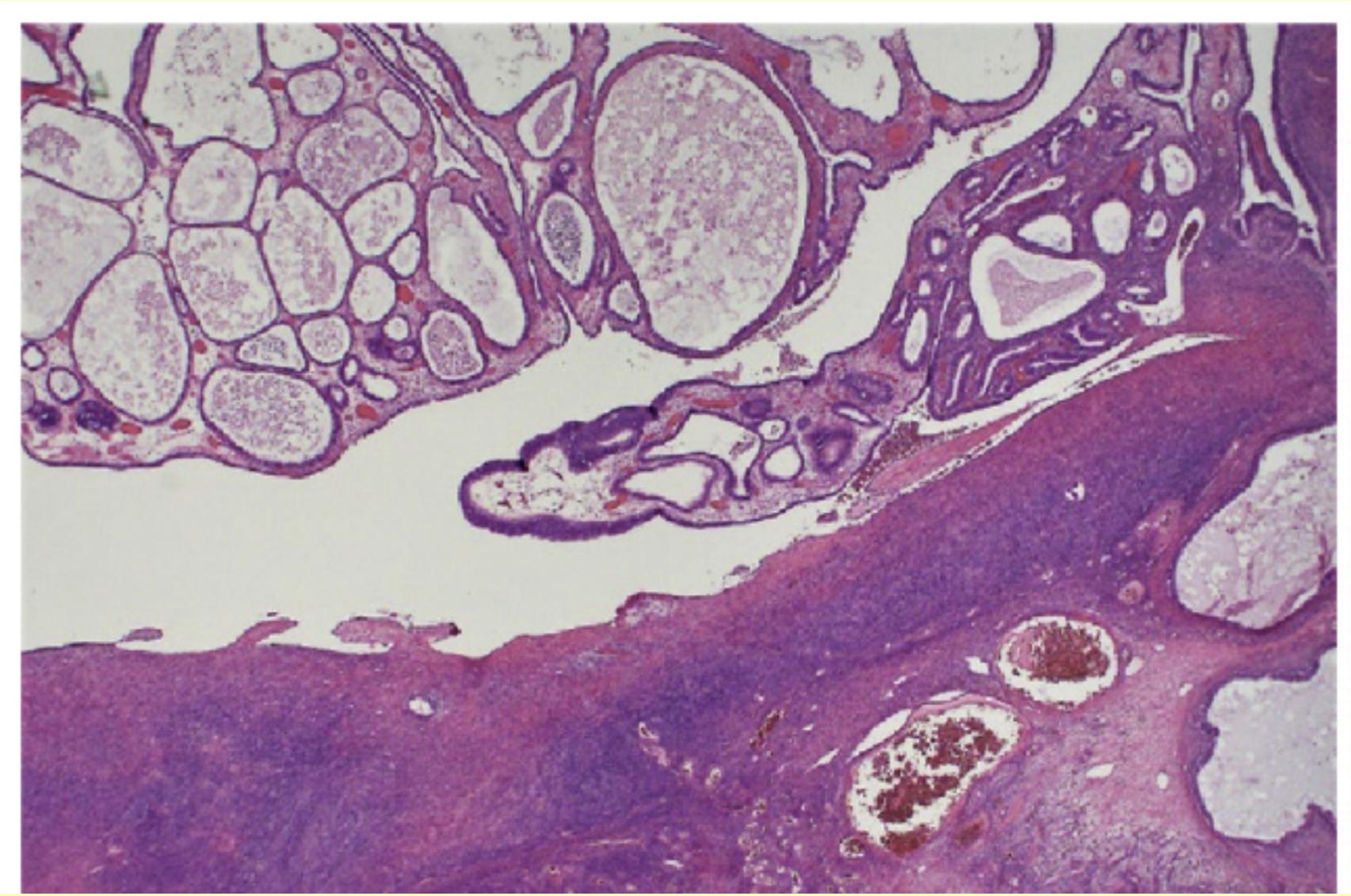

Atypical Endometriosis

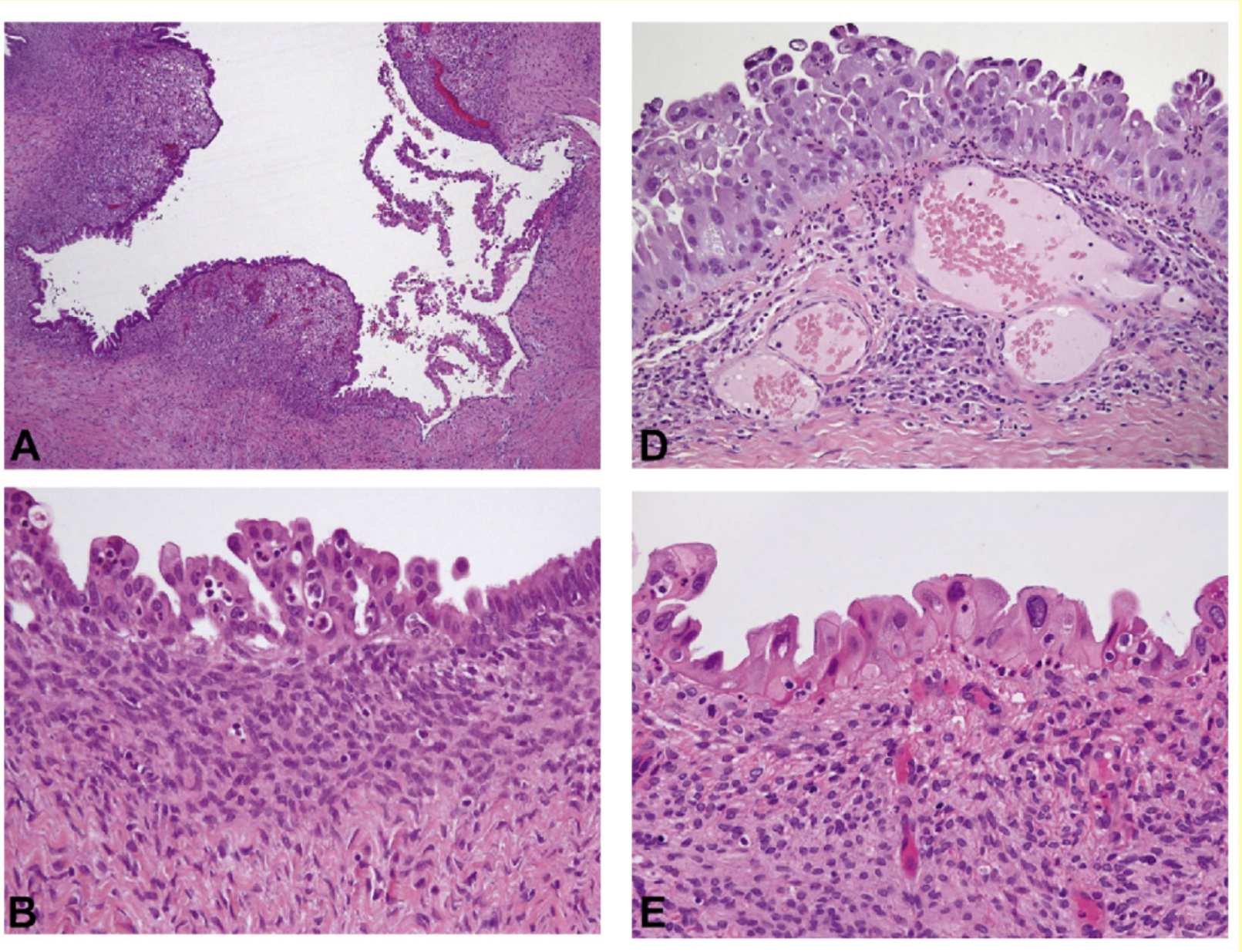

Contents of Endometriotic Cysts, Especially the High Concentration of Free Iron, Are a Possible Cause of Carcinogenesis in the Cysts through the Iron-Induced Persistent Oxidative Stress

Ken Yamaguchi,[1] Masaki Mandai,[1] Shinya Toyokuni,[2] Junzo Hamanishi,[1] Toshihiro Higuchi,[1] Kenji Takakura,[1] and Shingo Fujii[1,3]

Clin Cancer Res 2008;14:32-40.

Int J Clin Oncol (2009) 14:383–391
DOI 10.1007/s10147-009-0935-y

© The Japan Society of Clinical Oncology 2009

REVIEW ARTICLE

Masaki Mandai · Ken Yamaguchi · Noriomi Matsumura
Tsukasa Baba · Ikuo Konishi

Ovarian cancer in endometriosis: molecular biology, pathology, and clinical management

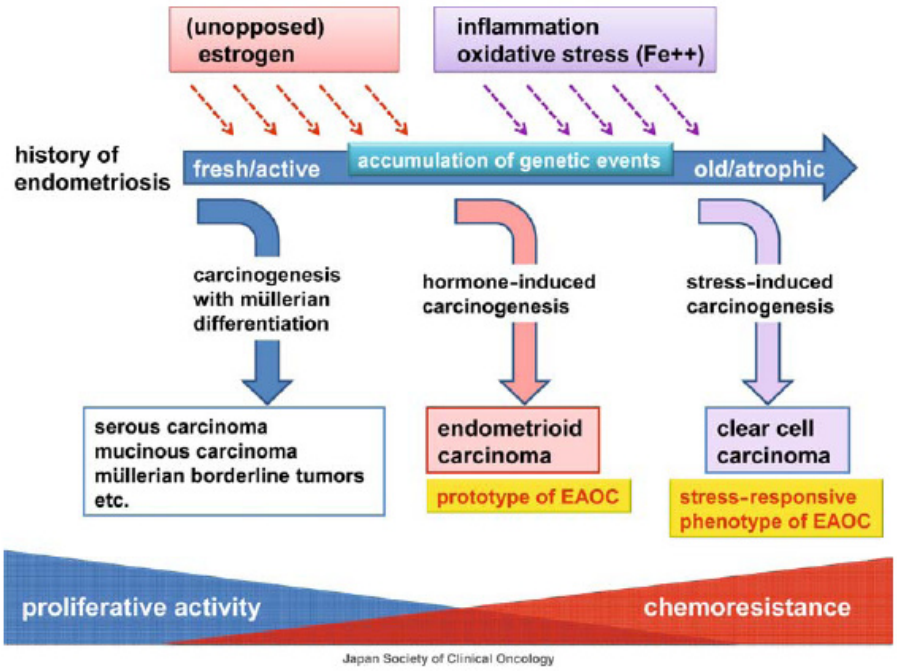

Fig. 4. Hypothetical pathogenesis of malignant transformation of endometriosis

Ovarian Tumors associated with Endometriosis

- Endometrioid
- Clear Cell
- Seromucinous

WHO Classification of Tumours of Female Reproductive Organs

Endometrioid tumours

Benign	
Endometriotic cyst	
Endometrioid cystadenoma	8380/0
Endometrioid adenofibroma	8381/0
Borderline	
Borderline endometrioid tumour / Atypical proliferative endometrioid tumour	8380/1
Malignant	
Endometrioid carcinoma	8380/3

Endometrioid cystadenoma / adenofibroma

Definition

Endometrioid cystadenoma is a cystic lesion lined by benign endometrioid epithelium lacking the stroma, typical vasculature and other stigmata of endometriosis. When associated with a dense fibromatous component the tumour is an endometrioid adenofibroma.

Endometrioid borderline tumour/ Atypical proliferative endometrioid tumour

Definition

A solid or cystic tumour composed of crowded glands lined by atypical endometrioid-type cells and lacking destructive stromal invasion and/or confluent glandular growth.

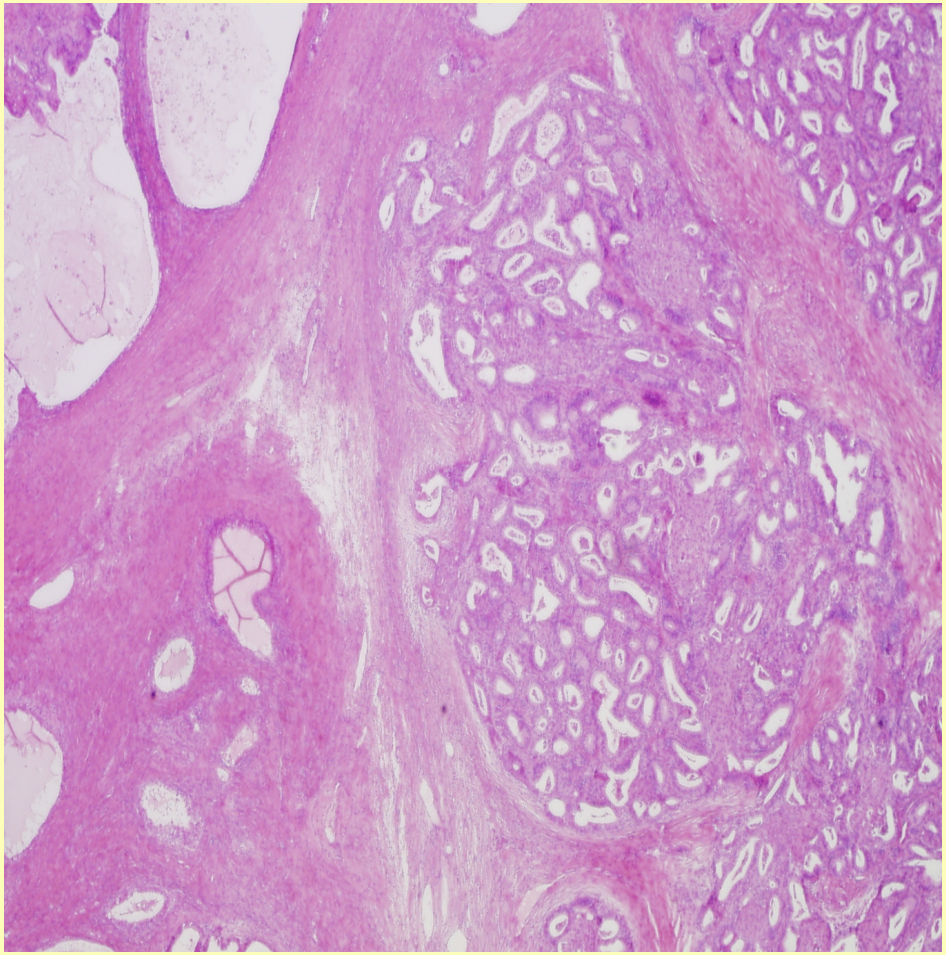

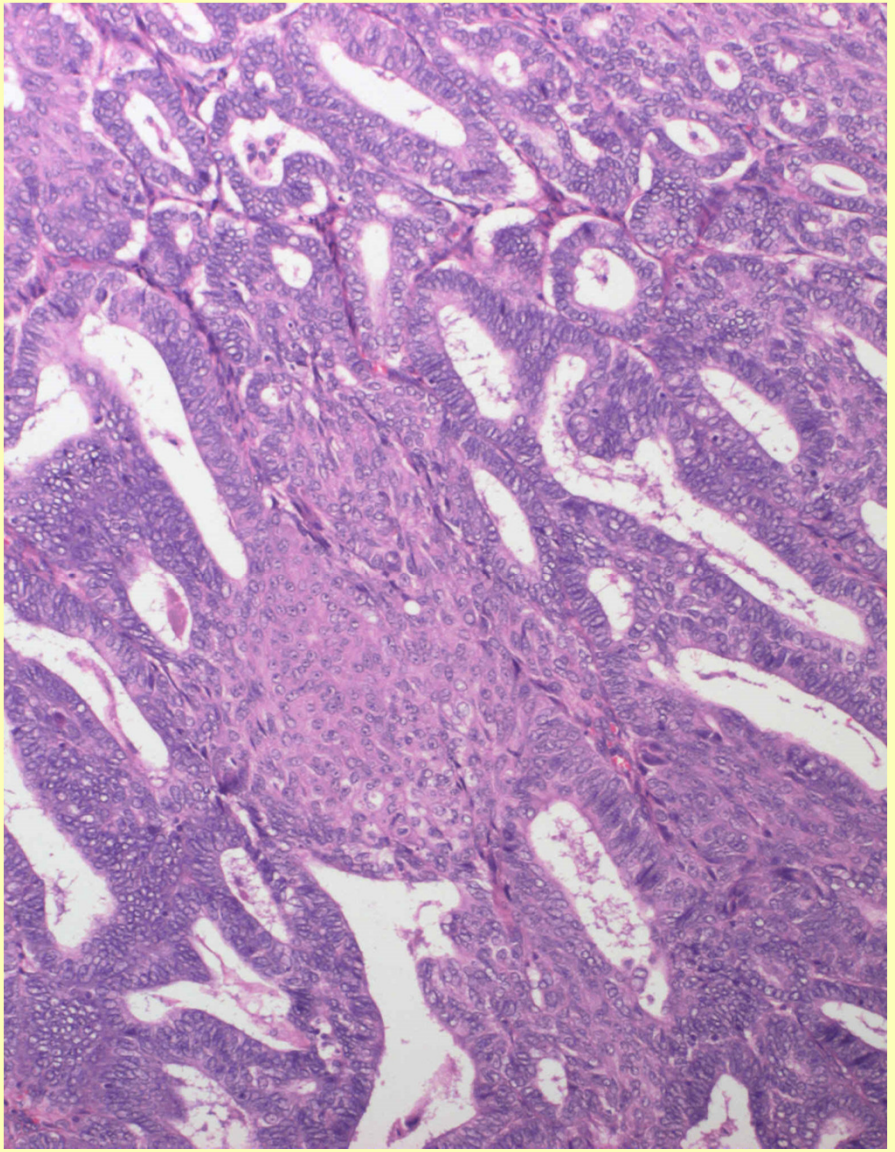

ENDOMETRIOID CARCINOMA OF THE OVARY (Definition)

A malignant epithelial tumor of the ovary that closely resembles the common variants of endometrioid carcinoma of the uterus

WHO, 2003

ENDOMETRIOID CARCINOMA OF THE OVARY (Clinical Features)

- Less than 10% of ovarian cancers (15-20% in older literature)
- Perimenopausal women
- Bilateral (28%)
- Early stages
- Associated with ipsilateral or pelvic endometriosis (40%)
- Associated with uterine endometriosis (10-20%)

ENDOMETRIOID CARCINOMA OF THE OVARY (Pathology)

- **Solid growth, occasionally coexisting with an endometriotic cyst or an adenofibroma**
- **mimic uterine counterpart**
- **Usually low grade (but not always)**
- **Squamous differentiation**
- **Spindle cell pattern and Sex cord like features may be present**

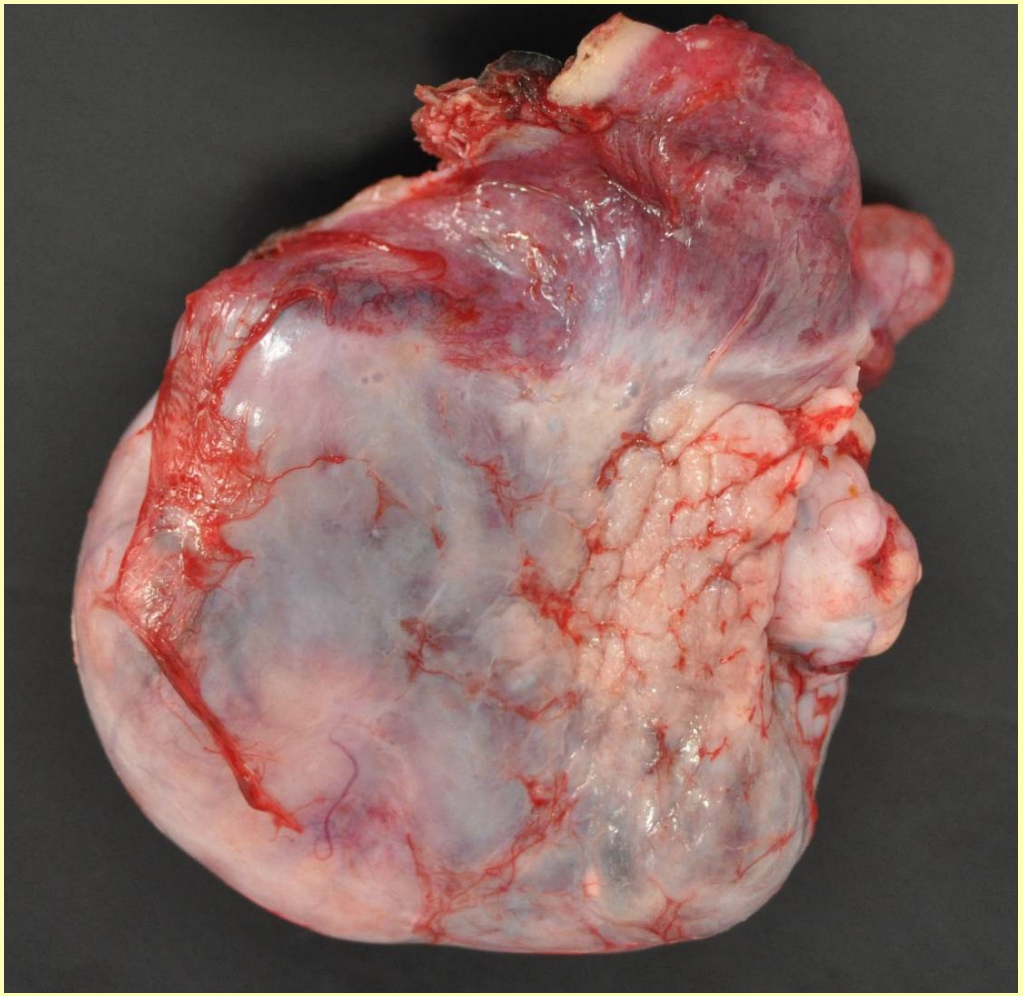

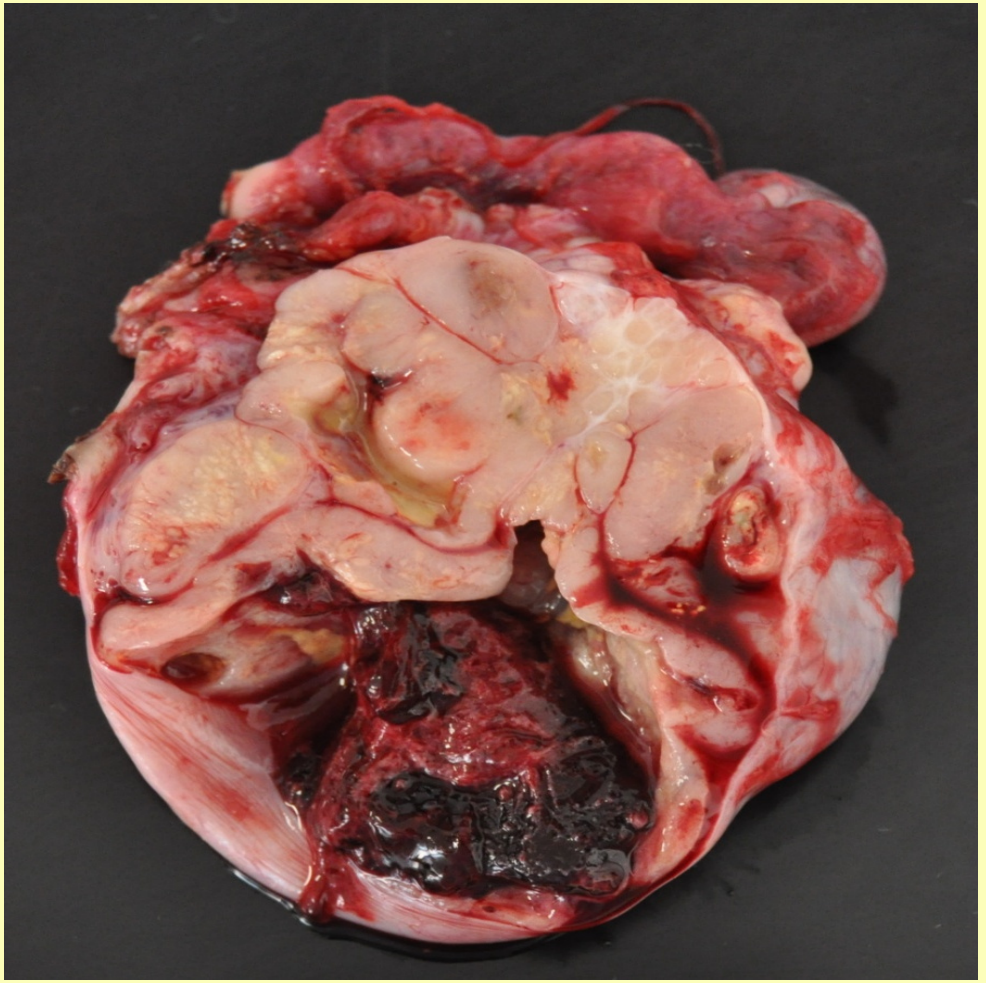

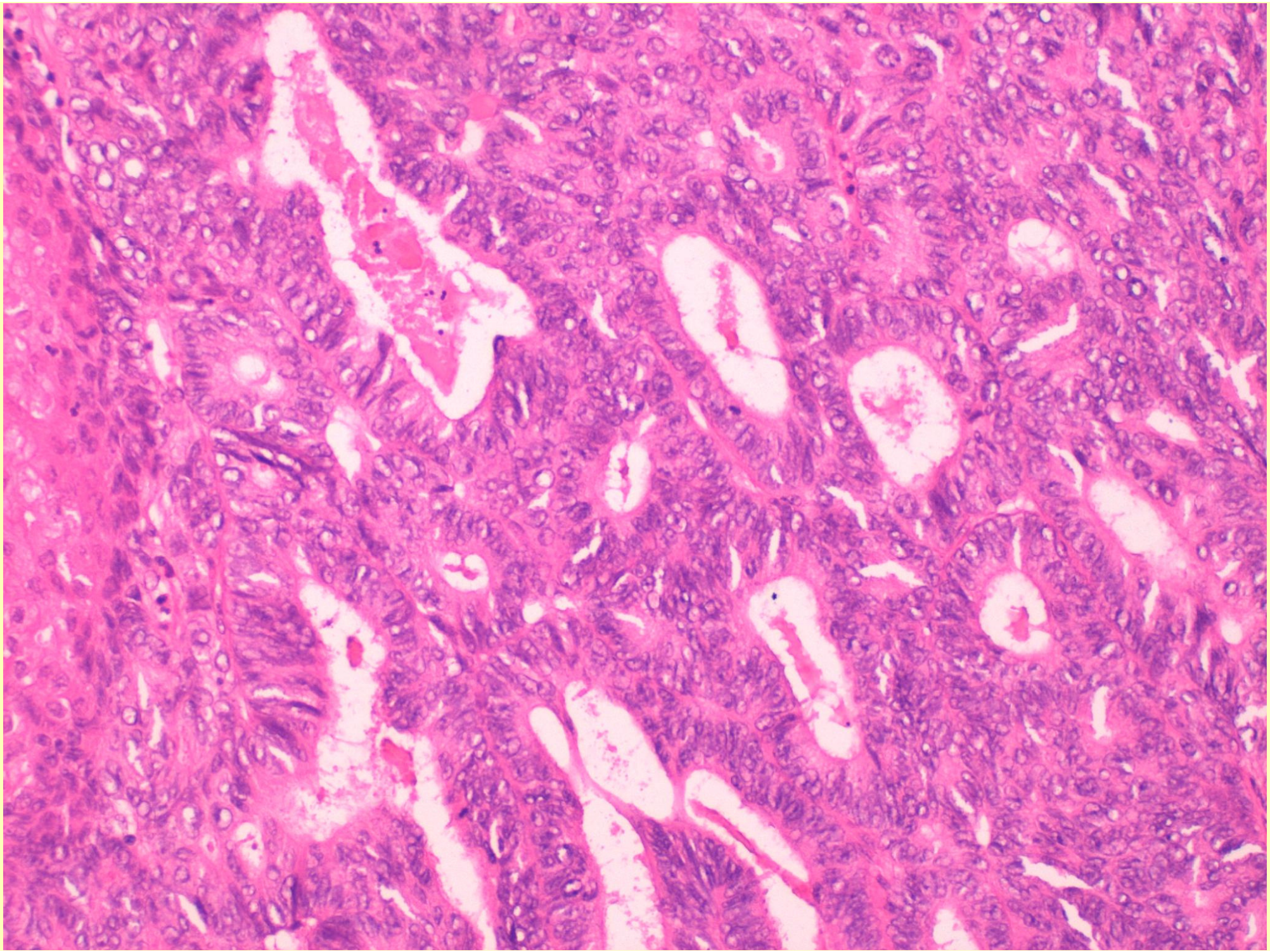

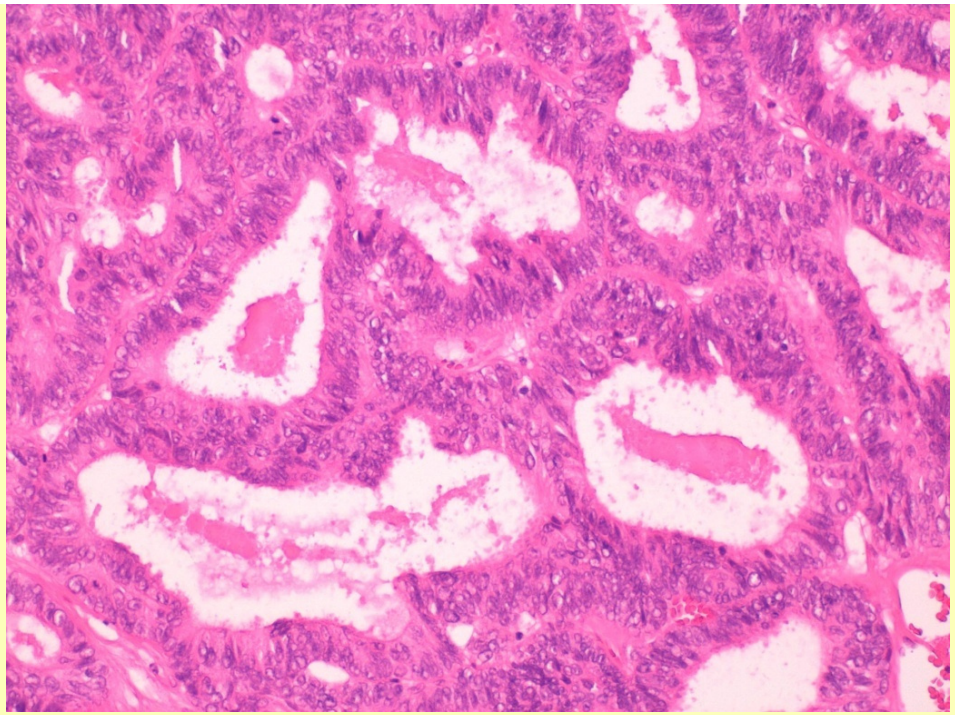

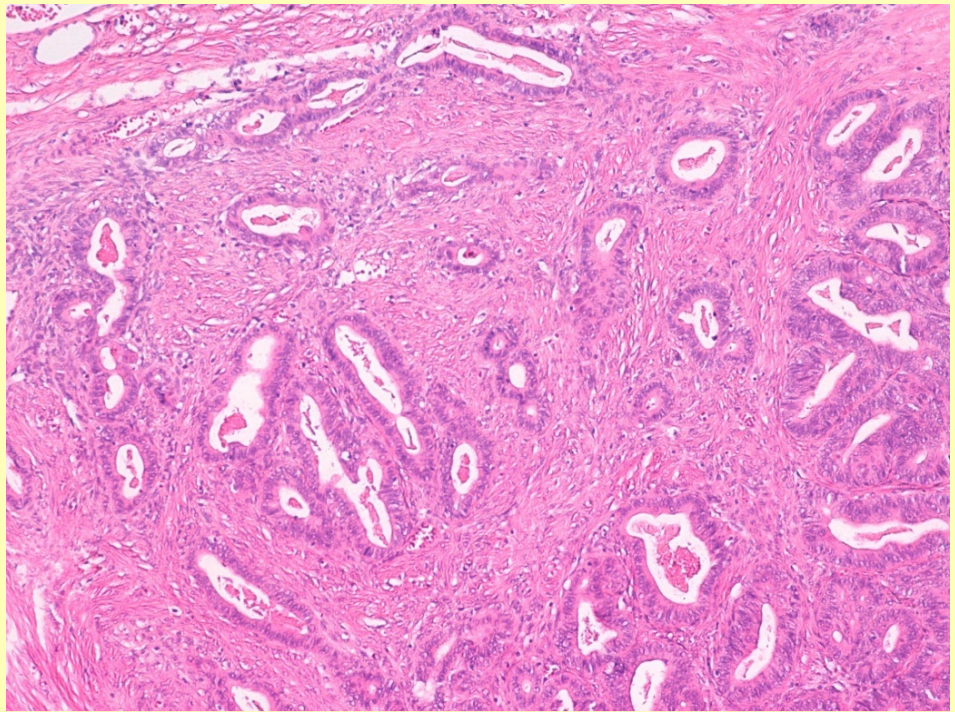

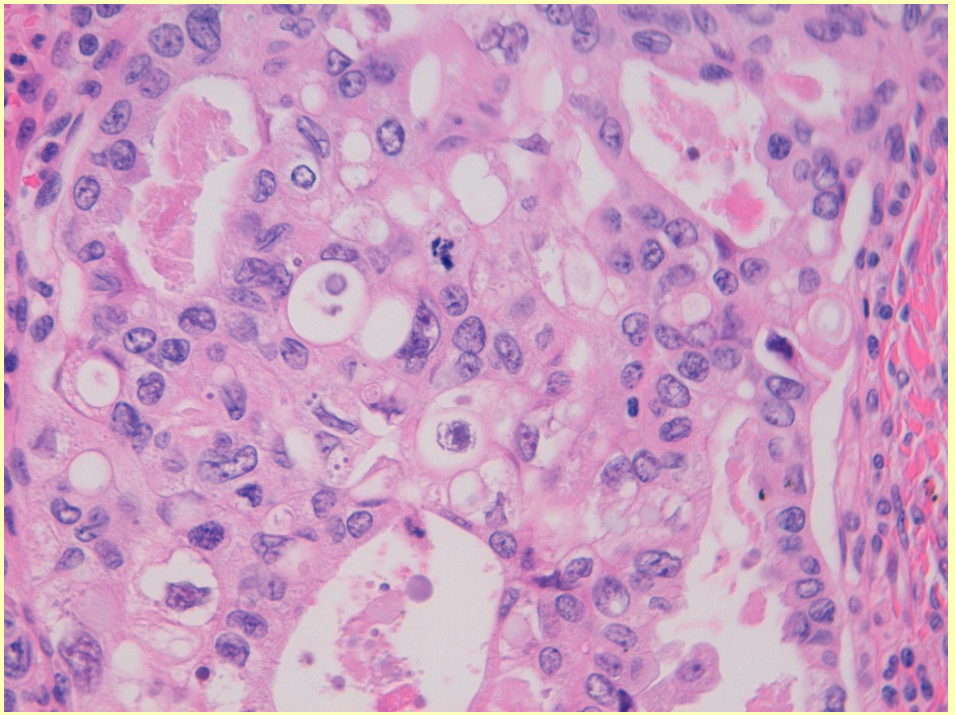

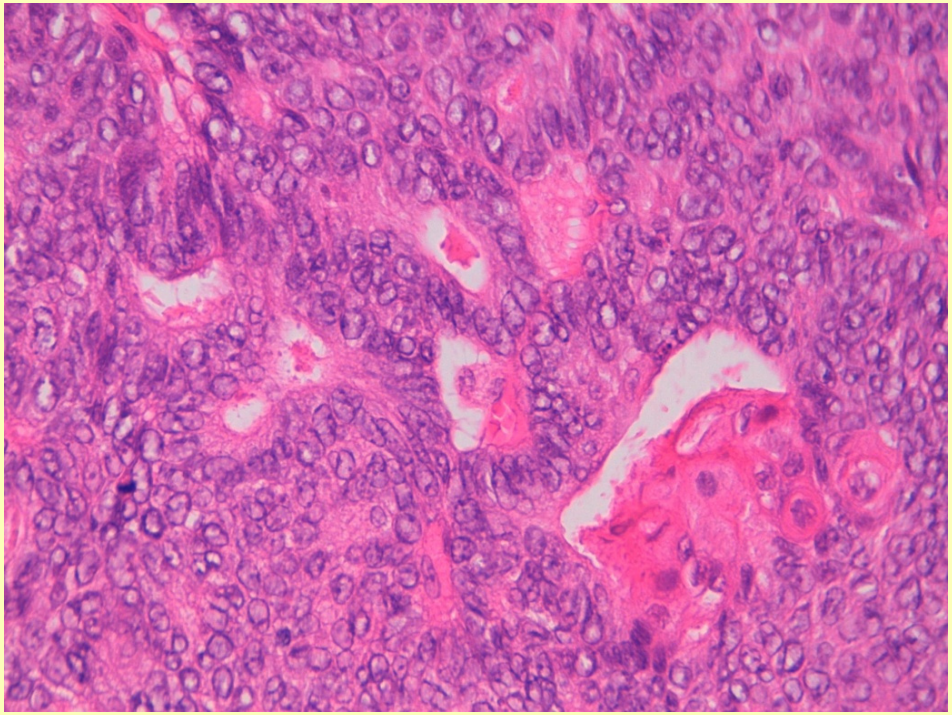

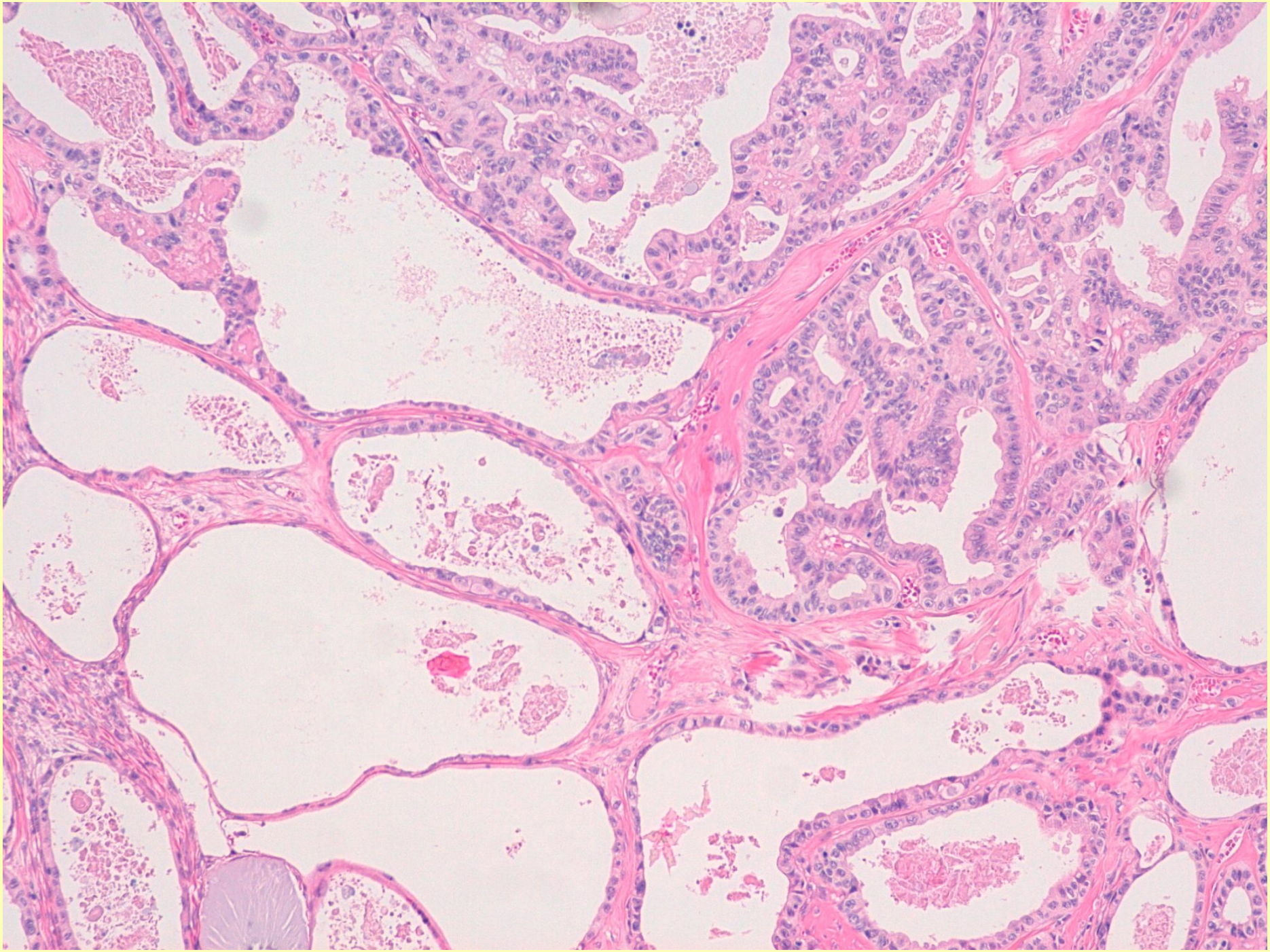

ENDOMETRIOID CARCINOMA OF THE OVARY

(Expansile versus destructive invasion)

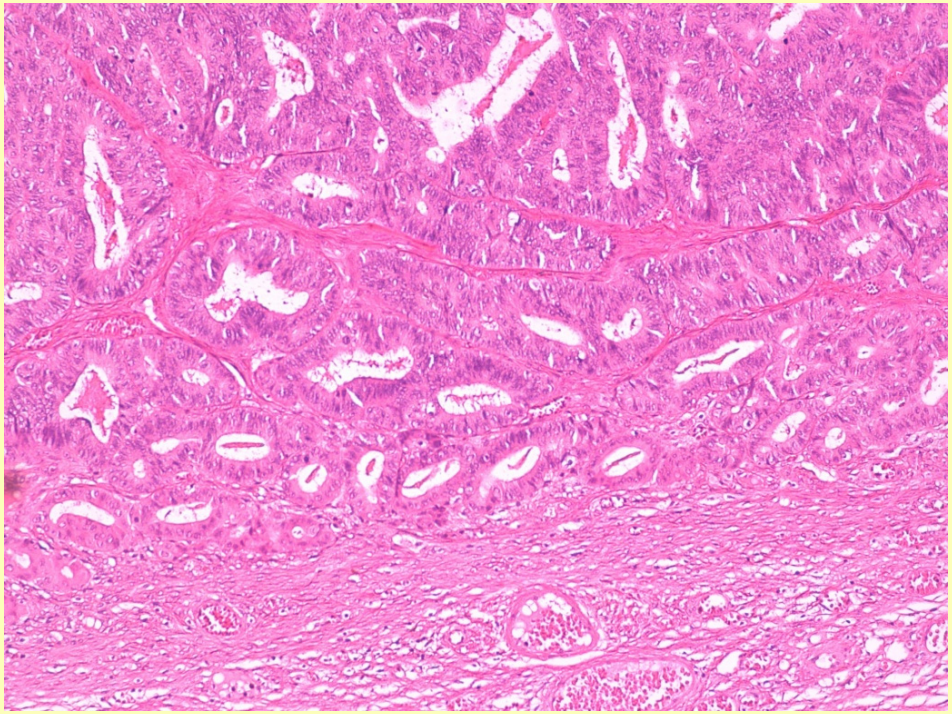

EXPANSILE INVASION

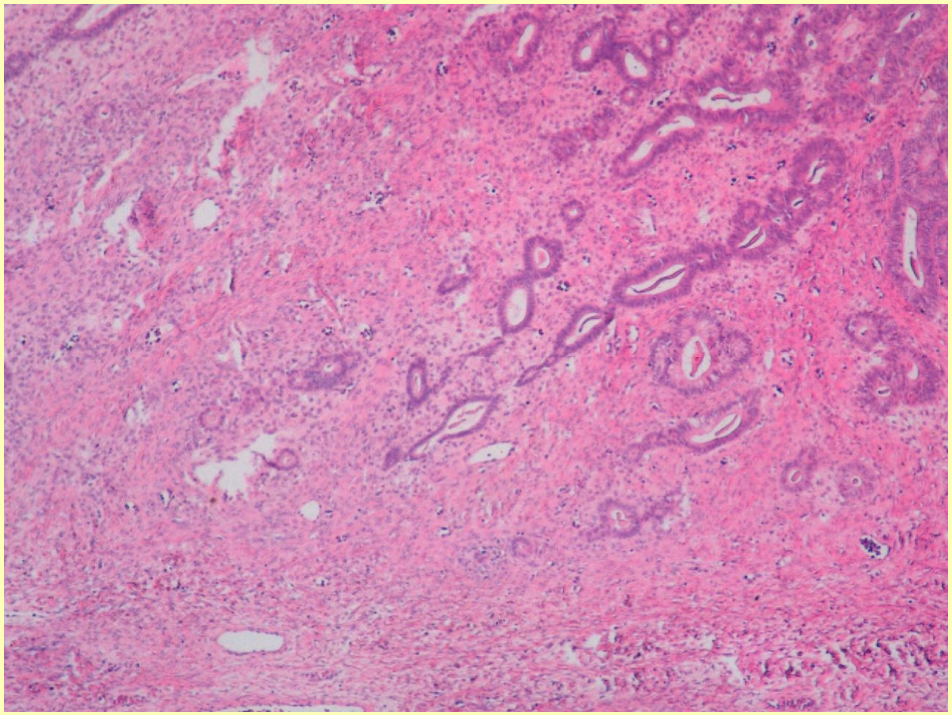

DESTRUCTIVE INVASION

ENDOMETRIOID CARCINOMA OF THE OVARY

(Expansile versus destructive invasion)

Chen S, Leitao MM, Tornos C, Soslow RA. Modern Pathology 2005 18:903-11.

Bell KA, Kurman RJ. Am J Surg Pathol. 2000 24:1465-79

Roth LM, Emerson RE, Ulbright TM, Am J Surg Pathol. 2003 27:1253-9

Keratin granulomas in the peritoneum

- **In endometrioid adenocarcinomas with squamous differentiation**
- **Aggregates of keratin (no viable cancer cells) surrounded by macrophages and foreing body giant cells.**
- **No prognostic significance**

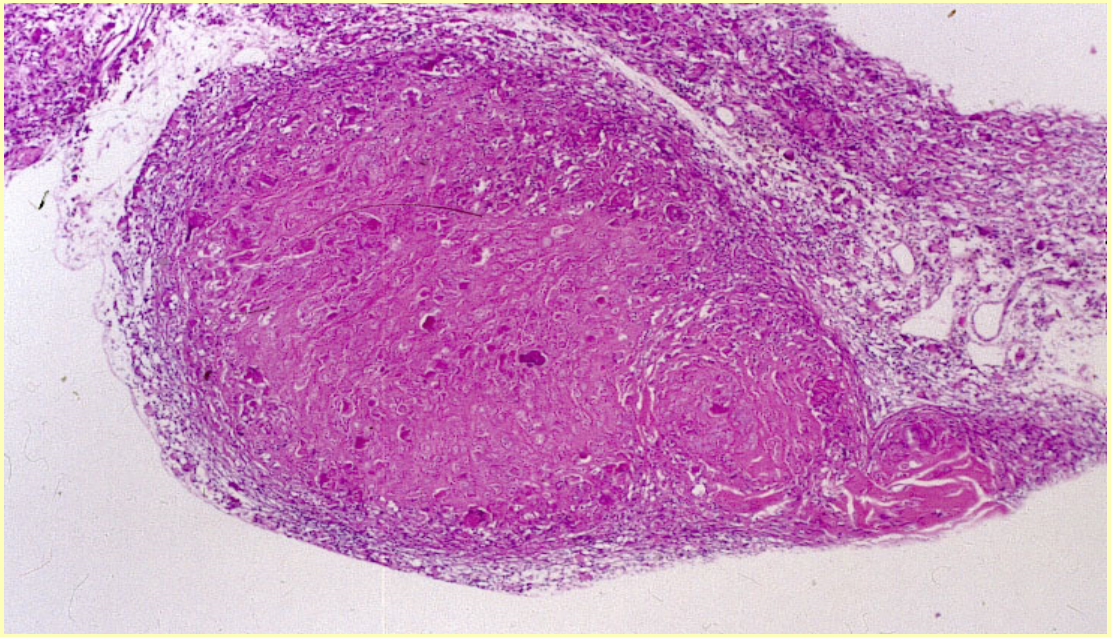

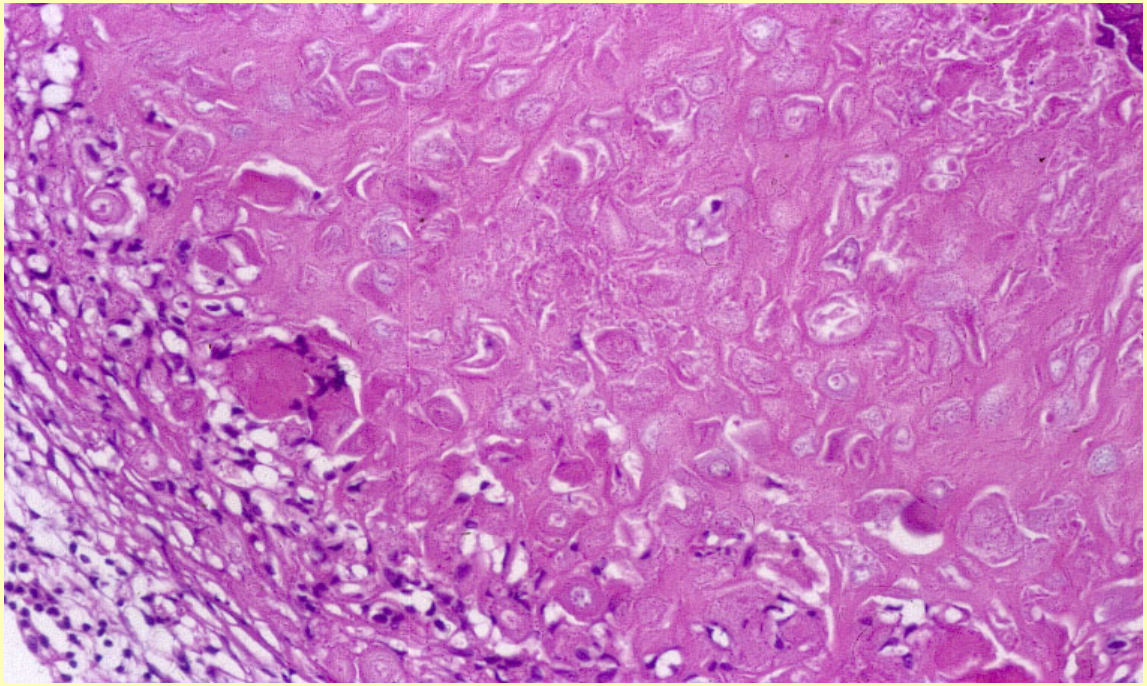

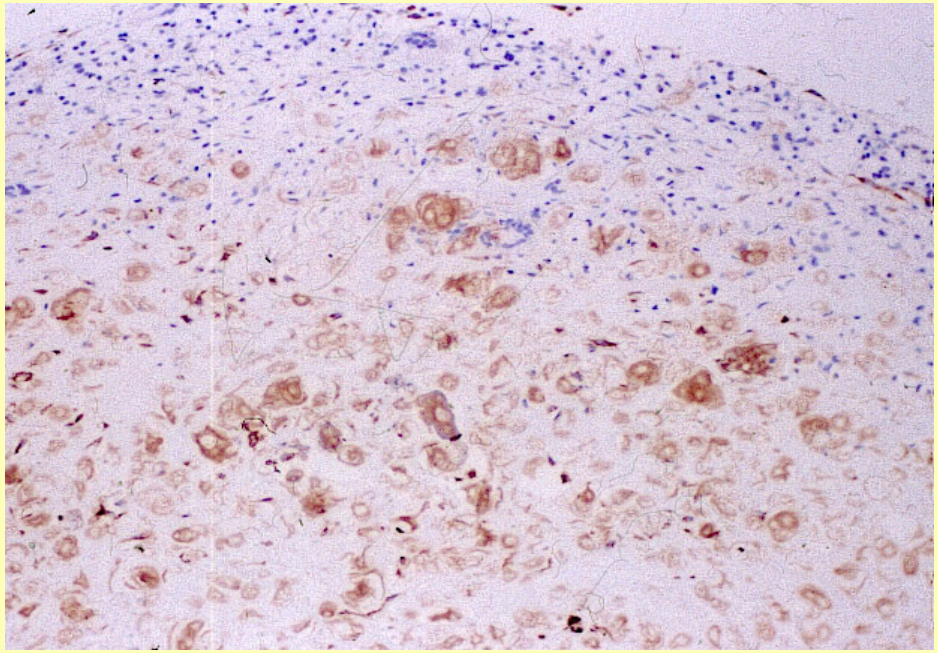

Endometrioid carcinoma (Histological Grade, FIGO)

- Grade 1 < 5% solid
- Grade 2 6 – 50% solid
- Grade 3 > 50% solid

- Squamous areas should not be considered
- High nuclear features increase grade by one

ENDOMETRIOID CARCINOMA OF THE OVARY (Differential Diagnosis)

- **Serous carcinoma**
- **Metastatic tumors**
- **Sex-cord stromal tumors**
- **Carcinoid**

ENDOMETRIOID CARCINOMA OF THE OVARY (Differential Diagnosis with serous carcinoma)

- **Low histological grade**
- **Round glands instead of slit-like spaces**
- **Squamous differentiation**
- **Adenofibromatous pattern**
- **Broad papillae**

The vast majority of mixed serous-endometrioid carcinomas are high grade serous carcinomas with glandular pattern

OVARIAN CARCINOMA (BRCA-1/2)

BRCA-1 LOH and promoter hypermethylation and BRCA-2 LOH are seen in high grade serous, endometrioid, and mixed endometrioid-serous carcinomas

Garcia A, Bussaglia E, Machin P, Matias-Guiu X, Prat J: Int J Gynecol Pathol 2000 19:152-157
Esteller M, Silva JM, Dominguez G et al: J Natl Cancer Inst 2000 92:564-9
Gras E, Cortes J, Diez O, Alonso C, Matias-Guiu X, Baiget M, Prat J, Cancer. 2001 92:787-95.

Morphologic patterns associated with *BRCA1* and *BRCA2* genotype in ovarian carcinoma

Robert A Soslow[1], Guangming Han[2], Kay J Park[1], Karuna Garg[1], Narciso Olvera[1], David R Spriggs[3], Noah D Kauff[3,4] and Douglas A Levine[5]

Modern Pathology (2012) **25**, 625–636;

Table 1 Summary of morphologic characteristics of the training set organized by genotype

	Tumor-infiltrating lymphocytes per high-power field, median (range)	*Mitotic index, median (range)*	*Solid, pseudoendometrioid, and transitional cell carcinoma-like (SET) features*	*Necrosis*	*Nuclear pleomorphism*	*Fallopian tube involvement*
BRCA1 germline ($n=4$)	31 (10–69)	52 (40–71)	2/4	3/4	2/4	1/1
BRCA1 somatic ($n=6$)	29 (5–62)	64 (19–105)	4/6	3/6	3/6	5/5
BRCA1 methylated ($n=13$)	52 (13–88)	60 (17–102)	10/13	7/13	7/13	4/5
BRCA2 germline ($n=4$)	19 (5–43)	62 (8–126)	4/4	4/4	4/4	3/3
BRCA2 somatic ($n=4$)	16 (12–60)	35 (12–60)	2/4	0/4	3/4	2/2
BRCA unassociated ($n=12$)	29 (2–140)	37 (15–94)	2/12	2/12	3/12	6/10
P-value[a]	0.034[b]	0.012[b]	0.0045	0.034	0.16	0.65
Overall ($n=43$)	36 (mean) 29 (median)	53 (mean) 51 (median)	24/43	19/43	21/43	21/26

Diagnosis of Ovarian Carcinoma Cell Type is Highly Reproducible

A Transcanadian Study

Martin Köbel, MD, Steve E. Kalloger, BSc,† Patricia M. Baker, MD,‡ Carol A. Ewanowich, MD,§ Jocelyne Arseneau, MD,‖ Viktor Zherebitskiy, MD,‡ Soran Abdulkarim, MD,¶ Samuel Leung, MSc,† Máire A. Duggan, MD,* Dan Fontaine, MD,¶ Robin Parker, MD,# David G. Huntsman, MD,† and C. Blake Gilks, MD, FRCPC†*

(*Am J Surg Pathol* 2010;34:984–993)

TABLE 1. Information Provided to Study Pathologists as an Aid in Interpretation of Immunostaining Data for the Test Set Cases

	ER (%)	HNF-1β (%)	Mammoglobin B (%)	Mesothelin (%)	MUC5 (%)	p16 (%)	p53 (%)	Vimentin (%)	WT1 (%)	Ki-67 (Median, 95% CI) (%)
Low-grade serous	80	0	10	82	0	0	20	64	70	2 (0.5-20)
High-grade serous	76	5	15	80	4	56	50	25	80	22 (4-70)
Clear cell				33	7					8 (1-27)
Endometrioid	77	8	58	26	18	6	10	61	3	8 (1-49)
Mucinous				0	73					13 (2-61)

ENDOMETRIOID CARCINOMA OF THE OVARY (Differential Diagnosis with serous carcinoma)

- **WT-1**
- **Estrogen and Progesterone receptor**
- **P53**
- **Beta-catenin**
- **P16**
- **Vimentin**

High-grade Endometrioid Carcinoma of the Ovary

A Clinicopathologic Study of 30 Cases

Hisham Assem, MD, Peter F. Rambau, MD,*† Sandra Lee, MD,* Travis Ogilvie, MD,* Anna Sienko, MD,* Linda E. Kelemen, ScD,‡§ and Martin Köbel, MD**

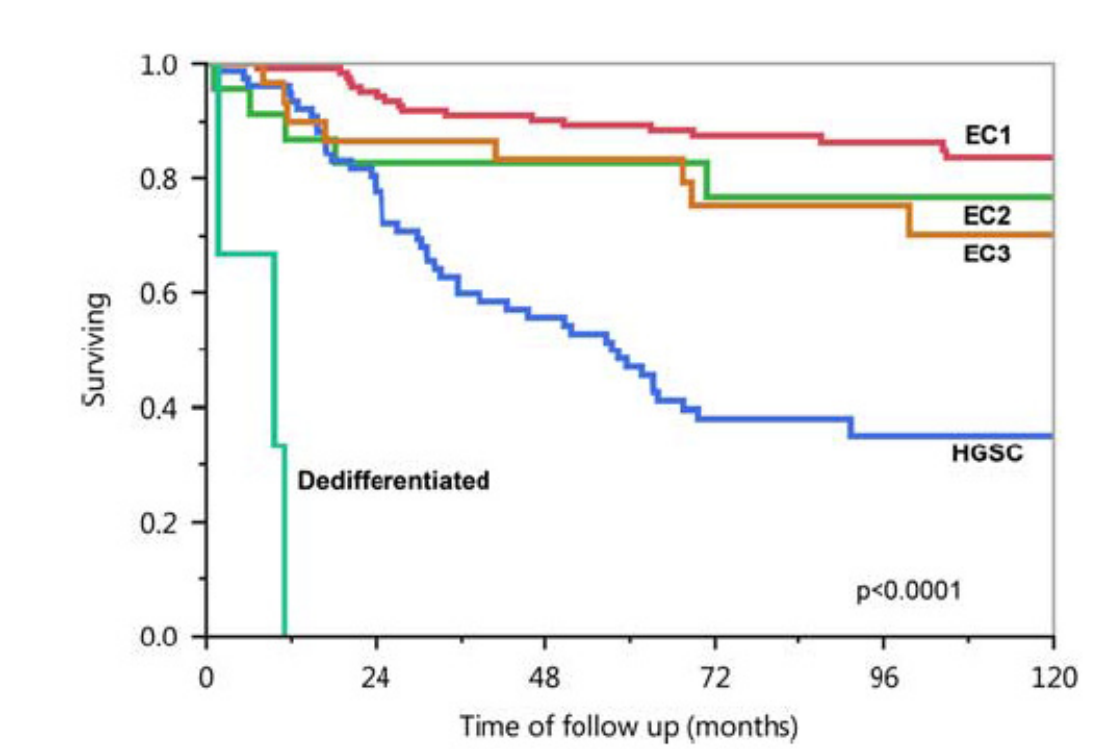

TABLE 3. Distribution of Grade 3 Endometrioid and High-grade Serous Carcinomas Across Immunohistochemical WT1 and p53 Status

	WT1 Absent	WT1 Present
TP53 normal	18 EC3 0 HGSC	2 EC3 3 HGSC
TP53 abnormal	8 EC3 3 HGSC	1 EC3 75 HGSC

EC3 indicates endometrioid carcinoma, grade 3; HGSC, high-grade serous carcinoma.

ENDOMETRIOID CARCINOMA OF THE OVARY (Differential Diagnosis with sex-cord stromal tumors)

- **Age, and presence of hormonal symptoms**
- **Bilaterality and pattern of metastatic spread**
- **Squamous elements and adenofibromatous pattern**
- **Endometriosis or obvious endometrioid elements**

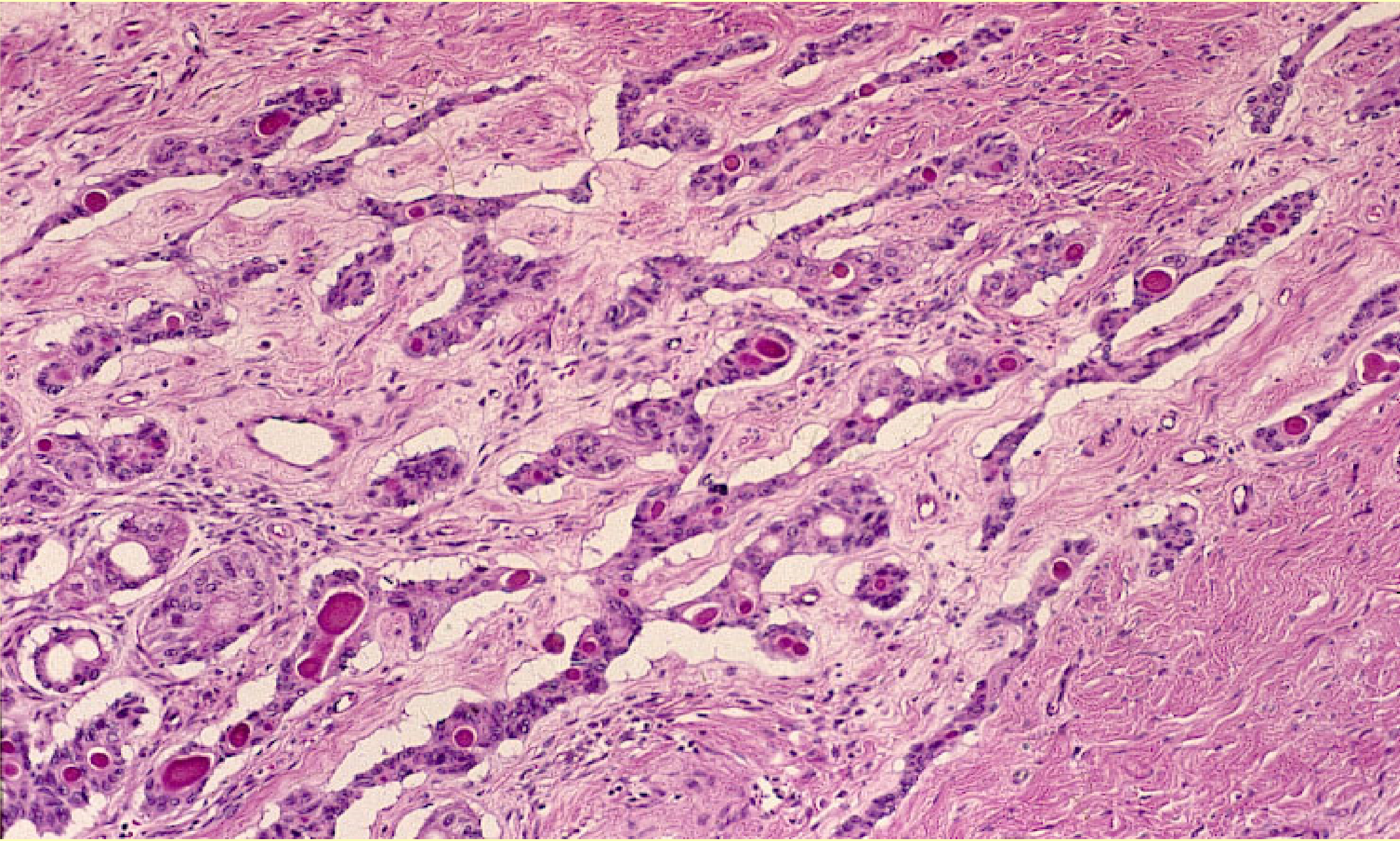

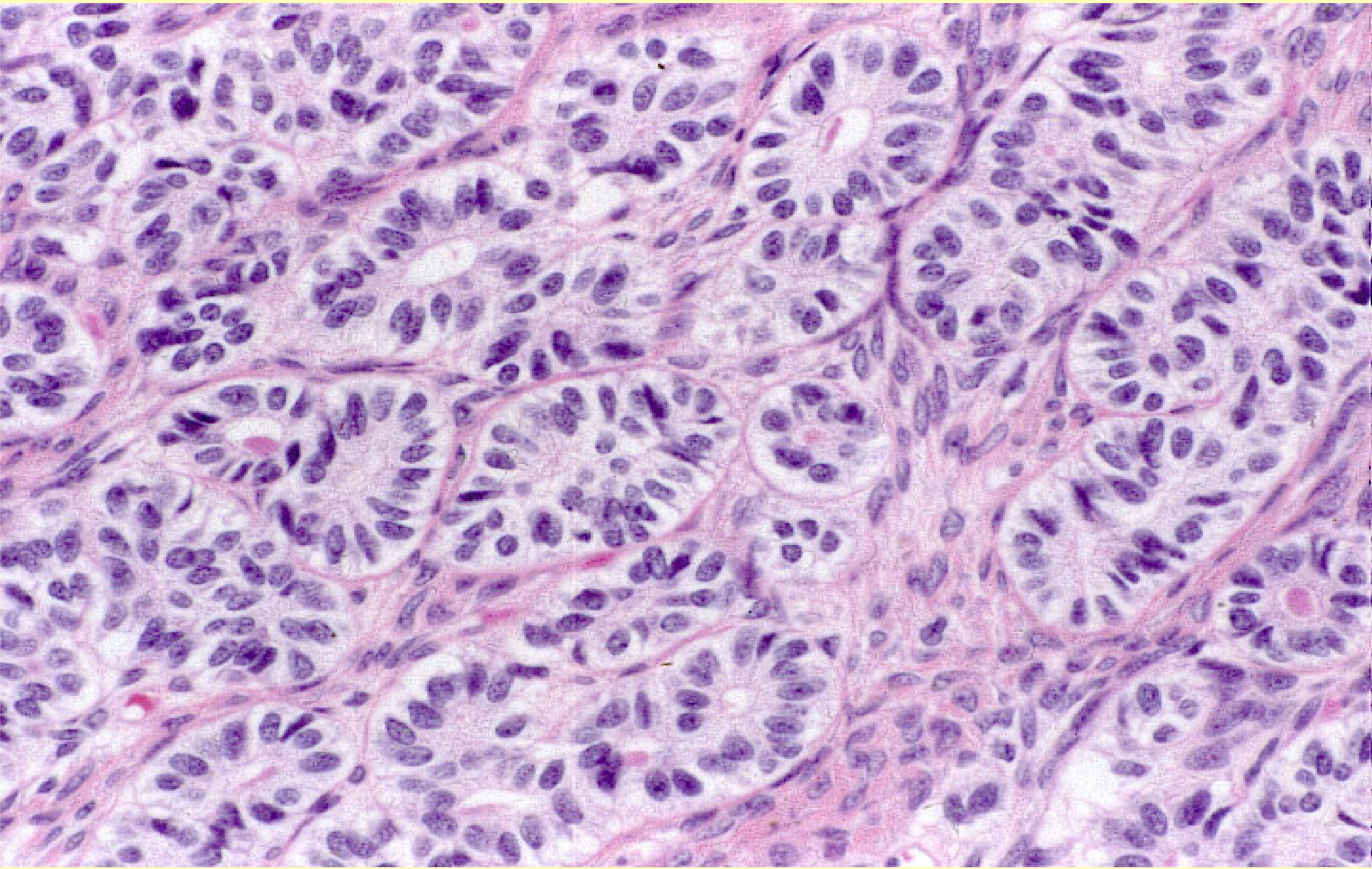

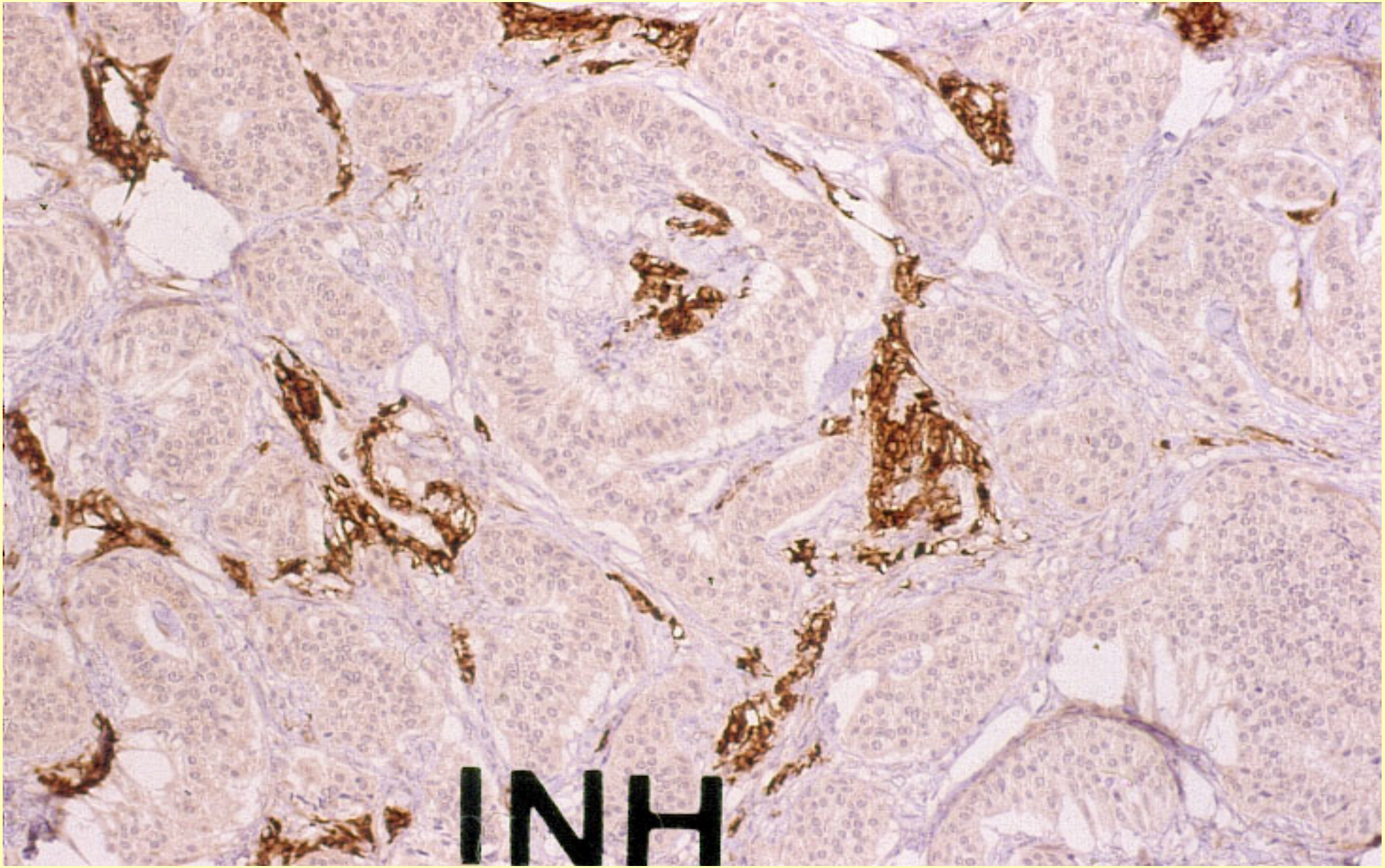
INH

ENDOMETRIOID CARCINOMA OF THE OVARY (Differential Diagnosis with metastatic carcinoma)

- **Bilaterality, and nodular pattern**
- **Infiltrative pattern with desmoplasia,and single cell infiltration**
- **Endometriosis and adenofibromatous areas**
- **Low grade and squamous elements**
- **Lymphovascular invasion, and extensive intraabdominal spread**

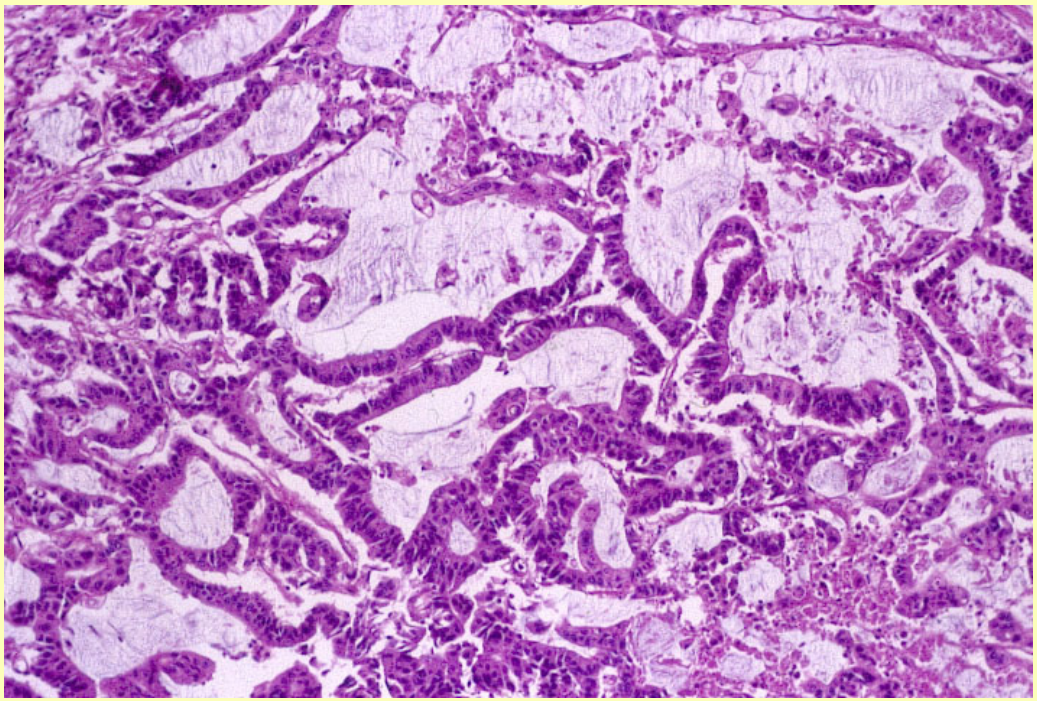

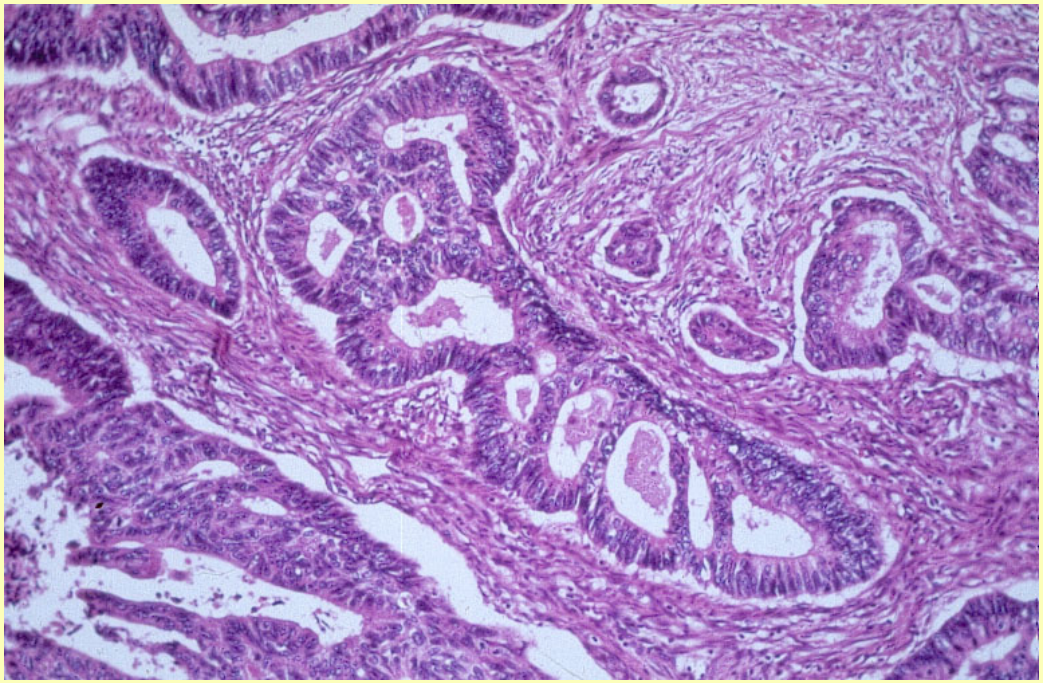

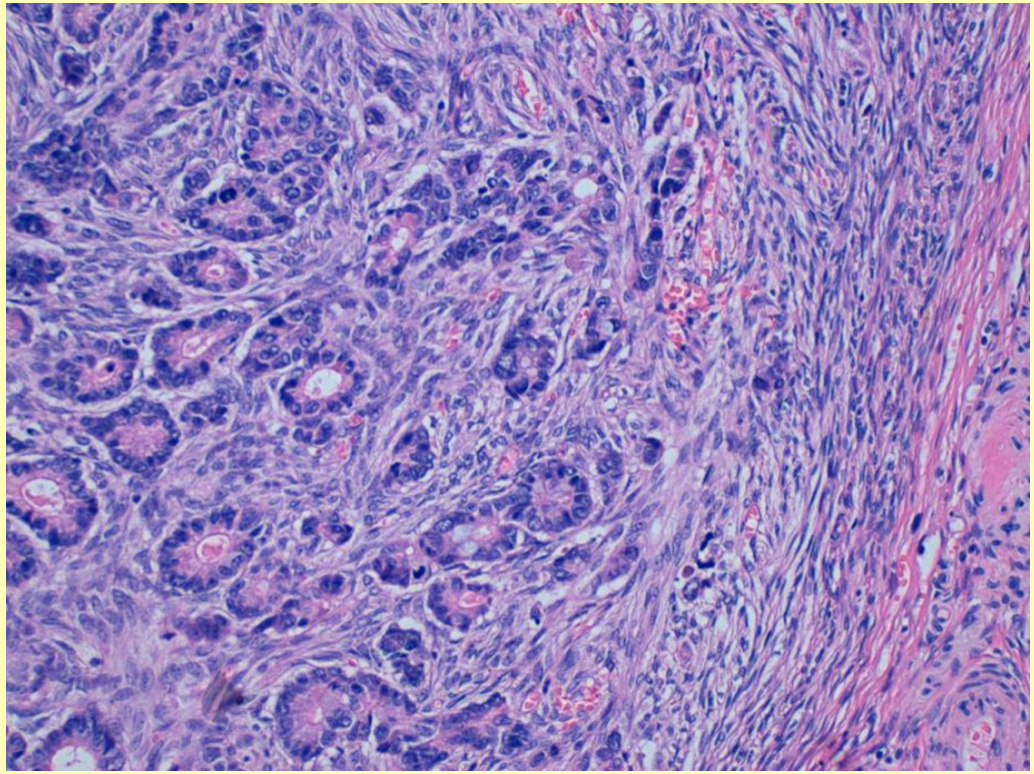

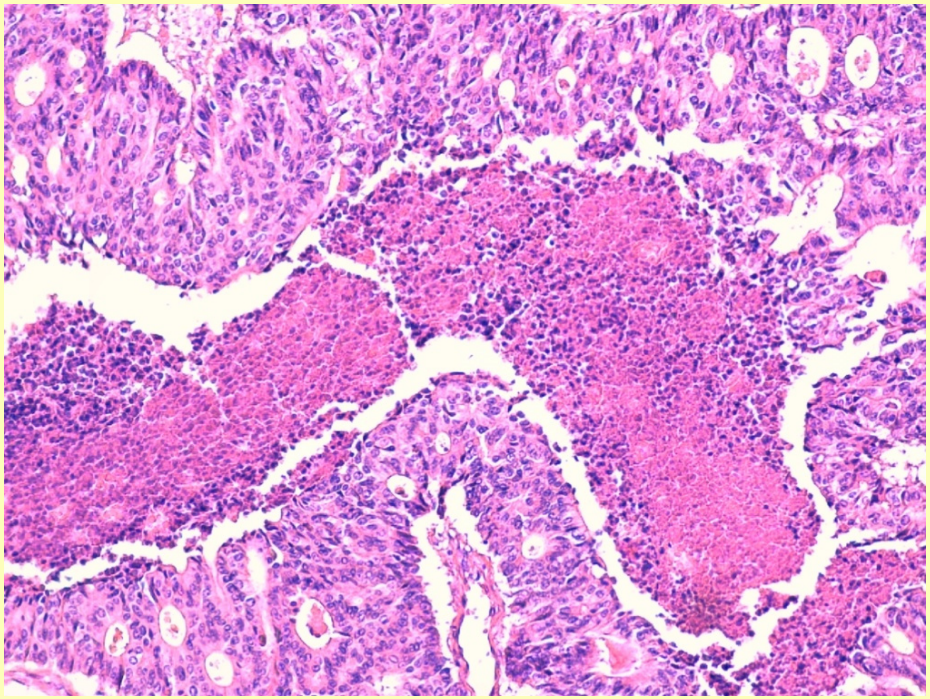

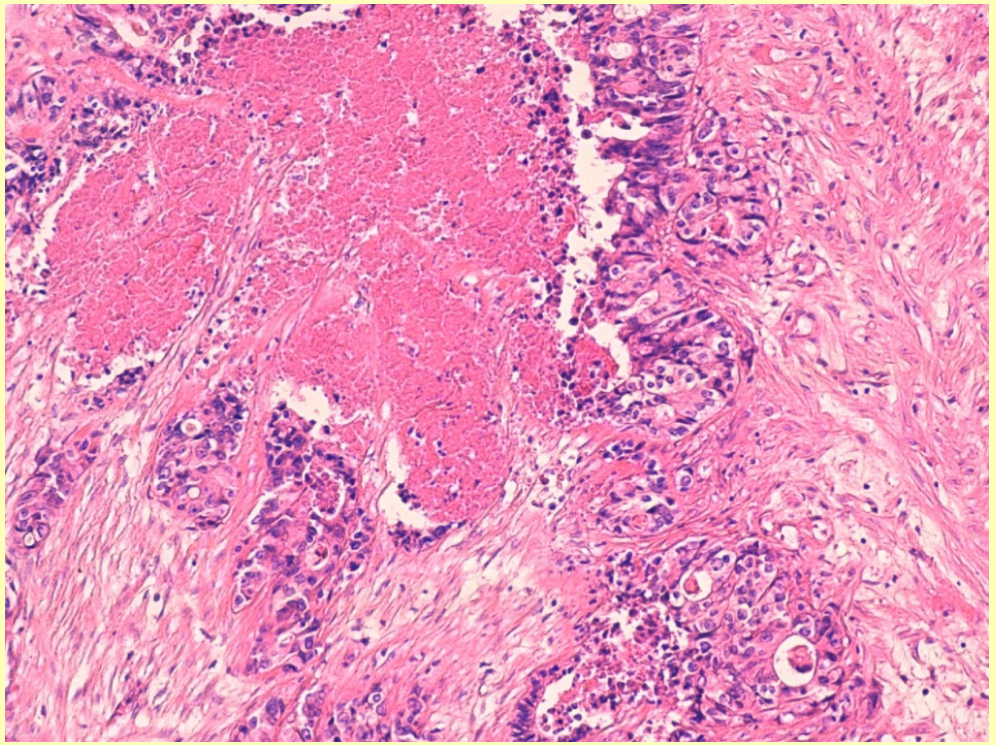

METASTATIC COLON CANCER (GI tract markers)

- **CK7 - / CK20 +, but right sided colon cancers may express CK7, and primary mucinous ovarian cancers may be patchy CK20+.**
- **Villin (sensitive for colon ca)**
- **CDX-2 (sensitive for colon ca; occasionally positive in mucinous ovarian adenoca)**
- **P504S**
- **Beta-Catenin**

OVARIAN CARCINOID

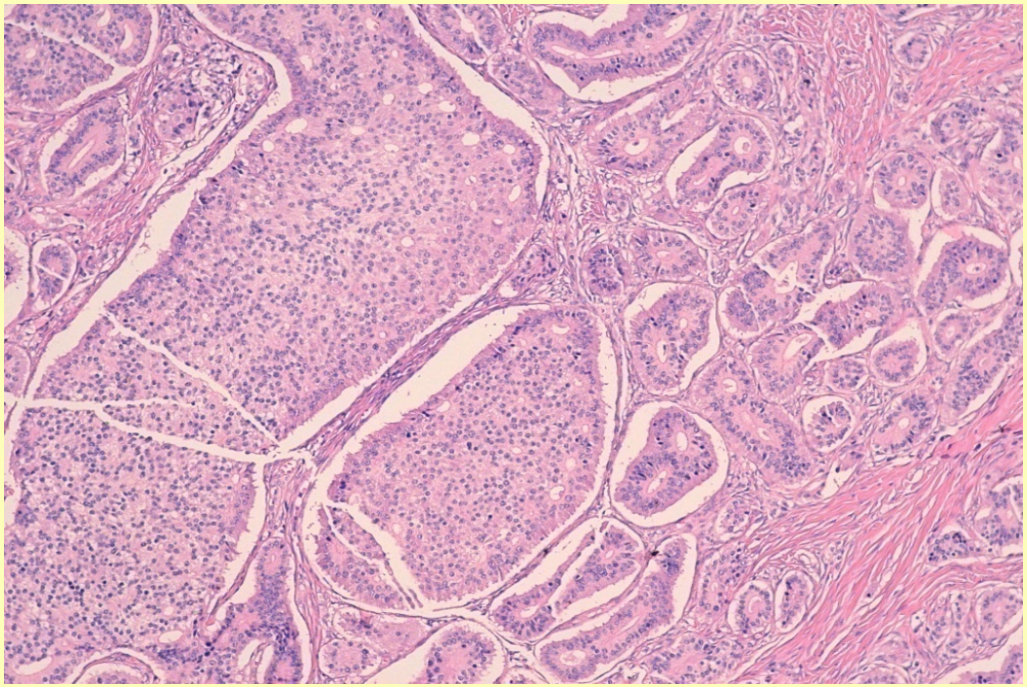

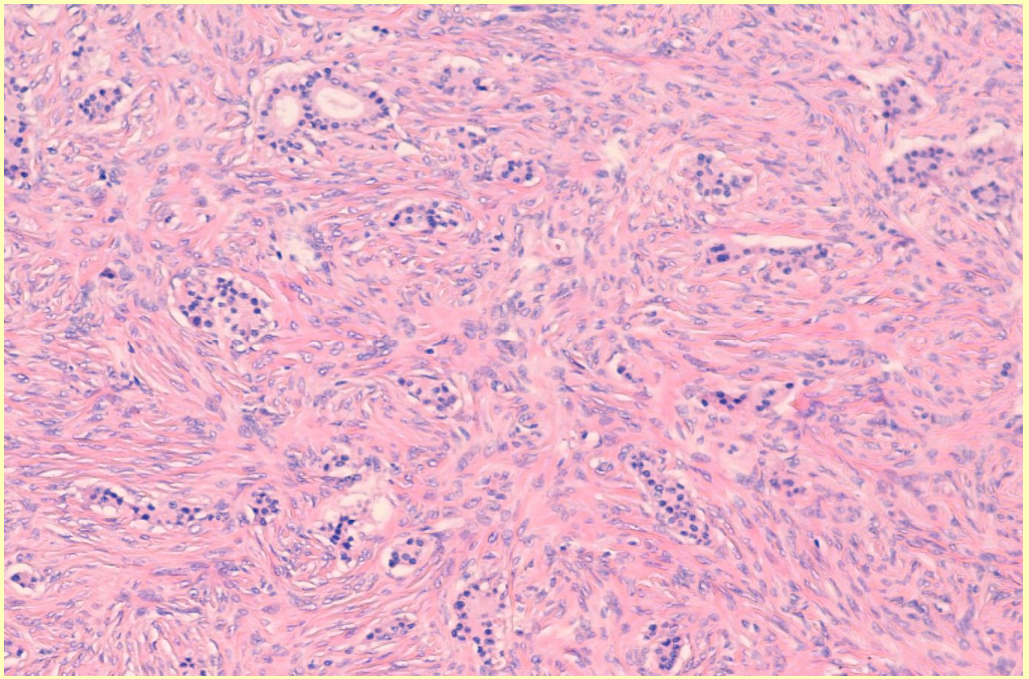

ENDOMETRIOID CARCINOMA OF THE OVARY WITH A SOMATIC GERM-CELL COMPONENT

A Germ-cell component (frequently Yolk-sac) may develop in an endometrioid carcinoma

ENDOMETRIOID CARCINOMA OF THE OVARY WITH A SOMATIC GERM-CELL COMPONENT

- **Adults**
- **Endometrioid or clear cell carcinomas**
- **Typical Yolk-sac elements**
- **Enteric differentiation (subnuclear vacuoles)**
- **Germ-cell markers**

Rutgers JL, Young RH, Scully RE.
Ovarian yolk sac tumor arising from an endometrioid carcinoma.
Hum Pathol. 1987 18:1296-9.

Nogales FF, Bergeron C, Carvia RE, Alvaro T, Fulwood HR.
Ovarian endometrioid tumors with yolk sac tumor component, an unusual form of ovarian neoplasm. Analysis of six cases.
Am J Surg Pathol. 1996 20:1056-66

Histopathology 2012, **60**, 1023–1033. DOI: 10.1111/j.1365-2559.2011.03889.x

REVIEW

Yolk sac tumours revisited. A review of their many faces and names

Francisco F Nogales, Ovidiu Preda & Alina Nicolae

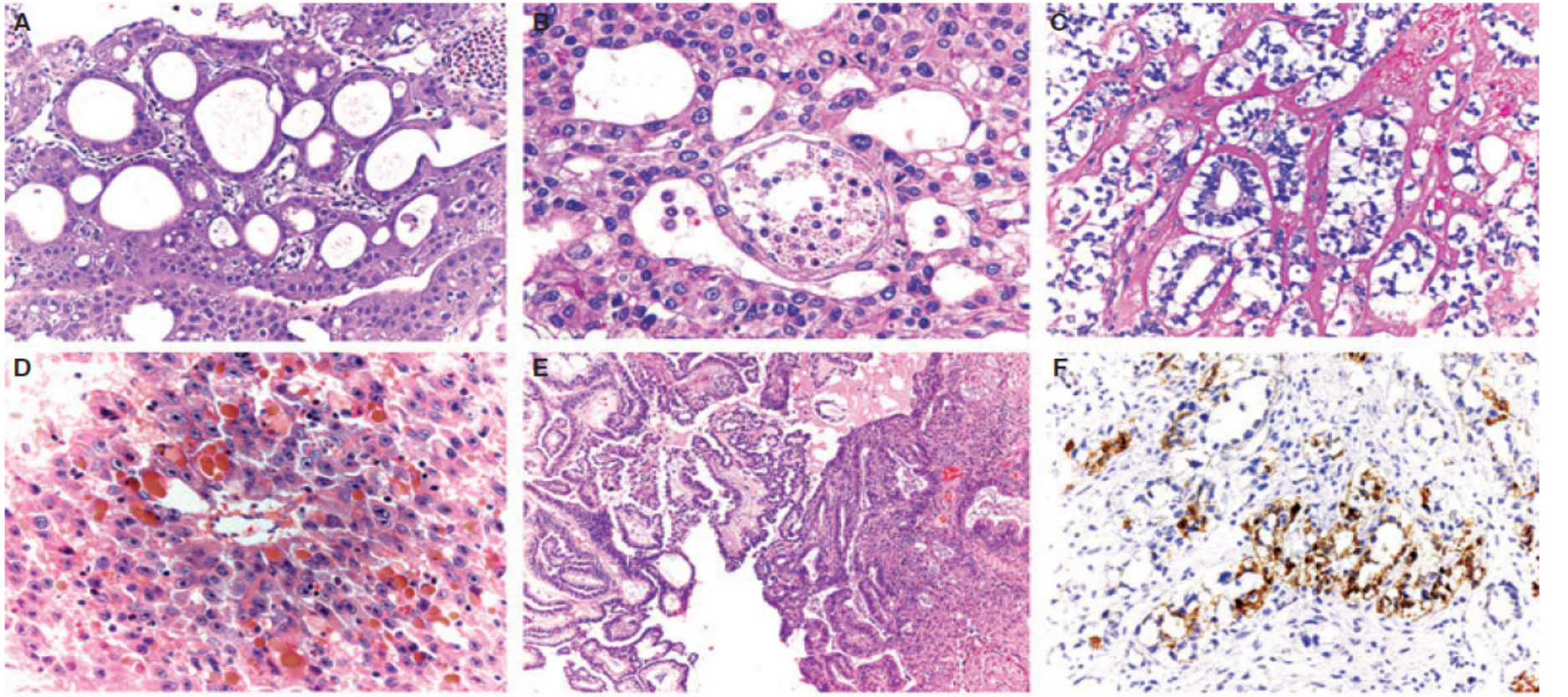

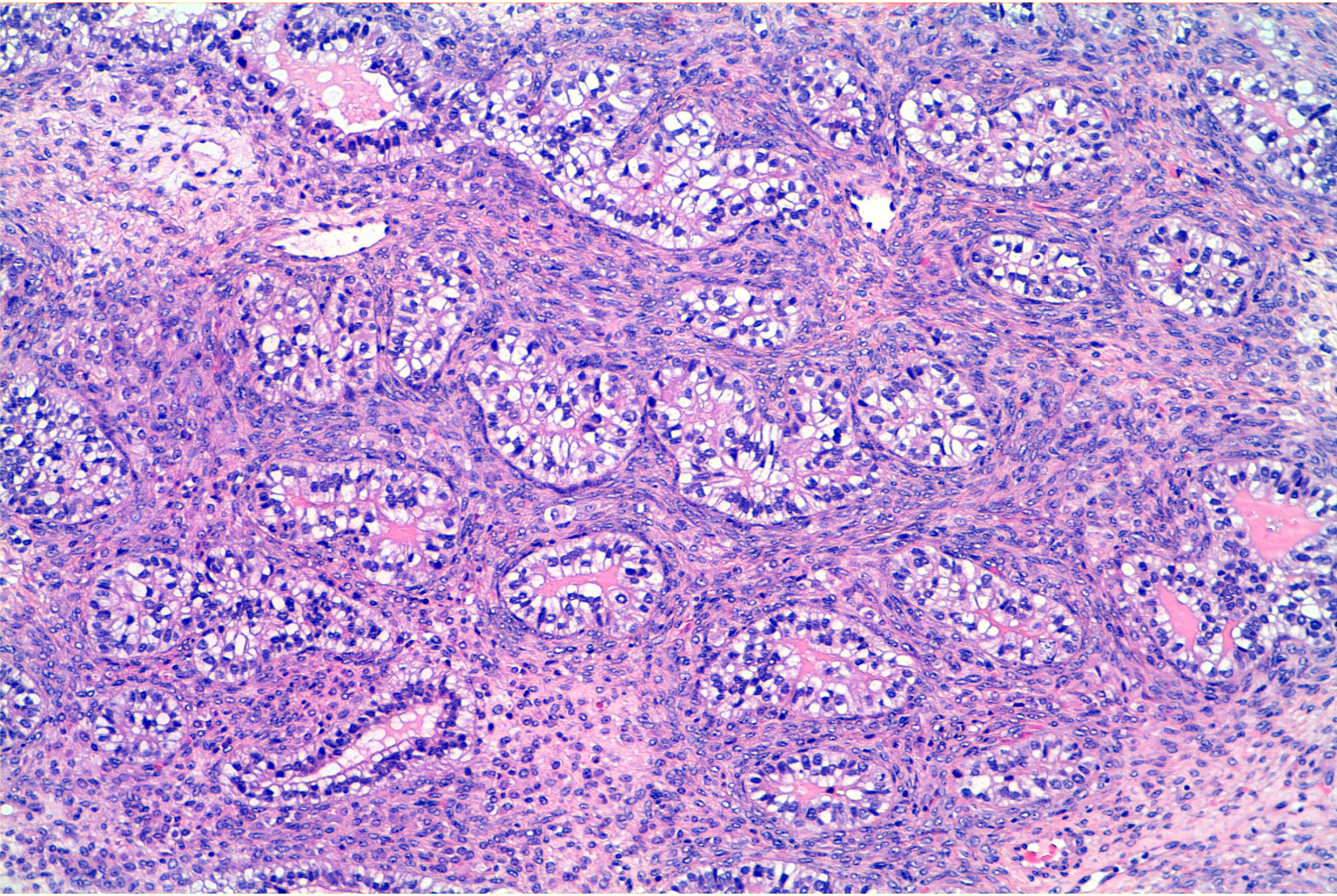

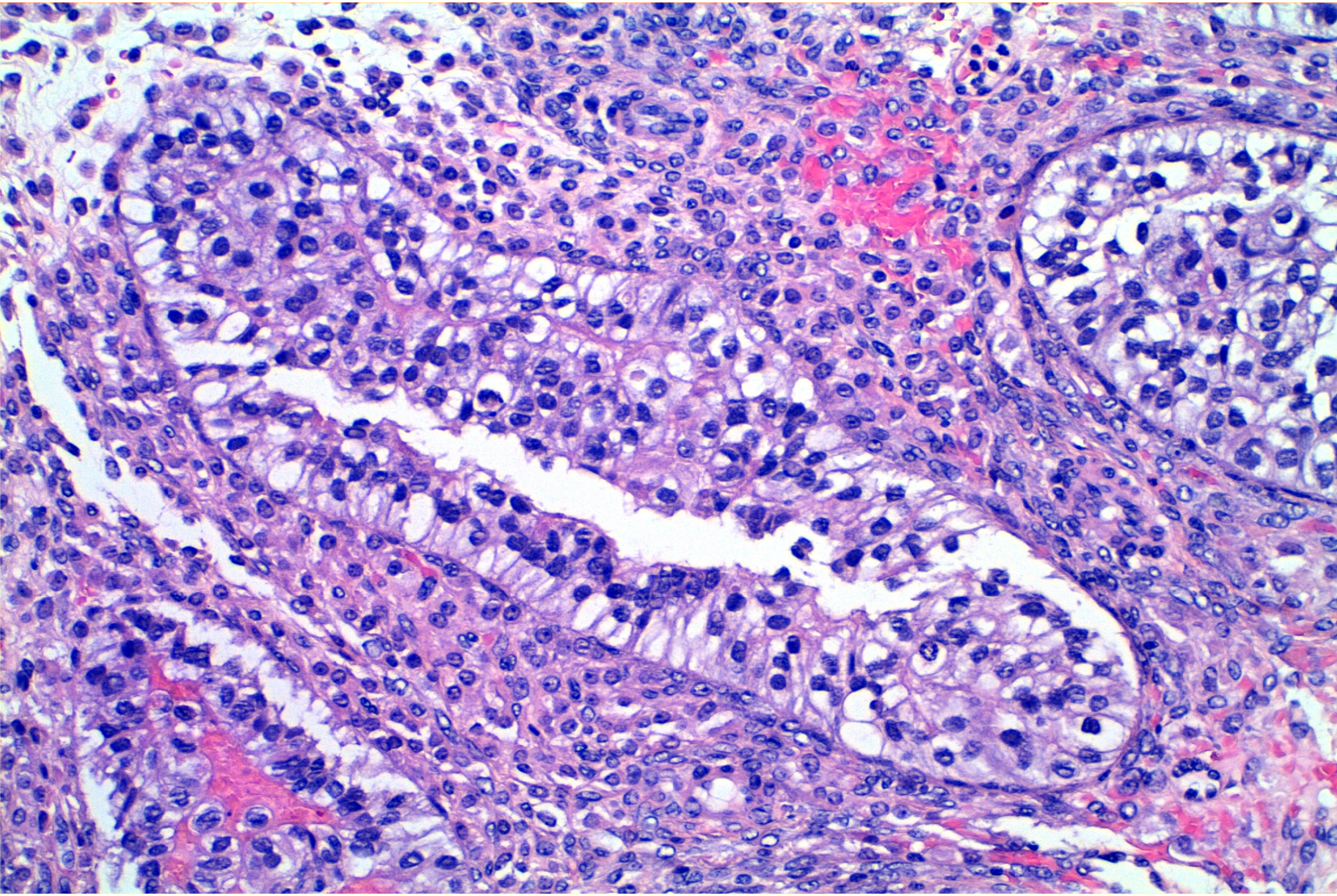

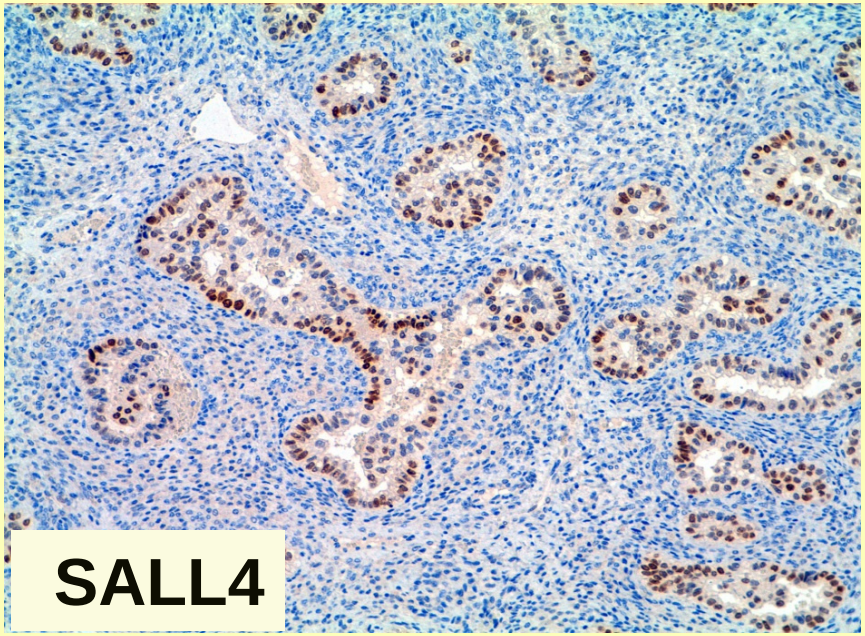
SALL4

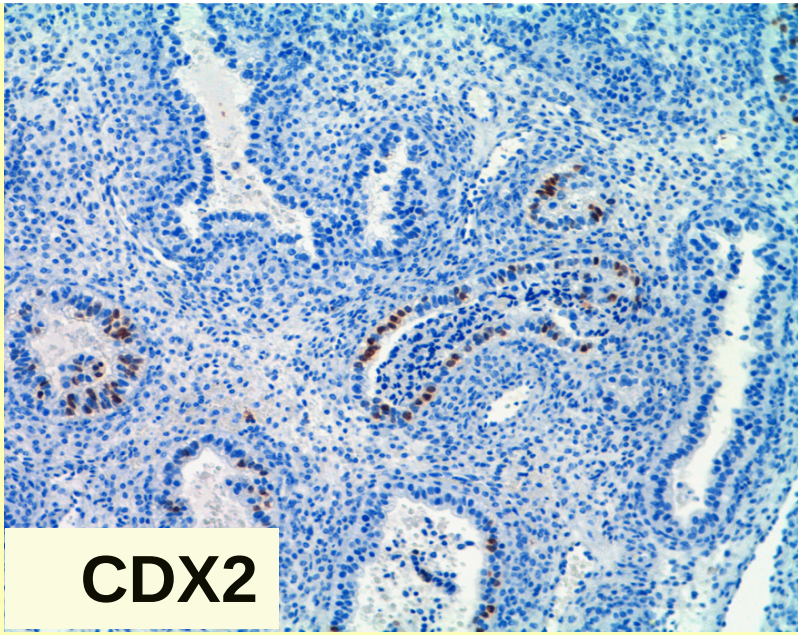
CDX2

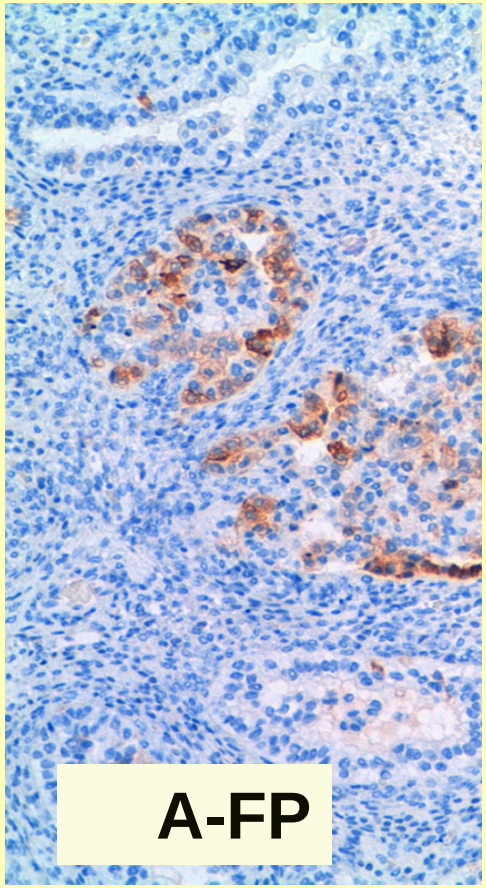
A-FP

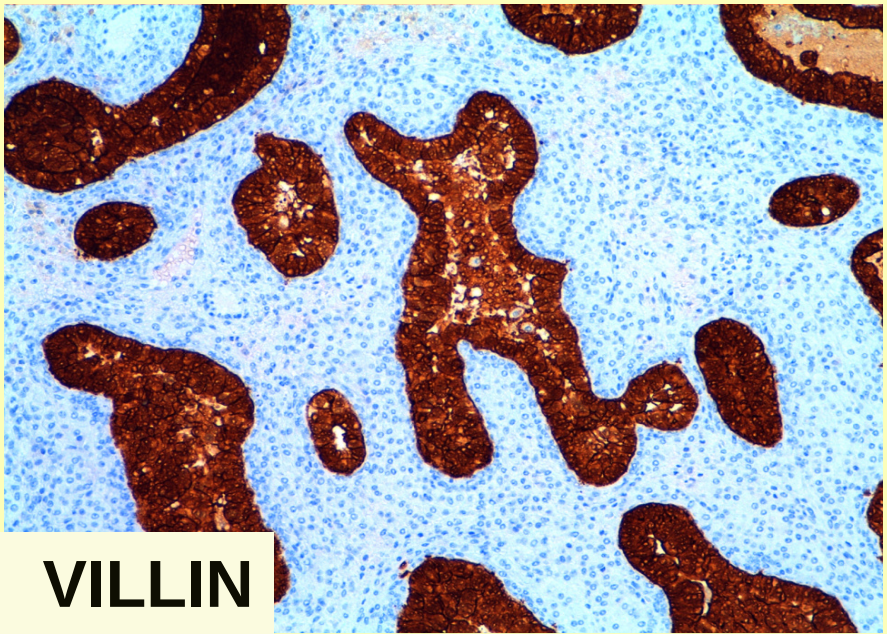
VILLIN

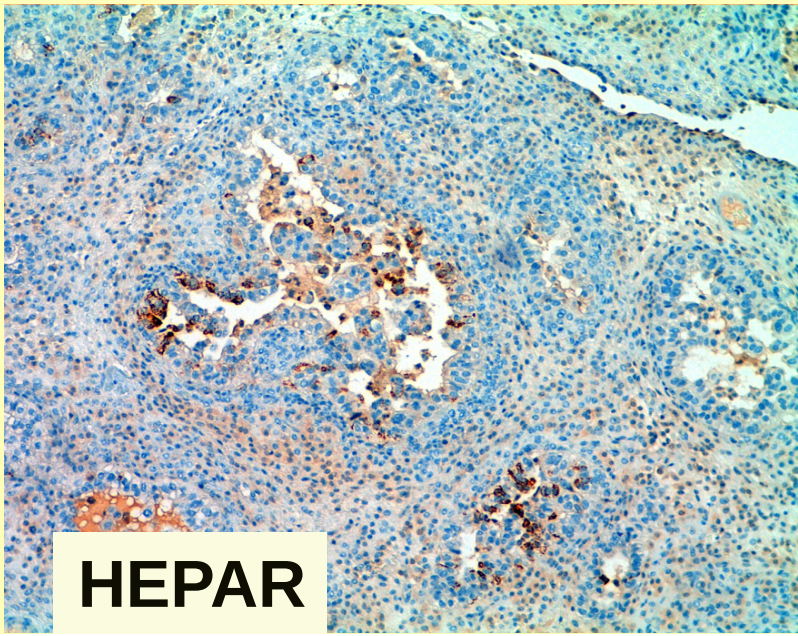
HEPAR

Histopathology 2018, **72**, 634–647. DOI: 10.1111/his.13426

Germ cell tumour growth patterns originating from clear cell carcinomas of the ovary and endometrium: a comparative immunohistochemical study favouring their origin from somatic stem cells

Francisco F Nogales,[1] Jaime Prat,[2] Maolly Schuldt,[1] Nelly Cruz-Viruel,[1] Baljeet Kaur,[3] Emanuela D'Angelo,[4] Xavier Matias-Guiu,[5] August Vidal,[5] W Glenn McCluggage[6] & J Wolter Oosterhuis[7]

Table 1. Clinicopathological findings

1	76	Left ovary/2 cm	CCC	Pure GLYST		III	TAH-BSO, omentectomy, chemotherapy	DOD 1 year
2	94	Left ovary/19 cm	ENC+CCC	GLYST+MYST	END-CAF	I	TAH-BSO, omentectomy, chemotherapy	Disseminated metastases, DOD 1 year
3	79	Left ovary/8 cm	Borderline CC adenofibroma	Pure GLYST		I	TAH-BSO. No further treatment	AW 21 months
4	48	Left ovary/18 cm	CCC	GLYST+MYST		III	LSO, omentectomy, chemotherapy	DOD 16 months after diagnosis
5	37	Left ovary/size not known	ENC+CCC	GLYST+MYST	Endometriosis	I	LSO, chemotherapy.	DOD 18 months after diagnosis. Early recurrences.
6	57	Right ovary/15 cm	ENC+ CCC	GLYST+CHO+ECL+ EMBRYOID	END-CAF	II	BSO, chemotherapy	DOD after 2 years Recurrence 7 months. Raised hCG
7	49	Ovary (laterality not known)/8 cm	ENC+CCC	GLYST+MYST	Endometriosis+END-CAF	II	TAH-BSO, omentectomy, pelvic LND, BEP chemotherapy 4 cycles	AW 2 years with negative markers
8	69	Ovary (laterality not known)/10 cm	CCC	GLYST (predominant)+ MYST SQUA (benign)		III	Debulking surgery, omentectomy, chemotherapy	DOD
9	40	Left ovary/4 cm	ENC+CCC	GLYST+NEURO+STM+ SQUA (benign)	Endometriosis	I	LSO, CarboTaxol chemotherapy 4 cycles	AW 4 years
10	58	Right ovary/20 cm	CCC	GLYST (predominant)+ MYST(focal)+ NEURO+ SQUA+STM+CART(benign)	Endometriosis	II	TAH-BSO, CarboTaxol chemotherapy 6 cycles	AW 20 months
11	72	Right ovary/17 cm	ENC+CCC	GLYST+MYST+NEURO+ EMBRYOID	Endometriosis	III	TAH-BSO, chemotherapy	Early recurrence. DOD 3 years
12	69	Uterus/11 cm	Carcinosarcoma+CCC	GLYST+NEURO+CHO+ECL		IV	TAH-BSO	DOD in postoperative period

Antibodies	Clear cell tumour	Glandular YST
HNF1-β	11/12 Diffuse	6/12 Heterogeneous
CK7	12/12 Diffuse	5/11 Heterogeneous
EMA	11/12 Diffuse	9/12 Heterogeneous
Napsin-A	9/10 Diffuse	0/11
PAX8	11/11 Diffuse	0/11
AFP	0/12	10/12 Heterogeneous
SALL4	0/12	12/12 Diffuse
Villin	0/11	11/11 Diffuse
HepPar1	0/11	7/11 Focal
GPC-3	2/12 Focal	10/12 Heterogeneous
GATA3	2/10 Focal	2/10 Focal
OCT4	6/10 Heterogeneous	0/12

GLYST, glandular yolk sac tumour; MYST, microcystic yolk sac tumour.

International Journal of Gynecological Pathology
25:52–58, Lippincott Williams & Wilkins, Baltimore
© 2005 International Society of Gynecological Pathologists

Association of Low-Grade Endometrioid Carcinoma of the Uterus and Ovary With Undifferentiated Carcinoma: A New Type of Dedifferentiated Carcinoma?

Elvio G. Silva, M.D., Michael T. Deavers, M.D., Diane C. Bodurka, M.D., and Anais Malpica, M.D.

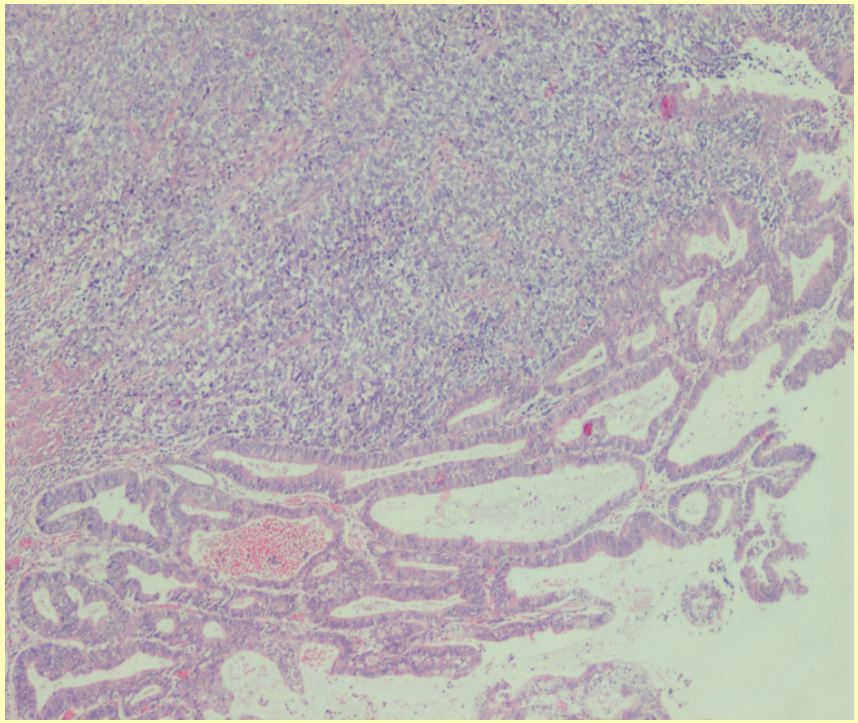

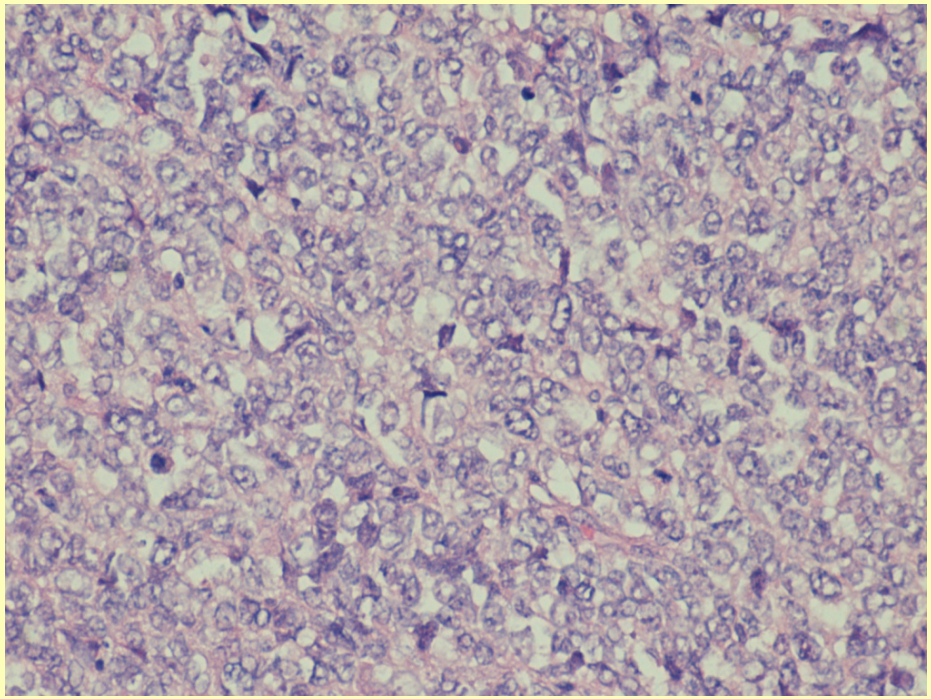

WHO Classification of Tumours of Female Reproductive Organs

Clear cell tumours	
Benign	
Clear cell cystadenoma	8443/0
Clear cell adenofibroma	8313/0
Borderline	
Clear cell borderline tumour / Atypical proliferative clear cell tumour	8313/1
Malignant	
Clear cell carcinoma	8310/3

Clear cell cystadenoma / adenofibroma

Definition

A tumour composed of glands or cysts lined by bland cuboidal to flattened cells with clear or eosinophilic cytoplasm embedded in a fibromatous stroma.

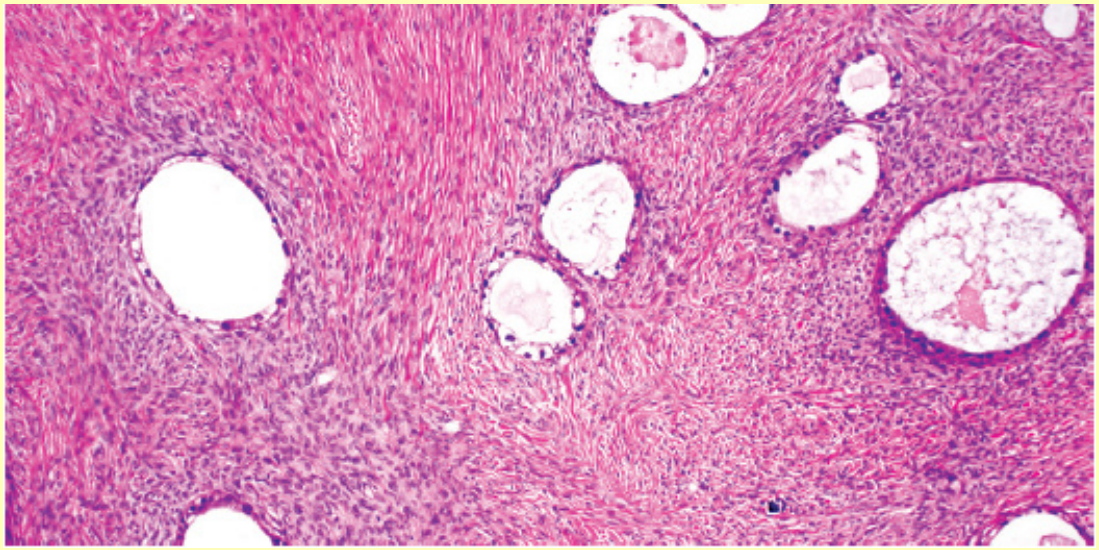

Clear cell borderline tumour / Atypical proliferative clear cell tumour

Definition

These are clear cell adenofibromatous tumours with atypia of the glandular epithelium but without stromal invasion.

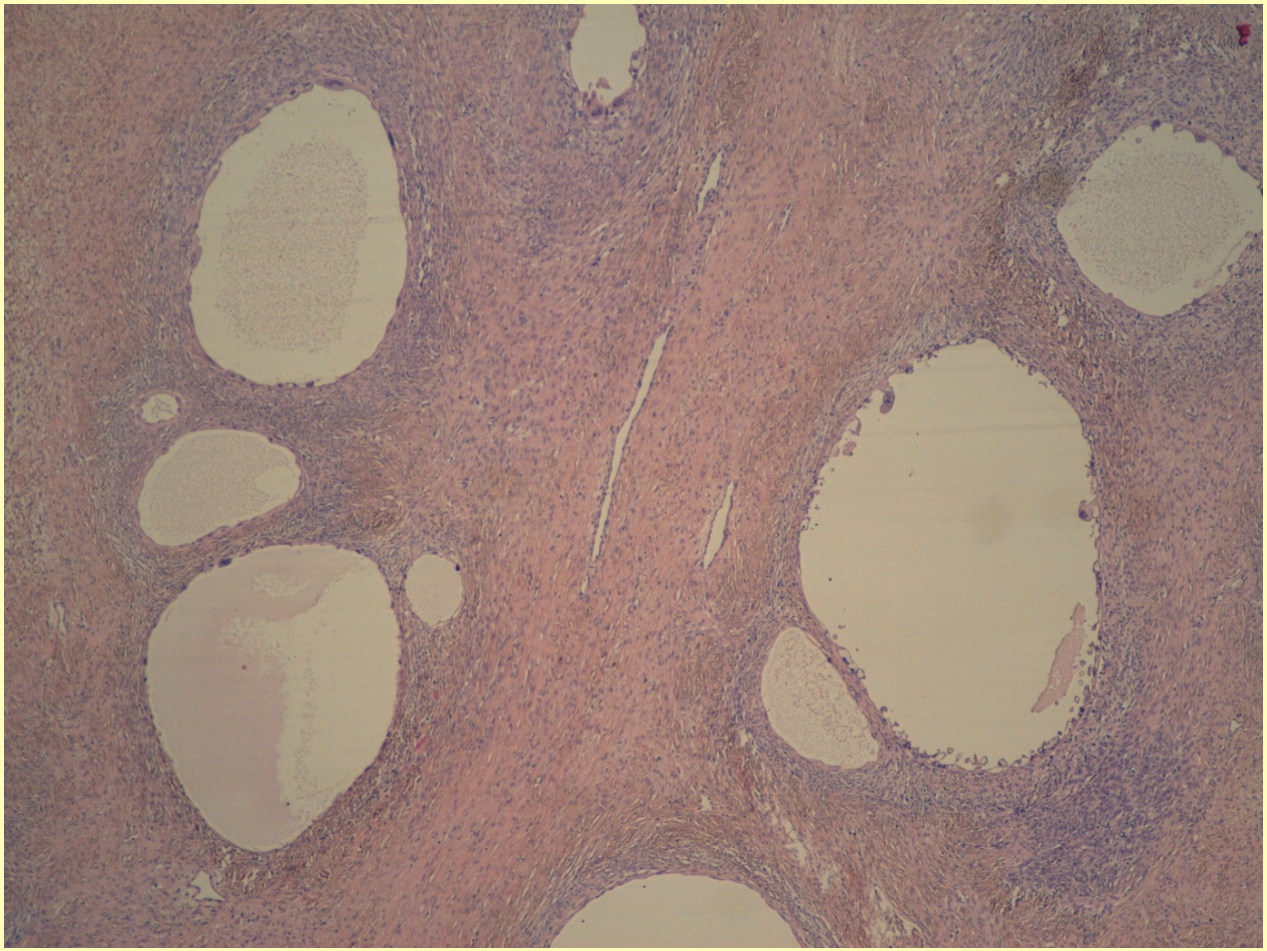

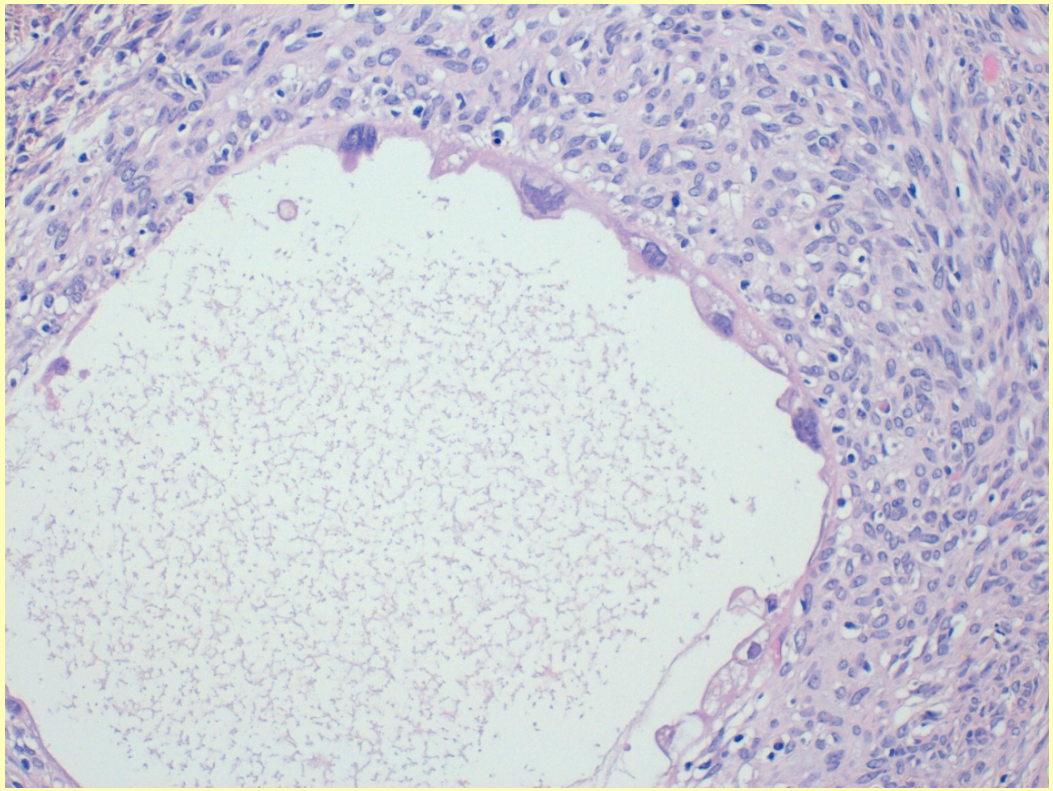

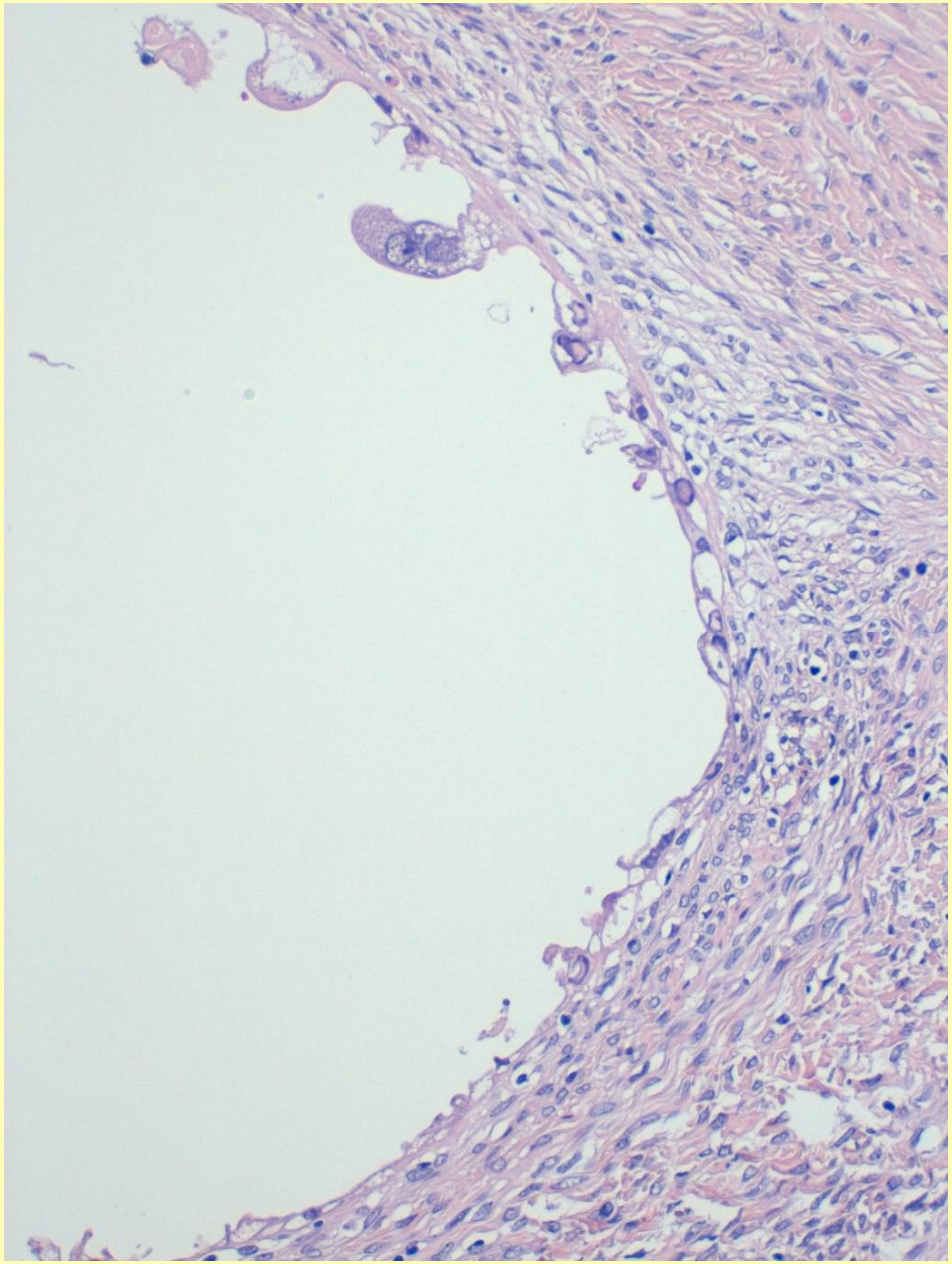

CLEAR CELL CARCINOMA OF THE OVARY (Definition)

A malignant tumour composed of clear, eosinophilic and hobnail cells, displaying a combination of yubulocystic, papillary and solid patterns.

WHO, 2003

CLEAR CELL CARCINOMA OF THE OVARY (Clinical Features)

- Around 10% of ovarian cancers
- Unilateral
- Early stages (60-70%)
- Associated with endometriosis
- Less likely to respond to platinum-based ChT


HUAV-HSM-UdL PATOLOGIA
cm 1 2 3
09/14289
8 9 10 11 12 13 14



CLEAR CELL CARCINOMA OF THE OVARY (Pathology)

- **Cystic and Solid growth, occasionally coexisting with an endometriotic cyst Tubulo-cystic / complex papillae**
- **Clear, hobnail, oxyphylic cells**
- **Hyaline basement membrane and hyaline bodies**
- **HNK1β, Napsin A, AMACR**

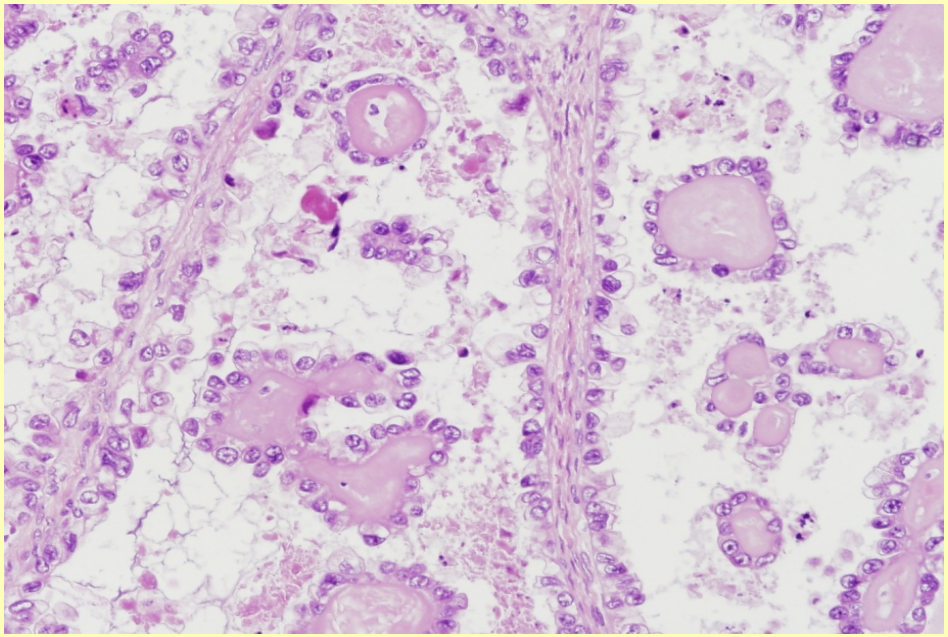

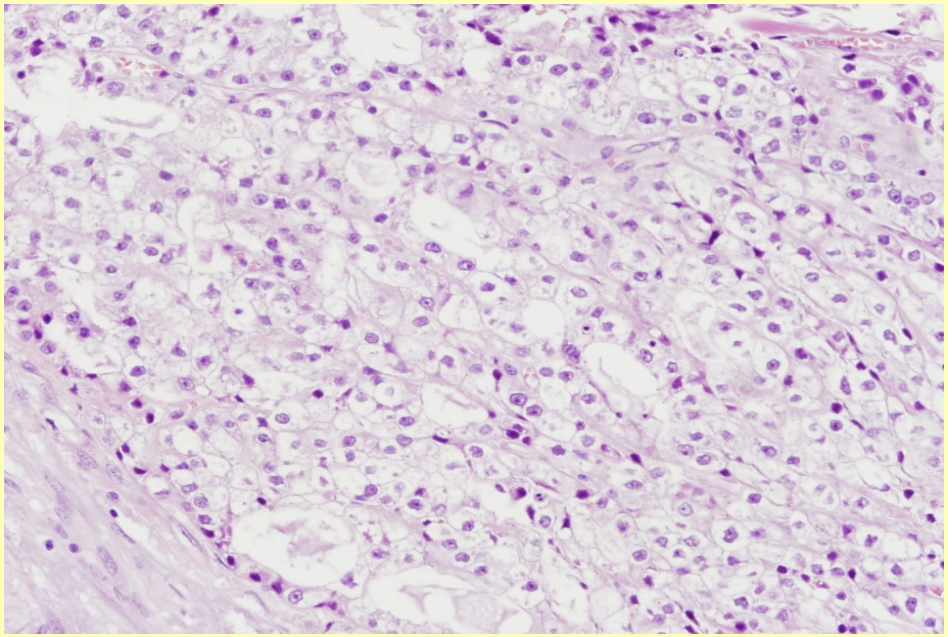

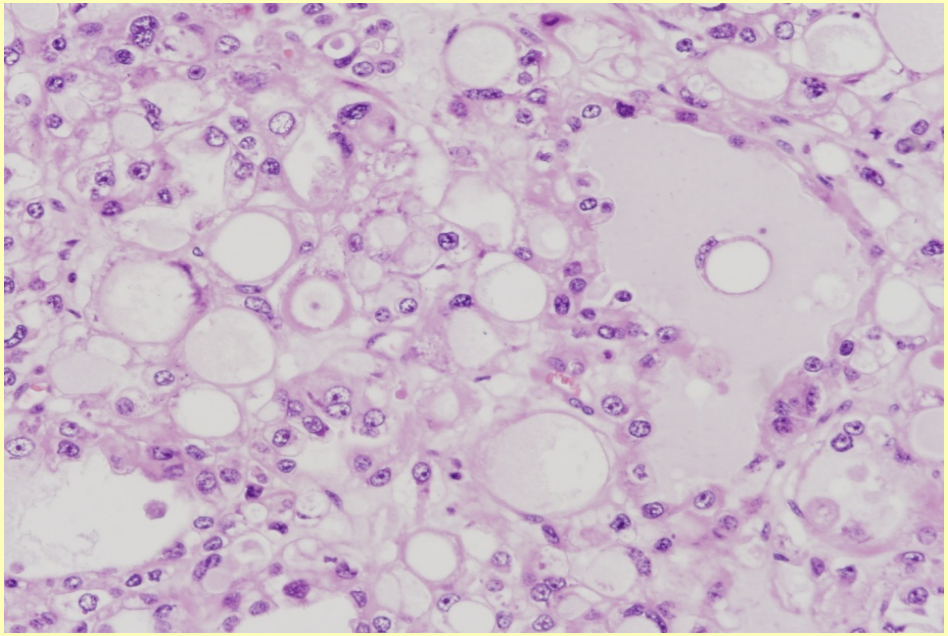

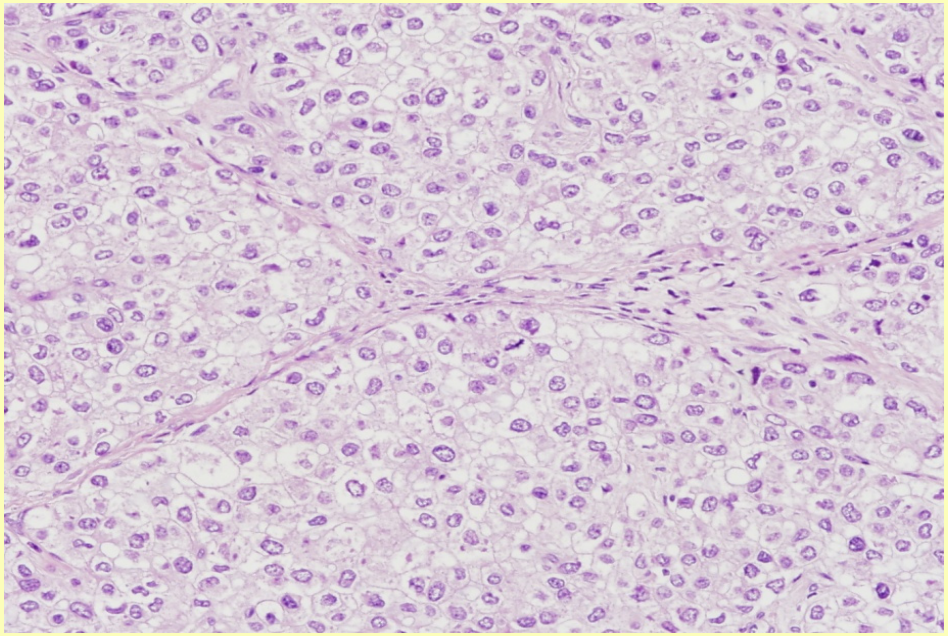

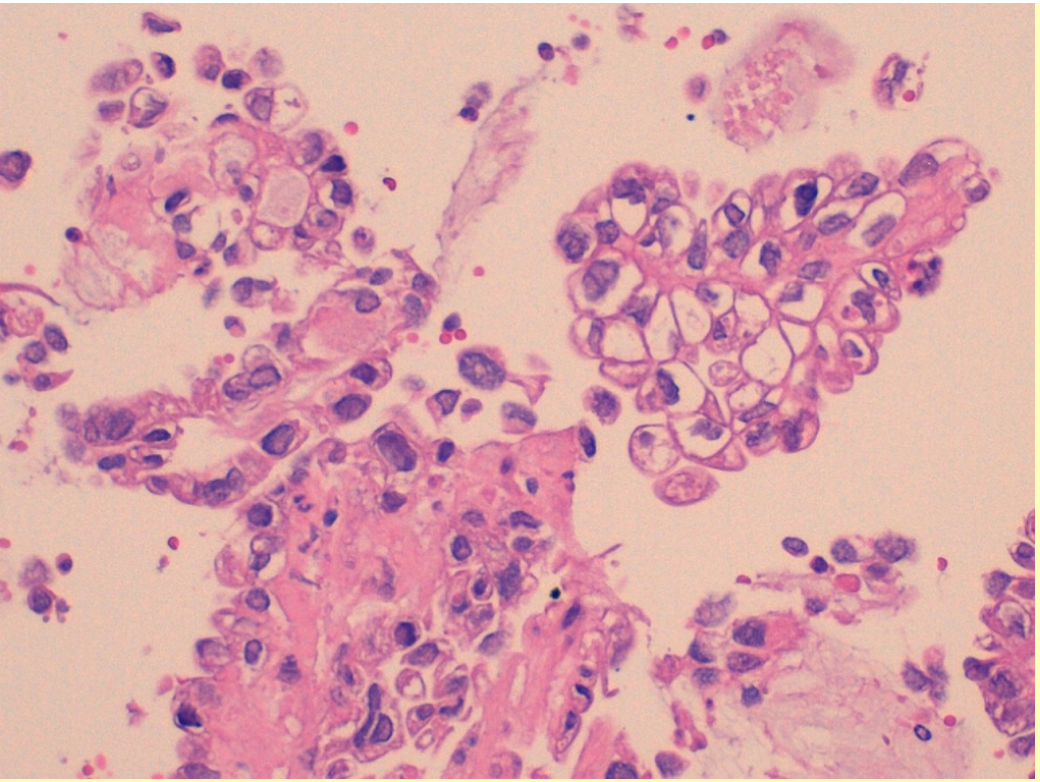

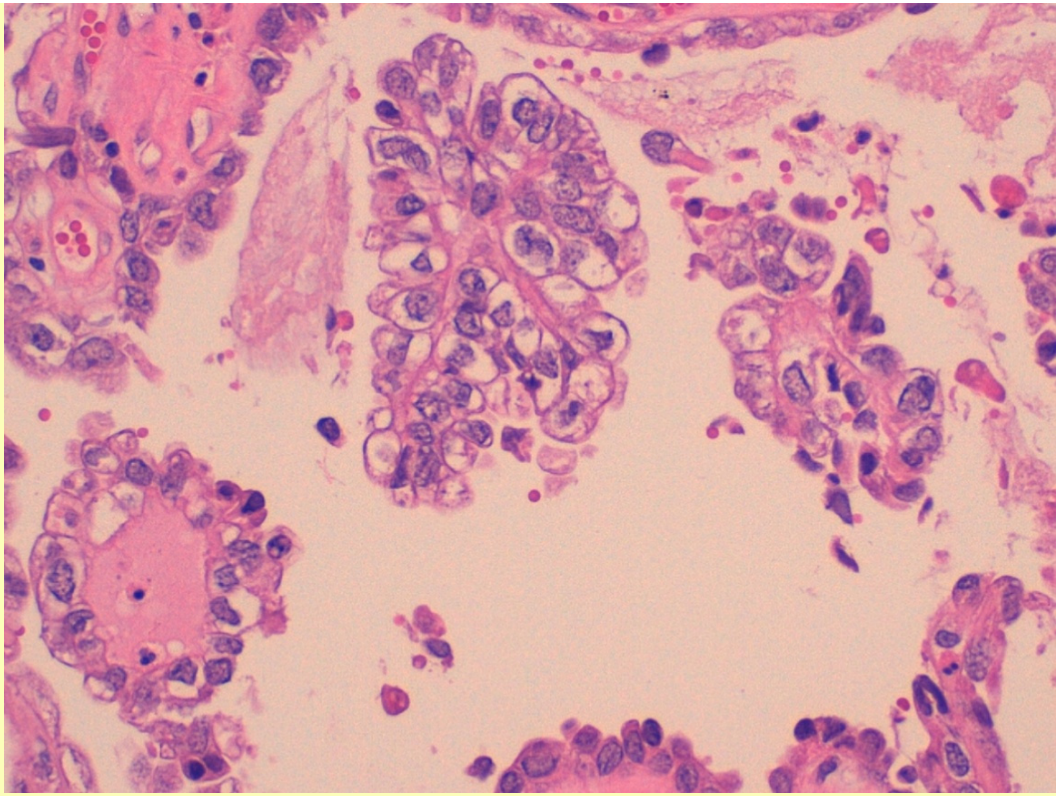

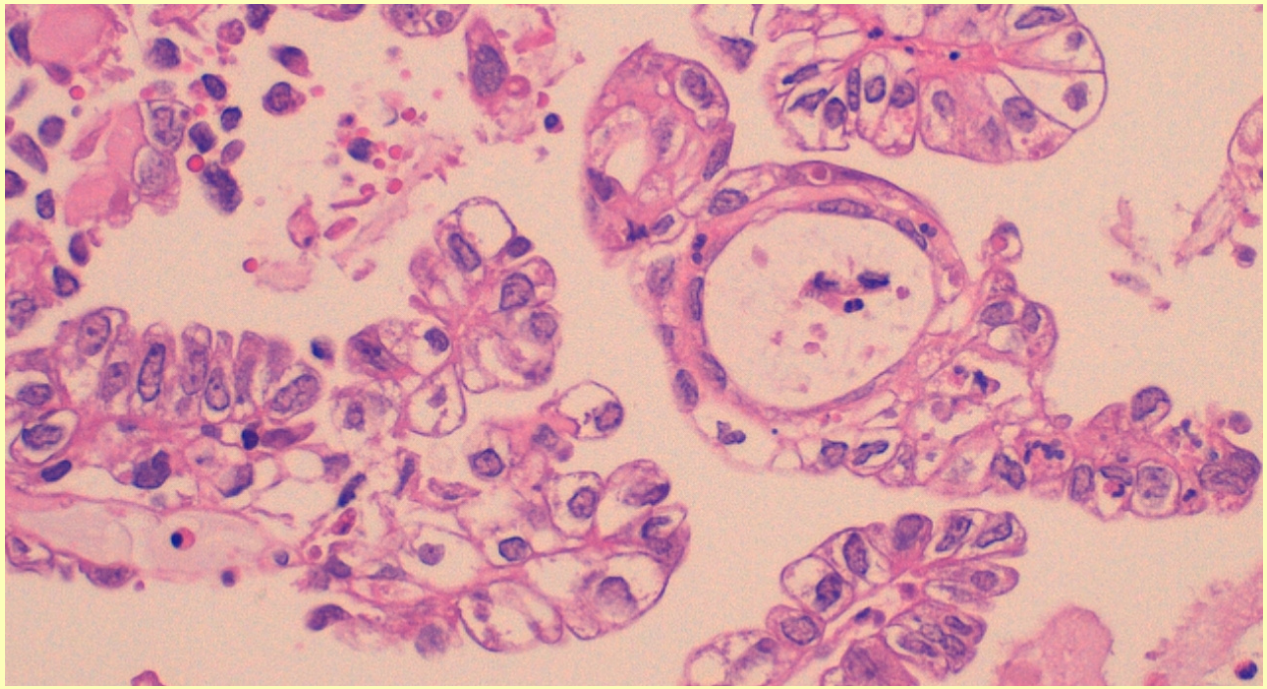

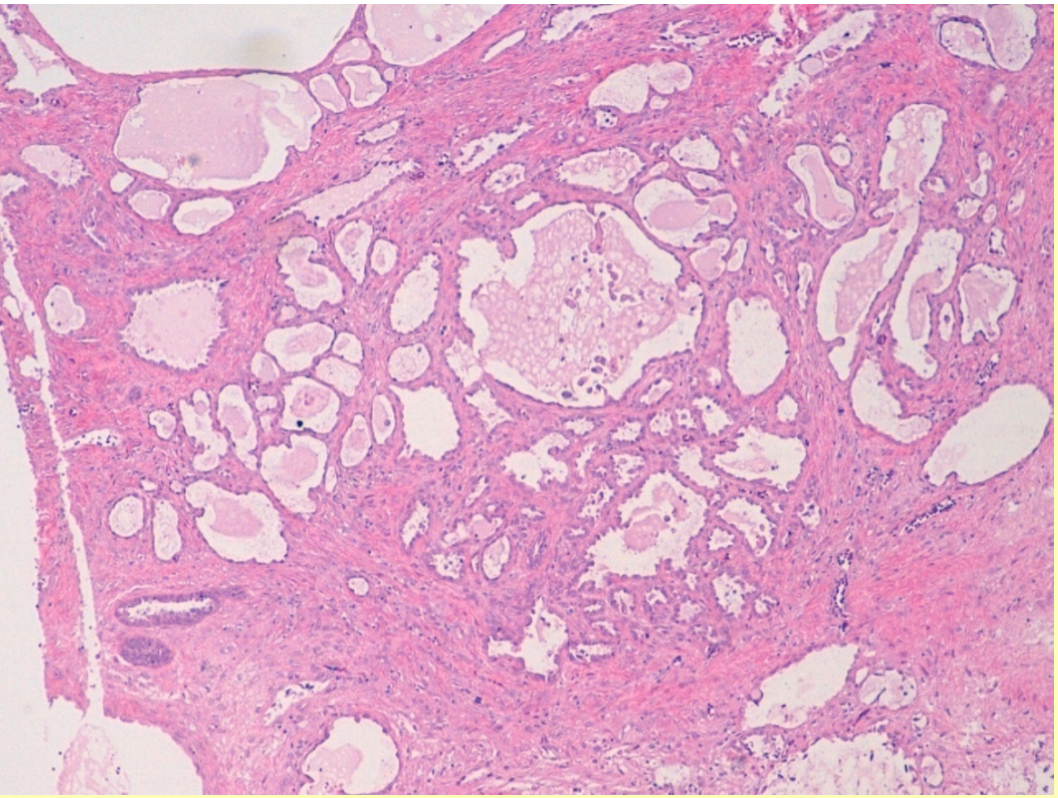

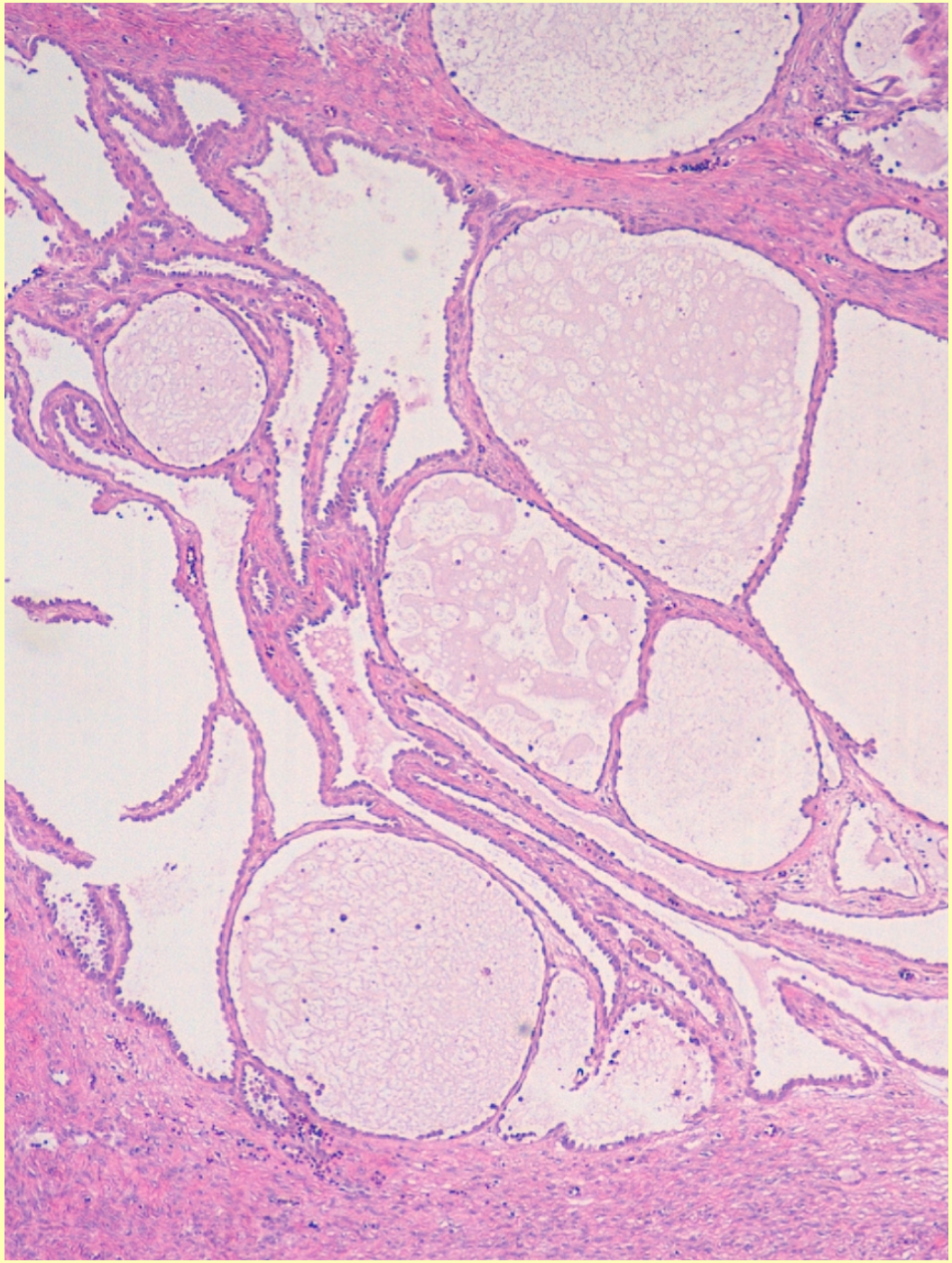

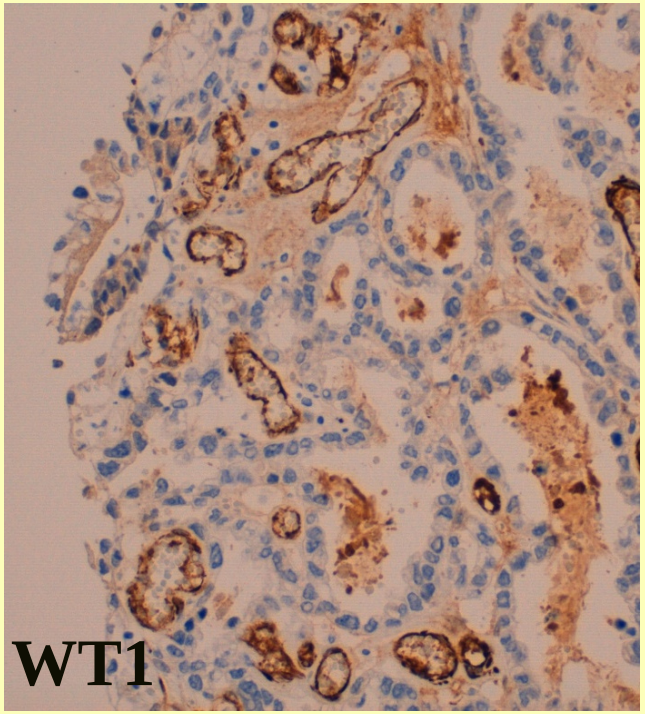
WT1

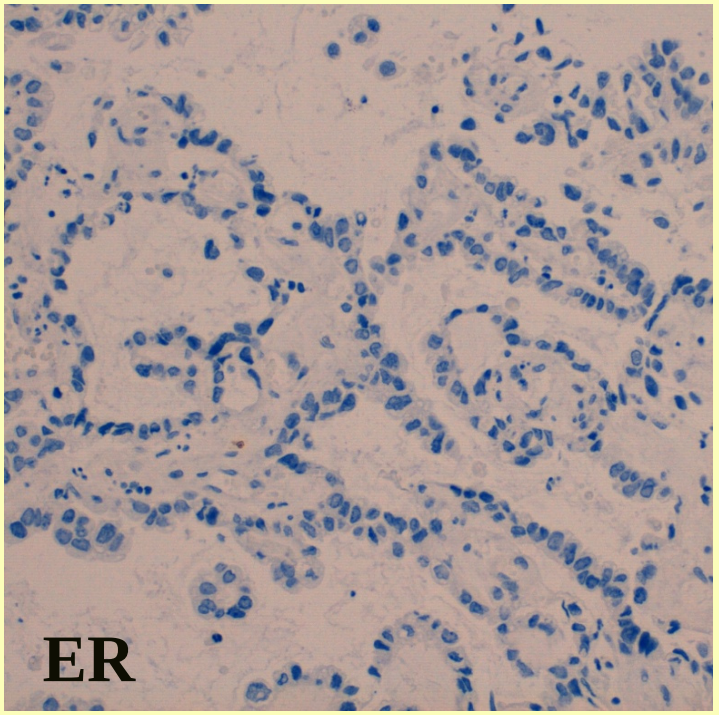
ER

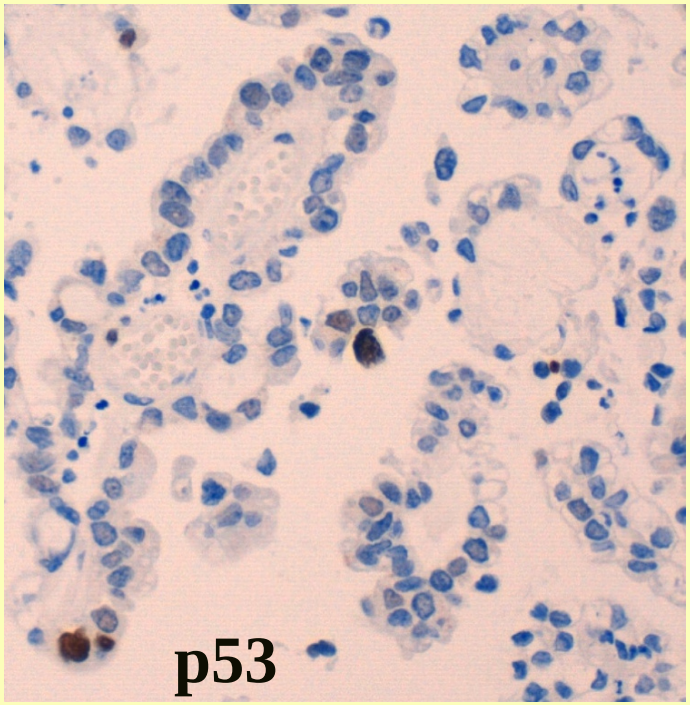
p53

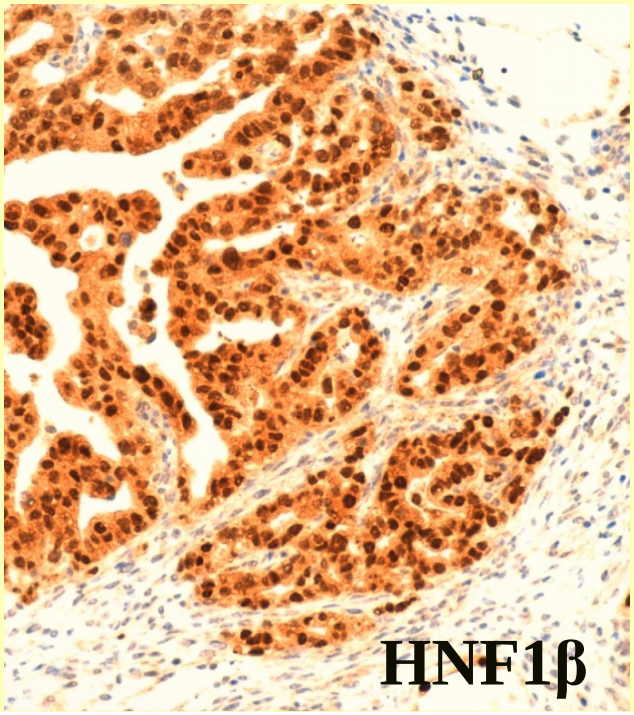
HNF1β

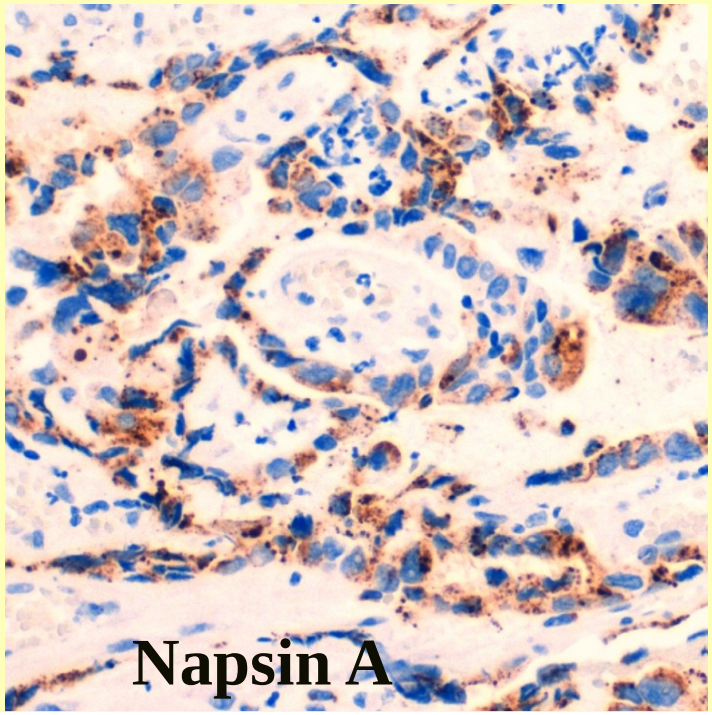
Napsin A

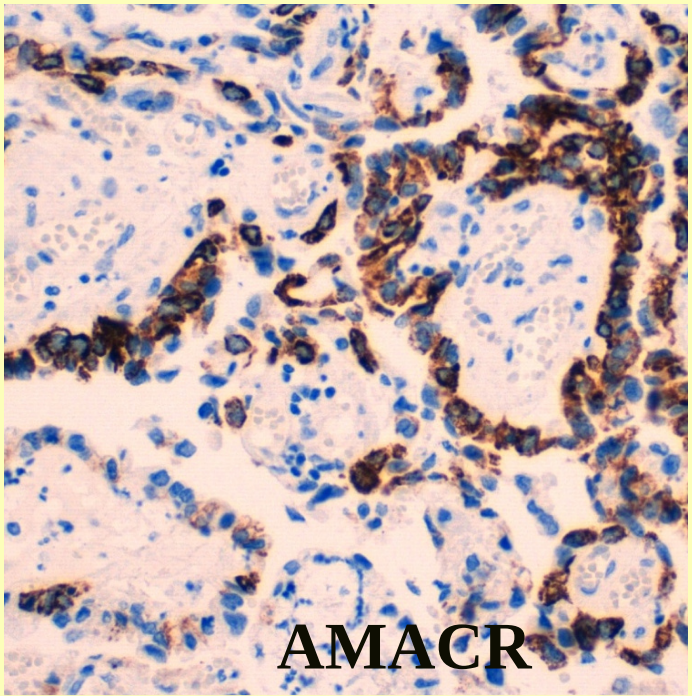
AMACR

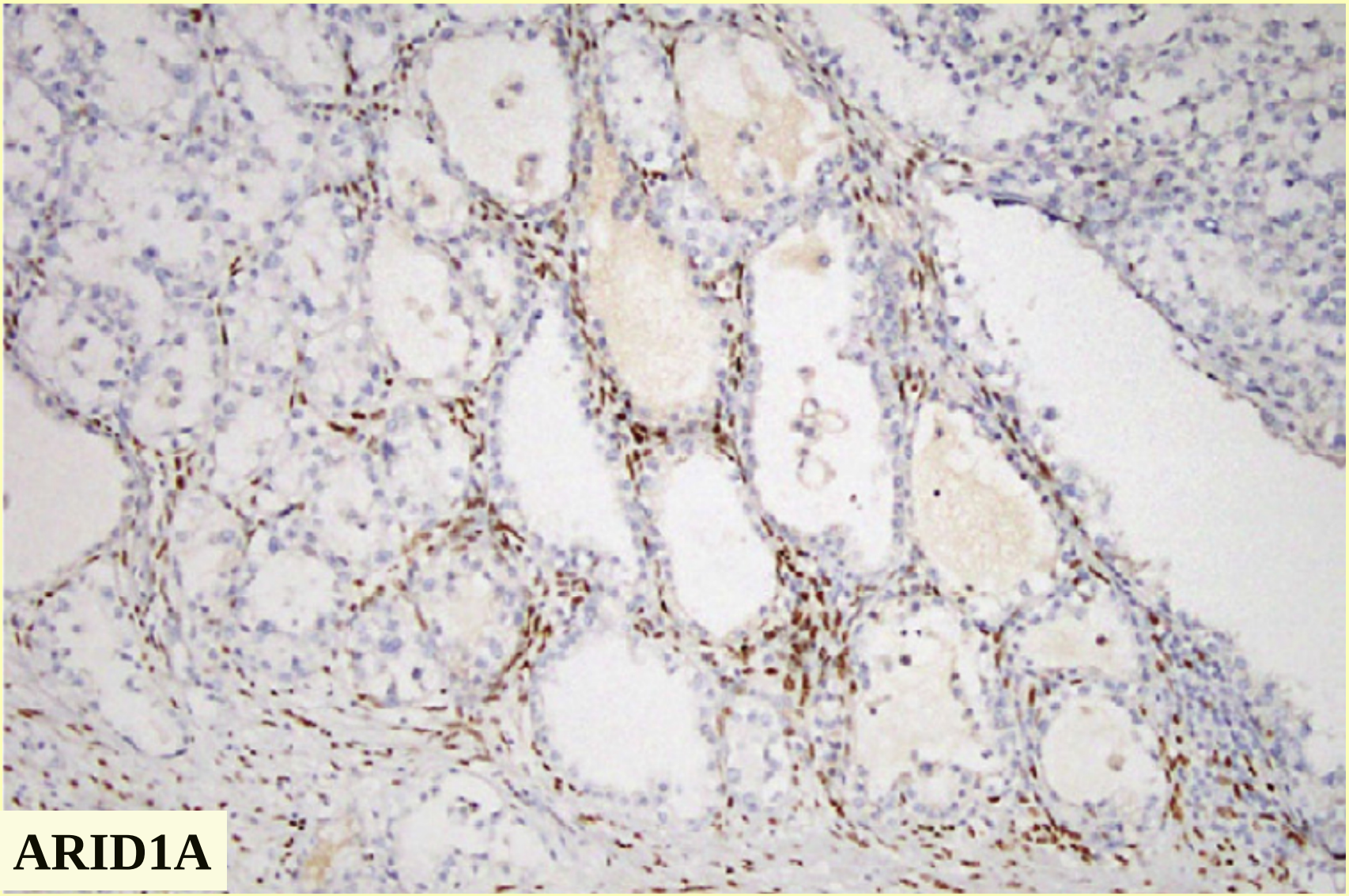
ARID1A

Low-Stage Ovarian Clear Cell Carcinoma: Population-Based Outcomes in British Columbia, Canada, With Evidence for a Survival Benefit As a Result of Irradiation

Paul J. Hoskins, Nhu Le, Blake Gilks, Anna Tinker, Jennifer Santos, Frances Wong, and Kenneth D. Swenerton

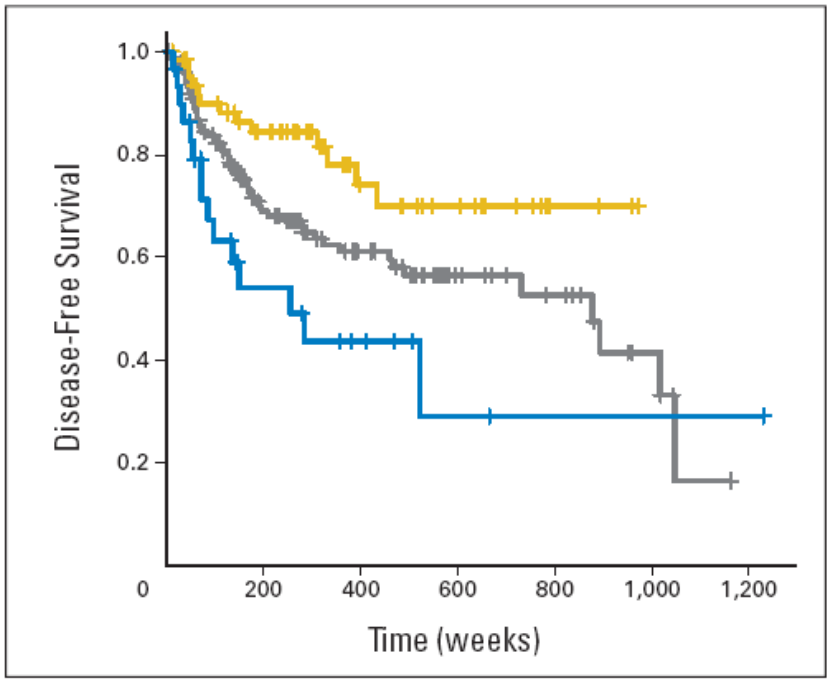

Fig 1. Disease-free survival by stage/substage (gold, stage IA/IB, n = 64; gray, stage IC, n = 147; and blue, stage II, n = 30).

Prognosis of ovarian clear cell carcinoma compared to other histological subtypes: A meta-analysis

Yoo-Young Lee [a,1], Tae-Joong Kim [a,1], Min-Ji Kim [b], Ha-Jeong Kim [a], Taejong Song [a], Min Kyu Kim [a], Chel Hun Choi [a], Jeong-Won Lee [a], Duk-Soo Bae [a], Byoung-Gie Kim [a,*]

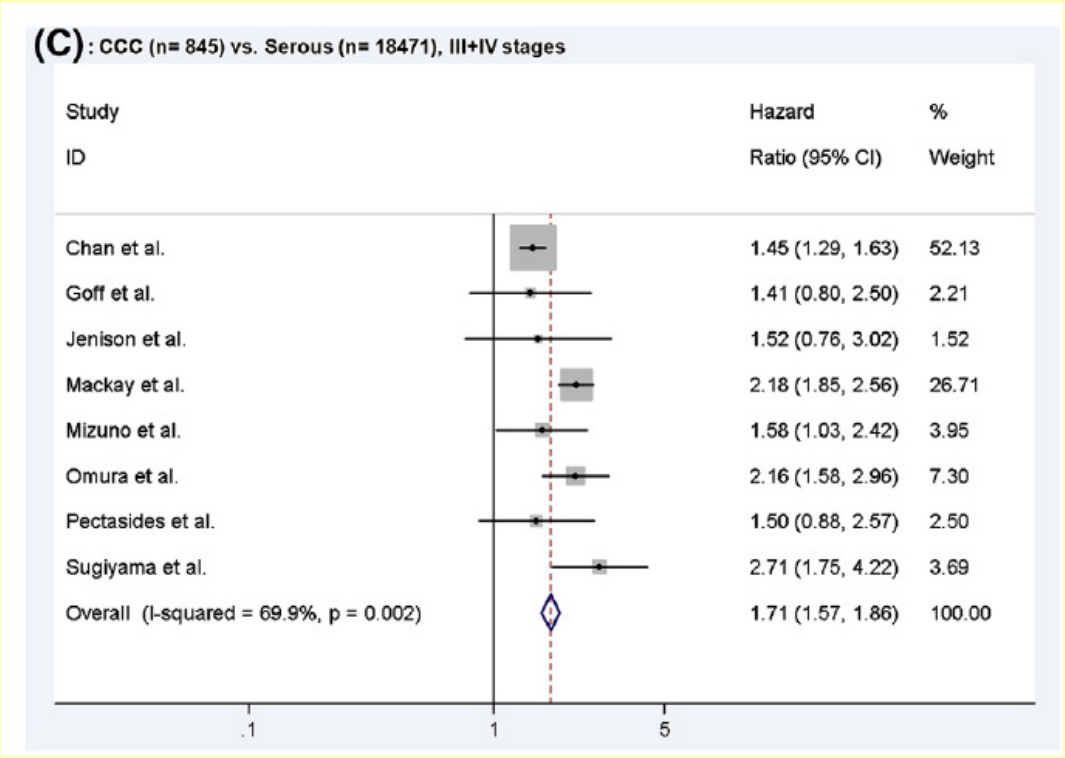

CLEAR CELL CARCINOMA OF THE OVARY (Differential Diagnosis)

- **High grade serous carcinoma with clear cell change**
- **Dysgerminoma**
- **Yolk sac tumor**
- **Serous Bordeline Tumor**

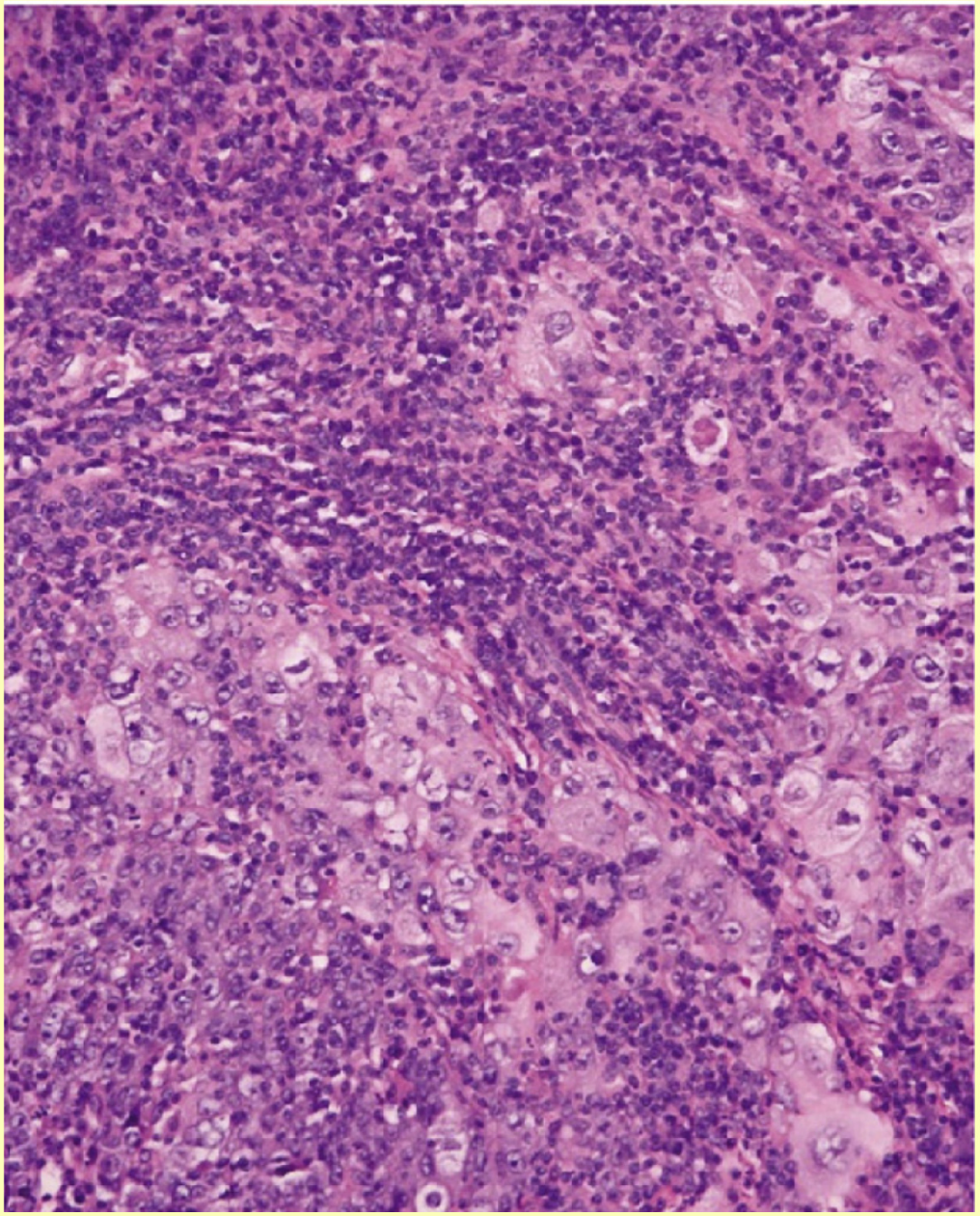

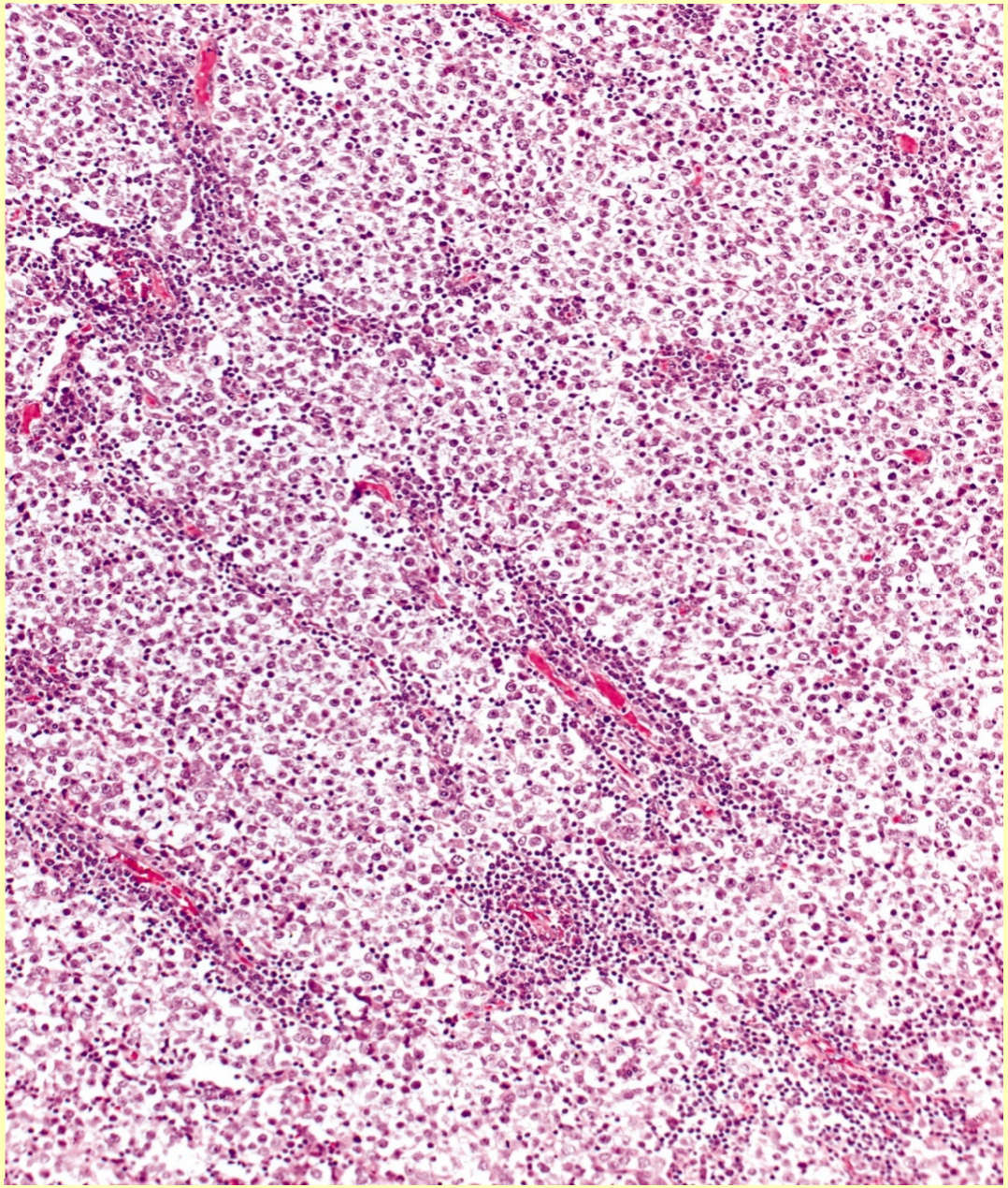

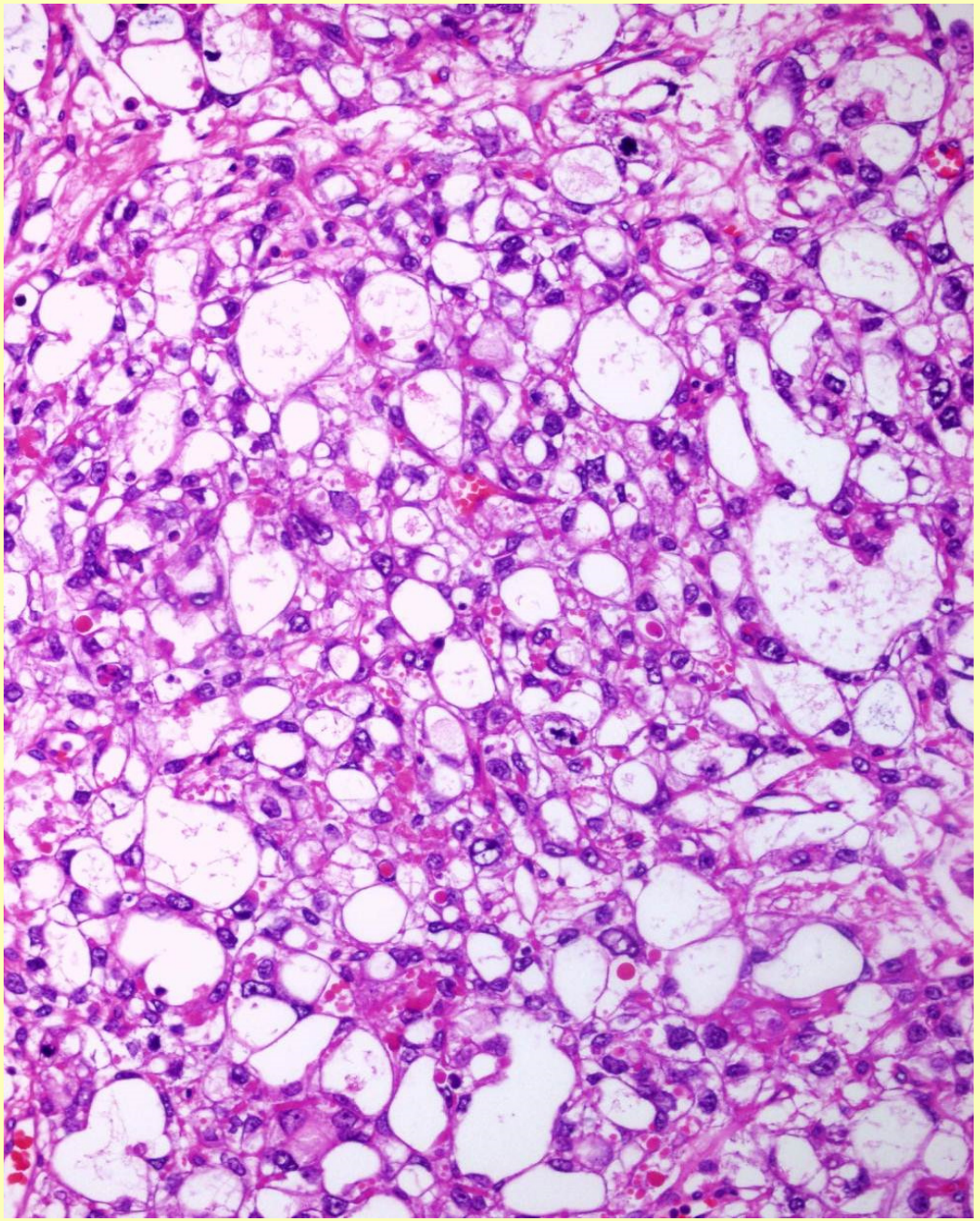

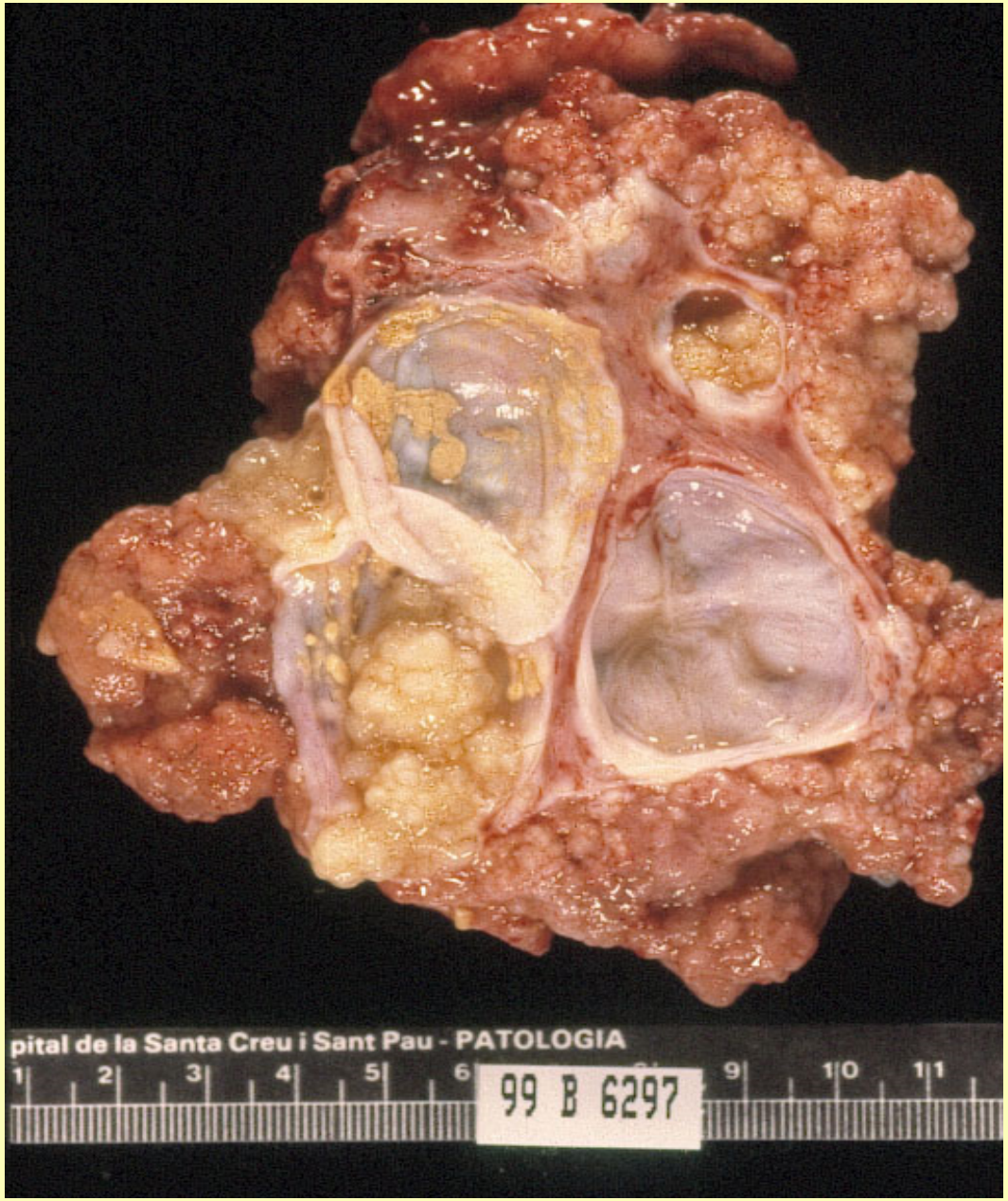
pital de la Santa Creu i Sant Pau - PATOLOGIA
1 2 3 4 5 6 9 10 11
99 B 6297

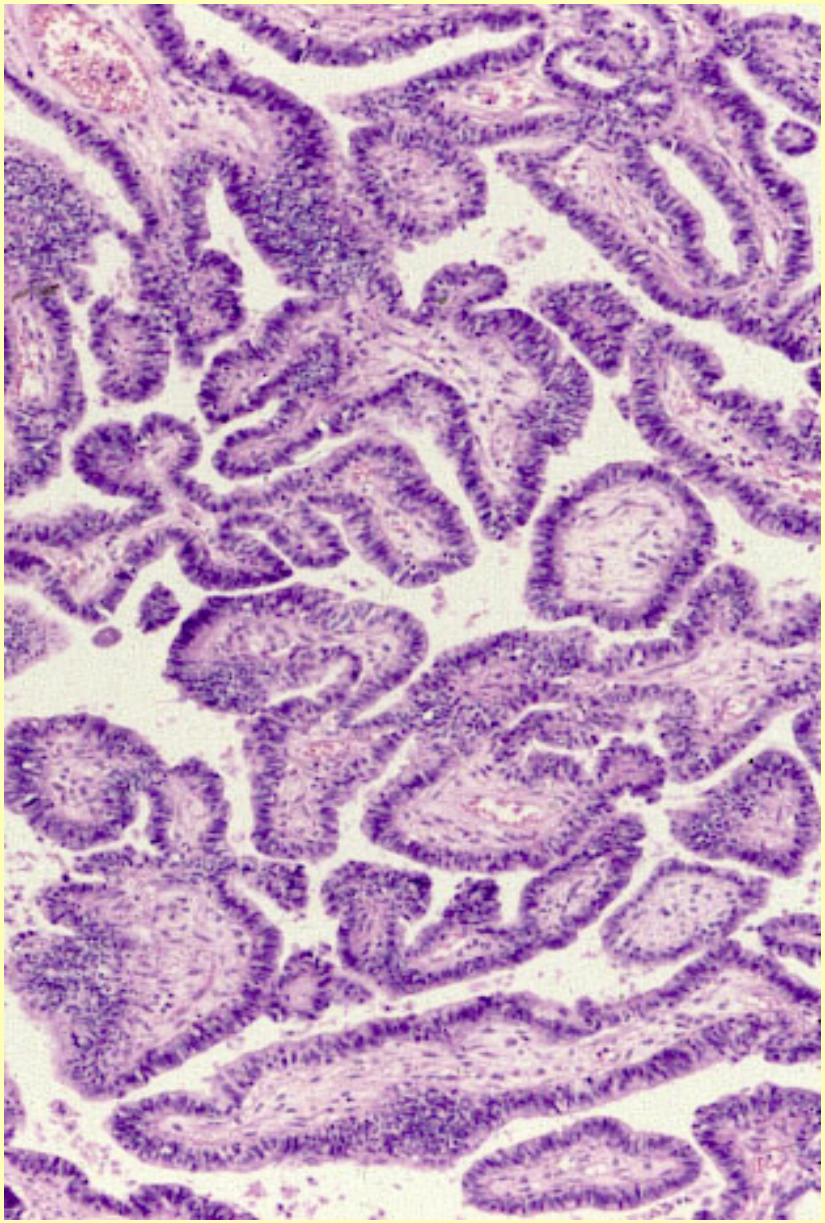

Seromucinous tumours

Benign

- Seromucinous cystadenoma
- Seromucinous adenofibroma

Borderline

- Seromucinous borderline tumour / Atypical proliferative seromucinous tumour

Malignant

- Seromucinous carcinoma

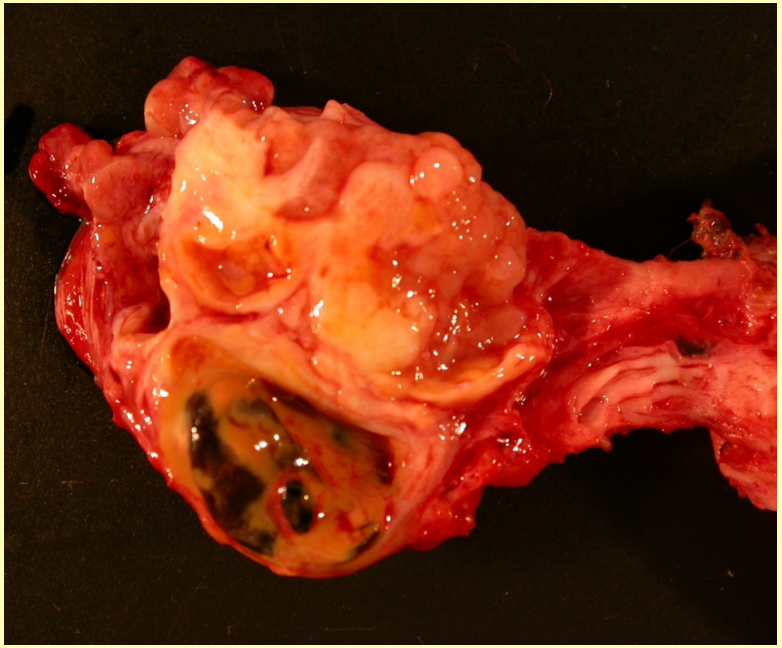


RIC 5-9/Gynaecology
MI 0.4
PRENATAL ARNAU
27202
12.5cm / 13Hz
20-05-2004
10:06:19
Uterus
11.50 - 4.00
Pot 100
Gn -2
C6 / M5
P3 / E1


HUAV-HSM-UdL PATOLOGIA
04 / 4212

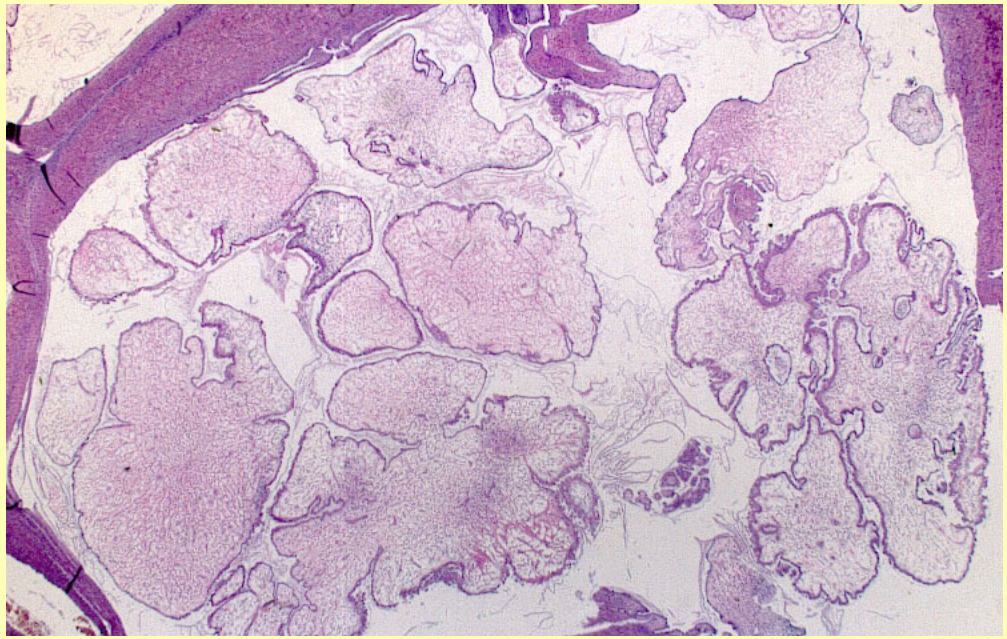



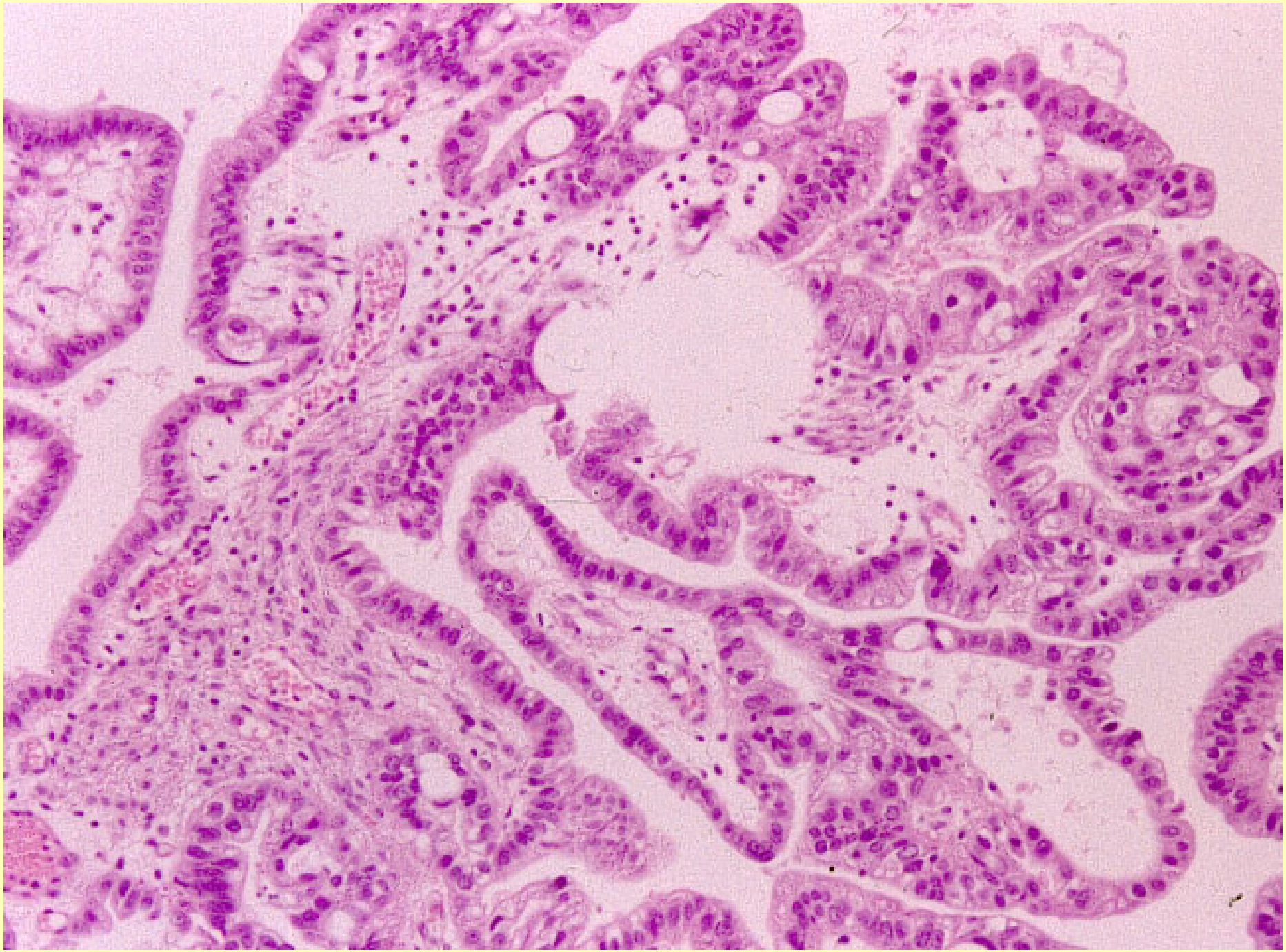

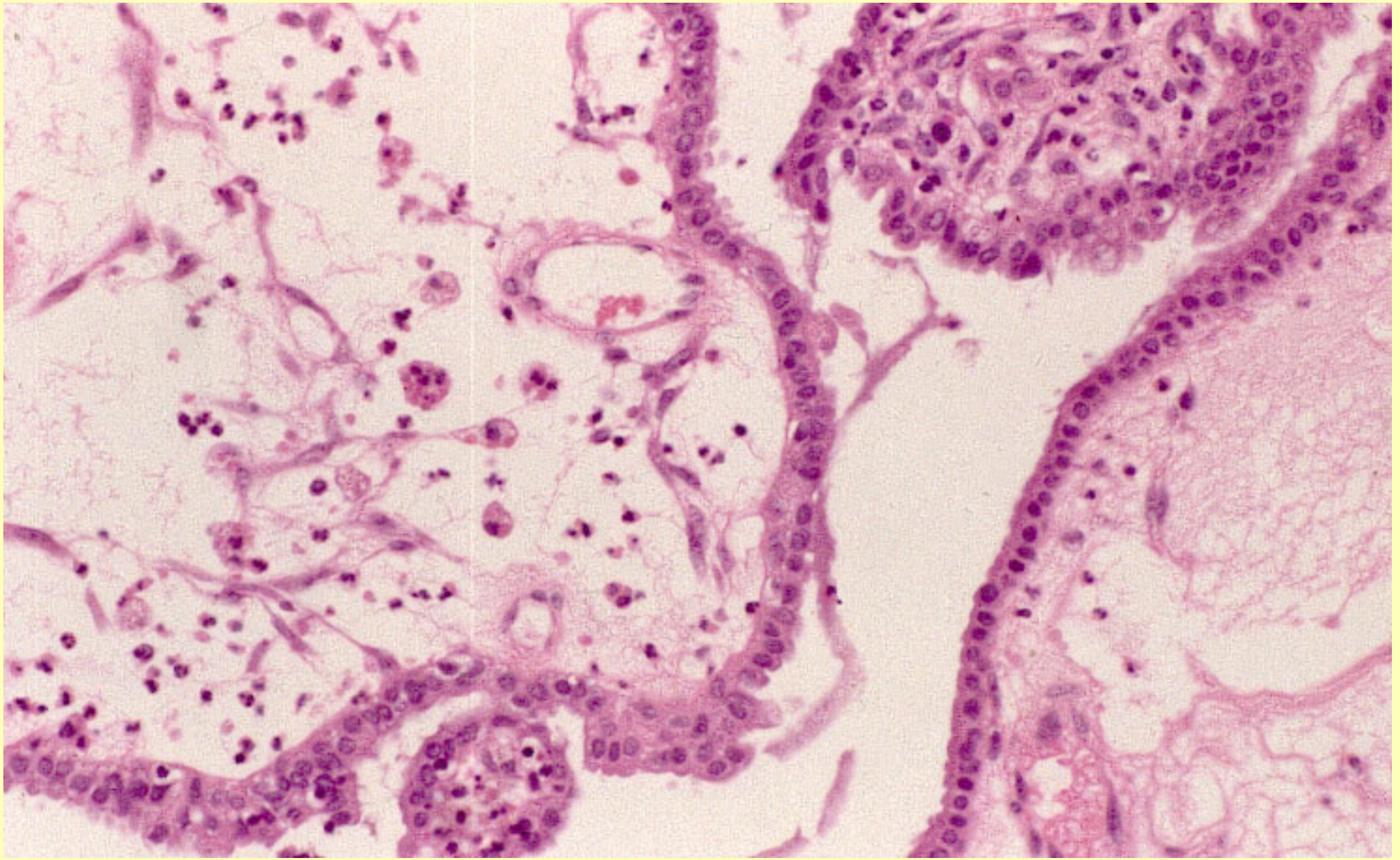

Seromucinous Carcinoma is a controversial entity

Kurman RJ, Shih IeM.

Seromucinous Tumors of the Ovary. What's in a Name?

Int J Gynecol Pathol. 2016 35:78-81.

Taylor J, McCluggage WG.

Ovarian seromucinous carcinoma: report of a series of a newly categorized and uncommon neoplasm.

Am J Surg Pathol. 2015 39:983-92.

Rambau PF, McIntyre JB, Taylor J, Lee S, Ogilvie T, Sienko A, Morris D, Duggan MA, McCluggage WG, Köbel M.

Morphologic reproducibility, genotyping, and immunohistochemical profiling do not support a category of seromucinous carcinoma of the ovary.

Am J Surg Pathol. 2017 41:685-695

xmatias@bellvitgehospital.cat

@bellvitgepath



TECHNOLOGY TRANSFER IN DIAGNOSTIC PATHOLOGY
10TH CENTRAL EUROPEAN REGIONAL MEETING

Gynecological Pathology

ORGANIZED BY THE HUNGARIAN DIVISION OF THE INTERNATIONAL ACADEMY OF PATHOLOGY

CO-SPONSORED BY ISGyP

Visegrád, June 27-29, 2019

ENDOMETRIOSIS AND ASSOCIATED NEOPLASIA

Xavier Matias-Guiu, MD, PhD

Hospital U Arnau de Vilanova, Univ Lleida, IRBLLEIDA,

Hospital U de Bellvitge. IDIBELL, Spain