Technology Transfer in Diagnostic Pathology – Gynecological Pathology
Visegrad, June 27 – 29, 2019

Pitfalls in selected areas of gynecological pathology

Thomas Krausz MD FRCPath
University of Chicago



Case 1
clinical history

- 65-year-old female with history of ductal carcinoma of the breast in 2003
- Recent Pap-test (2017) showed “atypical glandular cells not otherwise specified”
- Subsequent endometrial (A) and endocervical curettage (B): rare clusters of malignant cells - ? type

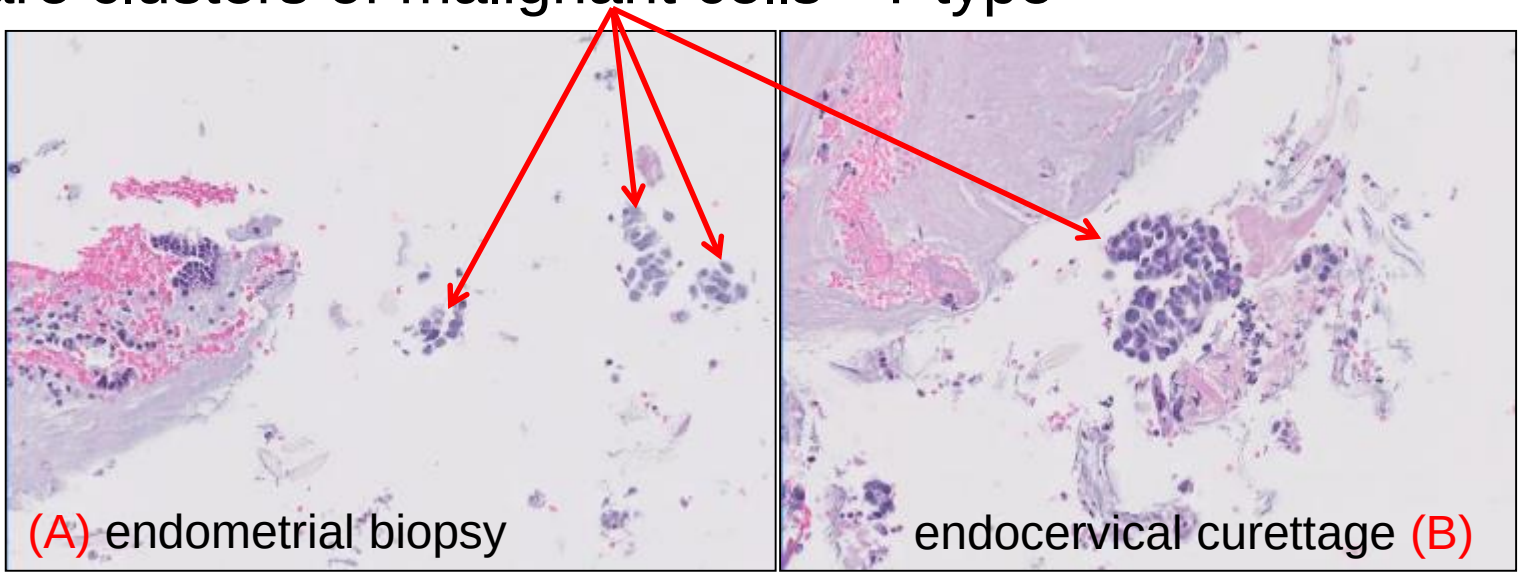

Endometrial biopsy: clusters of malignant cells

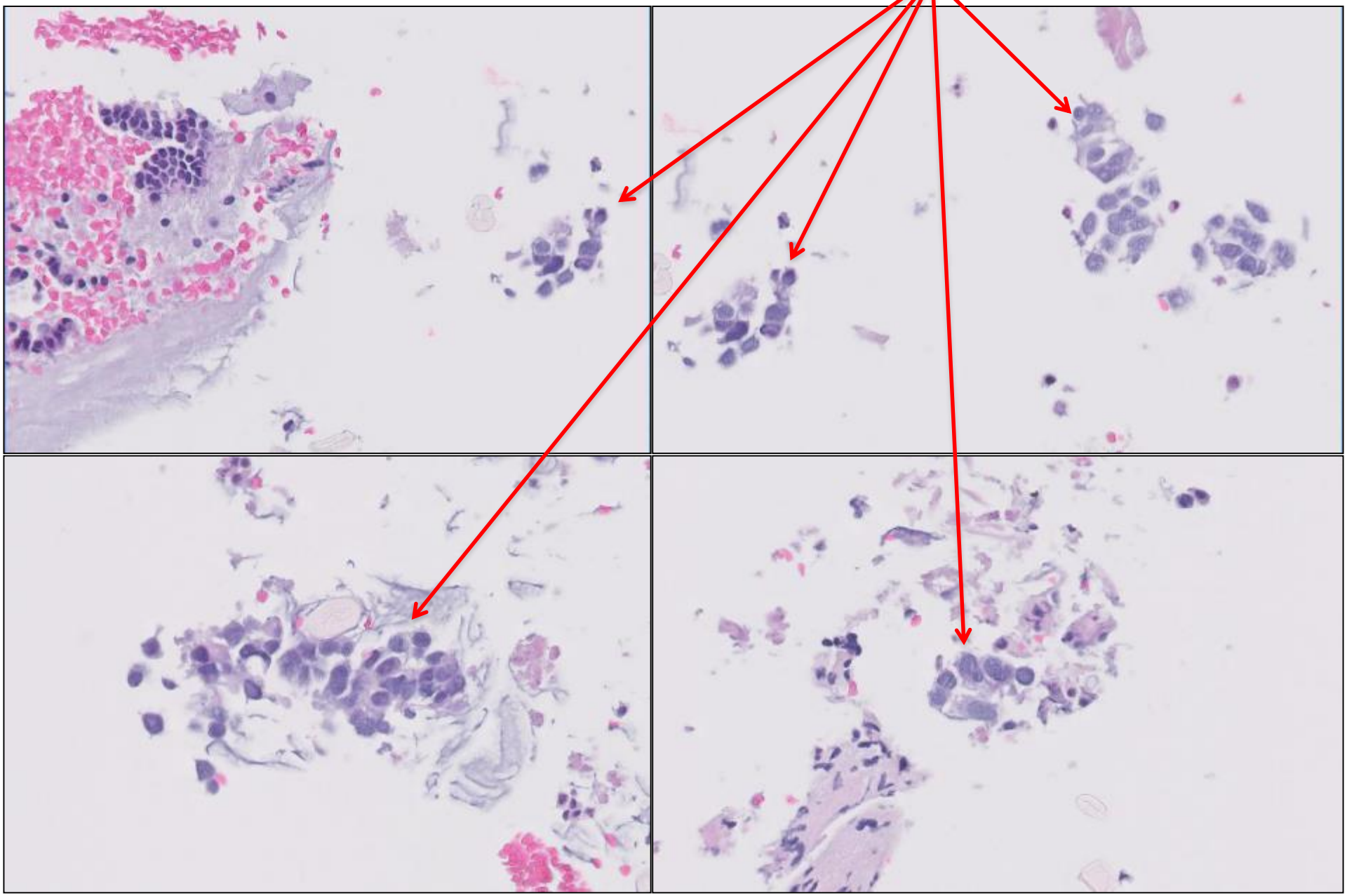

Endocervical curettage: clusters of malignant cells

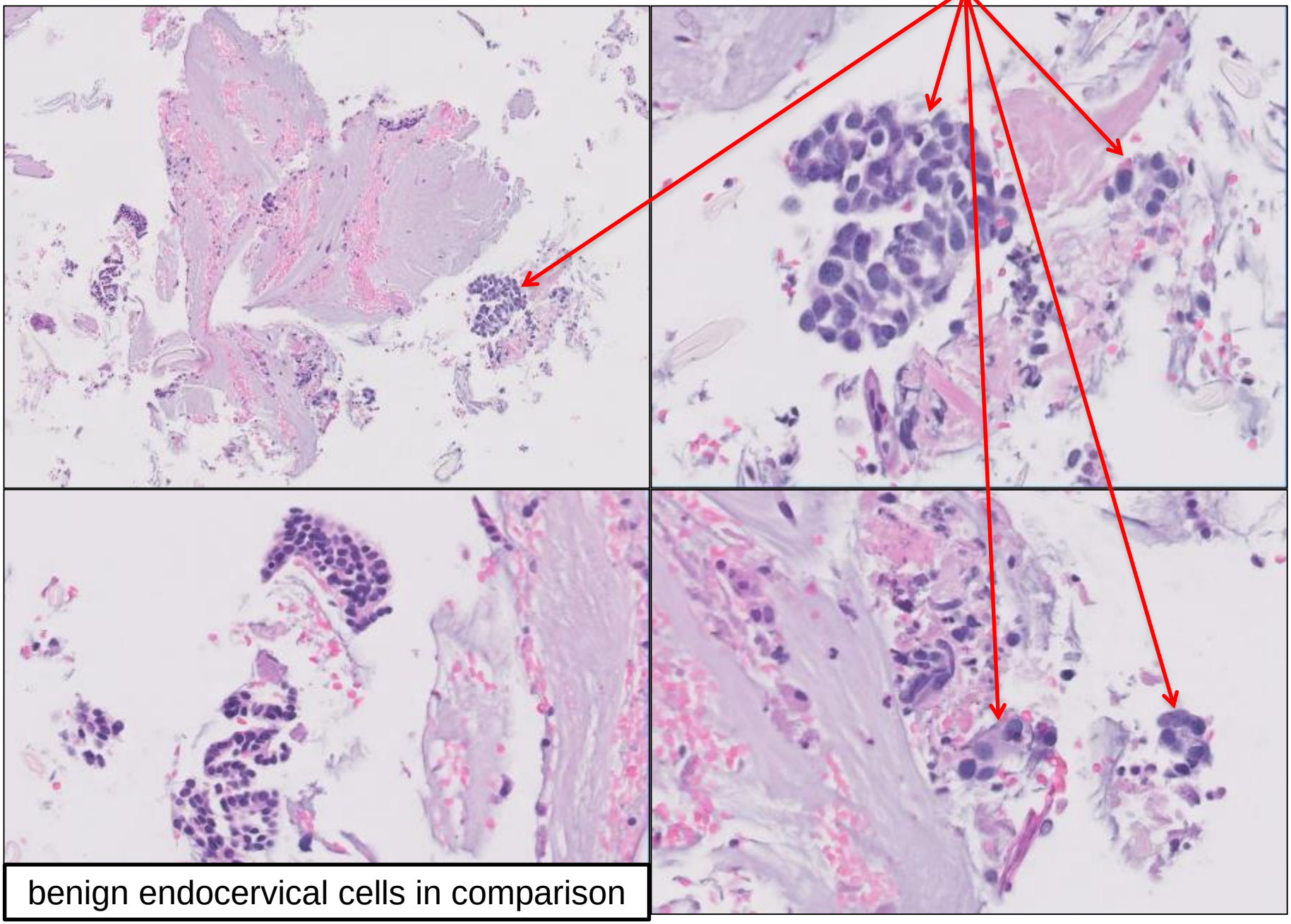

benign endocervical cells in comparison

Diagnostic difficulty - immunohistochemical study
malignant but typing is problematic

- Positive: Cam5.2, EMA, E-cadherin, CD10 (weak)
- Rare positive cells: chromogranin, synaptophysin
- Negative: GATA3, PAX-8, WT1, ER, PR, Her2/neu, p16
  Conclusion: neither gynecologic cancer nor metastatic breast cancer looked likely
- The possibility of tissue contamination considered,
  - deemed unlikely given the presence of malignant cells in two separate specimens (endometrial and endocervical)
  - also, Pap-test showed atypical glandular cells, though on review, they look different →

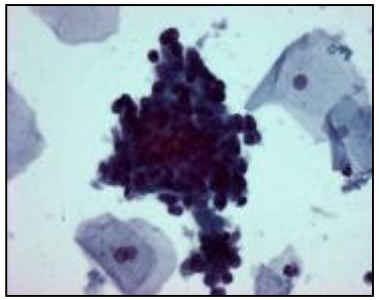

selected immunohistochemical result

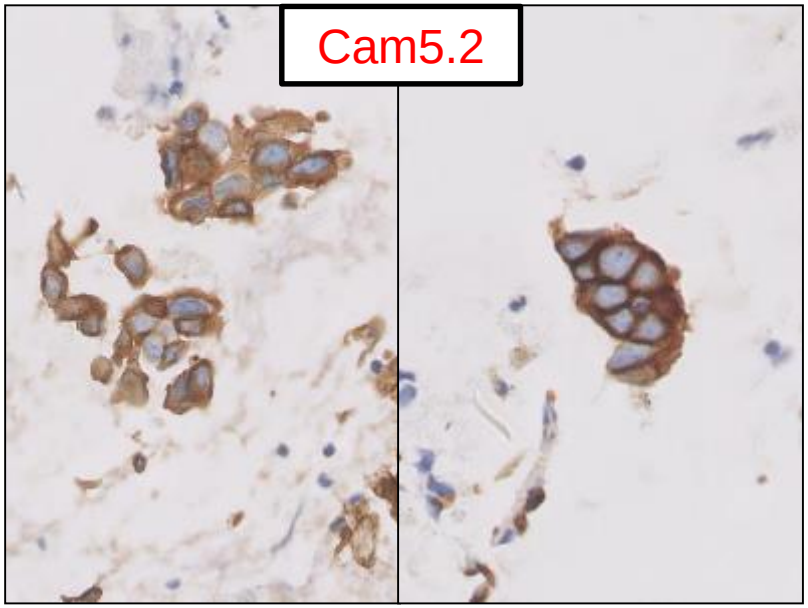

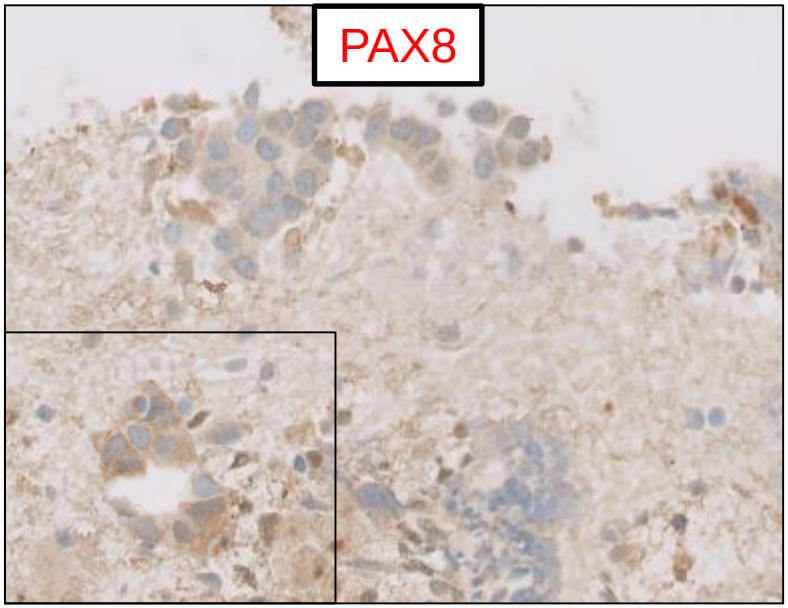

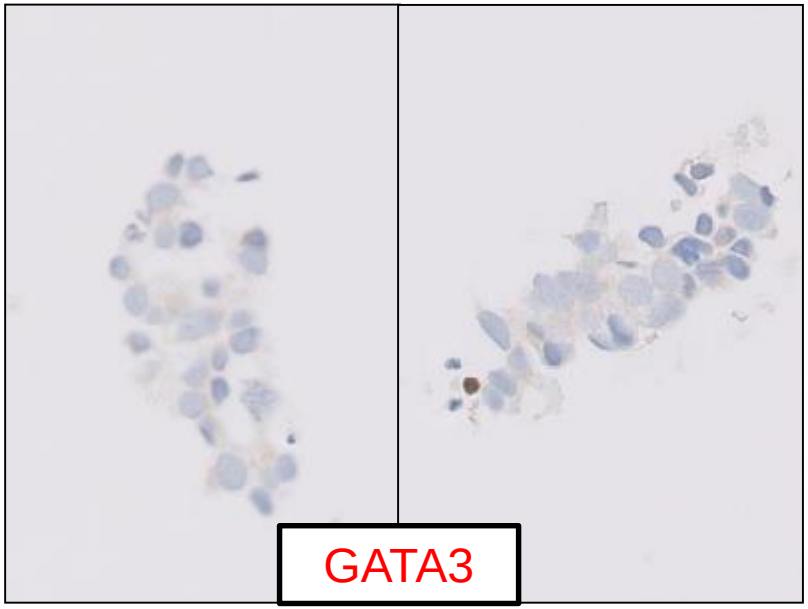

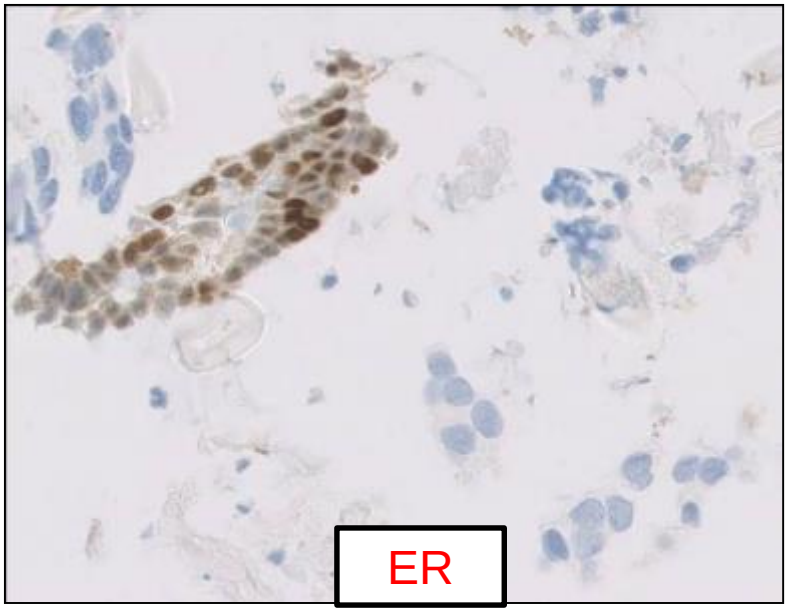

Diagnostic difficulty discussed with the clinician

- Some morphologic overlap with the breast carcinoma
- However, immunohistochemical profiles different: breast carcinoma was ER, PR and GATA3 positive
- Repeat curettage suggested
- Repeat endometrial and endocervical curettage failed
- The clinician referred the patient to a gynecologic surgeon

Gynecologic surgeon decided to perform surgery

- Intraoperative consultation:
  no grossly visible tumor in the hysterectomy specimen
- Surgeon proceeded to bilateral salpingo-oophorectomy, omentectomy and pelvic/paraaortic lymphadectomy
  no grossly visible tumor either
- All tissues submitted for histologic examination:
  no cancer identified
- What has happened?

Tissue contamination (tissue “carryover”)?

- All histologic slides produced on the same day reviewed
- Three other cases from different patients also contained small malignant tissue fragments similar to those found in the index case (they were missed at the original histologic examination, however – no impact on patient care)
- The source of contamination identified: abundant, focally necrotic fragments of a high grade prostatic adenocarcinoma in a transurethral resection specimen

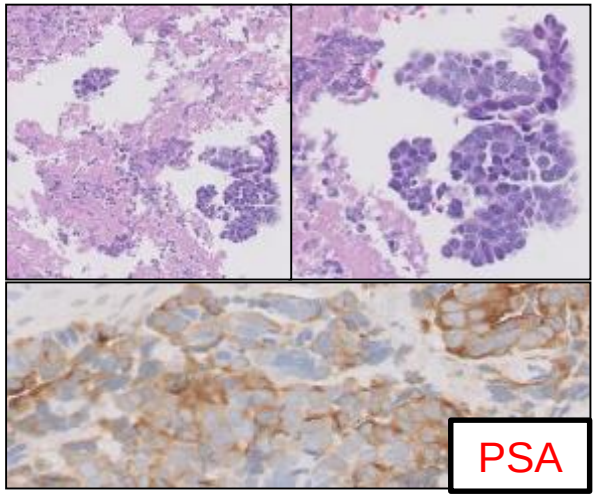

Tissue contamination - tissue “carryover”

- Tissue “carryovers” are contaminants that become incorporated into the paraffin-embedded tissue block of an anatomic pathology case
- They represent a source of potential diagnostic error
- In contrast to well-described tissue “floaters” or “pickups” which occur during slide cutting & staining, carryovers have traditionally been attributed to either the grossing bench or the embedding station

How did the “carryover” happen?

Root cause analysis using the electronic tracking record

- Gross examination – excluded
- Embedding – excluded
- Microtomy – excluded
- Can any other mechanism be considered?
- What is the incidence of “carryovers” in our laboratory?

  At the University of Chicago, an increased number of cases were found to be affected by carryovers after the relocation of the grossing room to a distant site from the histology laboratory

Another example of tissue contamination
pilocytic astrocytoma contaminated by neuroblastoma

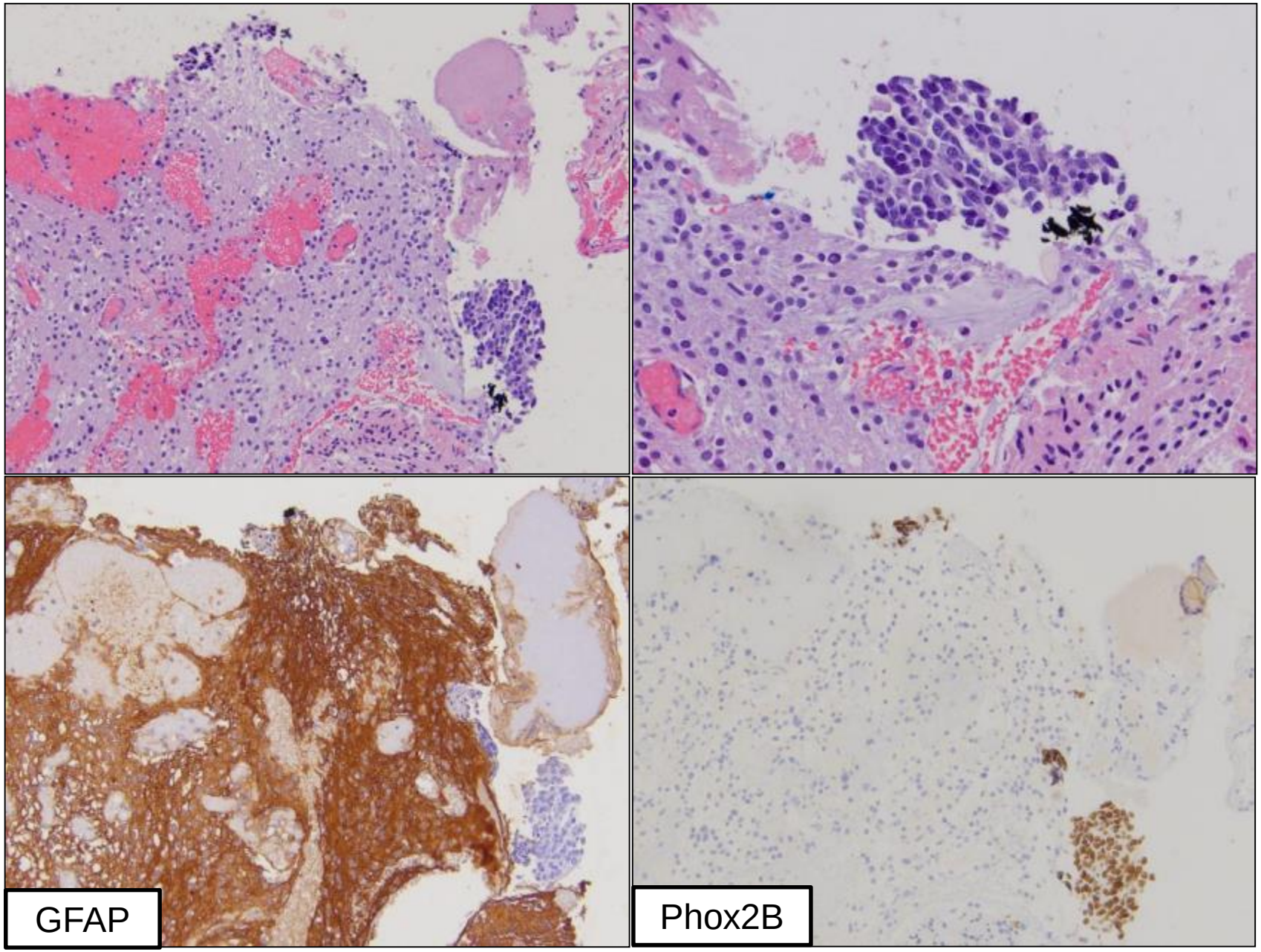

Relocation of the grossing room
to a distant site from the histology laboratory

New hospital with 30 operating rooms
and new “state of the art” grossing room

Department of Pathology
histology laboratory



Increased frequency of tissue contamination, but why?

Grossing room in the new hospital

Specimen transport: pneumatic tube system





Tissue “carryover”
What other mechanism can be considered?

- Somehow tissue fragments “escaped” from mesh bag in one cassette and contaminated other cassettes containing different specimens, but how?
- Workflow analysis suggested that contamination was likely the result of transporting cassettes from the relocated gross room to the histology laboratory via pneumatic tube system
- Literature review reveals very little information regarding the factors that promote case contamination by carryovers beyond the grossing bench and the embedding station
- No credible data available regarding adverse events during the transport of tissue from grossing bench to histology processor

Investigation towards the suitability of pneumatic tube system in transporting tissue cassettes

Methods

- Various “donor” tissue composed of friable tumors (urothelial carcinoma, colorectal adenocarcinoma, lung adenocarcinoma, and clear cell renal cell carcinoma) and “recipient” tissue composed of spongy benign tissue (lung and placental parenchyma) were obtained
- They were packed into several runs, in which cassettes of donor and recipient tissue placed together in formalin in an airtight container and shipped via hospital pneumatic tube system from the gross room to the histology laboratory





One of the pneumatic tube stations





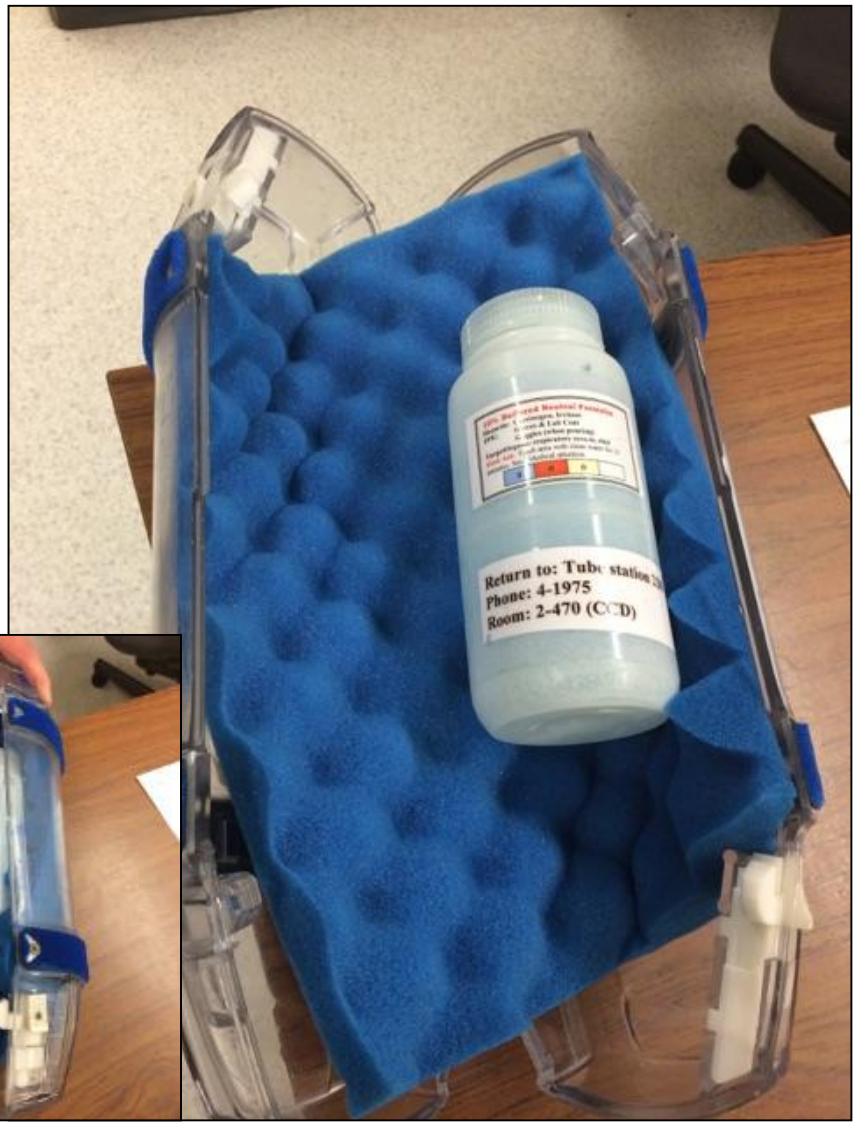

Methods cont.

- Several iterations were submitted with variation in tissue selected as well as in the means of tissue packing: “naked”, in occlusive filter paper, between sponges, and in occlusive mesh bags
- Cassettes were submitted for routine histology processing, embedding, cutting and staining after transport through the pneumatic tube system
- To reduce the chance of contaminants prior and subsequent to transport, tissue was prepared at separate grossing stations and on different days, and embedding of recipient tissue was performed prior to that of donor tissue

Methods cont.

- Single H&E slide from each block was reviewed for contaminants attributable to carryovers
- Formalin from each transport run was retained, from which samples were taken for cytospin examination
- Select mesh bags housing recipient tissue were subjected to scraping and cell blocks prepared to evaluate for adherent contaminants

Results

- In total, 121 cassettes were processed and submitted across 10 transport runs
- 19 of these cassettes exhibited contaminants appreciated as due to carryovers on histologic review (15.7%) including in the paraffin blocks of donor tissue
- Several cases demonstrated contamination from multiple sources
- 10 blocks displayed fragments of urothelial carcinoma, 8 blocks displayed placental villi
- 7 blocks contained fragments of colorectal carcinoma

Impact of the packing material on rate contamination
Results

- Relative rate of contamination of recipient blocks by packing material: 21.7% “naked” recipient blocks, 20% with sponges, 8.1% with filter papers, 16.2% with mesh bags
- Effect of packing of donor blocks on recipient block contaminant rate: 17.4% “naked” donor block, 25% with sponges, 4.3% with paper, 3.0% with mesh bag
- Cytospin preparation of transport fluid showed markedly increase loose tissue fragments in runs with “naked” donor blocks in comparison with all other packing methods

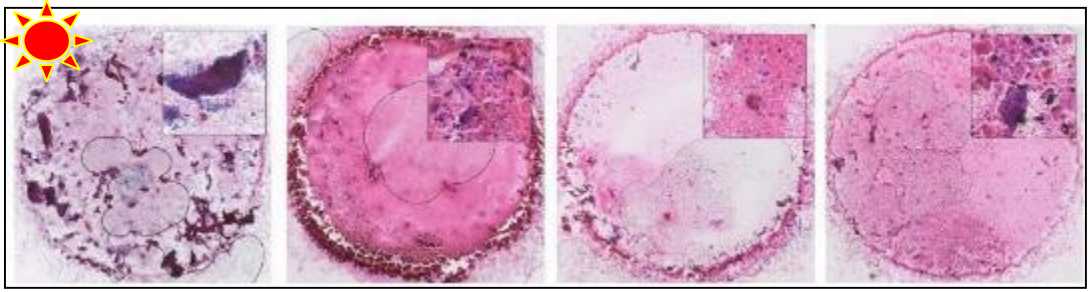

Examples of contamination of “recipient” blocks following pneumatic transport of cassettes

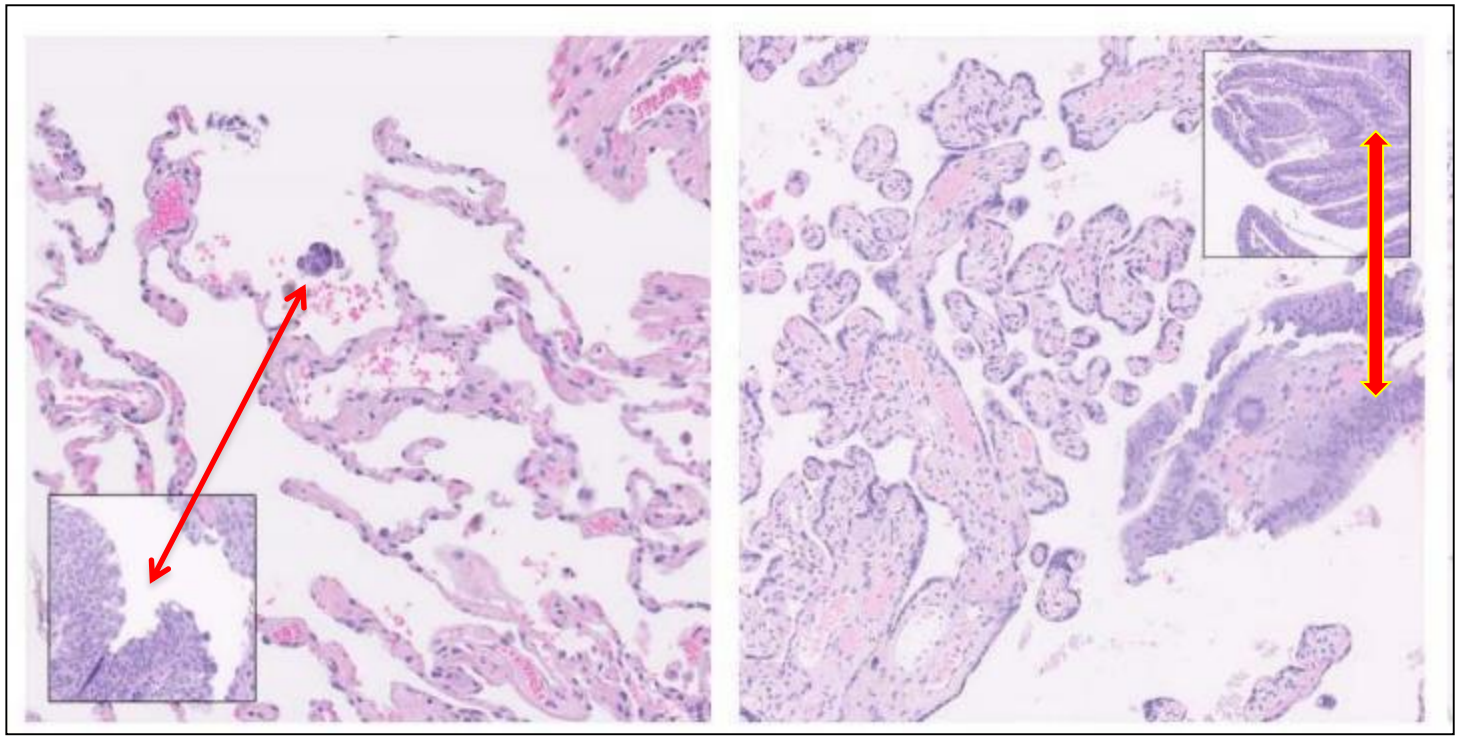

Contaminant urothelial carcinoma in “recipient” lung block

Contaminant colonic carcinoma in “recipient” placental block

Is pneumatic tube system safe to transport tissue cassettes in formalin?

- The rate of contamination of blocks (15.7%) was markedly higher than that typically expected during normal clinical practice
- The results of the investigation implicate specimen packing and transportation as a potential source of contamination in addition to the grossing bench and embedding station
- Pneumatic tubing of tissue blocks can result in substantial tissue contamination and should be avoided
- Although the use of occlusive packing material appeared to reduce the presence of donor tissue contaminant in fluid transport media, they appeared to be insufficient to completely prevent contamination in any recipient block

Is pneumatic tube system safe to transport tissue cassettes in formalin?

- During pneumatic tubing small tissue fragments may leak-out from tissue cassettes to the formalin bath even when occlusive packing method used
- Subsequently, these may contaminate other tissue cassettes
- Contaminating tissue fragments can adhere to the outside of the mesh-bags therefore can be a source of contamination during embedding
- Electronic tracking of histology blocks aid in the investigation of unusual or unexpected sources of contamination

Case 1
reflections

- Tissue contamination, even though considered, but originally not investigated
- No literature data on tissue contamination between specimens occurring during transport of histologic cassettes by pneumatic tube system, but the presented special study confirmed such eventuality
- No proper communication between the clinician and the gynecologic surgeon (gynecologic surgeon assumed a specific diagnosis of carcinoma of gynecologic origin)
- Gynecologic surgeon ignored the result of intraoperative consultation and proceeded to bilateral salpingo-oophorectomy, omentectomy and lymphadenectomy

Case 1
concluding remarks

- Possibility of tissue contamination must be investigated when either the clinical or the pathologic data do not match
- Pneumatic tube system is not suitable for transporting tissue cassettes in formalin “bath”
- Mesh-bags, filter paper, tissue cassettes are not fool proof
- Proper communication between pathologists and all clinicians involved with the care of the patient is a must
- Litigation/compensation cost of misdiagnosis in this particular case was: $1,500 000

University of Chicago Department of Pathology
special circumstances

- Operating rooms and grossing room are located in a new hospital building, 10 minutes walking time from the histology laboratory and from surgical pathology
- Pneumatic tube system is operating successfully (with minor glitches) for specimen transport between operating rooms and gross room
- Special investigation revealed that tissue contamination may occur between different cassettes in formalin bath when transported by pneumatic tube system

University of Chicago Department of Pathology

changing the transport of histologic cassettes between gross room and histology laboratory

- Hourly porter/cart transport of tissue containing cassettes dry (not in formalin bath)





Case 1
selected references

- Hollensead SC et al. Errors in pathology and laboratory medicine: consequences and prevention. J Surg Oncol 2004; 88:161-181
- Valenstein PN, Sirota RL. Identification errors in pathology and laboratory medicine. Clin Lab Med 2004; 24:979-996
- Tiwari AK et al. Speed of sample transportation by pneumatic tube system can influence the degree of hemolysis. Clin Chem Lab Med 2011; 50:471-474
- Minato H et al. Specimen misidentification in pathology laboratory: trends and measures. Rinsho Byori 2013; 61:751-759
- Mullins GR et al. Smartphone monitoring of pneumatic tube system induced sample hemolysis. Clin Chim Acta 2016; 462-1-5
- Demetrick DJ. Molecular auditing: an evaluation of unsuspected tissue specimen misidentification. Arch Pathol Lab Med 2018; 142:1407-1414

Case 2
clinical history

- 68-year-old female (G3P3) presenting with uterine bleeding
- Transvaginal ultrasound: large, partly necrotic uterine tumor mass (22 cm); endometrium could not be visualized
- The mass appeared to replace myometrium with metastatic nodules on pelvic peritoneum
- She underwent total abdominal hysterectomy, bilateral salpingo-oophorectomy, peritoneal biopsies, and pelvic/paraaortic lymphadenectomy

Case 2

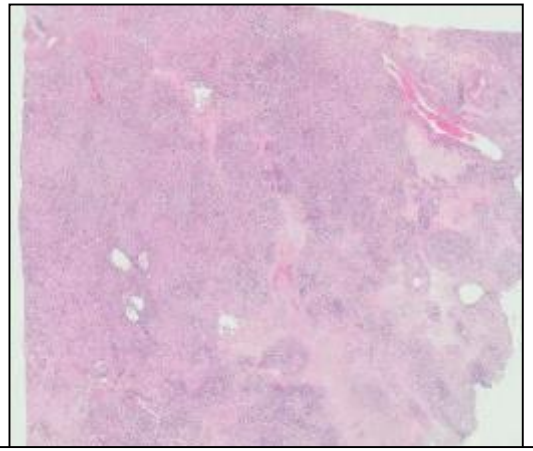

sheets of malignant epithelioid tumor cells with areas of geographic necrosis

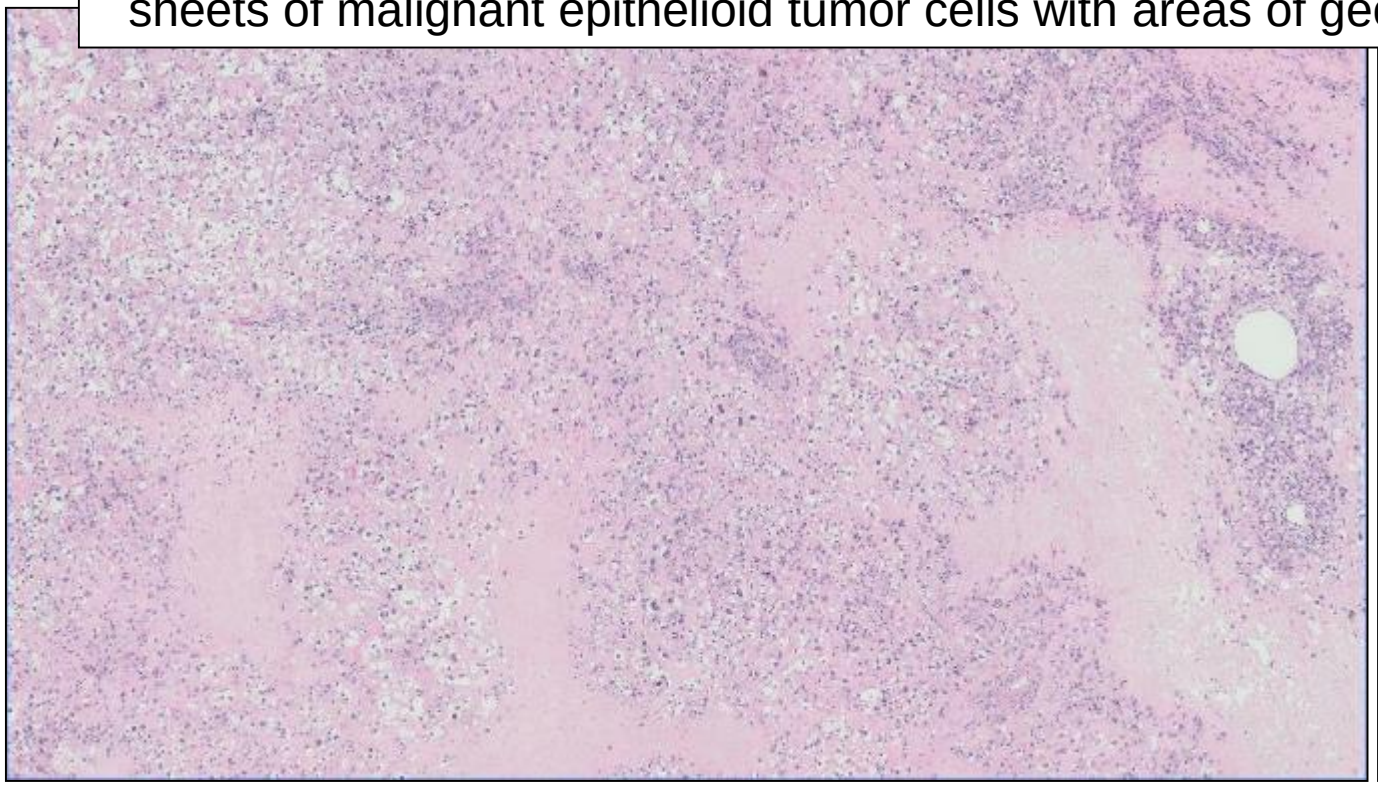

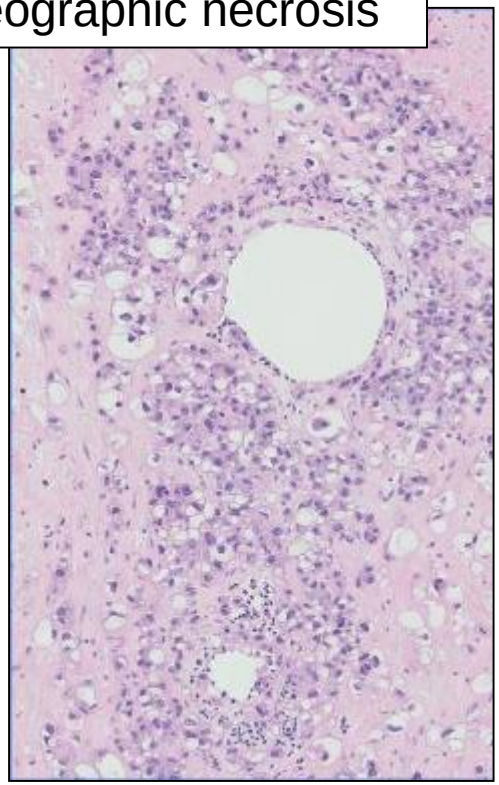

Viable tumor cells with clear cytoplasm in perivascular location

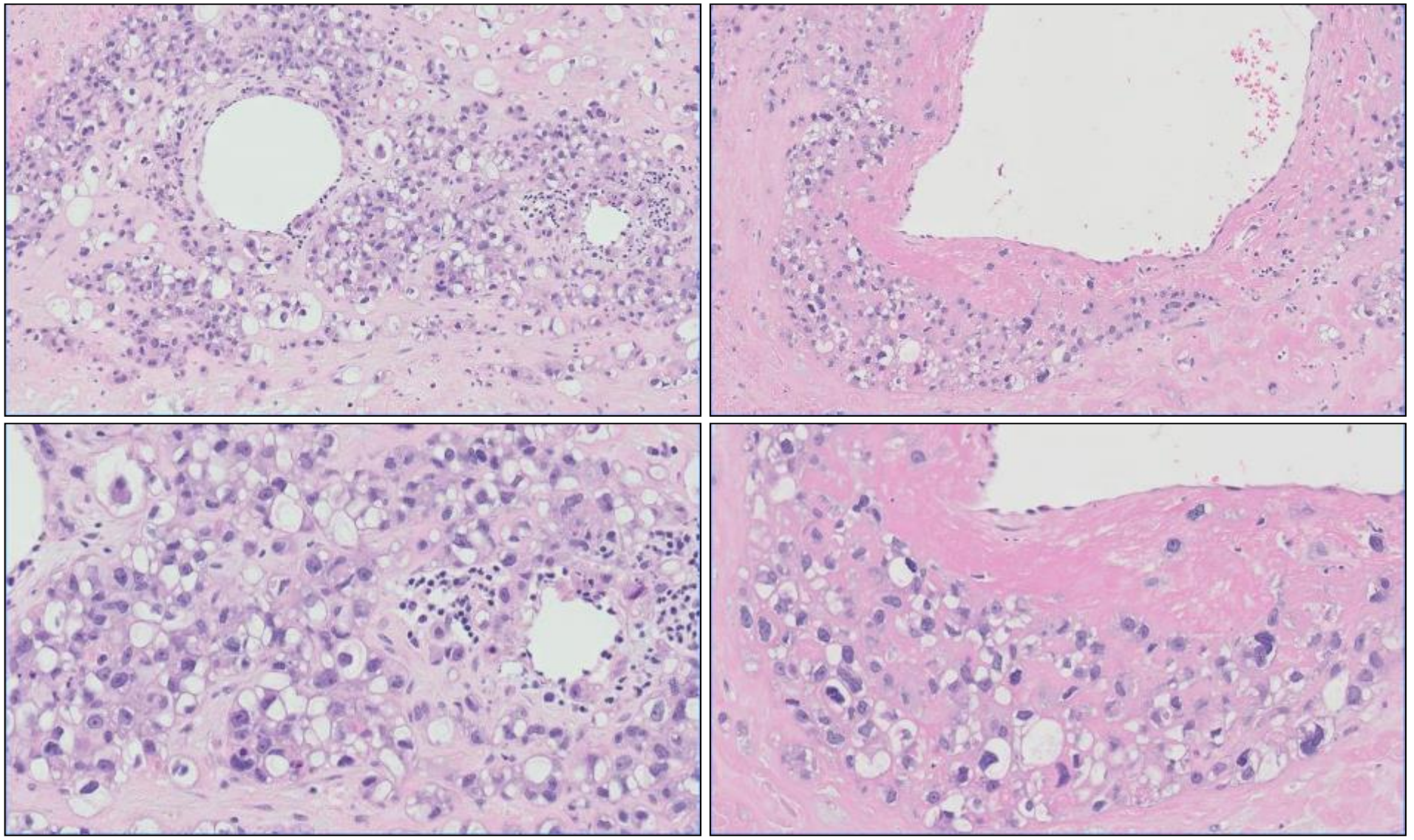

Clear to pale eosinophilic cytoplasm and distinct cell borders

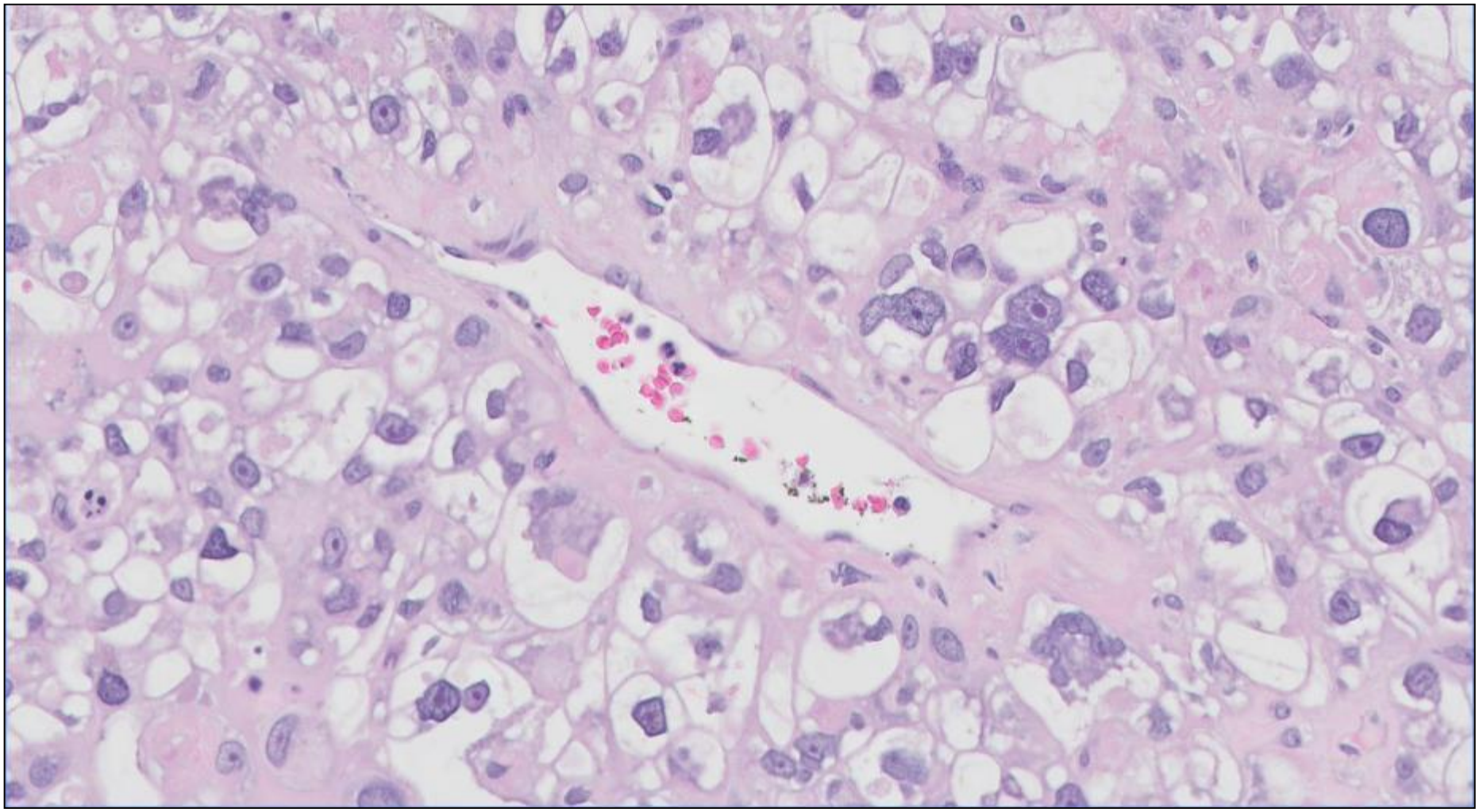

Mitotic figures – variable nuclear pleomorphism

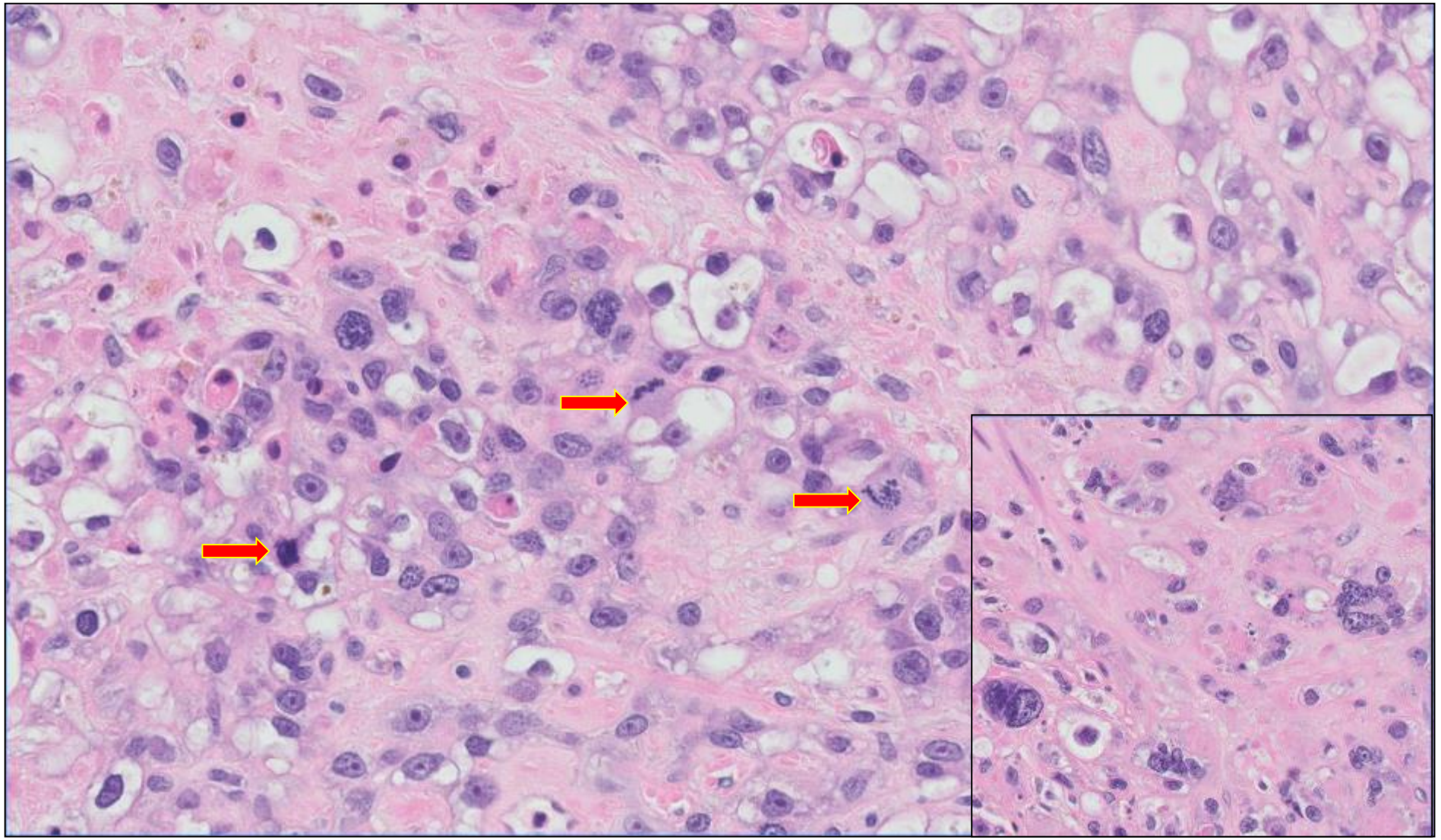

Differential diagnosis

- Carcinoma
  - uterine clear cell carcinoma
  - squamous cell carcinoma with clear cell change
- Mesenchymal
  - leiomyosarcoma, epithelioid variant
  - undifferentiated uterine sarcoma
- Perivascular epithelioid cell tumor (PEComa)
- Gestational trophoblastic tumor
  - placental site trophoblastic tumor
  - epithelioid trophoblastic tumor

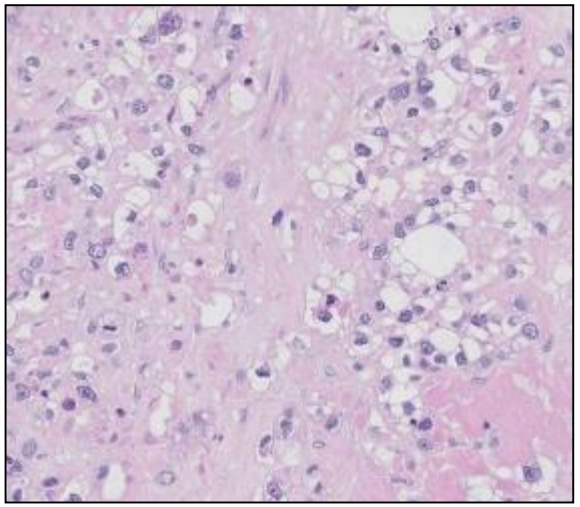

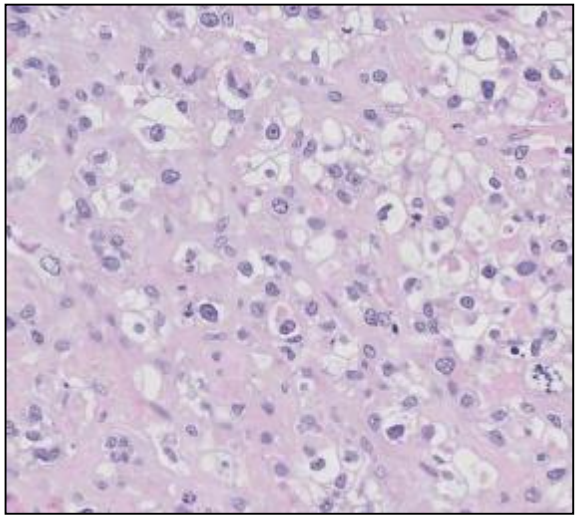

Immunohistochemistry – epithelial markers

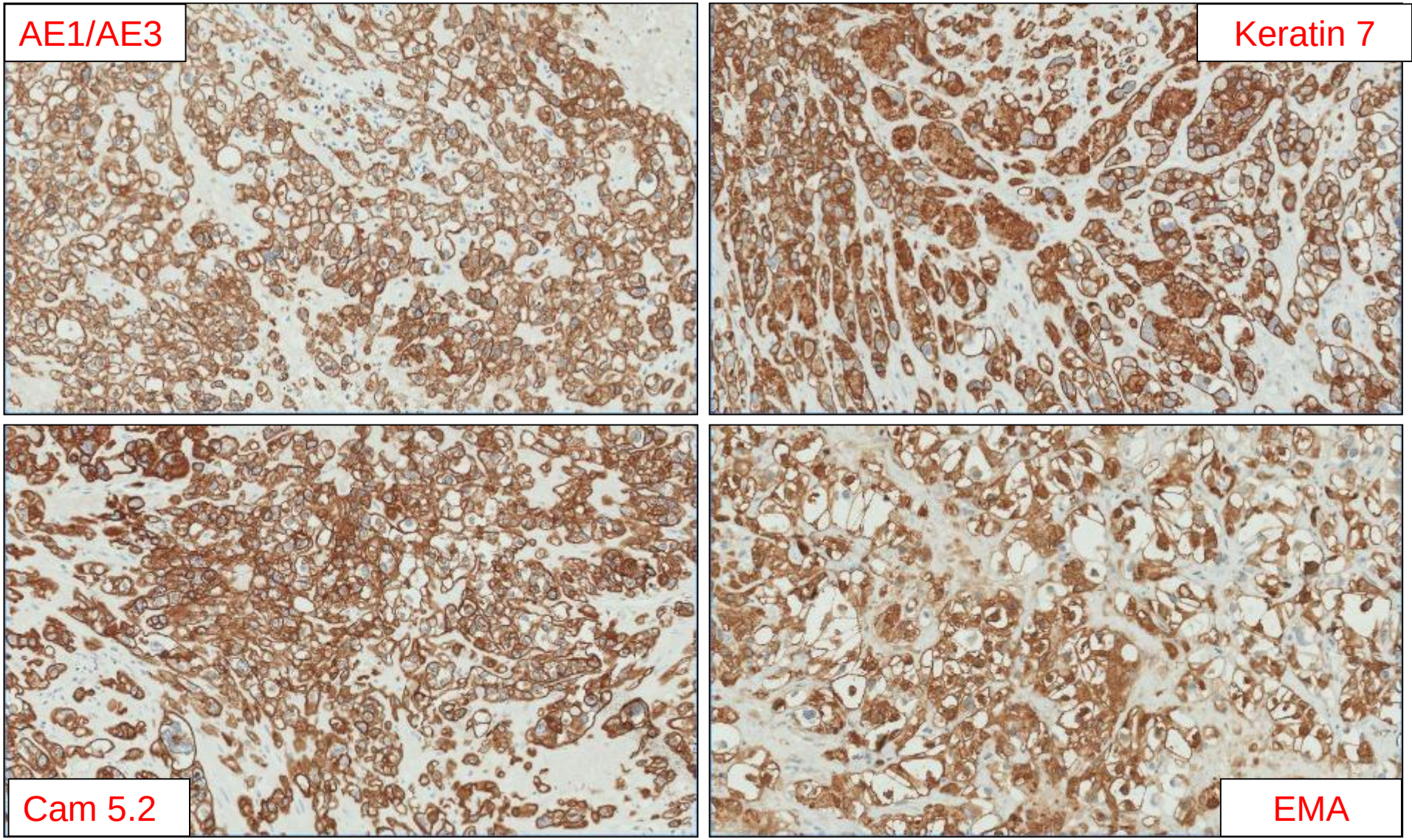

Immunohistochemistry – is it uterine clear cell carcinoma ?



Immunohistochemistry – is it epithelioid leiomyosarcoma?

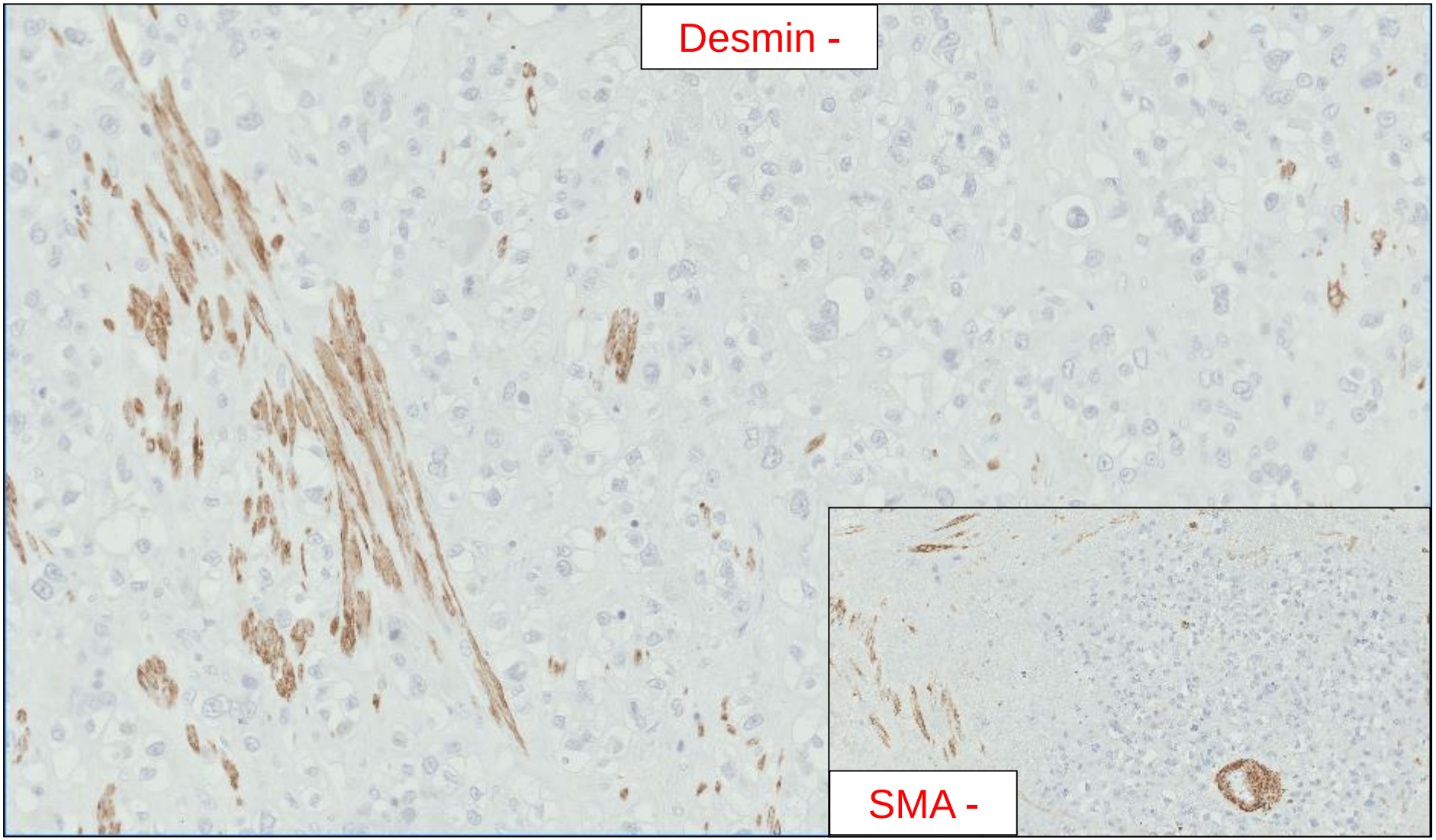

Immunohistochemistry – is it PEComa?

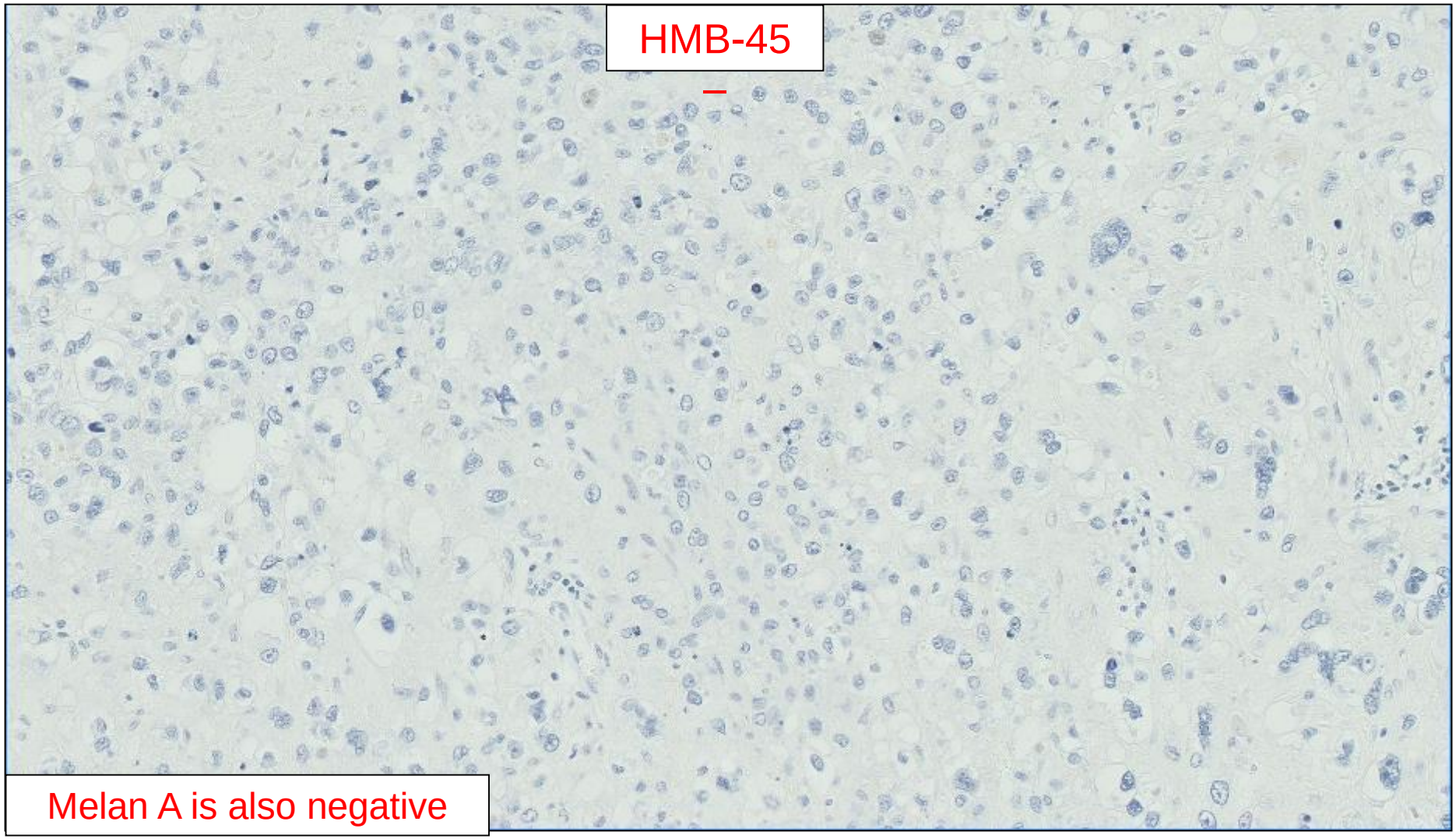

Immunohistochemistry

is it cervical squamous cell carcinoma?

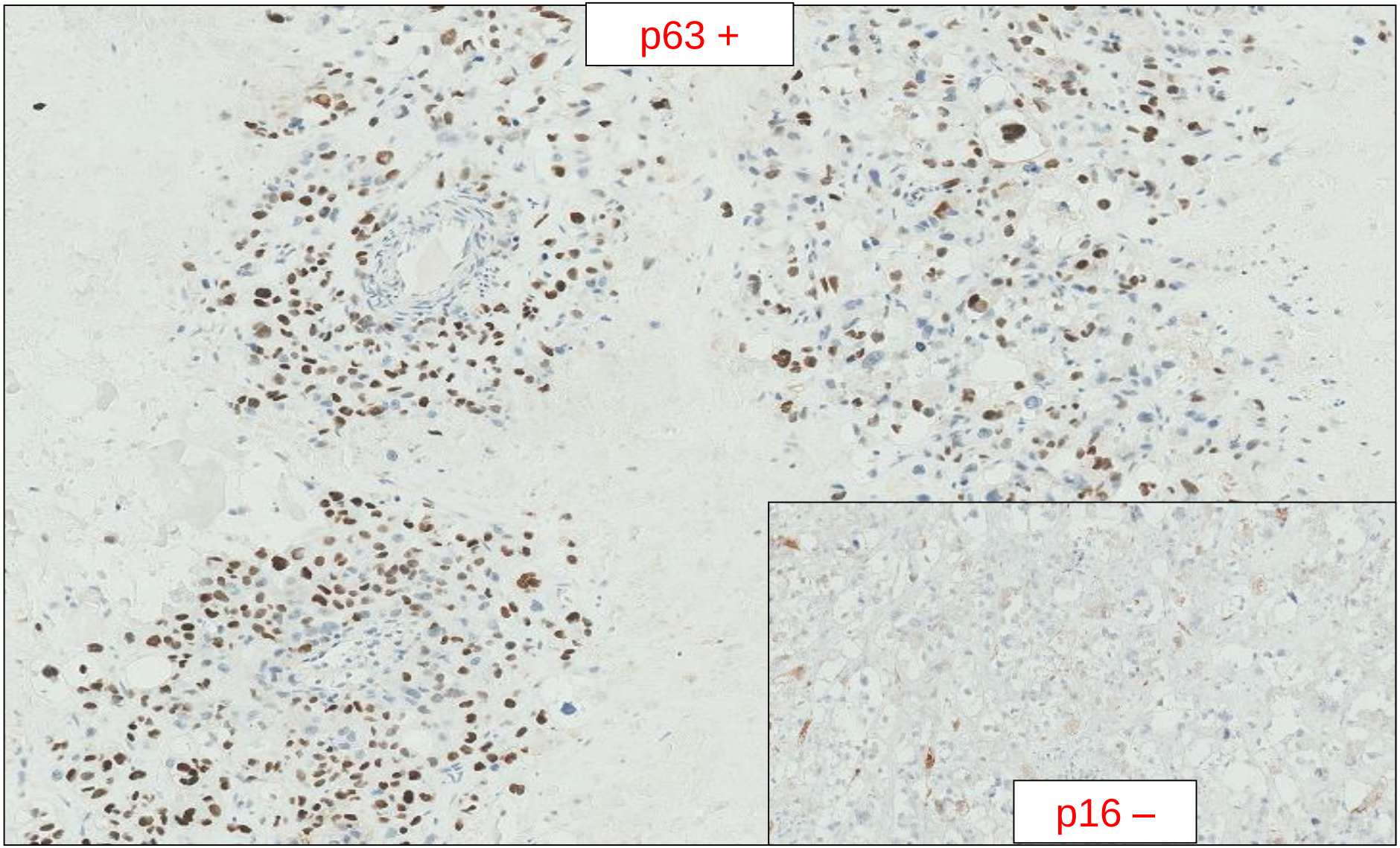

Immunohistochemistry – is it trophoblastic

but the patient is 68 years old

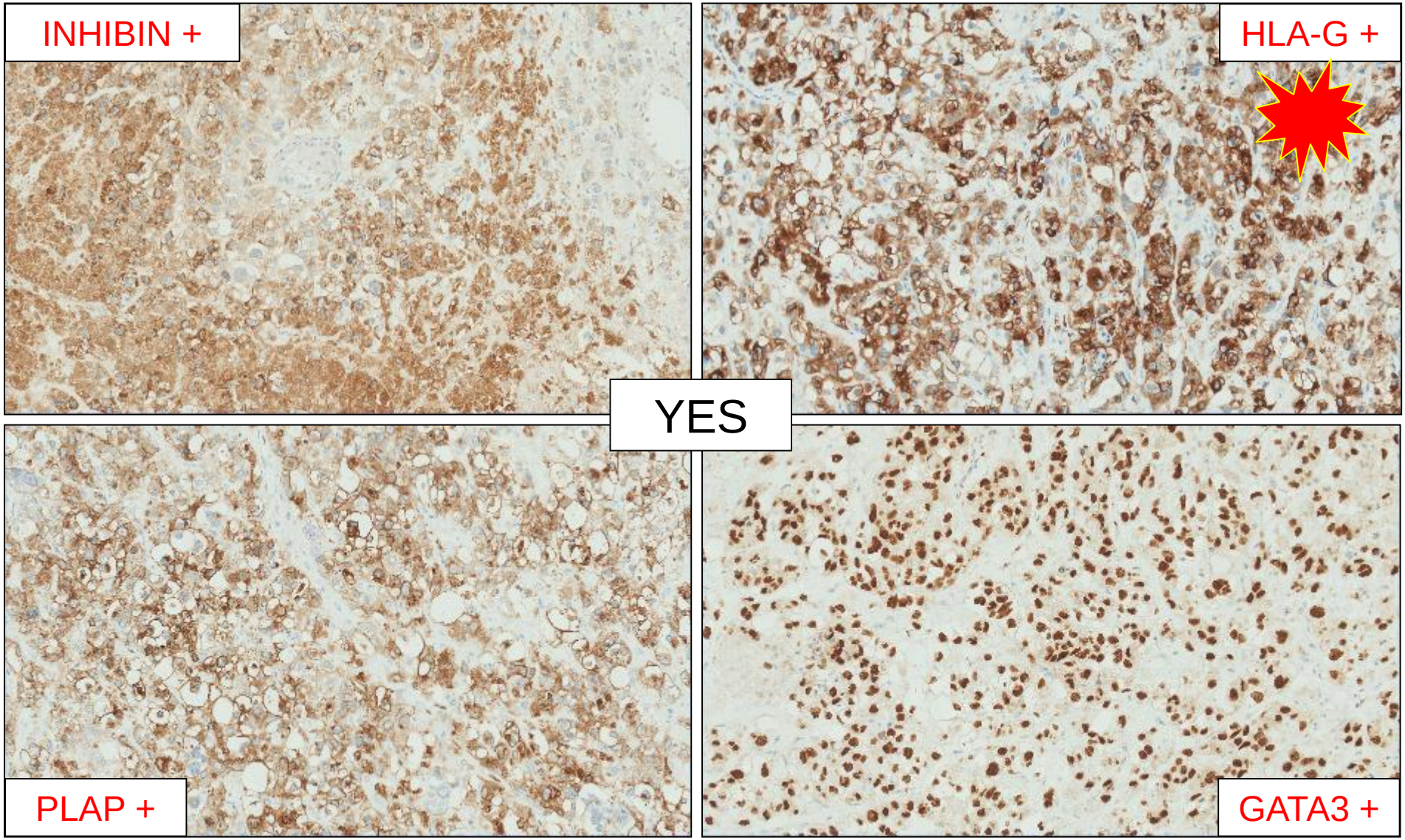

HLA-G immunoreactivity is specific for intermediate trophoblasts in gestational trophoblastic disease

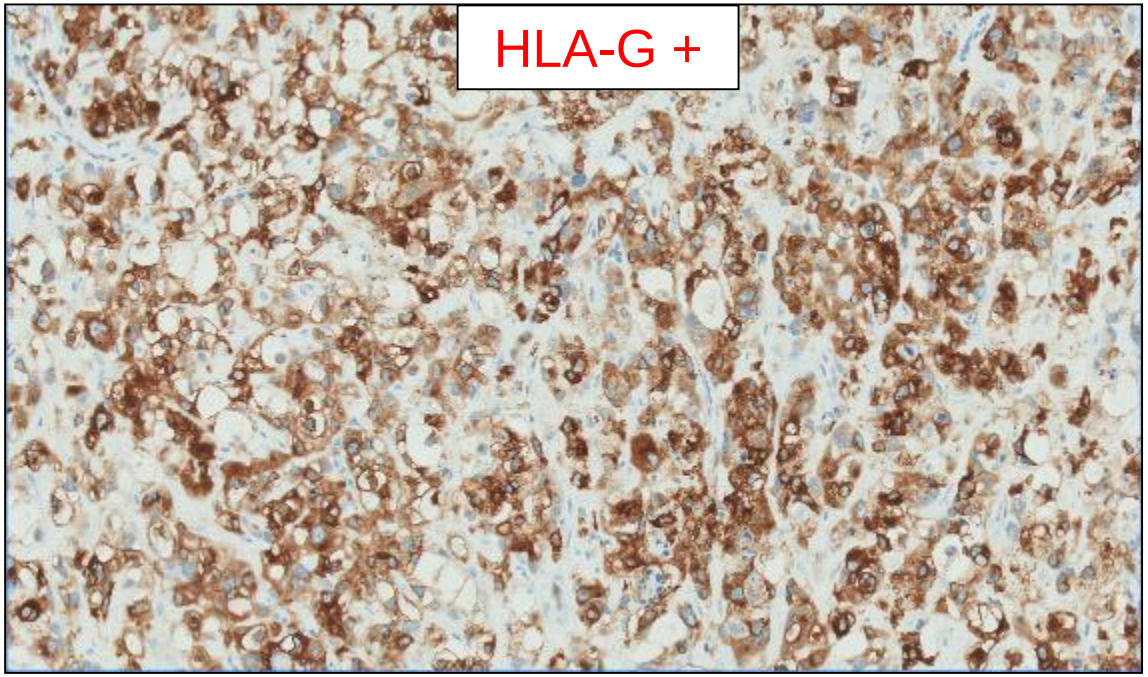

- HLA-G is a nonclassical MHC class I antigen
- A specific marker for intermediate trophoblasts
- Important for the escape of immunsurveillance by host T lymphocytes and NK cells
- Plays a role in maternal tolerance toward fetal tissue

So, it is trophoblastic, but which type?

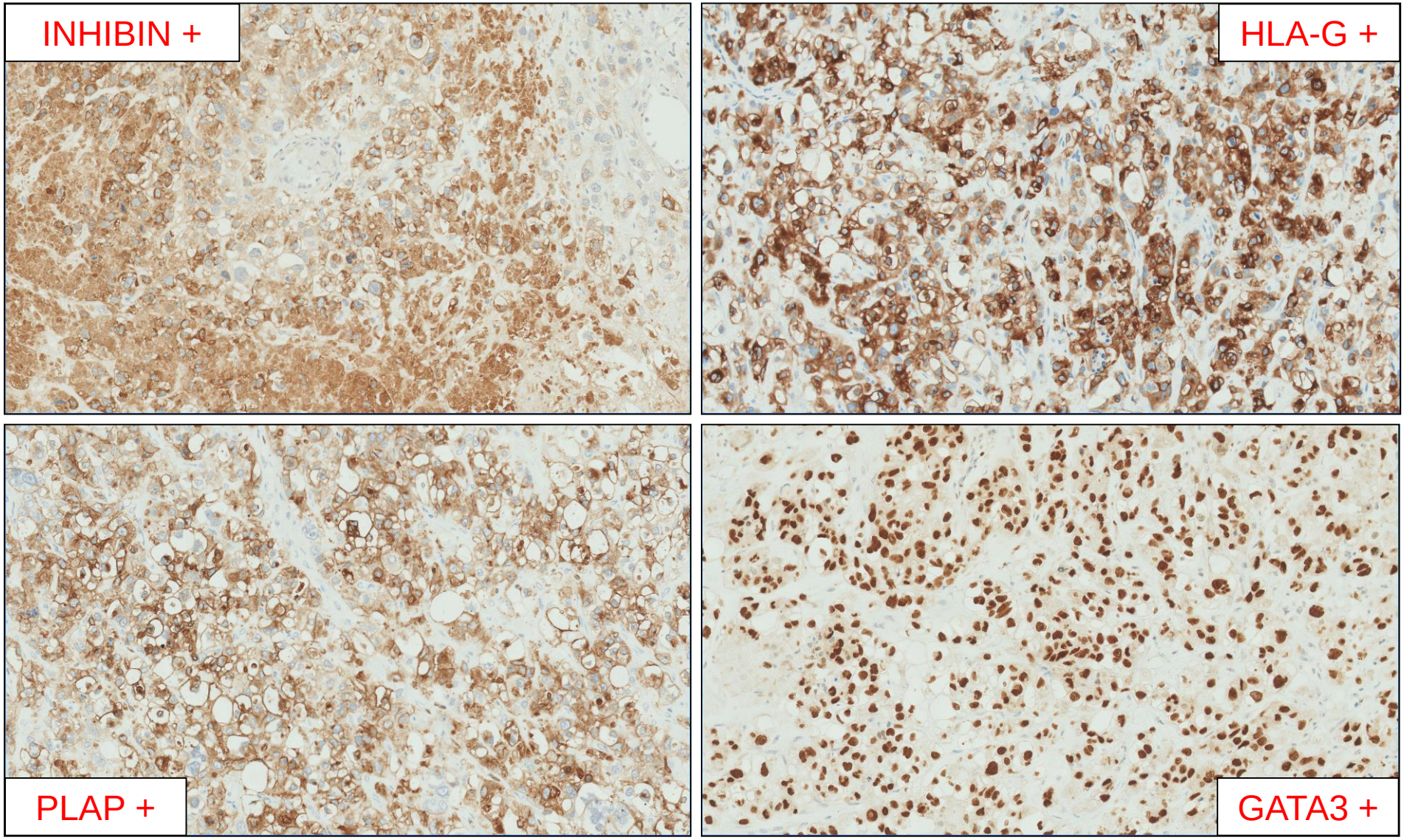

Gestational trophoblastic tumors
3 distinct entities

- Gestational choriocarcinoma
  – differential diagnosis: curettage from early "previllous" stage of gestation, nongestational choriocarcinoma of germ cell or somatic origin
- Placental site trophoblastic tumor
  – differential diagnosis: exaggerated placental site reaction, choriocarcinoma, poorly differentiated carcinoma, epithelioid leiomyoma/leiomyosarcoma
- Epithelioid trophoblastic tumor
  – differential diagnosis: placental site nodule, squamous cell carcinoma, clear cell carcinoma, epithelioid leiomyosarcoma, PEComa

The presented case is NOT a choriocarcinoma

a classic example of choriocarcinoma:

bilaminar pattern: syntitiotrophoblasts and cytotrophoblasts

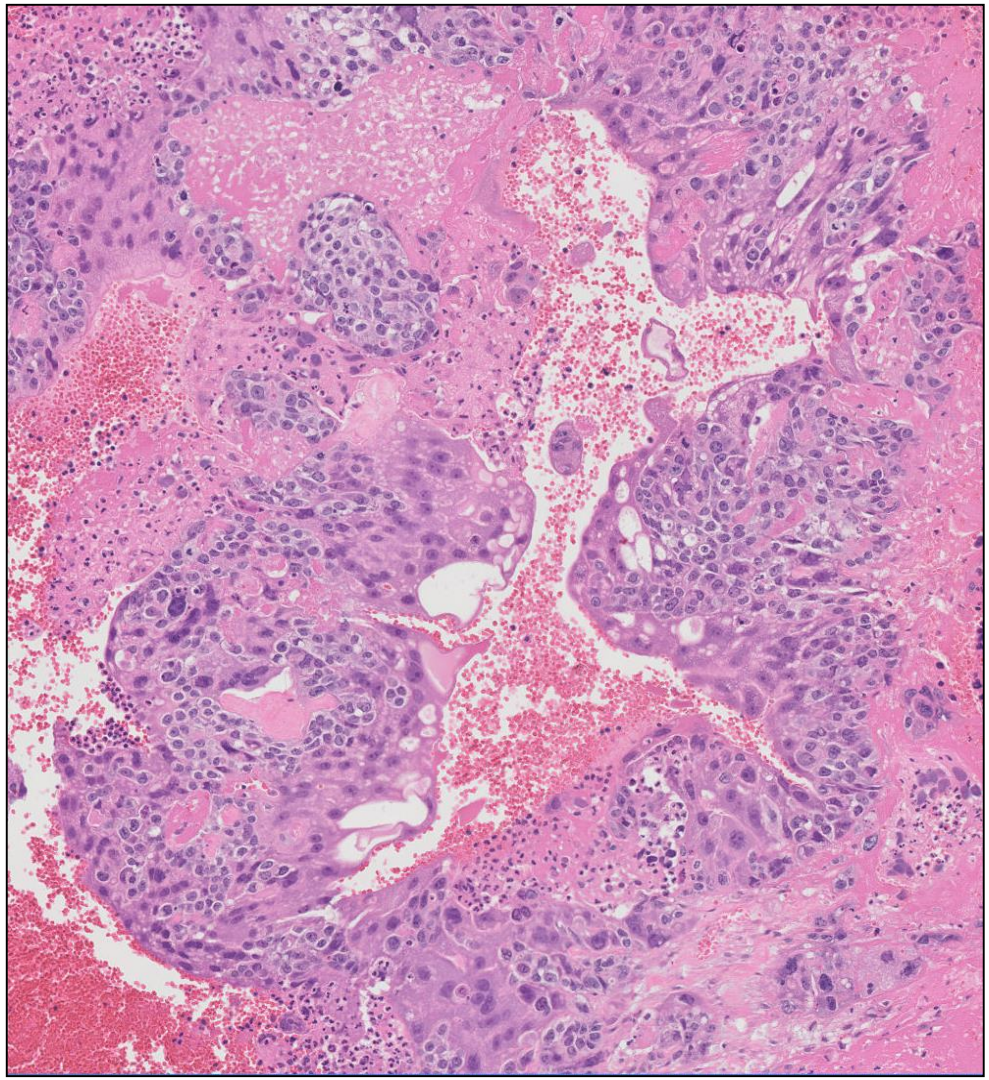

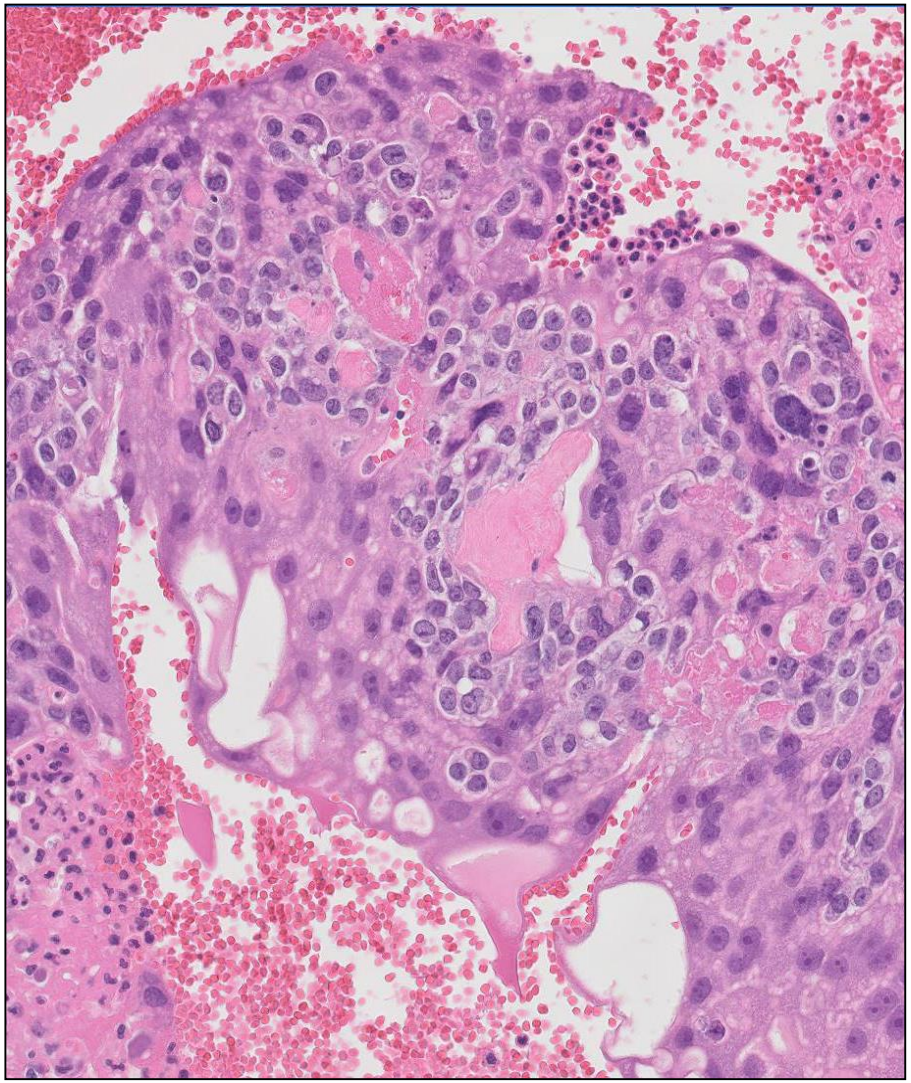

Intermediate trophoblastic tumors and lesions role of p63 and hPL in the differential diagnosis

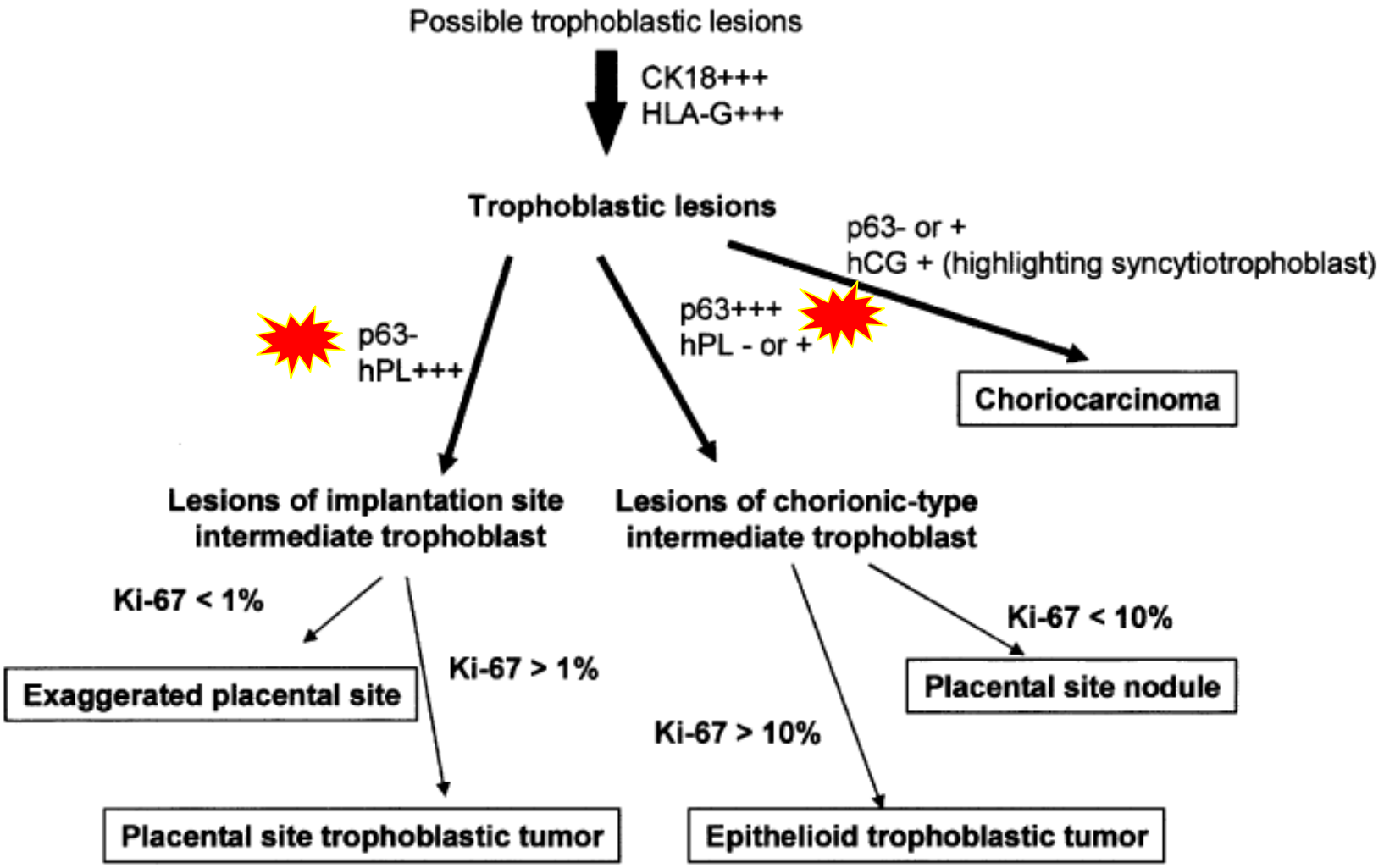

Shih IM, Kurman RJ. p63 expression is useful in the distinction of epithelioid trophoblastic and placental site trophoblastic tumors by profiling trophoblastic subpopulations. *Am J Surg Pathol.* 2004 Sept;28(9):1177-83.

Chorion laeve with chorionic-type intermediate trophoblasts

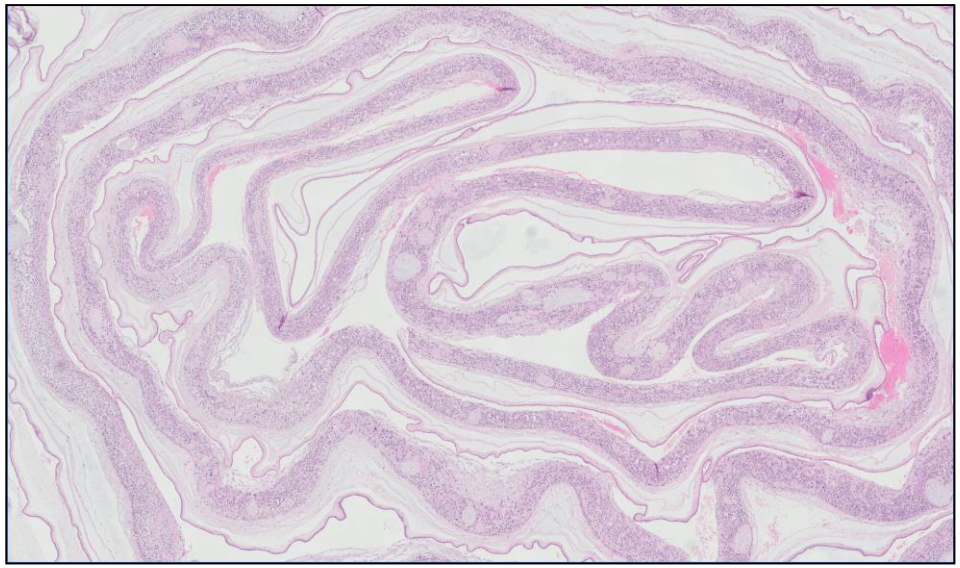
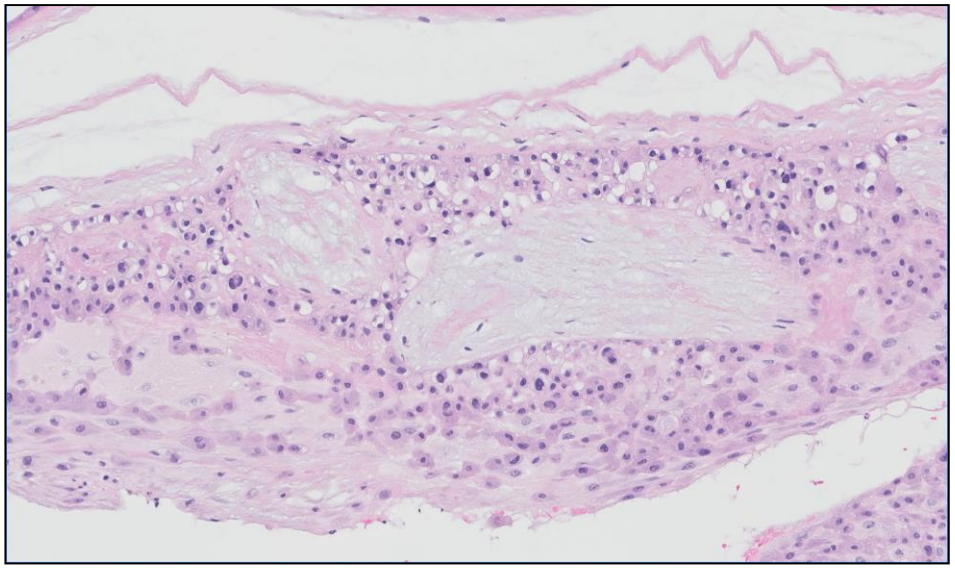
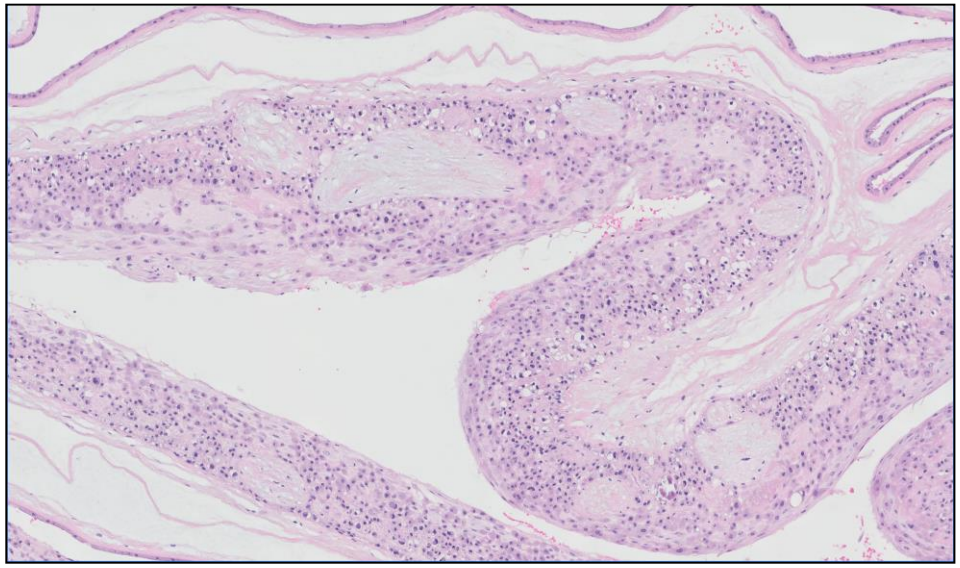
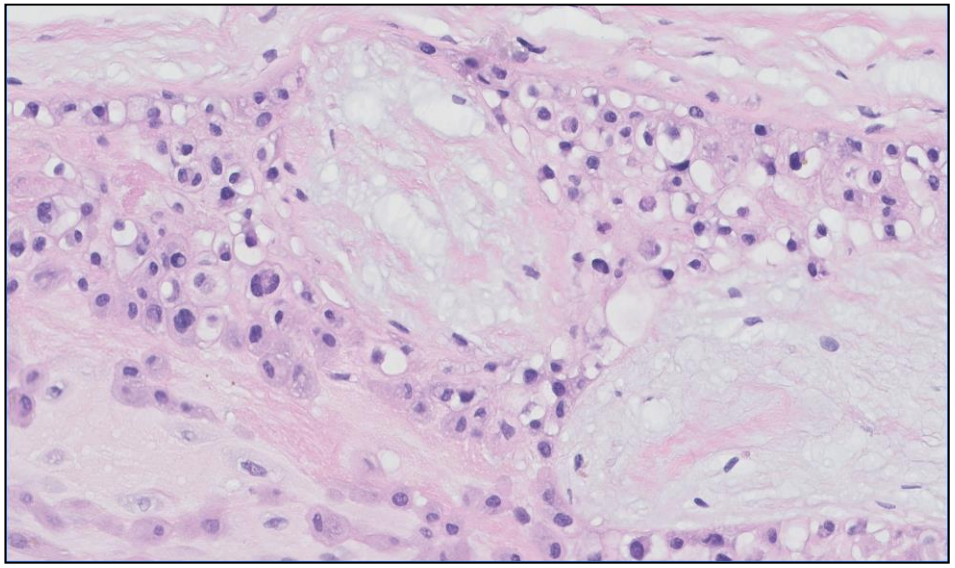

Chorion leave with chorionic-type intermediate trophoblasts

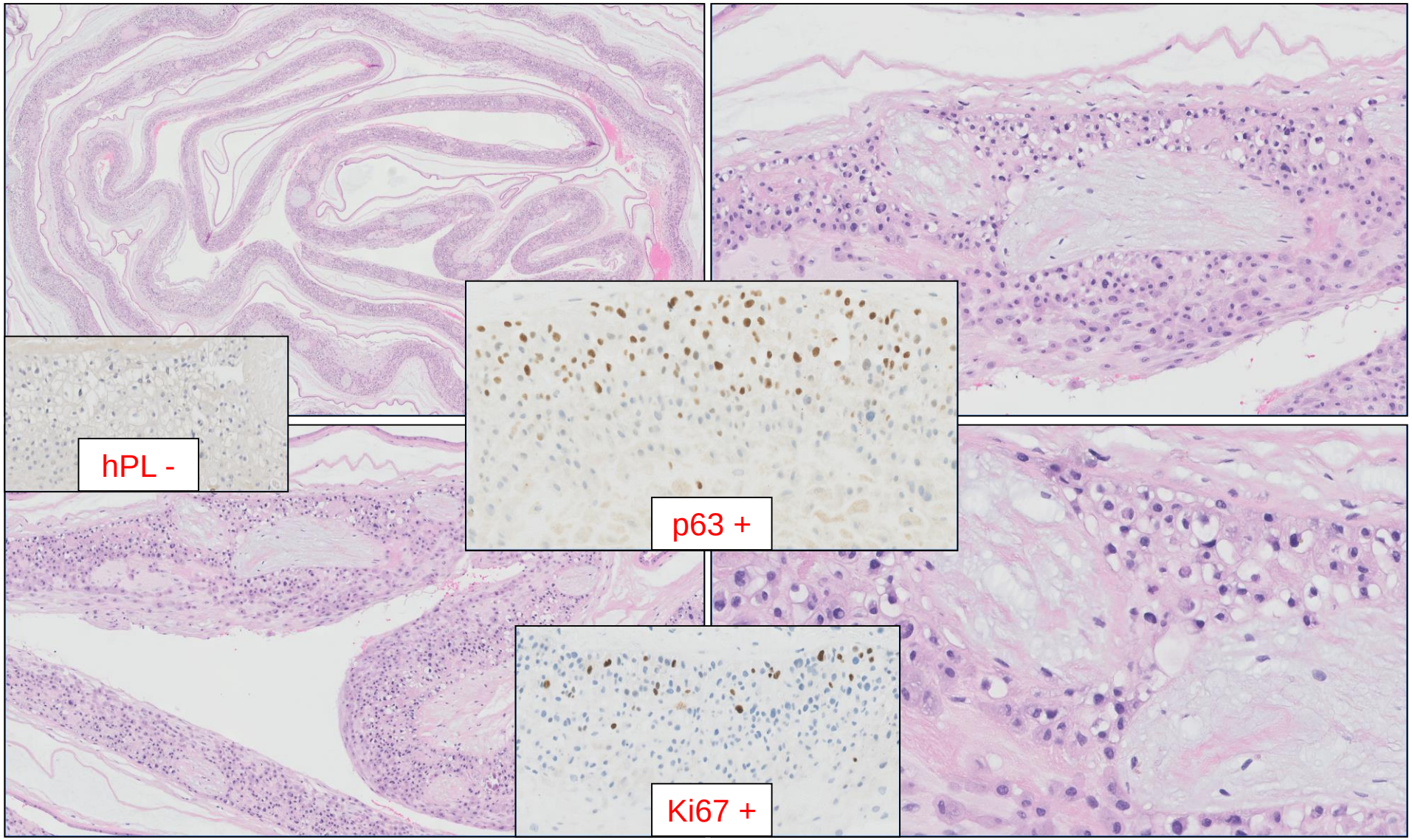

Working diagnosis: epithelioid trophoblastic tumor but the patient is 68 years old…..

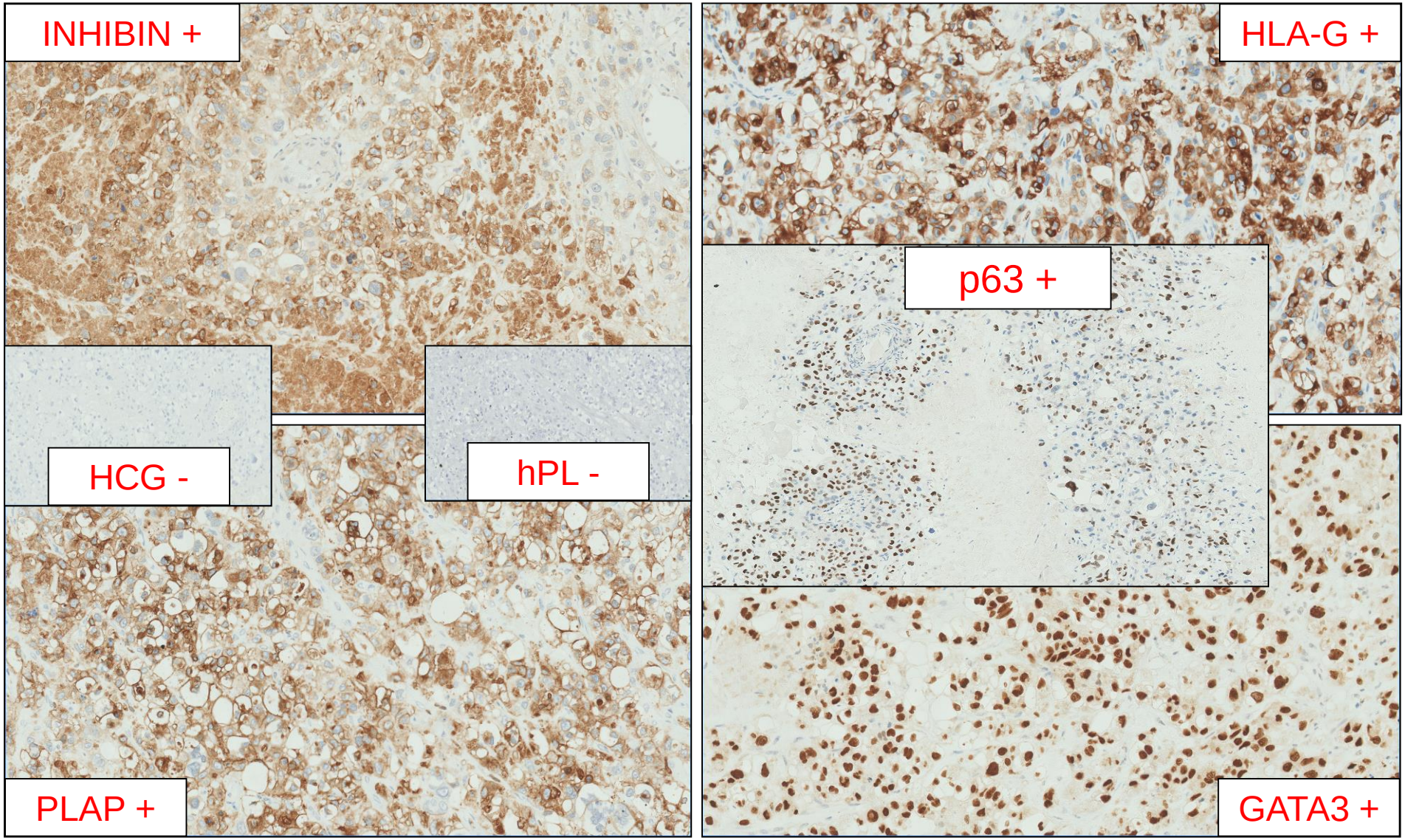

Epithelioid trophoblastic tumor

a neoplasm distinct from choriocarcinoma and placental site trophoblastic tumor simulating carcinoma

Shi IM, Kurman RJ. Am J Surg Pathol 1998; 22:1393-1403

- Epithelioid trophoblastic tumor is a rare malignancy derived from chorionic laeve-type intermediate trophoblast
- Uterine, unifocal disease
- Uterine corpus (42%), lower uterine segment/cervix (58%)
- Expansile growth pattern
- Epithelioid tumor cells with abundant eosinophilic cytoplasm growing in nests and sheets
- Fibrinoid and/or hyalinized material in a geographic pattern
- Reproductive-aged women
- Usually after normal pregnancy

Epithelioid trophoblastic tumor

a neoplasm distinct from choriocarcinoma and placental site trophoblastic tumor simulating carcinoma

Shi IM, Kurman RJ. Am J Surg Pathol 1998; 22:1393-1403

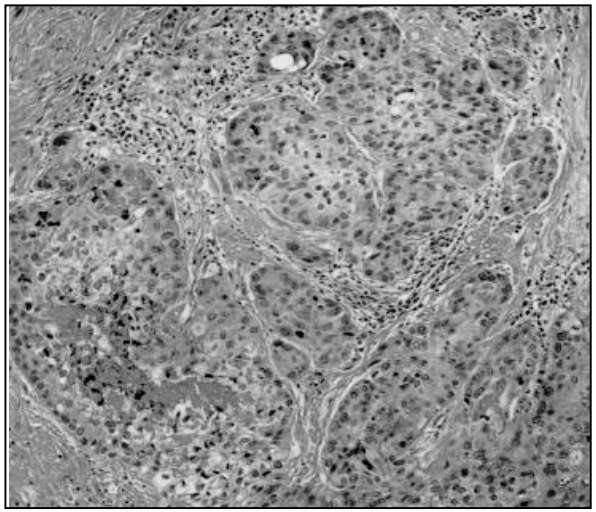

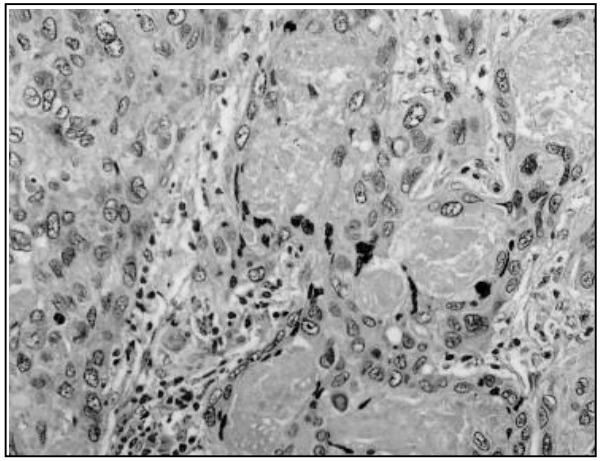

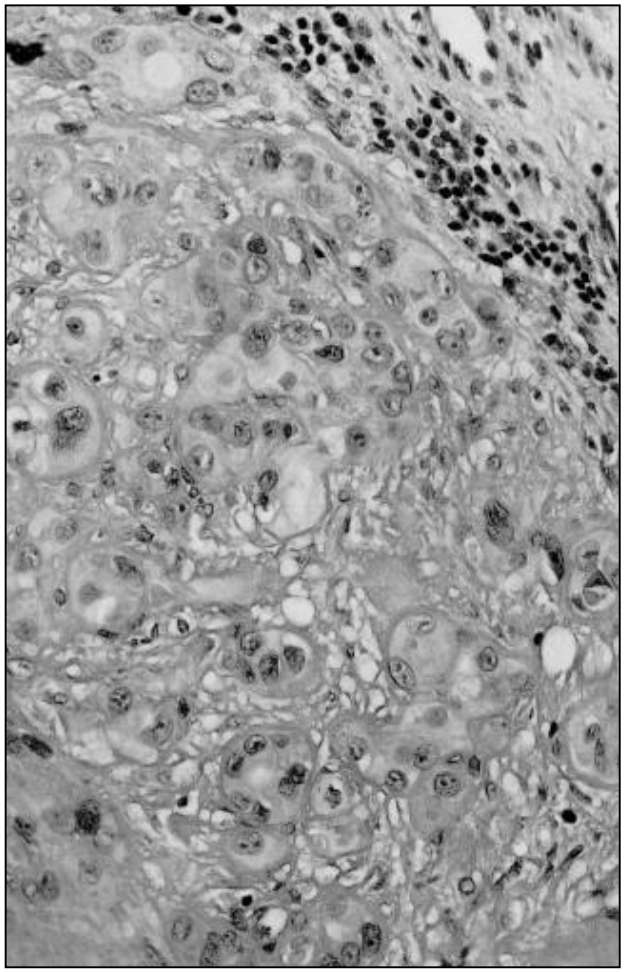

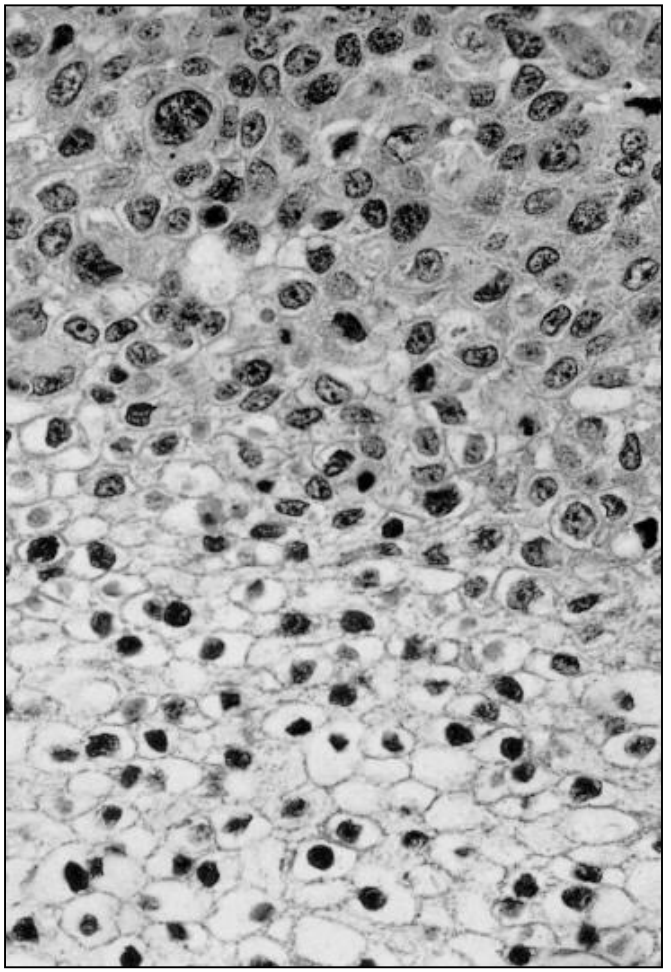

Epithelioid trophoblastic tumor

Hui P, Arch Pathol Lab Med 2019; 143:65-74

Epithelioid tumor cells with eosinophilic cytoplasm, admixed with hyalinized material, simulating squamous cell carcinoma

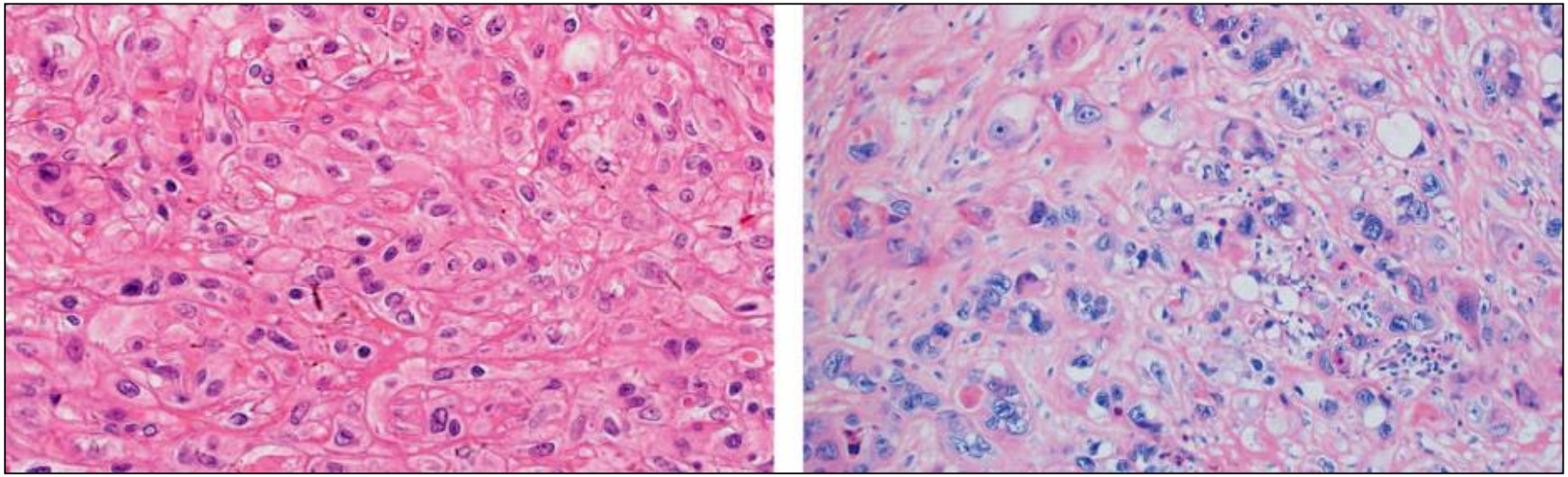

International Journal of Gynecological Pathology
00:1–11, Lippincott Williams & Wilkins, Baltimore
Copyright © 2018 by the International Society of Gynecological Pathologists

Original Article

Epithelioid Trophoblastic Tumor: Expanding the Clinicopathologic Spectrum of a Rare Malignancy

University of Chicago

Stephanie M. McGregor, M.D., Ph.D., Larissa V. Furtado, M.D., Anthony G. Montag, M.D., Rebecca Brooks, M.D., and Ricardo R. Lastra, M.D.

Summary: Epithelioid trophoblastic tumor is a malignancy derived from the chorionic laeve-type intermediate trophoblast with sufficient rarity that the vast majority of literature on the topic exists in the form of case reports and small series. Classically, it is regarded as a well-circumscribed tumor with an expansile growth pattern that occurs in

Epithelioid trophoblastic tumor

expanding the clinicopathologic spectrum of a rare malignancy

McGregor et al. In J Gyn Pathol 2018; 00:1-11

- Presented case: deviates from the classic description: a 68-year-old postmenopausal female with an aggressive tumor 30 year after her most most recent pregnancy
- Review of English literature: 77 patients with a broader spectrum of disease and highlights frequent misdiagnosis
- ETT can rarely be seen long following menopause (12%)
- Confined to uterus (52%), uterine with extrauterine spread (23%), extrauterine only (25%, lung, adnexa, cesarean scar, bowel, kidney, vagina, peritoneum)
- After full term delivery (52%), molar pregnancy (11%), spontaneous abortion (19%)

Epithelioid trophoblastic tumor – clinical features

- Most common presenting symptom: vaginal bleeding
- Age at diagnosis: 15-48 years (avg. 36 yrs)
- Rare cases (~12%) in postmenopausal women
- Two-thirds occur following previous term pregnancy
- Rarely following molar gestation or spontaneous abortion
- Latency period: 1–15 years (avg. 6 yrs), but can be longer – case presented: 30 years after last delivery

Genotyping of Epithelioid Trophoblastic Tumor

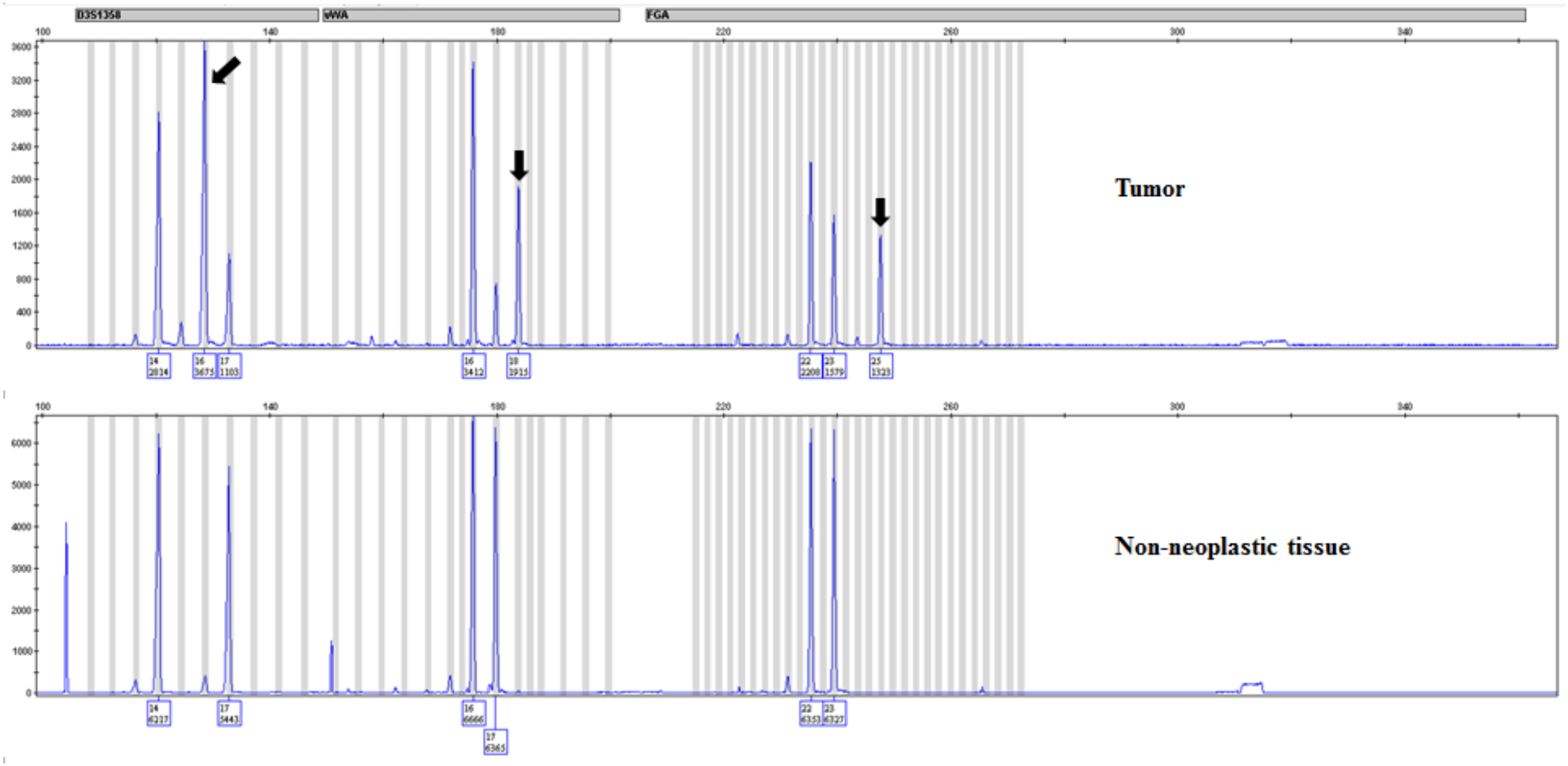

Microsatellite genotyping of microdissected tumor tissue

- Three different alleles identified at each locus, the third corresponding to paternal DNA from previous pregnancy in which the trophoblast originated
- The extra alleles are not present in microdissected non-neoplastic tissue of the patient

Case 2
final diagnosis

Epithelioid trophoblastic tumor

….but, how did this happen?

How is this possible? – from preexisting placental-site nodule?

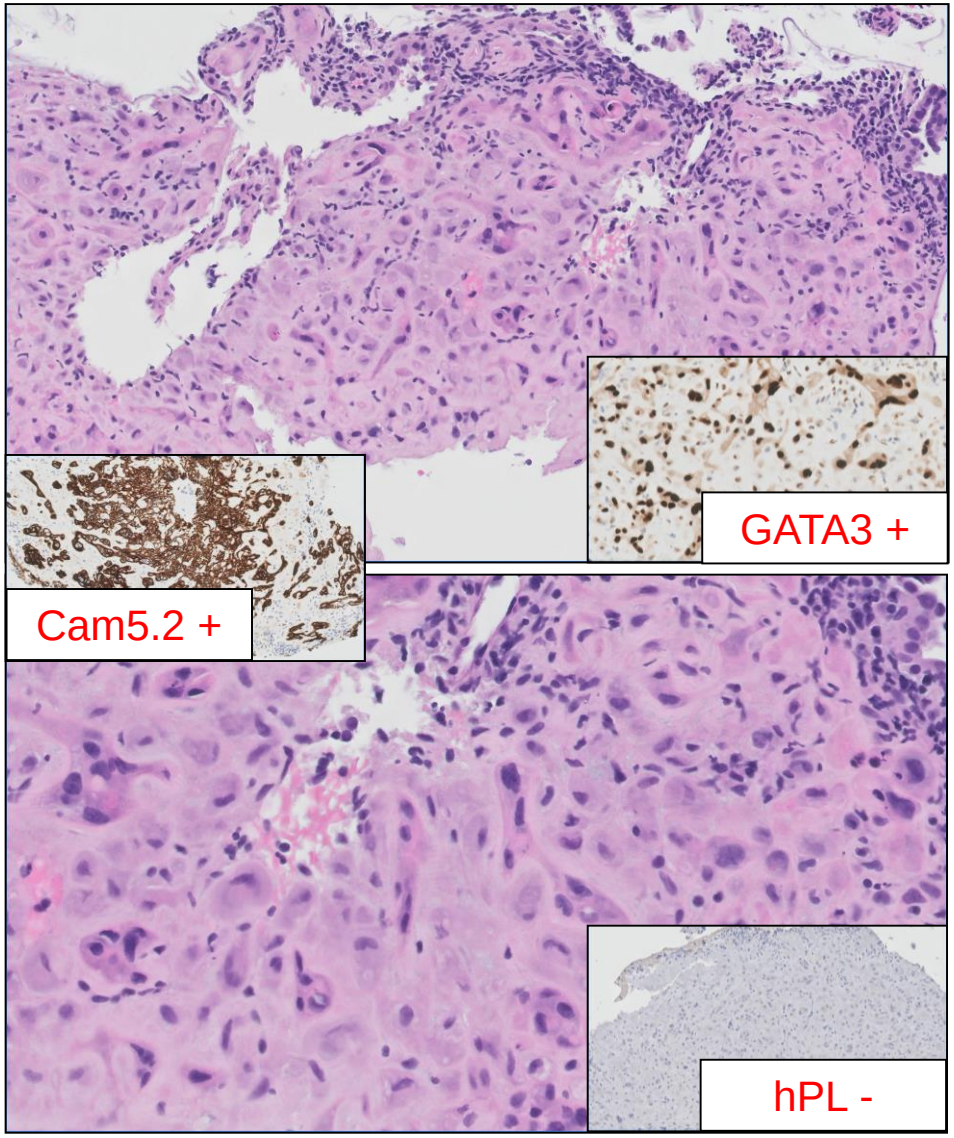

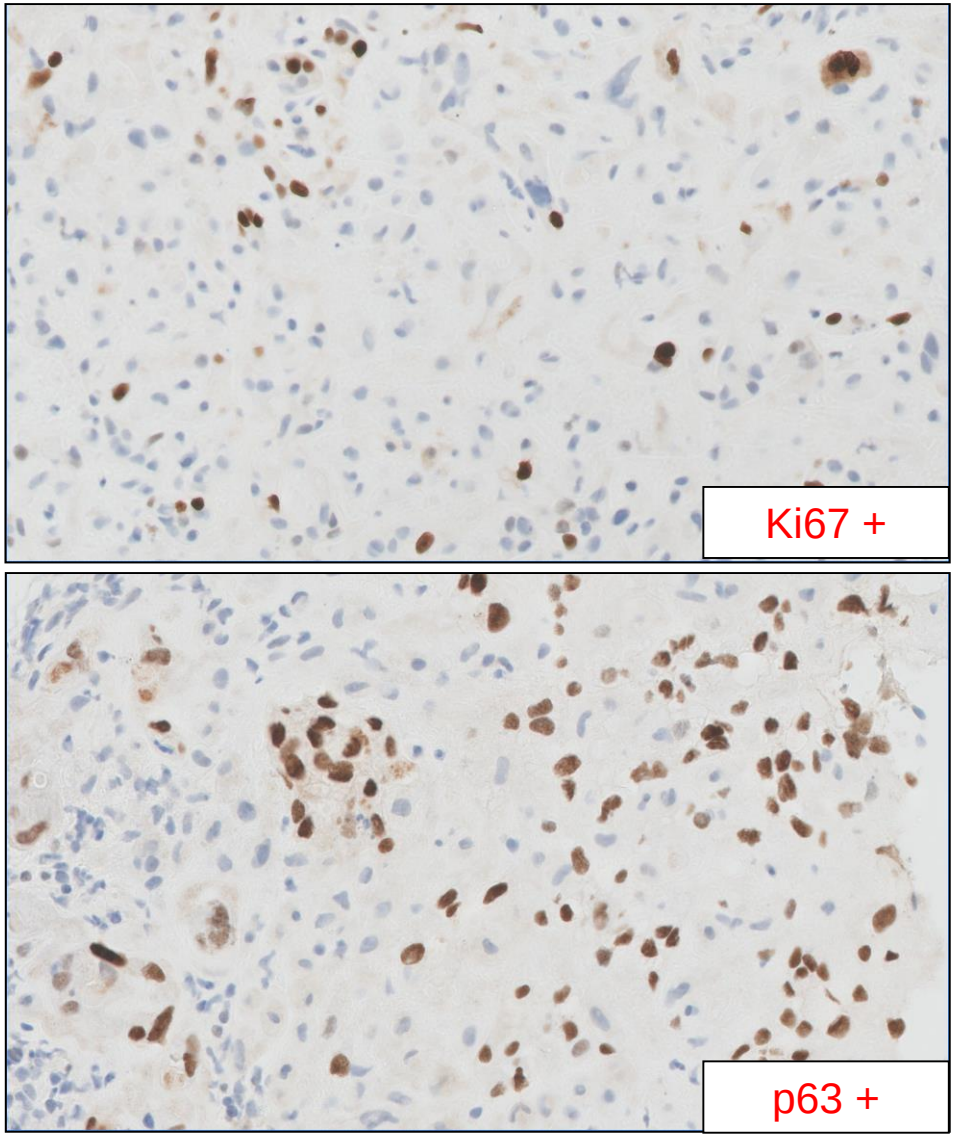

A Rare Case of Atypical Placental Site Nodule With an Emerging Intermediate Trophoblastic Tumor

Int J Gynecol Pathol 2019; 00:1-9

Jhalak Dholakia, M.D., Wei Chen, M.D., Ph.D., David M. O'Malley, M.D., and Brigitte M. Ronnett, M.D.

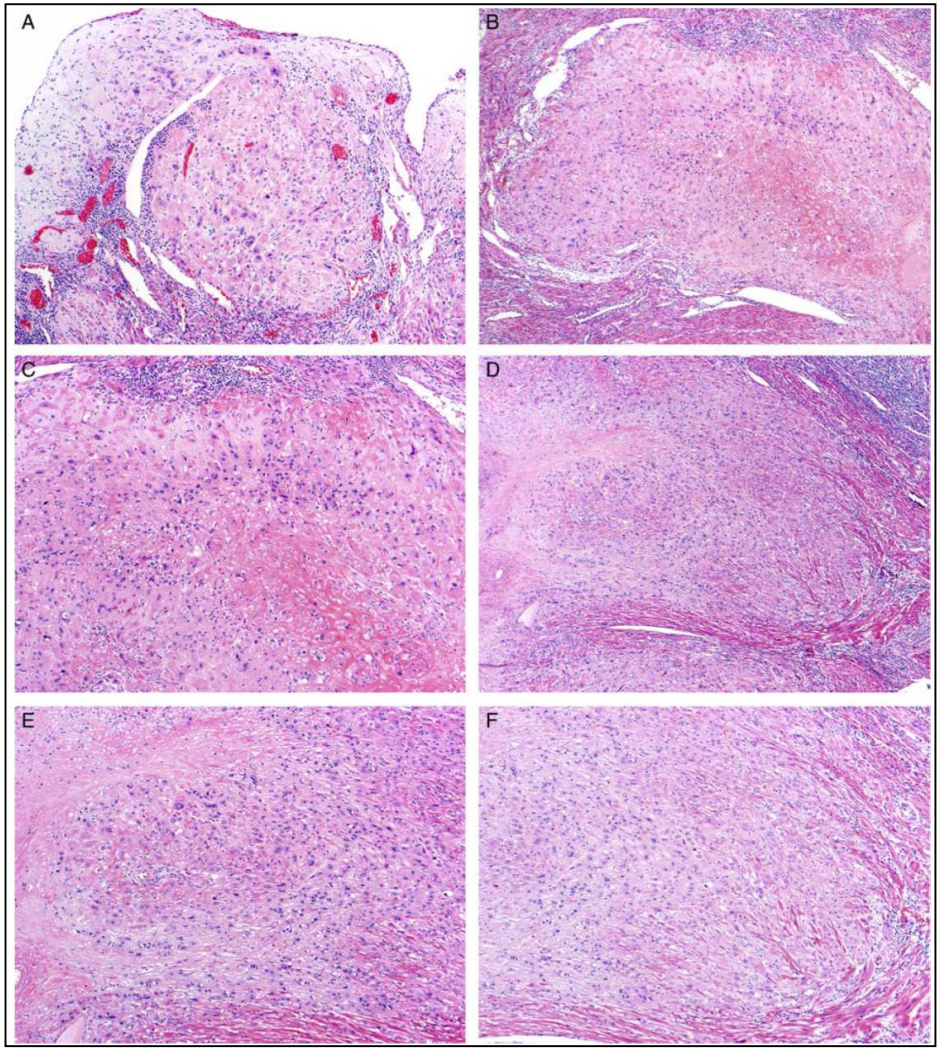

Atypical placental site nodule as a precursor of lesion to epithelioid trophoblastic tumor

Hui P. Arch Pathol Lab Med 2019; 143:65-74

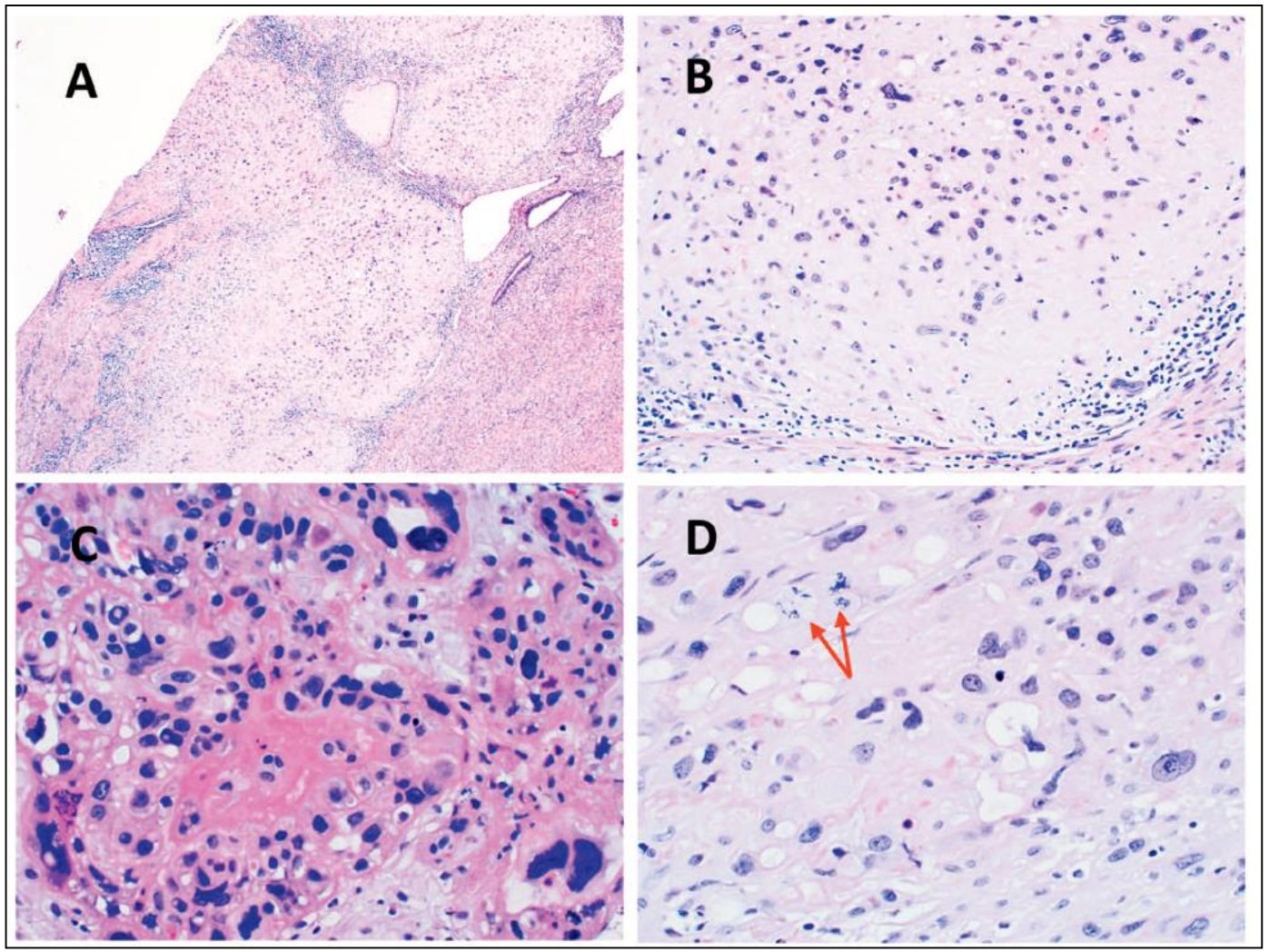

Epithelioid trophoblastic tumor – prognosis

- Overall survival: 90-100%
- Metastasis: 25%
- Overall survival if metastases present: 50-60%

Case 2
clinical follow-up

- Nine months following hysterectomy, presented with small bowel obstruction
- Exploratory laparotomy, small bowel resection; intraoperative peritoneal, omental, and pelvic biopsies showed no evidence of residual epithelioid trophoblastic tumor
- Patient is well at three years follow-up

Case 2
key points

- A high-grade uterine neoplasms with broad differential diagnosis in 68-year-old patient is presented
- Immunohistochemical and molecular study confirmed the diagnosis of epithelioid trophoblastic tumor
- Epithelioid trophoblastic tumor usually occurs in reproductive age group, but rare examples may arise in postmenopausal women
- Epithelioid trophoblastic tumor differentiates along the lines of chorionic laeve-type intermediate trophoblasts
- HLA-G, hPL and p63 are very helpful distinguishing epithelioid trophoblastic tumor from mimics

Case 2
Epithelioid trophoblastic tumor – a diagnostic pitfall

- Frequent (25%) misdiagnosis
- Most commonly mistaken for squamous cell carcinoma, clear cell carcinoma, moderate to poorly differentiated carcinoma NOS, choriocarcinoma, placental site trophoblastic tumor, PEComa, epithelioid leiomyosarcoma
- Immunoreactivity for epithelial markers: keratin, EMA, p63, GATA3 in addition to HLA-G, Inhibin, PLAP
- Diagnostic pitfall is even greater in cases which may occur primarily at extrauterine sites (lung, adnexa, bowel, kidney, vagina, peritoneum)

Implantation site intermediate trophoblasts

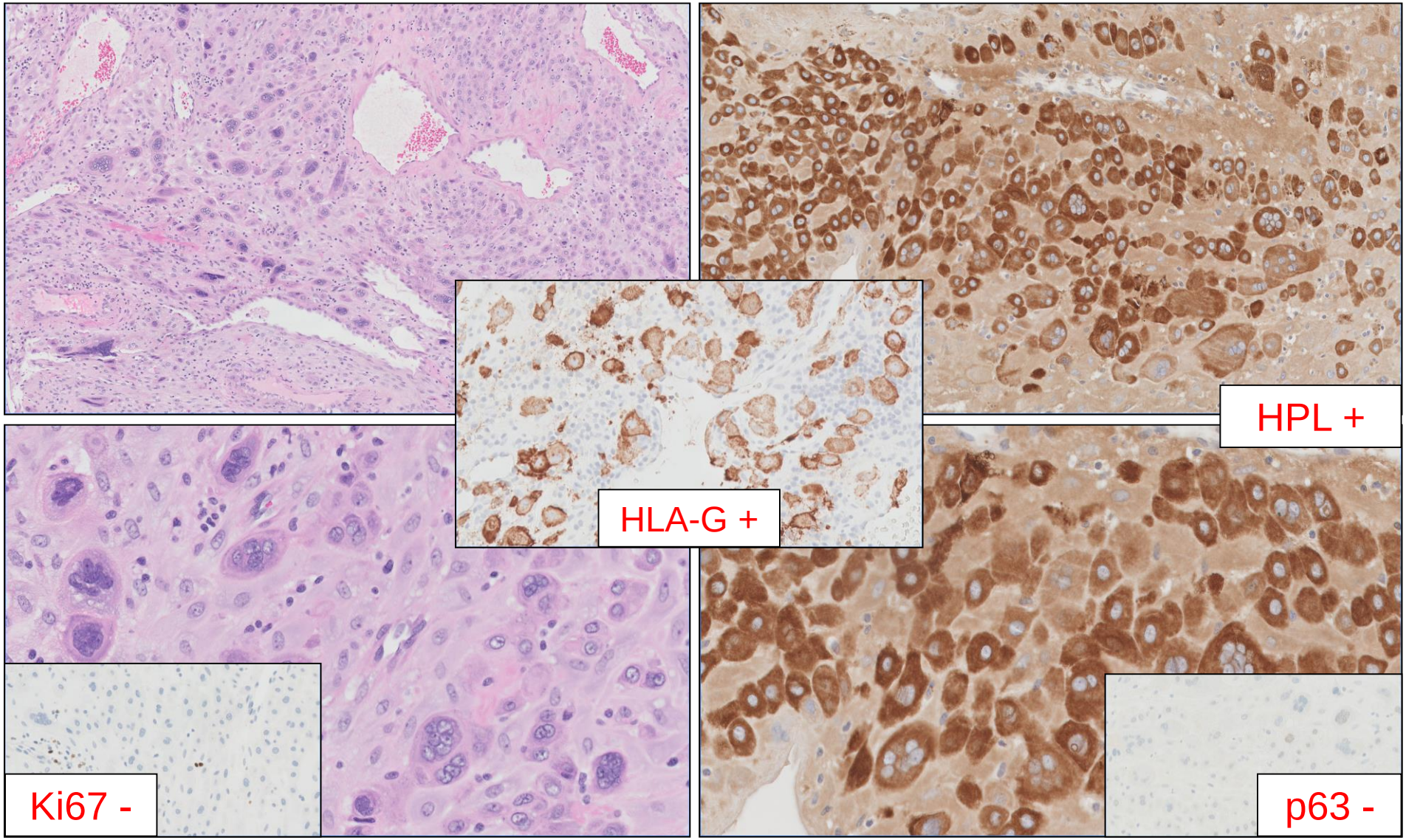

Placental site trophoblastic tumor

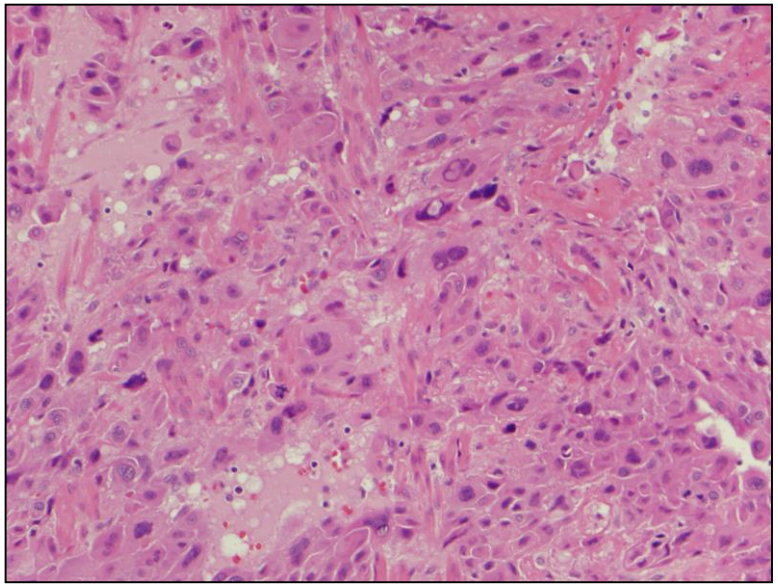

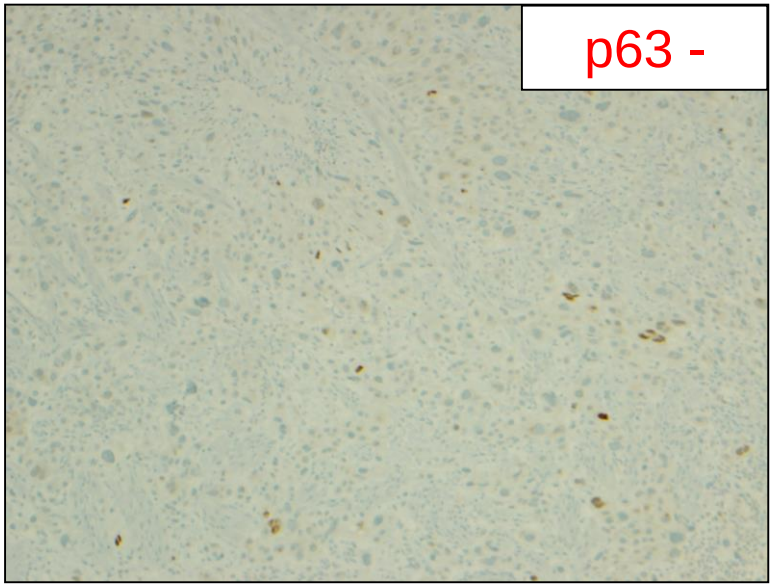

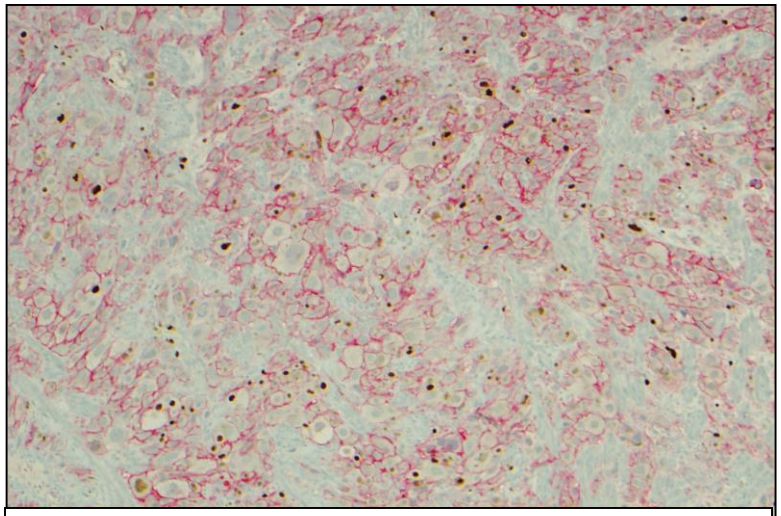

hLA-G/Ki67 dual stain: > 15%

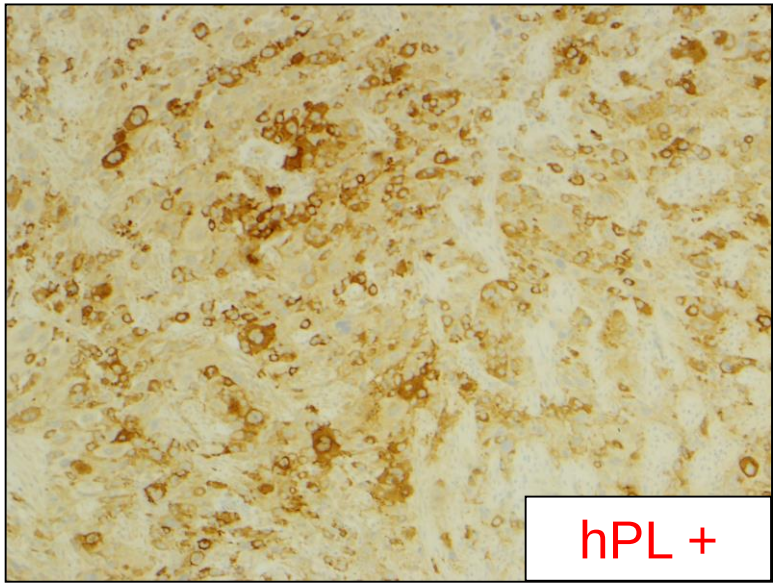

Case 2

References

- Shih IM, Kurman RJ. p63 expression is useful in the distinction of epithelioid trophoblastic and placental site trophoblastic tumors by profiling trophoblastic subpopulations. Am J Surg Pathol. 2004 Sep;28(9):1177-83.
- Singer G, Kurman RJ, McMaster MT, Shih IeM. HLA-G immunoreactivity is specific for intermediate trophoblast in gestational trophoblastic disease and can serve as a useful marker in differential diagnosis. Am J Surg Pathol. 2002 Jul;26(7):914-20.
- Shih IeM, Kurman RJ. Molecular basis of gestational trophoblastic diseases. Curr Mol Med. 2002 Feb;2(1):1-12.
- Almarzooqi S, Ahmad Al-Safi R, Fahad Al-Jassar W, Akhter SM, Chiab-Rassou Y, Albawardi A. Epithelioid trophoblastic tumor: report of two cases in postmenopausal women with literature review and emphasis on cytological findings. Acta Cytol. 2014;58(2):198-210.
- Banet N, Gown AM, Shih IM, et al. GATA3 expression in trophoblastic tissues: An immunohistochemical study of 445 cases, including diagnostic utility. Am J Surg Pathol. 2015 January; 39(1): 101–108.
- Kaur B, Short D, Fisher RA, Savage PM, Seckl MJ, Sebire NJ. Atypical placental site nodule (APSN) and association with malignant gestational trophoblastic disease; a clinicopathological study of 21 cases. Int J Gynecol Pathol. 2015 Mar;34(2):152-8.
- McGregor SM, Furtado LV, Montag AG, Brooks R, Lastra RR. Epithelioid trophoblastic tumor: expanding the clinicopathologic spectrum of a rare malignancy. Int J Gyn Pathol 2018; 00:1-11

Case 3
clinical history

- 80-year-old woman with peritoneal tumor deposits
- Previous peritoneal core needle biopsy diagnosed as metastatic "adenoid cystic-like carcinoma"

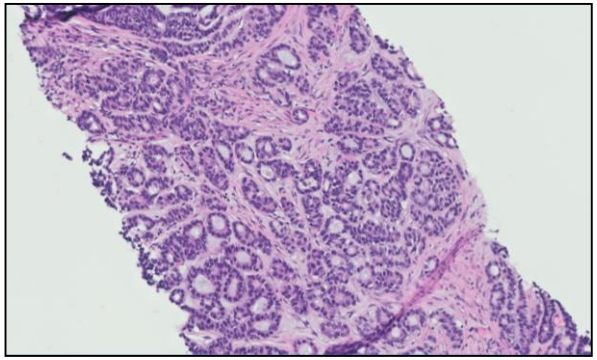

- Right ovarian partly cystic, partly solid mass, 10.5 cm
- Patient underwent neoadjuvant chemotherapy and subsequently total abdominal hysterectomy with bilateral salpingo-oophorectomy, omentectomy and tumor debulking
- Submitted slide for the seminar is from the metastatic tumor deposits on the peritoneum

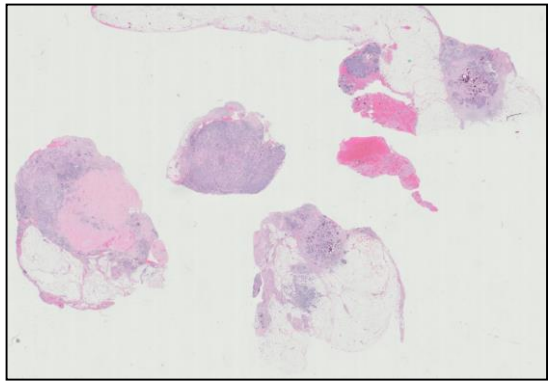

Case 3

metastatic tumor deposits with two different components

one is clearly serous carcinoma (low grade) – the other is "adenocarcinoma" with microglandular pattern - difficult to type

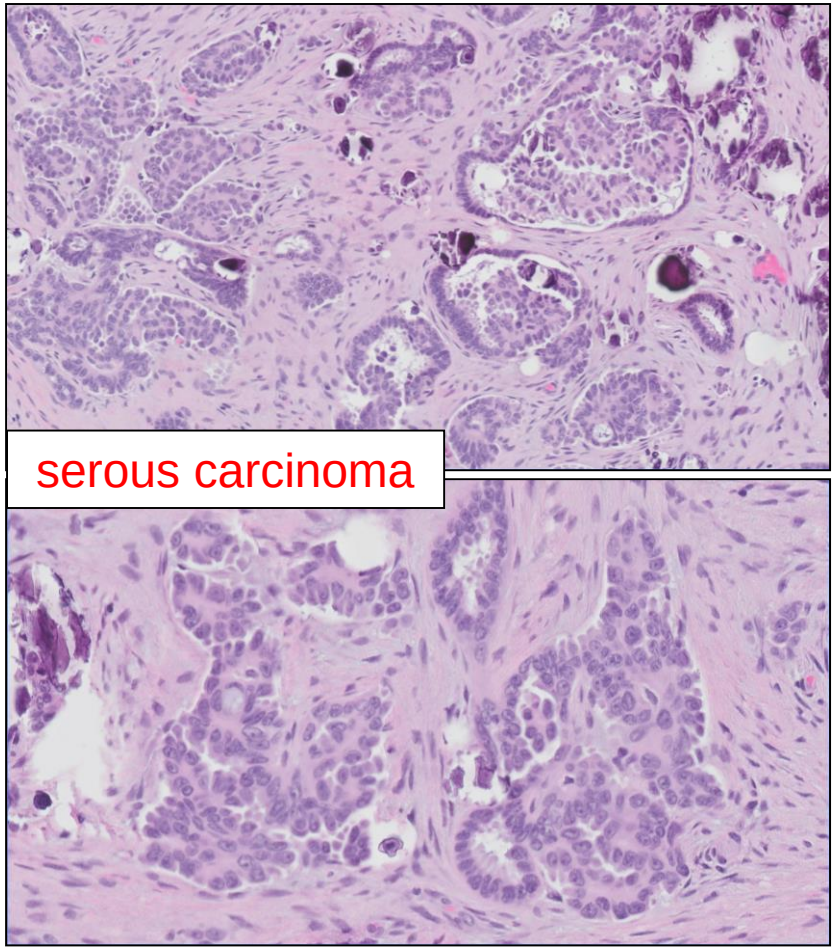

serous carcinoma

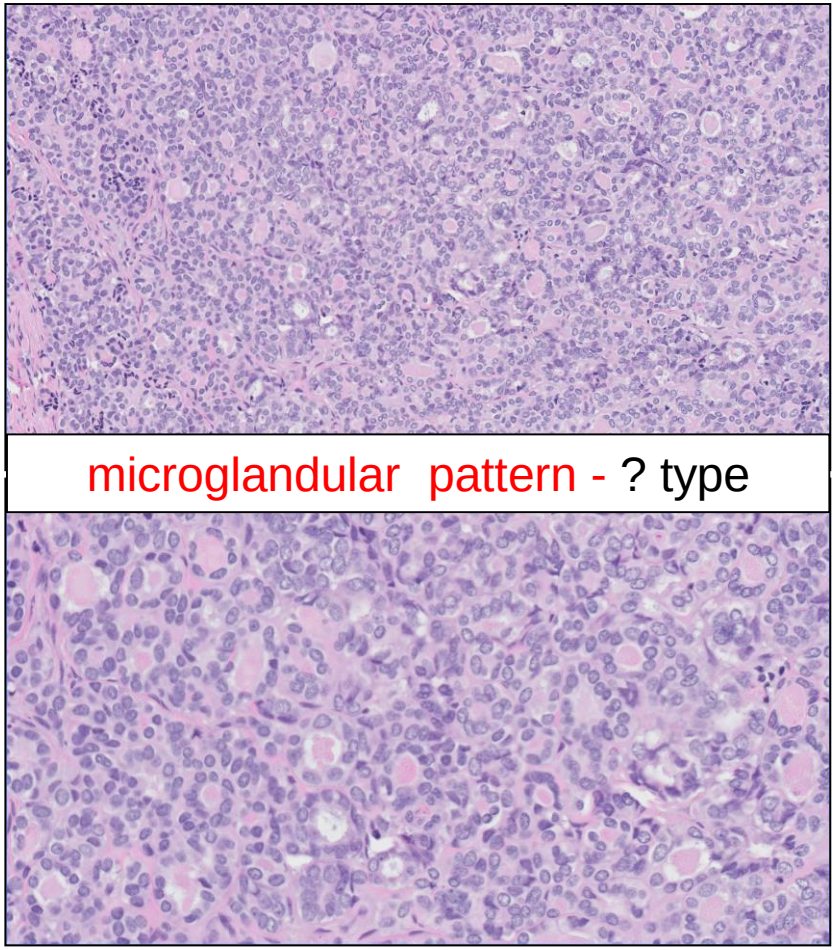

microglandular pattern - ? type

Microglandular component – difficult to type

mimics thyroid cancer

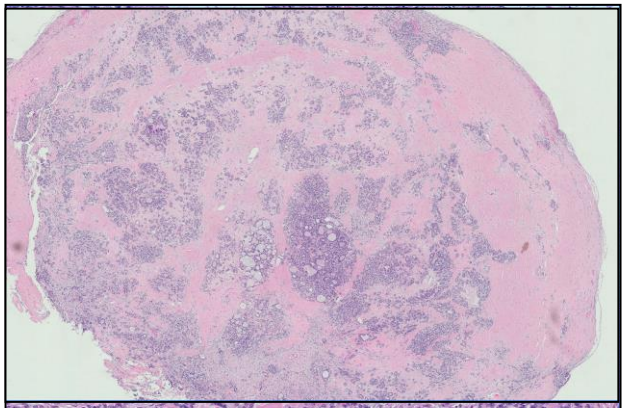

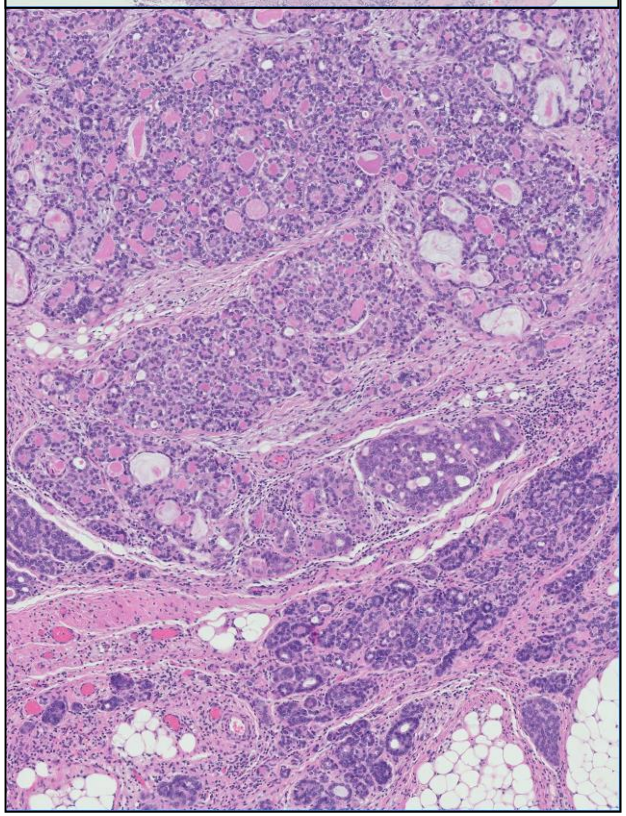

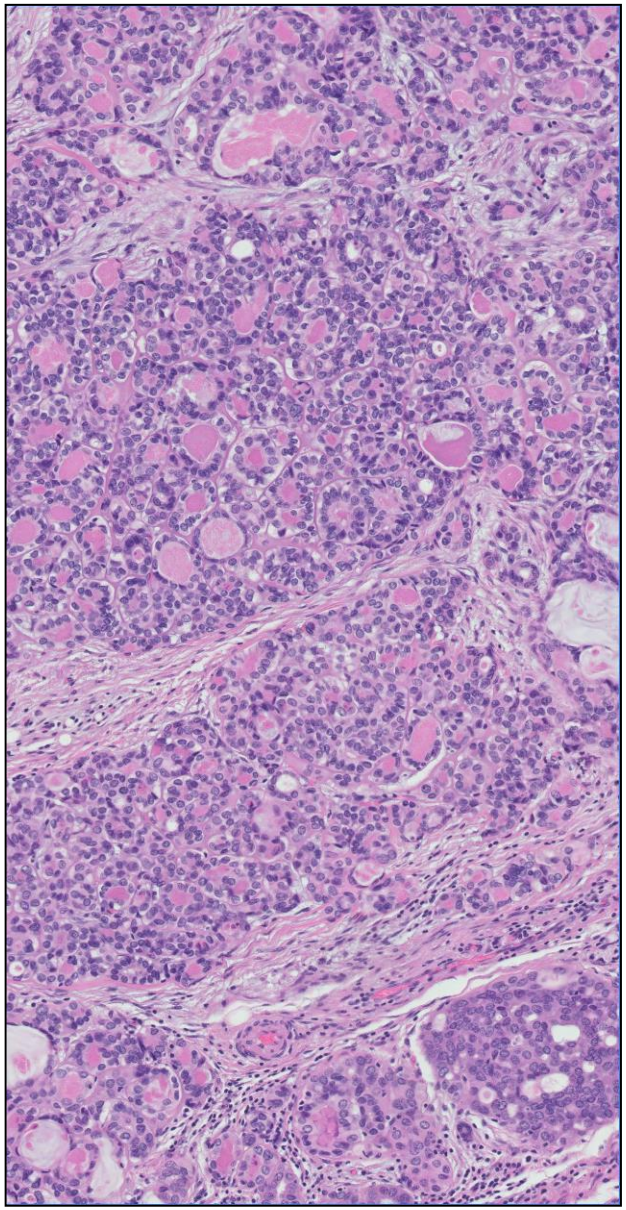

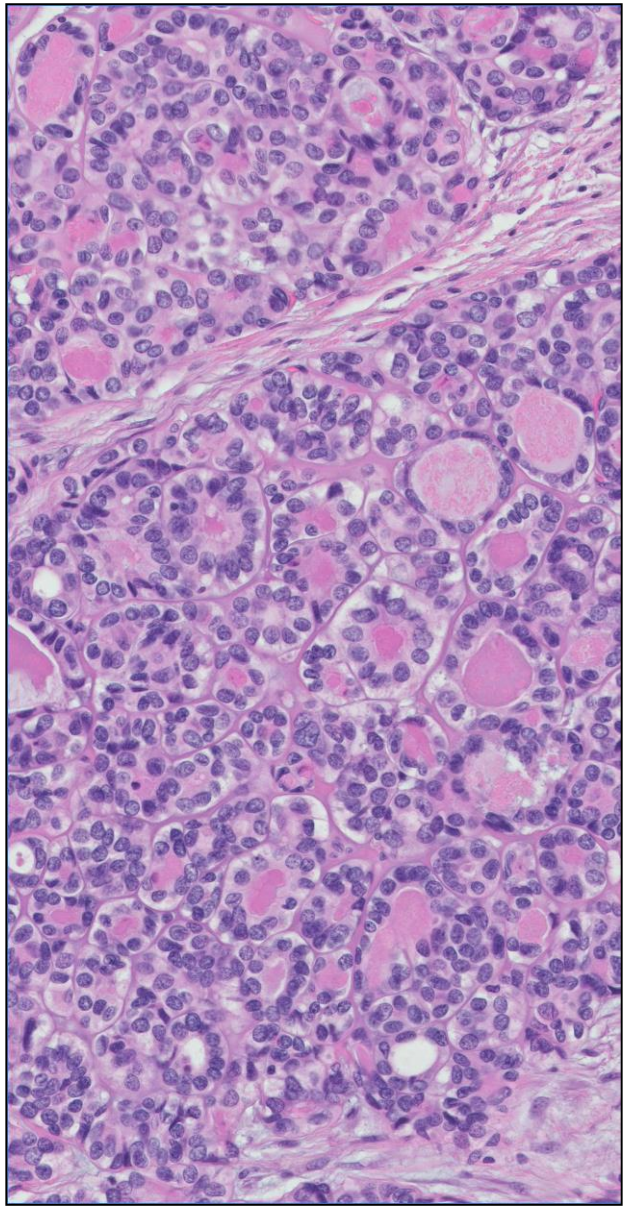

Case 3

Right ovarian mass: both cystic and solid components

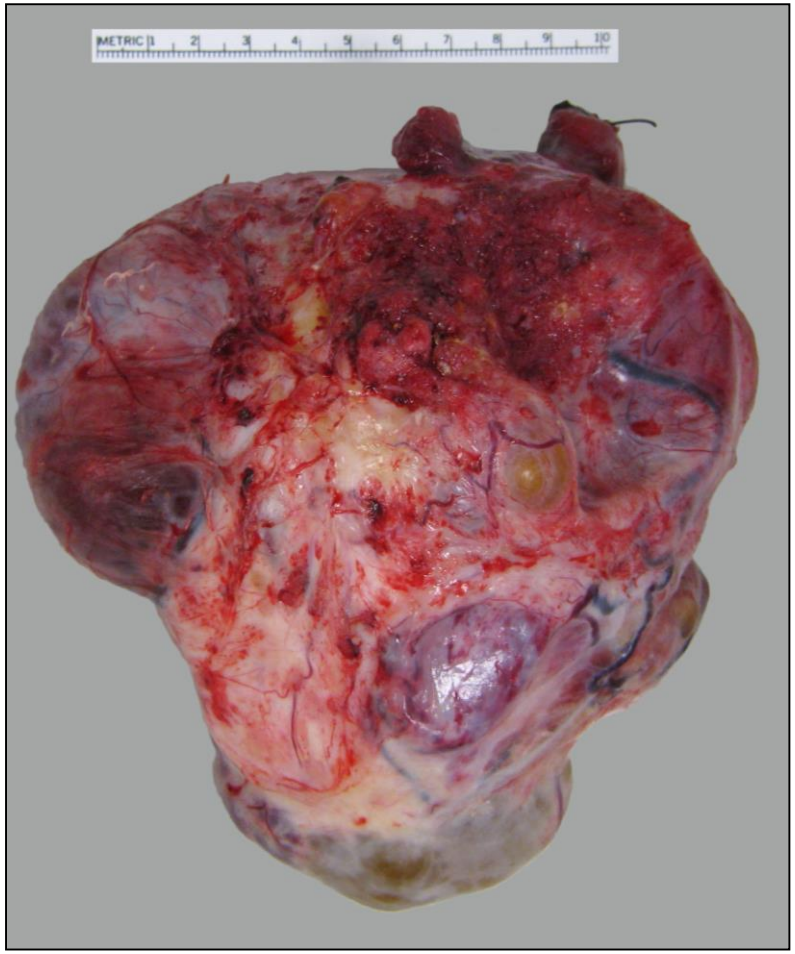



Two histologically completely different components

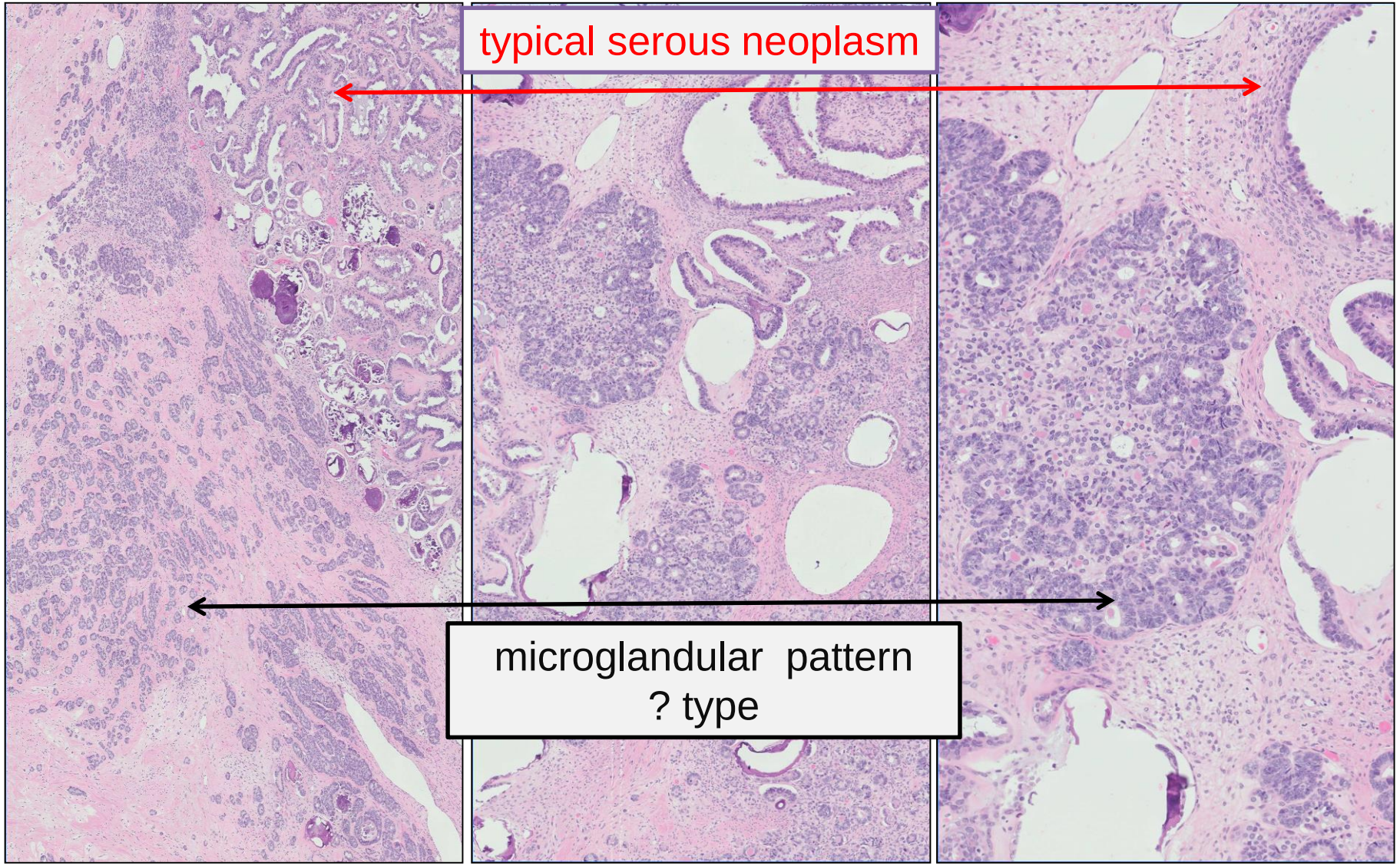

One of the components is a
low-grade serous carcinoma *evolving from* serous borderline tumor

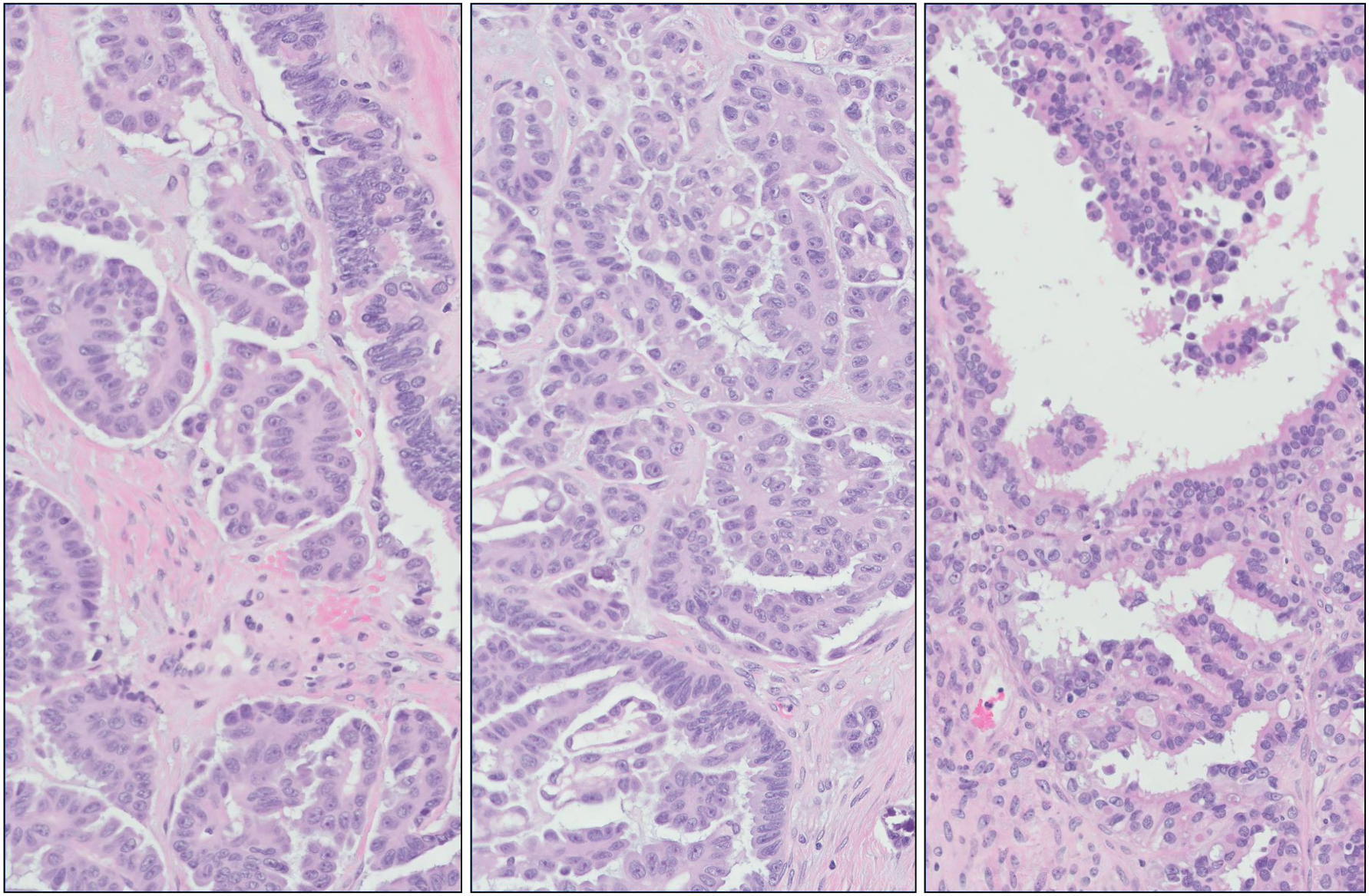

Other component is an adenocarcinoma with microglandular pattern

primary *versus* metastatic – difficult to determine

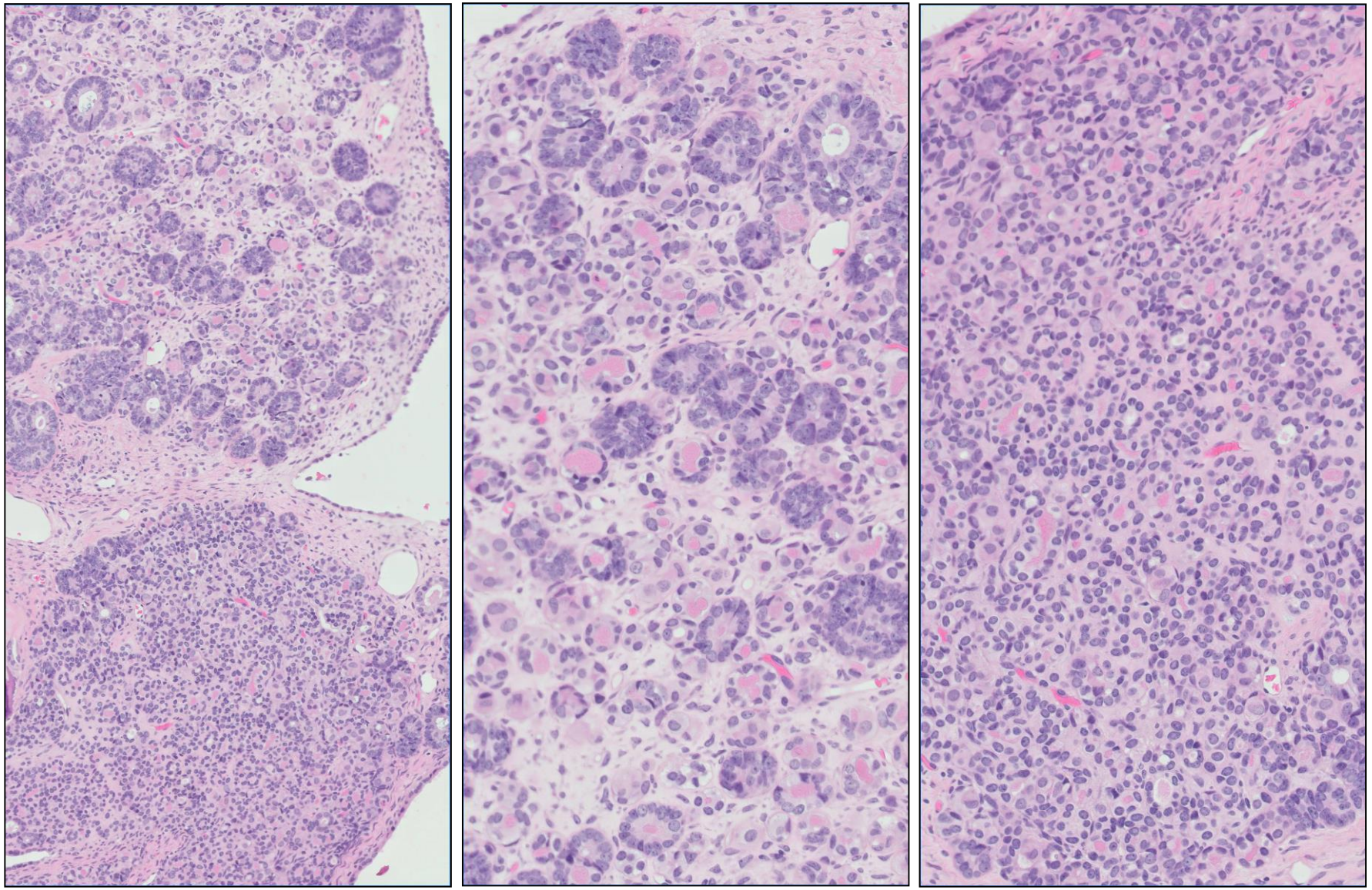

Focal mingling of the two different components

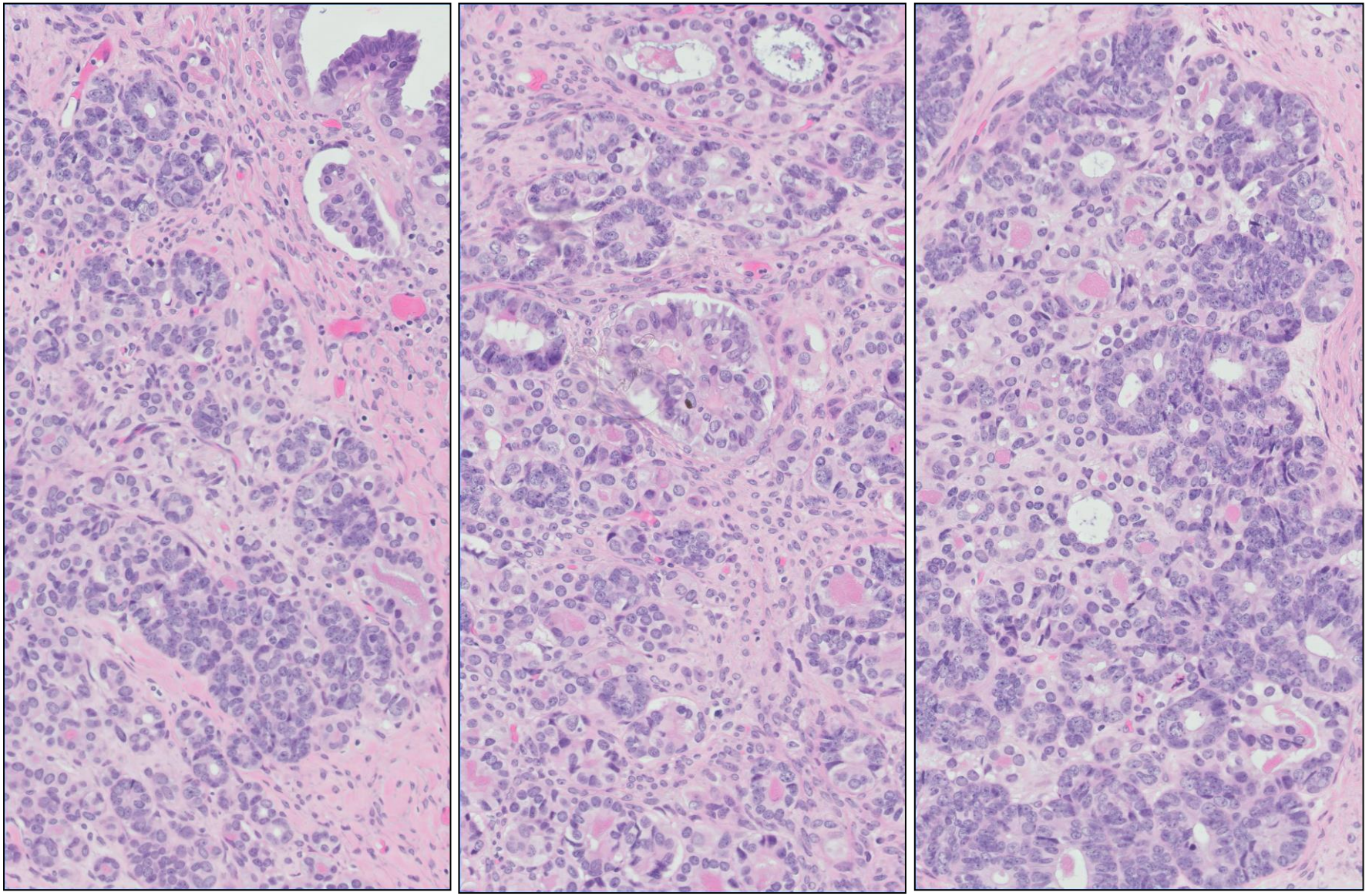

Microglandular pattern – some with colloid-like secretion

unusual histologic features for a primary ovarian neoplasm

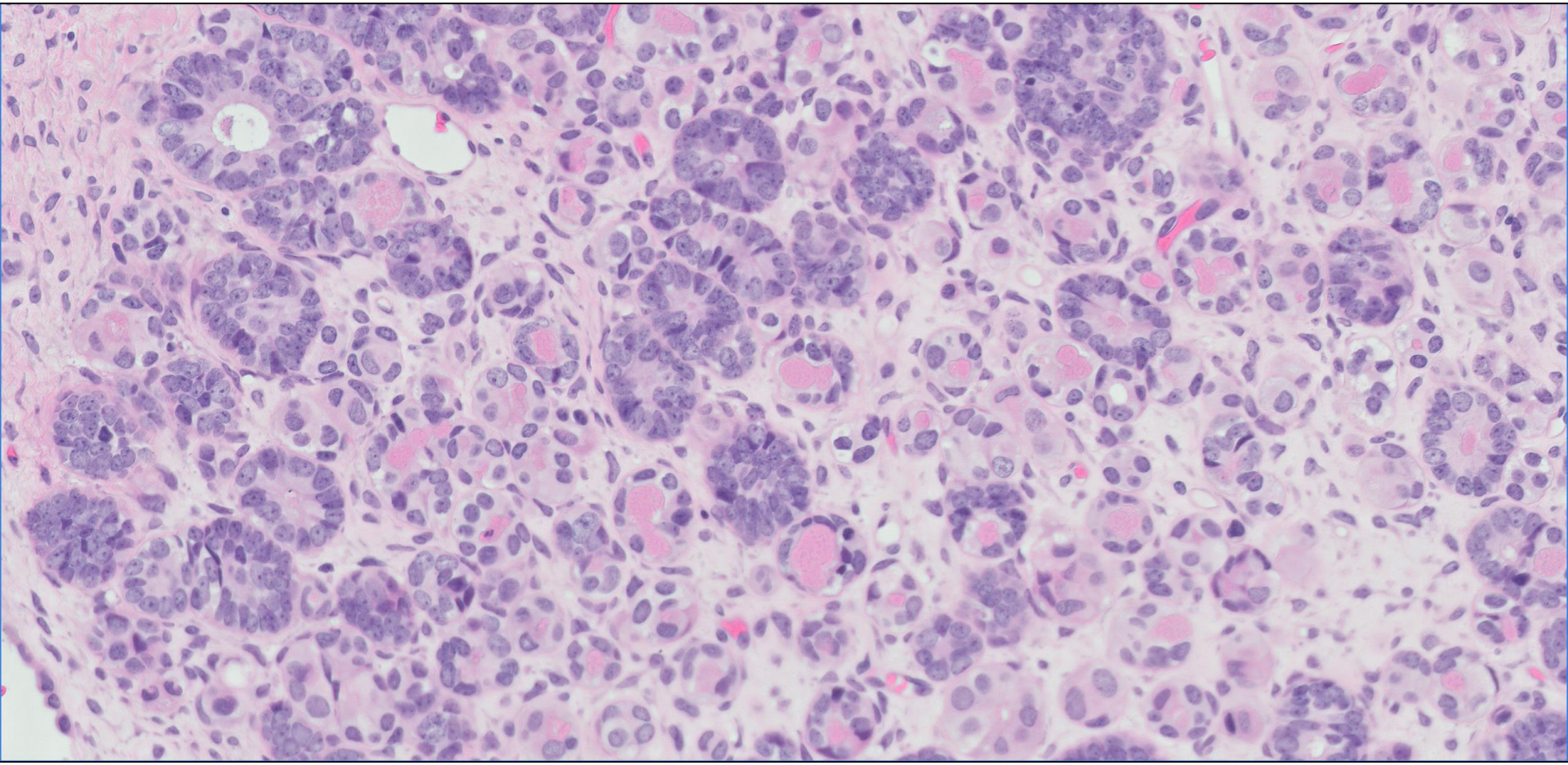

Microglandular component

histologically unusual neoplasm for primary ovarian site

broad differential diagnosis

- Thyroid carcinoma primary (from struma ovarii) or metastatic
- Metastatic adenoid cystic carcinoma
- Microglandular endometrioid carcinoma
- Low-grade serous carcinoma with rare microglandular/ microcystic pattern evolving from borderline serous tumor
- FATWO (female adnexal tumor of probable Wolffian origin)
- Metastatic mesonephric adenocarcinoma from the cervix, but the cervix is tumor free
- Primary mesonephric carcinoma of the ovary, but is there such a neoplasm?

One of the differentials:
microcystic variant of low-grade serous carcinoma

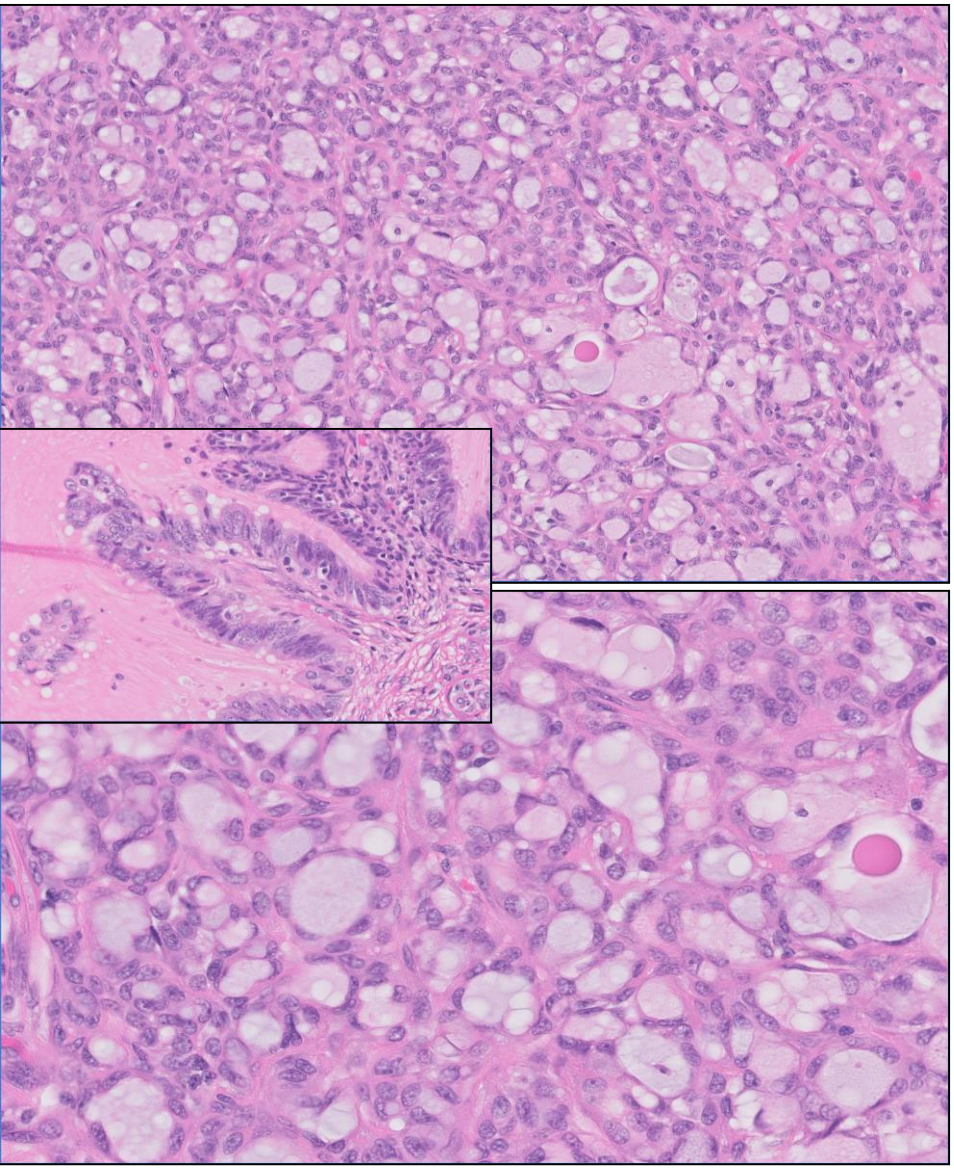

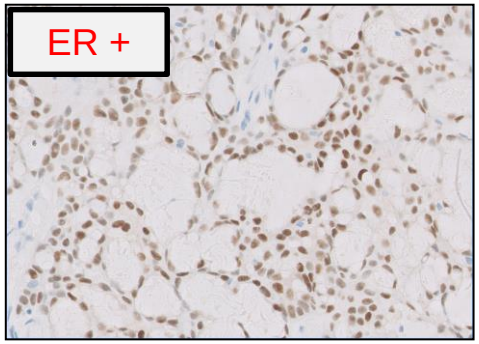

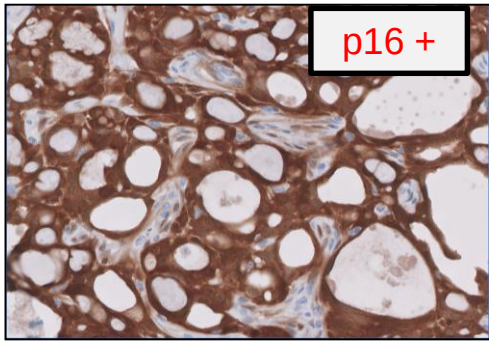

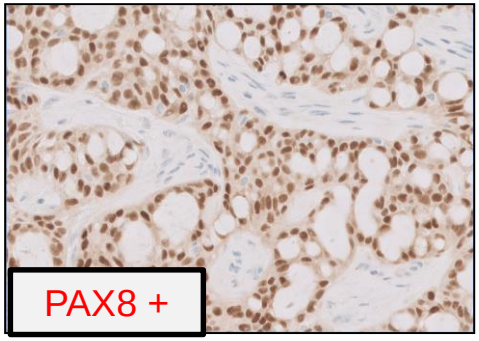

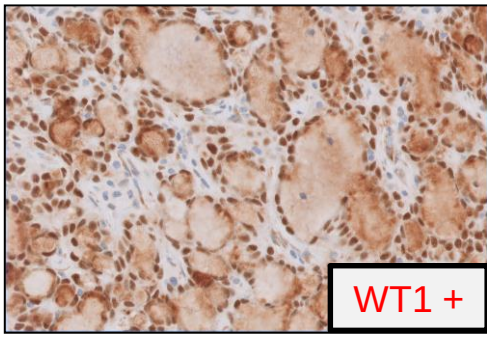

however, the immunoprofile does not fit

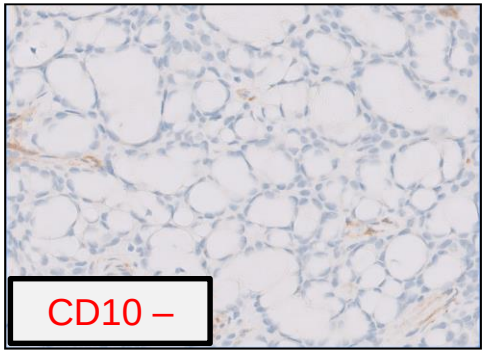

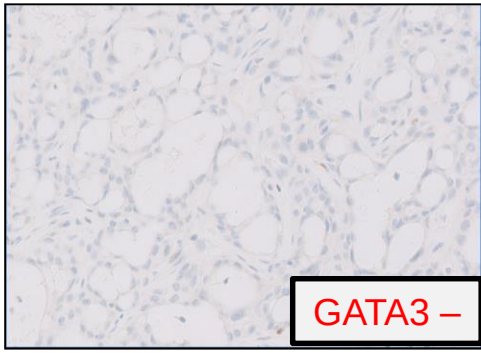

Microglandular component
broad differential diagnosis

- Thyroid carcinoma primary (from struma ovarii) or metastatic
- Metastatic adenoid cystic carcinoma
- Microglandular endometrioid carcinoma
- Low-grade serous carcinoma with rare microglandular/ microcystic pattern evolving from borderline serous tumor
- FATWO (female adnexal tumor of probable Wolffian origin)
- Metastatic mesonephric adenocarcinoma from the cervix, but the cervix is tumor free
- Primary mesonephric adenocarcinoma of the ovary, but is there such a neoplasm? – No, but…..
- What about mesonephric-like adenocarcinoma of the ovary?

For comparison

mesonephric adenocarcinoma of cervix – evolving from mesonephric remnants

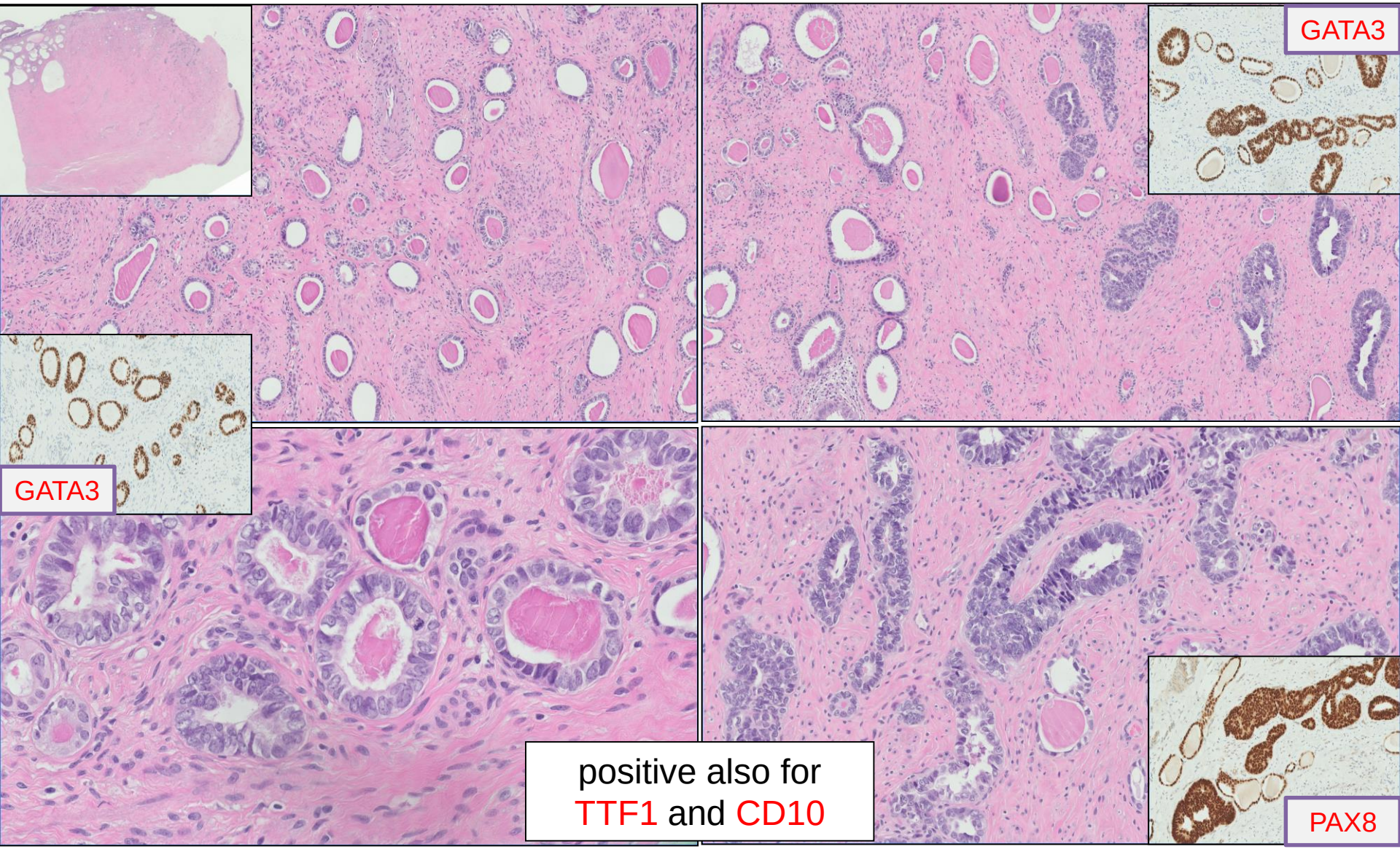

Case 3 – Histologically unusual neoplasm for ovarian site, but

immuno-profile is also similar to cervical mesonephric carcinoma

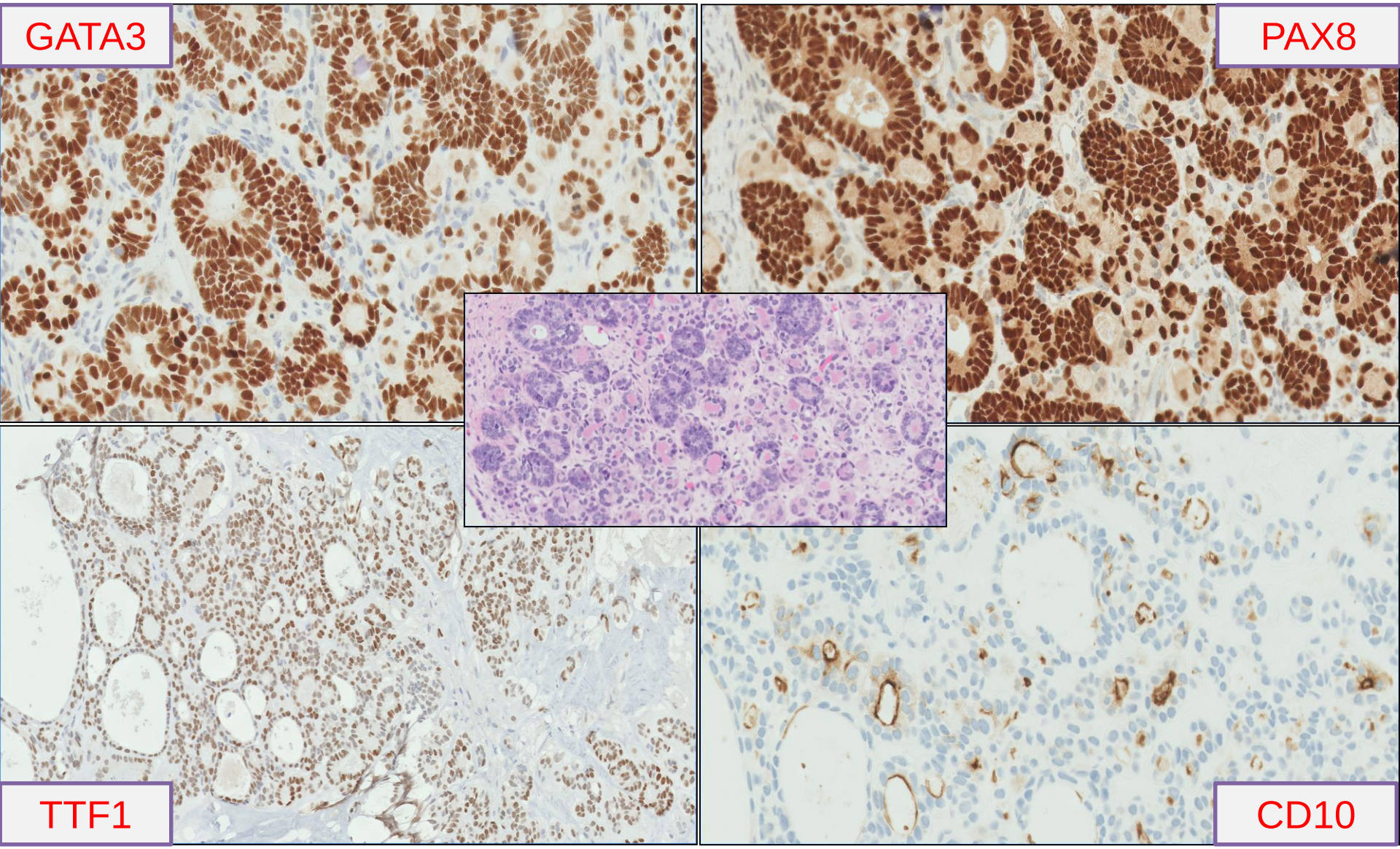

Case 3 – microglandular component
immunohistochemical study

Positive	Negative
Cytokeratin 7	Cytokeratin 20, 5/6
PAX8	Vimentin
GATA3	ER and PR
Inhibin (focal)	Thyroglobulin and parathormone
CD10 (focal, luminal)	Napsin A and HNF-1β
TTF1 (focal)	WT1
	p16
	p53

Differential expression of immuno-markers

between serous and microglandular components

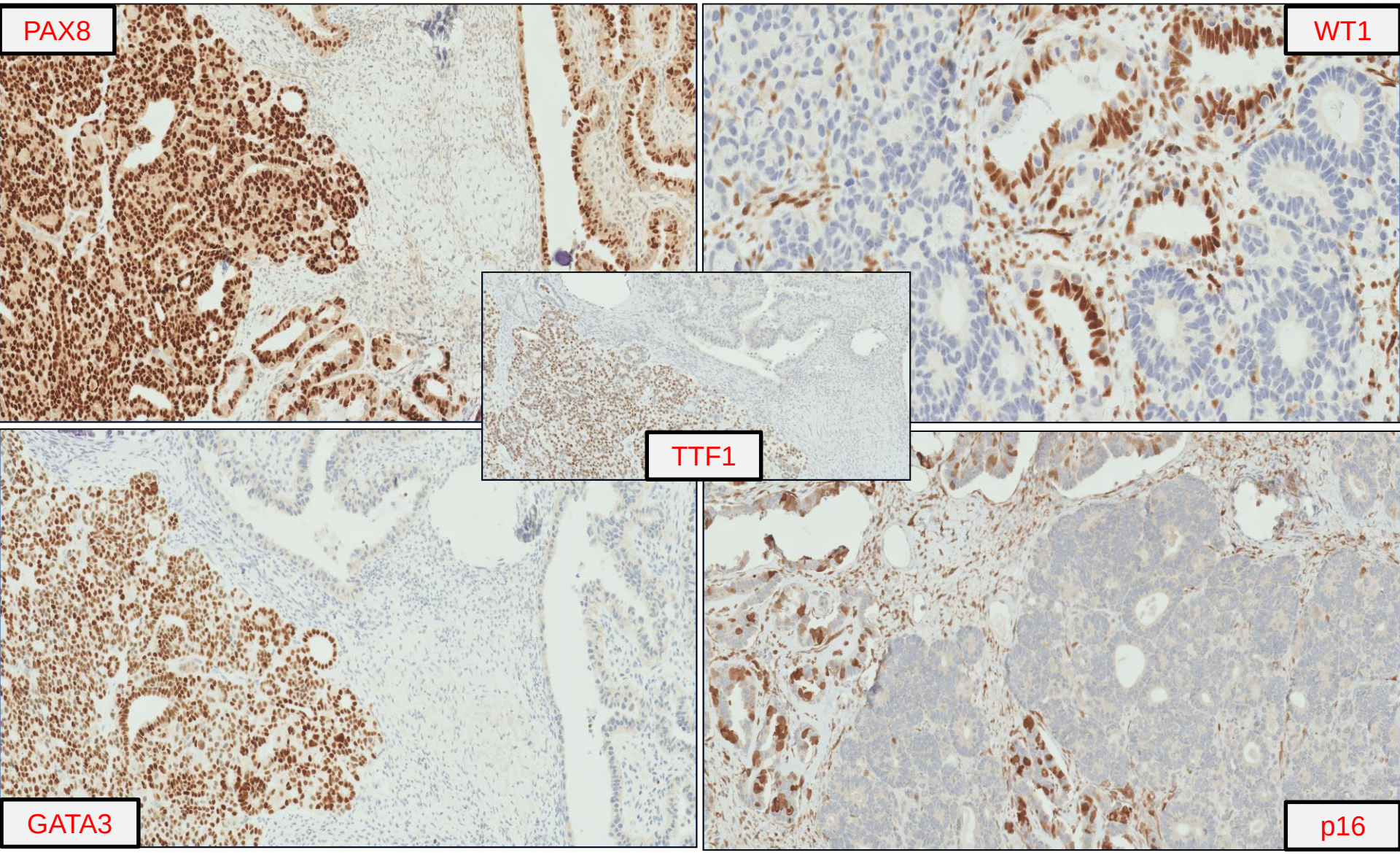

Microglandular component
diagnosis

Mesonephric-like adenocarcinoma of the ovary

…but

is there such a primary neoplasm in the ovary?

Hormone receptor negative, TTF1-positive uterine and ovarian mesonephric-like adenocarcinomas

McFarland M, et al, 2016

- A series of 7 uterine corpus and 5 ovarian neoplasms
- Authors believe that they probably represent mesonephric adenocarcinomas based on their characteristic morphology and immunophenotype, however…
- Mesonephric adenocarcinomas have only rarely been reported to arise in the uterine corpus and never in the ovary
- Authors recommend they be termed "mesonephric-like adenocarcinomas" until their histogenesis firmly established
- Characteristic immunophenotype:
  - Positive: GATA3, PAX8,TTF1,CD10
  - Negative: ER, PR, Vimentin, WT1, Napsin A, HNF-1β, p16, p53

Hormone receptor negative, TTF1-positive uterine and ovarian mesonephric-like adenocarcinomas

McFarland M, et al 2016

- Mean age: 60 years; age range: 42 – 72 years
- No benign mesonephric remnants were identified in association with the uterine tumors
- In all uterine cases the neoplasms predominantly involved the endometrium
- In three of the ovarian cases, there were foci of endometriosis in the same ovary
- Histogenesis: mesonephric-like adenocarcinomas could arise from mesonephric remnants in or around the ovary
- Alternatively mesonephric-like adenocarcinomas could arise from Mullerian structures and differentiate along mesonephric pathway

Hormone receptor negative, TTF1-positive uterine and ovarian mesonephric-like adenocarcinomas

McFarland M, et al 2016

- Follow-up available on 10 patients
  (5 ovarian and five uterine corpus primaries)
- 7 patients alive with no evidence of disease
  (although the periods of follow-up are limited, 1 - 18 months)
- One of the uterine cases was stage IIIC due to pelvic nodal metastasis; patient subsequently developed lung metastasis, but alive at 56 months follow-up
- Another uterine case was stage IV due to ovarian and omental metastasis, but alive at 25 months follow-up
- One of the ovarian cases was stage IIIC at presentation and the patient is still alive with progressive disease at 12 months follow-up

Case 3 – peritoneal nodules

metastatic mesonephric-like adenocarcinoma and low-grade serous carcinoma

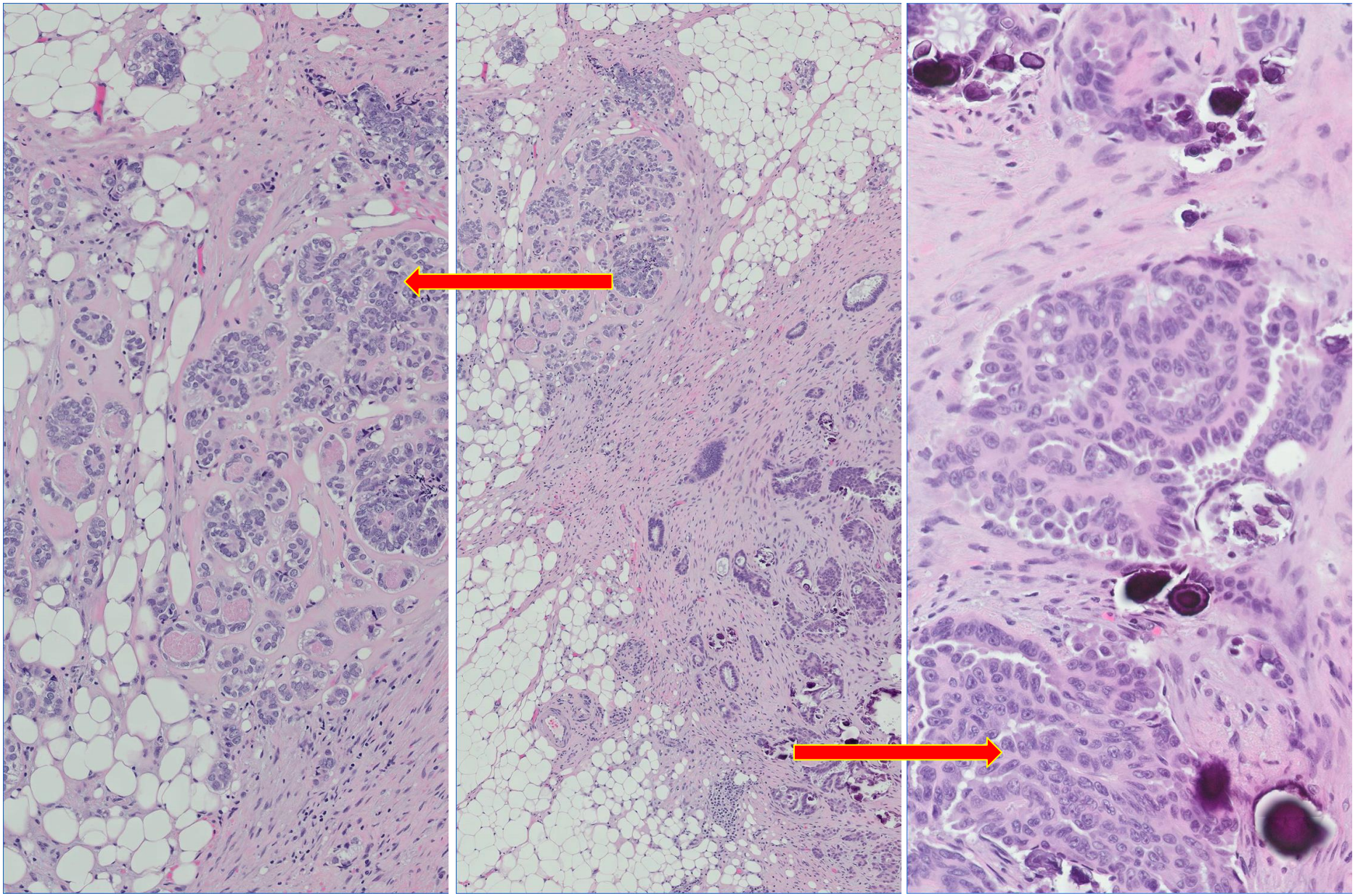

Case 3
diagnosis

Serous component:

Low-grade serous carcinoma arising from serous borderline tumor

Microglandular component:

Mesonephric-like adenocarcinoma of the ovary

Both tumors spread to pelvic peritoneum and omentum either in pure or combined forms, though the spread from mesonephric-like adenocarcinoma was more extensive

Collision tumor *versus* one neoplasm with dual differentiation?
molecular study

- Capture-based NGS was performed using an assay that targets the coding regions of 480 cancer-related genes
- Sequencing libraries were prepared from the genomic DNA extracted from all three components of the ovarian tumor (SBT, LGSC, MLC) and selected metastatic foci
- Target enrichment was performed by hybrid capture using a costume oligonucleotide library
- Sequencing was performed on an Illumina HiSeq 2500
- Only insertions/deletions up to 100 base pairs in length were visualized and verified using integrated Genome Viewer

Collision tumor *versus* one neoplasm with dual differentiation?
molecular study

- All tumor samples (SBT, LGSC, MLC and metastatic foci pure and combined) harbored an *NRAS* p.Q61R hotspot mutation at clonal mutant allele frequency
- All samples shared multiple chromosomal copy number variants (CNVs), including gains in chromosome 1q and 18p and losses in chromosome 1p, 18q, and 22
- SBT and primary LGSC did not show additional mutations, but the metastatic LGSC had additional subclonal mutations in *KDM5A* and *STAG2*
- All of the mesonephric-like samples had additional mutations in the tumor suppressor genes *BCOR* and *AMER1*, which were not present in the serous components

Conclusion: single carcinoma with divergent morphology rather than a collision tumor

- Common *NRAS* p.Q61R driver mutation in both tumor components, including the metastases
- Additionally, all tumor components shared five distinct CNVs, including gain of chromosome 1q (previously reported to occur in 75% of mesonephric carcinomas by Mirkovic et al, 2015)
- These shared genetic features indicate that this is a single carcinoma with divergent morphology, rather than a collision tumor
- Accumulation of additional mutations in *AMER1* and *BCOR* in the MLC component, and *STAG2* and *KDM5A* in the LGSC, indicates continued evolution after the genetic divergence of the two morphologic components

Ramifications from the molecular findings

- Serous borderline elements contained *NRAS* p.Q1R mutation, suggesting obligate differentiation toward invasive carcinoma
- SBT may therefore form the root of phylogeny, in which the *NRAS*-mutated SBT gives rise to an invasive Mullerian carcinoma with both LGSC and MLC elements
- All Mullerian in origin and all bearing the same pathogenetic *NRAS* p.Q61R driver mutation, as well as five unique shared CNVs
- *NRAS* p.Q61R mutation has been reported in 26% of LGSCs (Hunter et al, 2015)
- *NRAS* p.Q61R mutation has also been reported in a case of mesonephric carcinoma (Mirkovic et al, 2015)

Case 3
concluding remarks

- A primary mesonephric-like adenocarcinoma of the right ovary in association with a low-grade serous carcinoma developing from serous borderline tumor is presented
- Mesonephric adenocarcinomas are rare neoplasms that most commonly arise in the uterine cervix, rarely in vagina and exceptionally rarely in the uterine corpus
- The mesonephric-like elements, in the ovarian tumor presented, are histologically and immunohistochemically indistinguishable from cervical mesonephric carcinoma
- Patient died of peritoneal carcinomatosis two years following diagnosis

Case 3
concluding remarks cont.

- All three components (SBT, LGSC, MLC) share an NRAS p.Q61R driver mutation and multiple copy number variations
- The molecular similarities together the overall morphologic features, indicate that both invasive carcinomatous components share an origin in the serous borderline tumor
- The findings suggest that some of the mesonephric carcinomas arise from Mullerian precursors

Mixed mesonephric adenocarcinoma and high-grade neuroendocrine carcinoma of the uterine cervix with molecular evidence of clonal origin has been reported (Cavalcanti et al. Int J Gynecol Pathol 2016)

Case 3

Int J Gynecol Pathol 2018; 37:448-459

An Ovarian Adenocarcinoma With Combined Low-grade Serous and Mesonephric Morphologies Suggests a Müllerian Origin for Some Mesonephric Carcinomas

David B. Chapel, M.D., Nancy M. Joseph, M.D., Ph.D., Thomas Krausz, M.D., and Ricardo R. Lastra, M.D.

Summary: Mesonephric carcinomas are rare adenocarcinomas of the female genital tract that occur most commonly in the uterine cervix. They are classically thought to arise from benign mesonephric remnants, and are rarely reported at other sites in the gynecologic tract. Here we present an interesting biphenotypic ovarian adenocarcinoma with intimately associated but distinct components of both low-grade serous carcinoma and mesonephric-like carcinoma. A serous borderline tumor was present adjacent to the invasive carcinoma, and no benign mesonephric precursors were identified. Numerous invasive peritoneal metastases were present, including multiple metastases with both low-grade serous and mesonephric-like elements. Consistent with recent reports, foci of mesonephric-like carcinoma were morphologically and immunohistochemically identical to classic mesonephric carcinoma of the cervix. On molecular analysis, the serous borderline tumor, primary and metastatic low-grade serous carcinoma, and primary and

Subsequent publication….
Int J Gynecol Pathol 2018

Case Report

Ovarian Combined Low-grade Serous and Mesonephric-like Adenocarcinoma: Further Evidence for A Mullerian Origin of Mesonephric-like Adenocarcinoma

W. Glenn McCluggage, F.R.C.Path., Hana Vosmikova, M.A., and Jan Laco, Ph.D.

Summary: Mesonephric-like adenocarcinomas are rare neoplasms occurring in the uterine corpus and ovary which bear a close morphologic resemblance to cervical mesonephric adenocarcinomas. They also have a similar immunophenotype and harbor similar molecular

1. A second reported case of combined ovarian low-grade serous tumor and mesonephric-like adenocarcinoma
2. Identical *KRAS* mutation in both components (the presented case had *NRAS* mutation in both components)
3. Review of published and unpublished mesonephric-like adenocarcinomas: 8 of 11 of these neoplasms contained other Mullerian lesions in the same ovary, mainly endometriosis and adenomas/adenofibromas

Am J Surg Pathol 2018; 42:227-233

Targeted Genomic Profiling Reveals Recurrent *KRAS* Mutations in Mesonephric-like Adenocarcinomas of the Female Genital Tract

Jelena Mirkovic, MD, PhD, Marie McFarland, FRCPath,† Elizabeth Garcia, PhD,‡ Lynette M. Sholl, MD,‡ Neal Lindeman, MD,‡ Laura MacConaill, PhD,‡§ Fei Dong,‡ Michelle Hirsch, MD, PhD,‖ Marisa R. Nucci, MD,‖ Charles M. Quick, MD,¶ Christopher P. Crum, MD,‖ W. Glenn McCluggage, FRCPath,† and Brooke E. Howitt, MD‖*

Abstract: Mesonephric adenocarcinoma most commonly arises in the cervix and is presumed to be derived from normal or hyperplastic mesonephric remnants. It is characterized by recurrent *KRAS* mutations and lack of *PIK3CA*/*PTEN* alterations. Adenocarcinomas of the uterine corpus and ovary characterized by

iants in exonic regions of 300 cancer genes, and 113 selected intronic regions across 35 genes. All 7 tumors (100%) harbored canonical activating *KRAS* mutations (4 G12D, 3 G12V). *PIK3CA* activating mutations were identified in 3 of 7 (43%) cases. There were no alterations in *PTEN*, *ARID1A*, or *TP53* in any of the tumors. In copy number analysis, 5 of 7 (71%) tumors ex-

1. Seven mesonephric-like adenocarcinomas (4 ovarian, 3 uterine corpus)
2. All 7 tumors harbored activating *KRAS* mutations
3. They exhibit similar molecular aberrations to mesonephric carcinomas, but also frequently harbor *PIK3CA* mutations, demonstrating biological overlap with carcinomas both mesonephric and Mullerian (endometrioid) differentiation

Am J Surg Pathol 2018; 43:389-398

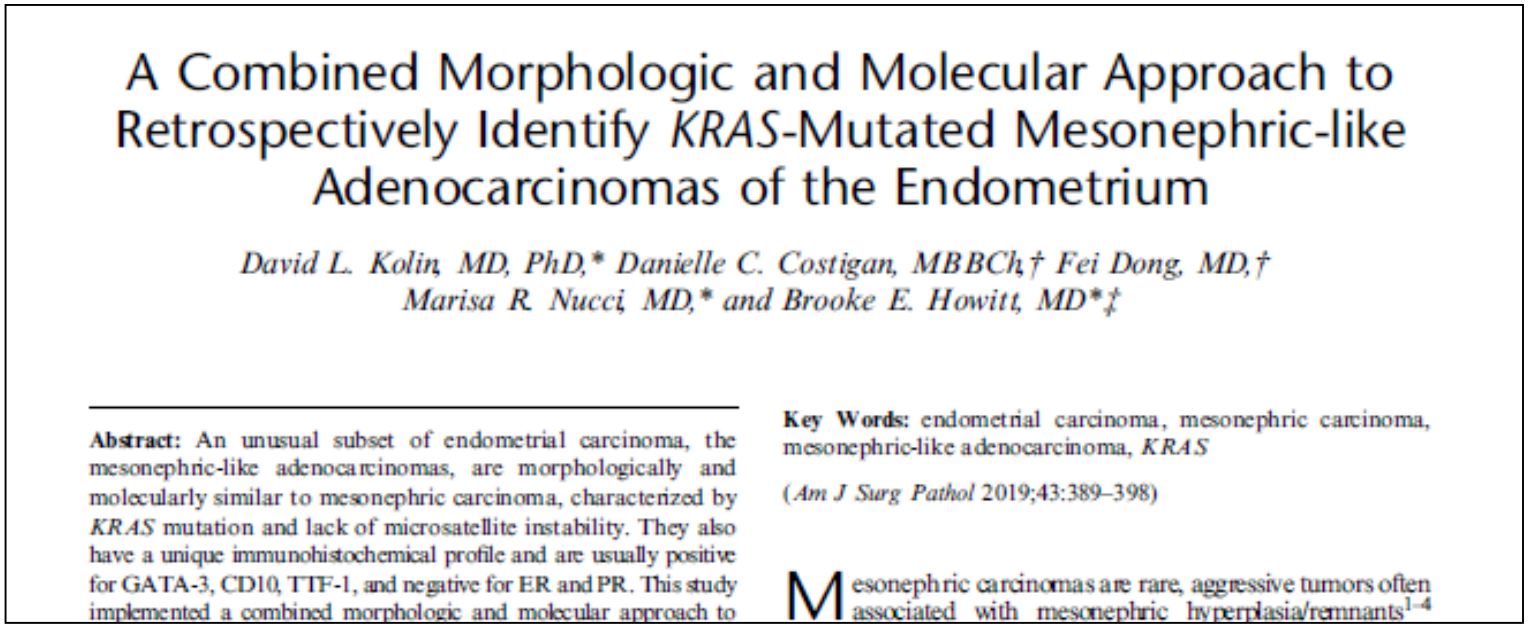

A Combined Morphologic and Molecular Approach to Retrospectively Identify *KRAS*-Mutated Mesonephric-like Adenocarcinomas of the Endometrium

David L. Kolin, MD, PhD, Danielle C. Costigan, MBBCh,† Fei Dong, MD,† Marisa R. Nucci, MD,* and Brooke E. Howitt, MD*‡*

Abstract: An unusual subset of endometrial carcinoma, the mesonephric-like adenocarcinomas, are morphologically and molecularly similar to mesonephric carcinoma, characterized by *KRAS* mutation and lack of microsatellite instability. They also have a unique immunohistochemical profile and are usually positive for GATA-3, CD10, TTF-1, and negative for ER and PR. This study implemented a combined morphologic and molecular approach to

Key Words: endometrial carcinoma, mesonephric carcinoma, mesonephric-like adenocarcinoma, *KRAS*

(*Am J Surg Pathol* 2019;43:389–398)

Mesonephric carcinomas are rare, aggressive tumors often associated with mesonephric hyperplasia/remnants[1–4]

1. Mesonephric-like adenocarcinomas are morphologically and molecularly similar to mesonephric carcinoma and lack of microsatellite instability
2. They are immunoreactive for GATA3, CD10, TTF1 and negative for ER and PR
3. *KRAS*-mutated mesonephric-like adenocarcinomas represents ~1% of all endometrial carcinomas

Mesonephric-like adenocarcinomas of the ovary

How were they called before?

- Eichhorn JH, Scully RE: "Adenoid cystic" and basaloid carcinomas of the ovary: evidence for a surface epithelial lineage. A report of 12 cases.
  Mod Pathol 1995; 8:731-740
- Six cases with an exclusive or predominant component resembling adenoid cystic carcinoma
- Most had an additional surface epithelial component: serous adenocarcinoma, endometrioid adenocarcinoma
- Case 3 on the first biopsy was called "adenoid cystic-like" carcinoma

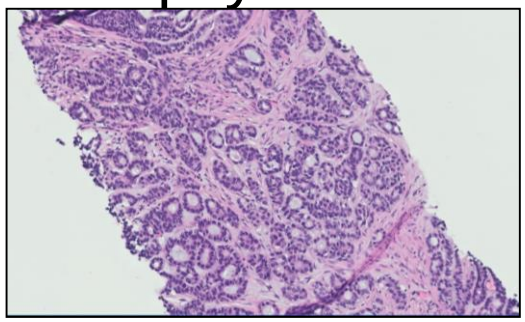

Case 3
selected references

- Kenny SL, McBride HA, Jamison J, McCluggage WG. Mesonephric adenocarcinomas of the uterine cervix and corpus: HPV-negative neoplasms that are commonly PAX8, CA125, and HMGA2 positive and that may be immunoreactive with TTF1 and hepatocyte nuclear factor -1β. Am J Surg Pathol 2012; 36:799-807
- Emmanuel C, et al. Genomic classification of serous ovarian cancer with adjacent borderline differentiates RAS pathway and TP53-mutant tumors and identifies NRAS as an oncogenic driver. Clin Cancer Res 2014; 20: 6618-6630
- Hunter SM, et al. Molecular profiling of low grade serous ovarian tumors identifies novel candidate target genes. Oncotarget 2015; 6:37663-37677
- McFarland M, Quick CM, McCluggage WG. Hormone receptor negative, TTF1 positive uterine and ovarian adenocarcinomas: report of a series of mesonephric-like adenocarcinomas. Histopathology 2016; 68:1013-1020
- Mirkovic J, et al. Targeted genomic profiling reveals recurrent KRAS mutations and gain of chromosome 1q in mesonephric carcinomas of the female genital tract. Mod Pathol 2015; 28:1504-1514

Case 3
selected references

- Chapel DB, Joseph NM, Krausz T, Lastra RM. An ovarian adenocarcinoma with combined low-gradew serous and mesonephric morphologies suggests a mullerian origin for some mesonephric carcinomas.
  Int J Gynecol Pathol 2018; 37:448-459 (the presented case)
- McCluggage WG, Vosmikova H, Laco J. Ovarian combined low-grade serous and mesonephric-like adenocarcinoma: further evidence for a mullerian origin of mesonephric-like adenocarcinoma. Int J Gynecol Pathol 2018; December
- Mirkovic J, McFarland M, Garcia E et al. Targeted genomic profiling reveals recurrent *KRAS* mutations in mesonephric-like adenocarcinomas of the female genital tract. Am J Surg Pathol 2018; 42:227-233

Case 4
clinical history

- 17-year-old G0P0 woman with past medical history of multinodular goiter and hypothyroidism
- Found unconscious at home by parents after acute onset of heavy vaginal bleeding
- Physical exam: 10 cm, friable hemorrhagic mass protruding from introitus
- Partial trachelectomy and mass excision
- Mass arising from ectocervix
- Excision was complete

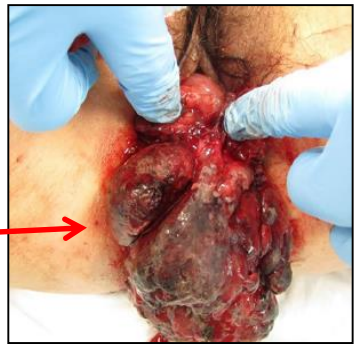

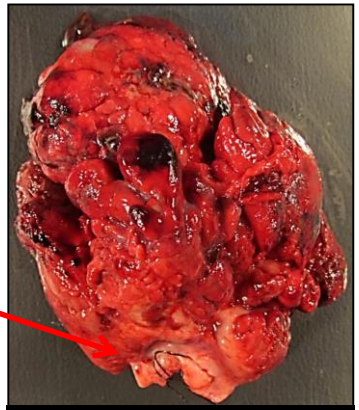

Ectocervix

Malignant mesenchymal neoplasm with subepithelial hypercellularity

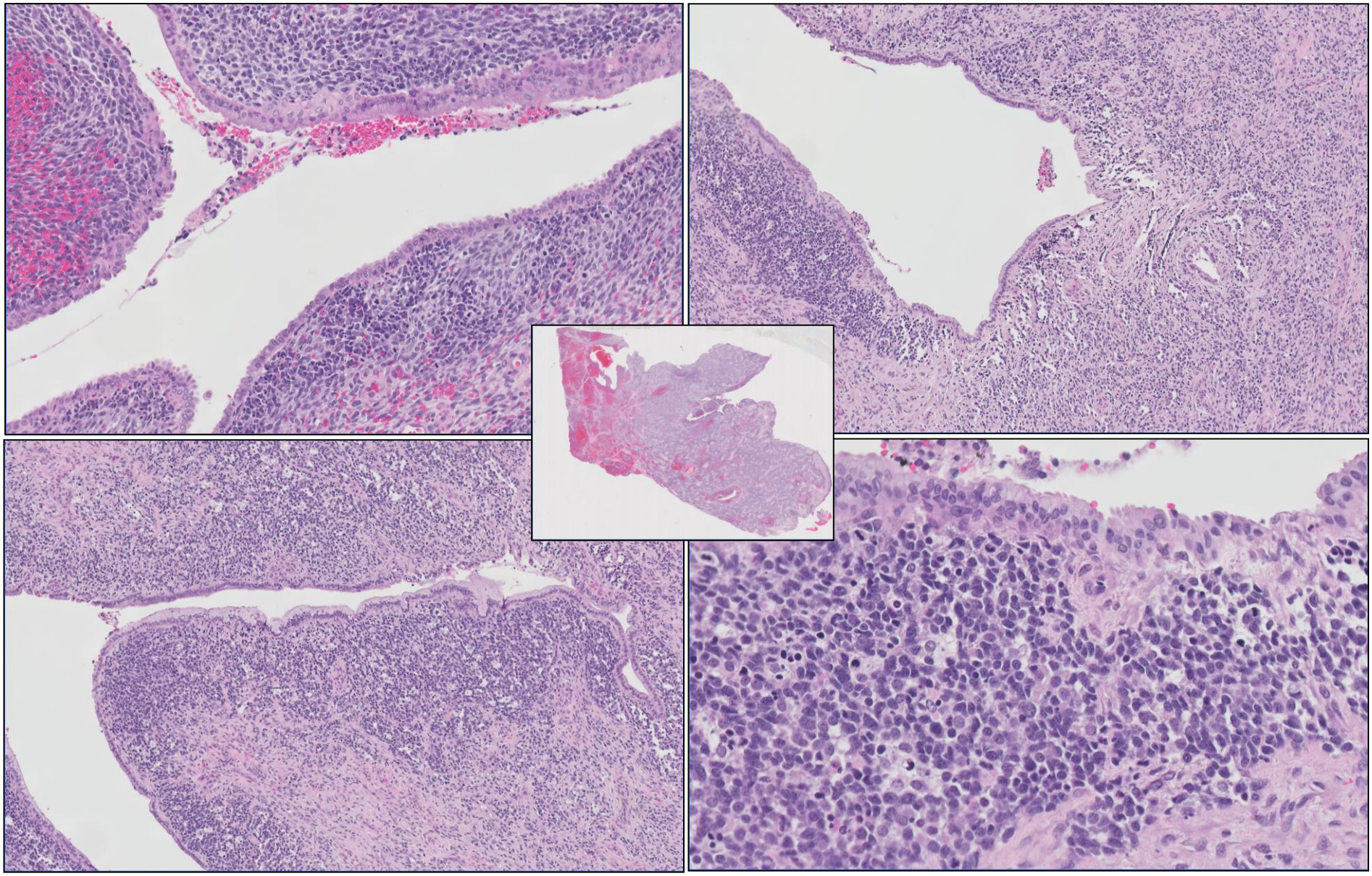

“Botryoid” features – subepithelial hypercellularity

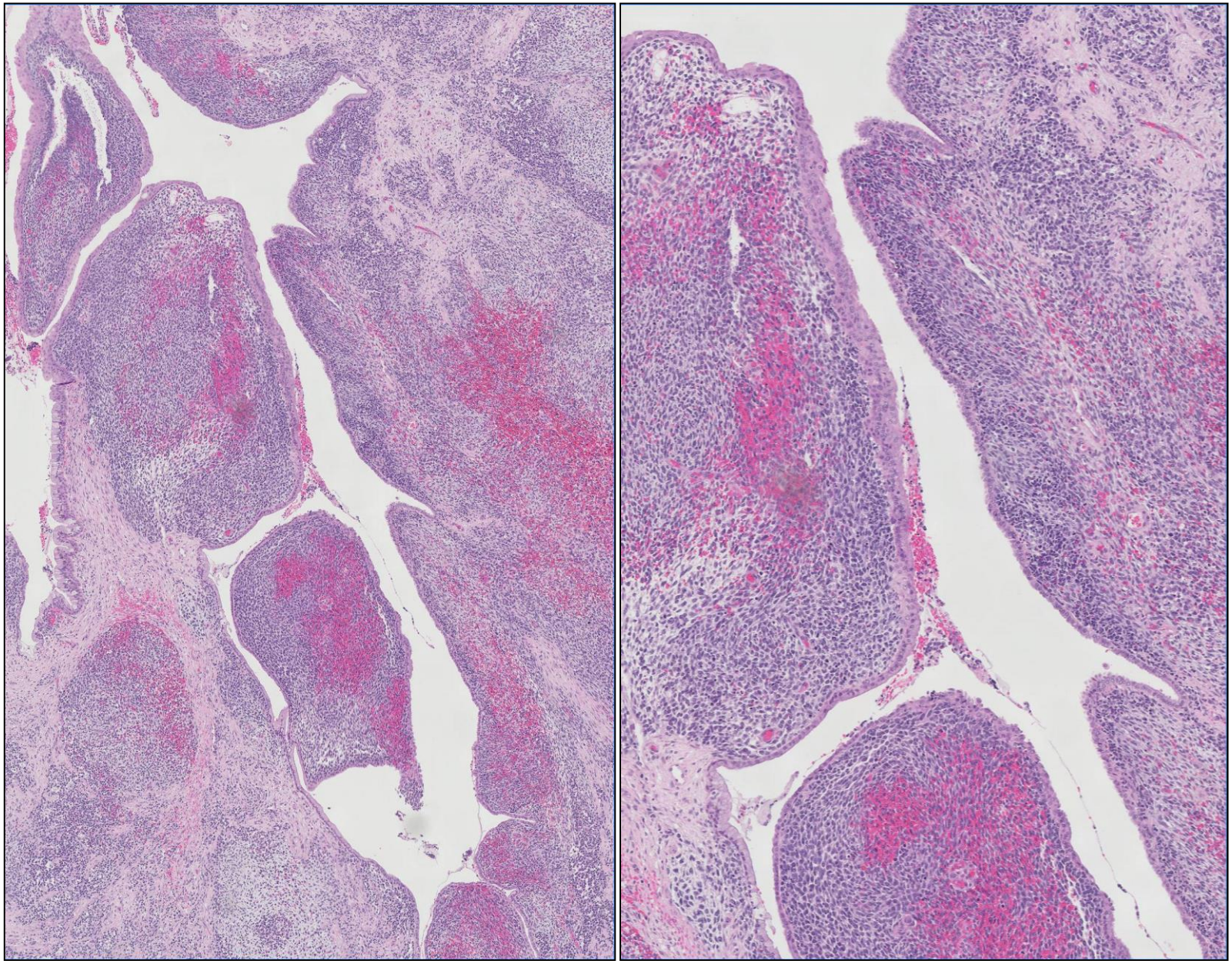

Mostly rounded tumor cells, but also focal spindling

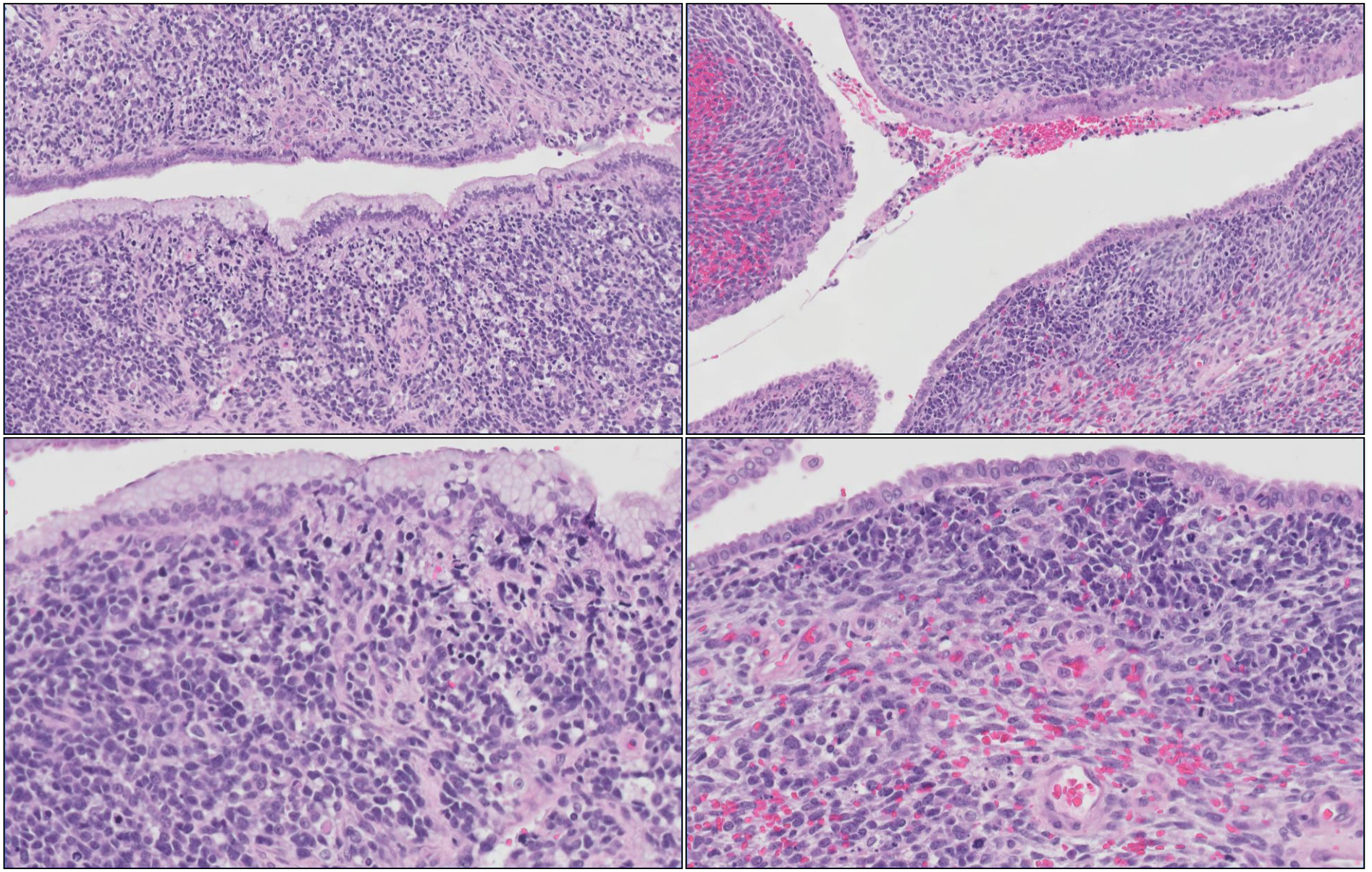

Rhabdomyoblastic differentiation

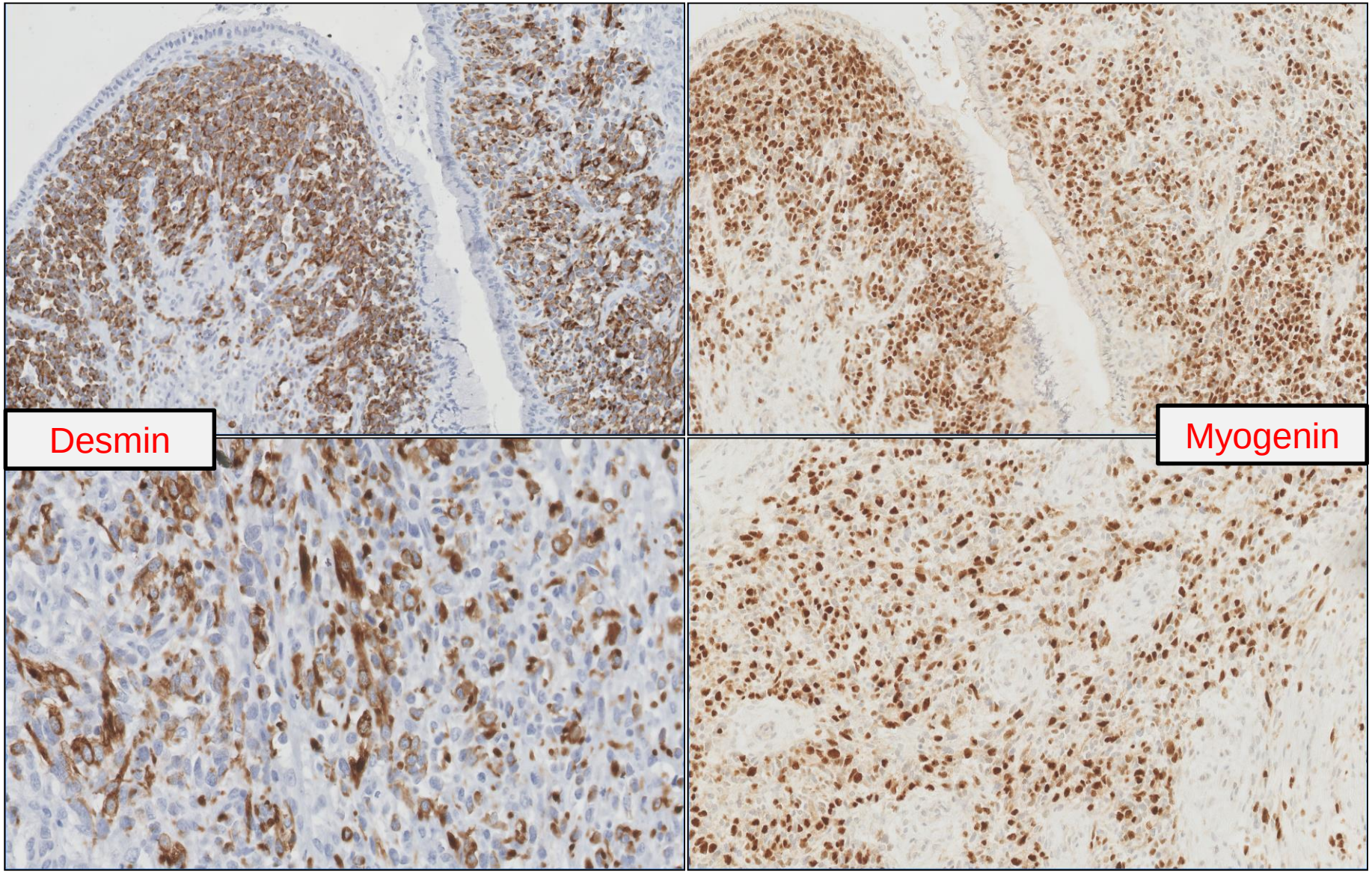

Deeper portion of the tumor – no glands – all sarcoma phenotypic heterogeneity with focal cartilaginous differentiation

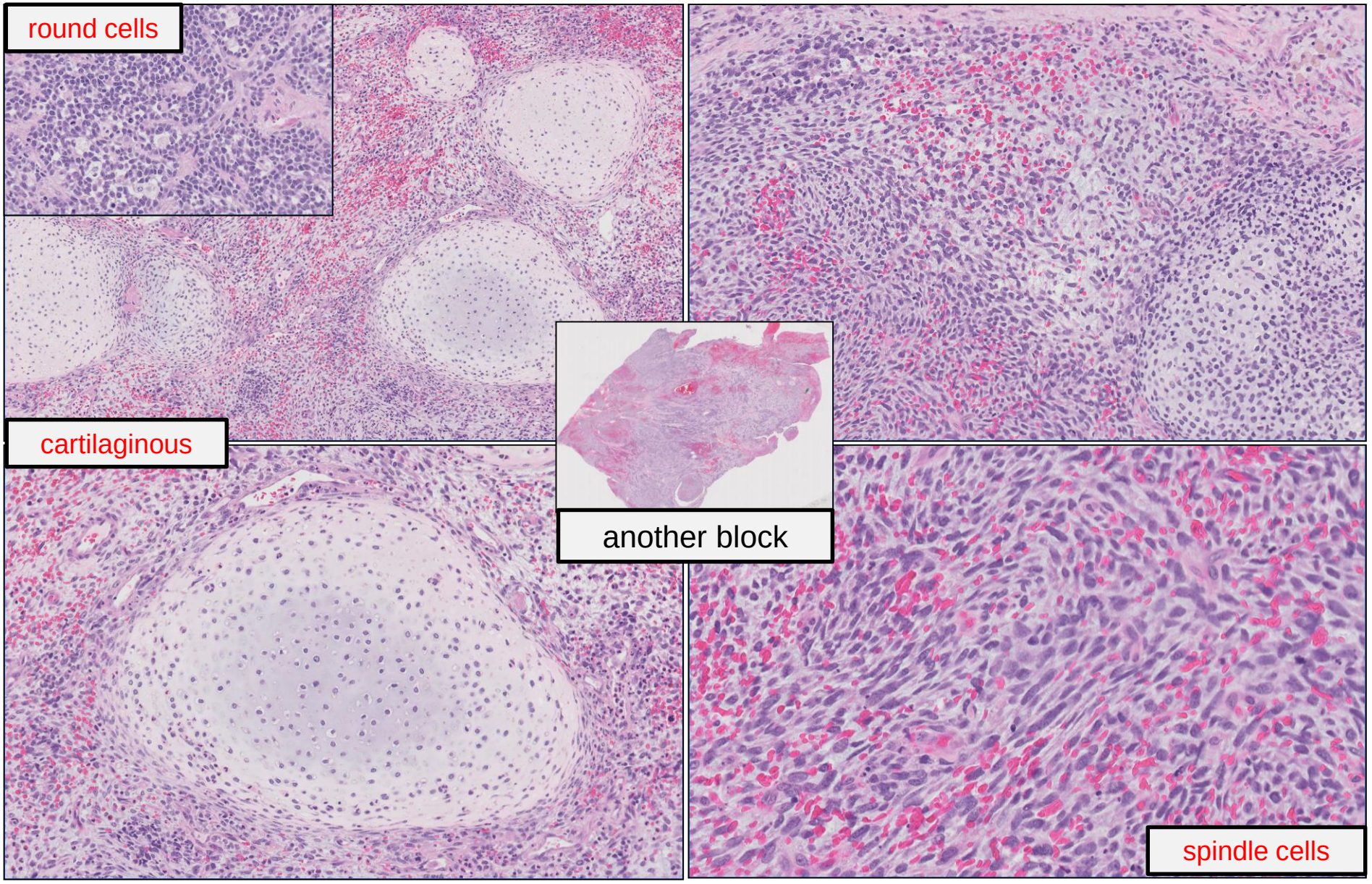

Case 4
differential diagnosis

- Adenosarcoma with sarcomatous overgrowth

- Embryonal rhabdomyosarcoma

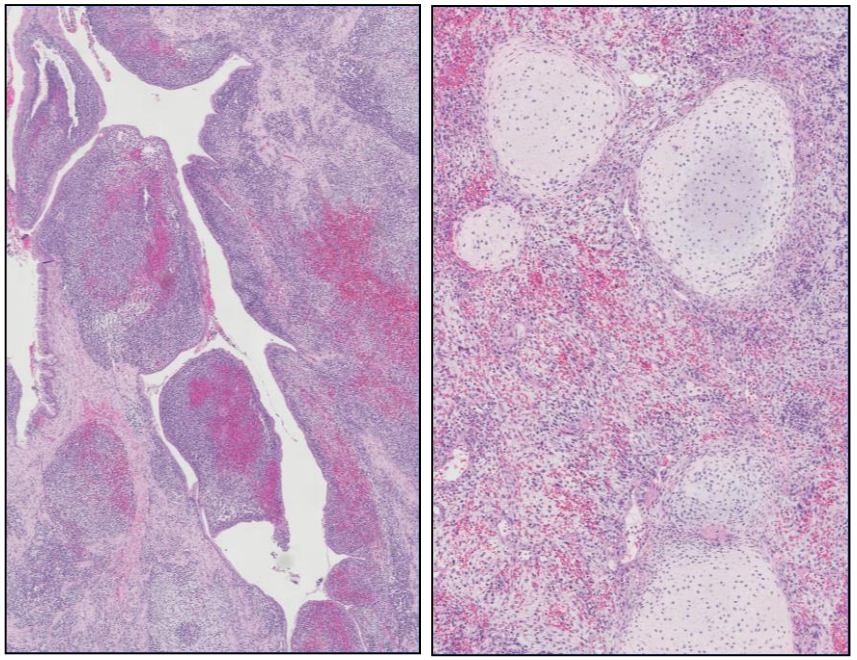

Case 4
diagnosis

Embryonal rhabdomyosarcoma of the cervix

but there is more to it….

also, what about the focal cartilaginous differentiation?

Childhood rhabdomyosarcomas

- Rhabdomyosarcoma is the most common soft tissue sarcoma of childhood, particularly the embryonal subtype
- Preferentially occur on the head & neck (35%) and genitourinary tract (25%)
- In the genital tract the vagina is one of the most common sites; about 90% diagnosed before the age 5
- However, the presented case occurred in the uterine cervix in a 17-year-old patient

Rhabdomyosarcoma of the cervix

- Cervical rhabdomyosarcomas are exceedingly rare; documented only in rare case reports and small series
- ~150 cases reported to date
- Older age at presentation (age 13 – 18)
- Favorable prognosis compared to younger patients with vaginal rhabdomyosarcomas
- One of the largest series published by Dehner et al 2012 (14 patients)

  - 6 cases with focal cartilaginous differentiation
    - several cases with concurrent extra-cervical neoplasms
  - possiblity of syndrome-association or germline predisposition was suggested

Interval clinical history

- Metastatic workup negative
  - Stage I (T1N0)
  - Clinical group IA (localized disease, completely excised)
- Originally the focal cartilaginous differentiation was “ignored” and no syndrome-association was considered by the pathologist signing-out the case (2012)
- Patient received 10 cycles of chemotherapy
- Interval increase of thyroid nodules; FNA of dominant nodule consistent with benign colloid nodule
- Followed up every 6 months with MRI and CXR

Interval clinical history

- 6-years later, surveillance MRI showed a new 7.5 cm left adnexal mass which was hypermetabolic on PET scan

  - Clinician suspected metastatic rhabdomyosarcoma, but …
- Physical exam: new prolapsed cervical polyp (5 cm x 2 cm) attached to the cervix
- Polypectomy specimen:
  recurrent cervical rhabdomyosarcoma
- Patient underwent hysterectomy and left oophorectomy

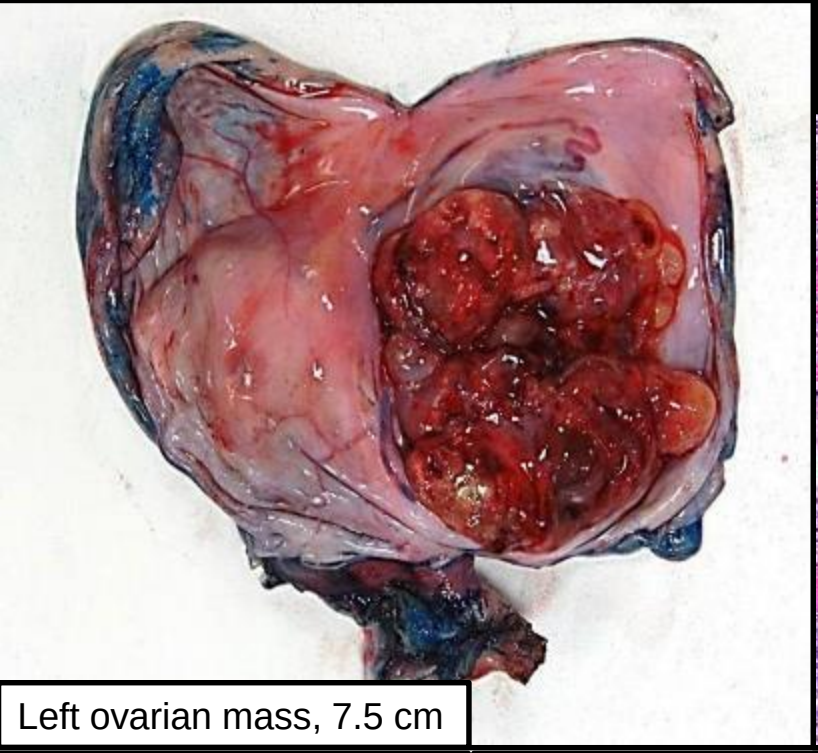

Left ovarian mass, 7.5 cm

Sertoli-Leydig cell tumor, intermediate differentiation with foci of heterologous mucinous intestinal-type glands

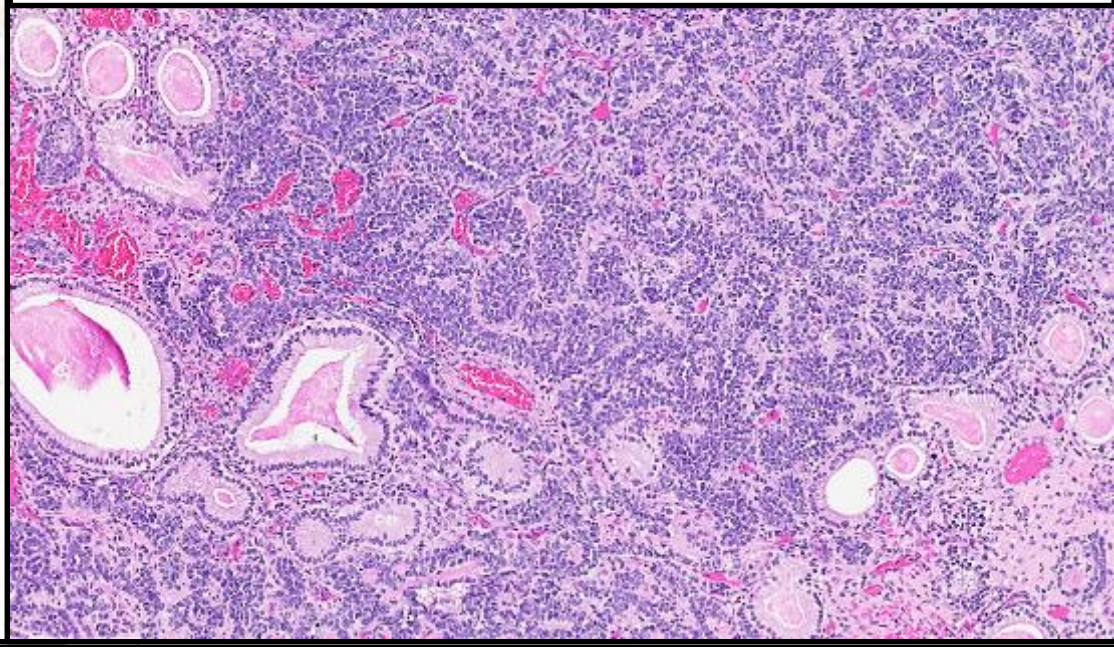

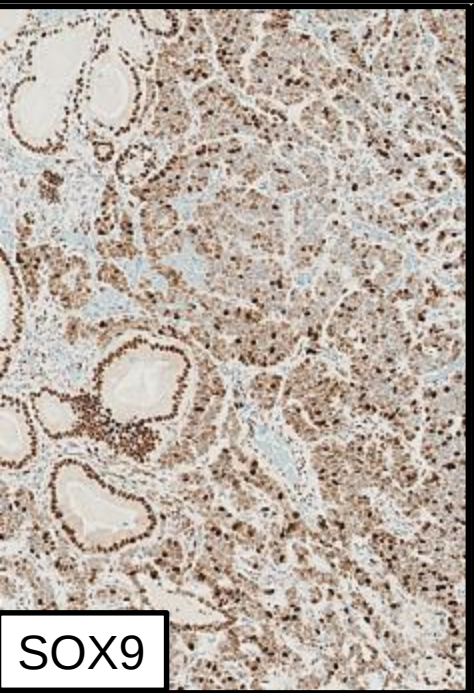

SOX9

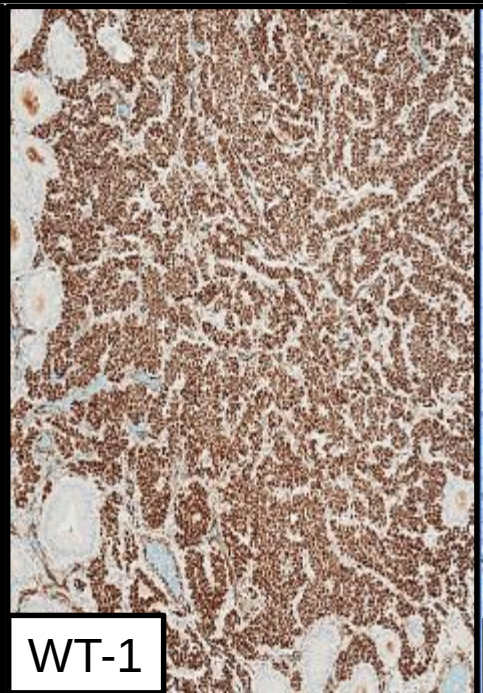

WT-1

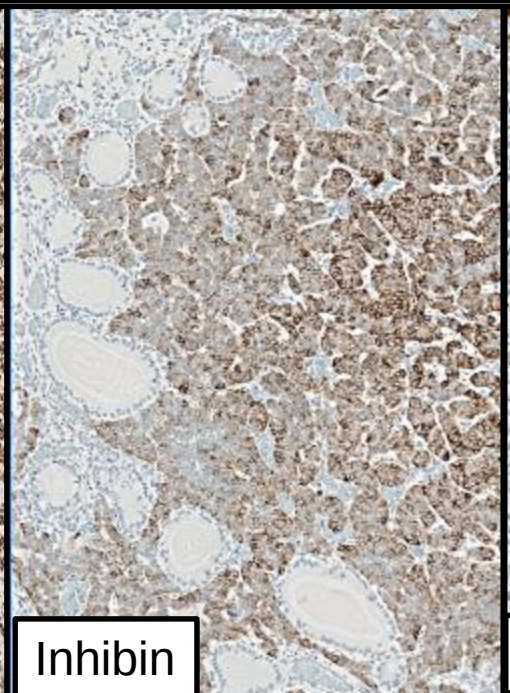

Inhibin

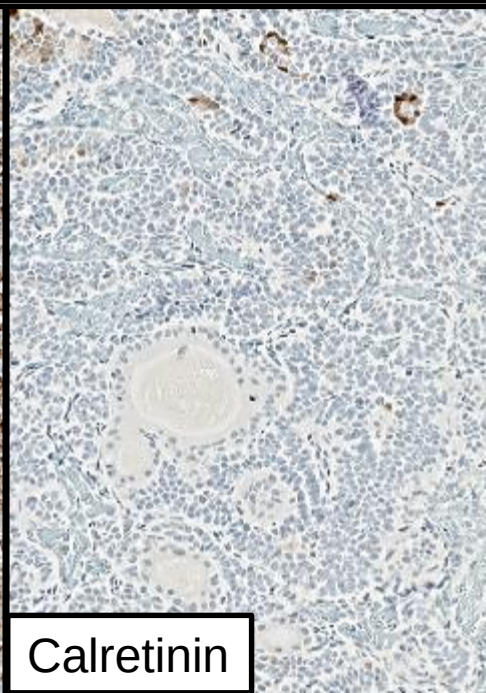

Calretinin

Coincidence?

- Young patient with an exceptionally rare cervical rhabdomyosarcoma, now recurrent
- Concurrent rare ovarian tumor
- Is there a link between the 2 tumors?
- Yes, germline mutation - *DICER1* syndrome should be considered
- Molecular analysis (NGS): *DICER1* mutation present
- Germline genetic testing: *DICER1* mutation present

DICER1 syndrome

- Familial tumor susceptibility syndrome
- First described in 2009 in patient with familial pleuropulmonary blastoma
- Caused by germline mutation in *DICER1* gene
- Inherited in an autosomal dominant manner
- Variable penetrance (~15%) for any of the associated manifestations
- Prevalence is currently unknown
- *DICER1* gene encodes for DICER1 enzyme that plays a critical role in the biogenesis of miRNAs regulating expression of various other genes

Foulkes et al. *Nature Reviews Cancer* 2014

Role of DICER1 Enzyme

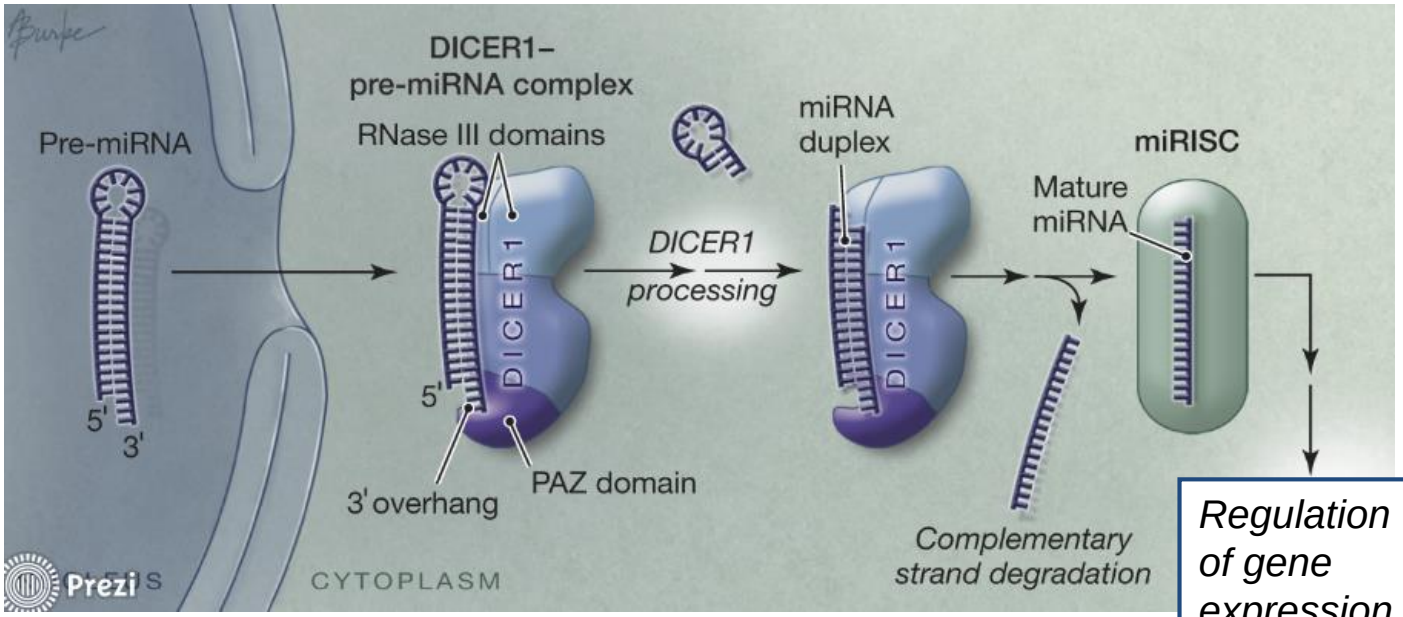

Regulation of gene expression → *Monitors cell proliferation & differentiation*

DICER1 enzyme forms a complex with pre-microRNA, than cleaves the microRNA precursors into their final mature form, which then help regulate gene expression, cell proliferation, and differentiation

Foulkes et al. *Nature Reviews Cancer* 2014

DICER1 gene mutation → abnormal DICER1 enzyme

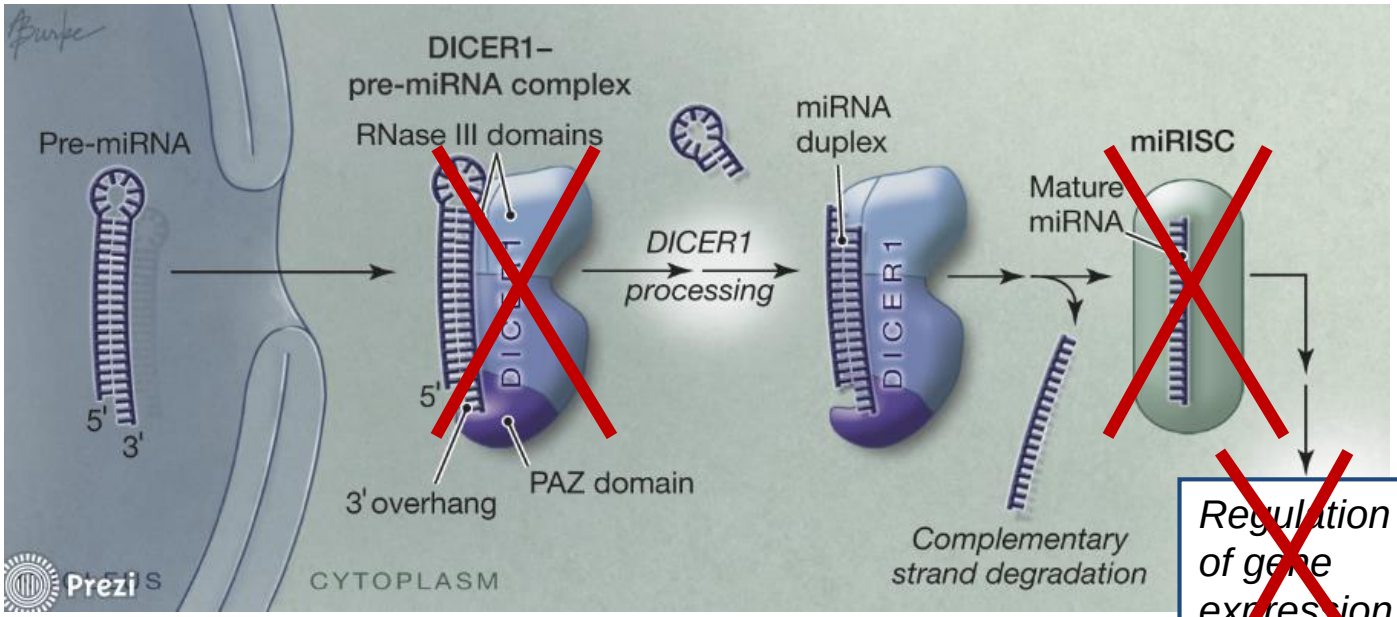

~~*Regulation of gene expression*~~

→ *Abnormal cell proliferation & differentiation/tumor formation*

Most gene mutations involved in *DICER1* syndrome lead to an abnormally short DICER protein that is functionally unable to aid in the production of microRNA

Without appropriate regulation by microRNA, genes are more likely to be expressed abnormally, potentially leading to abnormal cell proliferation/differentiation and tumor formation

Foulkes et al. *Nature Reviews Cancer* 2014

Role of DICER1 Enzyme

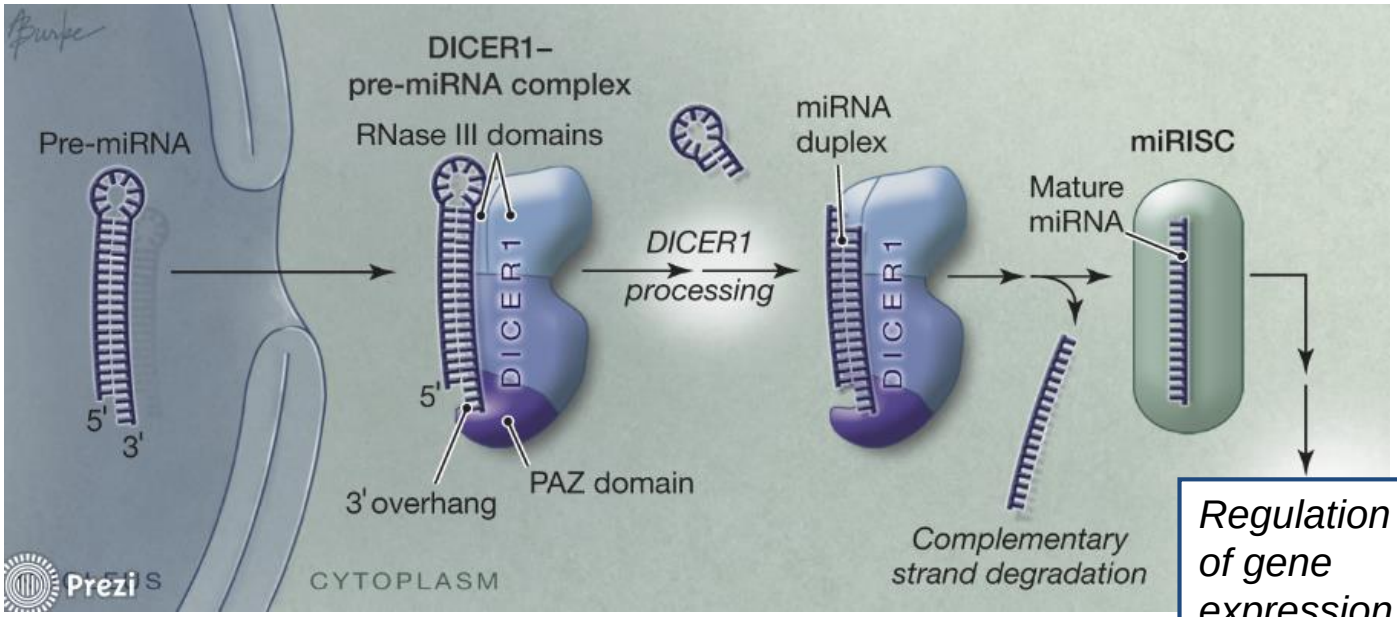

Regulation of gene expression

DICER1 gene is located on chromosome 14 and has 27 exons.

Exons:

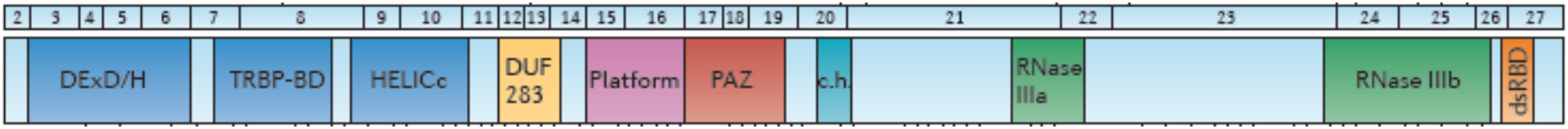

Foulkes et al. *Nature Reviews Cancer* 2014

Role of DICER1 Enzyme

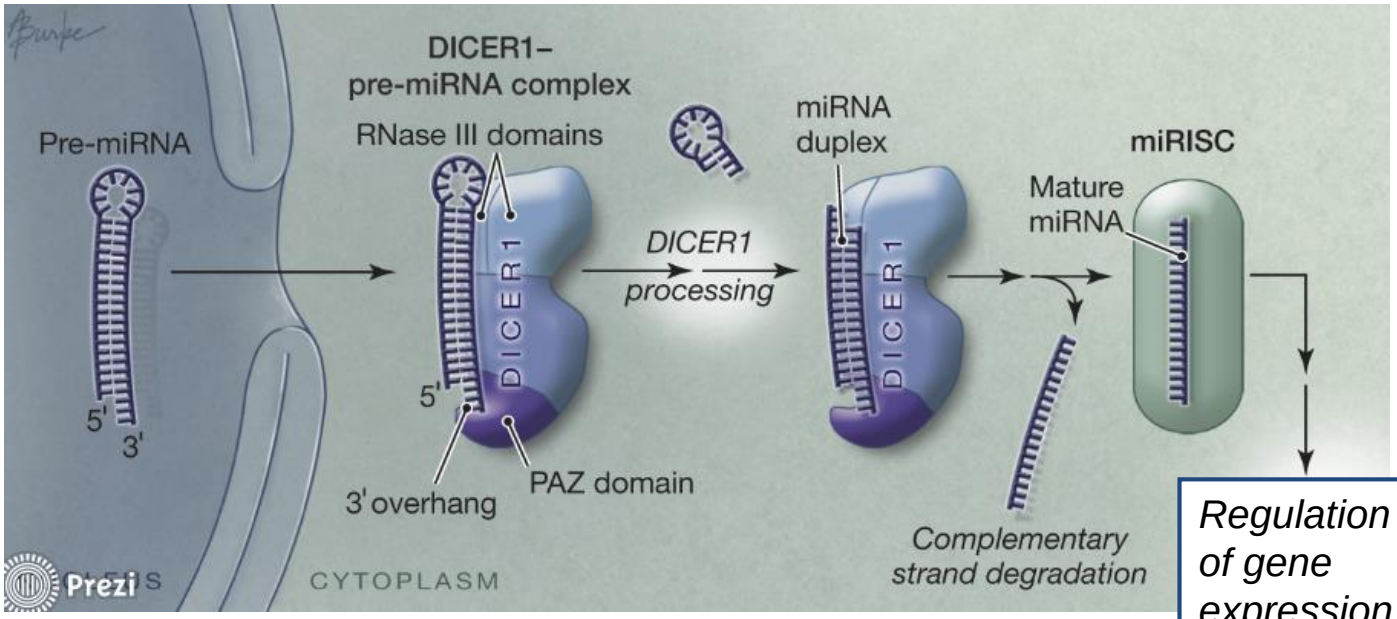

Regulation of gene expression

DICER1 gene is located on chromosome 14 and has 27 exons.

The mutation pattern is unique among tumor suppressor genes in that the "first hit" in germline is widely distributed truncating, inactivation mutations

Exons:

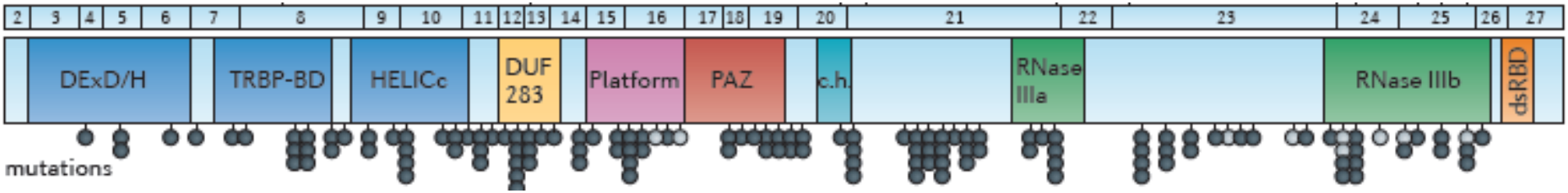

Germline Mutations

- Predicted truncating mutations
- Predicted non-truncating mutations

Foulkes et al. *Nature Reviews Cancer* 2014

Role of DICER1 Enzyme

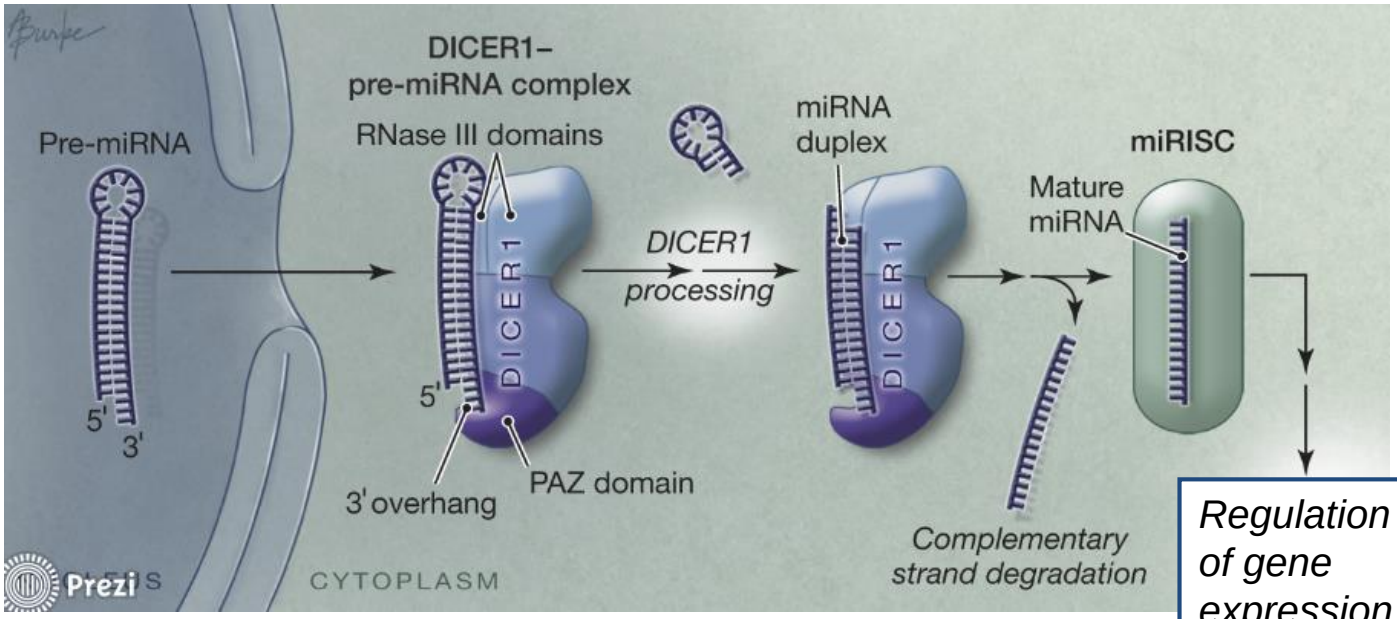

Regulation of gene expression

Somatic Mutations

The 'second hit' consists of hotspot somatic missense mutations highly focused to exons 24 and 25, which encode the RNase IIIb domain, responsible for cleaving precursor microRNAs to their final mature length

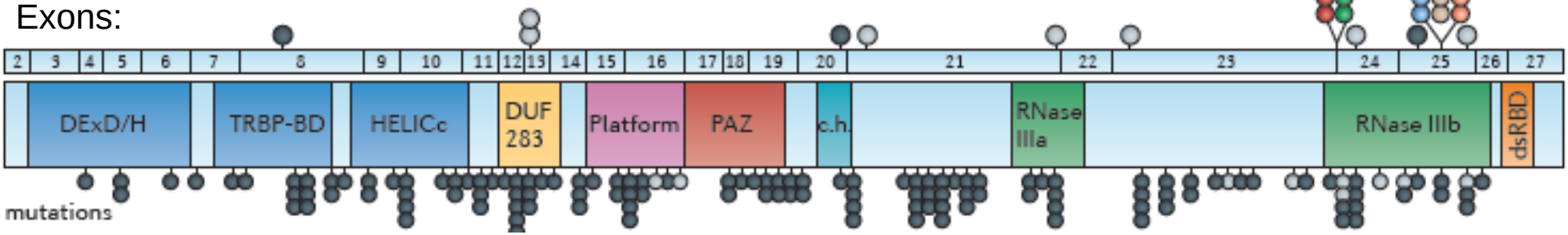

Germline Mutations

Predicted truncating mutations

Predicted non-truncating mutations

Foulkes et al. *Nature Reviews Cancer* 2014

Role of DICER1 Enzyme

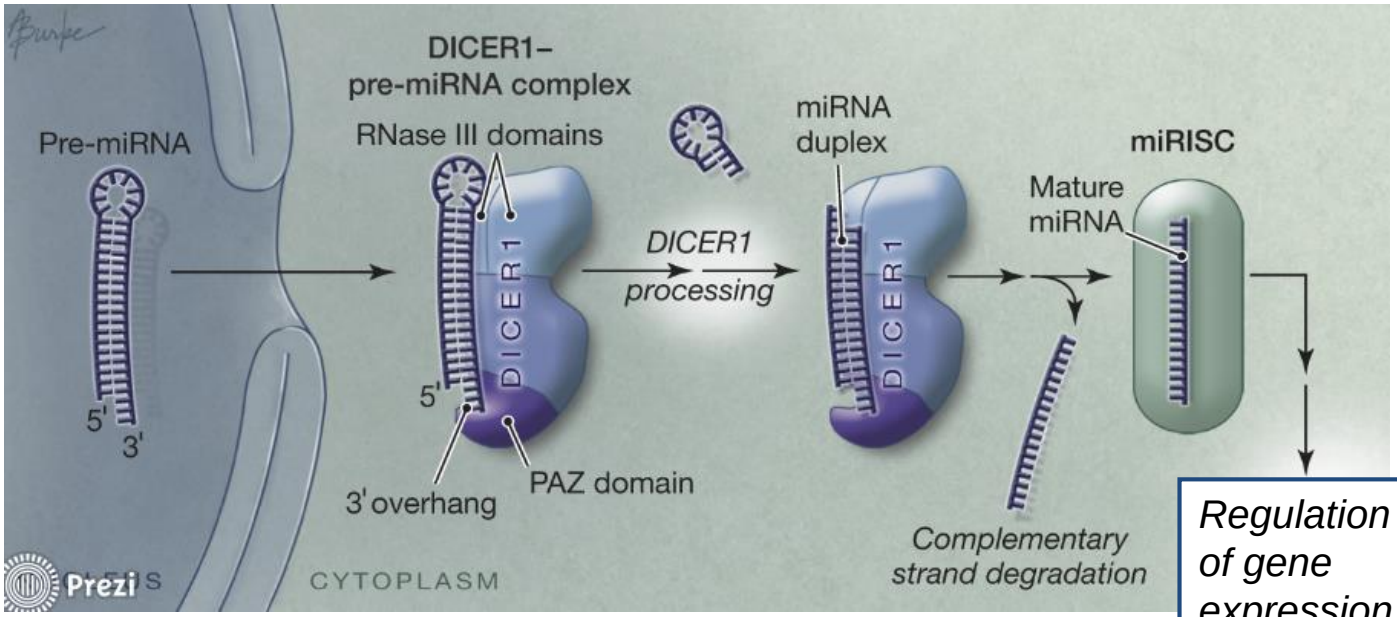

Regulation of gene expression

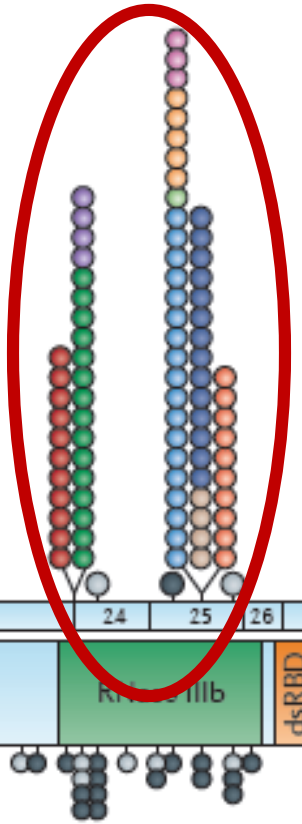

Somatic Mutations

Our patient was found to have a germline mutation near exon 10, as well as an expected 'hotspot' somatic mutation within the RNase IIIb domain (exon 24/25)

Exons:

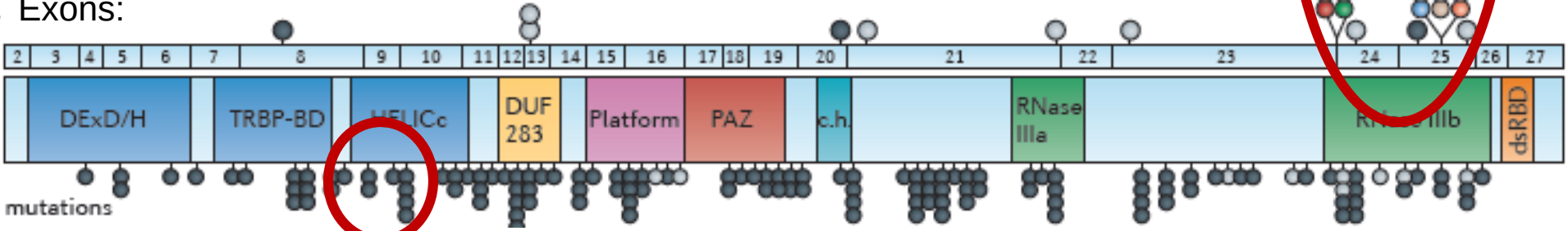

Germline Mutations

- Predicted truncating mutations
- Predicted non-truncating mutations

DICER1 syndrome – key clinical phenotypes

heterozygous germline *DICER1* mutation, in the context of tissue-specific somatic mutations on the other allele,
predisposes a patient to various tumors, both benign and malignant

- Pleuropulmonary blastoma (0 - 72 months); most well-defined association
- **Nodular hyperplasia**/carcinoma of thyroid (10 - 20 years)
- Cystic nephroma (0 - 48 months)
- **Sertoli – Leydig cell tumor of the ovary** (10 - 25 years)
- **Cervical embryonal rhabdomyosarcoma** (10 - 20 years)
- Nasal chondromesenchymal hamartoma (6 - 18 years)
- Ciliary body medulloepithelioma (3 - 10 years)
- Pineoblastoma/pituitary blastoma (0 - 25 years)

DICER1 syndrome – gynecologic manifestations

- Sertoli - Leydig cell tumor of the ovary >
  50% shown to have *DICER1* mutation
  100% in cases of moderate to poorly differentiated tumors, but 0% in well-differentiated Sertoli-Leydig cell tumors (*de Kock L et al, 2017*)
- Cervical embryonal rhabdomyosarcoma
  ~30% shown to have *DICER1* mutation

Case 4
key points

- Cervical embryonal rhabdomyosarcomas are often associated with *DICER1* mutation and clinico-pathologically different than vaginal ones occurring in infancy
- They must be differentiated from adenosarcomas
- *DICER1* syndrome is highly pleiotropic; the clinical spectrum and the natural history are yet to be fully defined
- The majority of *DICER1* related diseases are rare; presence should raise suspicion of genetic mutation
- Cervical embryonal rhabdomyosarcoma and Sertoli-Leydig cell tumor of the ovary are highly suggestive of *DICER1* mutation; diagnosis should prompt referral for genetic risk assessment

Case 4
references

- Dehner LP et al. Embryonal rhabdomyosarcoma of the uterine cervix: a report of 14 cases and a discussion of its unusual clinicopathologic associations. Mod Pathol 2012; 25:602-614
- Foulkes WD et al. DICER1: mutations, microRNAs and mechanisms. Nature Rev Cancer 2014; 14:662-672
- Wang Y et al. The oncogenic roles of DICER1 Rnase IIIb domain mutations in ovarian Sertoli-Leydig cell tumors. Neoplasia 2015; 17:650-660
- de Kock L et al. High-sensitivity sequencing reveals multi-organ somatic mosaicism causing DICER1 syndrome. J Med Genet 2016; 53:43-52
- Stewart CJR et al. Gynecologic manifestations of the DICER1 syndrome. Surgical Pathology 2016; 9:227-241

Case 4
references

- Cai S et al. Multimorbidity and genetic characteristics of DICER1 syndrome based on systematic review.
  J Pediatr Hematol Oncol 2017; 39:355-361
- De Kock L et al. *DICER1* mutations are consistently present in moderately differentiated and poorly differentiated Sertoli-Leydig cell tumors. Am J Surg Pathol 2017; 41:1178-1187
- Schultz KAP et al. *DICER1*-related Sertoli-Leydig cell tumor and gynandroblastoma: clinical and genetic findings from the International Ovarian and Testicular Stromal Tumor Registry.
  Gynecol Oncol, 2017; 147: 521-527
- Bean GR et al. *DICER1* mutations are frequent in mullerian adenosarcomas and are independent of rhabdomyosarcomatous differentiation. Modern Pathology 2019; 32:280-289

Case 5
clinical history

- 57-year-old female with history of uterine bleeding
- Previous endometrial biopsy was diagnosed as high-grade carcinoma, favoring a variant of endometrioid carcinoma
- Hysterectomy specimen contained a 5 cm yellow-tan,

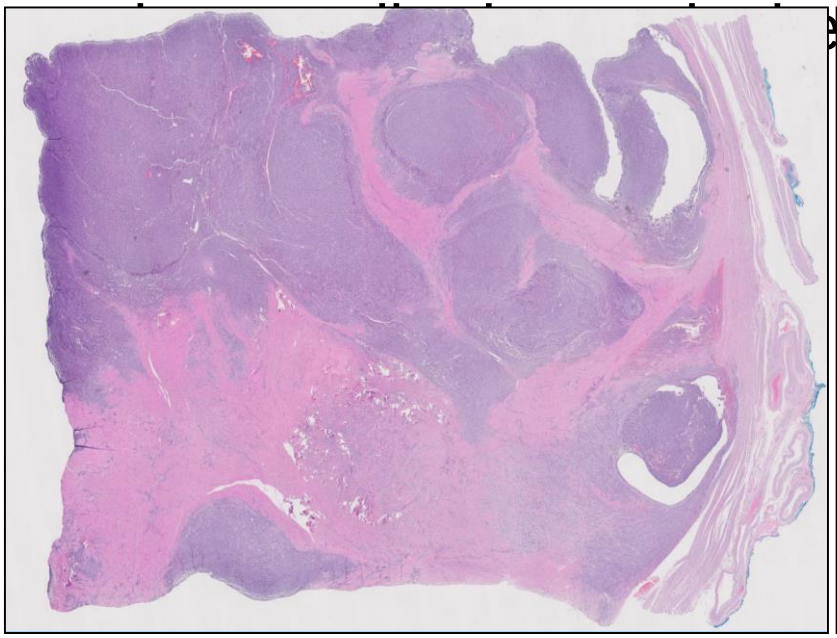

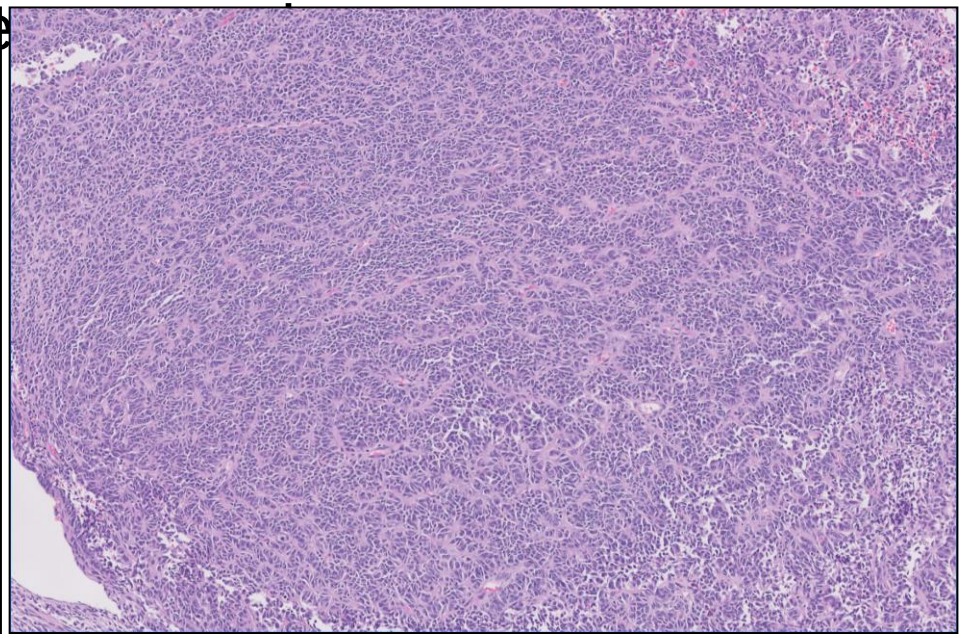

Tumor incorporates myometrium – diffuse, corded, pseudo-rosetting pattern

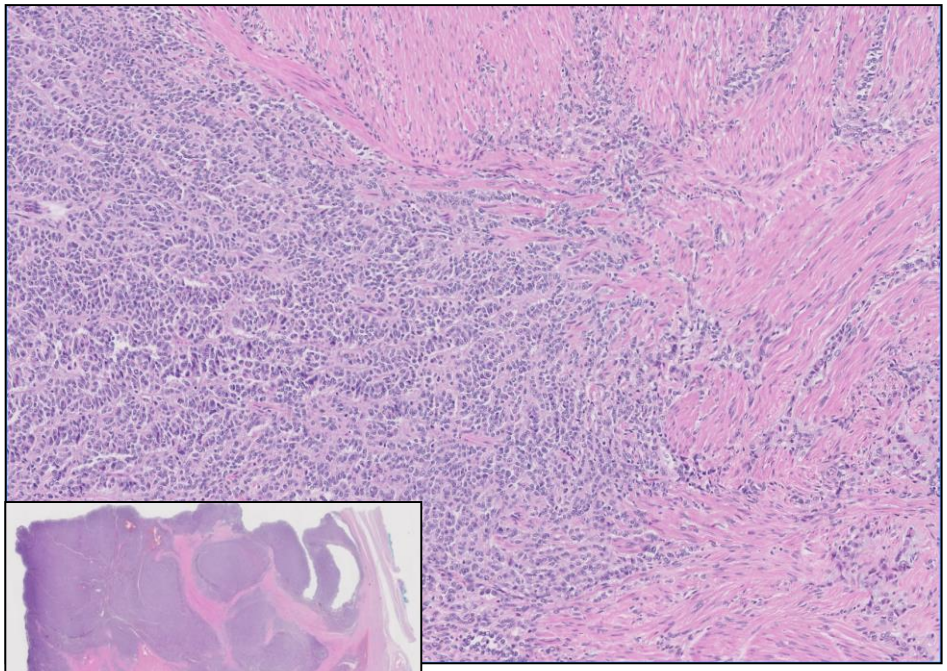

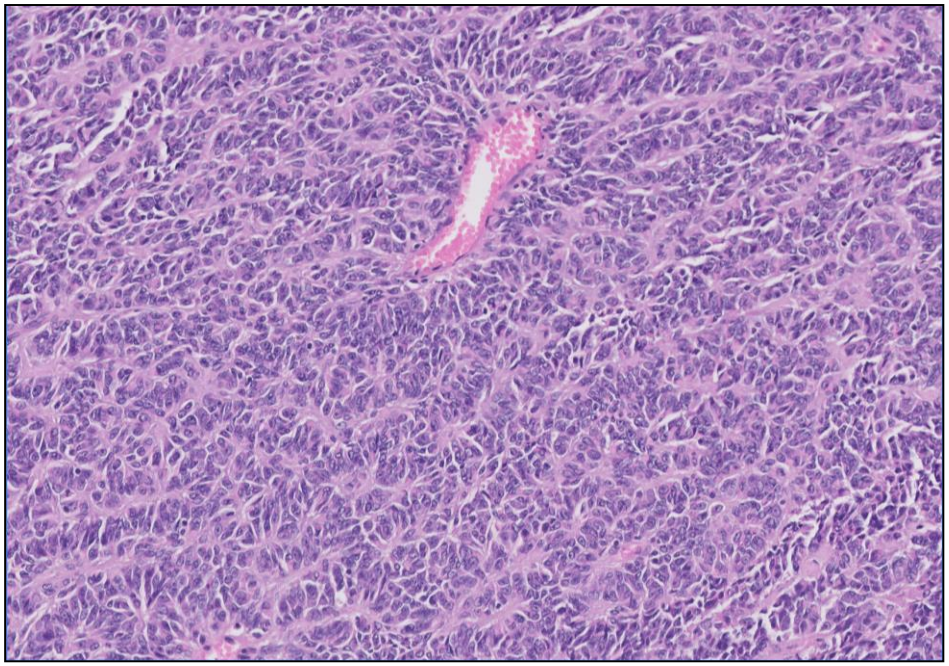

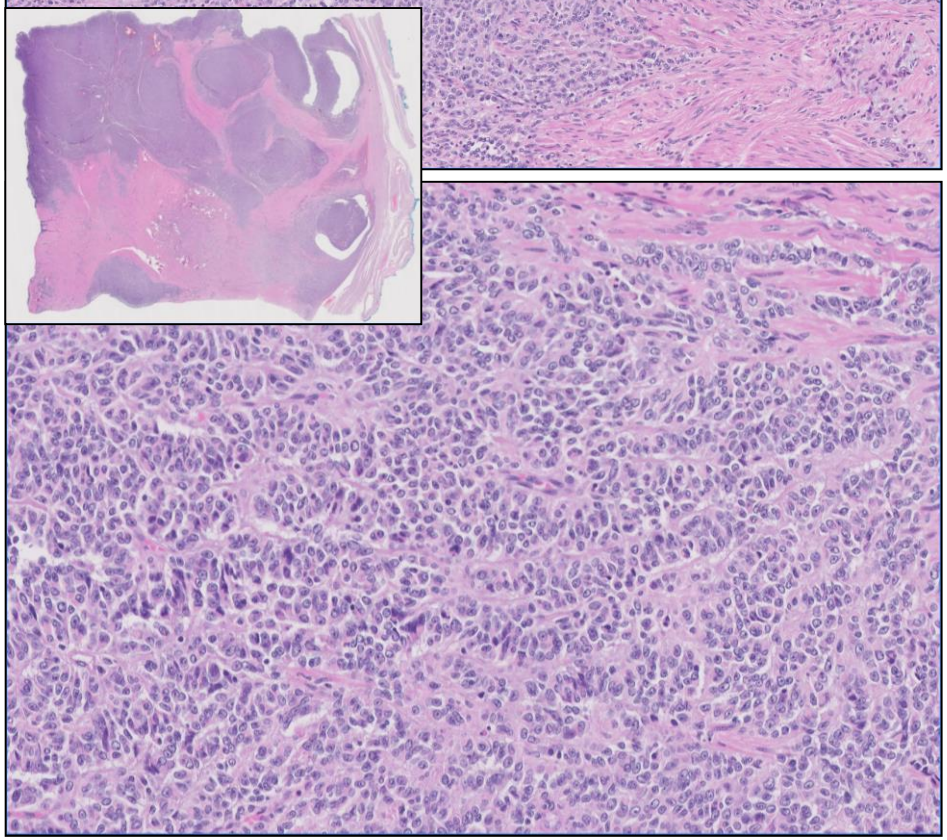

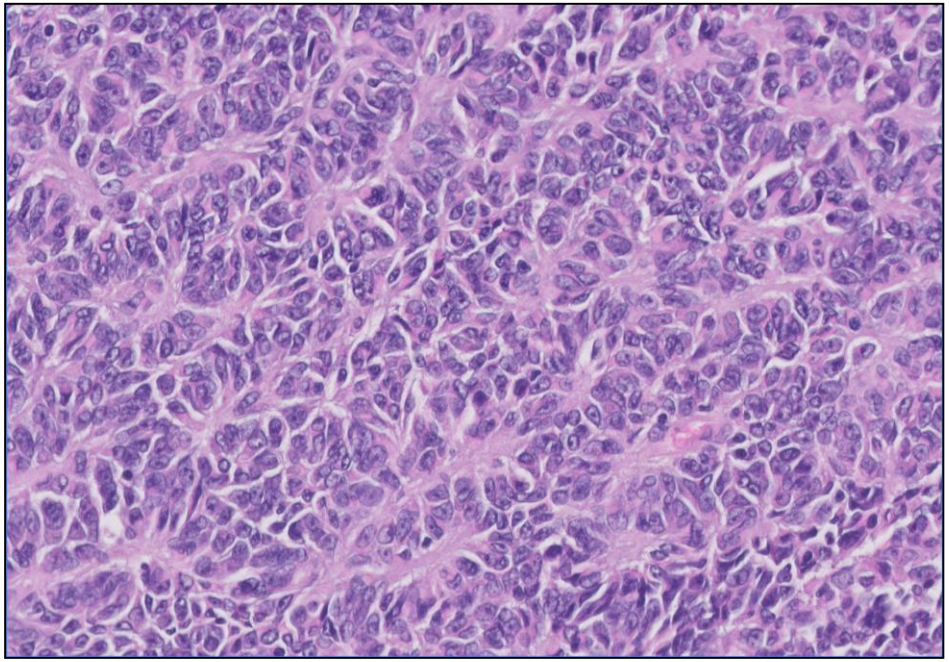

Neoplasm with striking pseudo-rosetting (Call-Exner-like bodies)

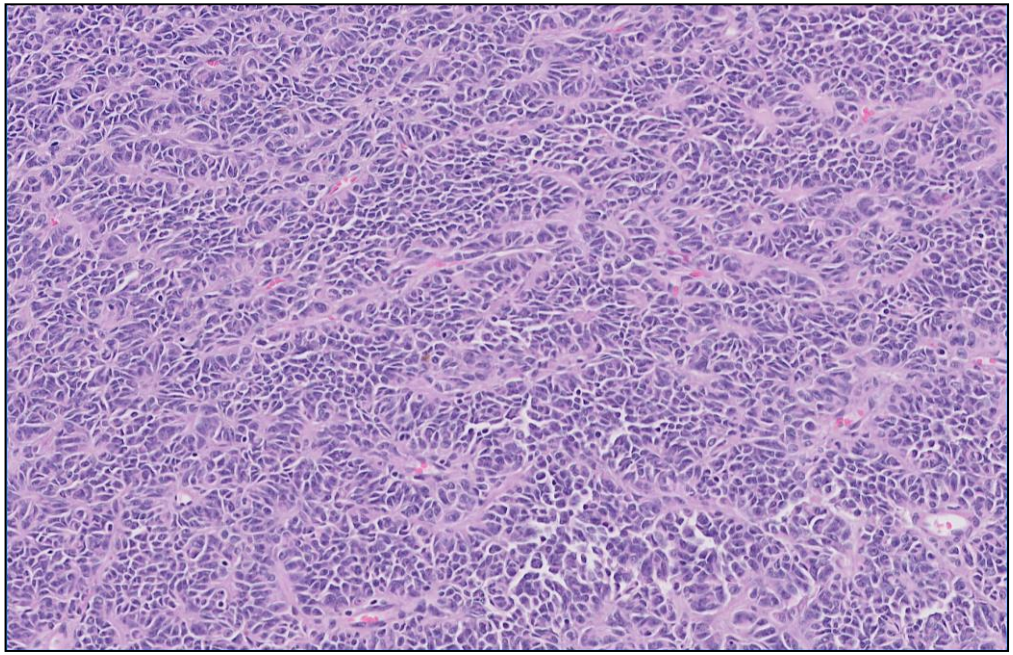

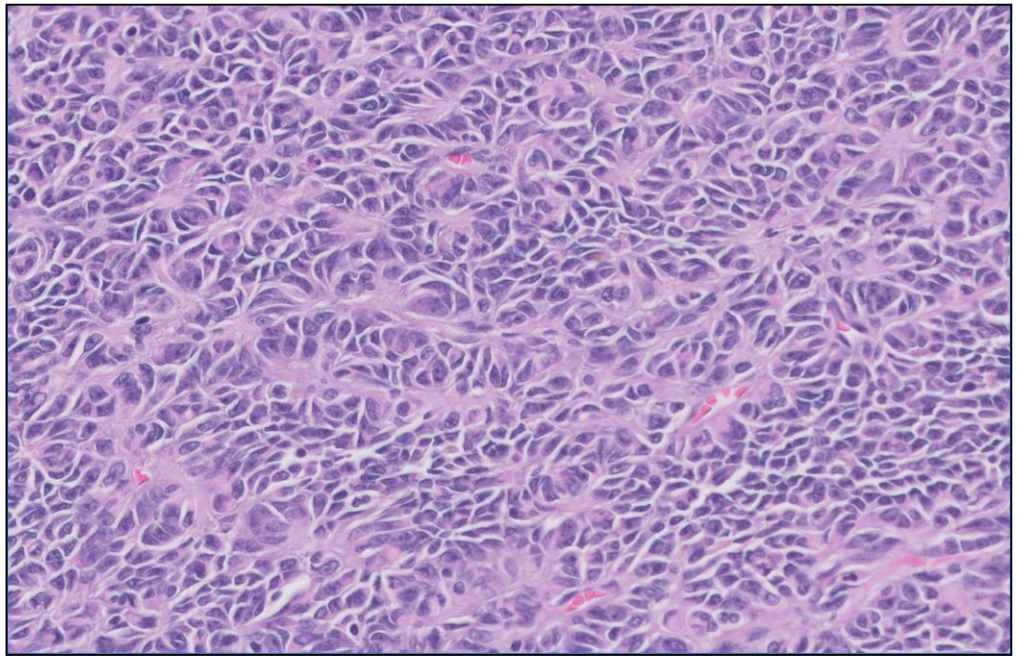

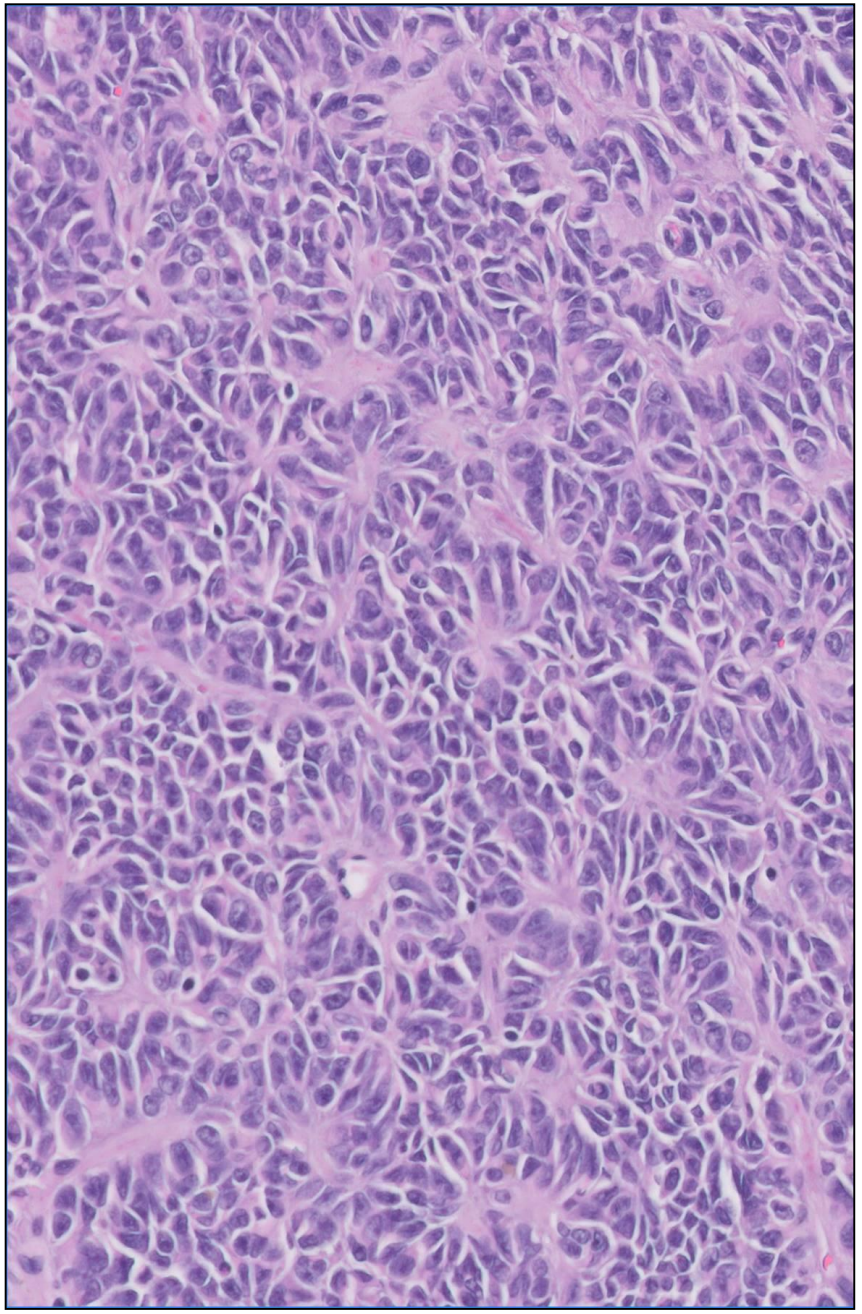

Infiltrating cords, angulated nuclei and eosinophilic cytoplasm

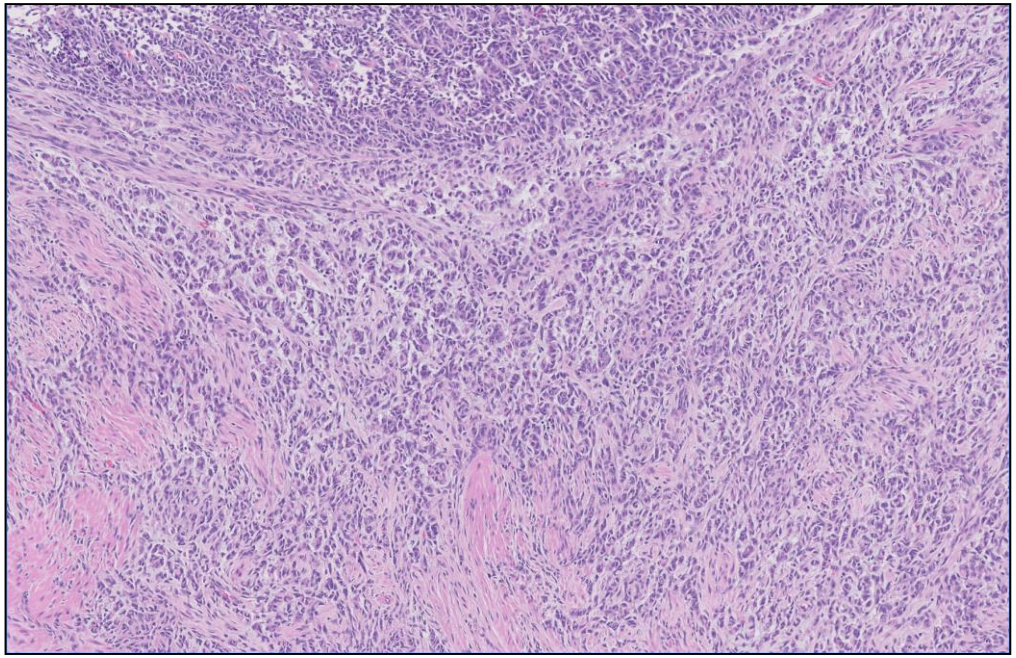

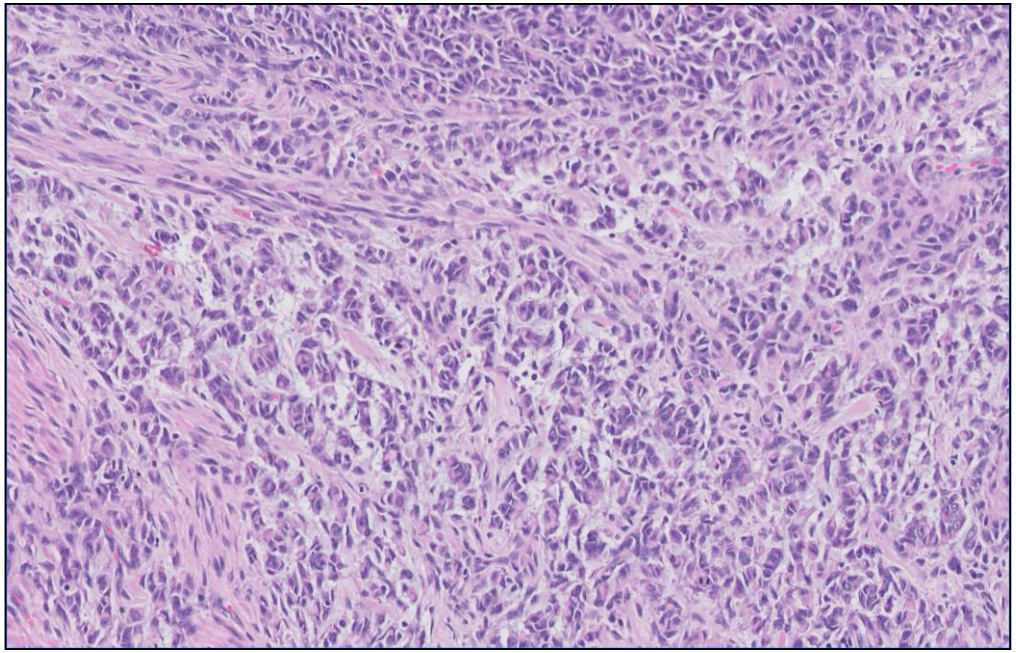

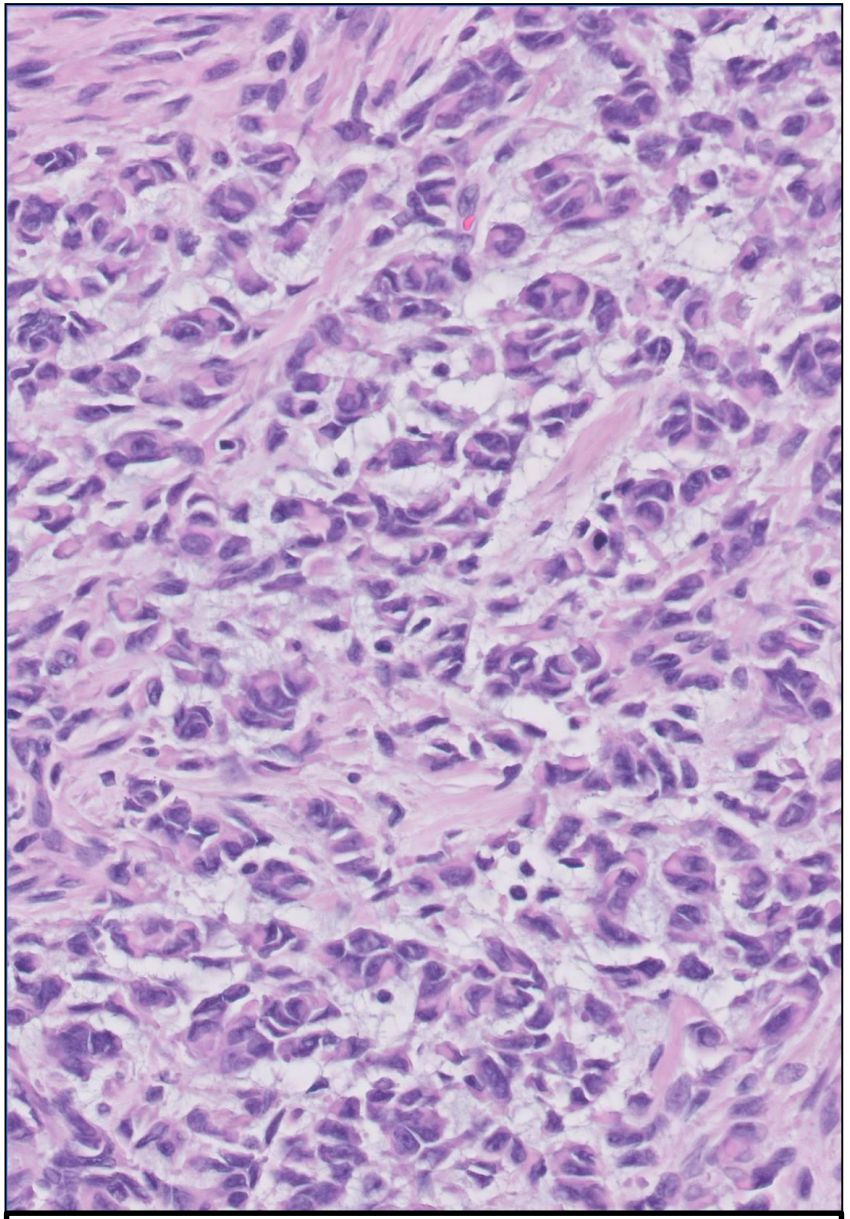

focal rhabdoid features

Oval to round, eccentrically positioned nuclei, low mitotic activity

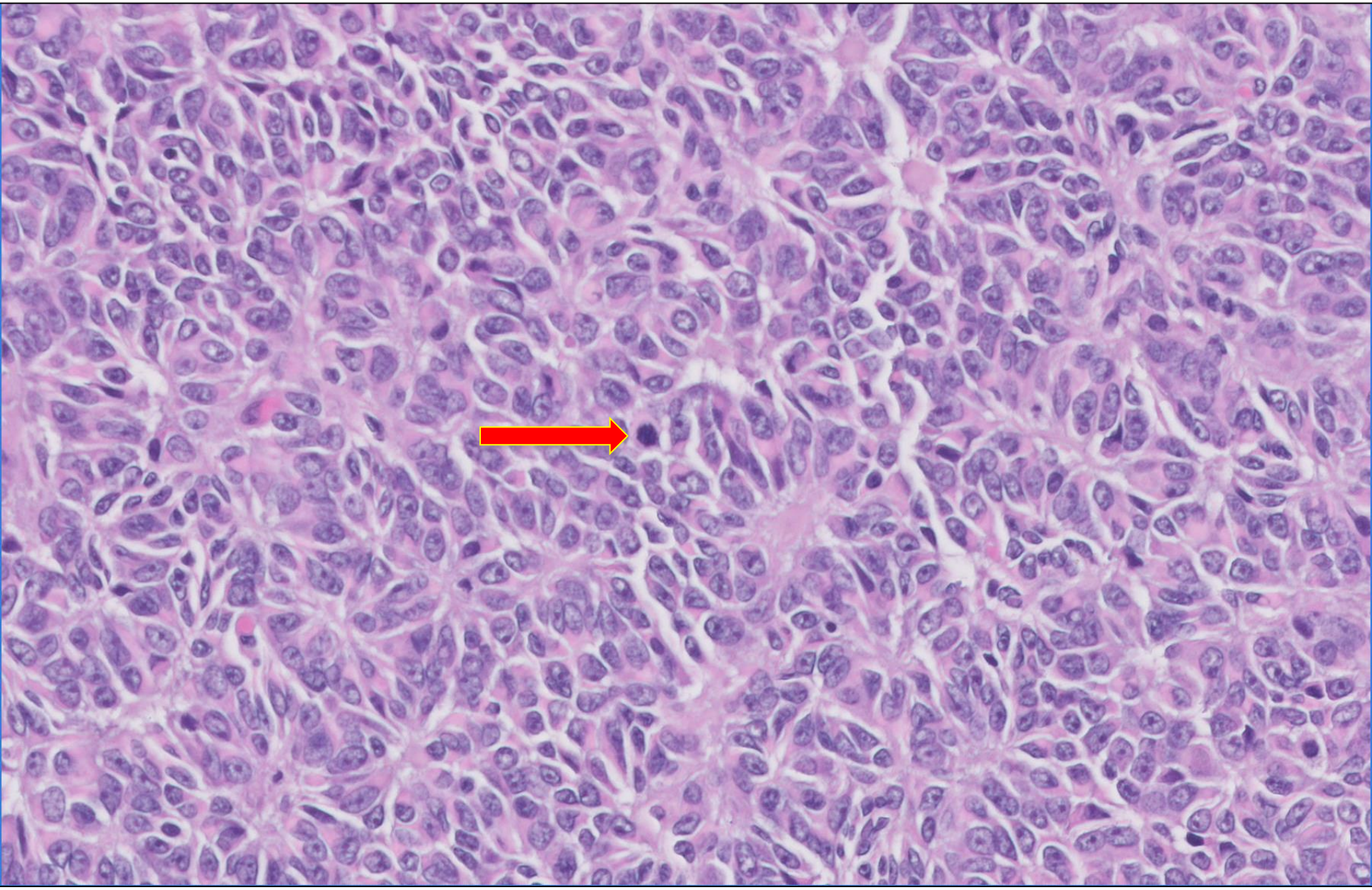

Case 5
differential diagnosis

- Endometrial stromal sarcoma with sex-cord-like features
- Endometrioid carcinoma with sex-cord-like features
- High-grade endometrioid carcinoma with neuroendocrine differentiation
- Metastatic neuroendocrine carcinoma
- PNET/Ewing sarcoma
- Uterine tumor resembling ovarian sex-cord tumor (UTROSCT)

Case 5
immunohistochemical study

- Positive: ER, PR, Vimentin, Cam5.2 (focal), SMA (focal), WT1, Inhibin (focal), Calretinin (focal)
- Negative: CD10, CK7, PAX8, EMA, chromogranin, synaptophysin, desmin, Melan-A, SOX10, S100, CD99

Excluded: endometrial stromal sarcoma, carcinoma, neuroendocrine tumor, PNET/Ewing sarcoma

Case 5

immunohistochemical study

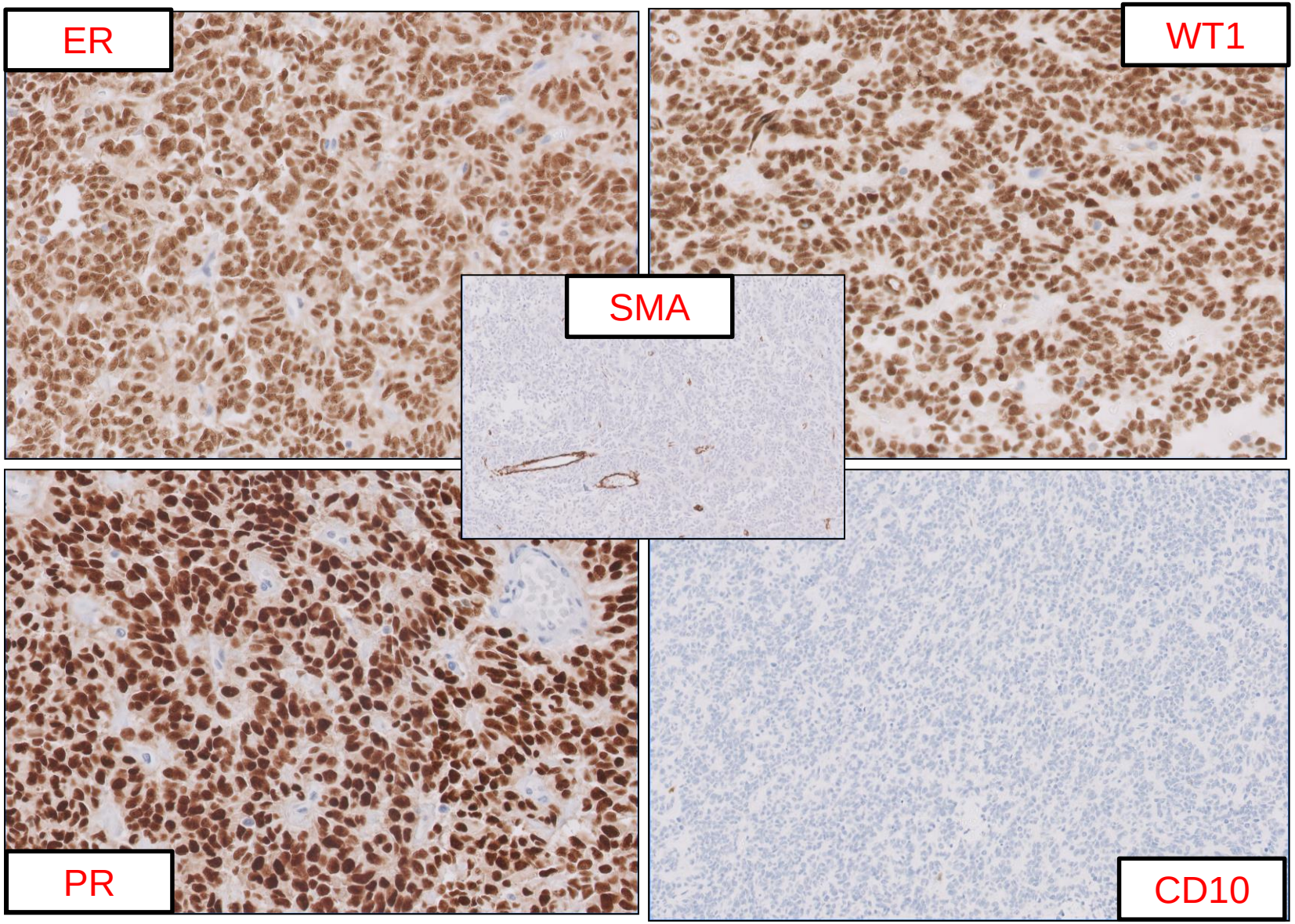

Case 5
immunohistochemical study

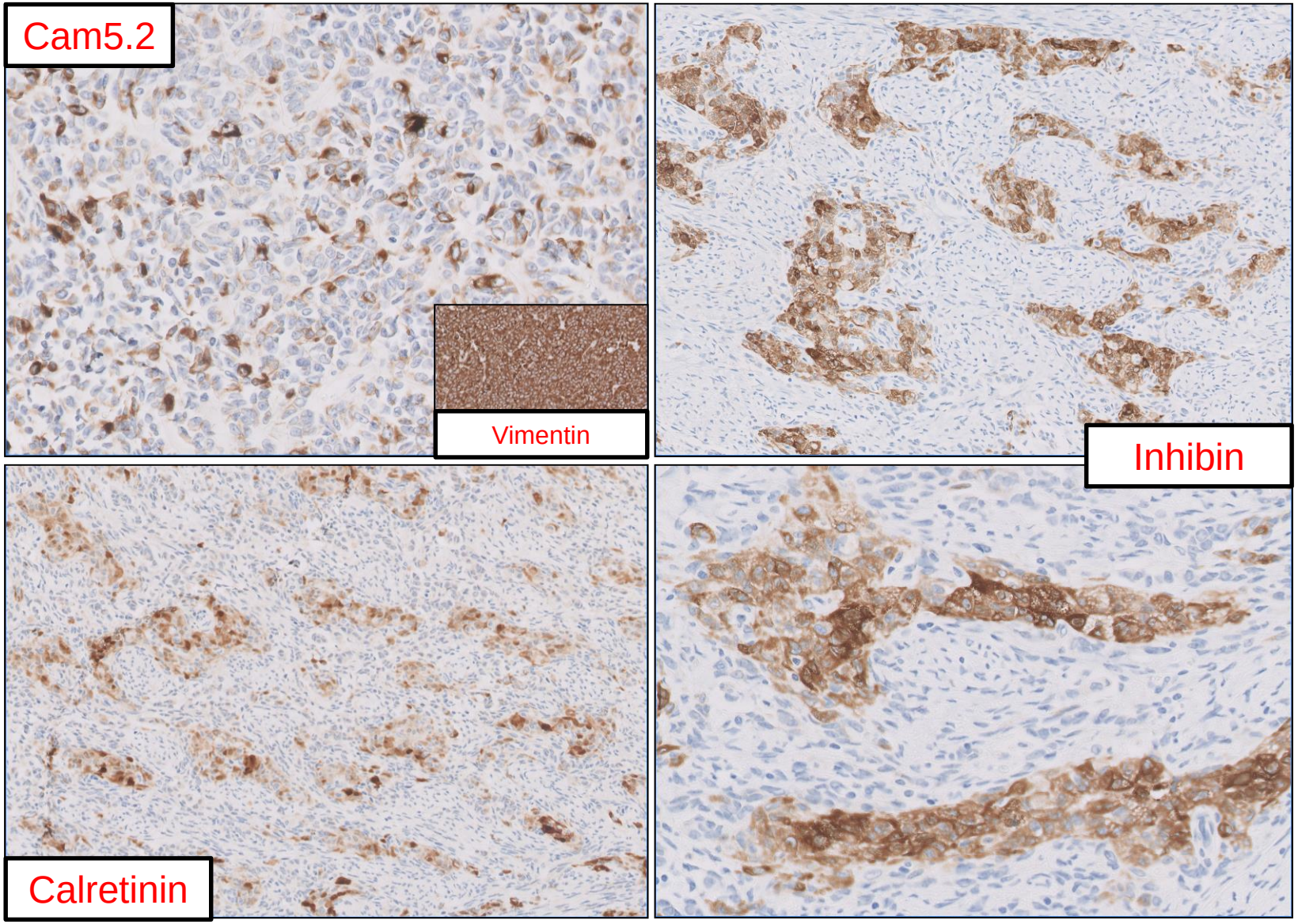

Case 5
diagnosis

Uterine tumor resembling ovarian sex-cord tumor

(UTROSCT)

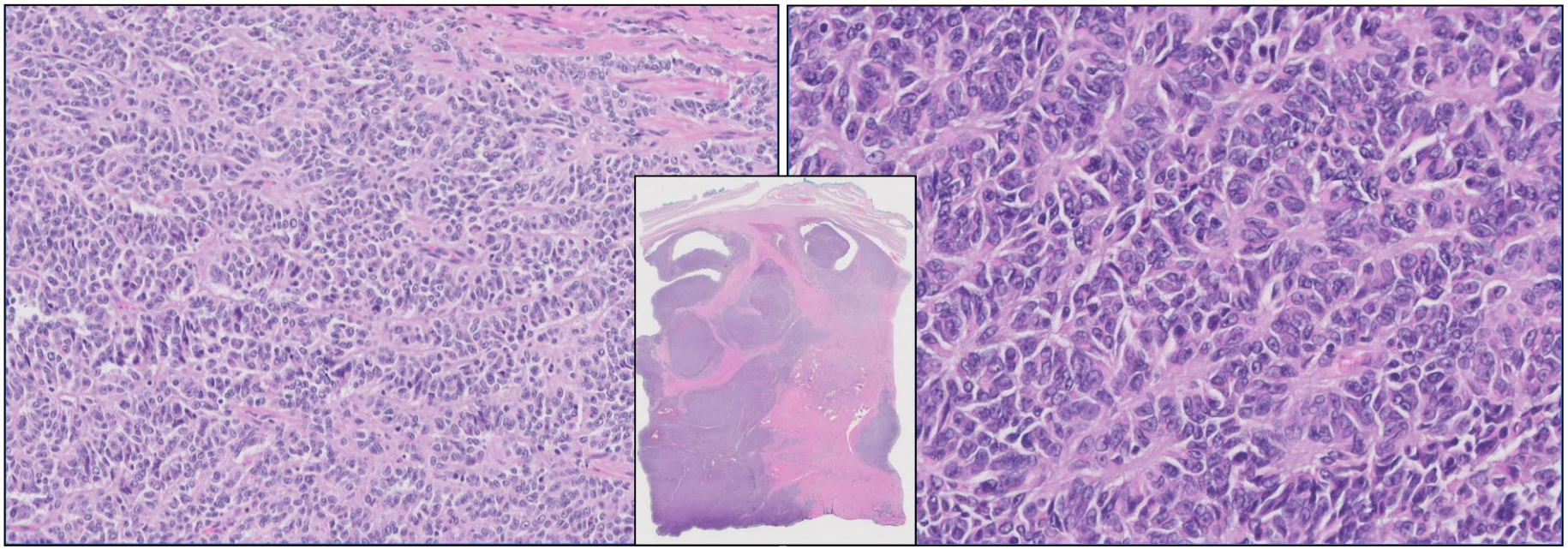

UTROSCT

- First described by Clement and Scully in 1976
  – group I tumors, 6 cases, composed of areas of typical endometrial stromal tumor with focal sex cord-like elements; behavior similar to low-grade endometrial stromal sarcoma
  – group II tumors, 8 cases, single, well-circumscribed: predominantly or exclusively composed of sex cord-like elements – behavior usually benign
- Uncertain histogenesis – IHC: polyphenotypic – stromal, epithelial, smooth muscle and sex cord differentiation
- WHO 2014: the term UTROSCT is reserved for group II tumors and included in the category of endometrial stromal and related neoplasms
  – behavior: uncertain or of low malignant potential, however!

UTROSCT

Does immunoreactivity with sex cord markers correlate with molecular data?

International Journal of Gynecological Pathology
35:301–308, Lippincott Williams & Wilkins, Baltimore
© 2015 International Society of Gynecological Pathologists

Original Article

Uterine Tumor Resembling Ovarian Sex Cord Tumor (UTROSCT) Commonly Exhibits Positivity With Sex Cord Markers FOXL2 and SF-1 but Lacks *FOXL2* and *DICER1* Mutations

Sabrina Croce, M.D., Leanne de Kock, B.Tech., Talia Boshari, B.Sc., Isabelle Hostein, Ph.D., Valerie Velasco, B.Sc., William D. Foulkes, Ph.D., and W. Glenn McCluggage, F.R.C.Path

Summary: Uterine tumor resembling ovarian sex cord tumor (UTROSCT) is a rare neoplasm which morphologically and immunohistochemically exhibits overlap with an ovarian sex cord tumor. Although many of these neoplasms are positive with markers of ovarian sex cord-stromal tumors, staining is often limited and the pathogenesis of UTROSCT is unknown. To further explore the sex cord lineage of UTROSCT, we studied 19 of these neoplasms and examined the expression of 2 recently described markers of ovarian sex cord-stromal tumors, FOXL2, and steroidogenic factor-1. We also undertook *FOXL2* and *DICER1* mutation analysis in these cases; a somatic missense mutation in codon C134W (402C→G) of *FOXL2* gene has been demonstrated in the vast majority (>95%) of ovarian adult granulosa cell tumors and somatic *DICER1* mutations are found in approximately 60% of ovarian Sertoli-Leydig cell tumors. Ten of 19 cases (53%) exhibited nuclear immunoreactivity with FOXL2 and 11 of 19 (58%) exhibited nuclear staining with steroidogenic factor-1. Neither *FOXL2* nor *DICER1* mutations were identified in any case where there was sufficient tumor tissue for analysis (18 and 9 cases, respectively). Despite exhibiting an immunophenotype characteristic of a sex cord-stromal tumor, mutations in *FOXL2* and *DICER1*, the 2 most common mutations hitherto reported in ovarian sex cord-stromal tumors, are not a feature of UTROSCT. **Key Words:** Uterus—Uterine tumor resembling ovarian sex cord tumor (UTROSCT)—FOXL2—DICER1—SF-1.

ORIGINAL ARTICLE

FOXL2 Mutation is Absent in Uterine Tumors Resembling Ovarian Sex Cord Tumors

Sarah Chiang, MD, Paul N. Staats, MD,† Janine Senz, BSc,‡,§ Friedrich Kommoss, MD,‖ Michele De Nictolis, MD,¶ David G. Huntsman, MD,‡,§ C. Blake Gilks, MD,‡,# and Esther Oliva, MD***

Abstract: Uterine tumors resembling ovarian sex cord tumors (UTROSCTs) are rare uterine neoplasms characterized by pure or predominant epithelial-like patterns that share morphologic, immunohistochemical, and ultrastructural features with ovarian sex cord tumors. FOXL2 immunoexpression has recently been found in sex cord stromal tumors of the ovary, including granulosa cell tumors, Sertoli-Leydig cell tumors, thecomas, and fibromas, but mutations have been identified mostly in adult granulosa cell tumors. In this study, we investigated *FOXL2* mutation status and protein expression in UTROSCTs. Mutational analysis using a TaqMan real-time polymerase chain reaction–based allelic discrimination assay was performed on formalin-fixed, paraffin-embedded tissue from 15 UTROSCTs. *FOXL2* mutation was absent in all tumors. FOXL2 immunoexpression was tested in all 15 tumors. Intensity of staining was scored as weak, moderate, or strong. Percentage of tumor cells with nuclear staining was recorded as follows: 0 (negative); 1+ (1% to 25%); 2+ (26% to 50%); 3+ (51% to 75%); and 4+ (76% to 100%). Nuclear expression of FOXL2 was present in 6 of 15 (40%) UTROSCTs. One tumor demonstrated strong 4+ staining. Moderate expression was seen in 3 cases, including 2 and 1 showing 2+ and 1+ staining, respectively. Weak expression was observed in 2 tumors demonstrating 3+ and 1+ staining. Although UTROSCTs show overlapping morphologic, immunohistochemical, and ultrastructural features with sex cord stromal tumors of the ovary, they do not harbor *FOXL2* mutation despite focal immunoreactivity in a subset of these tumors.

Key Words: *FOXL2*, uterine tumor resembling ovarian sex cord tumor, sex cord stromal tumor

(*Am J Surg Pathol* 2015;39:618–623)

Uterine tumors resembling ovarian sex cord tumors (UTROSCTs) are rare uterine neoplasms that show predominant or exclusive morphologic patterns of sex cord elements.[1] These neoplasms typically occur in premenopausal or menopausal women in the setting of abnormal vaginal bleeding, an enlarged uterus, or as an incidental finding after hysterectomy. They were originally described as a distinct clinicopathologic entity in 1976 by Clement and Scully[2] who divided uterine neoplasms with sex cord–like differentiation into 2 categories on the basis of morphologic features. In their study, group I tumors were defined as otherwise conventional endometrial stromal tumors (ESTs) with foci of sex cord–like elements comprising <50% of the neoplasm.[2] In contrast, group II tumors were composed of either predominant or exclusive sex cord–like elements including cords, nests, trabeculae, tubules, luteinized cells with eosinophilic or foamy cytoplasm, and retiform structures.[2] Tumors in this latter category were descriptively termed UTROSCTs because of their histologic resemblance to sex cord stromal neoplasms of the ovary, particularly granulosa and Sertoli cell tumors.[2]

Although group I neoplasms are now considered a morphologic variant of ESTs for which their prognosis depends on tumor circumscription, the pathogenesis and clinical behavior of UTROSCTs remain uncertain. UTROSCTs typically exhibit a polyphenotypic immunohistochemical profile with frequent coexpression of stromal, sex cord, epithelial, and smooth muscle markers.[3–20] Ultrastructural studies have demonstrated focal epithelial and variable sex cord–like features, but no evidence of smooth muscle differentiation in these tumors.[10,21] Rare UTROSCTs in which cytogenetic analysis was per-

UTROSCT – molecular pathogenesis: recurrent *ESR1-NCOA3/2 or GREB1-NCOA2* gene fusion

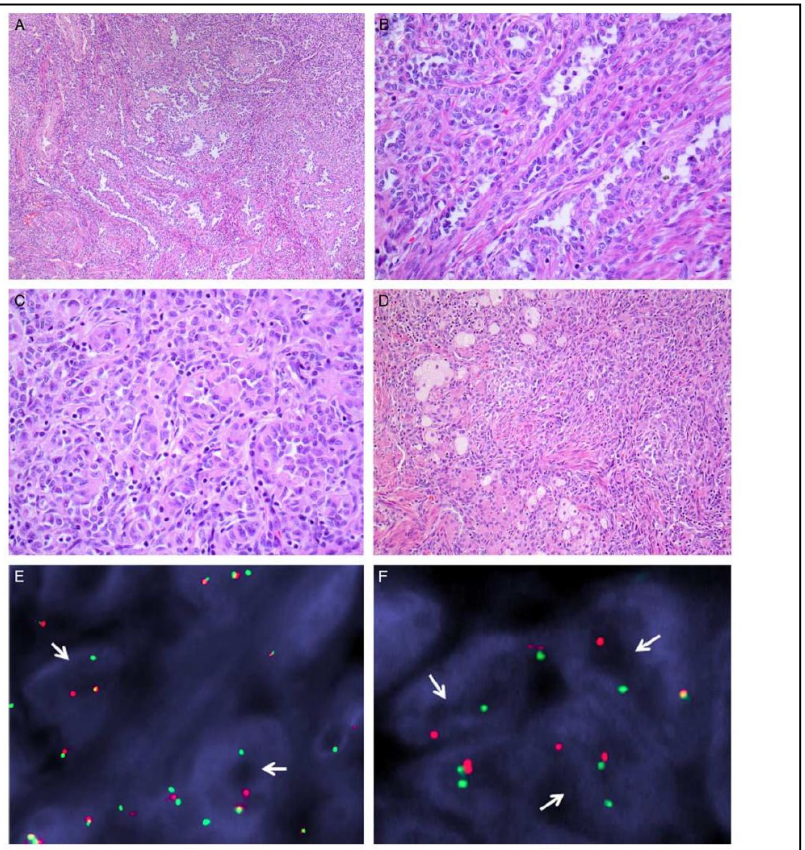

FIGURE 1. *ESR1-NCOA3* gene fusion in a myometrial UTROSCT (patient 1): (A) tumor centred in myometrium with a retiform pattern of epithelioid cells, and area of interstitial hyalinization. B, Tubules lined by epithelioid cells with scant cytoplasm. C, Nests of plump epithelioid cells with abundant eosinophilic cytoplasm. D, Aggregates of cells with foamy cytoplasm. FISH showing break-apart signals for (E) *ESR1*, and (F) *NCOA3* (white arrows: red, centromeric; green, telomeric).

t(6;20)(q25.1;q13.12)

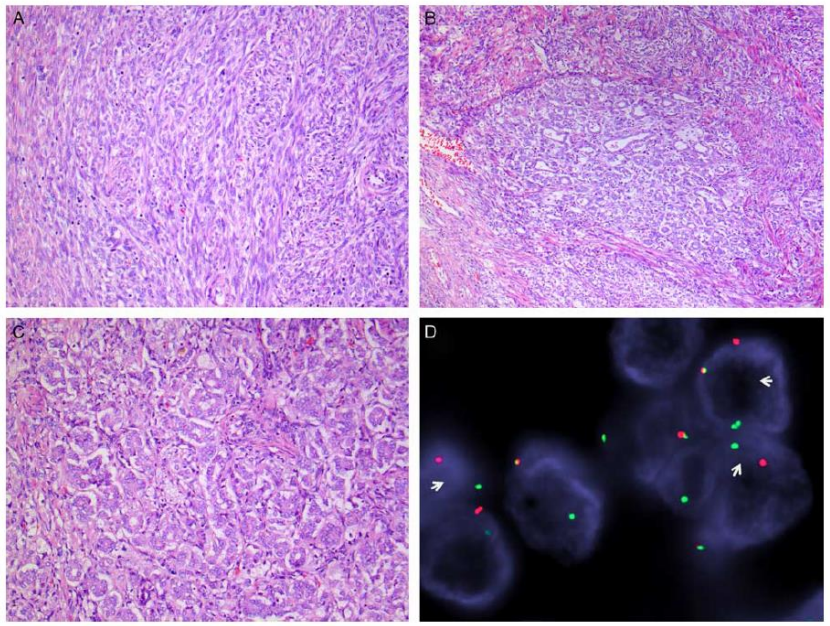

FIGURE 4. *GREB1-NCOA2* gene fusion in a myometrial UTROSCT (patient 4): (A) areas of plump spindle cells with a prominent fascicular-herringbone pattern reminiscent of monophasic synovial sarcoma. B, Spindle cell fascicles admixed with epithelioid cells with a tubular pattern. C, Epithelioid cells with tubular pattern. D, FISH showing break-apart signals for *NCOA2* (white arrows: red, centromeric; green, telomeric).

t(2;8)(p25.1;p13.3)

Uterine Tumor Resembling Ovarian Sex Cord Tumor

A Distinct Entity Characterized by Recurrent NCOA2/3 Gene Fusions

Brendan C. Dickson, MSc, MD,† Timothy J. Childs, MD,‡ Terrence J. Colgan, MD,*† Yun-Shao Sung, MSc,§ David Swanson, BSc,*† Lei Zhang, MD,§ and Cristina R. Antonescu, MD§*

(*Am J Surg Pathol* 2019;43:178–186)

Case 5 – Molecular study

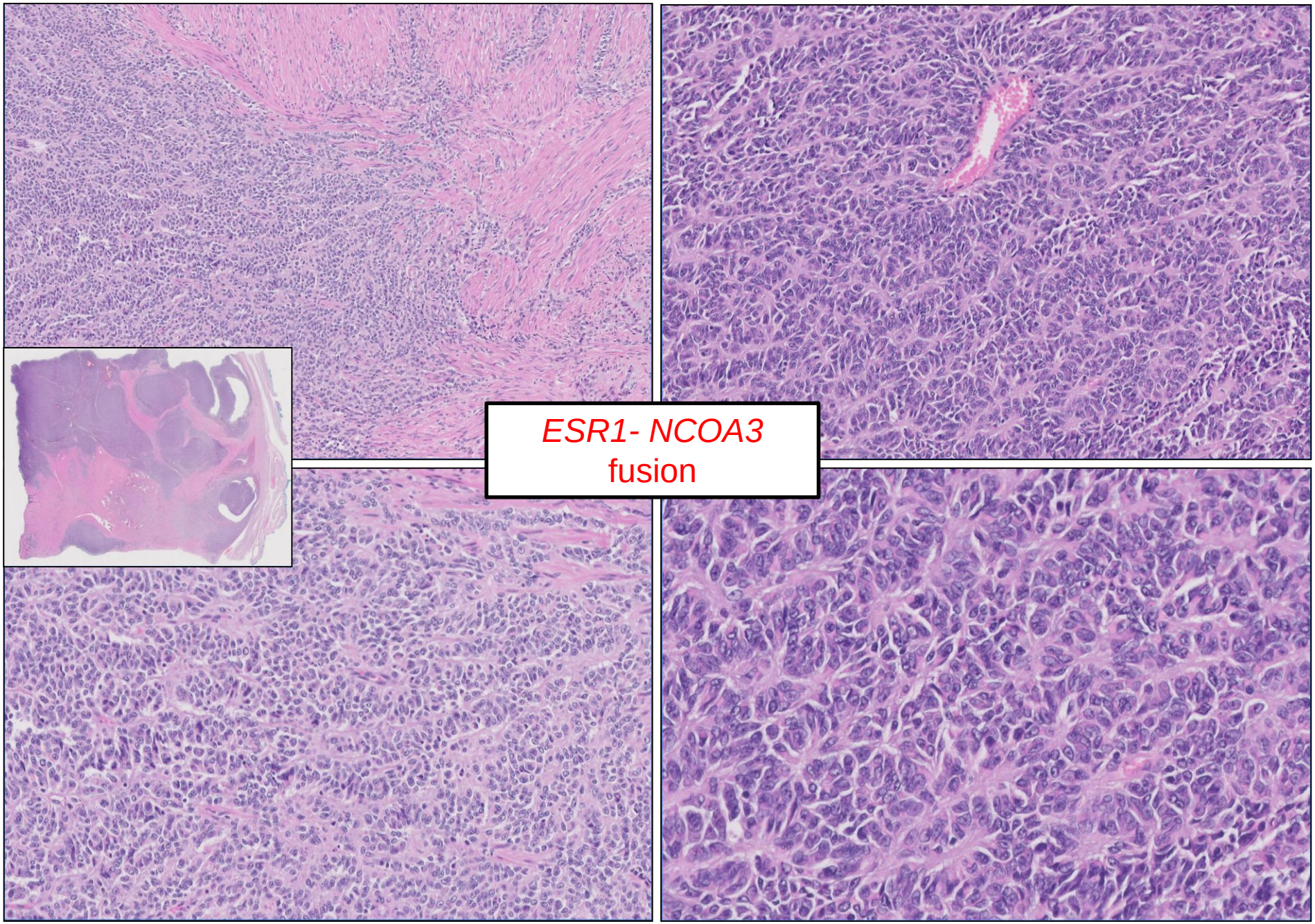

ESR1- NCOA3
fusion

Case 5
follow up

- No extrauterine spread
- Lymph nodes are free of tumor
- Patient is well, without tumor at 14 months follow-up

UTROSCT – Prognosis

CREB1 fusions suggest – aggressive behavior

Clinicopathologic Characterization of *GREB1*-rearranged Uterine Sarcomas With Variable Sex-Cord Differentiation

Cheng-Han Lee, MD, PhD, FRCPC, Yu-Chien Kao, MD,† Wan-Ru Lee, BS,‡ Yi-Wen Hsiao, MS,§ Tzu-Pin Lu, PhD,§ Chia-Ying Chu, MD,‖ Yi-Jia Lin, MD,¶ Hsuan-Ying Huang, MD,# Tsung-Han Hsieh, PhD,** Yun-Ru Liu, PhD,** Cher-Wei Liang, MD,†† Tom Wei-Wu Chen, MD,‡‡ Stephen Yip, MD, PhD, FRCPC,§§ Amy Lum, BS,§§ Kuan-Ting Kuo, MD,‡ Yung-Ming Jeng, MD, PhD,‡ Shih-Chen Yu, MS,# Yung-Chuan Chung, MS,‡ and Jen-Chieh Lee, MD, PhD‖,*

(*Am J Surg Pathol* 2019;43:928–942)

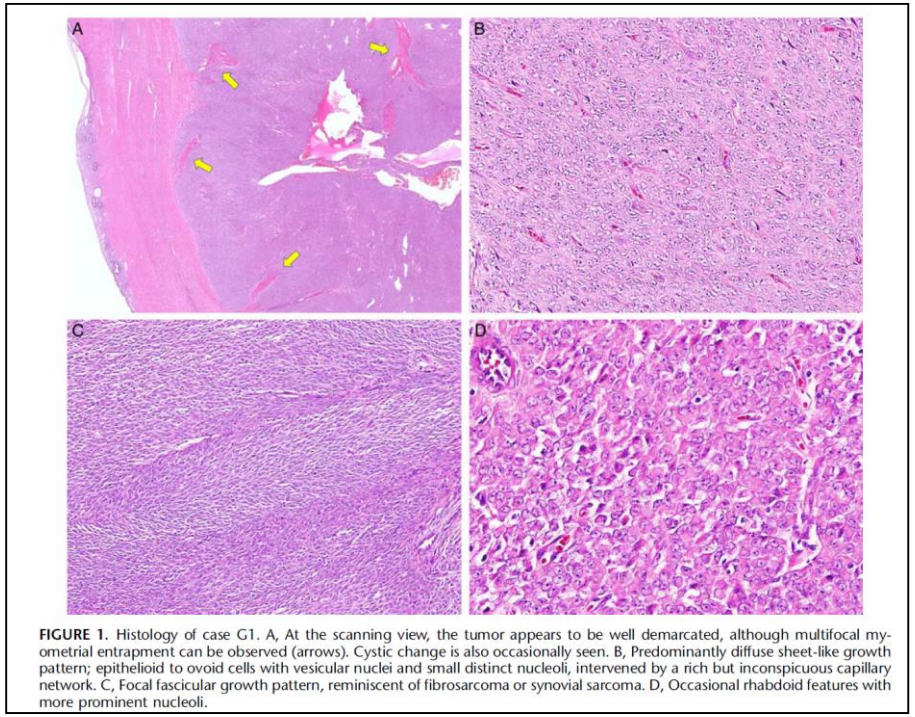

FIGURE 1. Histology of case G1. A, At the scanning view, the tumor appears to be well demarcated, although multifocal myometrial entrapment can be observed (arrows). Cystic change is also occasionally seen. B, Predominantly diffuse sheet-like growth pattern; epithelioid to ovoid cells with vesicular nuclei and small distinct nucleoli, intervened by a rich but inconspicuous capillary network. C, Focal fascicular growth pattern, reminiscent of fibrosarcoma or synovial sarcoma. D, Occasional rhabdoid features with more prominent nucleoli.

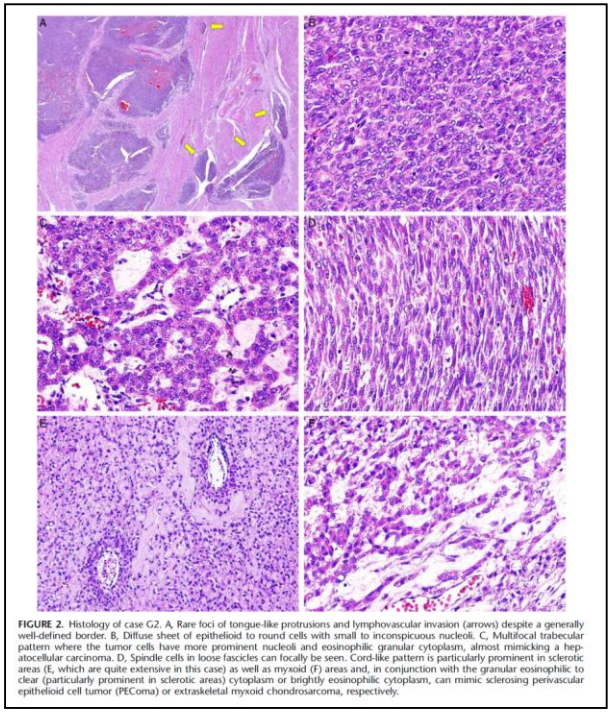

FIGURE 2. Histology of case G2. A, Rare foci of tongue-like protrusions and lymphovascular invasion (arrows) despite a generally well-defined border. B, Diffuse sheet of epithelioid to round cells with small to inconspicuous nucleoli. C, Multifocal trabecular pattern where the tumor cells have more prominent nucleoli and eosinophilic granular cytoplasm, almost mimicking a hepatocellular carcinoma. D, Spindle cells in loose fascicles can focally be seen. Cord-like pattern is particularly prominent in sclerotic areas (E, which are quite extensive in this case) as well as myxoid (F) areas and, in conjunction with the granular eosinophilic to clear (particularly prominent in sclerotic areas) cytoplasm or brightly eosinophilic cytoplasm, can mimic sclerosing perivascular epithelioid cell tumor (PEComa) or extraskeletal myxoid chondrosarcoma, respectively.

UTROSCT – Prognosis

GREB1-CTNNB1 fusion

Croce S et al, Genes Chromosomes Cancers 2019; 58:155-163

- 70-year-old female with a 10 cm myometrial mass
- Developed extrauterine metastasis 17 months later
- Novel translocation t(2;3)(p25;p22) involving the *GREB*1 and *CTNNB1* in a UTROSCT described
- Nuclear expression of β-catenin
- Constitutive activation of Wnt/β-catenin signaling pathway with major oncogenic effect
- Significance: β-catenin could be a possible therapeutic target in this tumor
- 11 additional UTROSCTs of the study showed no CTNNB1 fusion transcript or nuclear β-catenin expression

Fallopian tube counterpart of UTROSCT

Moore M et al. Histopathology 2018; 73:175-178

A case at University of Chicago with

GREB1-CTNNB1 fusion

- 58-year-old female with a 28 cm pelvic mass attached to the right fallopian tube; normal ovaries and uterus
- Spindle and epithelioid neoplasm with sex-cord like areas
- 2 mitotic figures/10HPFs, areas of necrosis
- IHC: positive for ER, PR, WT1, keratin, vimentin and focally for calretinin, SMA, FOXL2 (no FOXL2 mutation)
- Absence of rearrangements of *JAZF1*, *PHF1* and *YWHAE*


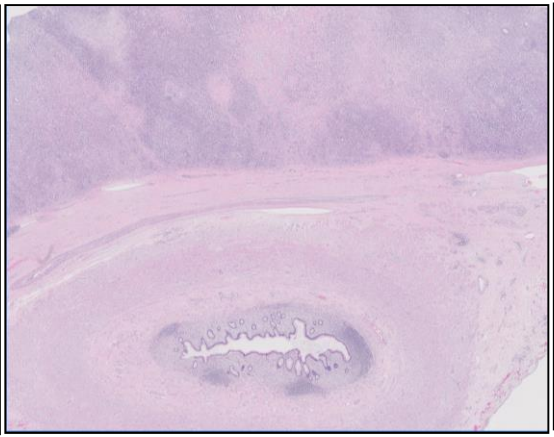
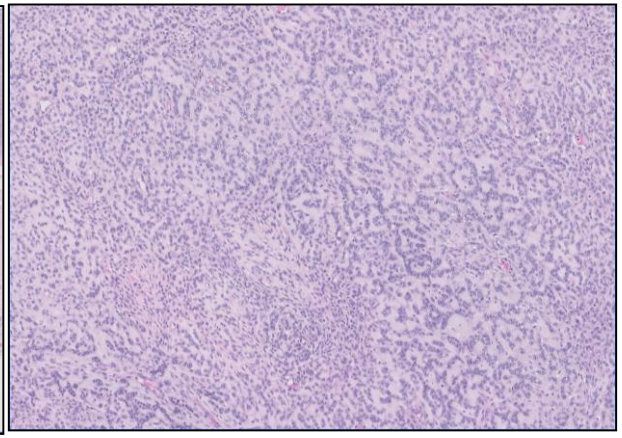

Fallopian tube counterpart of UTROSCT

GREB1-CTNNB1 fusion

University of Chicago

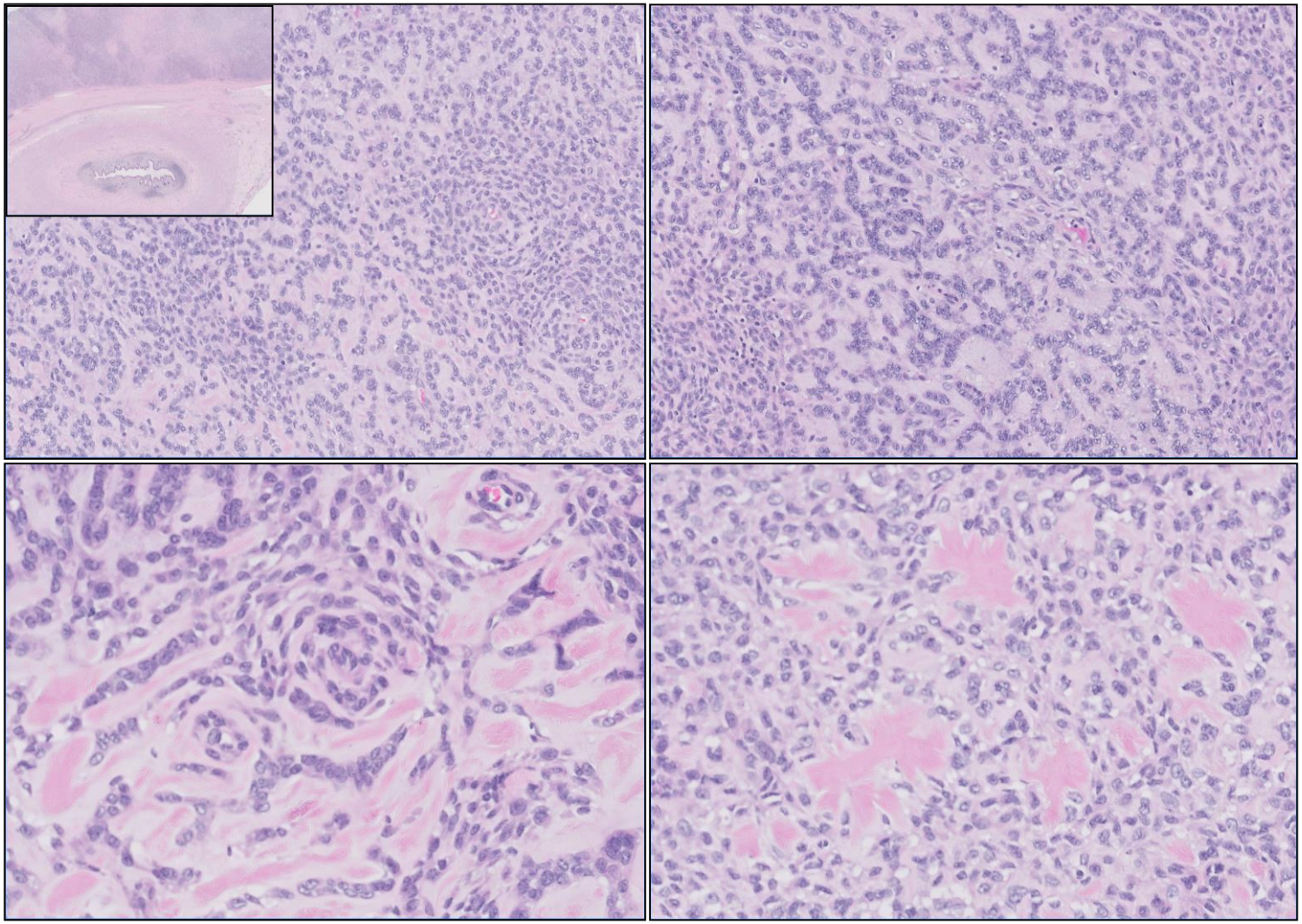

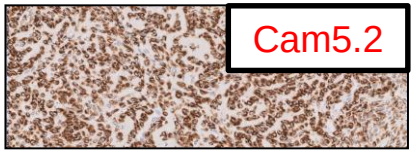

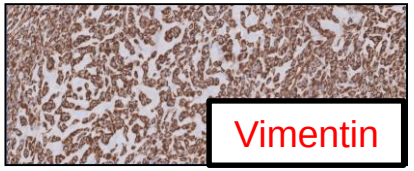



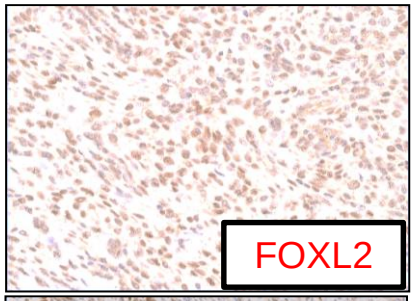

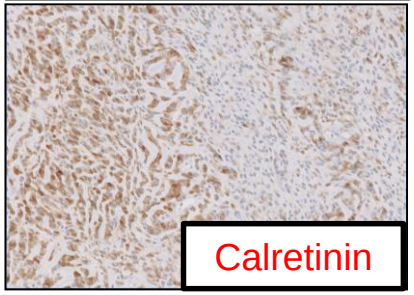

UTROSCT – Prognosis

report of a large series with follow-up

Moore M and McCluggage WG, Histopathology 2017; 71:751-759

- 34 cases
- Mean follow up: 39 months (6 – 135 months)
- Eight of 34 patients (23.5%) developed extrauterine metastasis to a variety of sites (peritoneum, ovary, lymph nodes, bone, liver and lung)
- Three patients (8.8%) died of tumor
- Malignant behavior: older patients, larger tumors, necrosis, cervical involvement, nuclear atypia, increased mitotic activity
- Conclusion: UTROSCT not uncommonly can have an aggressive clinical course with extrauterine metastases
- UTROSCTs are best regarded as potentially malignant tumors

UTROSCT – Prognosis

report of a large series with follow-up

Moore M and McCluggage WG, Histopathology 2017; 71:751-759

- Limitations of this study:
  - No detailed examination of the different cytological and architectural features which may occur in UTROSCT and investigate these with regard to outcome
  - No molecular investigation to identify *ESR1* versus *GREB1* fusions and determine any difference in prognosis (molecular study on this series, however, currently in progress)
- Therefore, the conclusion, that “UTROSCTs are best regarded as potentially malignant tumors” should be revisited after the completion of the molecular study

Previous endometrial biopsy:

UTROSCT was not recognized

An unusual variant of high-grade endometrioid carcinoma was favored, by expert pathologist

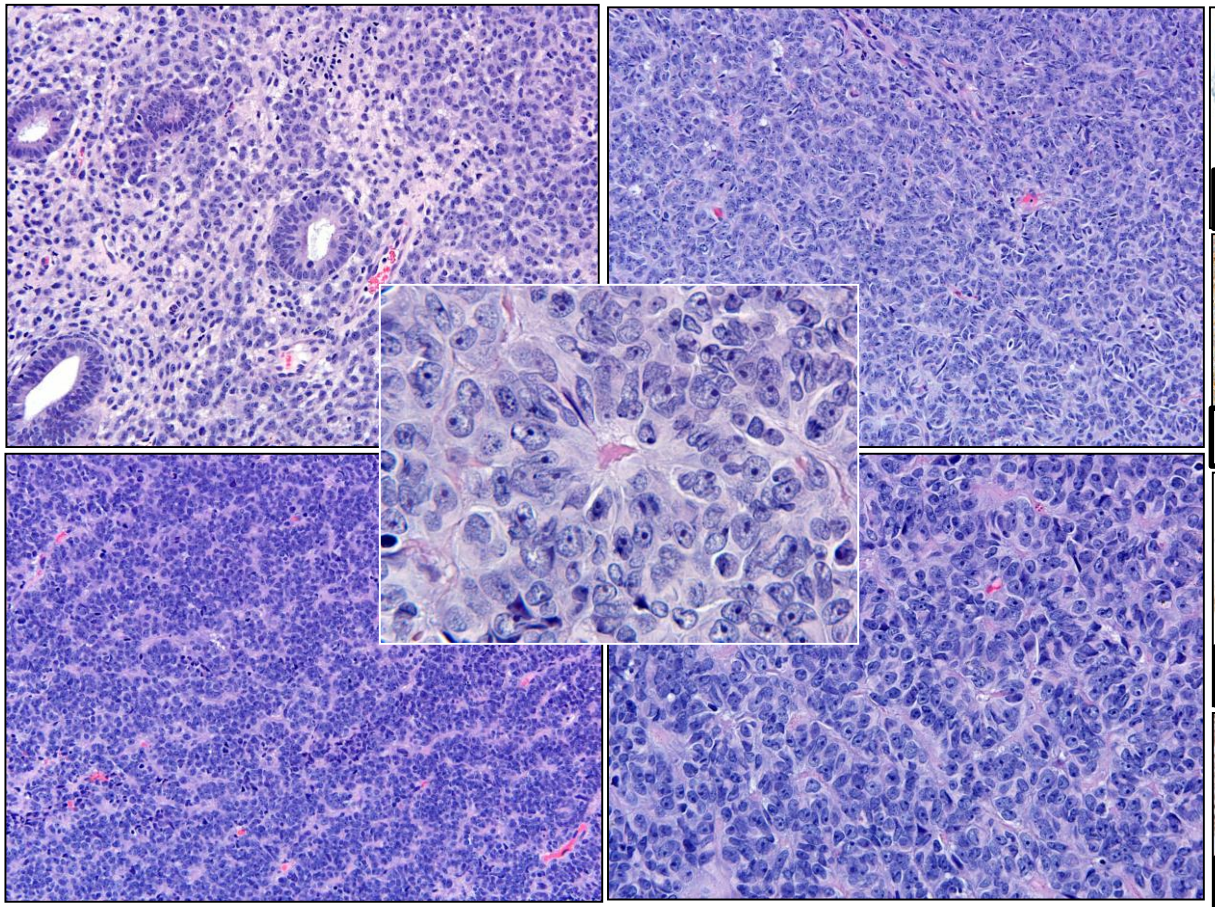

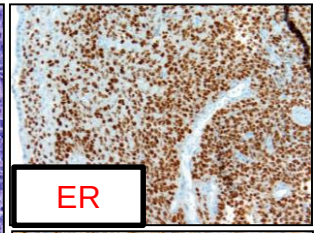

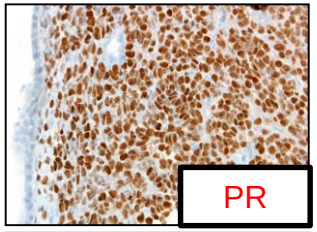

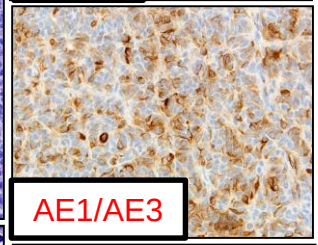

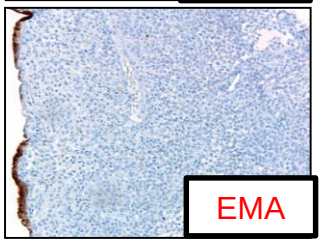

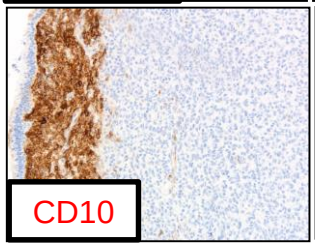

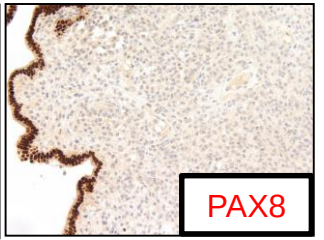

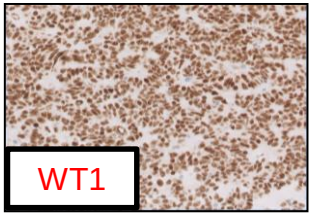

Also negative:
p53, p16, inhibin, calretinin, SMA, Desmin, synaptophysin

Previous cervical Pap test (ThinPrep) reviewed

UTROSC was not recognized…

Malignant neoplasm, favor an unusual form of adenocarcinoma

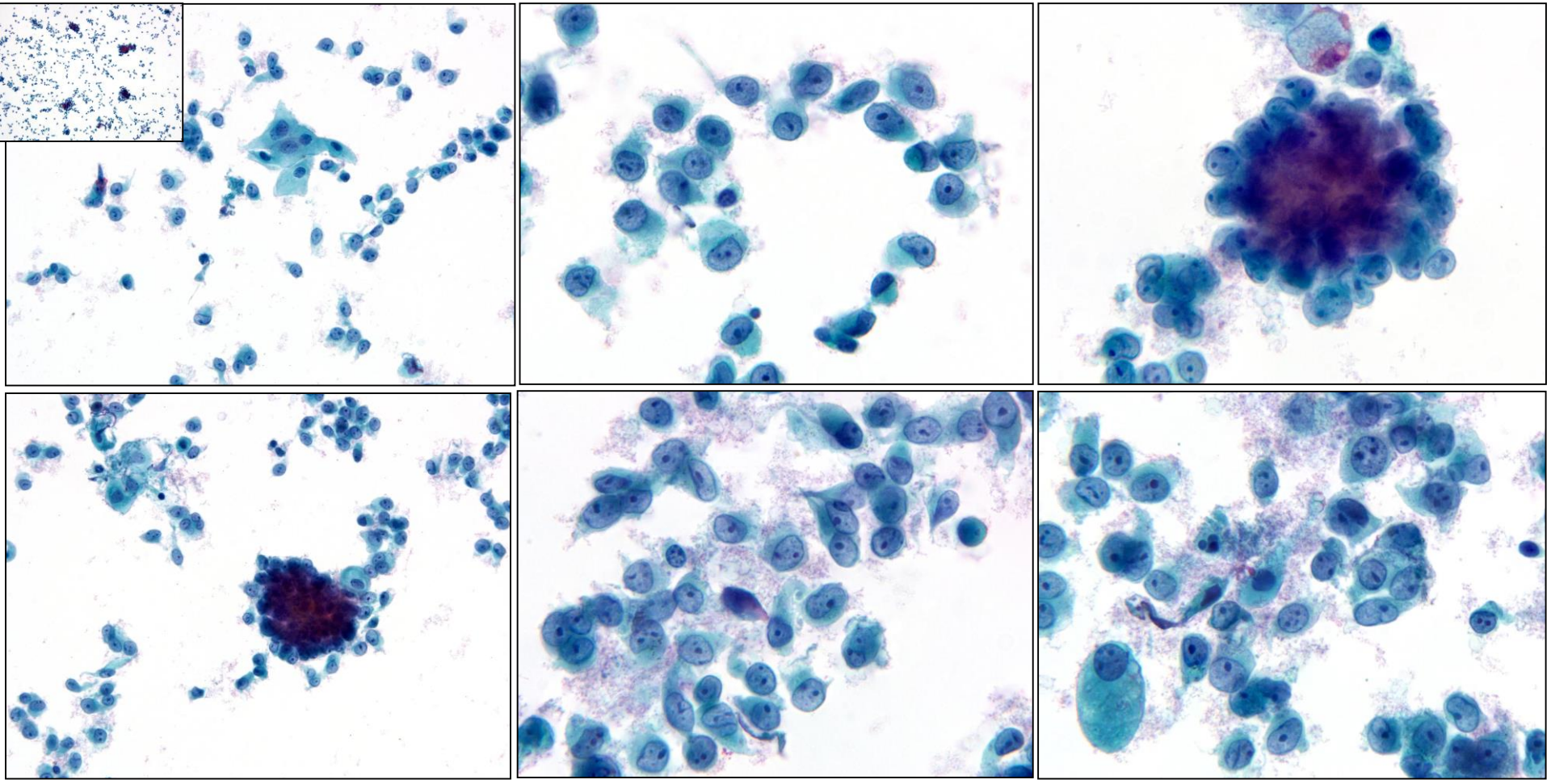

Case 5
concluding remarks

- Uterine tumor resembling ovarian sex cord tumor (UTROSCT) is a rare and distinctive neoplasm of uncertain histogenesis
- Morphologically resembles sex-cord tumors of the ovary and possesses polyphenotypic immunophenotype
- The molecular pathogenesis has yet to be elucidated, but current evidence suggests recurrent *NCOA2/3* gene fusions (with *ESR1* or possibly *GREB1* partners)
- UTROSCT is molecularly distinct from from both endometrial stromal sarcoma (*JAZF1-SUZ12* and *YWHAE-FAM22*) and sex-cord tumors (*FOXL2* or *DICER1*) of the ovary

Case 5
concluding remarks cont.

- UTROSCTs with *ESR1* rearrangement usually behave in a benign fashion
- Large UTROSCTs with increased mitotic activity, significant nuclear atypia, areas of spindling/fasciculated pattern, focal necrosis, lymphovascular invasion in postmenopausal women likely to have *GREB1* rearrangement and aggressive behavior
- Further molecular studies to underpin the clinicopathologic differences between *ESR1* and *GREB1* rearranged tumors are needed
- Diagnostically, UTROSCT is a known “pitfall” (often misdiagnosed)

Case 5
selected references

- Clement PB, Scully RE. Uterine tumors resembling ovarian sex-cord tumors. A clinicopathologic analysis of fourteen cases. Am J Clin Pathol 1976; 66:512-525
- Croce S et al. Uterine tumor resembling ovarian sex cord tumor (UTROSCT) commonly exhibits positivity with sex cord markers FOXL2 and SF-1 but lacks FOXL2 and DICER1 mutations. Int J Gynecol Pathol 2016; 35:301-308
- Oliva E. Int J Gynecol Pathol 2014; 33:374-384
- Moore M, McCluggage WG. Uterine tumor resembling ovarian sex cord tumor: first report of a large series with follow-up. Histopathology 2017; 71:751-759
- Dickson BC et al. Uterine tumor resembling ovarian sex cord tumor: a distinct entity characterized by recurrent NCOA2/3 gene fusions. Am J Surg Pathol 2018; 43: 178-186
- Dubruc E et al. Cytological features of uterine tumors resembling ovarian sex-cord tumors in liquid-based cervical cytology. Report of a unique and rare case. Diagn Cytopathol 2019; 47:603-607

Case 5
selected references

- Lee CH et al. Clinicopathologic characterization of *GREB1*-rearranged uterine sarcomas with variable sex-cord differentiation.
  Am J Surg Pathol 2019; 43:928-942
- Croce S et al. *GREB1-CTNNB1* fusion trnscript detected by RNA-sequencing in a uterine tumor resembling ovarian sex cord tumor (UTROSCT): a novel *CTNNB1* rearrangement.
  Genes Chromosomes Cancer 2019; 58:155-163

Case 6
clinical history

- 39-year-old female with history of vaginal strictures and primary infertility
- Biopsies of the vaginal stricture interpreted as clear cell carcinoma arising in vaginal adenosis at two independent institutions (no history of diethylstilbestrol exposure)
- Patient referred to University of Chicago for definitive treatment

Preoperative vaginal biopsy from stricture diagnosed as clear cell carcinoma

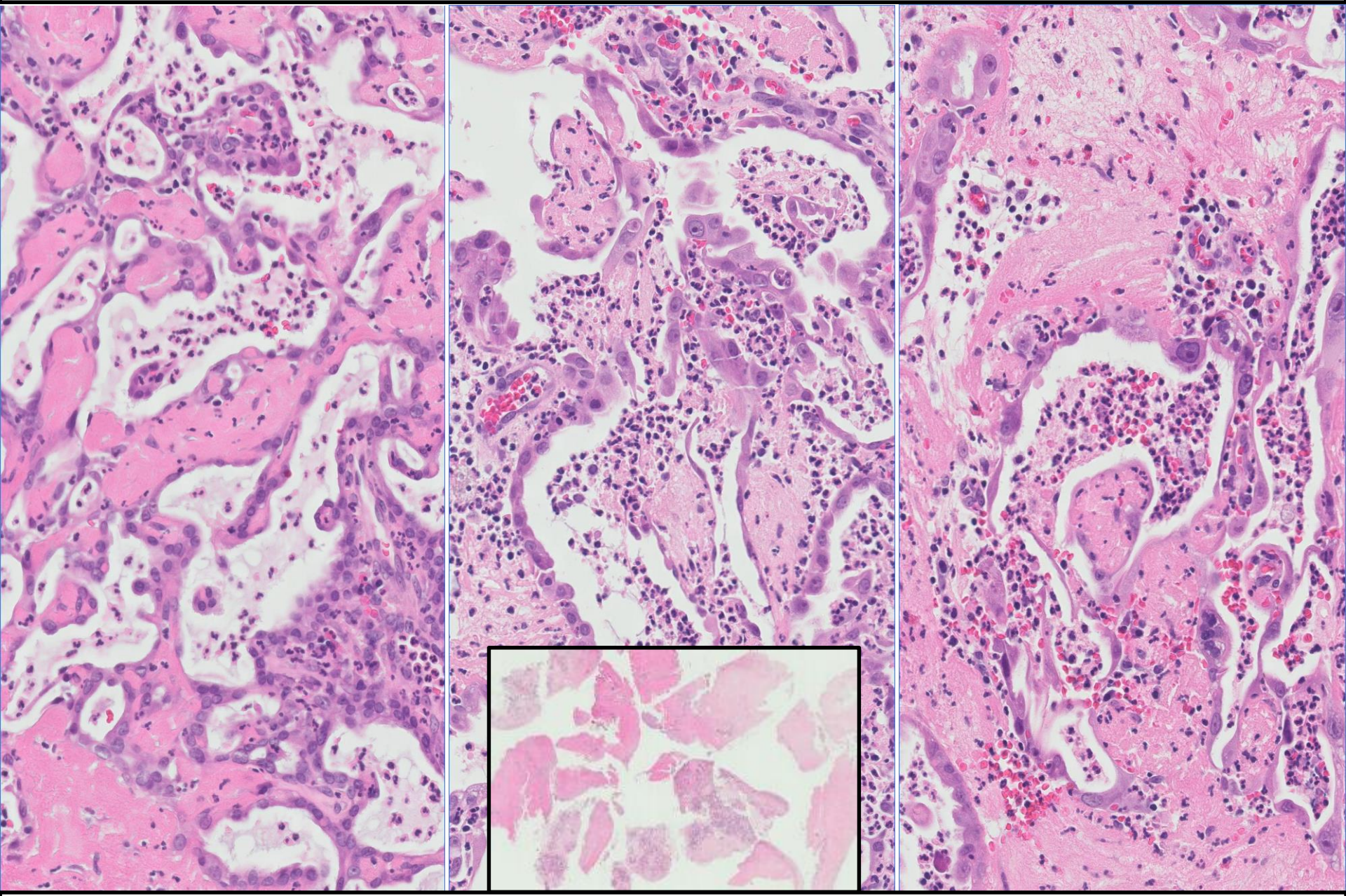

architecturally complex glands with focal atypia and numerous neutrophils

Preoperative vaginal biopsy from stricture diagnosed as clear cell carcinoma

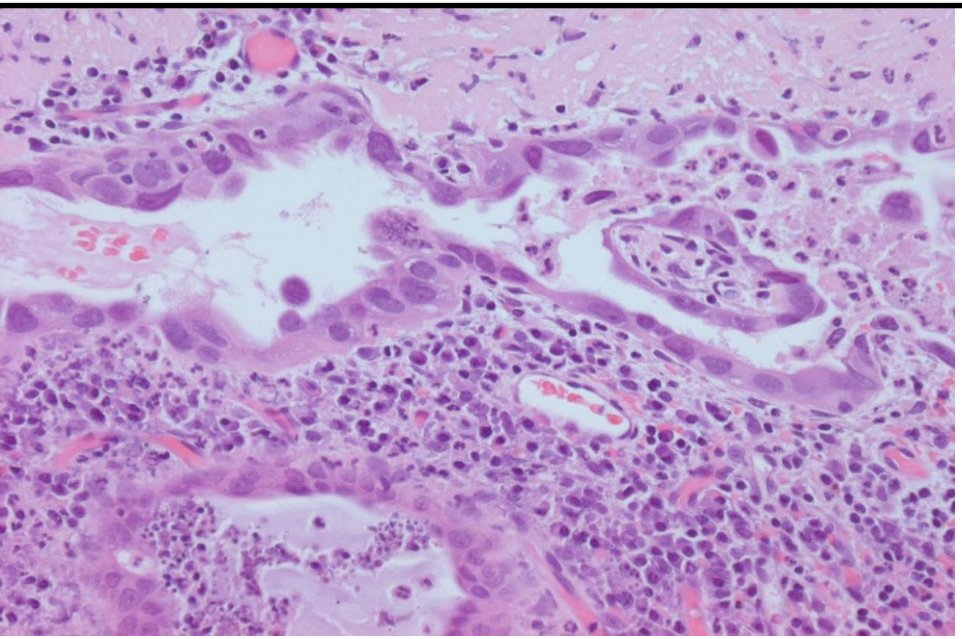

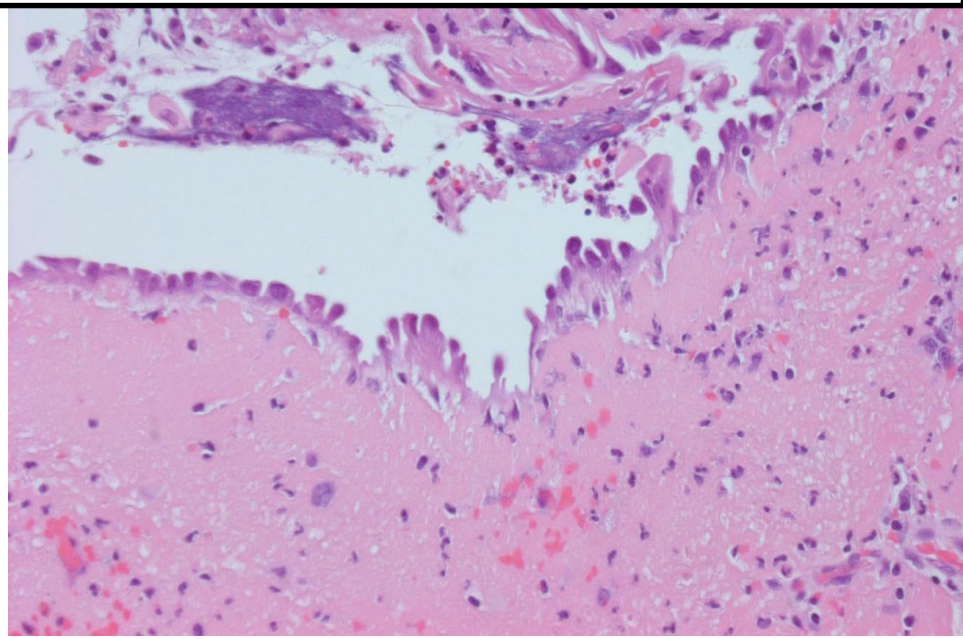

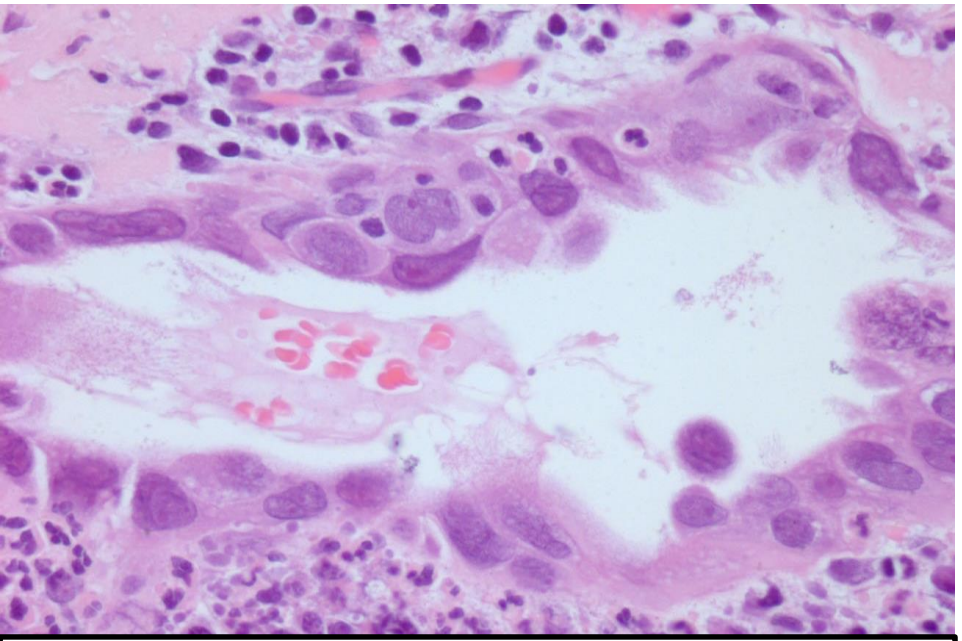

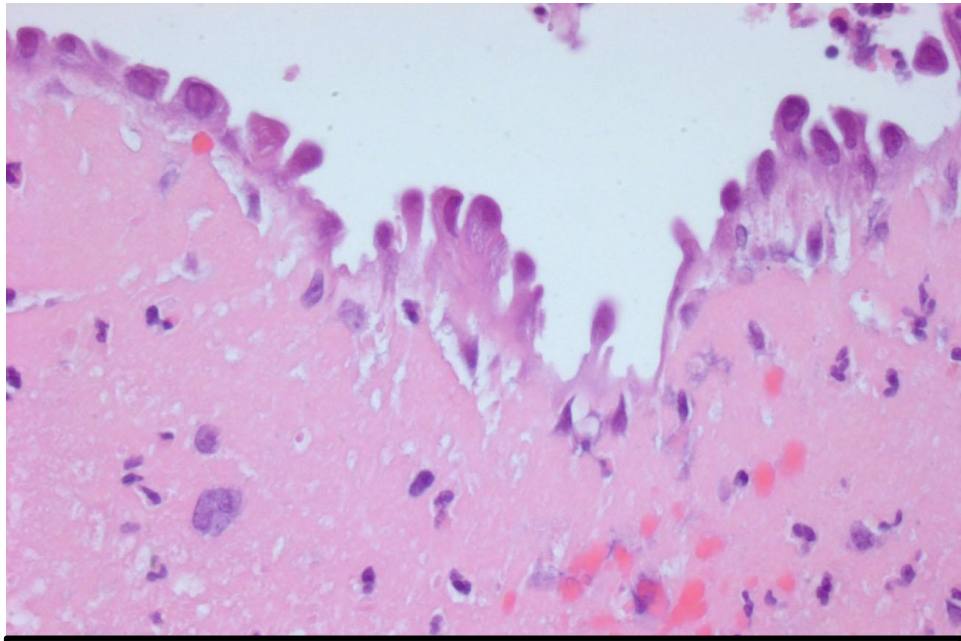

nuclear atypia, but no mitosis

focal hobnail features

Preoperative vaginal biopsy from stricture diagnosed as clear cell carcinoma

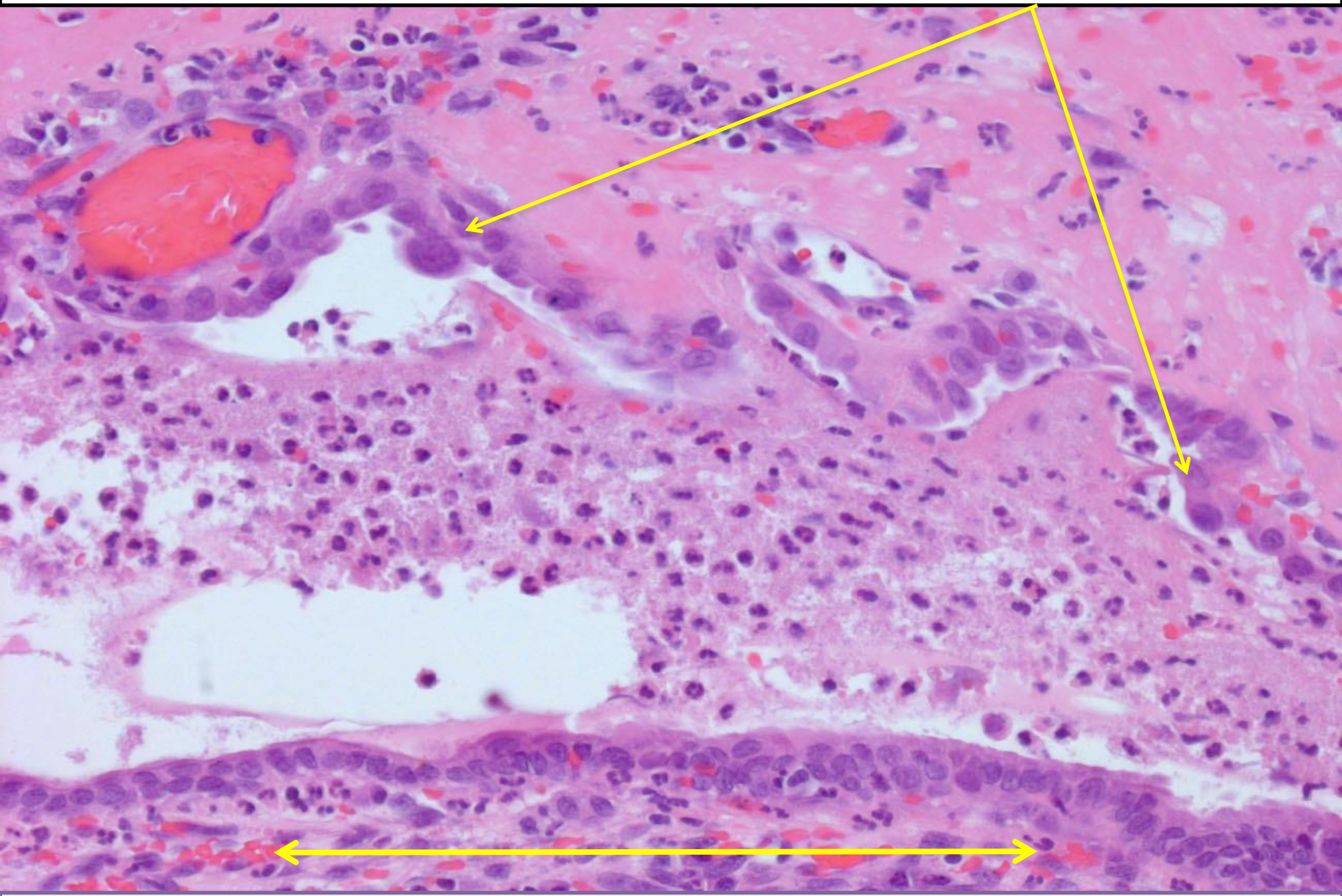

focally normal glandular epithelium – tubo-endometrioid vaginal adenosis

Preoperative vaginal biopsy from stricture focally showed benign features

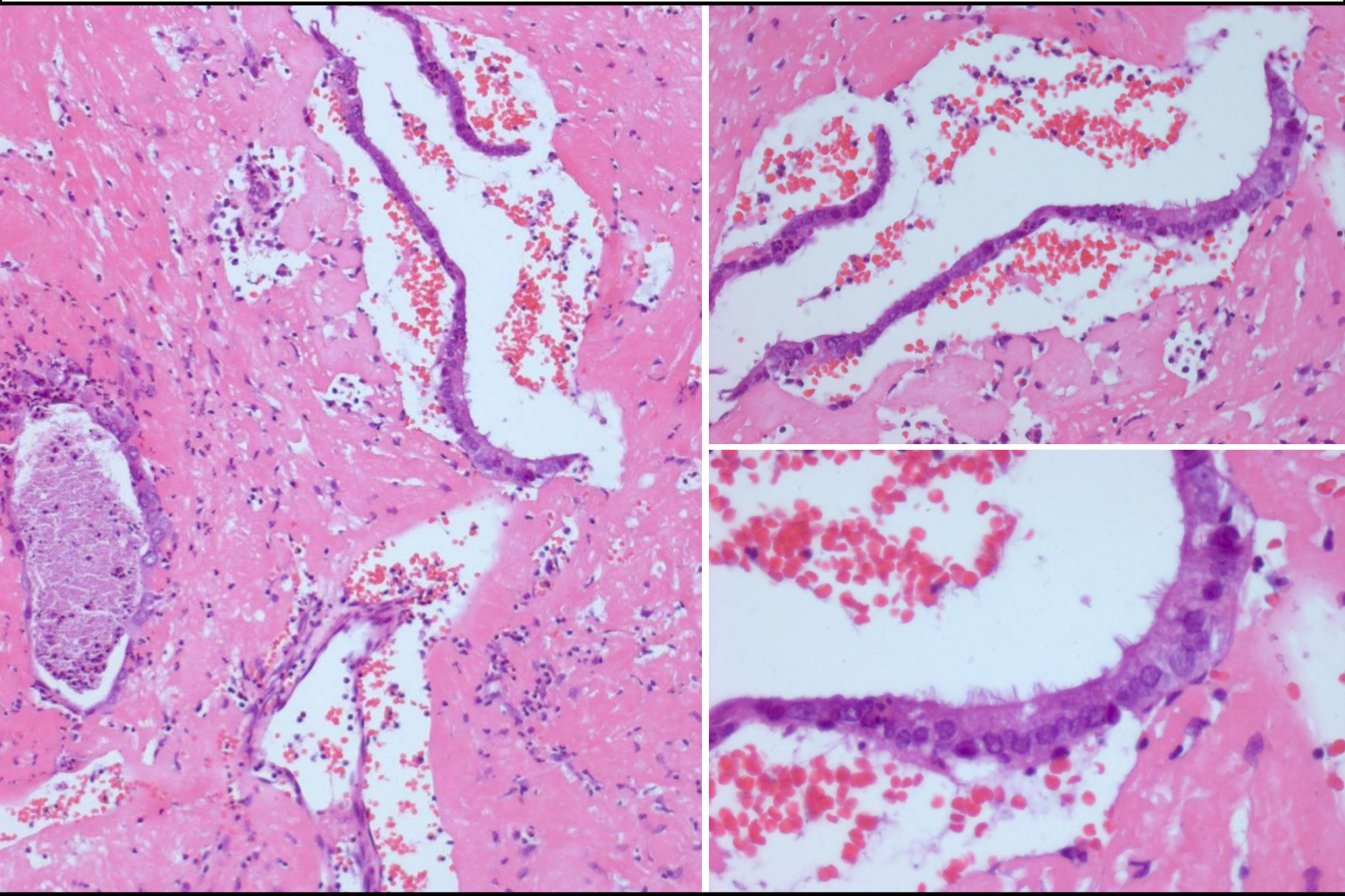

focal tubo-endometrioid vaginal adenosis in fibrinous/hyalinized matrix

Preoperative vaginal biopsy from stricture with focal benign features

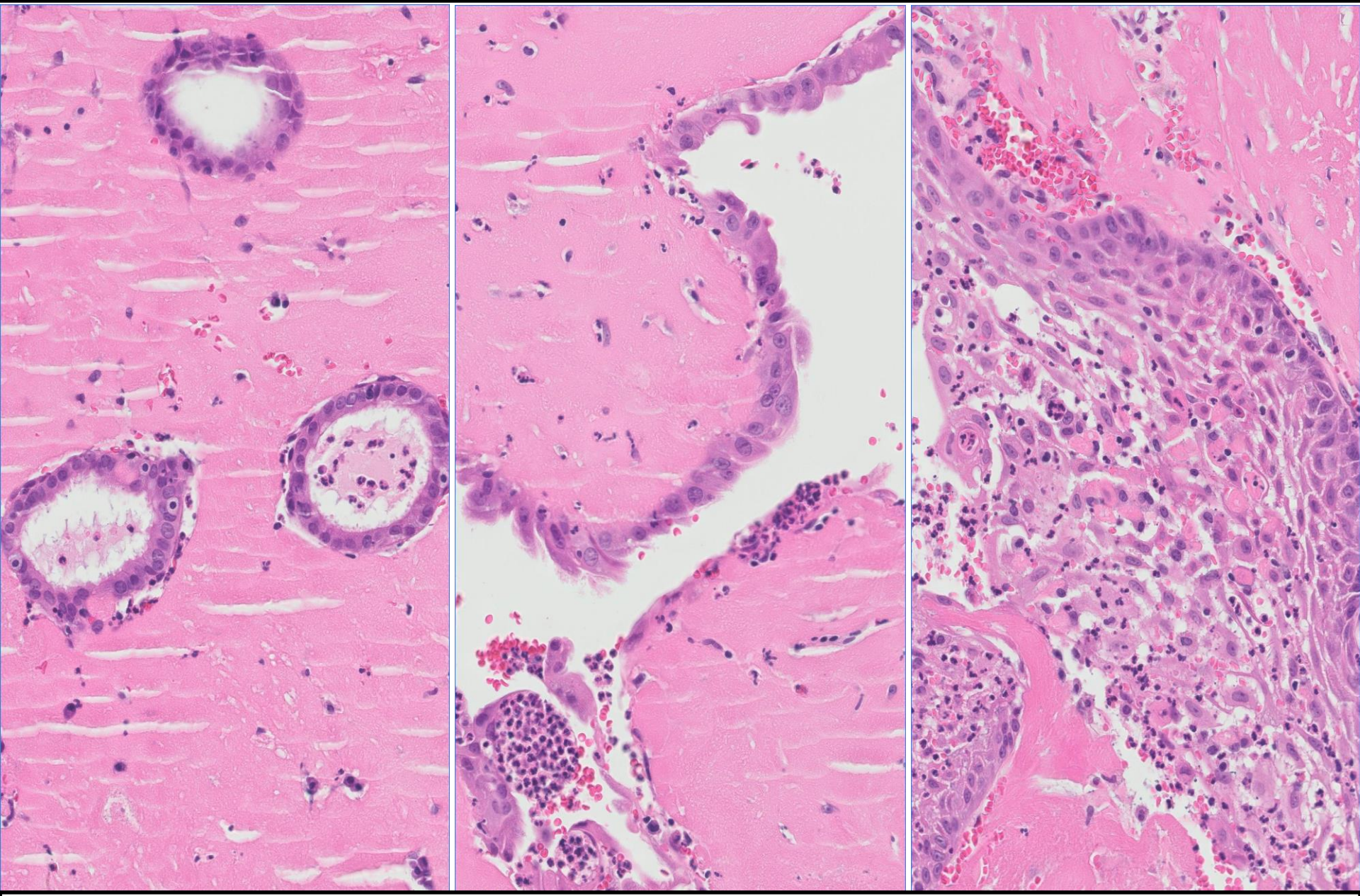

tubo-endometrioid vaginal adenosis with focal squamous metaplasia

Case 6
clinical history cont.

- Radical hysterectomy with bilateral salpingo-oophorectomy, upper vaginectomy and paraaortic lymph node sampling performed – no tumor at gross examination
- However, intraoperative frozen section slides of upper vagina and periovarian adhesions were reported as consistent with clear cell carcinoma
- Paraffin sections: atypical vaginal adenosis; no residual clear cell carcinoma; pelvic adhesions
- Postoperative course: recurrent vaginal nodules causing strictures – follow-up vaginal biopsies performed

follow up biopsy from remaining portion of vagina one year postoperatively

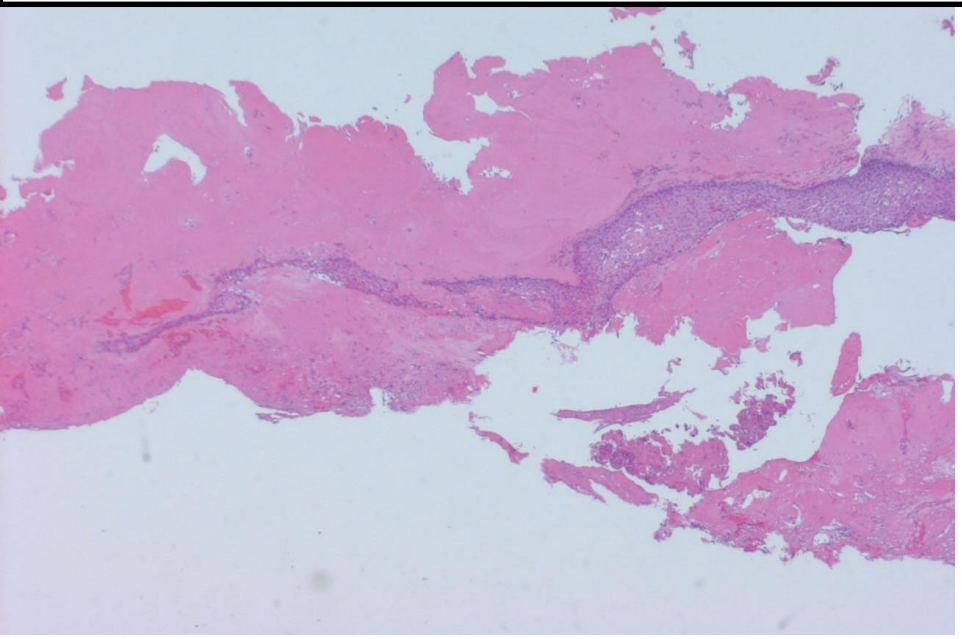

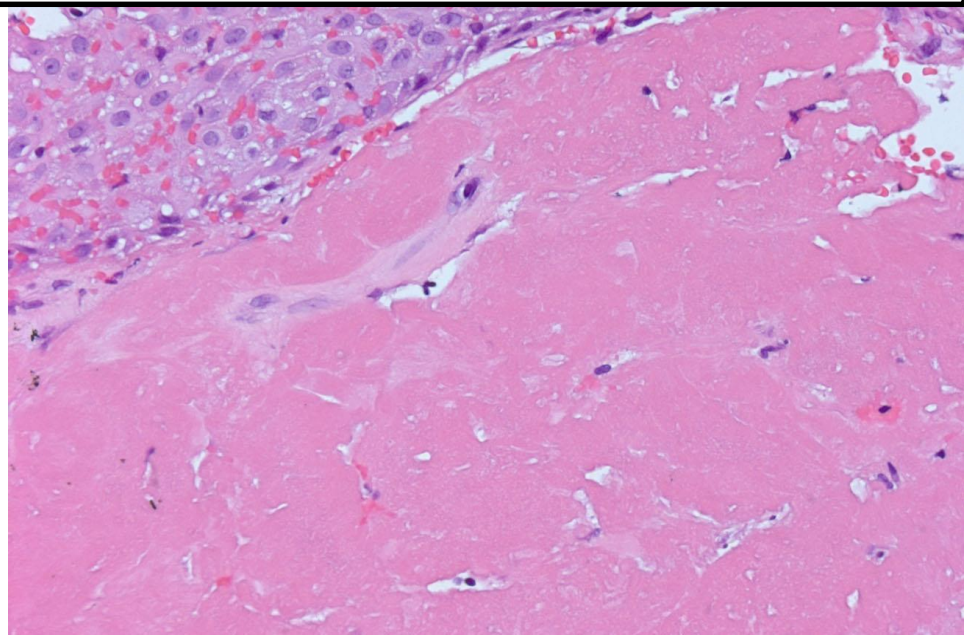

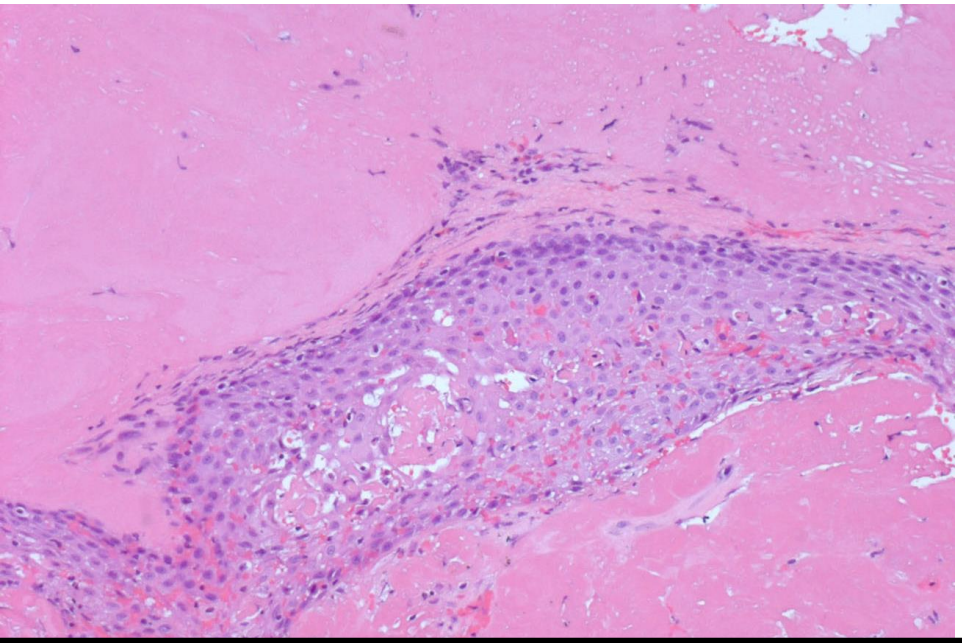

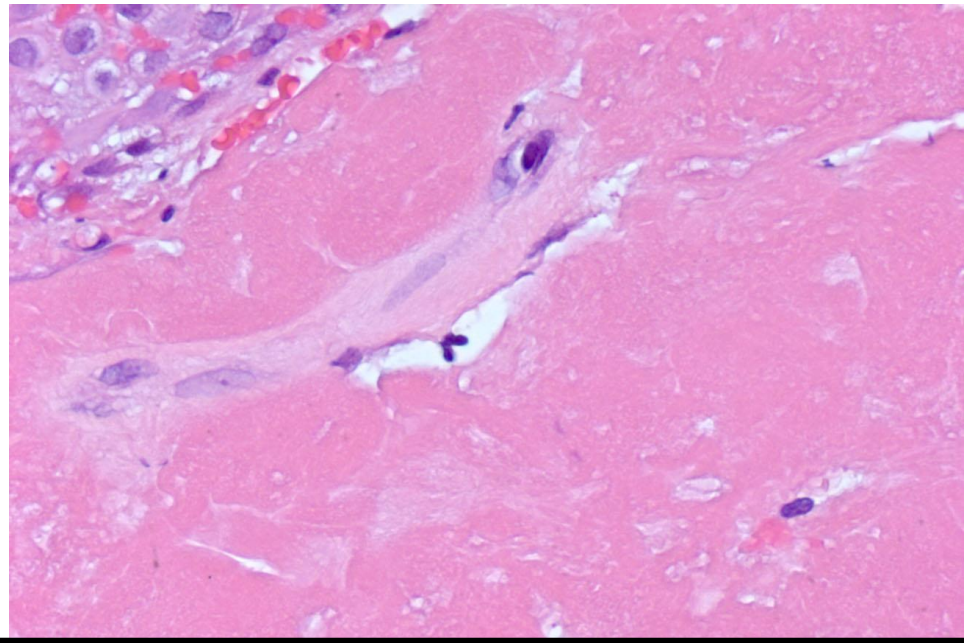

no residual carcinoma – benign squamous epithelium – fibrinous/ hyalinized matrix

follow up biopsy from remaining portion of vagina two years postoperatively

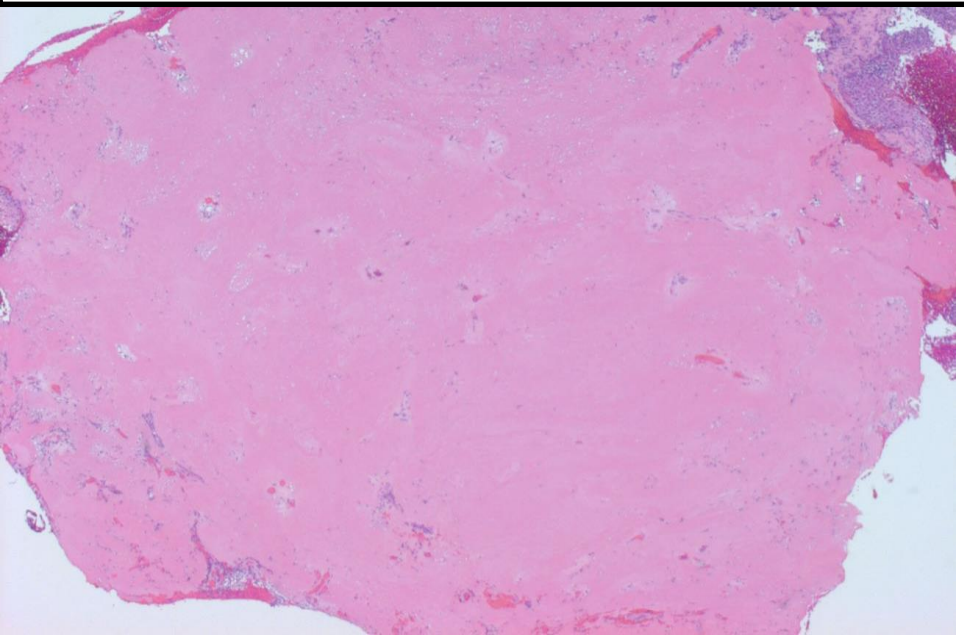

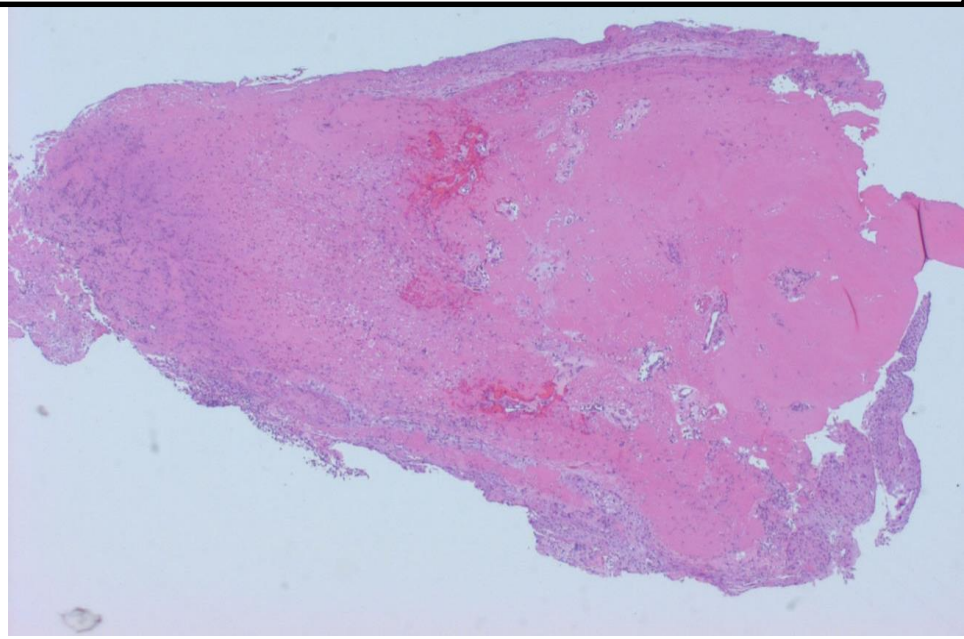

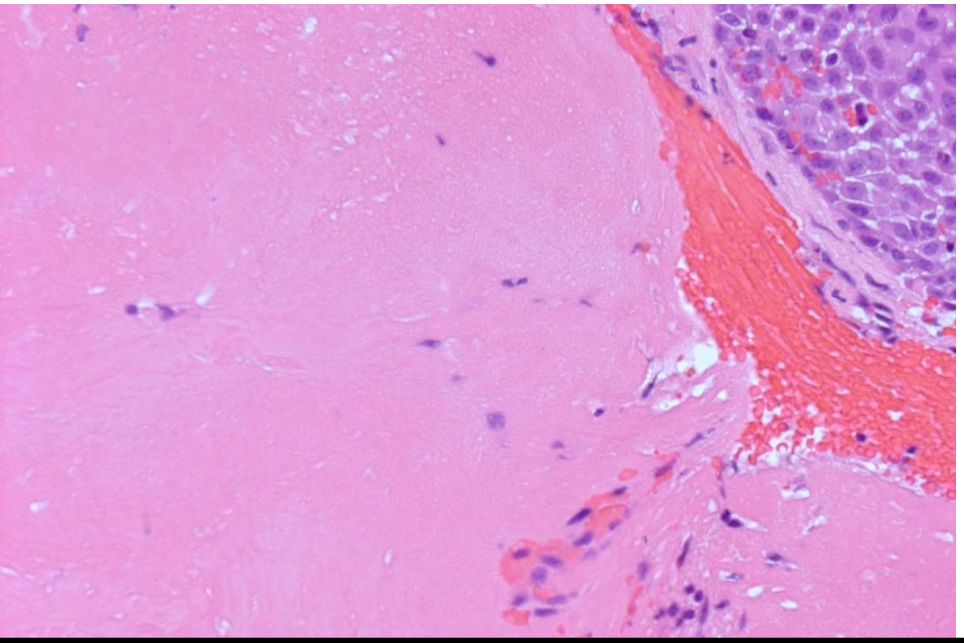

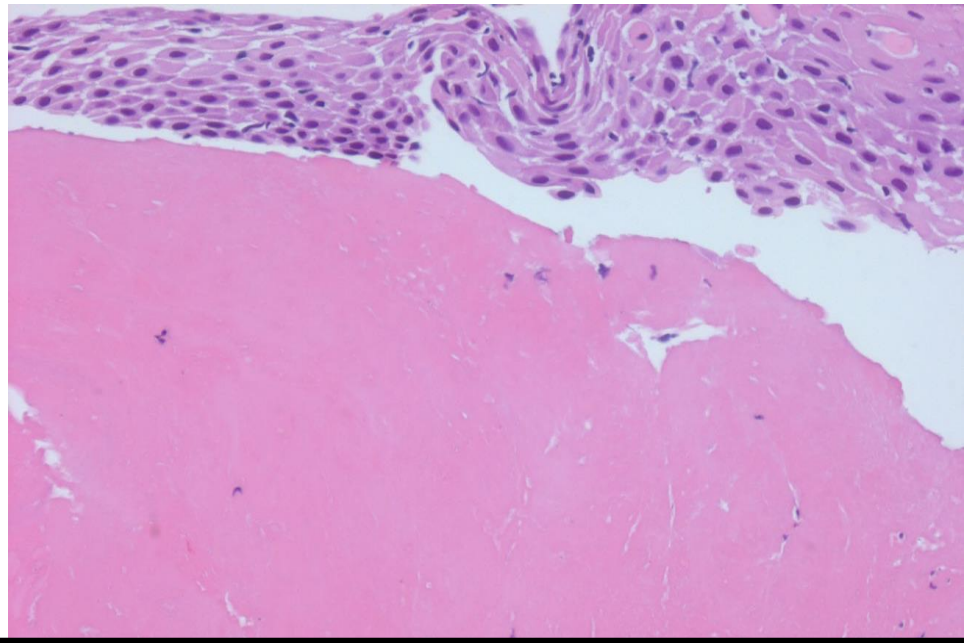

no residual carcinoma – benign squamous epithelium – fibrinous/hyalinized matrix

Reevaluation of the case
two years after radical surgery

- The fibrinous/hyalinized matrix in the postoperative follow-up vaginal biopsies prompted “new” diagnostic considerations
- Question 1: what is the nature of the fibrinous/hyalinized material?
- Question 2: was this peculiar fibrinous/hyalinized matrix present in the preoperative vaginal biopsies and also in the radical surgical specimens?
- Question 3: was the previous diagnosis of vaginal clear cell carcinoma correct?

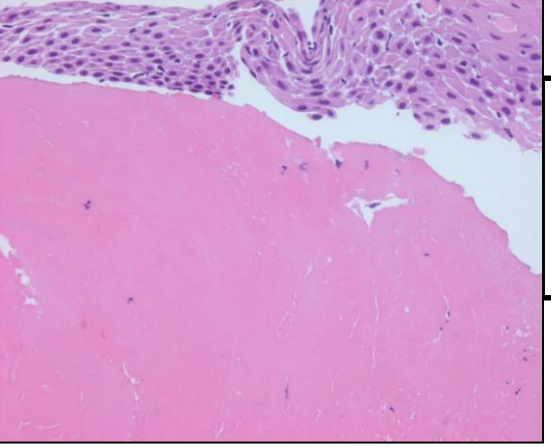

What is the significance of the fibrinous/hyalinized material?

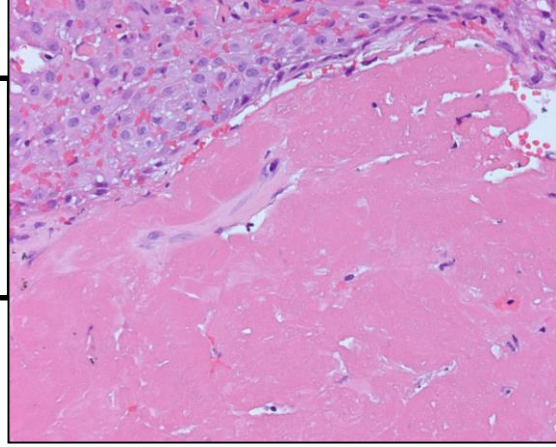

- Although fibrinous inflammatory exudate and hyalinization a common histologic finding at various sites of injury and repair, the persistence of such material in abundance at various mucosal sites should be investigated further
- Histochemical, immunohistochemical and EM studies revealed: abundant fibrin mixed with collagen - not amyloid
- Deposition of abundant fibrinous/hyalinized material on ulcerated mucosal surfaces or beneath regenerative epithelia should rise the possibility of “ligneous” (wooden) mucositis/vaginitis as a consequence of type I plasminogen deficiency

Nature of hyalinized/fibrinous material

Vaginal mucosa replaced by abundant hyalinized/fibrinous material

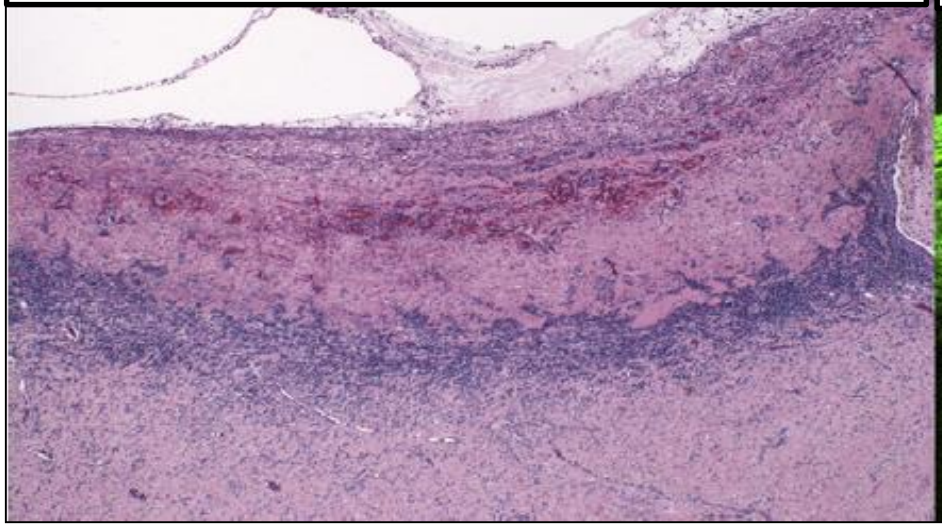

Immunofluorescence: fibrinogen

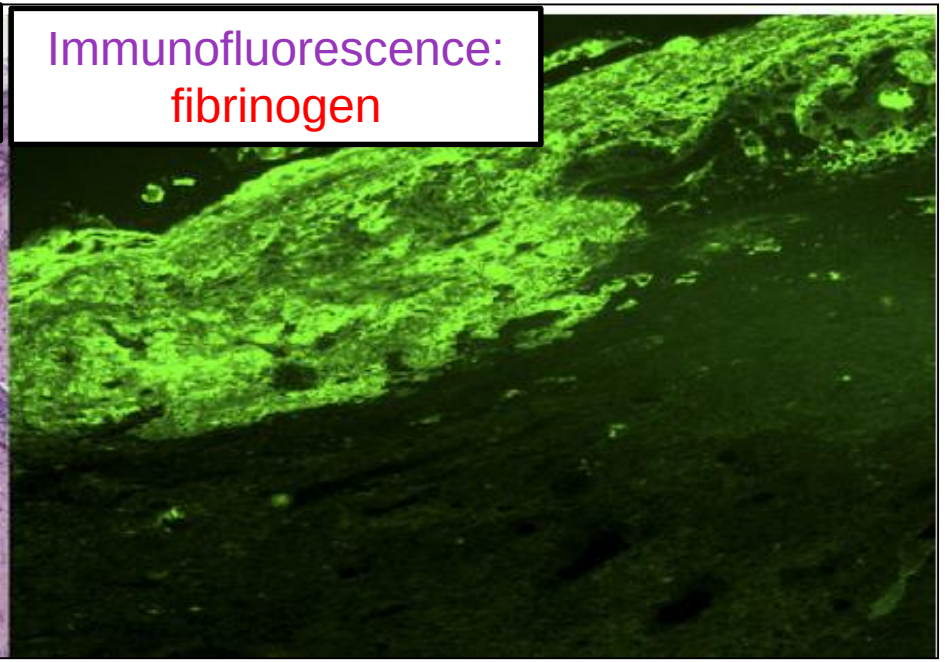

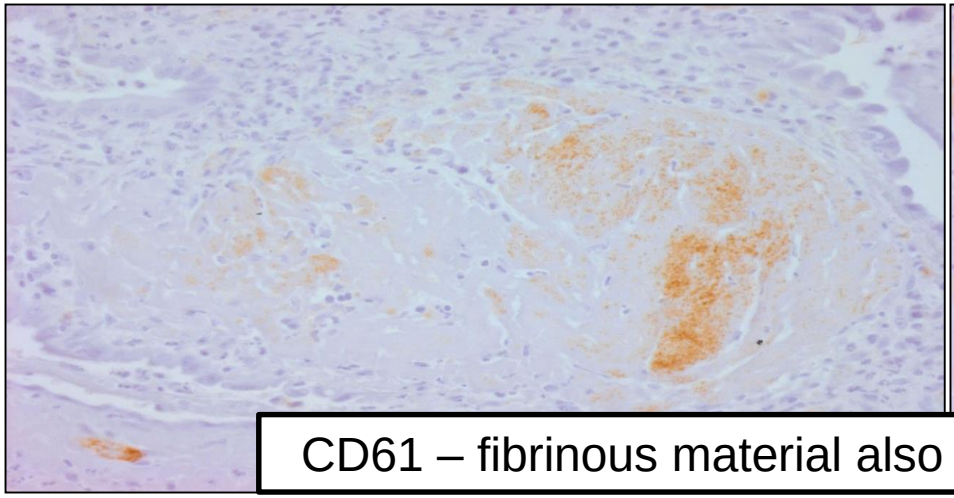

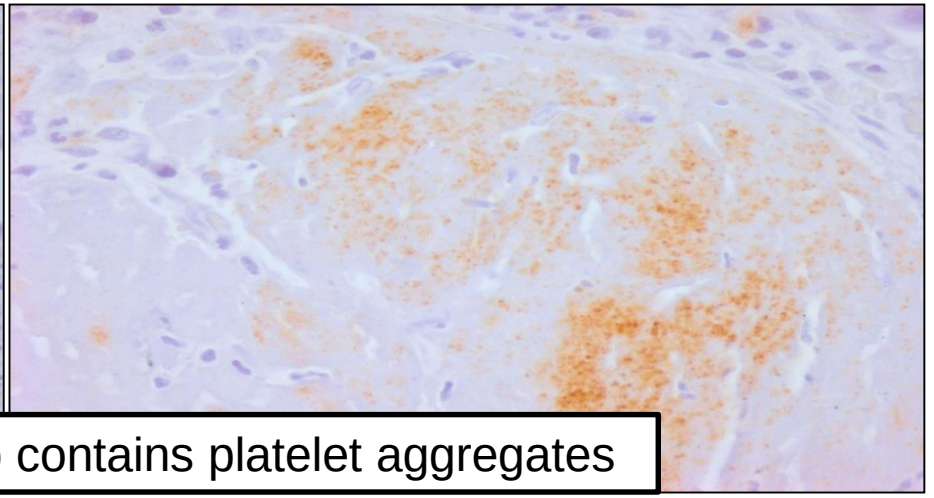

CD61 – fibrinous material also contains platelet aggregates

Preoperative vaginal biopsy from stricture diagnosed as clear cell carcinoma

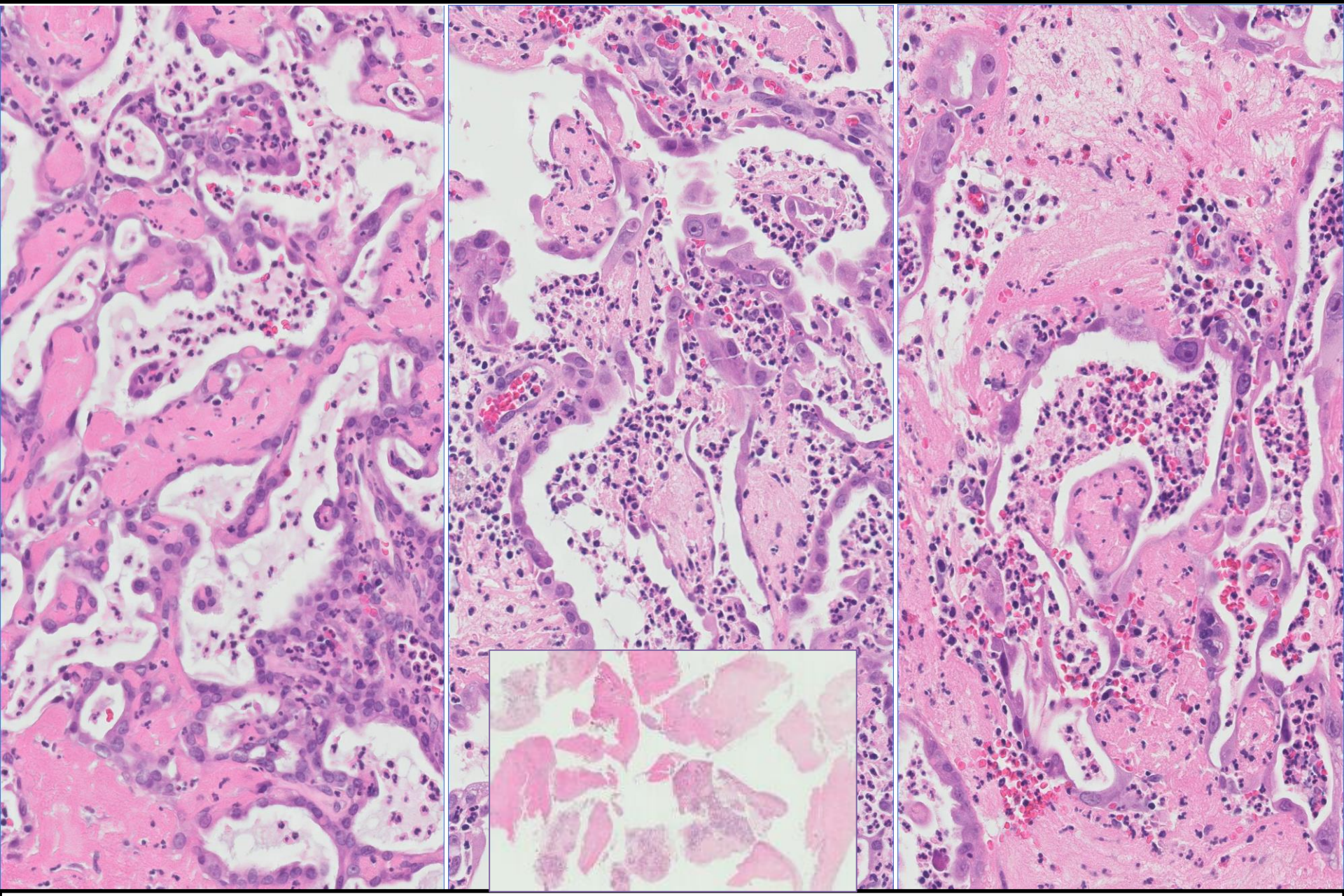

complex atypical glands in an inflammatory “fibrinous/hyalinized” background

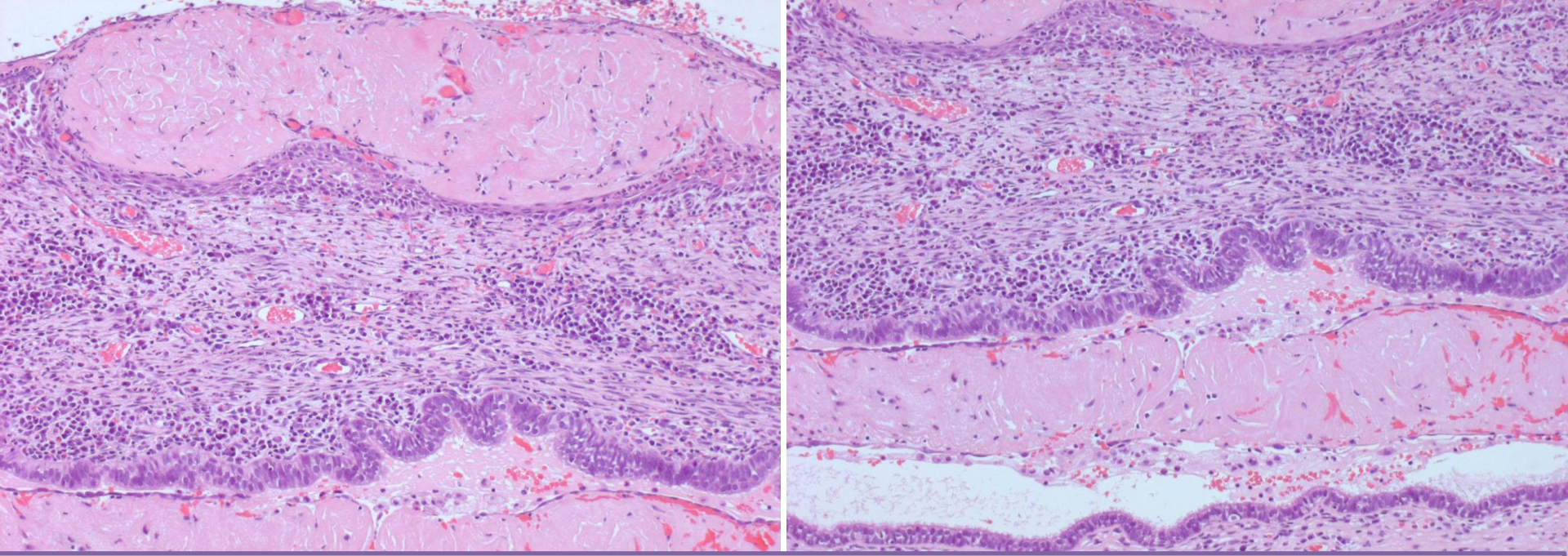

Upper vaginectomy: focally atypical adenosis with “pseudomembrane” - ligneous vaginitis

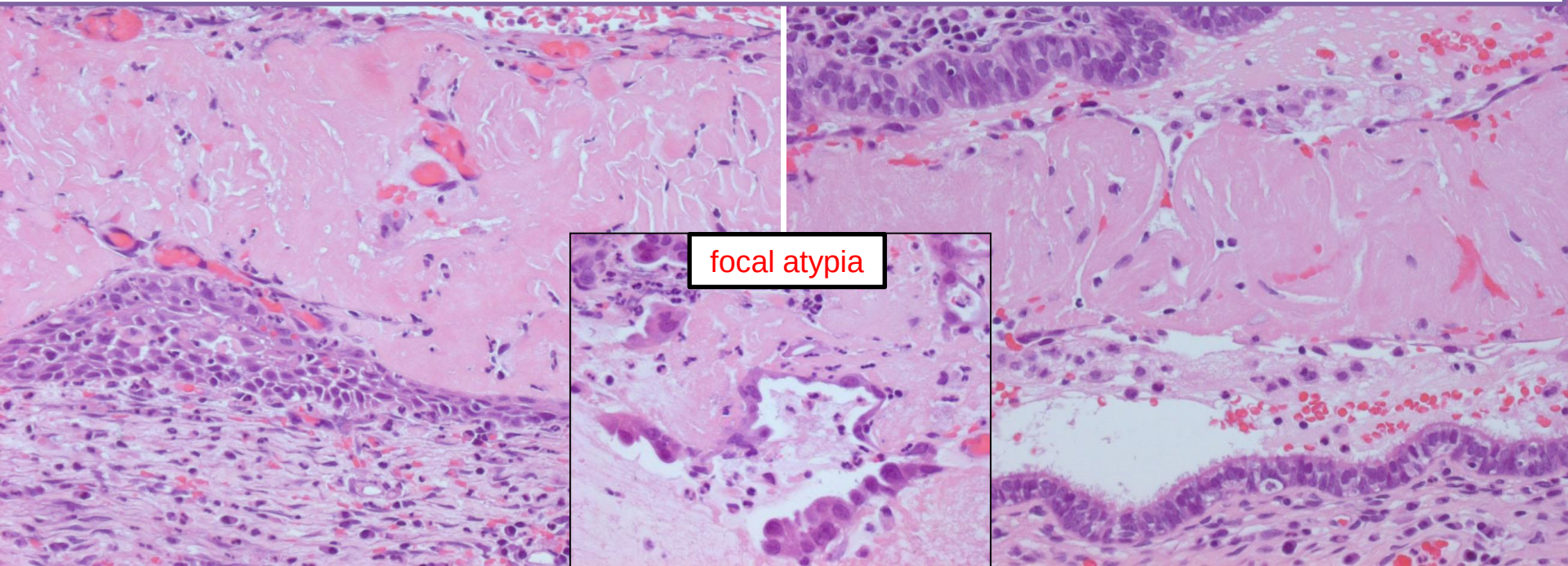

Ligneous cervicitis: normal & atypical glands in a fibrinous/hyalinized setting

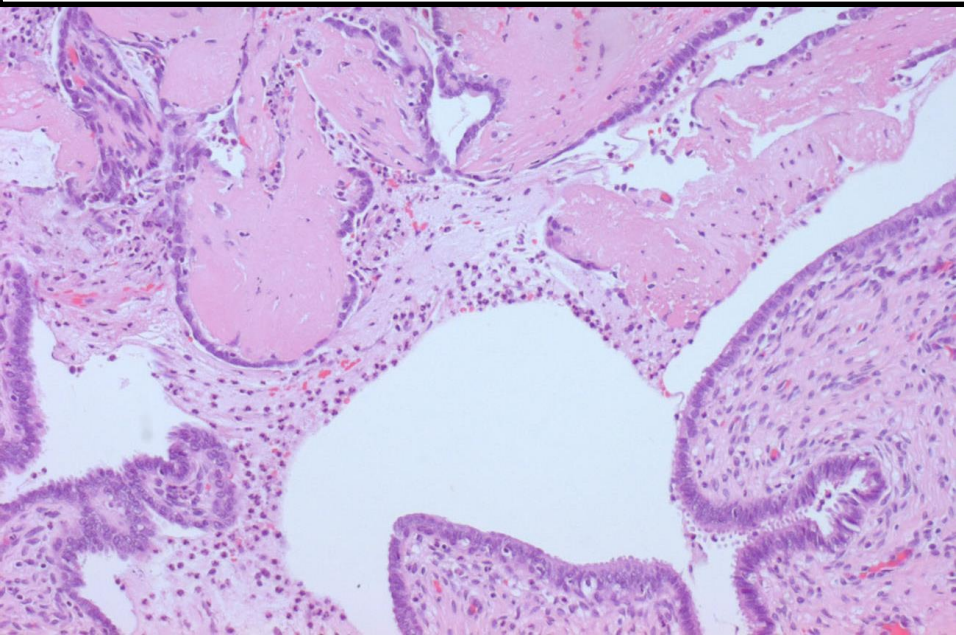

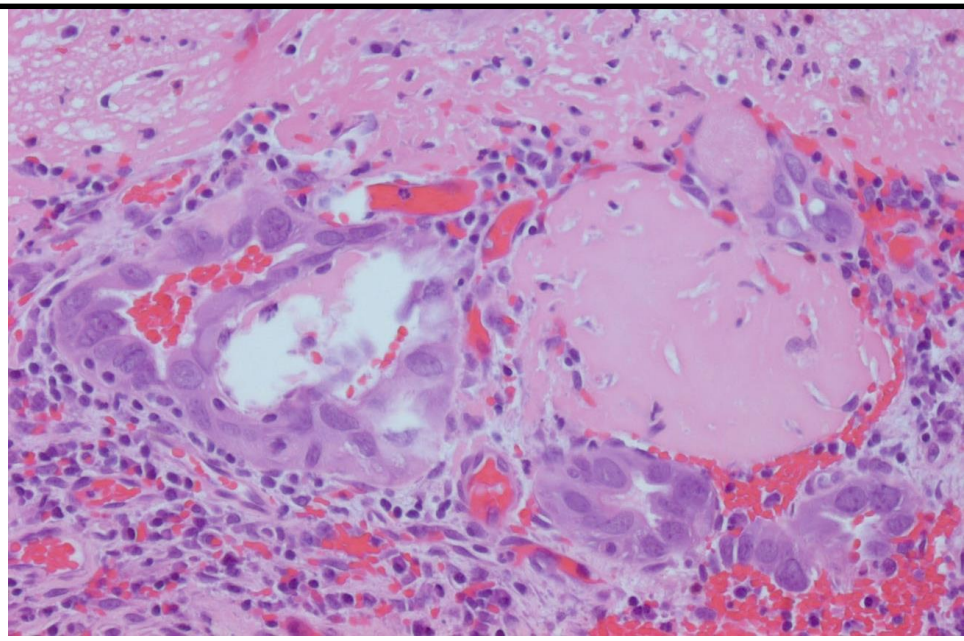

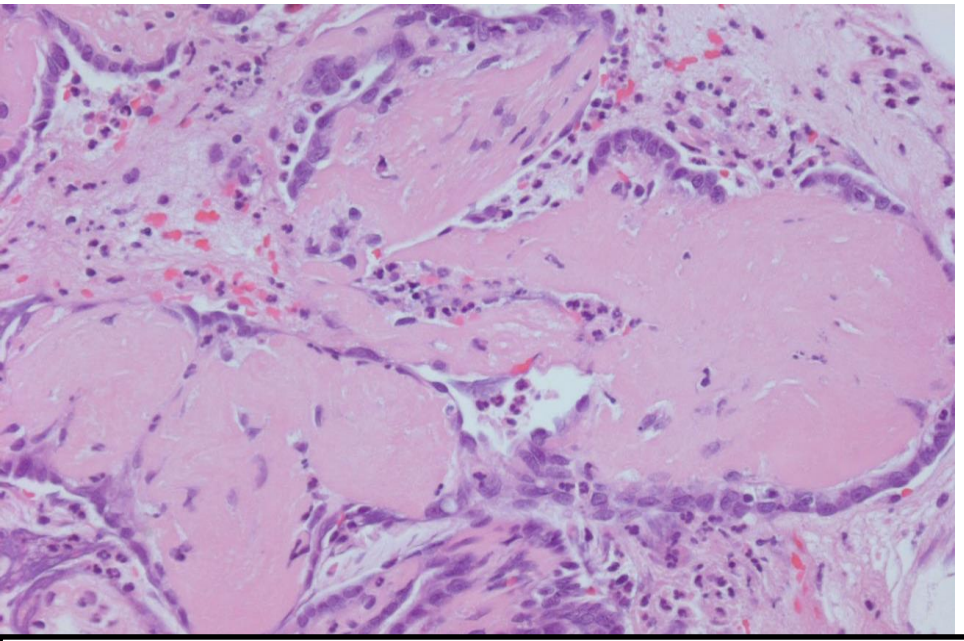

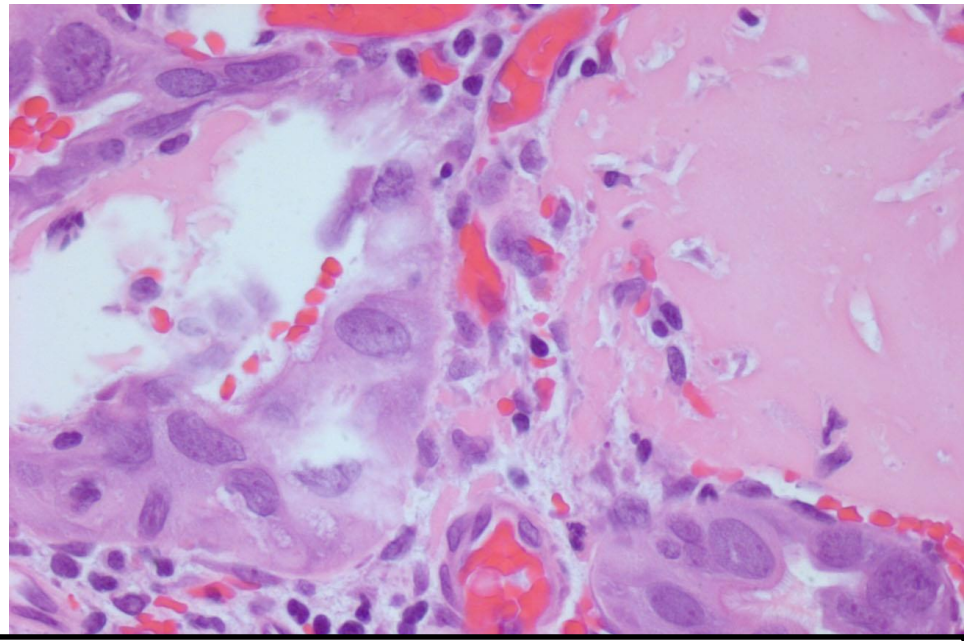

cytologically atypical & architecturally complex glands around hyalinized matrix

Ligneous endometritis: fibrinous pseudomembrane

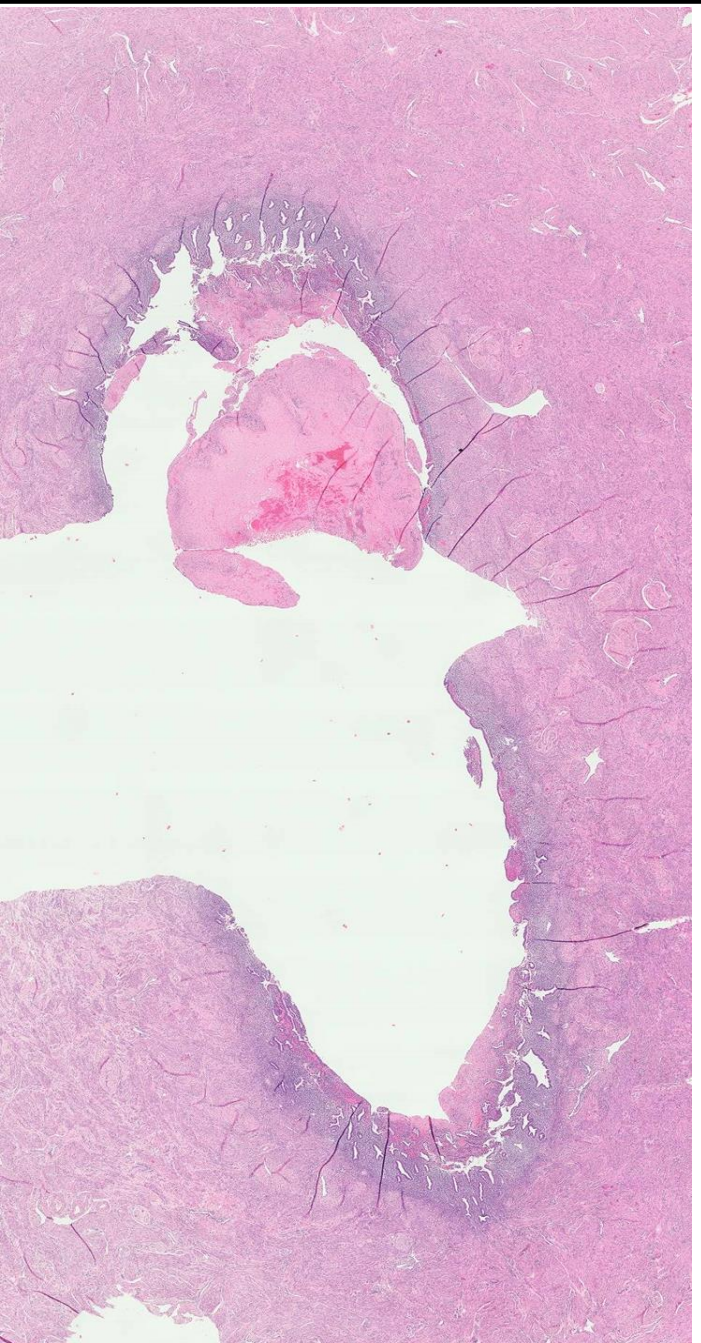

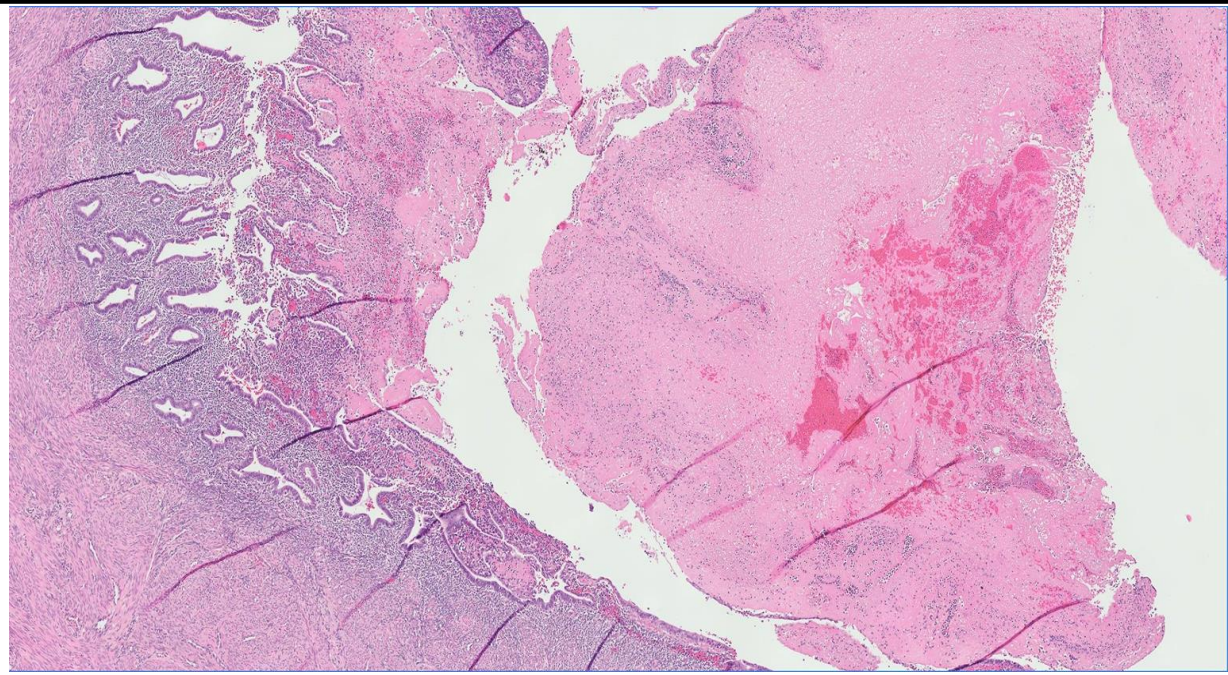

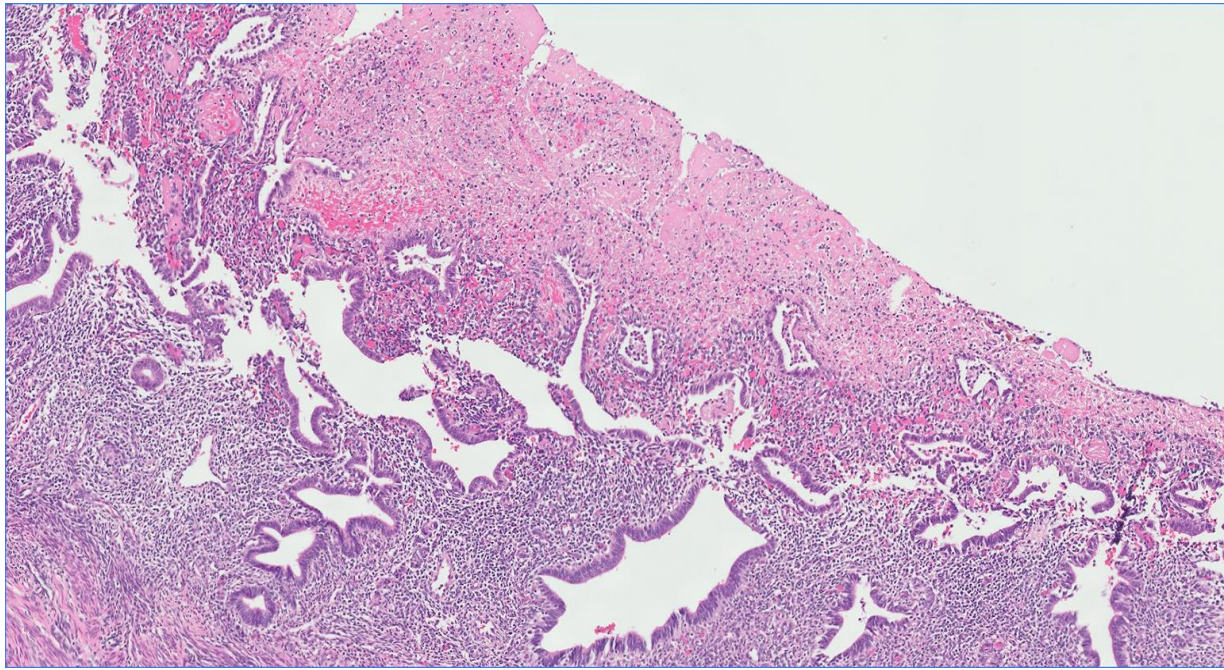

Ovary: fibrinous material – corpus albicans formation impaired

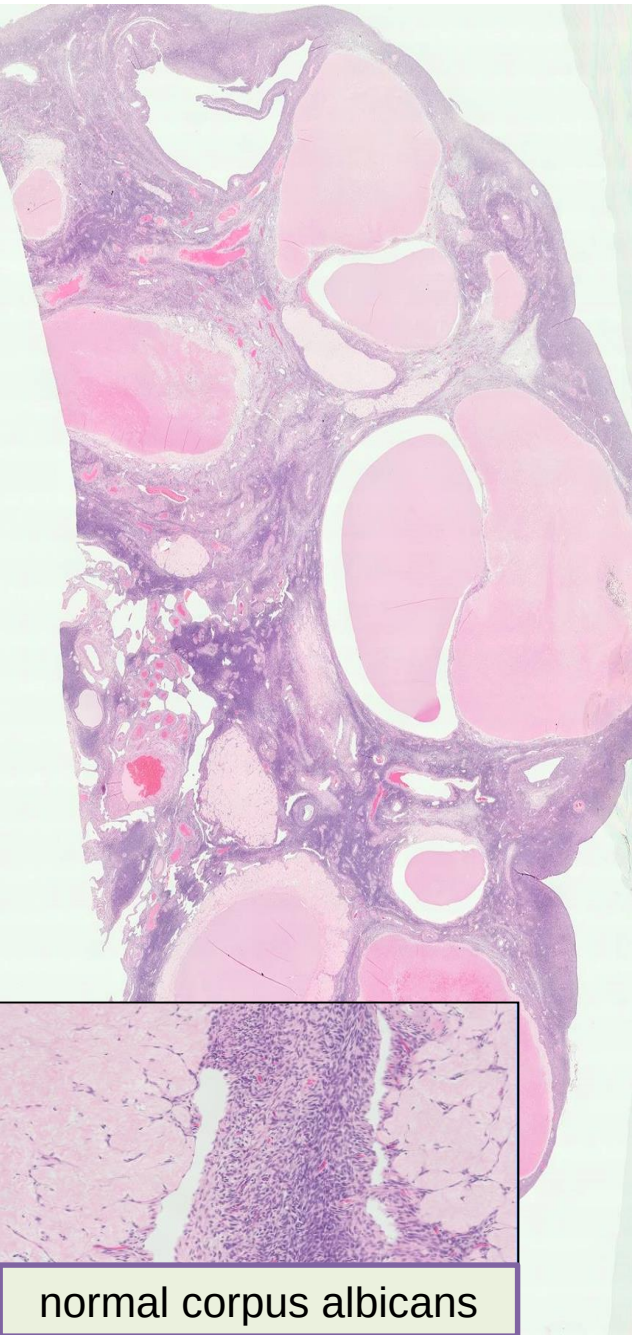

normal corpus albicans

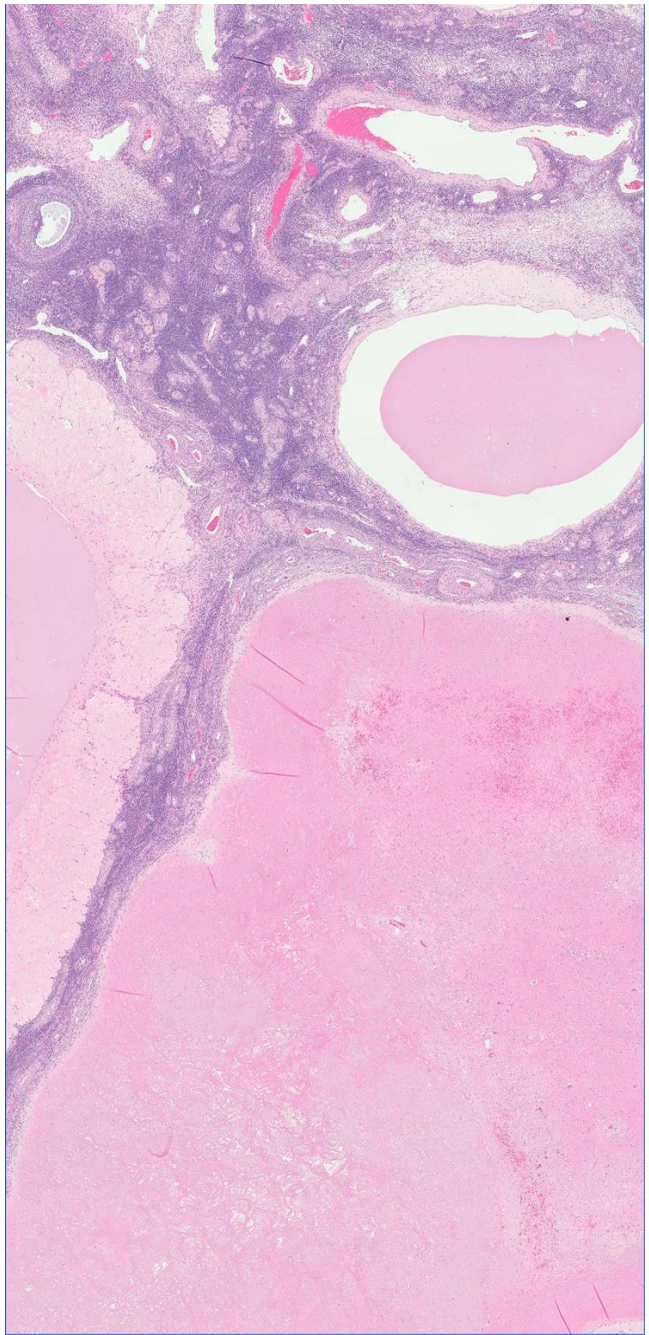

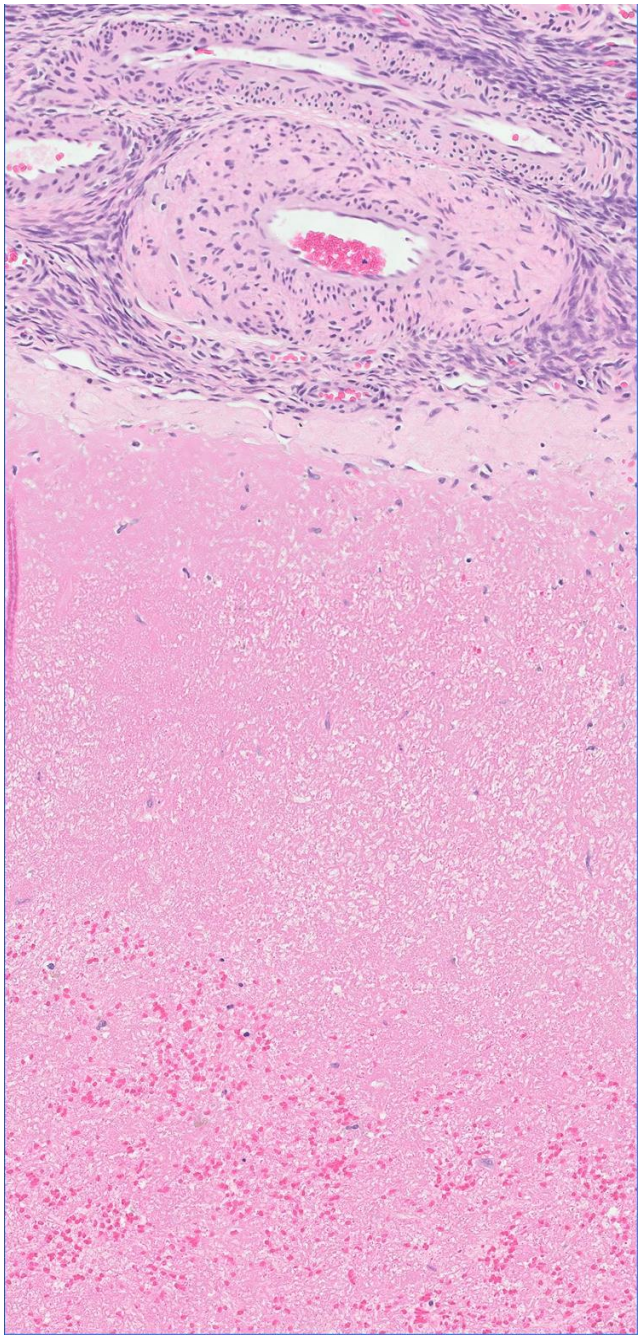

Involvement of fallopian tube and paratubal tissue by ligneous disease

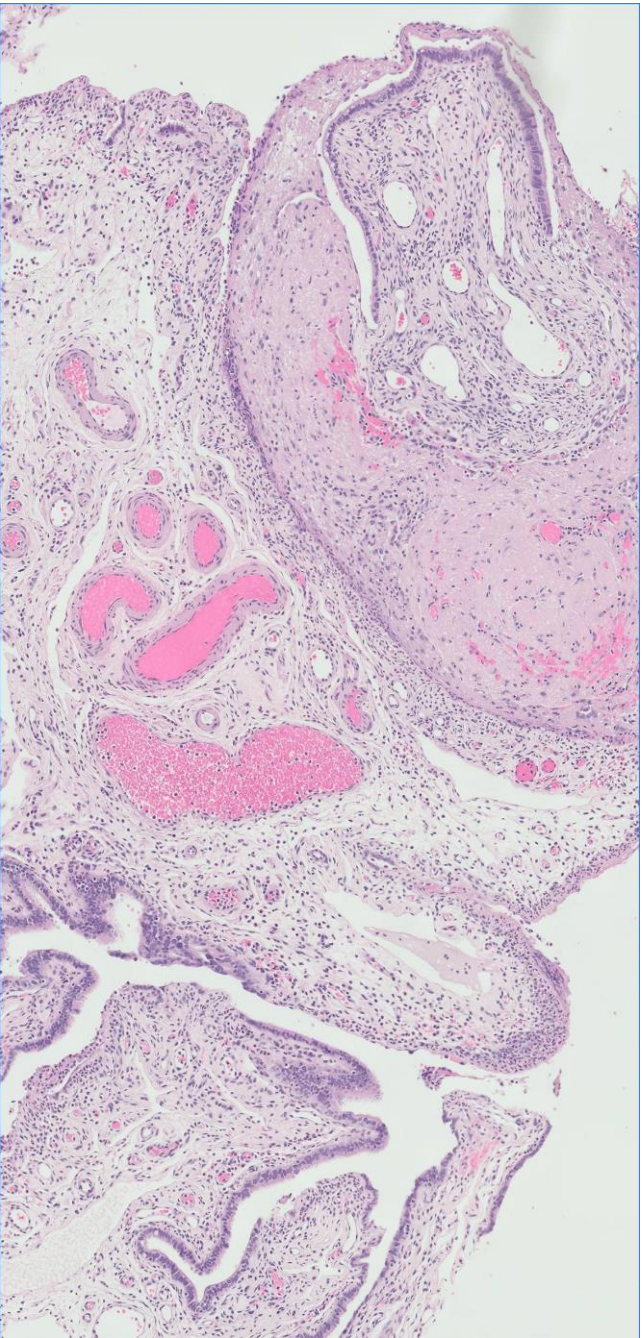

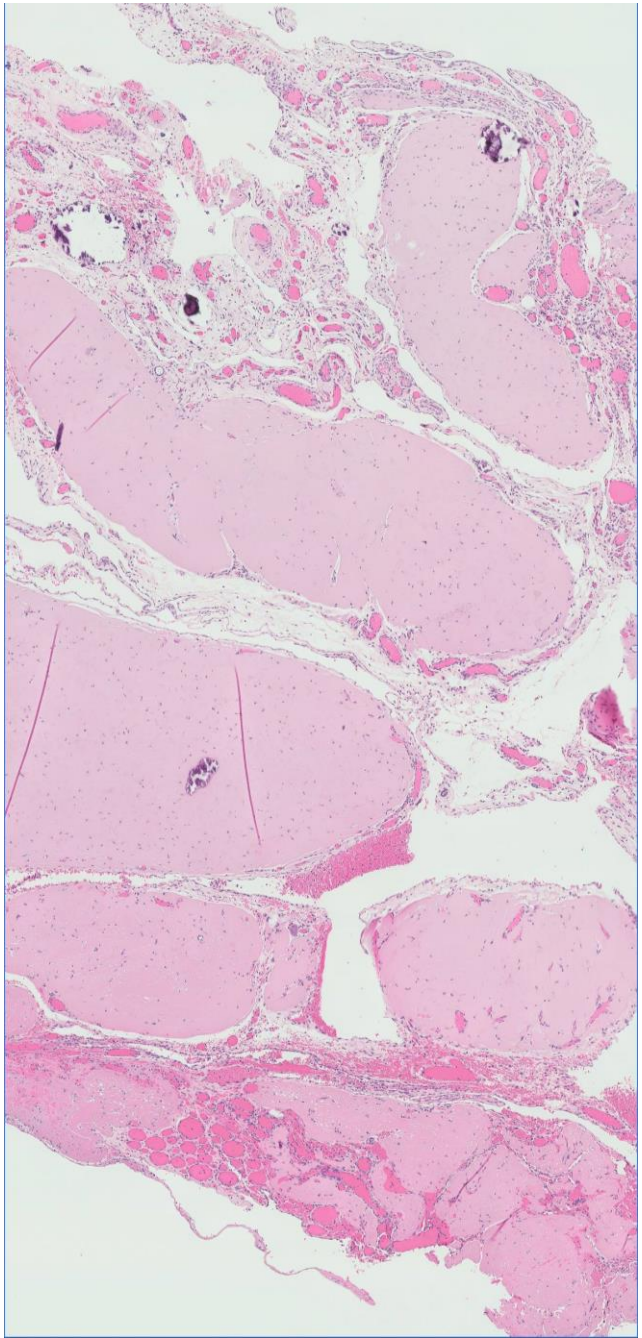

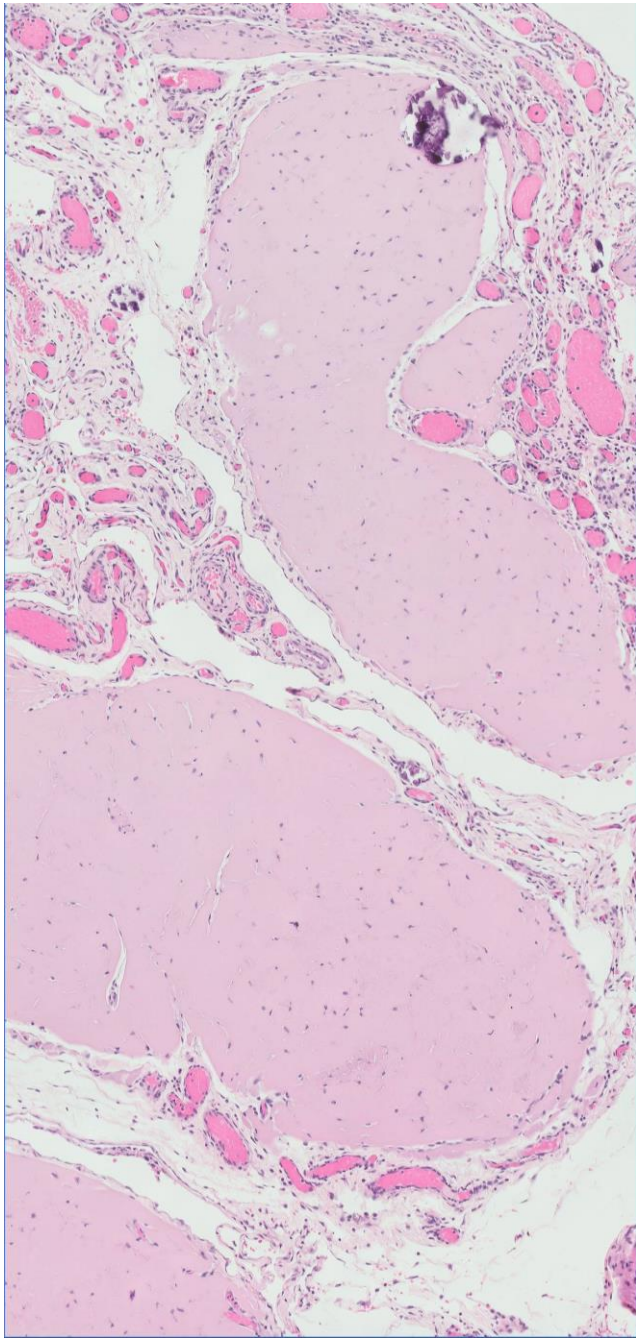

Case 6

additional history

Following a discussion with the clinician about the possibility of “ligneous vaginitis” (due to plasminogen I deficiency), directed questioning of the patient revealed important additional history:

- Chronic periodontal problems since childhood
- “Granulomas” of the ear
- Intermittent hoarseness for many years

Laboratory and molecular tests to confirm ligneous mucositis were performed

Case 6

laboratory tests and molecular study

- Functional plasminogen level markedly decreased
  13% of normal (reference range, 70 – 127%)
- Low plasminogen antigen:
  2.1mg/dL (reference range, 7.5 – 15.5 mg/dL)
- Genomic DNA from peripheral blood analysed for mutations and polymorphisms in the plasminogen gene by direct sequencing
- Compound heterozygous for the most common plasminogen missense mutation *K19E* in exon 2 and
  nonsense mutation *R471X* in exon 12 detected

Case 6
Diagnosis

Ligneous vaginitis

inherited plasminogen I deficiency

Essence of the disease:

compromised extracellular fibrin clearance during wound healing, leading to pseudomembraneous (ligneous) lesions on affected mucus membranes

Plasminogen deficiency
pathogenesis

- In healthy individuals plasminogen is synthesized in the liver and converted into its active form plasmin
- Plasmin is a protease that segregates fibrin into soluble degradation products, important for wound healing
- Plasminogen deficiency: in case of tissue injury or inflammation extracellular fibrin deposits in mucus membranes cannot be dissolved
- The pathologic findings are fibrin deposits with associated inflammation and so called ligneous (wooden) plaques

Inherited plasminogen deficiency

a potentially life-threatening disease

- Pseudomembranous lesions of mucosal surfaces exposed to minor trauma (conjunctiva, oral, upper, and lower respiratory tract mucosa, vaginal/cervical mucosa)
- Most commonly clinically encountered: ligneous conjunctivitis in young children





- With time, patients develop gingival hyperplasia, hoarseness, respiratory distress or intestinal obstruction caused by pseudomembranes
- Female genital tract is involved in 8% of patients

Female genital tract

inherited hypoplasminogenemia

- Fourth most commonly involved organ system, following the conjunctiva and the oral, upper, and respiratory tract mucosa
- Tissue damage caused by sexual activity, menstruation or ovulation may make the gynecologic tract vulnerable to fibrin accumulation
- 30 published cases, nearly half presented with gynecologic symptoms but without evidence of ophthalmologic disease
- Primary infertility, dysmenorrhea, abnormal cytologic findings and poor wound healing after biopsies or surgical intervention

Case 6

Key question and reconsideration of histologic findings

- Was the original diagnosis of clear cell carcinoma correct?
- In my opinion there is no evidence of clear cell carcinoma
- The architectural and cytological atypia of the vaginal adenosis is reactive in nature – “pseudomalignant” reactive epithelial changes described at various anatomic sites and clinical settings (stomal sites, in granulation tissue etc.)
- The morphologic alterations in the vaginal adenosis are attributed to the pathologic displacement of normal vaginal stroma by abundant fibrinous/hyalinized material

Ligneous cervicitis in a woman with plasminogen deficiency associated with an atypical form of microglandular hyperplasia

Taube ET et al, Int J Gynecol Pathol 2013; 32:329-334

- 19-year-old woman was diagnosed with clear cell adenocarcinoma of the cervix on colposcopic biopsies
- The patient had a history of plasminogen deficiency
- Reevaluation of cervical biopsies led to a diagnosis of ligneous cervicitis with a background of atypical microglandular hyperplasia
- There were also pseudomembranes involving the peritoneum, cul-de-sac and surface of fallopian tube
- Sentinel lymph nodes were negative; follow-up uneventful

Ligneous cervicitis in a woman with plasminogen deficiency associated with an atypical form of microglandular hyperplasia

Taube ET et al, Int J Gynecol Pathol 2013; 32:329-334

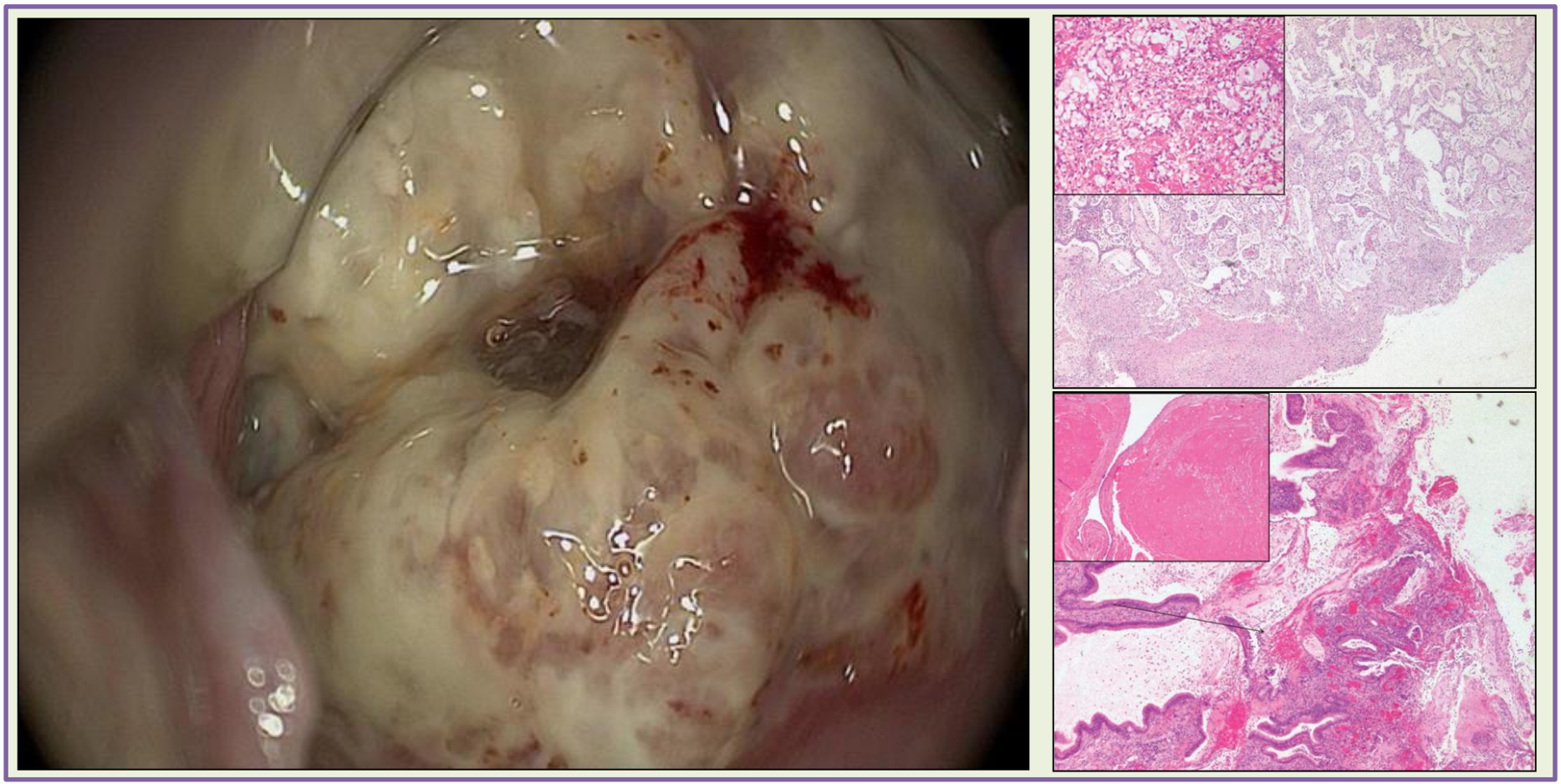

Preoperative vaginal biopsy from stricture diagnosed as clear cell carcinoma

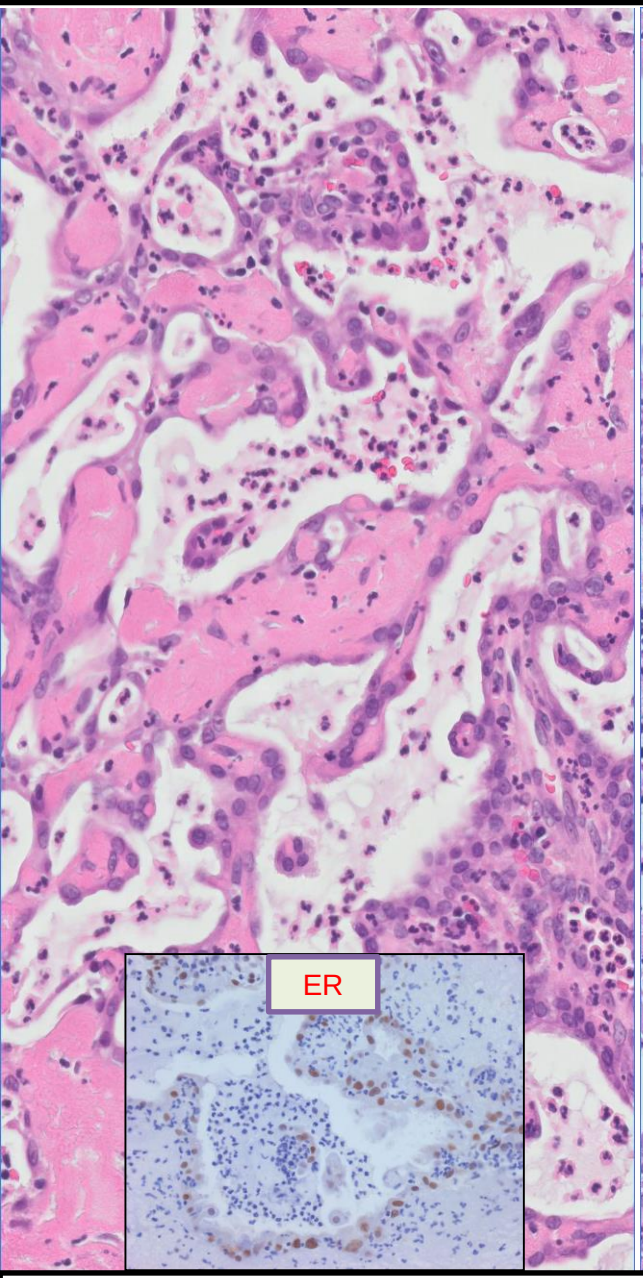

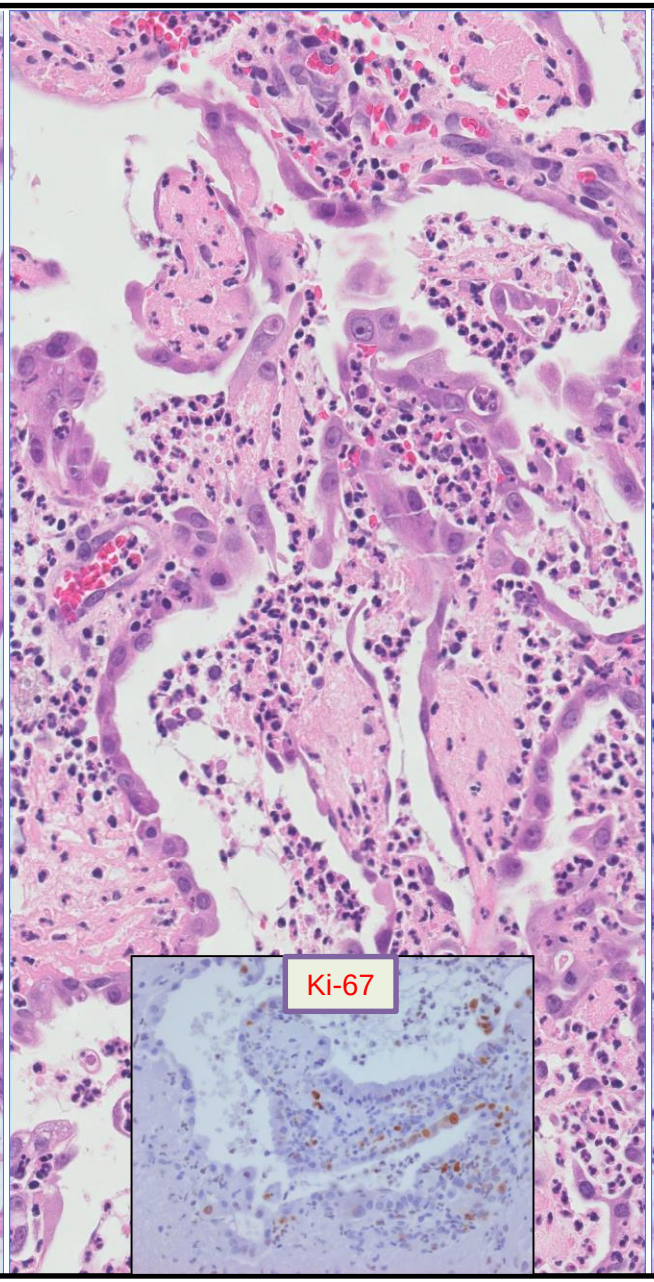

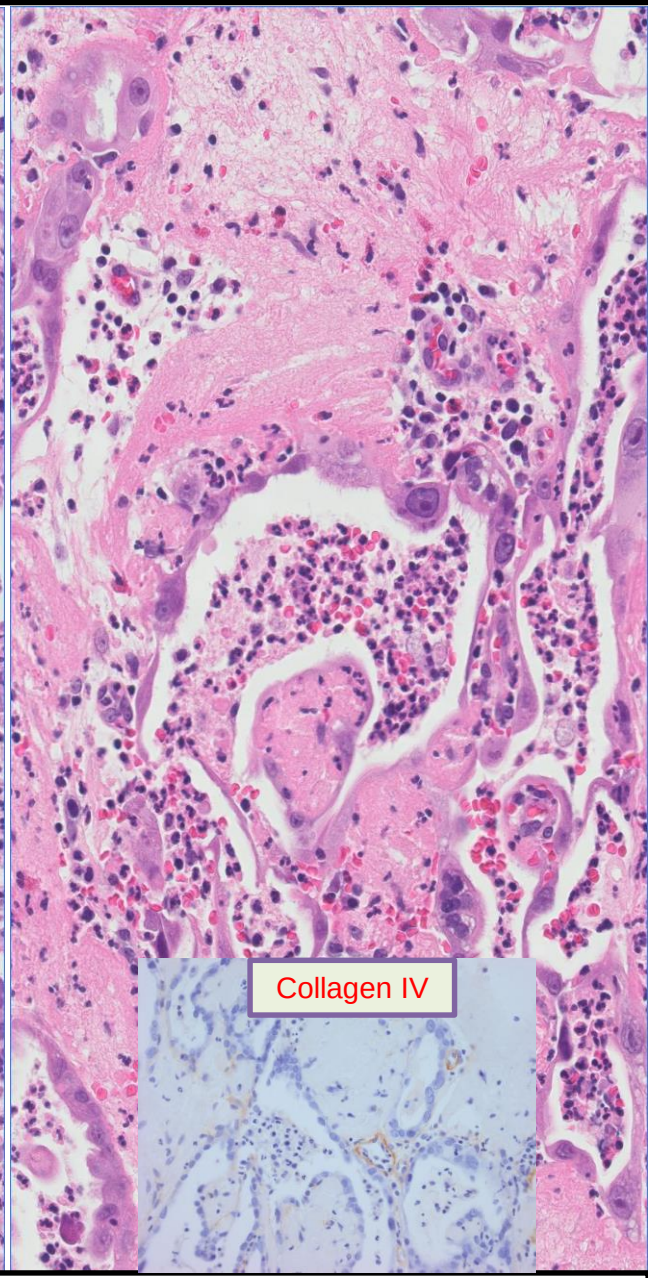

cytologically atypical and architecturally complex glands

“Genuine” clear cell adenocarcinoma for comparison

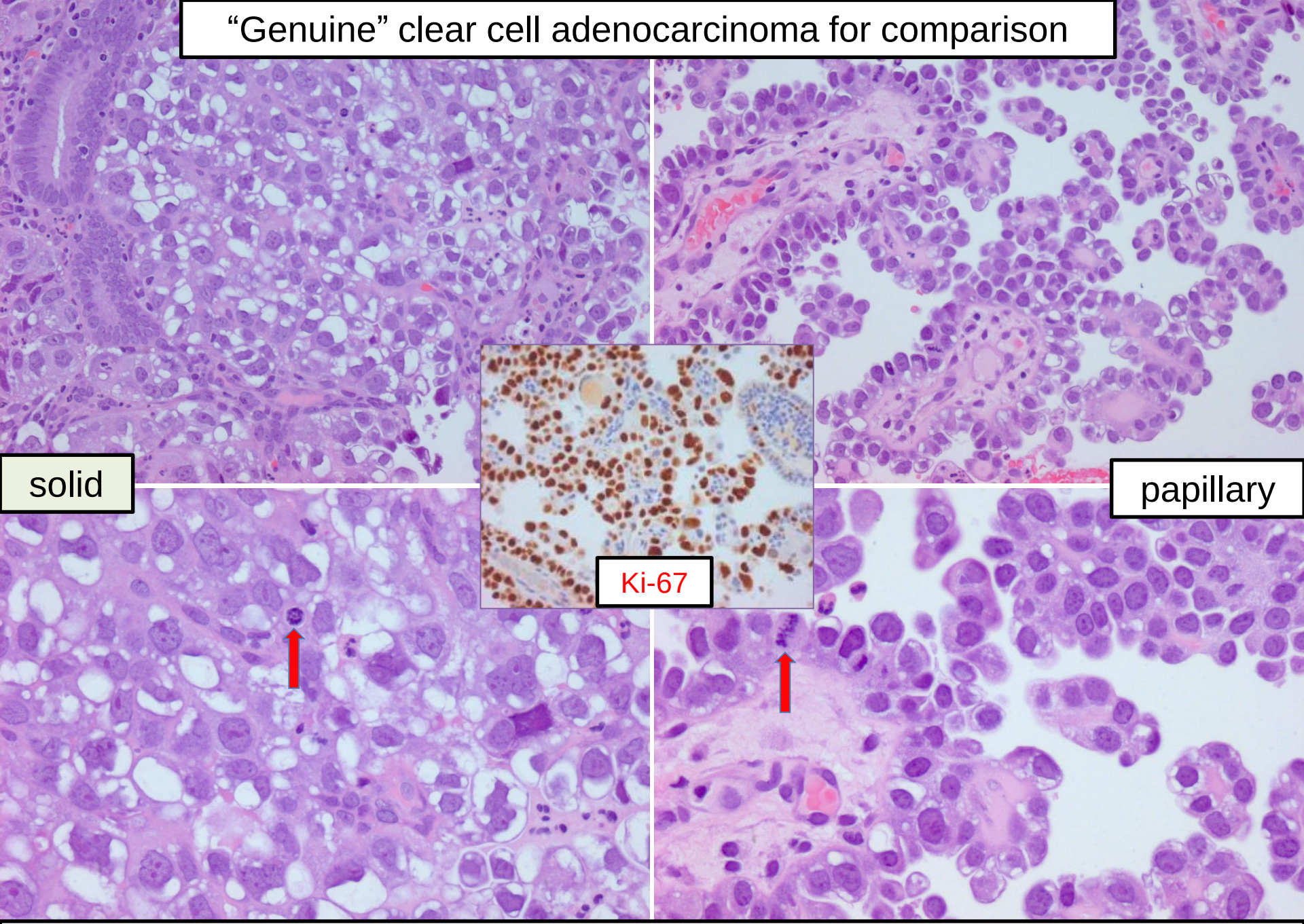

clear cell adenocarcinoma is highly proliferative in contrast to vaginal adenosis

“Genuine” clear cell adenocarcinoma – hyalinization of core of papillae

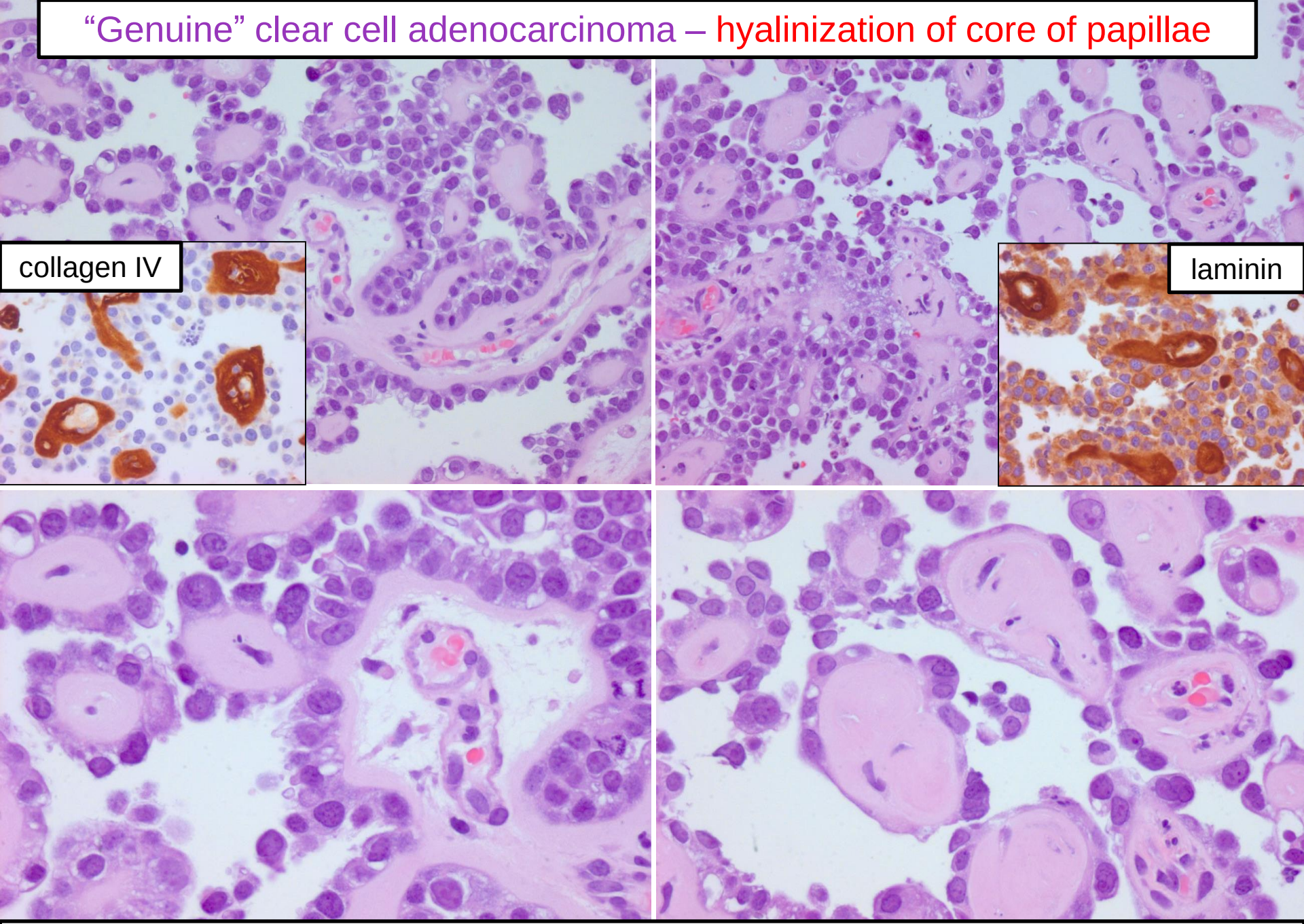

the hyalinization represents basement membrane material not fibrin

Case 6
follow-up

- The patient's oral, laryngeal and vaginal symptoms reduced dramatically on regular treatment by plasminogen products (spray, cream)
- No evidence of malignancy at 12 years follow-up

Concluding remarks

pitfall "A": ignoring a diagnostically important feature

- Both preoperative and radical surgical material contained abundant eosinophilic fibrinous/hyalinized material
- Most frequent types of extracellular eosinophilic material on H&E sections: fibrin, hyalinized collagen, amyloid, osteoid
- Obviously not osteoid and not amyloid (congo red negative)
- Histochemical, immunohistochemical and ultrastructural studies: abundant fibrin with hyalinization (collagenization)
- In order to avoid pitfall: keep plasminogen deficiency in mind

Concluding remarks

pitfall "B": misinterpreting reactive changes as malignancy

- Several features are unusual for an adenocarcinoma
- Virtually no mitotic activity
- Nuclear atypia is random
- Nuclear/cytoplasmic ratio is low
- Atypical epithelium mixed with both ciliated and squamous metaplasia
- Atypical glands are restricted to areas where the stroma consists of peculiar abundant eosinophilic fibrinous/hyalinized material

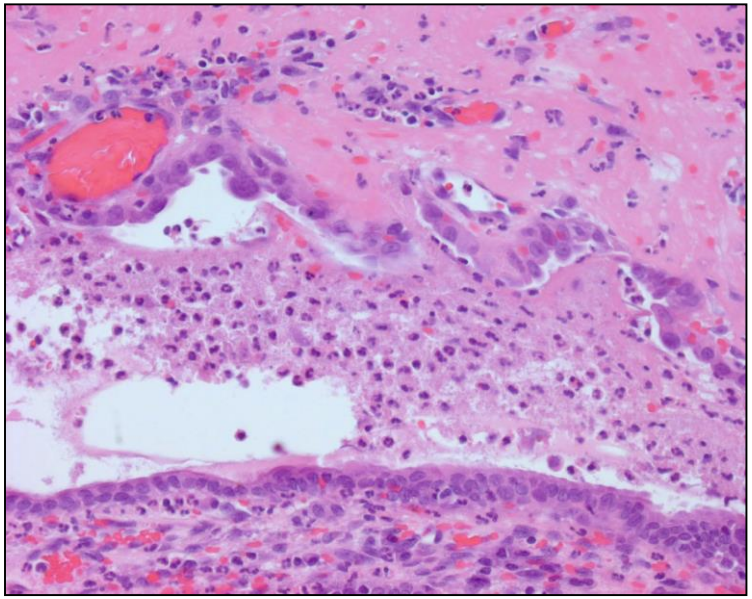

Severe ligneous conjunctivitis in an affected Scottish terrier

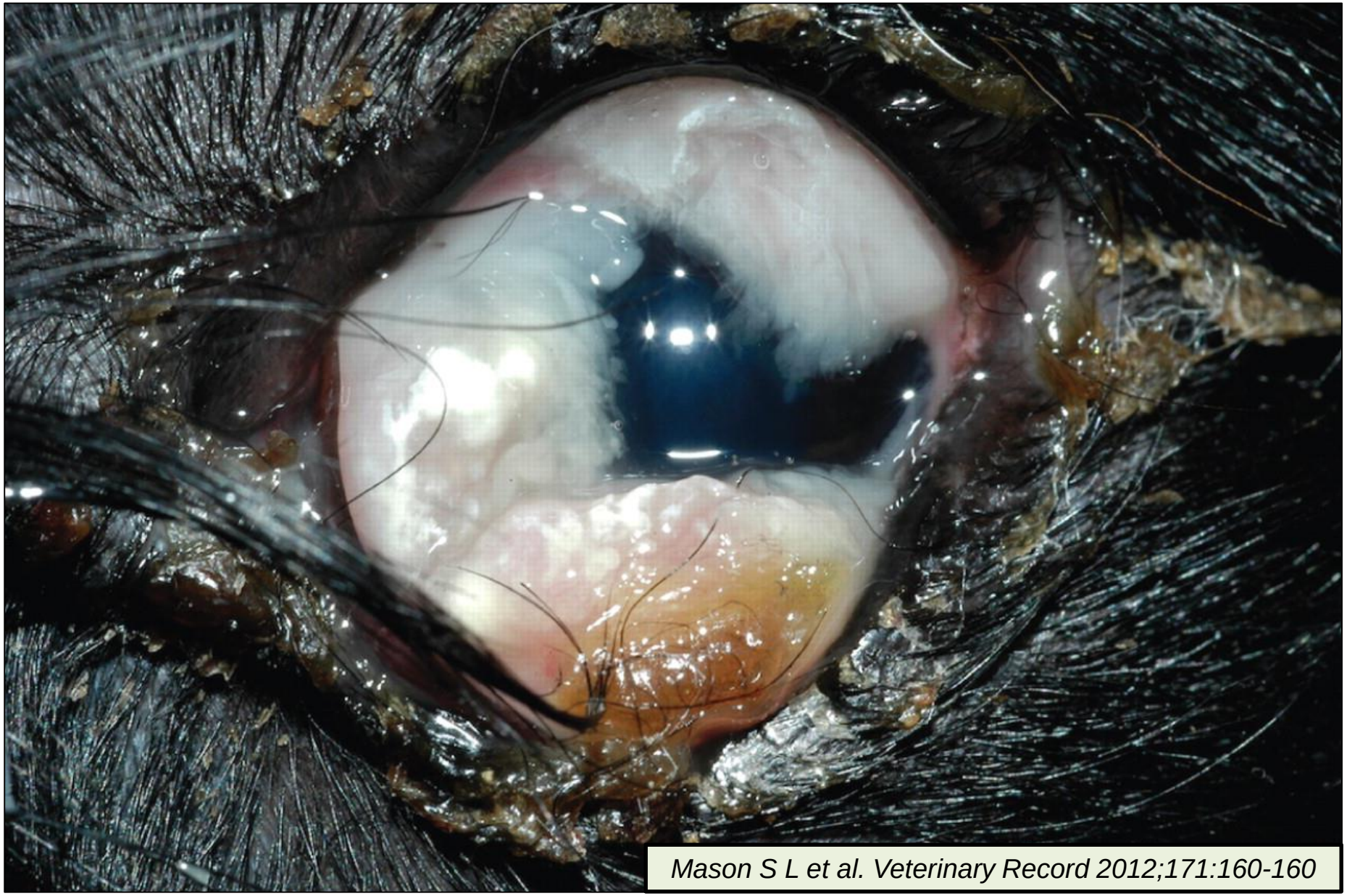

Mason S L et al. Veterinary Record 2012;171:160-160

Case 6
References

- Lotan TL, Tefs K, Schuster V, Miller J, Manaligold J, Filstead A, Yamada SD, Krausz T. Inherited plasminogen deficiency presenting as ligneous vaginitis: a case report with molecular correlation and review of the literature. Hum Pathol 2007; 38:1569-1575
- Schuster V et al. Plasminogen deficiency. J Thromb Haem 2007; 5:2315-2322
- Caputo R et al. Long-term efficacy of surgical removal of pseudomembranes in a child with ligneous conjunctivitis treated with plasminogen eyedrops. Thromb Haemost 2008; 100:1196-1198
- Pergantou H et al. Management of ligneous conjunctivitis in a child with plasminogen deficiency. Eur J Pediatr 2011, May
- Taube ET et al. Ligneous cervicitis in a woman with plasminogen deficiency associated with an atypical form of microglanular hyperplasia. Int J Gynecol Pathol 2013; 32:329-334

