# CERVICAL ADENOCARCINOMA AND PRECURSORS

**Simona Stolnicu**

**Professor of Pathology**

**University of Medicine and Pharmacy, Histopat-Invest Laboratory, Tirgu Mures, Romania**



# I. IN SITU ADENOCARCINOMA

# INTRODUCTION

- We are better in the diagnosis of squamous cervical lesions
- Squamous cervical lesions are more frequent
- Screening: higher prevalence of glandular lesions (less than SIL) and new entities described
- But also, the relative and real incidence of glandular lesions has increased

# INTRODUCTION

- 1952 Helper: described for the first time the precursor glandular lesions of the cervix
- 1957 Stewart: correlation between invasive and precursor glandular lesions
- Colposcopy and citology: difficult to evaluate
- Localization: transformation zone but also higher in the canal

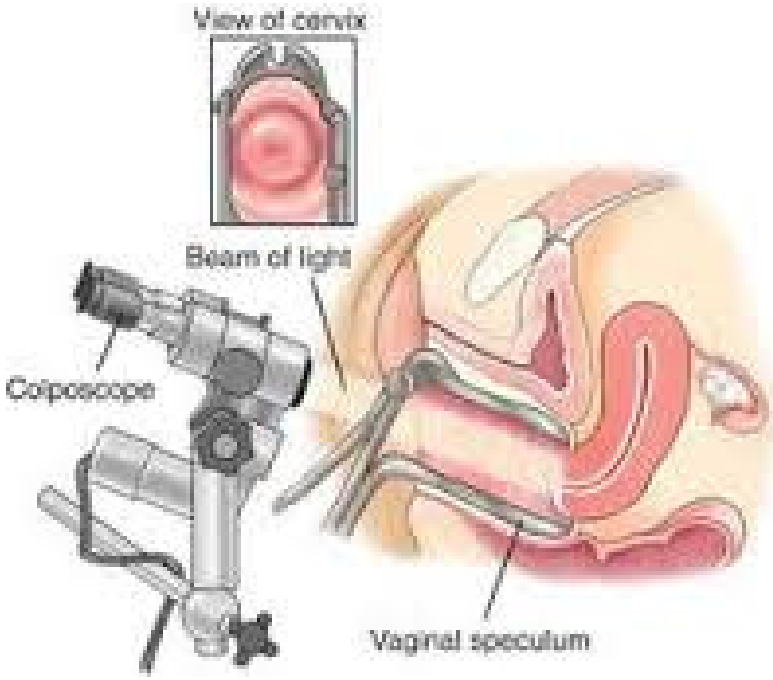

# LAST PROJECT

- Two-tier system to report squamous lesions of the ano-genital tract
- HPV-related squamous lesions are similar and management is similar
- Glandular lesions: not included

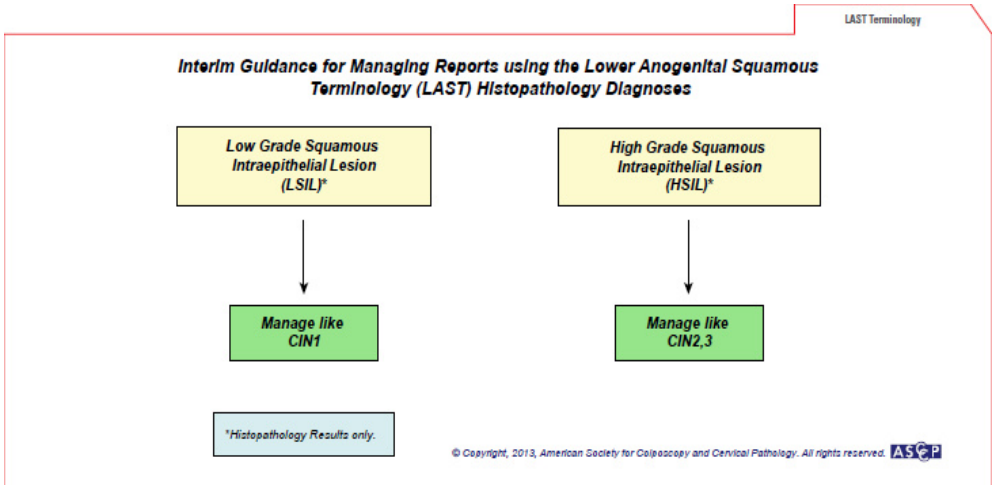

# WHO, 2014

- In situ endocervical adenocarcinoma (high-grade cervical glandular intraepithelial neoplasia HG-CGIN)
- LG-CGIN (dysplasia): lesions with cytological atypia less than HG-CGIN
- Poorly reproducible diagnosis for which criteria are not well defined and behavior is unknown
- The term “dysplasia” is not recommended and diagnosing LG-CGIN to be avoided

# ADENOCARCINOMA IN SITU-DEFINITION (1953; Friedell, Mackay)

- Preservation of normal glandular architecture
- Alteration of the epithelium lining the glands or surface (focally or entirely)
- Different type of architecture
- Mucin: reduced or abundant
- Stratification of nuclei
- Nuclear enlargement, coarse chromatin, small single or multiple nucleoli
- Mitoses and apoptotic bodies

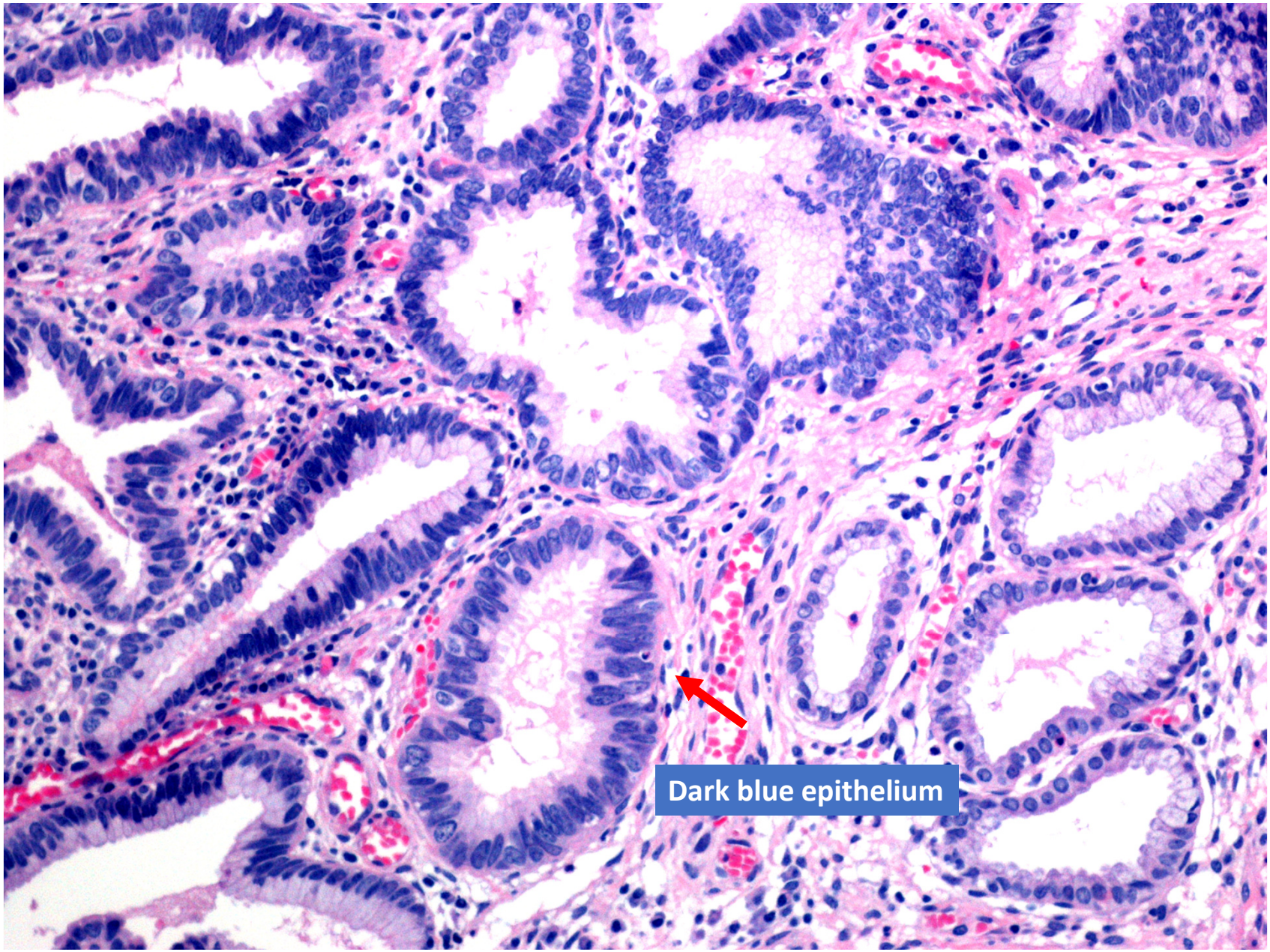
Dark blue epithelium

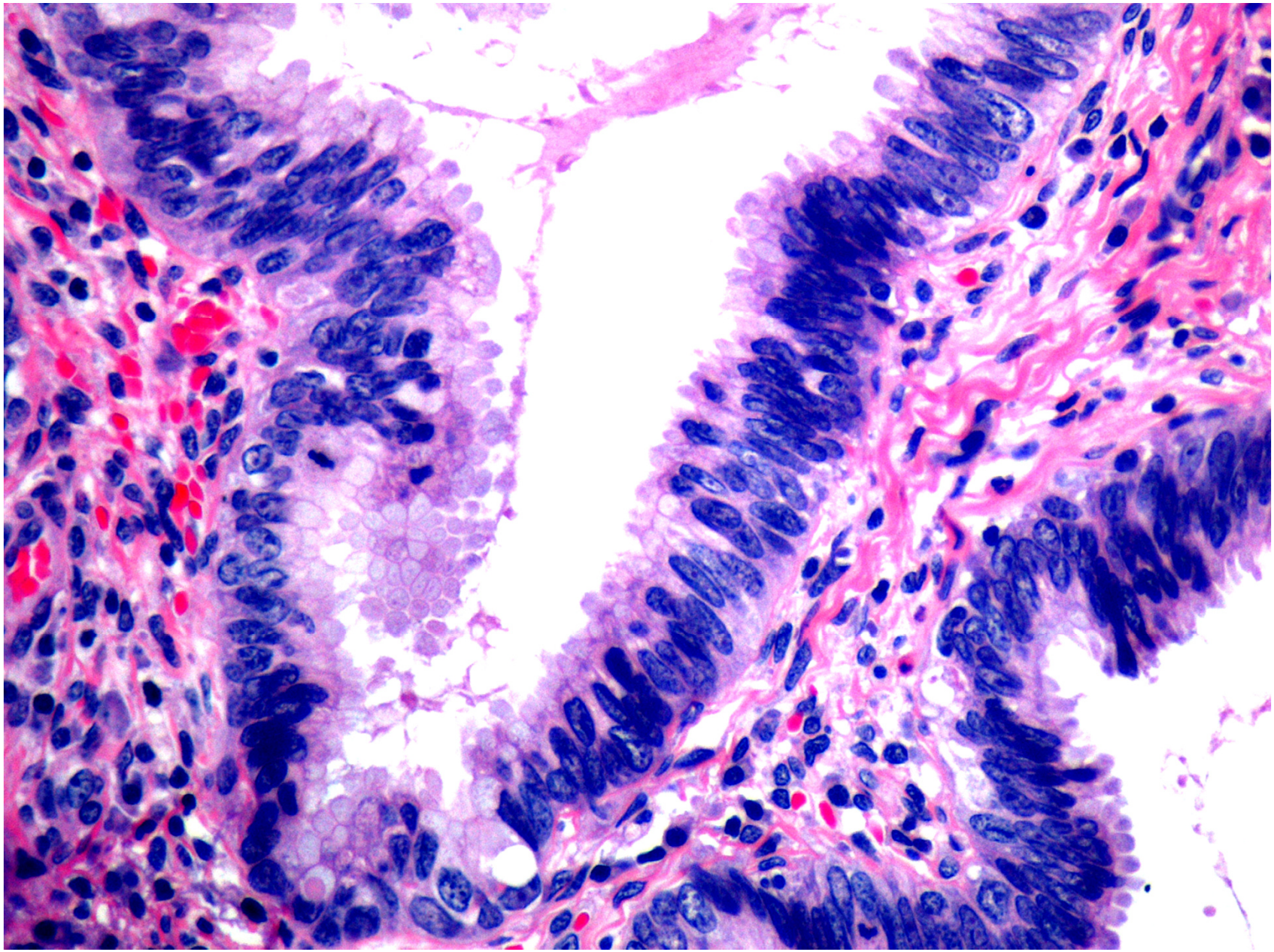

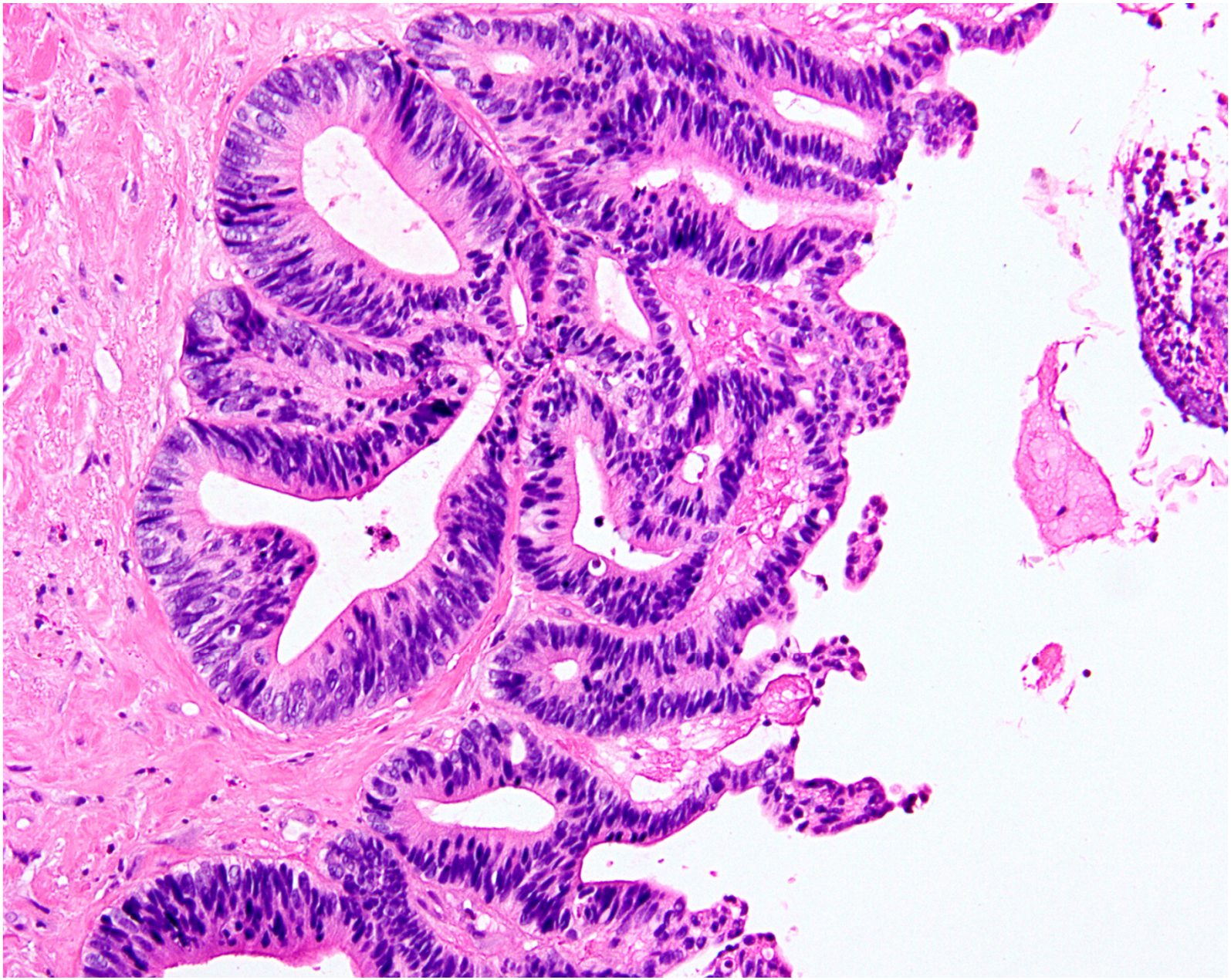

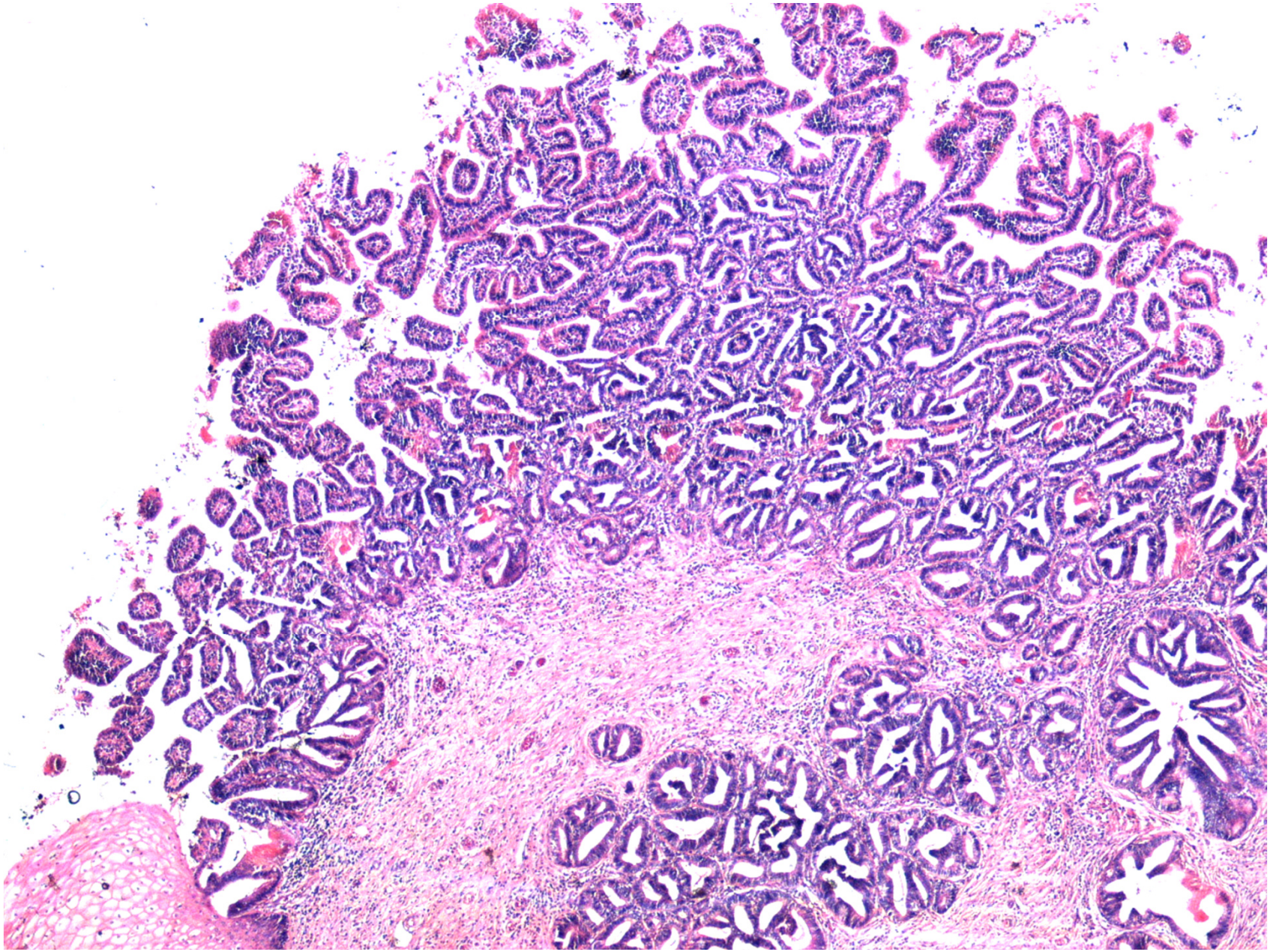

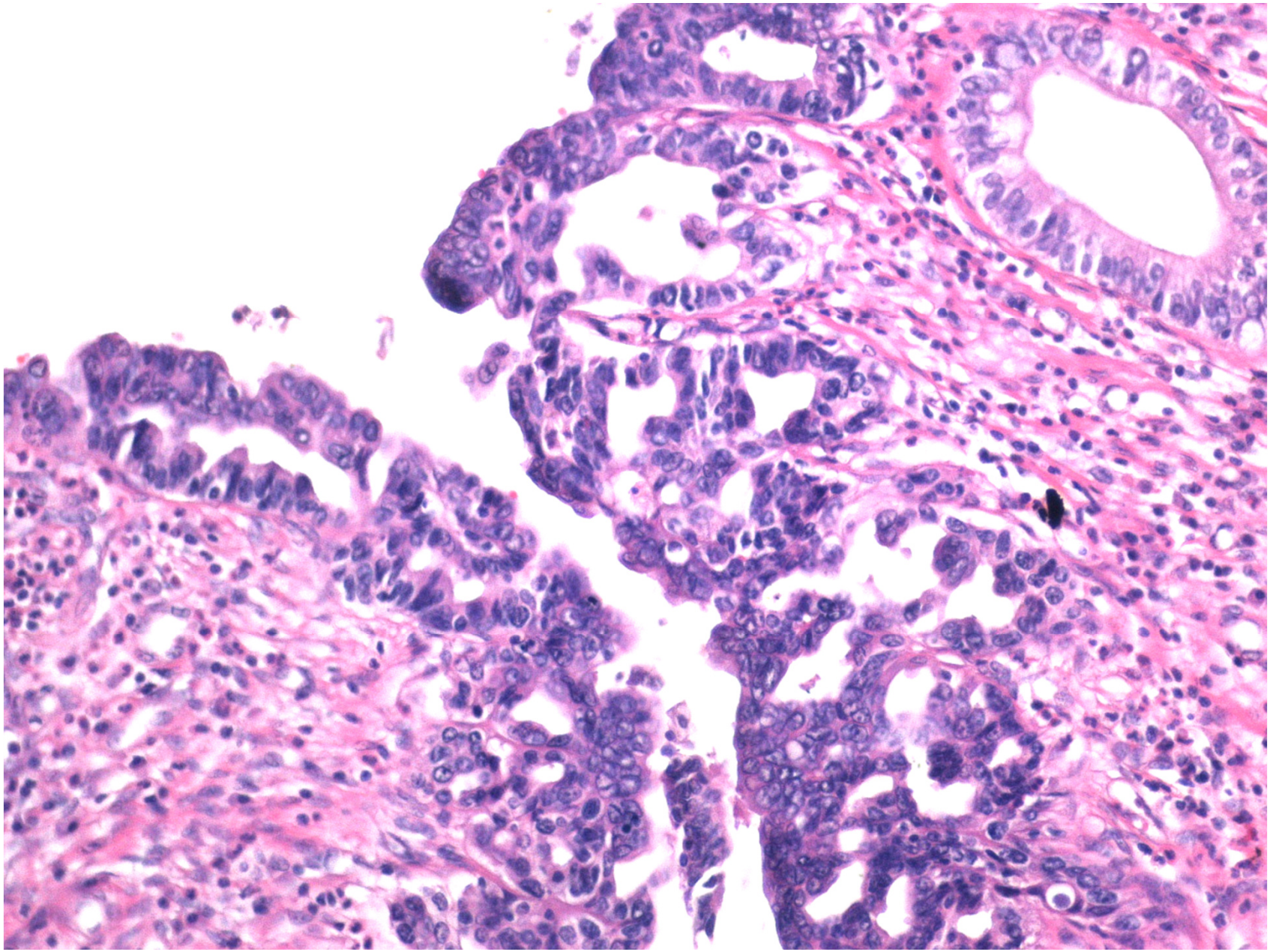

# ADENOCARCINOMA IN SITU- microscopic types (WHO 2014)

- **Endocervical/Usual (HPV+)**
- **Intestinal (HPV+)**
- **SMILE (stratified mucin-producing intraepithelial lesion) (HPV+)**

---

- **Endometrioid (HPV-?)**
- **Tubal/Ciliated? (HPV-?)**
- **Gastric (HPV-)**

# Adenocarcinoma in situ endocervical type: HPV+



# Adenocarcinoma in situ intestinal type: HPV+

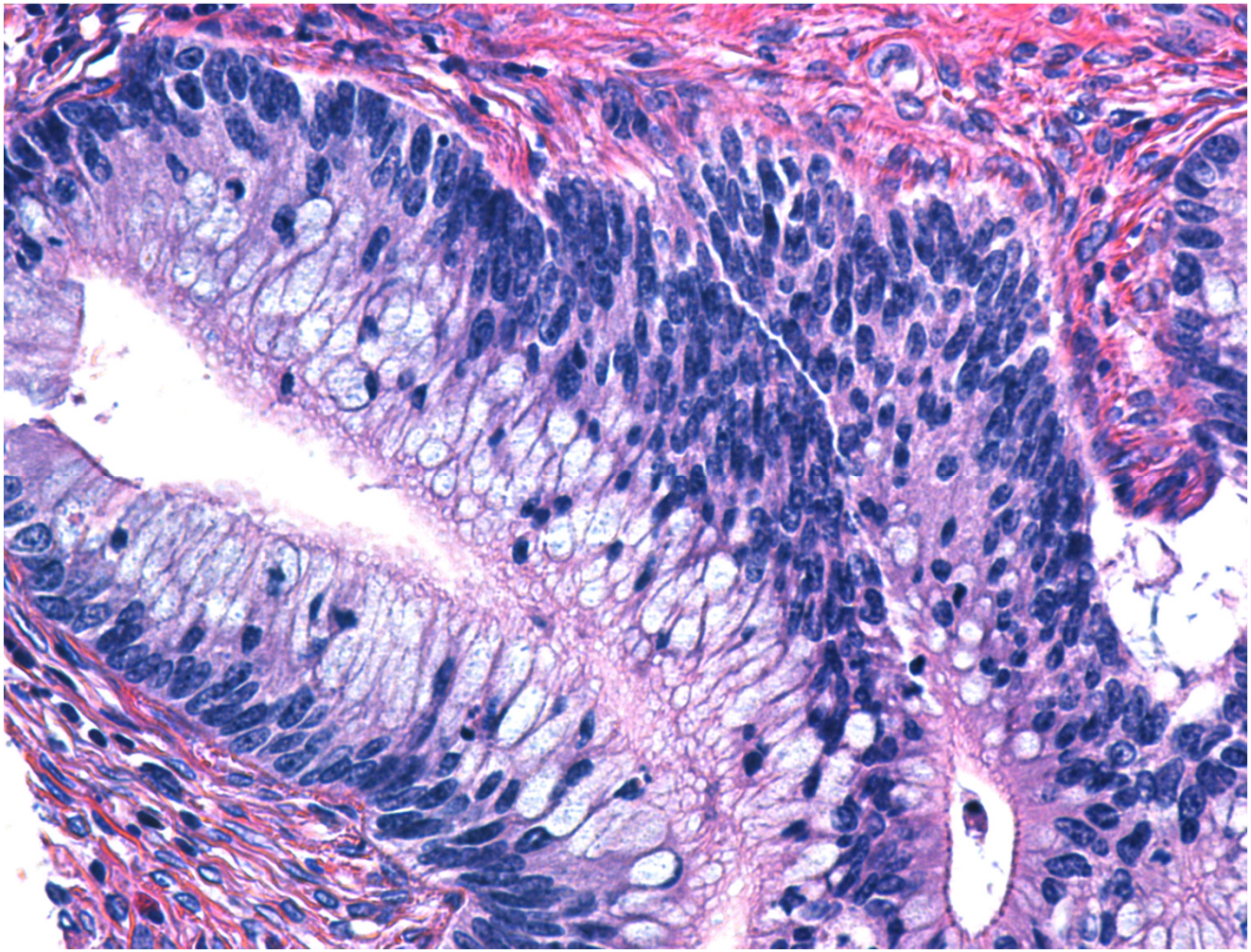

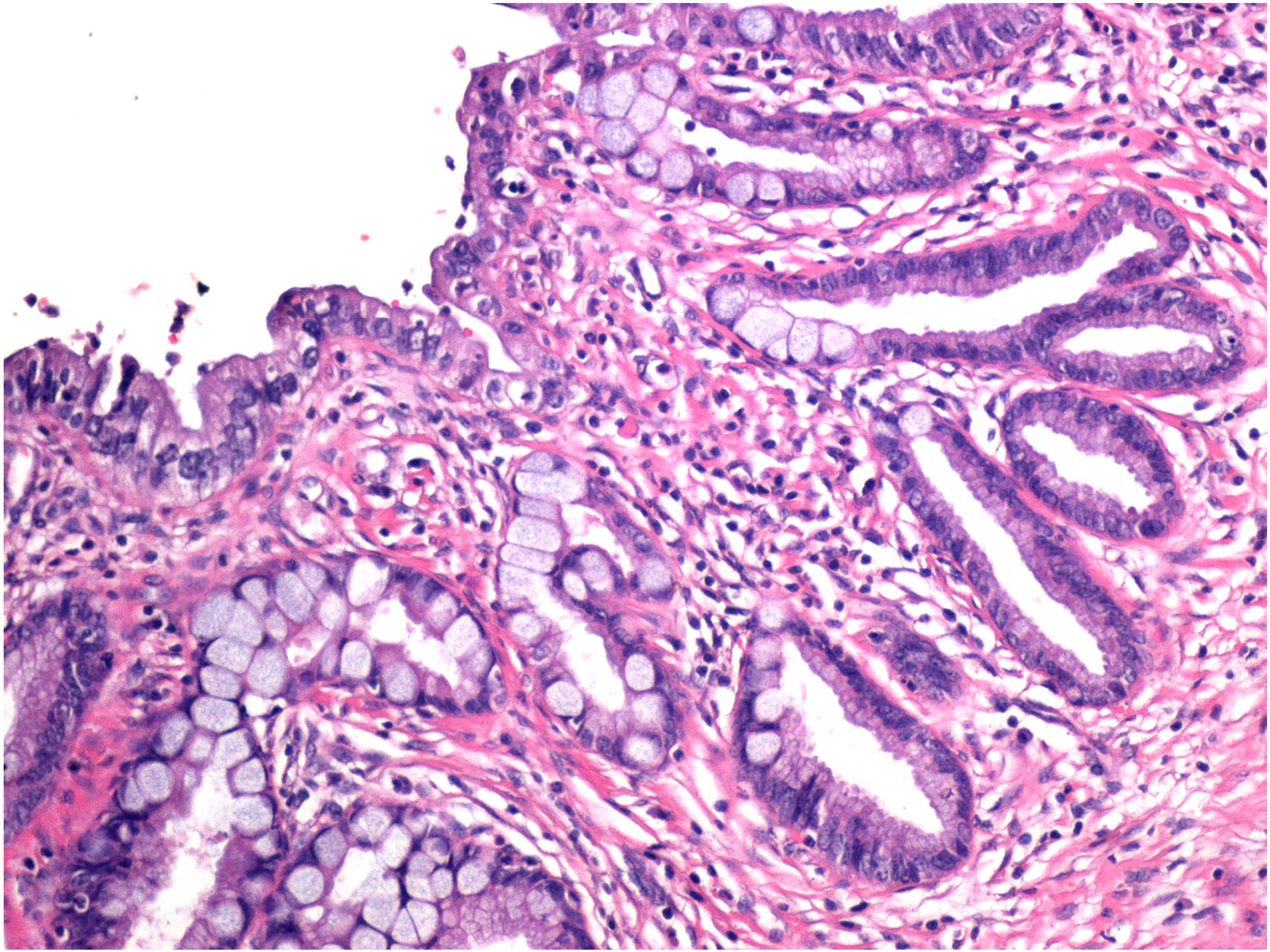

# Adenocarcinoma in situ SMILE type: HPV+

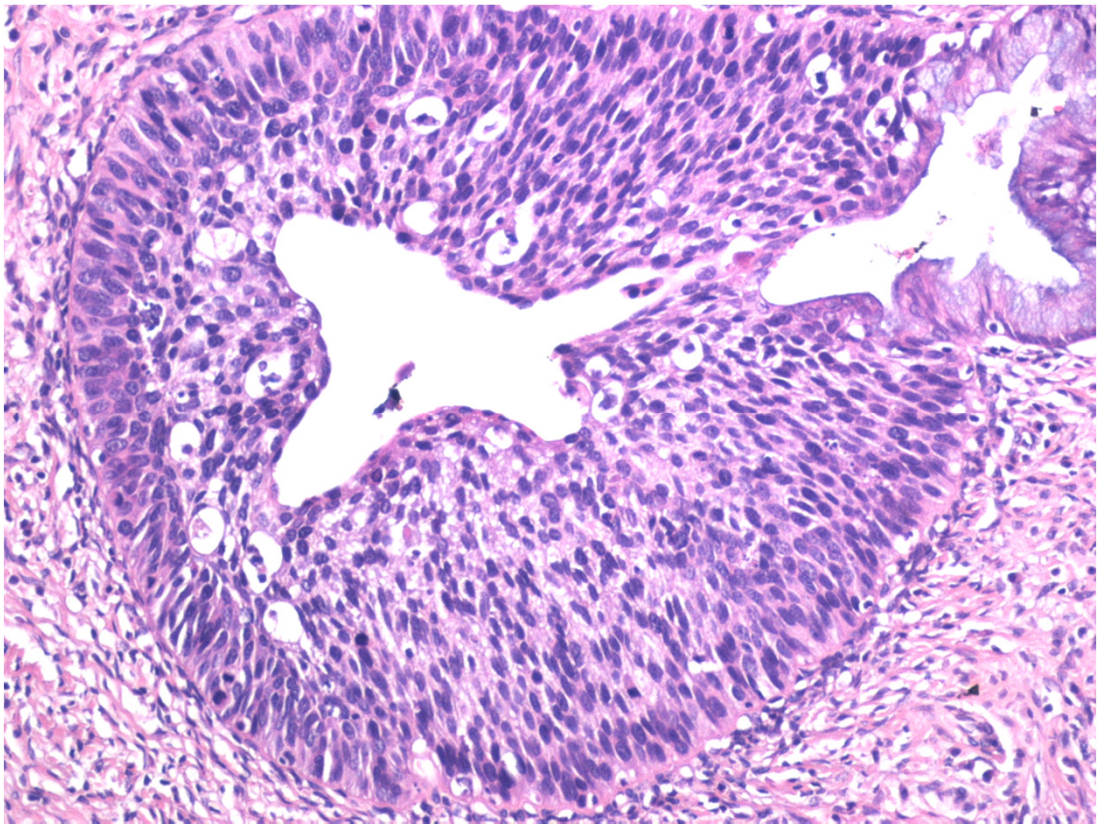

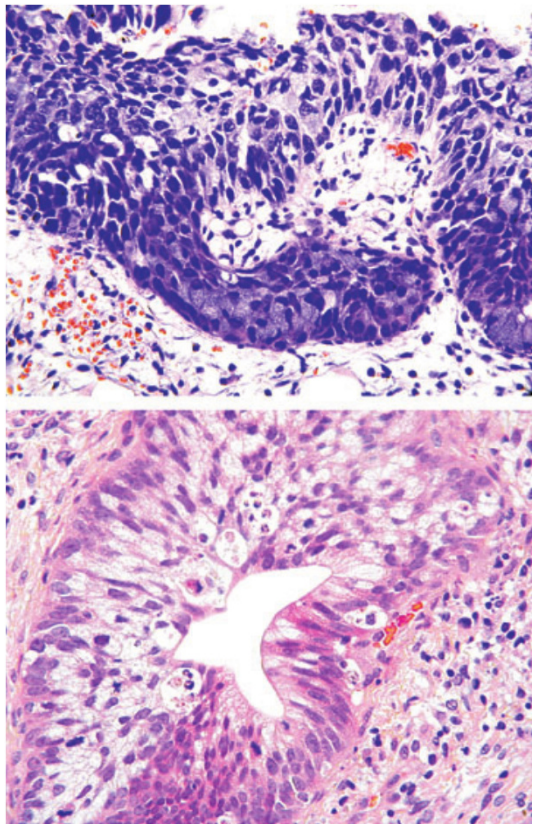

# Adenocarcinoma in situ endometrioid type: HPV-??

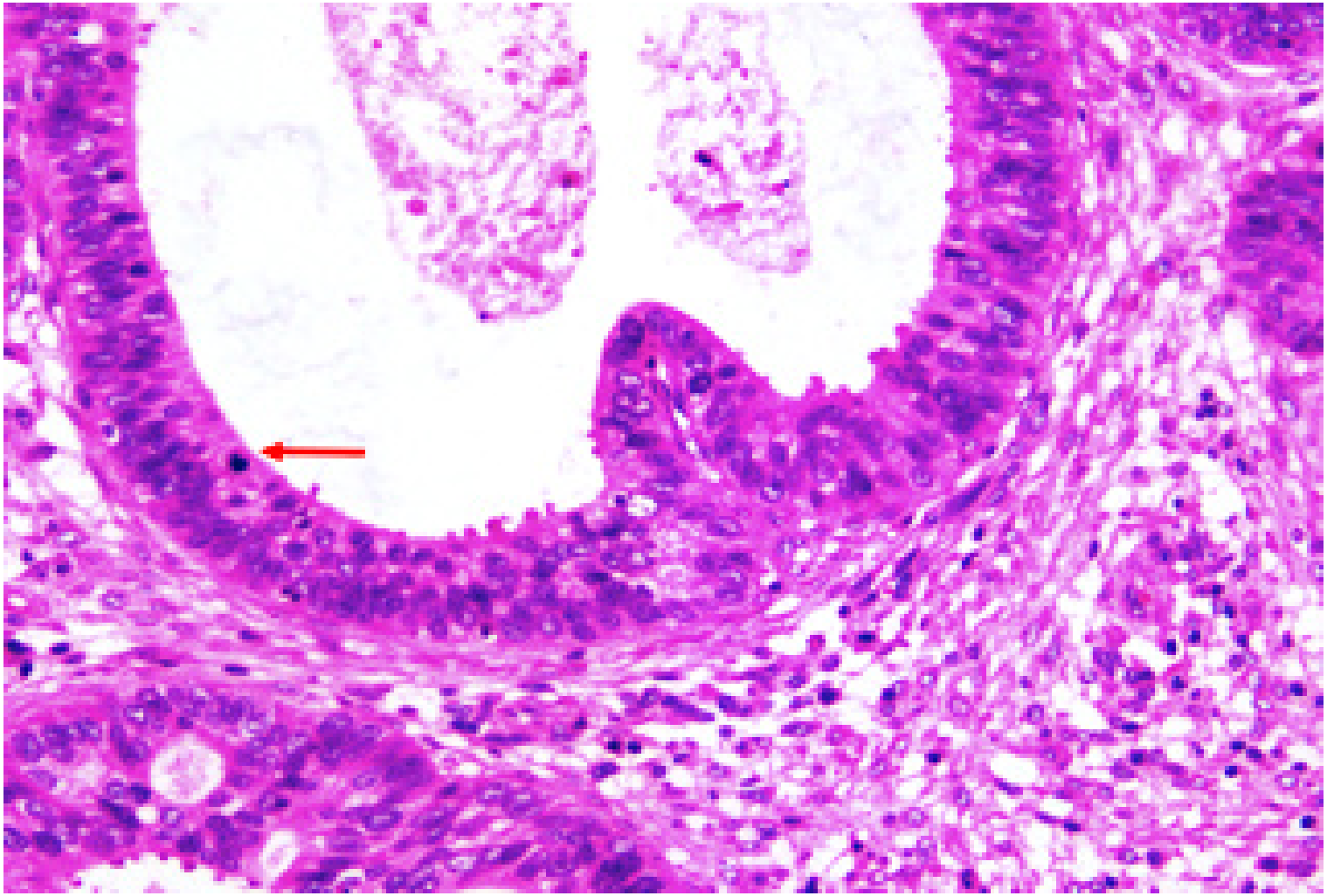

# Endocervical adenocarcinoma in situ of tubal type and its relation to atypical tubal metaplasia Schlesinger C and Silverberg, 1999, IntJGynecolPathol

- 11 cases showing tubal and other types of AIS arising in the background of tubal metaplasia are reported
- The relationship of atypical TM (dysplasia) to tubal-type AIS must be defined, and the latter pattern should be added to the known types of differentiation of cervical AIS
- HPV-??

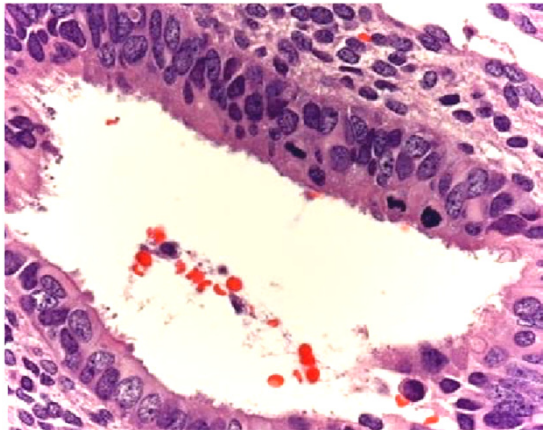

# HPV-negative gastric type adenocarcinoma in situ of the cervix: a spectrum of rare lesions exhibiting gastric and intestinal differentiation
Tale Kl et al, 2017, AmJSurgPathol

- 9 cases, older patients (mean: 51y)
- All cases located at or close to the transformation zone
- 3 cases with extension to the lower uterine segment
- Mixed gastric and intestinal type of cells
- Nuclear variable atypia present in all cases, mitoses and apoptosis rare
- HPV- in 100% of cases tested (4 cases)
- This lesion together with atypical lobular endocervical glandular hyperplasia: gAIS
- Malignant potential and optimal treatment unknown

# Adenocarcinoma in situ gastric type: HPV-

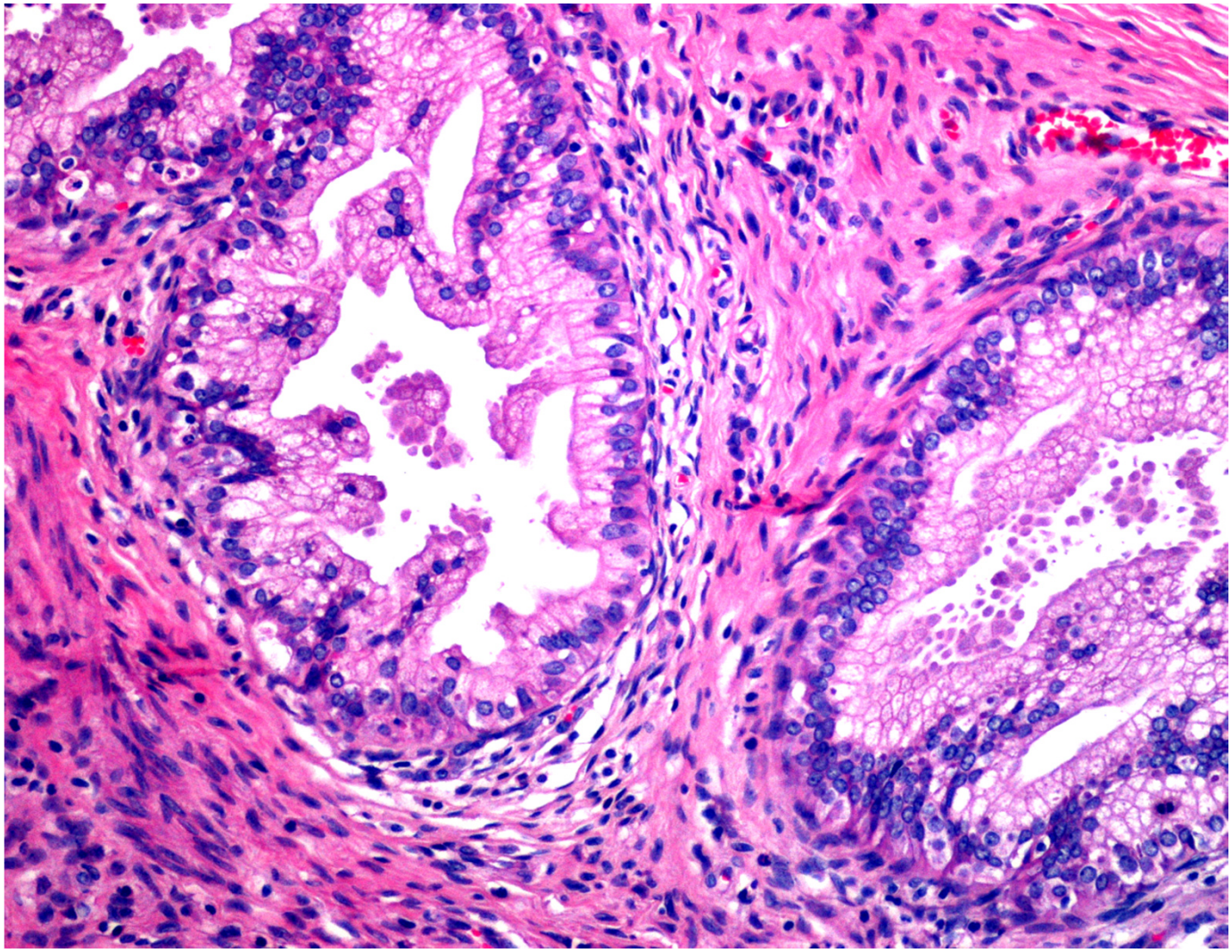

# HPV-negative gastric type adenocarcinoma in situ of the cervix

- Most lesions described in the paper are LEGH with atypia
- So: LEGH with atypia is similar to in situ adenocarcinoma of gastric type
- But gastric atypia without LEGH has not been described yet
- Cytologic abnormalities on Pap smear related to NHPV lesions have not been decribed yet
- Mucin type marker in Japan on Pap smears to detect gastric type precursor lesions (HPV-)

# ANCILARRY STUDIES FOR DIAGNOSIS OF IN SITU ADENOCARCINOMA

- **p16: diffuse intense positivity (block-like)**
- **Ki67 (MIB1 index): + over 50% of cells**
- Apoptosis index: high
- ER, PR: negative
- Bcl-2: negative
- PAX2 negative

# p16

- Not expressed in normal epithelium otherwise than patchy

- It is expresses in lesions associated with HPV infection (sensitive and specific diagnostic marker of HRHPV infection)

# p16 in glandular lesions of the cervix: nuclear and cytoplasmatic

| **Lesion** | **p16 immunostain** |
|---|---|
| AIS | +++ (more than 90%) |
| Normal/reactive | -- |
| Microglandular hyperpl. | --/+ |
| Lobular endocervical hyp. | +/++ |
| Tubo-endometrioid met. | +/- (focal) |
| Endometrioisis | ++/- |
| Endometrium | ++/- |

# MIB1 in glandular lesions
# McCluggage 1995

| **Lesion** | **% +MIB** | **Range (%)** |
|---|---|---|
| Normal | 1 | 0-8 |
| Tubo-endo metaplasia | 4 | 0-21 |
| AIS | 48 | 15-88 |
| Acc invasive | 60 | 24-96 |

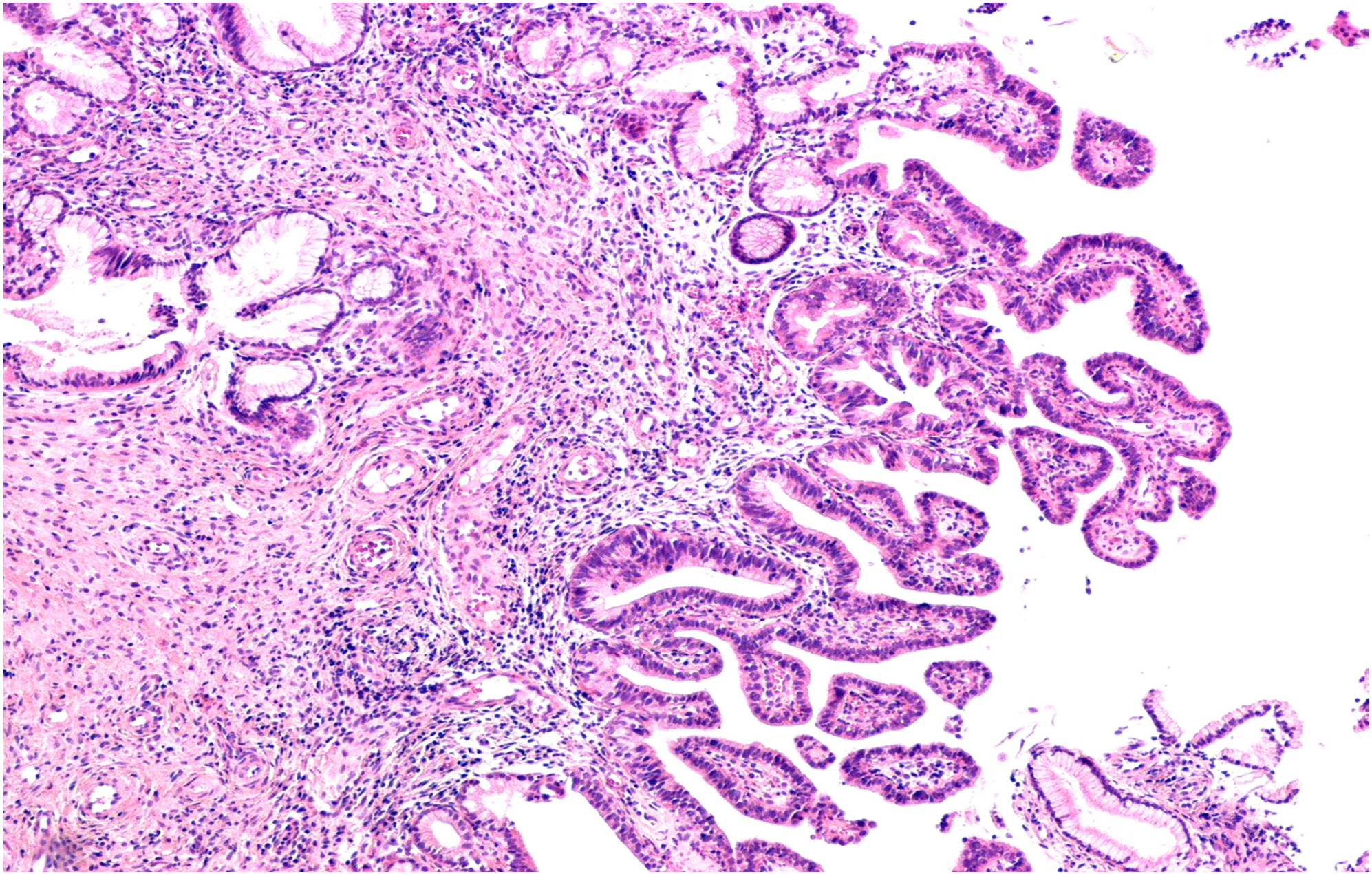

# p16

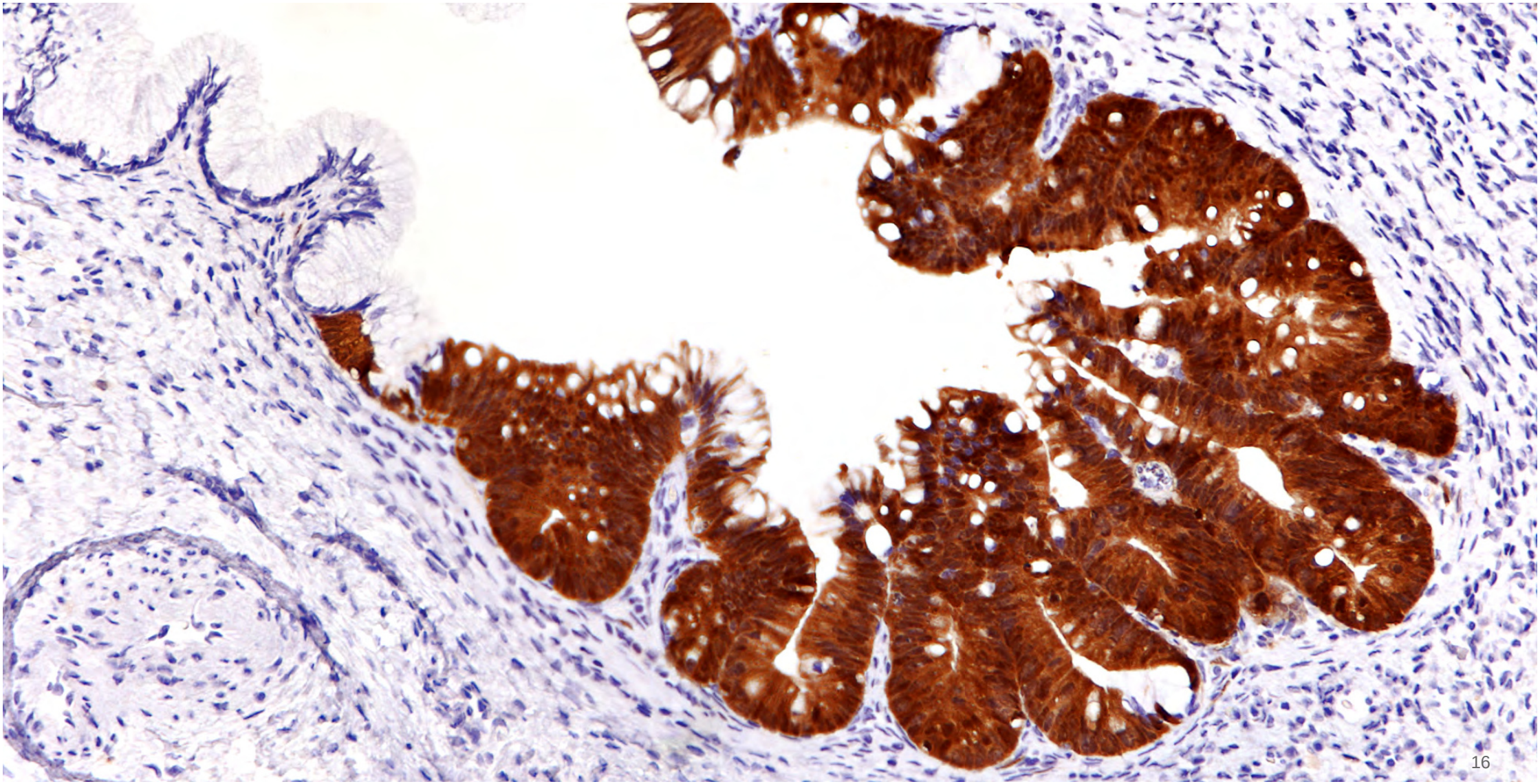

# ki 67

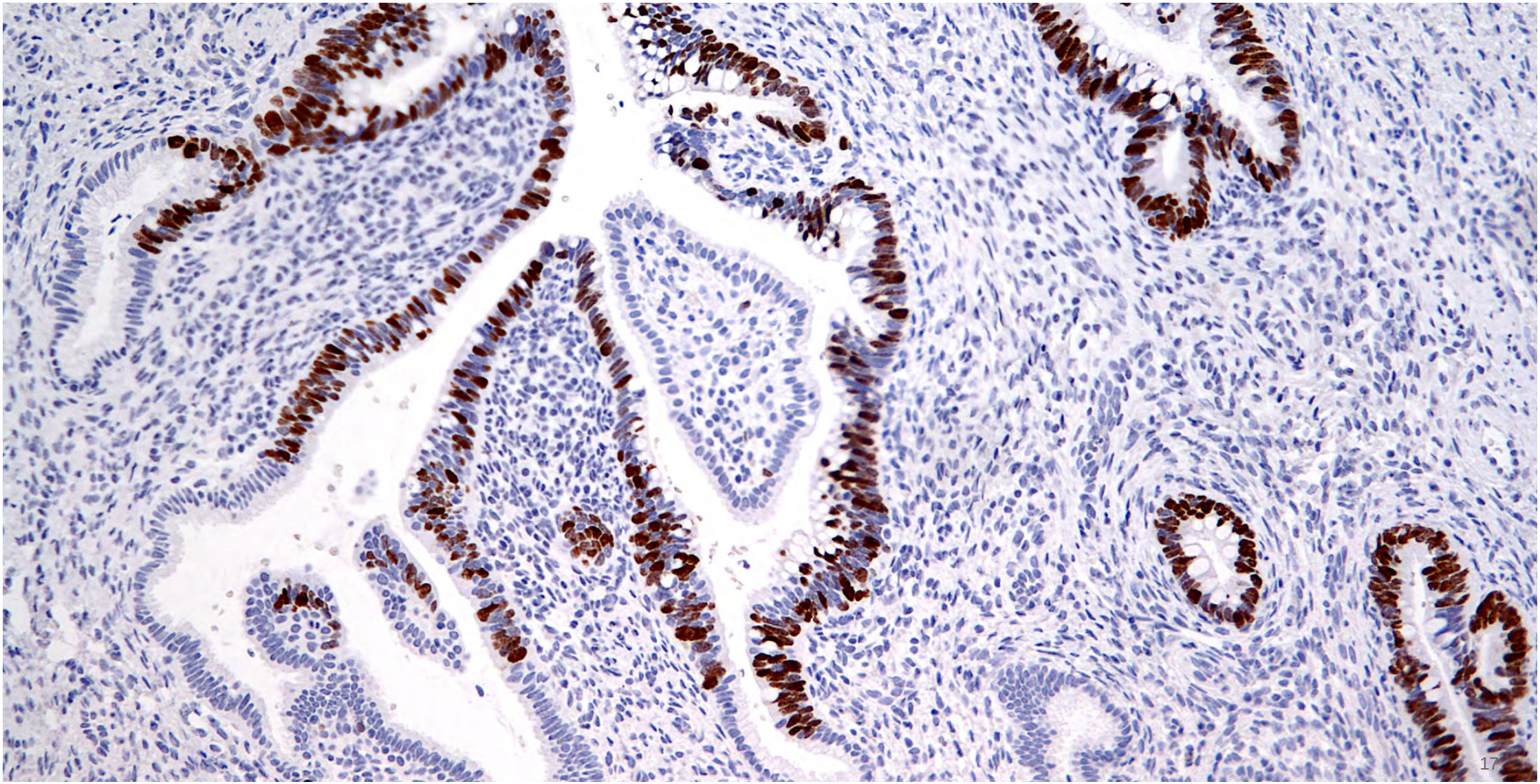

# Ancillary studies

- p16 is not predictive or prognostic
- Any p16++ area must meet H&E morphologic criteria for a high-grade lesion to be interpreted as such
- Report p16-positivity as: **presence** (diffuse block+) or **absence** (negative or patchy) (same as for SIL)
- Concurrent routine ki67 is not recommended but is useful in specific cases

# MIMICS OF AIS: p16 patchy, low ki67 index

- Atypia of repair, inflammation
- Radiation-induced atypia
- Immature sq. metaplasia
- Microglandular hyperplasia
- Mesonephric hyperplasia
- Tubo-endometrioid metaplasia
- Cervical endometriosis
- Arias-Stella reaction

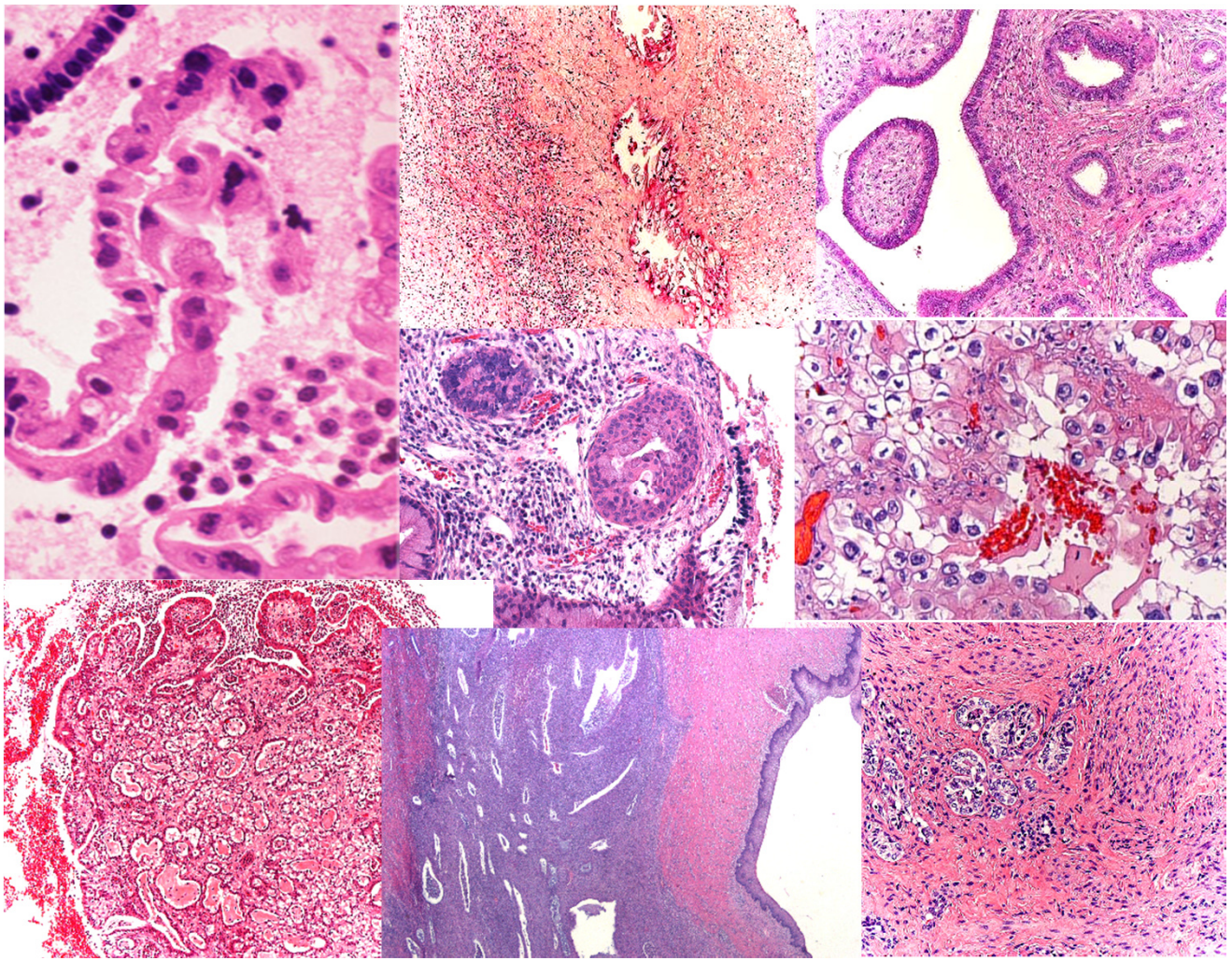

# II. INVASIVE ADENOCARCINOMA

# Introduction

- Prevalence of invasive adenocarcinomas of the cervix has increased in the last decades
- Most frequent subtype of invasive adenocarcinoma of the endocervix (ECA) (WHO, 2014): usual type invasive adenocarcinoma (HPV-related)
- Other morphological subtypes, some of them non- HPV-associated (15%)

# Introduction

- Gastric-type ECA: the second most frequent subtype (WHO, 2014)
- Almost always HPV-unassociated
- Listed as a subtype of "mucinous ECA," itself a combination of HPV-positive and –negative adenocarcinomas
- Gastric-type: important differences in behavior and survival (worse outcome, mets to distant organs, resistant to chemotherapy)

- Usual (WHO, 2014): cells with “relative” mucin depletion; how much mucin to be considered usual vs mucinous vs endometrioid? **Cut off threshold is missing**

- In the routine practice: endometrioid type is frequently diagnosed

- ECAs are currently classified (WHO, 2014) by vague and descriptive **morphologic features** (specifically cytoplasmic) assessed on H&E stained slides lacking clinical and/or pathogenetic correlations

# Adenocarcinoma subtypes: is there a better way????

**WHO 2003**

- Mucinous
  - Endocervical
  - Intestinal
  - Signet ring cell
  - Minimal deviation
- Villoglandular
- Endometrioid
- Clear cell
- Serous
- Mesonephric

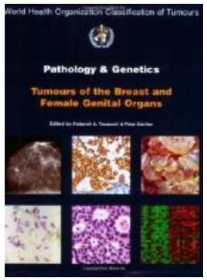


**WHO 2014**

- Usual
- Mucinous
  - Intestinal
  - Signet ring cell
  - Gastric (includes minimal deviation)
- Villoglandular
- Endometrioid
- Clear cell
- Serous
- Mesonephric

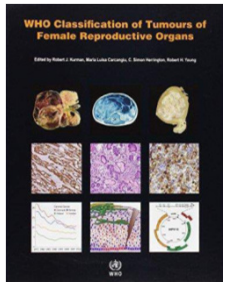

# International Endocervical Adenocarcinoma Criteria and Classification (IECC)

## *A New Pathogenetic Classification for Invasive Adenocarcinomas of the Endocervix*

*Simona Stolnicu, MD,* Iulia Barsan, MD,* Lien Hoang, MD,† Prusha Patel, MPH,‡ Cristina Terinte, MD,§ Anna Pesci, MD,‖ Sarit Aviel-Ronen, MD,¶ Takako Kiyokawa, MD,# Isabel Alvarado-Cabrero, MD,** Malcolm C. Pike, PhD,‡ Esther Oliva, MD,†† Kay J. Park, MD,‡ and Robert A. Soslow, MD‡*

An international panel of pathologists has been studying ECAs (USA, Romania, Japan, Mexico, Italy, Israel)

- Using evaluation of tumor **morphology** but also **modern diagnostic techniques** including immunohistochemistry and HPV evaluation (in situ hybridization)
- Aim: to classify ECAs by using an iterative process based on morphological features **linked to etiology** (i.e. HPV infection)- *in contrast to the 2014 WHO classification*

# International Endocervical Adenocarcinoma Criteria and Classification (IECC)

**HPVA**
**HPV-Associated-ECA**

→ Apical mitotic features and apoptotic bodies at scanning magnification

**NHPVA**
**Non-HPV-Associated-ECA**

→ No easily identified mitoses and apoptosis at scanning magnification

HPVA: subcategorized based on cytoplasmic features, mostly to provide continuity with pre-existing classification schemes (i.e. usual, mucinous, adenosquamous, etc)

NHPVA: subclassified based on published criteria defining morphologically, etiologically and phenotypically unified diagnostic entities (i.e. gastric, clear cell, etc)

# HPVA

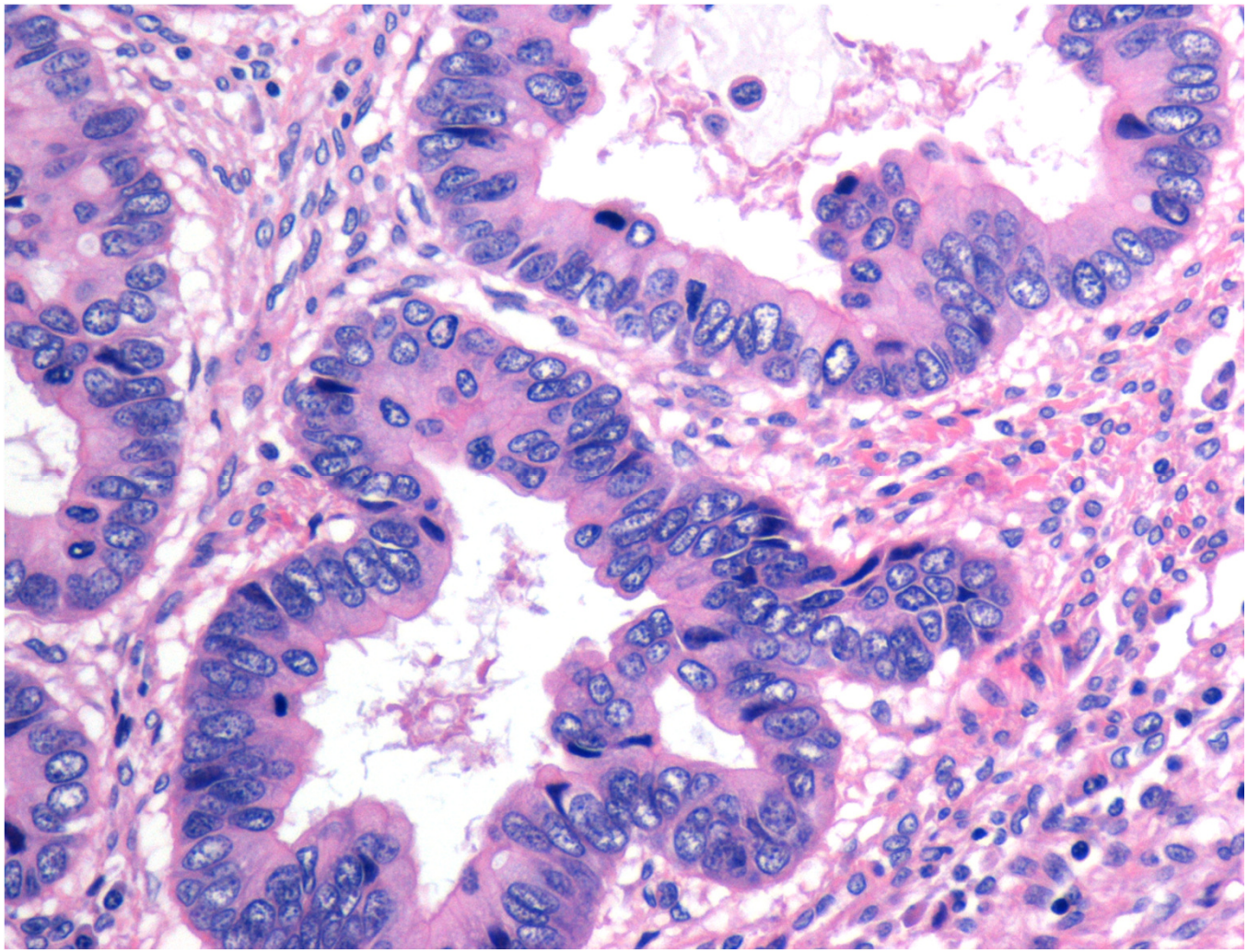

# NHPVA

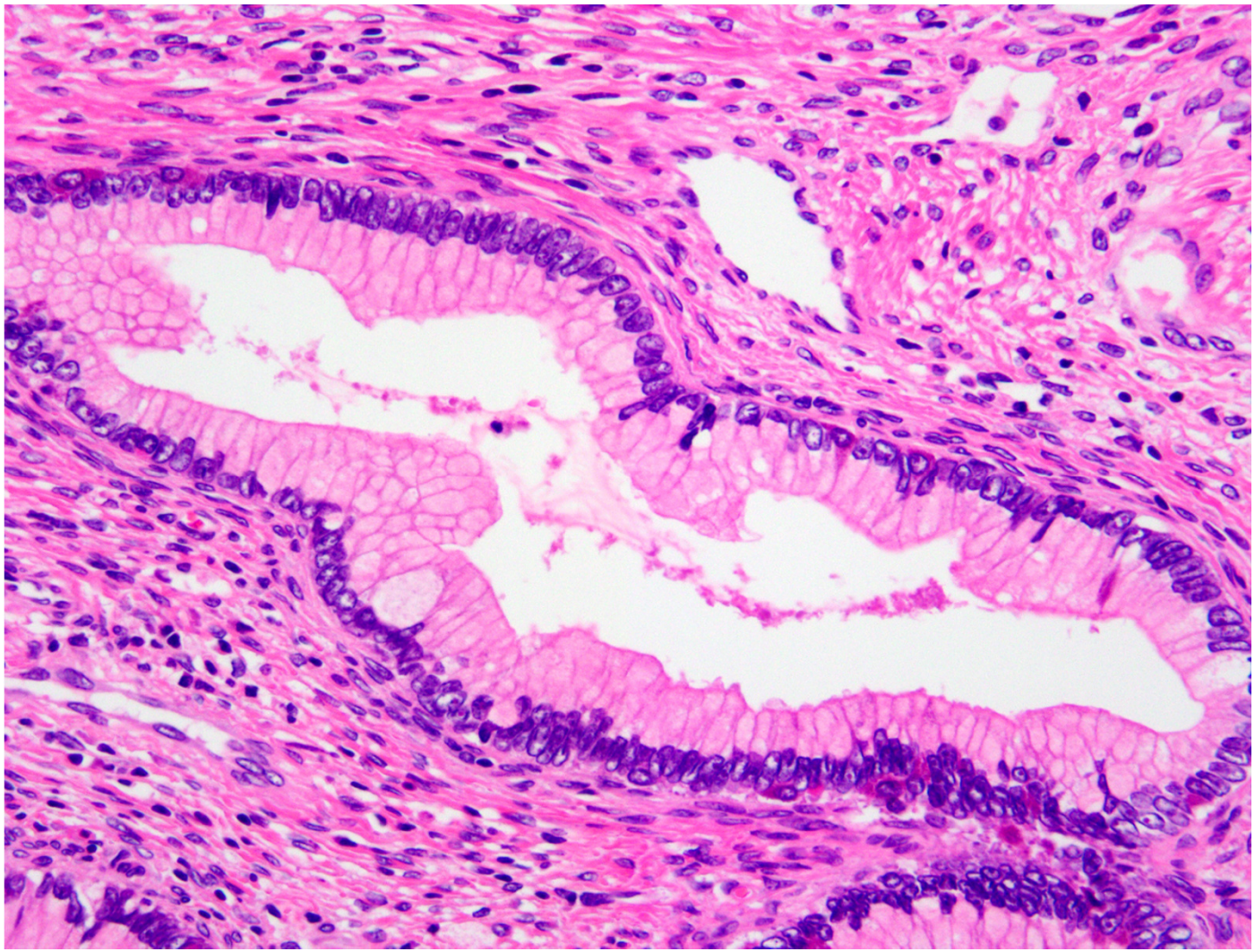

# Stolnicu et.al.,Virchows Arch, IECC Classification updated 2019

**HPV associated (HPVA)**

- **Usual**
- **Mucinous**
- **Adenocarcinoma NOS (HPV+)**

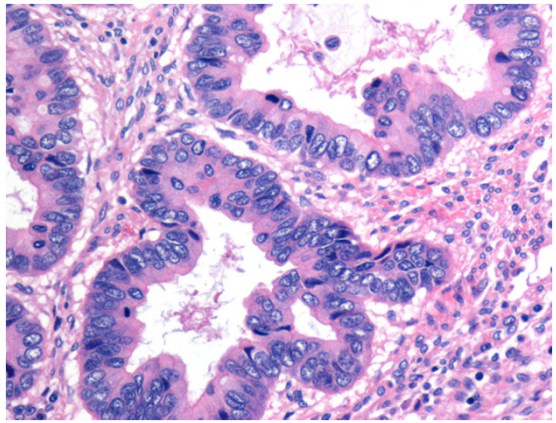

**HPV unassociated* (NHPVA)**

- **Gastric**
- **Clear cell**
- **Endometrioid**
- **Mesonephric**
- **Adenocarcinoma NOS (HPV-)**

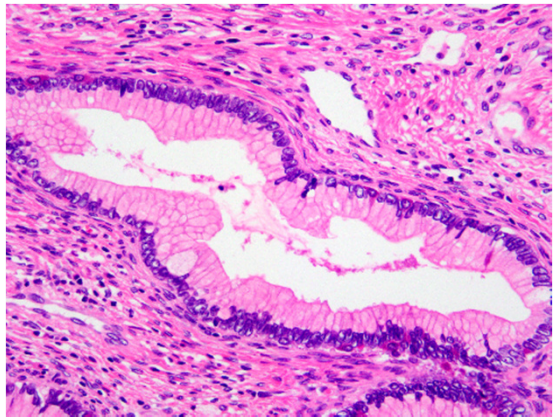

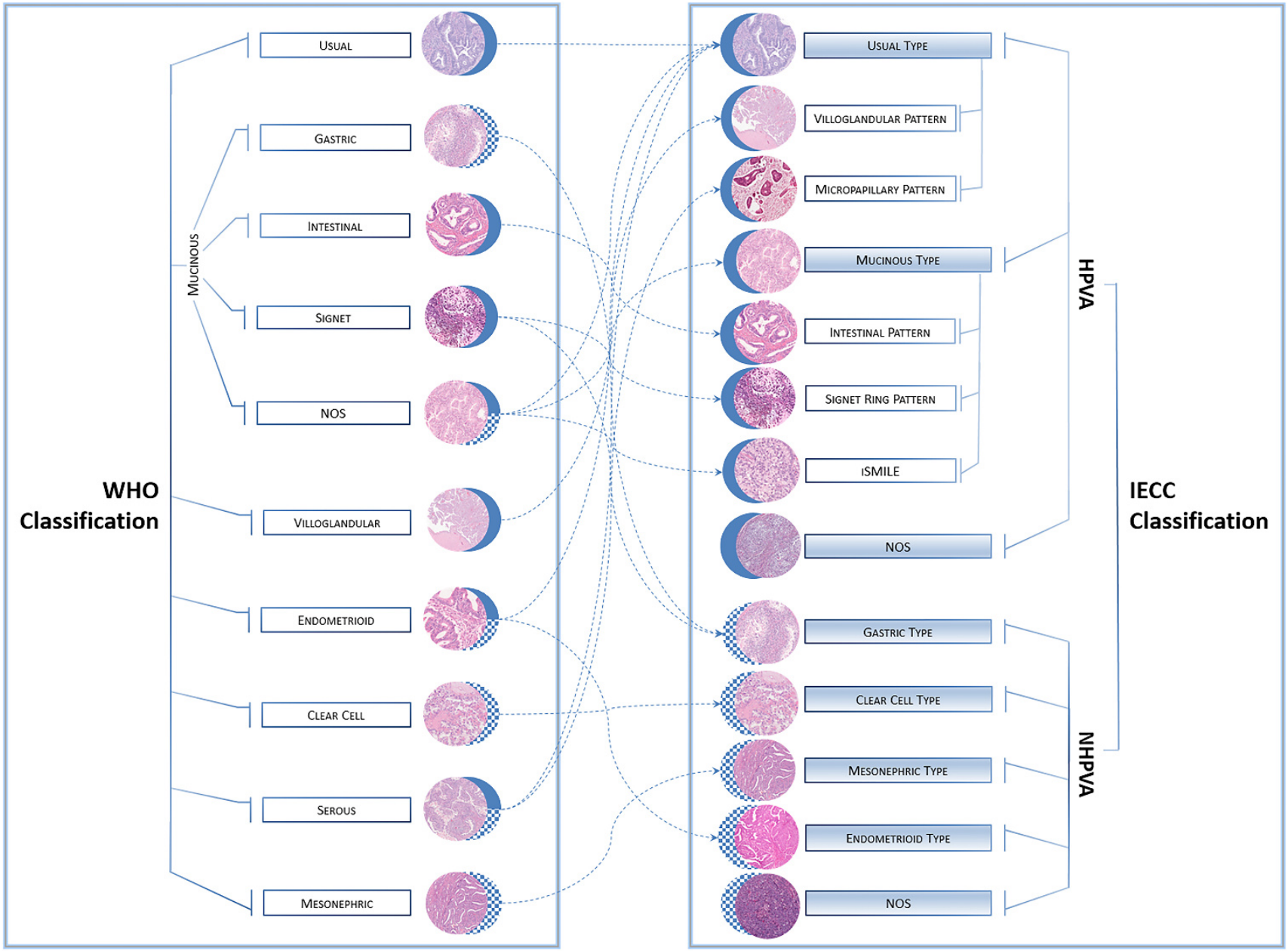
WHO Classification
Mucinous
Usual
Gastric
Intestinal
Signet
NOS
Villoglandular
Endometrioid
Clear Cell
Serous
Mesonephric
IECC Classification
HPVA
Usual Type
Villoglandular Pattern
Micropapillary Pattern
Mucinous Type
Intestinal Pattern
Signet Ring Pattern
ISMILE
NOS
NHPVA
Gastric Type
Clear Cell Type
Mesonephric Type
Endometrioid Type
NOS

**IECC 2019**

# Clinical and demographic features

# Clinical and demographic features of IECC-classified cases

| | SUBTYPES | AGE, N | AGE, median (IQR) | TUMOR SIZE, N | TUMOR SIZE, median (IQR) | TUMOR STAGE, N | TUMOR STAGE, I% | TUMOR STAGE, II% | TUMOR STAGE, III% | TUMOR STAGE, IV% |
|---|---|---|---|---|---|---|---|---|---|---|
| HPVA | USUAL | 272 | 42 yrs (37-53) | 201 | 23 mm (11-37) | 254 | 92 | 6.3 | 1.6 | 0.4 |
| HPVA | MUCINOUS NOS | 11 | 41 yrs (32-50) | 8 | 11 mm (4-20) | 10 | 80 | 10 | 10 | |
| HPVA | MUCINOUS INTESTINAL | 11 | 36 yrs (32-49) | 10 | 5 mm (2-15) | 11 | 73 | 27 | - | - |
| HPVA | MUCINOUS SIGNET RING | 1 | 50 yrs | 1 | 9 mm | 1 | 100 | | | |
| HPVA | INVASIVE SMILE | 9 | 45 yrs (35-51) | 8 | 16 mm (8-27) | 9 | 100 | - | - | - |
| HPVA | VILLOGLANDULAR | 3 | 34 yrs (31-39) | 1 | 8 mm | 3 | 100 | - | - | - |
| | ADENOCARCINOMA NOS | 9 | 48 yrs (43-58) | 7 | 33 mm (15-45) | 9 | 33 | 44 | 11 | 11 |
| NHPVA | GASTRIC | 37 | 54 yrs (42-66) | 25 | 38 mm (21-55) | 35 | 49 | 43 | 8.6 | - |
| NHPVA | CLEAR CELL | 11 | 56 yrs (33-75) | 9 | 33 mm (28-44) | 10 | 60 | 40 | - | - |
| NHPVA | ENDOMETRIOID | 4 | 61 yrs (49-67) | 3 | 40 mm (30-45) | 2 | 100 | - | - | - |
| NHPVA | SEROUS | 2 | 64 yrs (59-69) | 1 | 44 mm | 2 | - | 100 | - | - |
| NHPVA | MESONEPHRIC | 1 | 52 yrs | 1 | 2 mm | 1 | 100 | - | - | - |

NHPVA tumors occurred in significantly older patients and were larger than HPVA tumors ($p<0.001$ for both measures). 51% of gastric-type presented at FIGO stage II or higher

# p16/HPV status

# IECC 2017, RESULTS

| IECC (%) N=371 (9.3% adenosquamous excluded) | |
|---|---|
| **USUAL** | **74%** |
| Usual type | 73% |
| Villoglandular type | 0.8% |
| **MUCINOUS HPV+** | **8.7%** |
| Intestinal | 3% |
| Mucinous NOS | 3% |
| iSMILE | 2.4% |
| Signet ring | 0.3% |
| **GASTRIC (MUCINOUS HPV-)** | **10%** |
| **CLEAR CELL** | **3%** |
| **ENDOMETRIOID** | **1.1%** |
| **SEROUS** | **0.5%** |
| **MESONEPHRIC** | **0.3%** |
| **ADENOCARCINOMA NOS** | **2.4%** |

**HPV positive 82.7%**

**HPV negative 14.9%**

# Prognostic parameters

# The Silva system: 2013

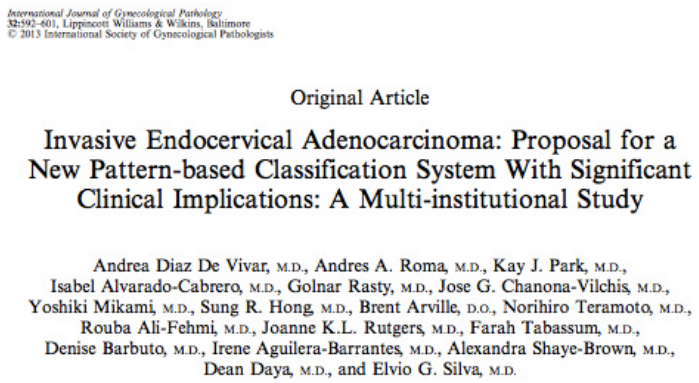

International Journal of Gynecological Pathology
32:592–601, Lippincott Williams & Wilkins, Baltimore
© 2013 International Society of Gynecological Pathologists

Original Article

Invasive Endocervical Adenocarcinoma: Proposal for a New Pattern-based Classification System With Significant Clinical Implications: A Multi-institutional Study

Andrea Diaz De Vivar, M.D., Andres A. Roma, M.D., Kay J. Park, M.D., Isabel Alvarado-Cabrero, M.D., Golnar Rasty, M.D., Jose G. Chanona-Vilchis, M.D., Yoshiki Mikami, M.D., Sung R. Hong, M.D., Brent Arville, D.O., Norihiro Teramoto, M.D., Rouba Ali-Fehmi, M.D., Joanne K.L. Rutgers, M.D., Farah Tabassum, M.D., Denise Barbuto, M.D., Irene Aguilera-Barrantes, M.D., Alexandra Shaye-Brown, M.D., Dean Daya, M.D., and Elvio G. Silva, M.D.

- As an alternative to evaluation of the depth of invasion (DOI) for staging purposes
- Identification of 3 subgroups of tumors: A, B, C
- Distinct pattern of invasion
- Different clinical behavior

| | Nr patients | Total +/resected LN | Total patients with + LN | Stage I | Stage II-IV |
|---|---|---|---|---|---|
| **Standard** | 352 | 78/6506 | 49 (13.9%) | 311 (88.3%) | 41 (11.7%) |
| **A** | 73 (20.7%) | **0/1333** | 0 (0%) | **73 (100%)** | 0 (0%) |
| **B** | 90 (25.6%) | **5/1750** | 4 (**4.4**%) | 86 (95.6%) | 4 (4.4%) |
| **C** | 189 (53.7%) | **73/3423** | 45 (**23.8**%) | 152 (80.4%) | 37 (19.6%) |

While Silva A (non-destructive invasion) and B (limited destructive invasion) are usually not associated with lymph node metastases, Silva C (diffuse destructive invasion) may be associated with LNM in up to 25% of cases

*De Vivar, 2013*

# Distribution of cases according to the IECC subtype and Silva pattern

| SUBTYPE | SILVA A N % | SILVA B N % | SILVA C N % |
|---|---|---|---|
| USUAL | 38/14.4% | 22/8.4% | 203/77.2% |
| GASTRIC | 0 | 0 | 33/100% |
| MUCINOUS NOS | 0 | 1/10% | 9/90% |
| MUCINOUS INTESTINAL | 3/33.3% | 2/22.2% | 4/44.4% |
| MUCINOUS SIGNET RING | 0 | 0 | 0 |
| CLEAR CELL | 0 | 0 | 6/100% |
| ISMILE | 1/11.1% | 0 | 8/88.9% |
| ADENO NOS | 1/25% | 0 | 3/75% |
| ENDOMETRIOID | 0 | 0 | 3/100% |
| VILLOGLANDULAR | 0 | 0 | 0 |
| SEROUS | 0 | 0 | 1/100% |
| MESONEPHRIC | 0 | 0 | 1/100% |

# Distribution of HPVA and NHPVA/Silva, LVI, Mets, Size and Stage

| | Silva | LVI[a] | LNM[a] | Size[b] | Stage 1[c] | Stage 2[c] | Stage 3[c] | Stage 4[c] |
|---|---|---|---|---|---|---|---|---|
| HPVA | A | 0.0% | 0.0% | 14 | 95.2% | 4.8% | | |
| | B | 18.5% | 0.0% | 10 | 100.0% | | | |
| | C | 62.6 | 19.8% | 25 | 87.4% | 9.2% | 2.9% | 0.5% |
| NHPVA | C | 73.5 | 30.6% | 40 | 47.7% | 43.2% | 6.8% | 2.3% |

- 49% of HPVAs were associated with lymph-vascular invasion (LVI) in contrast to 69.5% of NHPVAs (p=0.006)
- 15.3% of HPVAs and 30.6% of NHPVAs were associated with LNM (p=0.009)

# *Stolnicu et.al., Gynecol.Oncol, 2018*
# Stromal invasion pattern identifies patients at lowest risk of lymph node metastasis in HPVAs but is irrelevant in NHPVAs

- Multivariate analysis: FIGO stage is the only parameter that best stratifies NHPVA tumors at risk for LNM, while age, tumor diameter, presence of LVI and microscopic subtype are of no value

- Unlike HPVAs, where both Silva invasion pattern and stage are important prognostically, in NHPVA cases, stage is the only significant prognosticator of the variables studied

# Survival

# Stolnicu et.al., AmJSurgPathol, 2019

**Survival curves in HPVA versus NHPVA (OS, DFS, PFS)**

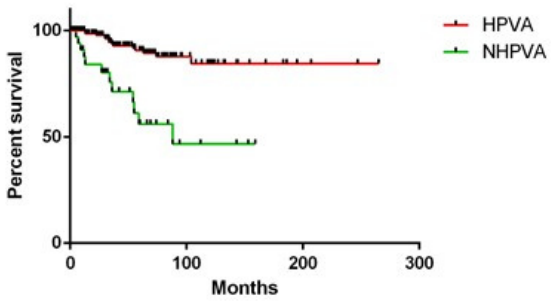


Overall survival

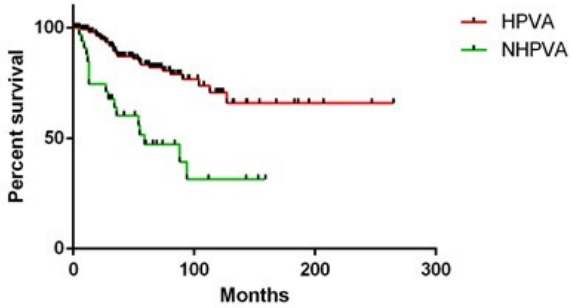


Disease free survival

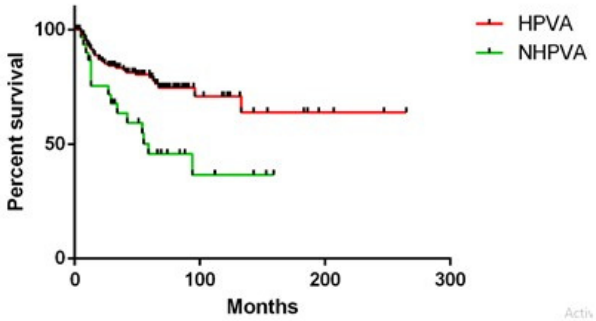


Progression free survival

p <0.0001, p <0.0001 and p: 0.0002

# IECC mucinous HPVA- survival

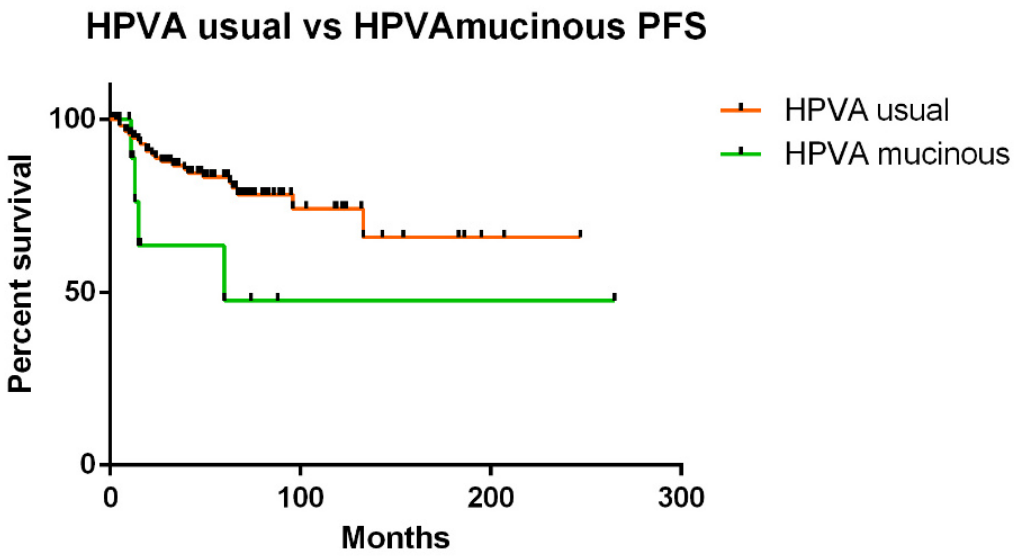


- Mucinous HPVAs had a worse PFS (p: 0.04), OS and DFS (not statistically significant) than usual HPVAs

# IECC mucinous HPVA- survival

- Mucinous HPVAs had a worse OS than usual HPVAs in a series of cases from British Columbia, Vancouver Canada (unpublished data)
- Current data suggest that mucinous HPVAs continue to be separated from both non-mucinous HPVAs and NHPVAs

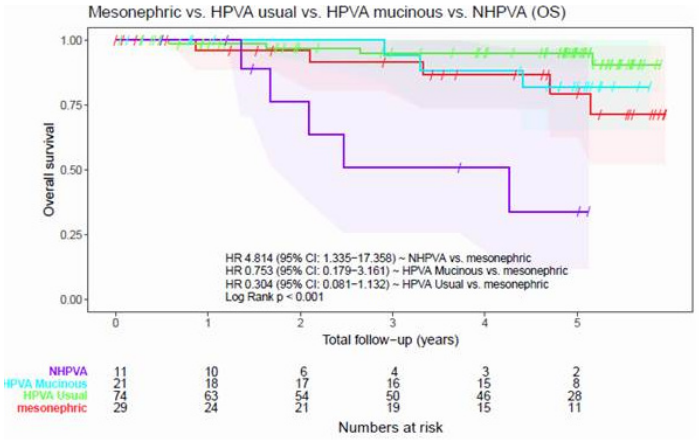


Figure 9: KM Curves of Cervical Cancers Mesonephric vs. HPVA Usual vs. HPVA Mucinous vs. NHPVA (OS)

# Stolnicu et.al., AmJSurgPathol, 2019

**Survival curves in HPVA versus NHPVA with surgical and adjuvant treatment (OS, DFS, PFS)**

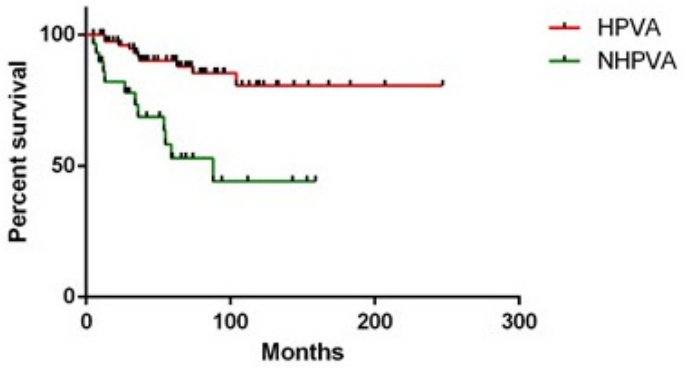


Overall survival

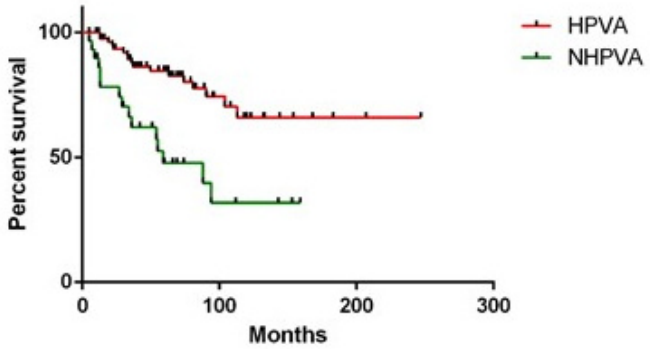


Disease free survival

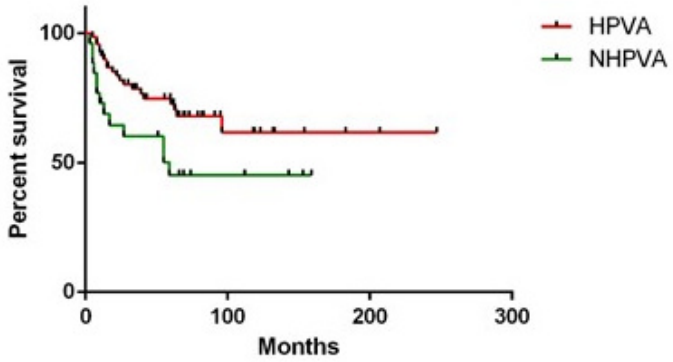


Progression free survival

# Stolnicu et.al., AmJSurgPathol, 2019

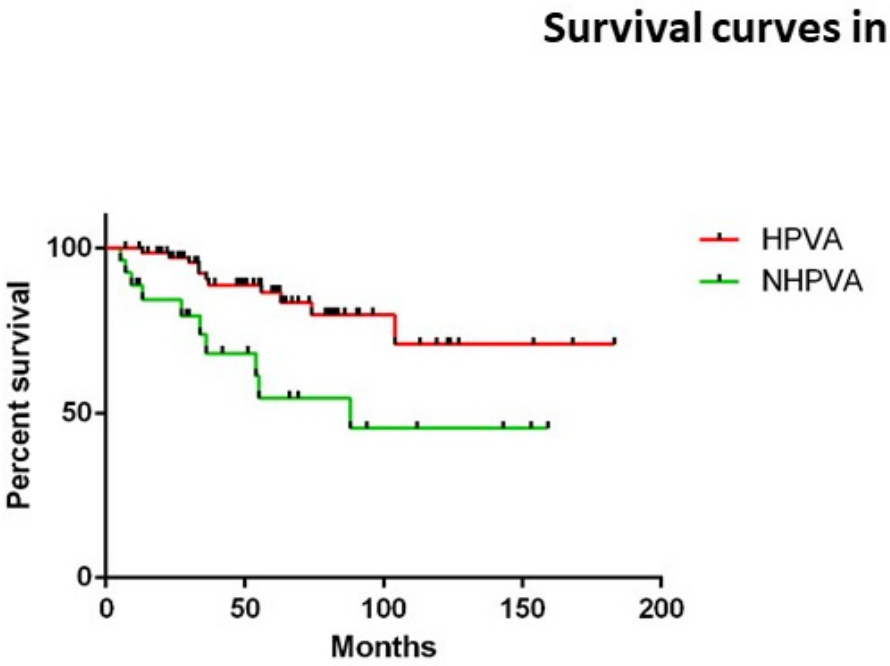


Overall survival

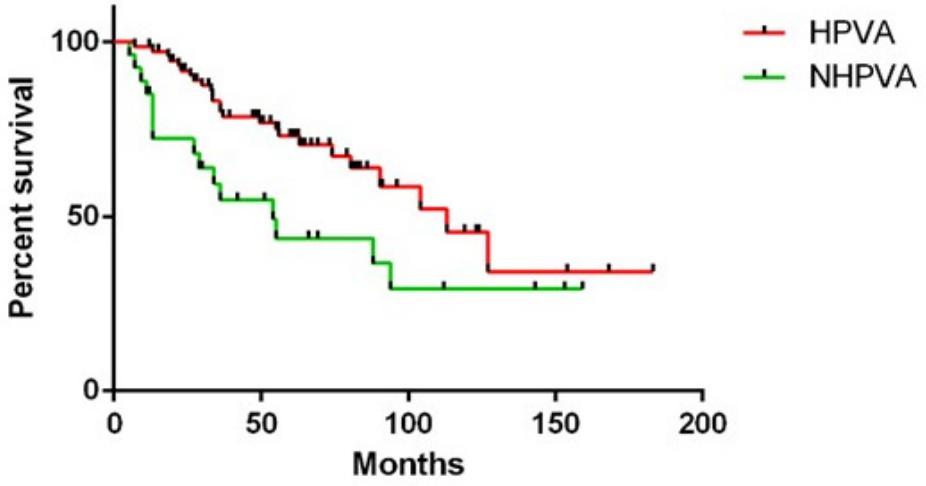


Disease free survival

# Stolnicu et.al., AmJSurgPathol, 2019

**Survival curves in HPVA vs NHPVA with local (pelvic) recurrences (OS, DFS, PFS)**

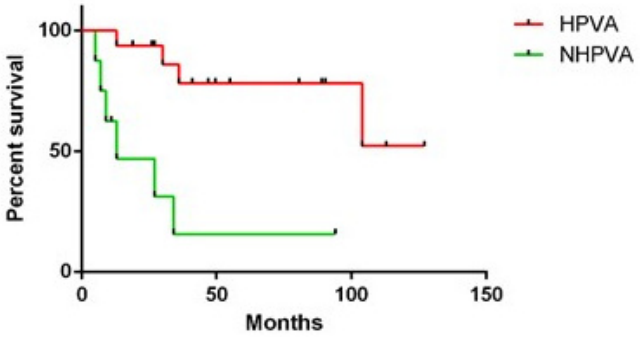


Overall survival

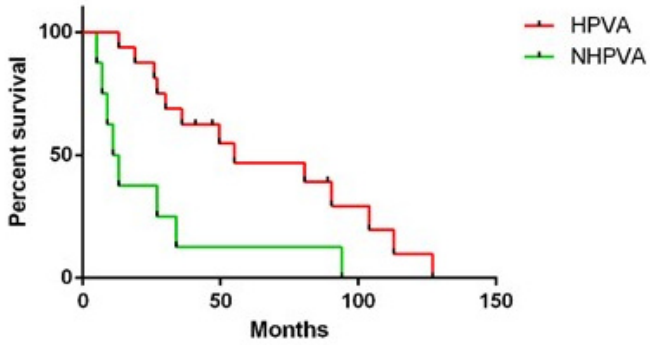


Disease free survival

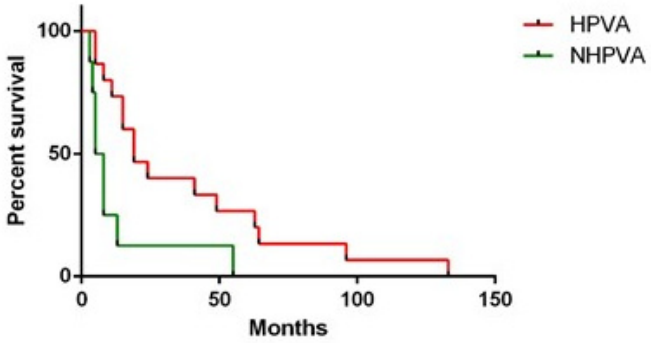


Progression free survival

However, no statistical significance was found for OS, DFS, PFS when HPVAs and NHPVAs with distant recurrences were compared

# Clinico-Pathologic Characterization of Endocervical Adenocarcinoma: Biologic Differences in Favour of an Updated International Criteria and Classification Model
Hodgson et al, USCAP 2018

- Validation of IECC
- 82 cases of EA from a single institution were identified
- HPVAs tumours comprised 87% of the cohort; 10% were NHPVAs and 3% (3/82) were unclassifiable
- However, NHPVAs had significantly higher rates of destructive invasive pattern (p=0.009), LVI (p=0.02) and advanced stage (p < 0 .001)

# Hodgson et al, USCAP 2018

- Worse recurrence free survival (RFS) and disease specific survival (DSS) were observed in NHPVAs compared to HPVAs

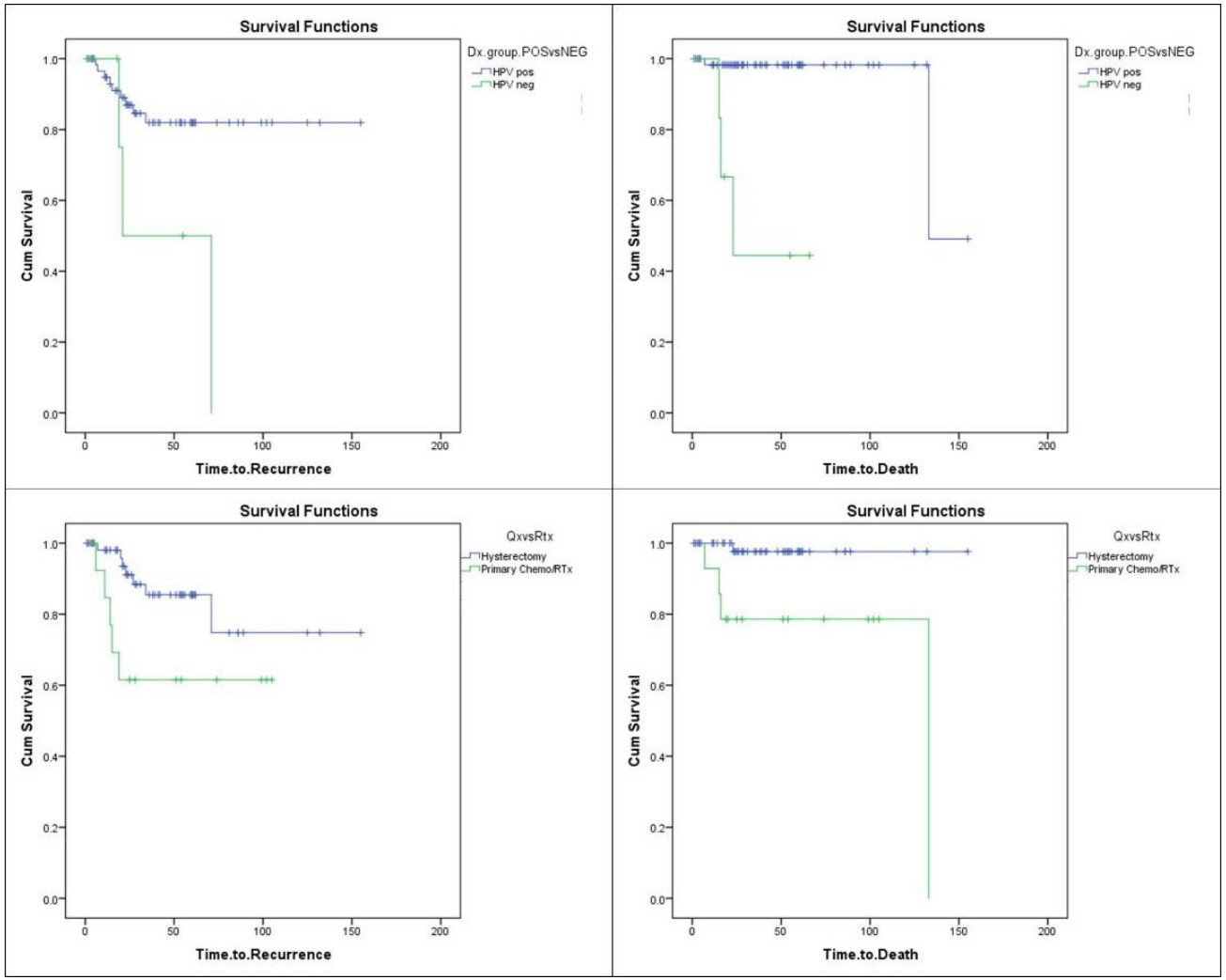

# HPVA subtypes of the IECC

# IECC Usual (HPVA)

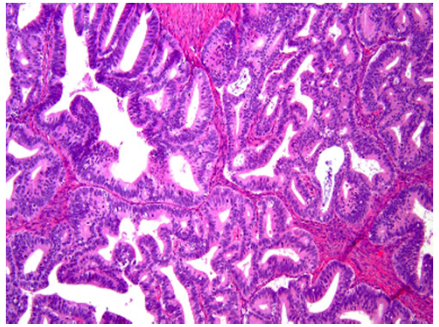

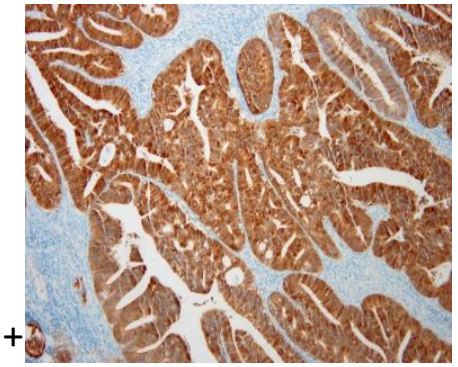

p16 +

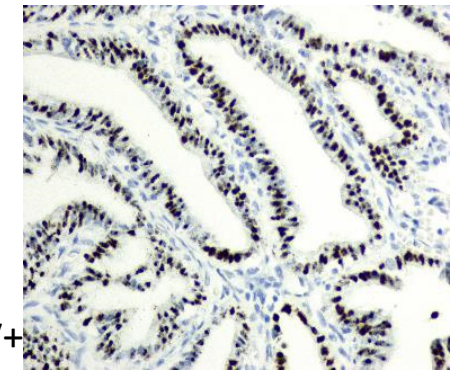

HPV+

- Vast majority of ECAs (80%) of ECAs
- 92% of usual-type cases were p16+ or HPV +
- Characteristic morphology
- IECC: 0-50% of cells with cytoplasmic mucin
- May have “endometrioid” features when lacks mucin

# IECC Villoglandular pattern (HPVA)

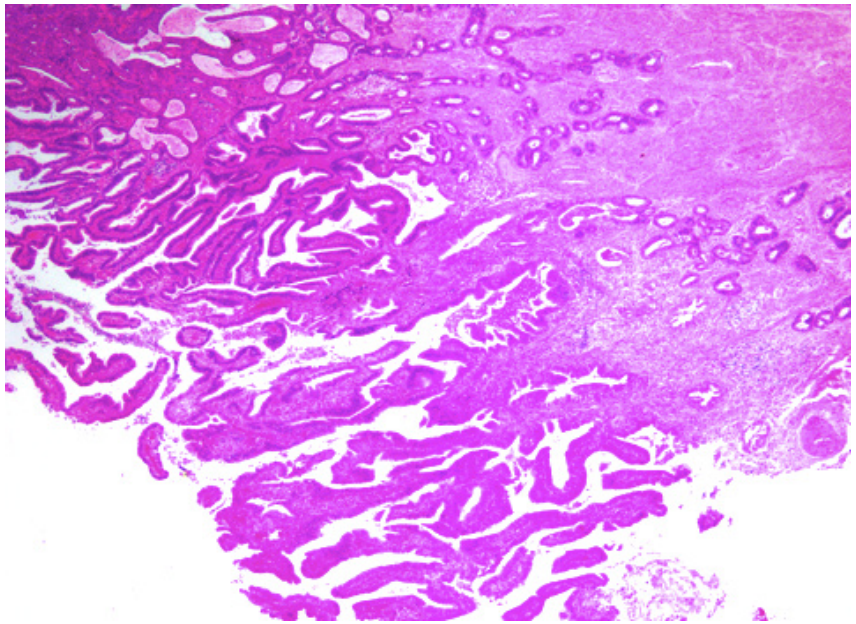

- Rare
- Characteristic macroscopy
- Usual cytomorphology with thin exophytic
- Papillae, minimal/moderate atypia
- IECC (n=3), p16+, HPV+

# IECC Micropapillary pattern (HPVA)

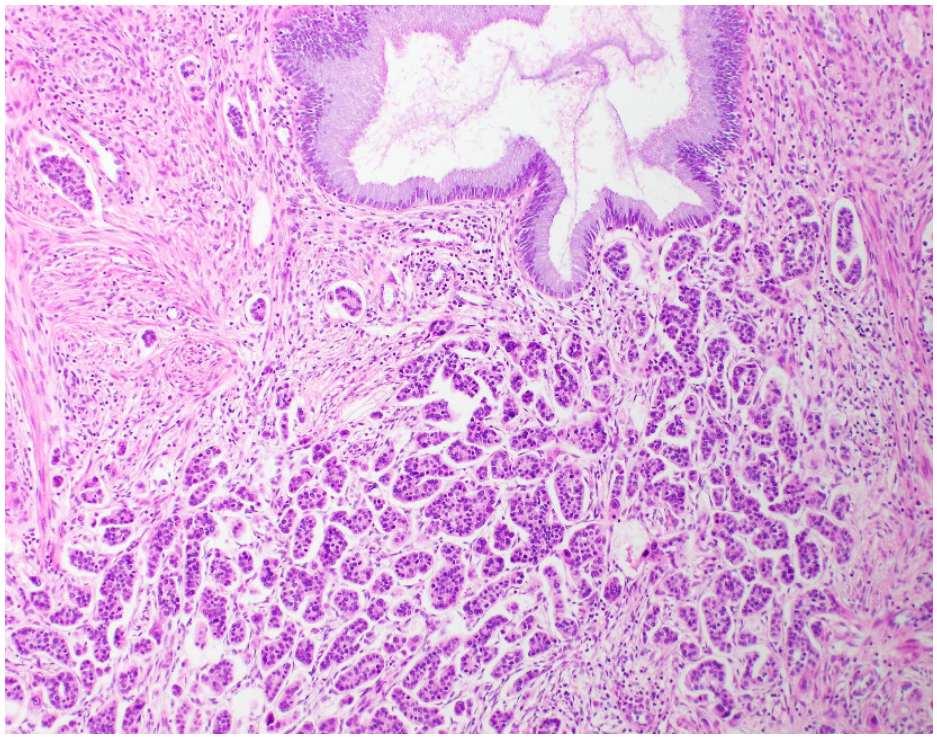

- Newly described histologic pattern
- Small tightly cohesive papillary groups
- Surrounded by clear spaces
- Pure or mixed
- LVI and LNM+, worse survival
- p16 +, HPV +

*Alvarado-Cabrero, 2019, AmJSurgPathol*

# IECC Mucinous NOS, intestinal, signet-ring, iSMILE (HPVA)

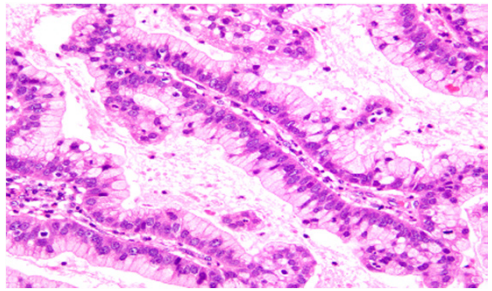

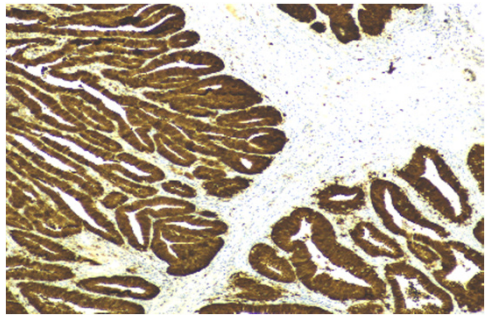

p16+

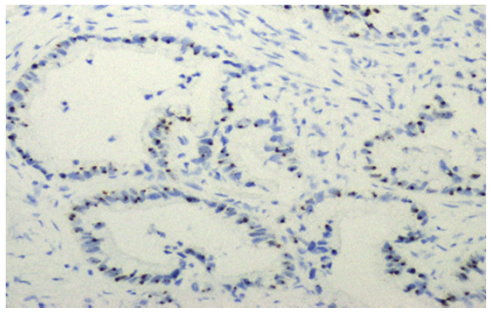

HPV +

- Diverse group of tumors
- Abundant cytoplasmic mucin (more than 50% of tumor cells)
- 100% positive for p16 and HPV

# IECC iSMILE pattern (HPVA)

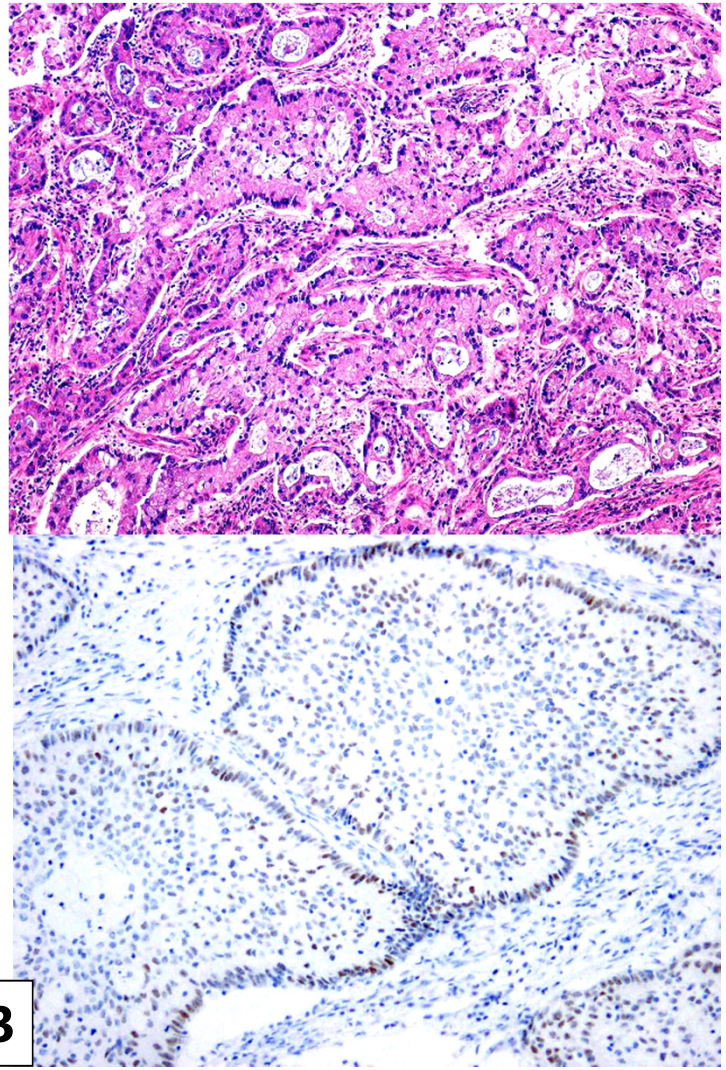

p63

- Newly recognized subtype of ECA
- Nests of columnar epithelium, variable amounts of intracytoplasmic mucin, hyperchromatic nuclei, peripheral palisading
- Higher prevalence of p40 and p63 expression
- Lower prevalence of PAX8 expression
- Origin: reserve cells
- More frequent aberrant p53 staining

# NHPVA subtypes of the IECC

# IECC Gastric (NHPVA)

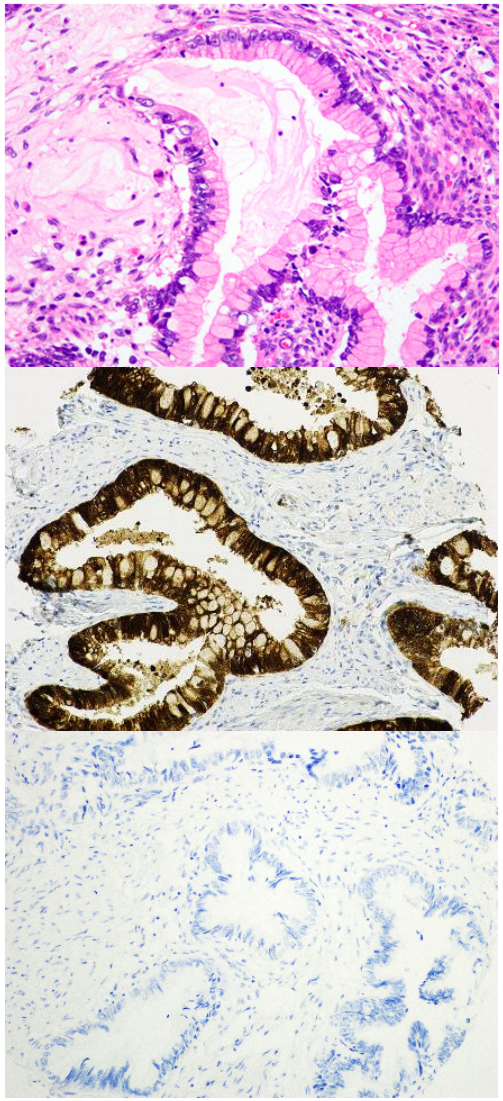


- A spectrum of tumors (including adenoma malignum)
- Peutz-Jeghers syndrome, mutations of STK11 identified
- Abundant cytoplasm, distinct borders, basally located nuclei
- Gastric type of mucus
- Pancreato-biliary morphology
- Usually p16- (33.3% were p16+)
- 100% HPV-negative

# IECC Clear cell (NHPVA)

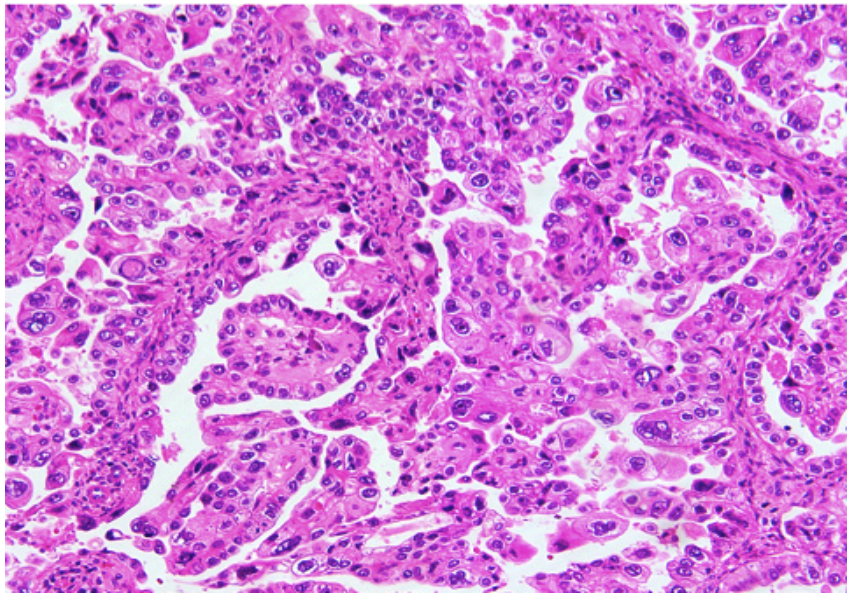

- Rare tumor
- In utero dietilsthylbestrol exposure or sporadic
- Clear/eosinophylic cytoplasm, atypical nuclei
- Variable architecture
- May be p16+ but HPV-negative
- Microsatellite unstable, association with Lynch syndrome unknown

# IECC Mesonephric (NHPVA)

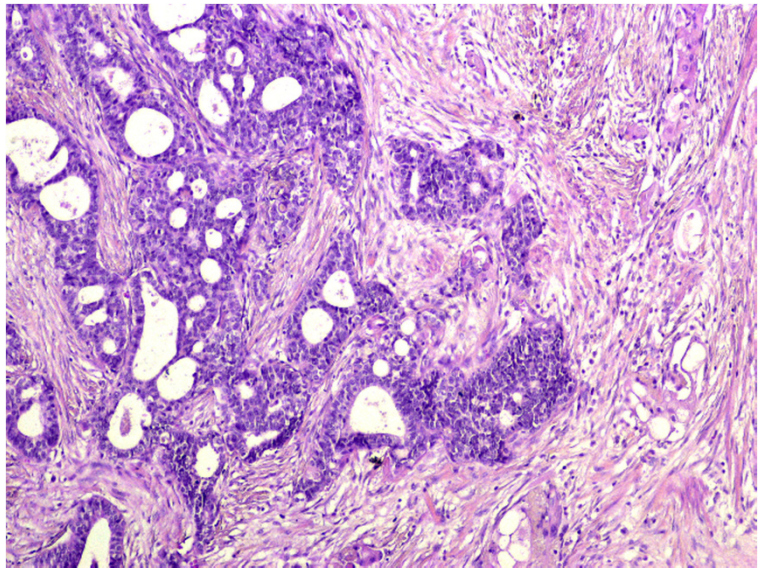

- Extremely rare
- Arises from mesonephric remnants
- p16, HPV-
- Alterations in *KRAS* and *NRAS* in up to 81% of cases, gene mutations (*ARID1A, ARID1B, SMARCA4*) in 2/3 of cases

# IECC Endometrioid (NHPVA)

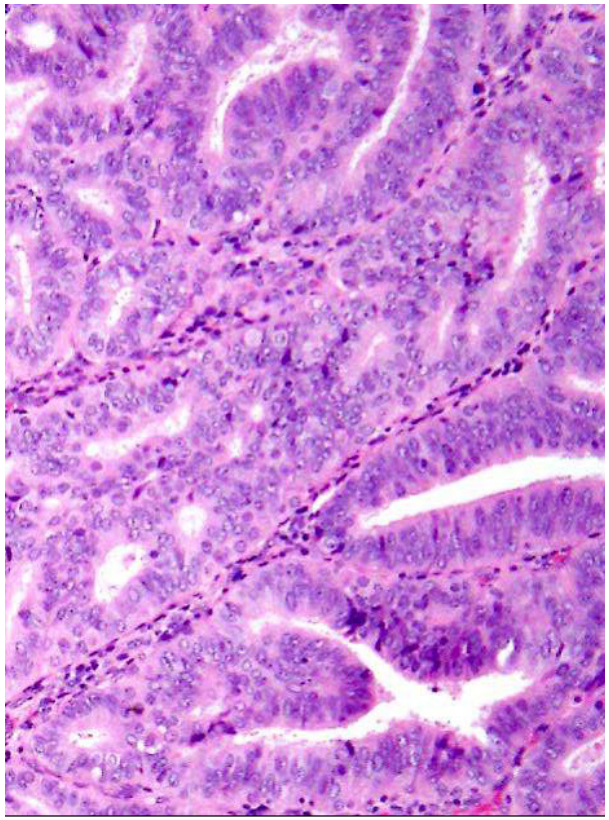

- IECC (n=3), very rare
- Developing from cervical endometriosis
- Confirmatory endometrioid features
- p16+ in all of them (but all of them were of high grade)
- HPV- in all of them
- True endometrioid carcinoma of endocervix should not be reflexively diagnosed in the presence of a mucin poor ECAs

- Any work in progress??????

# Genomic characterization of ECA types and implications

- Higher mutational burden in NHPVAs compared with HPVAs
- CDKN2A, STK11, ATM and NTRK3 alterations more frequently seen in NHPVAs (gastric type) versus HPVAs
- NGS may serve as a prognostic and histotype classification tool in ECAs

*Hodgson, 2017*

*Nagaria, 2018*

*Hodgson et al, USCAP, 2019*

MODERN PATHOLOGY (2017) 30, 1633–1641
© 2017 USCAP, Inc All rights reserved 0893-3952/17 $32.00


# Genomic abnormalities in invasive endocervical adenocarcinoma correlate with pattern of invasion: biologic and clinical implications

Anjelica Hodgson[1,2], Yutaka Amemiya[1,2,3], Arun Seth[1,2,3], Matthew Cesari[1,2], Bojana Djordjevic[1,2] and Carlos Parra-Herran[1,2]

*[1]Department of Pathology, Sunnybrook Health Sciences Centre, Toronto, ON, Canada; [2]Department of Laboratory Medicine and Pathobiology, University of Toronto, Toronto, ON, Canada and [3]Genomics Core Facility, Sunnybrook Research Institute, Toronto, ON, Canada*

**The pattern-based classification system for HPV-related endocervical adenocarcinoma, which classifies tumors based on the destructiveness of stromal invasion, is predictive of the risk of nodal metastases and adverse outcome. Previous studies have demonstrated clinically important molecular alterations in endocervical adenocarcinoma, including *KRAS* and *PIK3CA* mutations; however, correlation between the molecular landscape and pathological variables including pattern of invasion has not been thoroughly explored. In this study, 20 endocervical adenocarcinomas were classified using the pattern-based classification system and were subjected to targeted sequencing using the Ion AmpliSeq Cancer Hotspot Panel v2 (ThermoFisher Scientific, Waltham, MA, USA) that surveys hotspot regions of 50 oncogenes and tumor suppressor genes. Single-nucleotide polymorphisms were correlated with clinical and pathologic variables including pattern of invasion. Five (25%), six (30%), and nine (45%) cases were classified as patterns A, B, and C respectively. Lymph node metastases, advanced stage at presentation and mortality from disease were exclusively seen in destructively invasive tumors (patterns B or C). Prevalent mutations in the cohort involved *PIK3CA* (30%), *KRAS* (30%), *MET* (15%), and *RB1* (10%). Most (94%) relevant genomic alterations were present in destructively invasive tumors with *PIK3CA, KRAS*, and *RB1* mutations seen exclusively in pattern B or C subgroups. *KRAS* mutations correlated with advanced stage at presentation (FIGO stage II or higher). Our findings indicate that the pattern of stromal invasion correlates with genomic abnormalities detected by next-generation sequencing, suggesting that tumors without destructive growth (pattern A) are biologically distinct from those with destructive invasion (patterns B and C), and that pattern B endocervical adenocarcinoma is more closely related to its pattern C counterpart. The pattern-based classification may be used as a triage tool when considering molecular testing for prognostic or therapeutic purposes.**
*Modern Pathology* (2017) **30,** 1633–1641; doi:10.1038/modpathol.2017.80; published online 21 July 2017

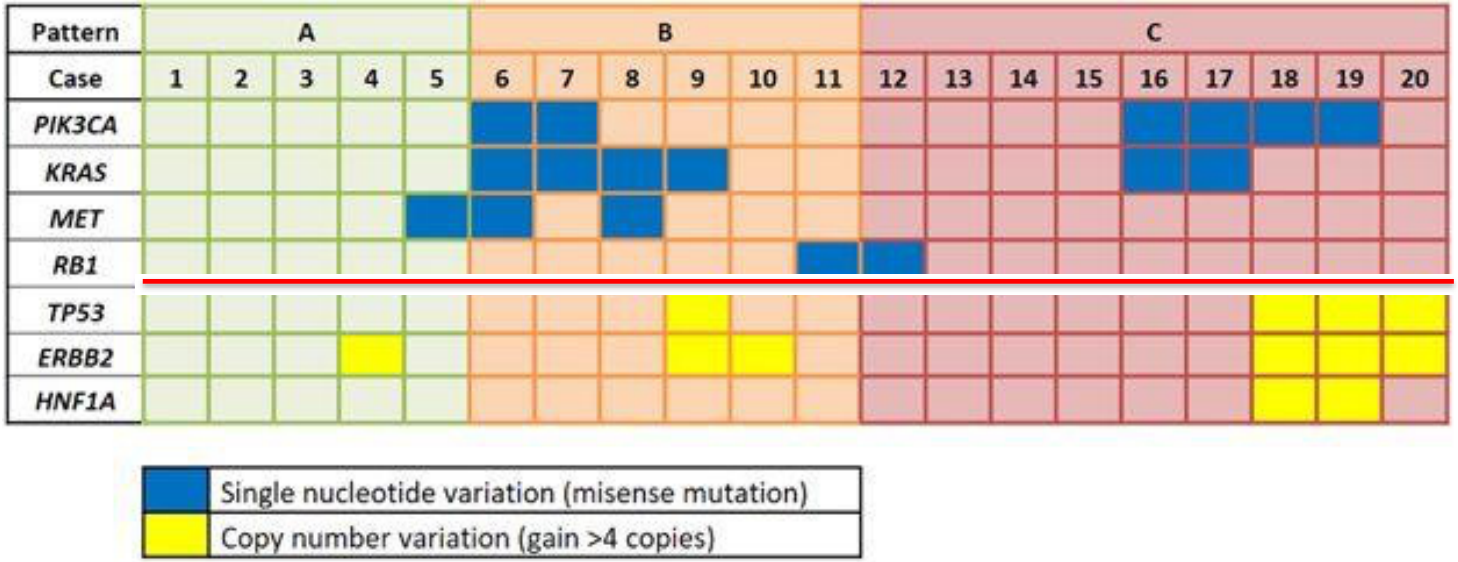


nucleotide variations and copy number gains in endocervical adenocarcinomas classified by pattern.

<u>Missense mutations</u>
*PIK3CA* mutations 6
*KRAS* mutations 6
*MET* mutations 3
*RB1 2*
*PIK3CA/KRAS* in 4
Mutations more frequent in Pattern B/C vs A

} Exclusive to pattern B/C

<u>Copy number variations (gains) more prevalent in pattern B and C</u>
*ERBB2* 6 (no correlation with IHC)
*p53* 4 (no correlation with IHC)
*HNF1A* 2

# Genomic characterization of ECA and patterns of invasion-Implications

- Significantly higher prevalence of oncogene and tumor supressor gene abnormalities in patterns B and C
- Non-destructive ECAs appear to be biologically different from destructive ECAs
- Pattern A: early phase or indolent tumor?
- Gives molecular support for histologic and clinicopathologic findings
- In practice: not sure yet; need more studies

# Conclusions

- We recommend replacement of the WHO 2014 criteria and classification with IECC 2019
- The IECC segregates endocervical adenocarcinomas into HPVA and NHPVA- ***using morphology alone***
- Both HPVA and NHPVA cases can be further stratified using existing criteria (which can be recognized on H&E slides)
- The validity of the HPVA and NHPVA categories is supported by clinical/demographic data, p16/HPV status and by survival data

# Conclusions

- The distinction between HPV-related and HPV-unrelated ECAs can be made with good reproducibility and excellent prediction of HPV status
- Adjuvant therapy may preferentially benefit patients with HPVAs
- Future management strategies need to be designed in accordance to these findings
- More studies to define the role of gene abnormalities in the diagnostic and invasion pattern of ECAs

Thank you