Case 1

- Female aged 79
- History of prolapse
- Vaginal hysterectomy performed
- Section from the cervix

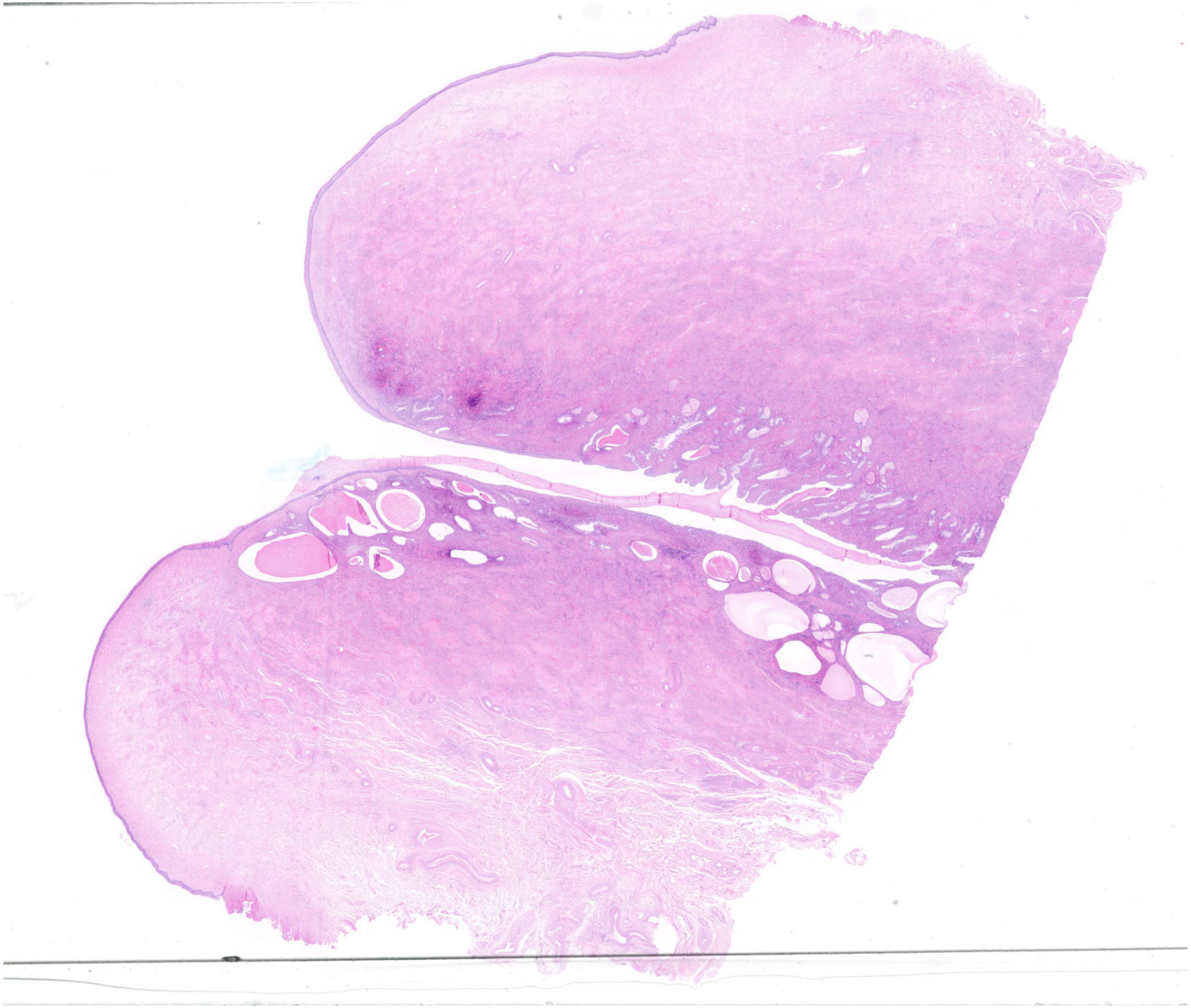
5 mm

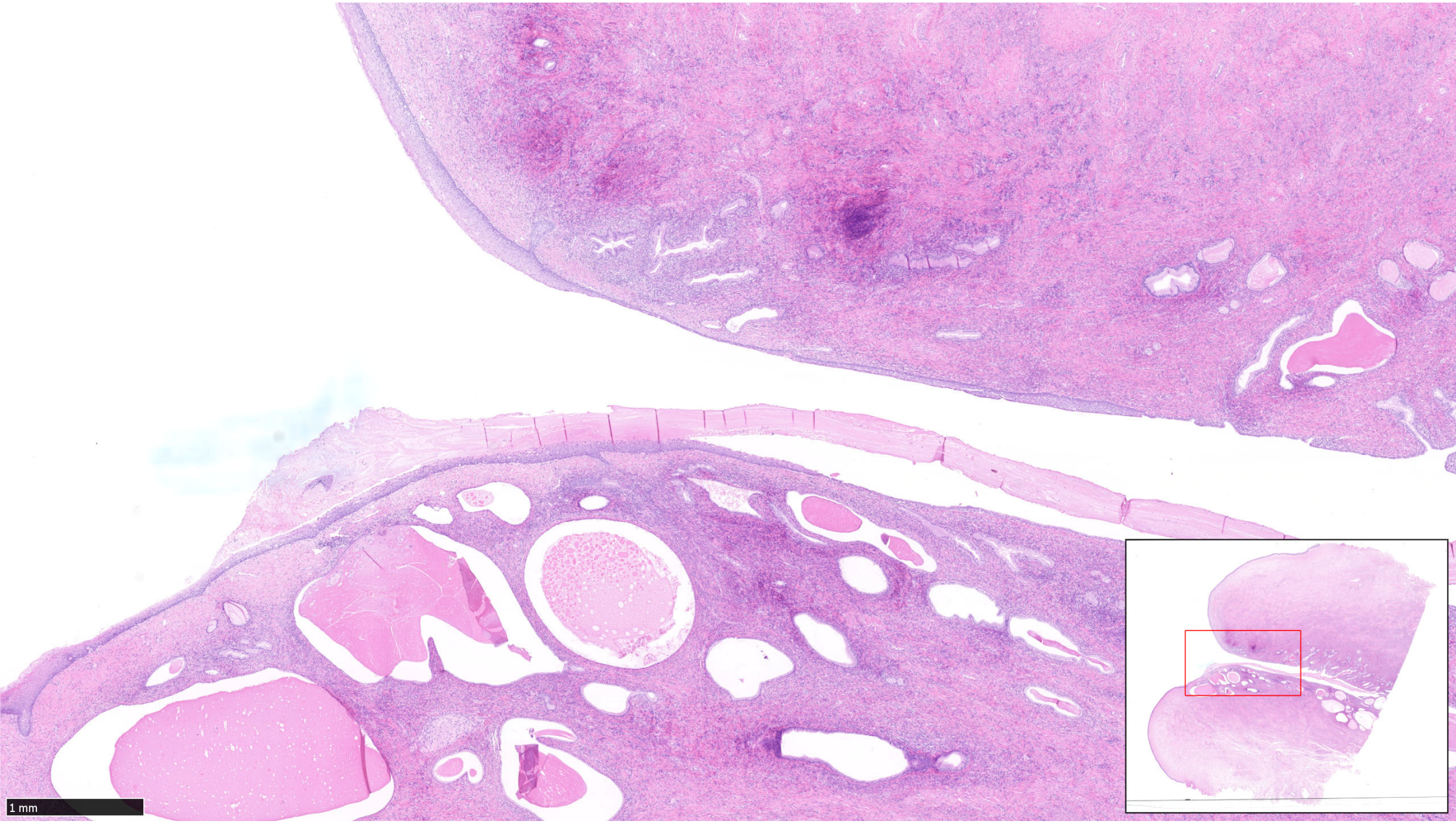
1 mm

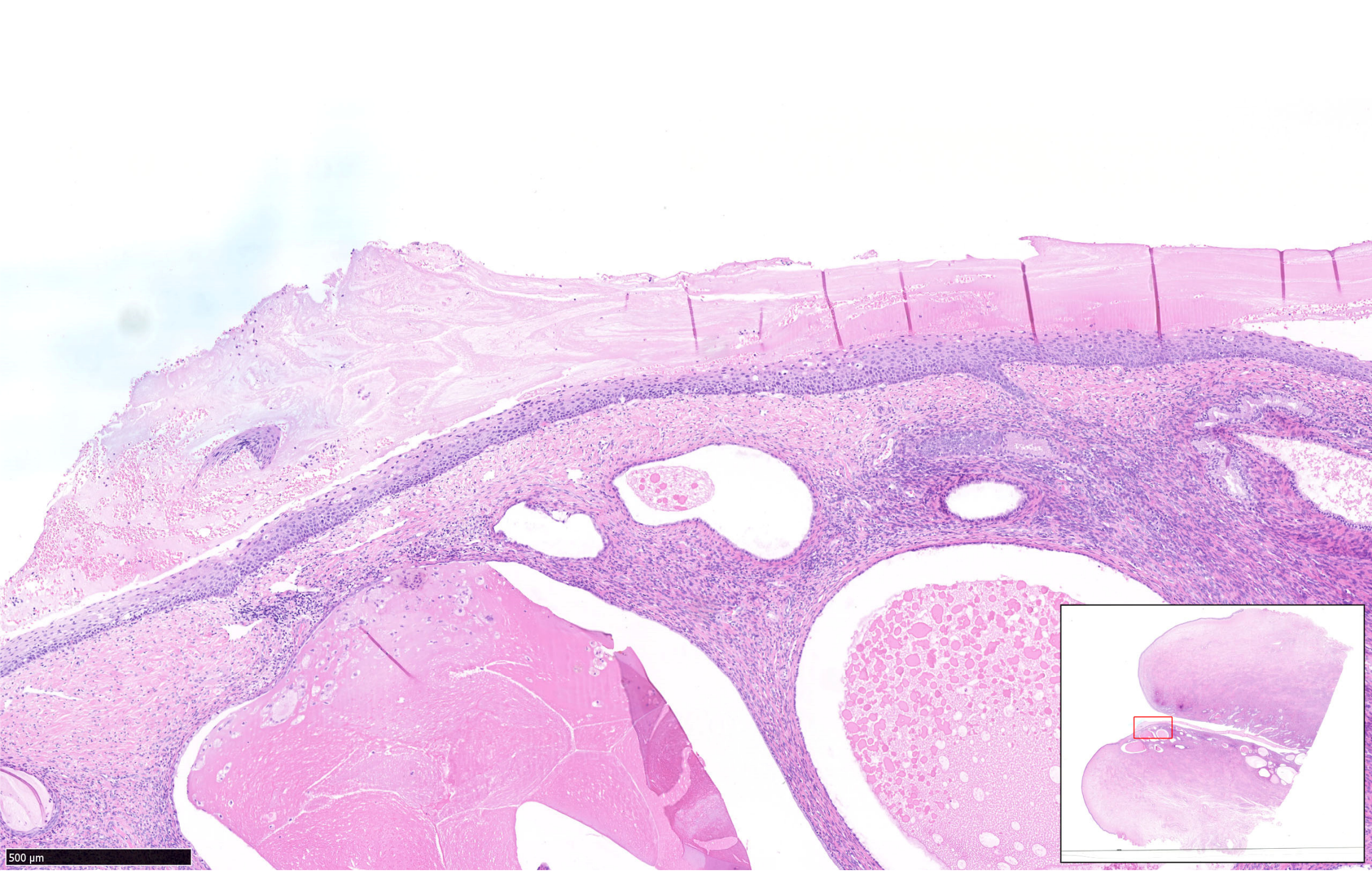
500 µm

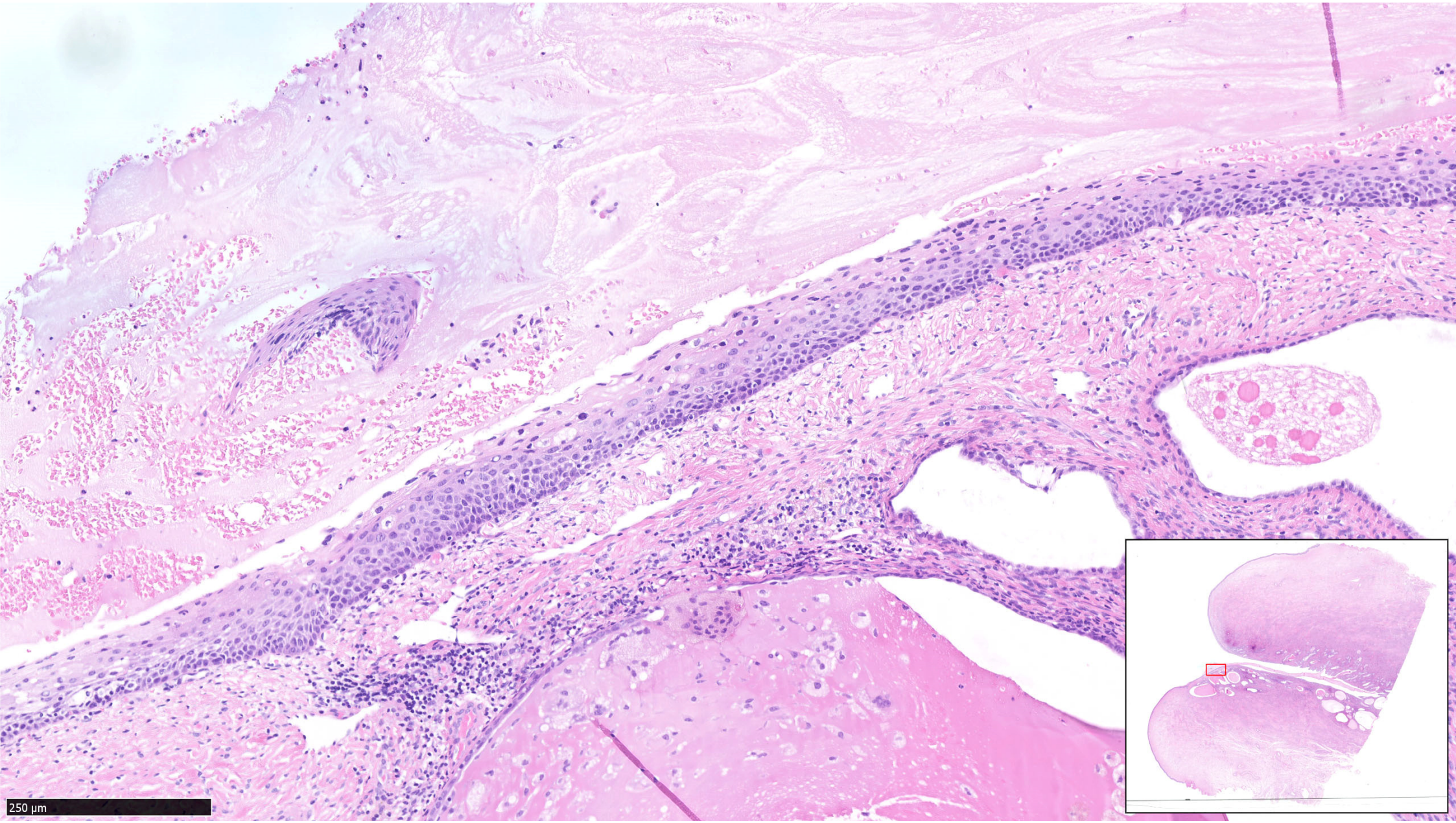
250 µm

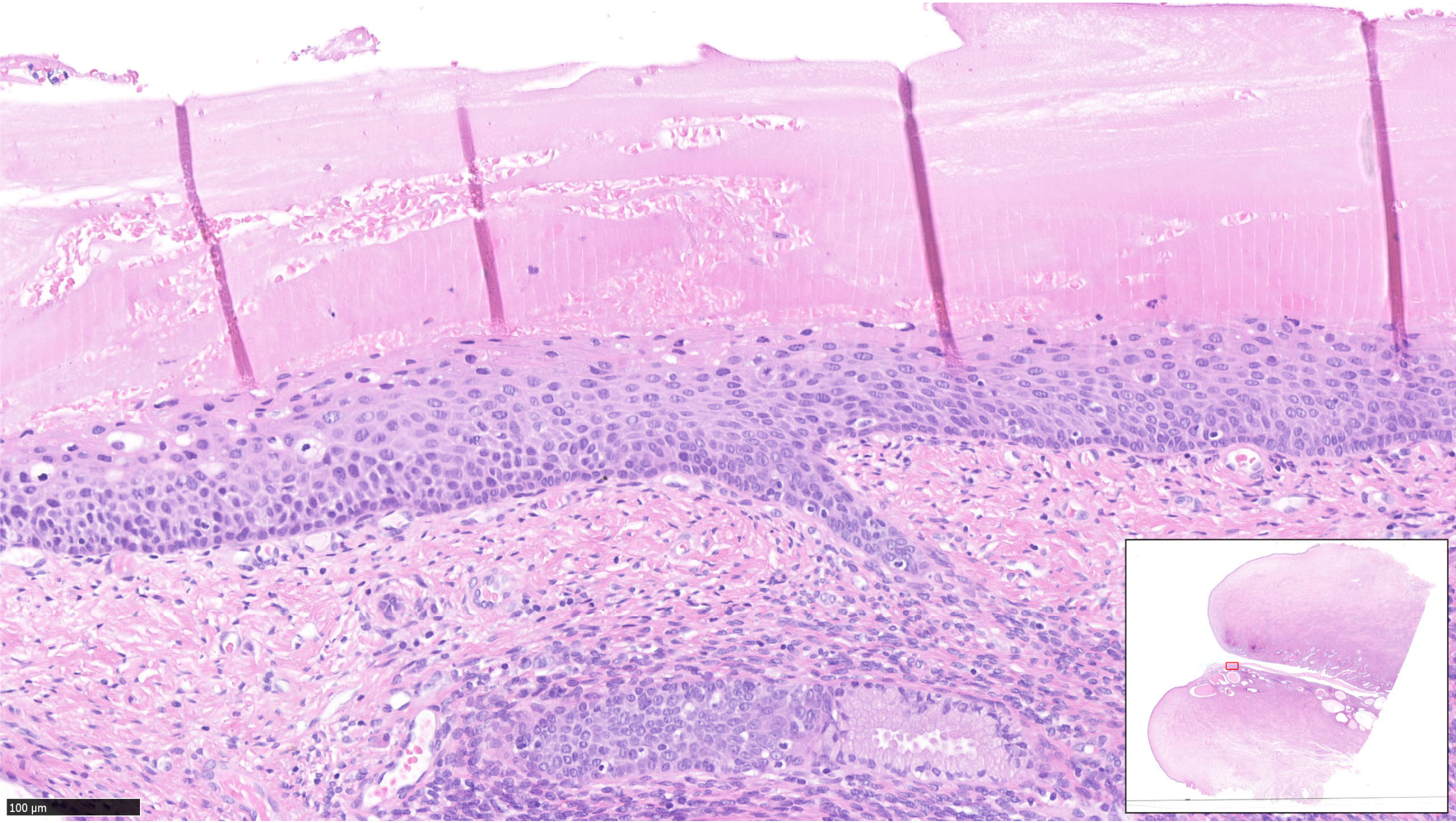
100 µm

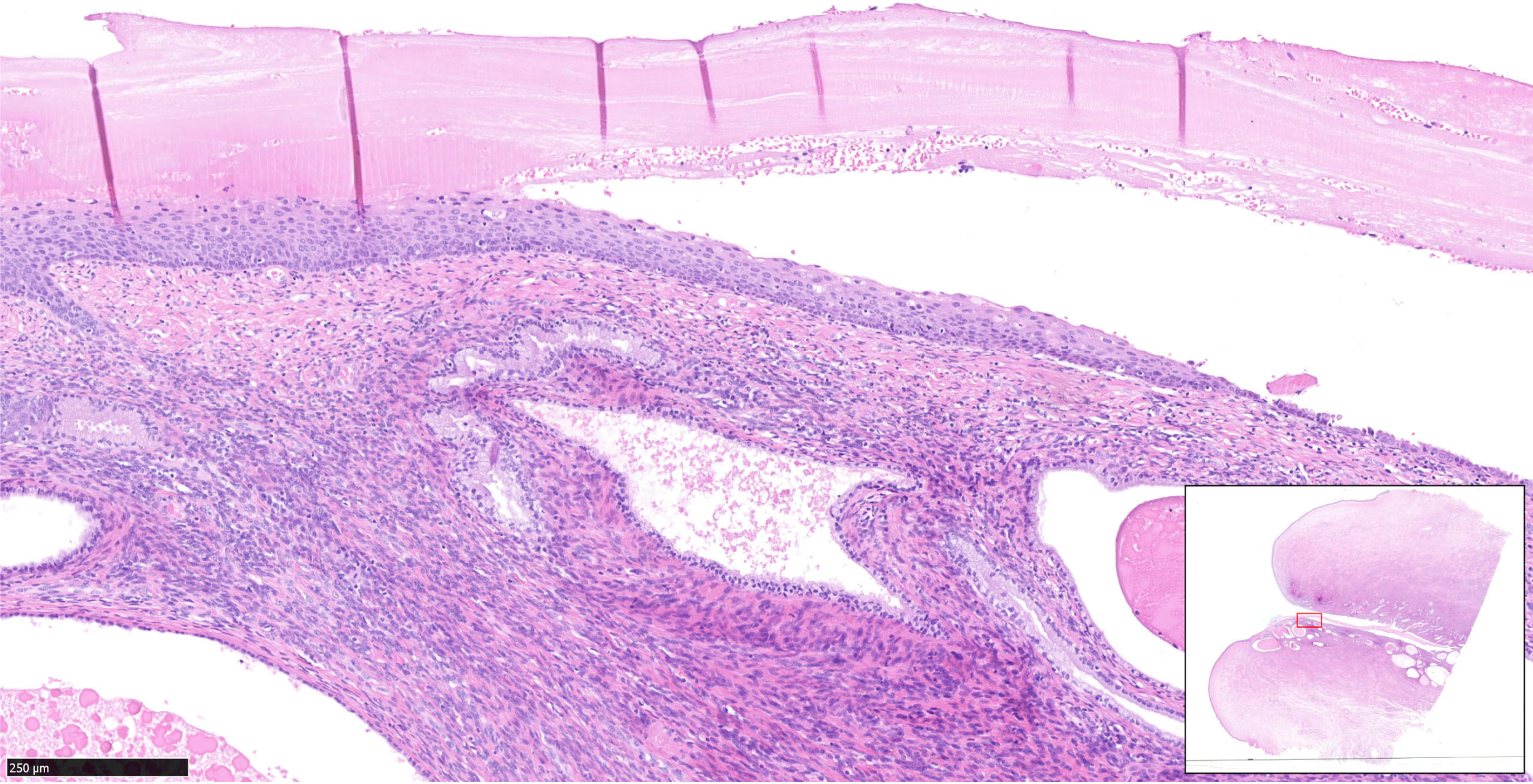
250 µm

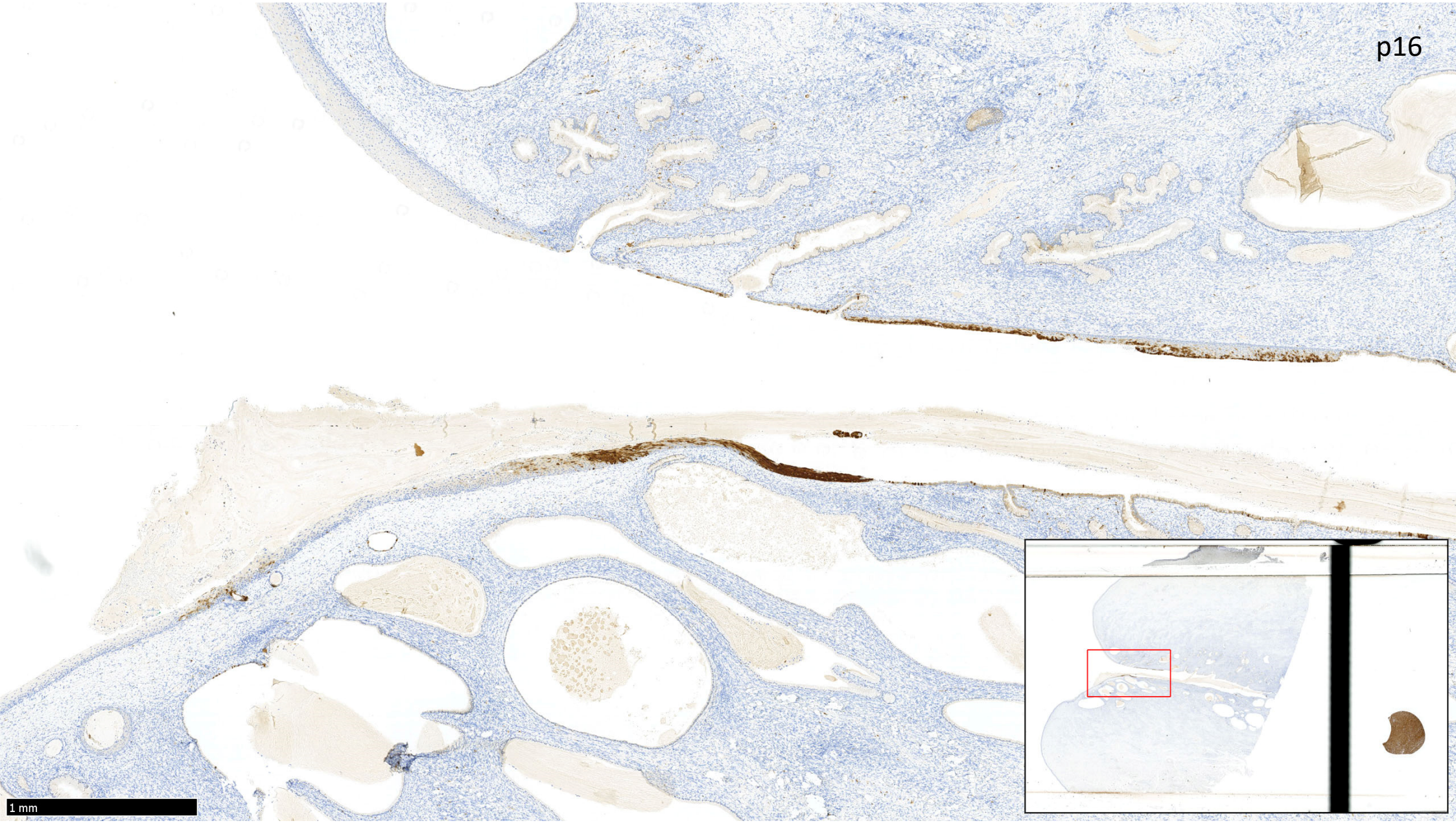
p16
1 mm

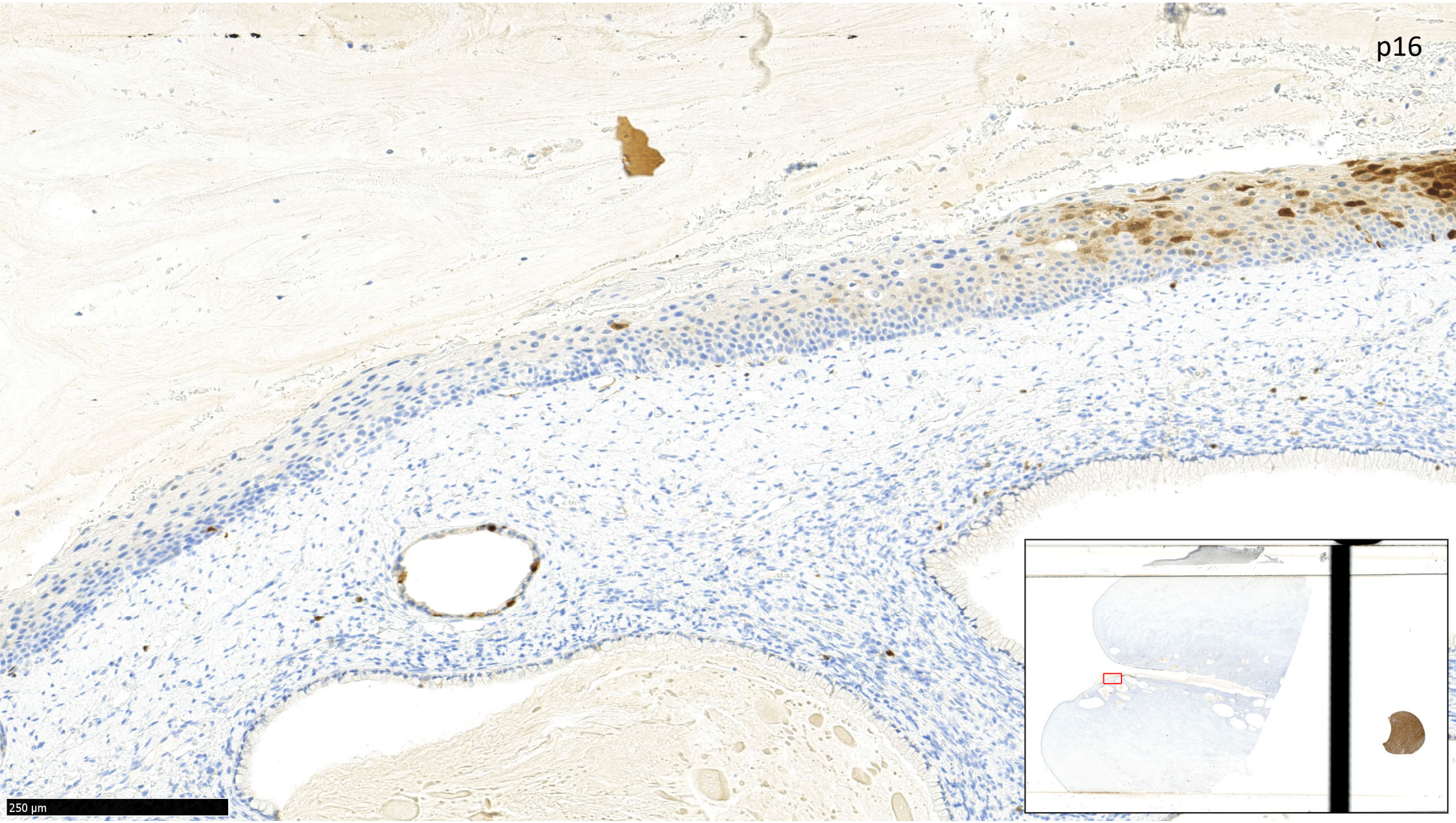
p16
250 µm

p16

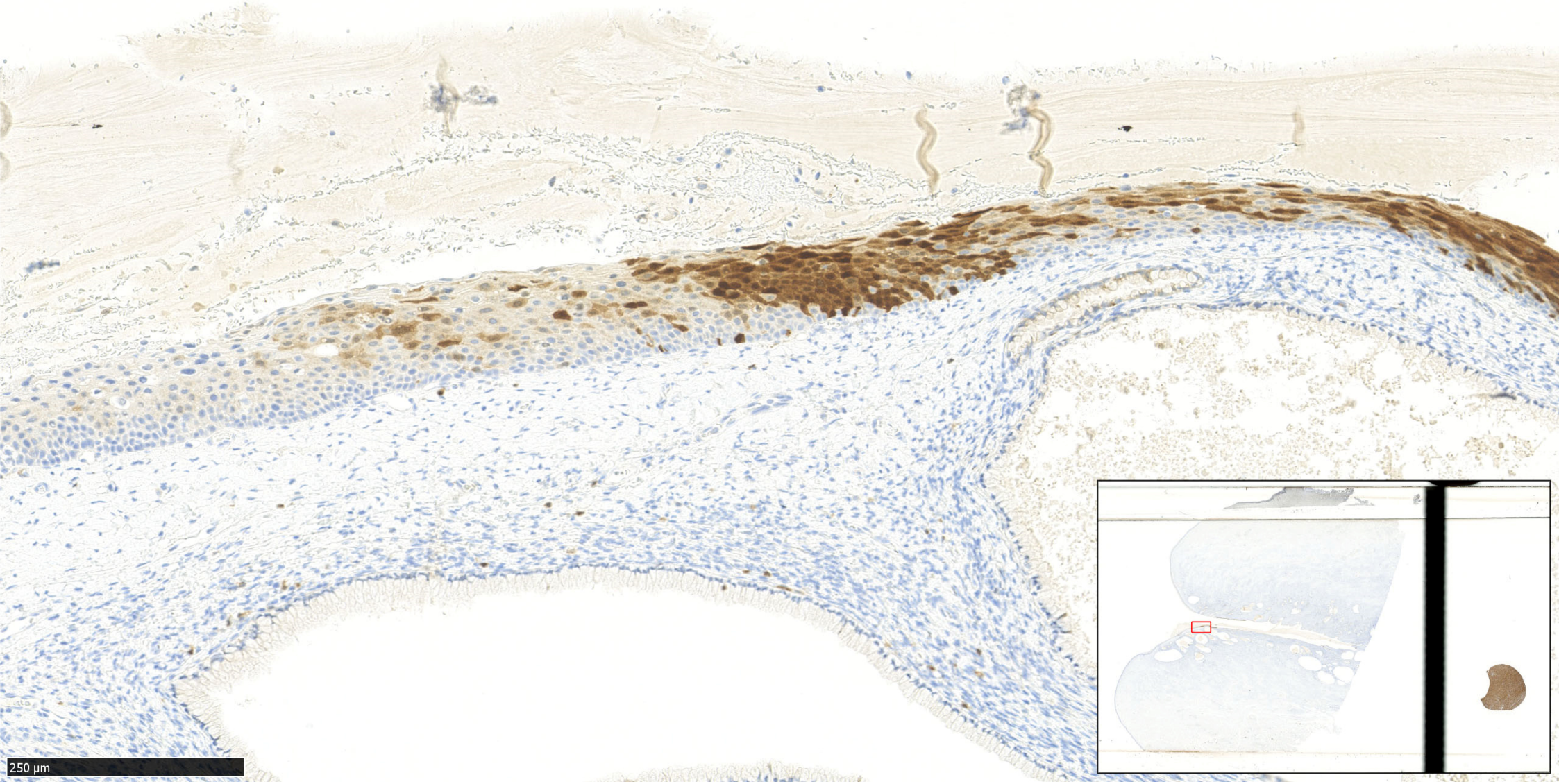

p16

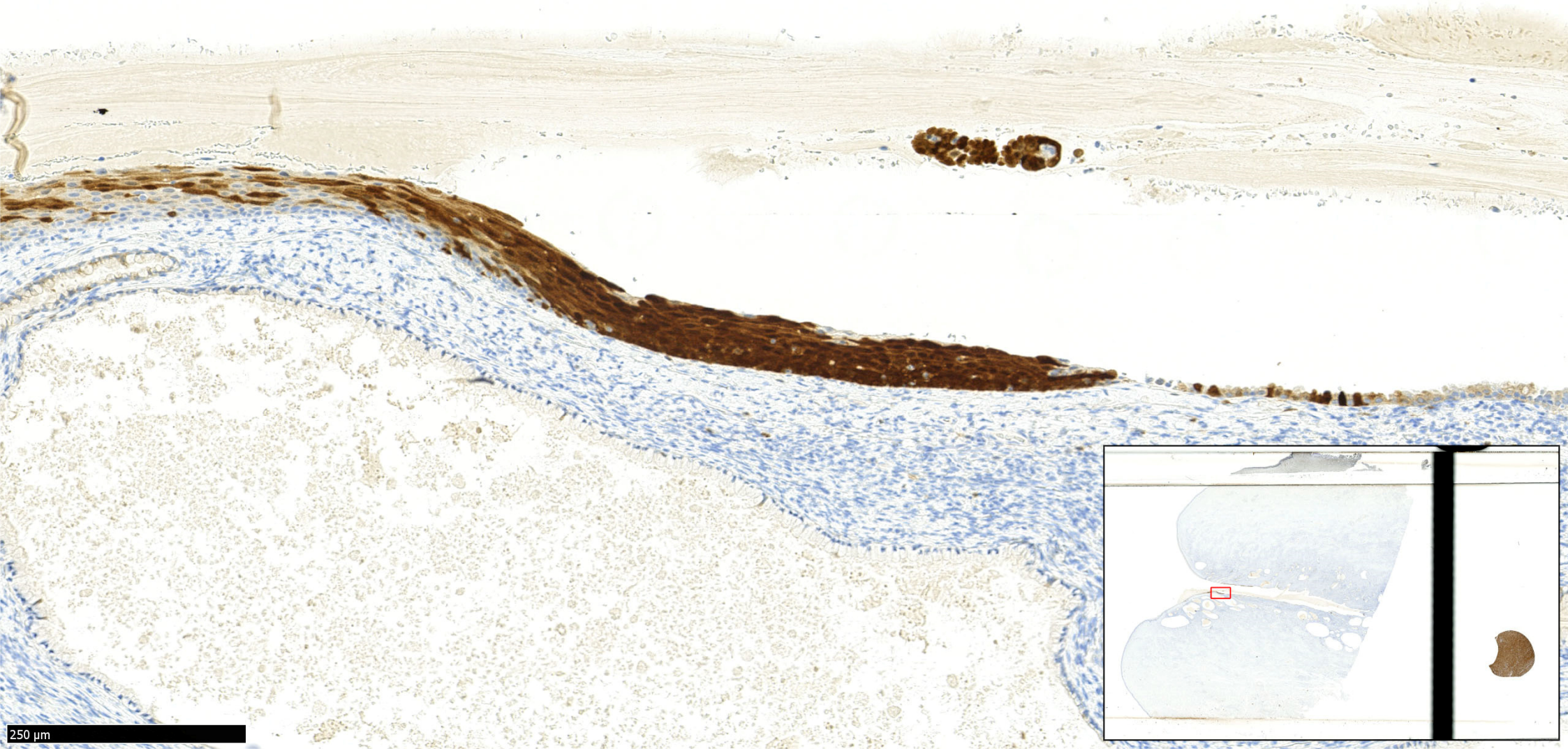

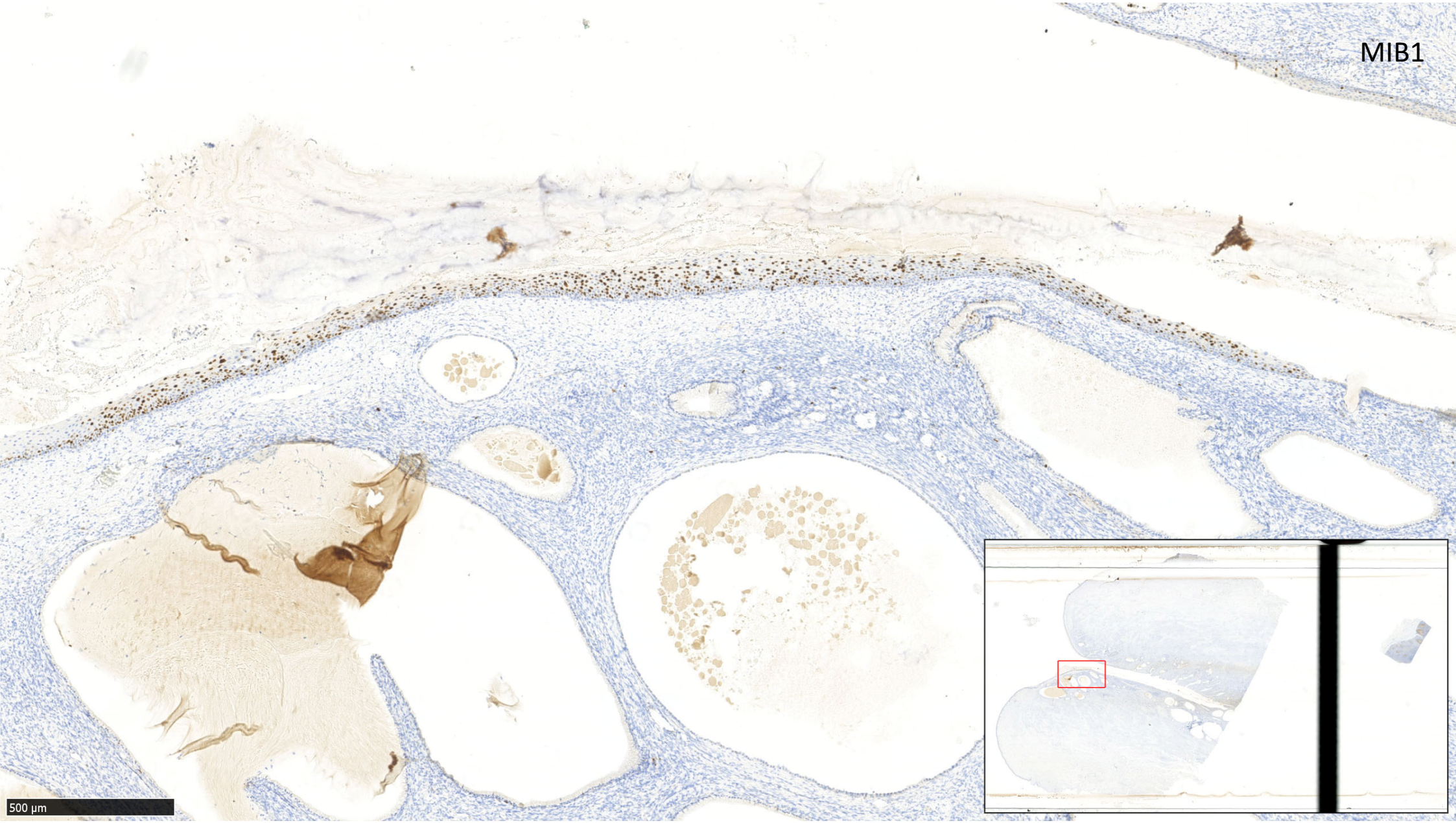
MIB1
500 µm

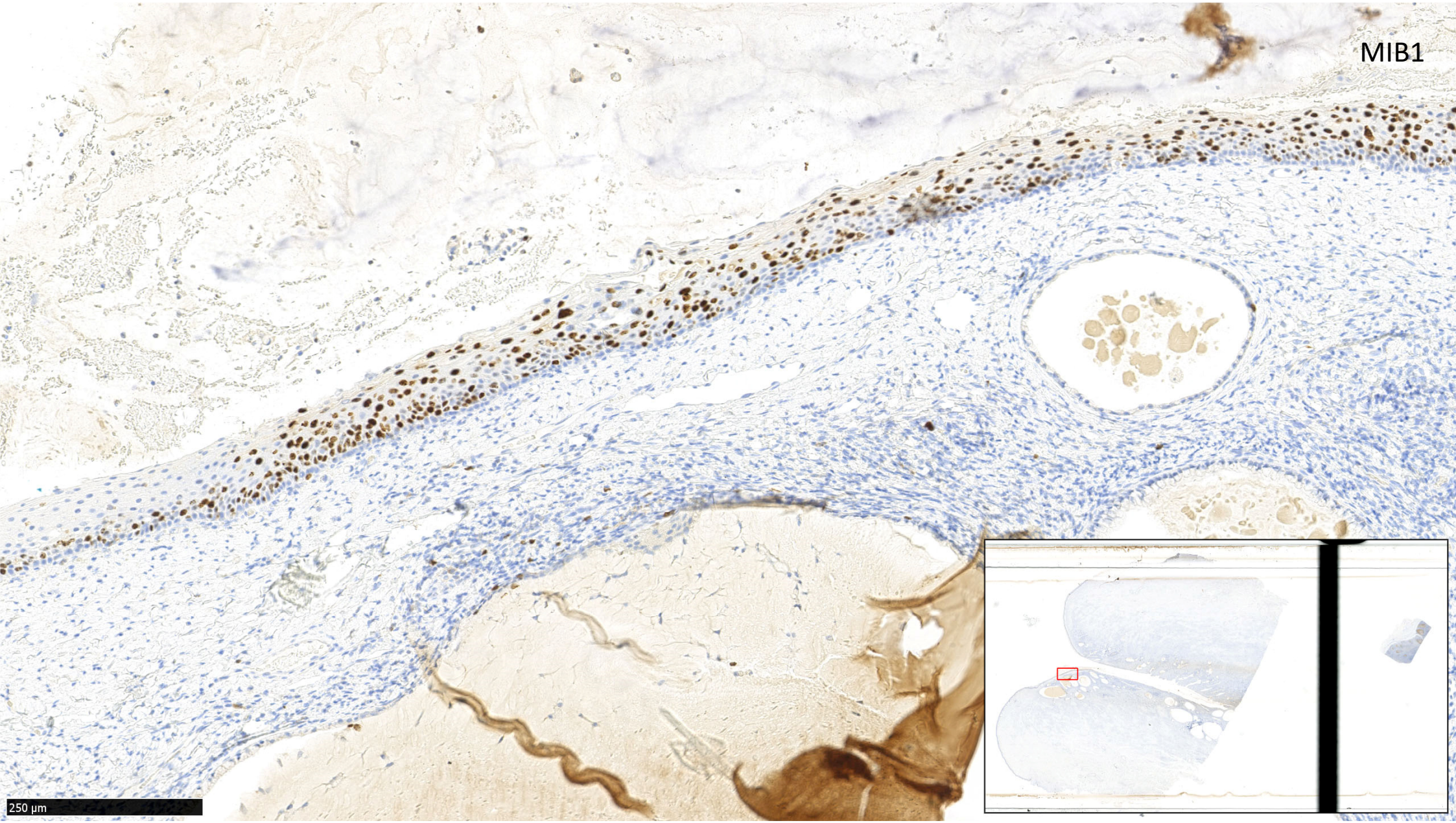
MIB1
250 µm

MIB1

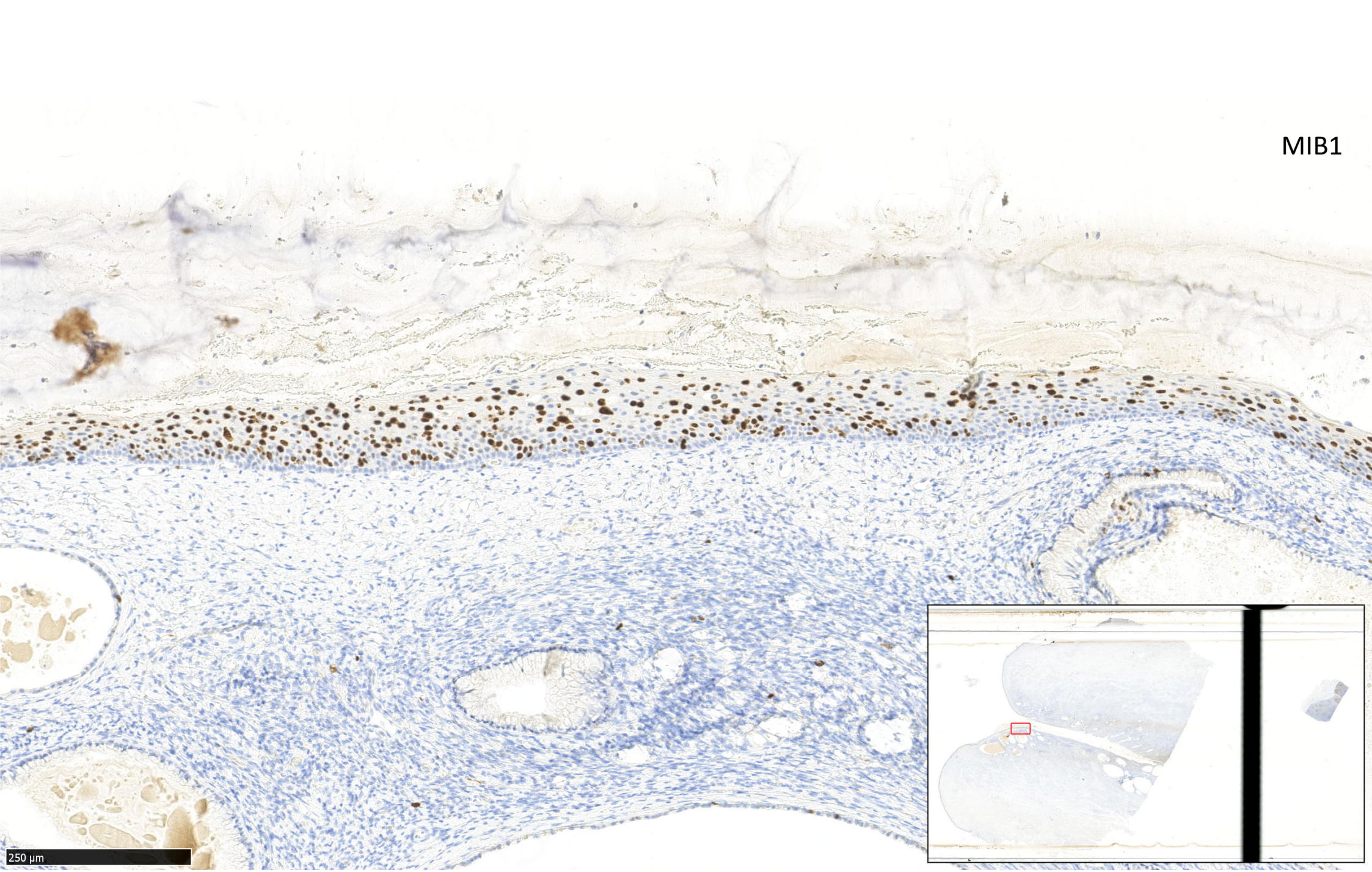

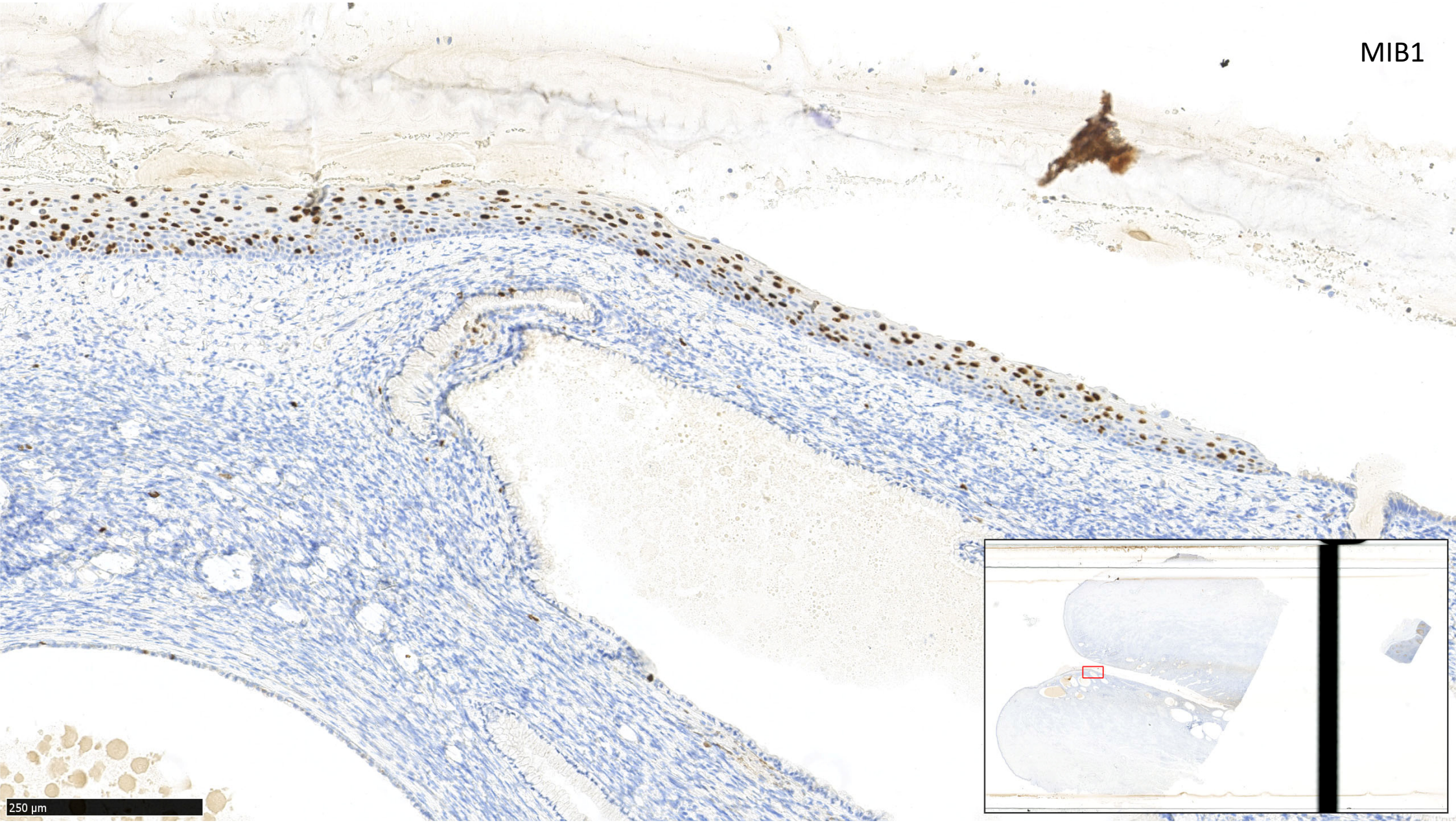
MIB1
250 µm

Diagnosis

Cervical SIL with Mixed HPV Infection

The Papillomavirus Life Cycle

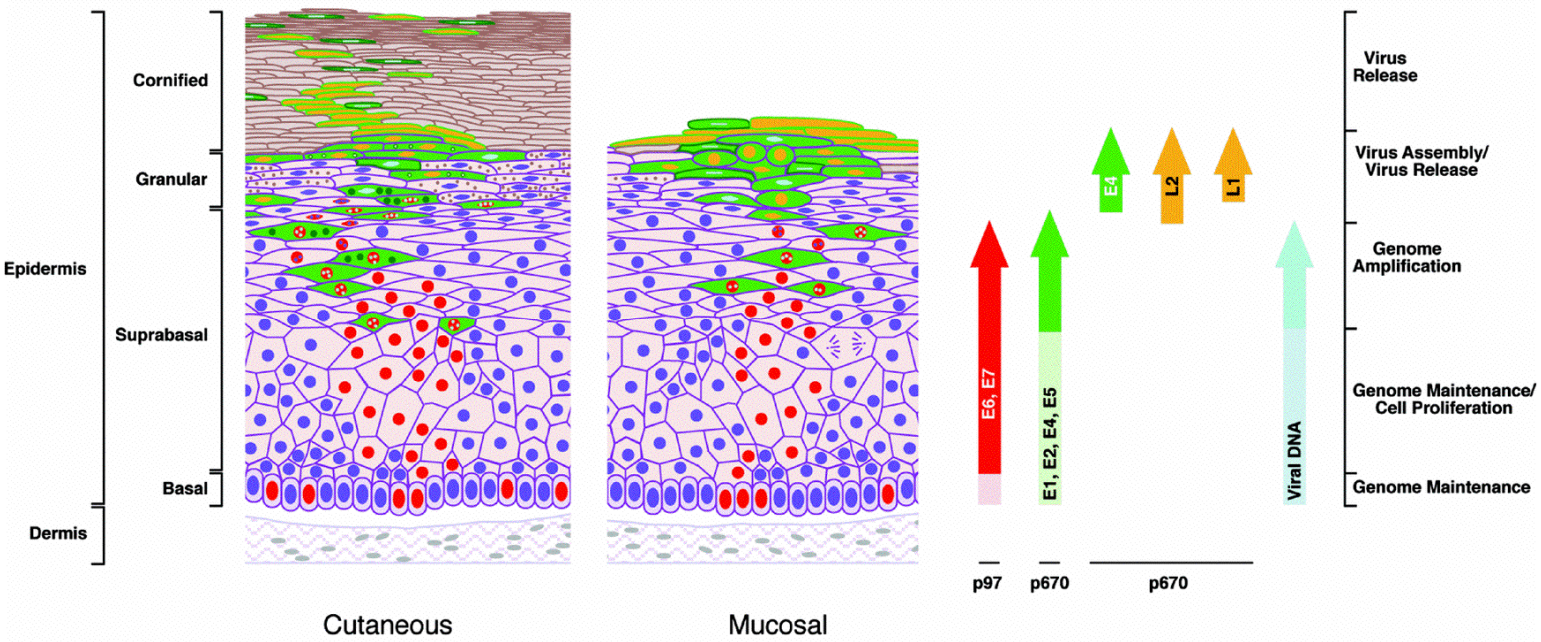

Doorbar J *Clin Sci* 2006;110:525-41

Case 2

- 64 year old female with a history of VIN
- New lesions on left and right side of vulva. Macroscopically the biopsies had an irregular skin surface
- The slides are from right (A) and left (B) vulval lesions

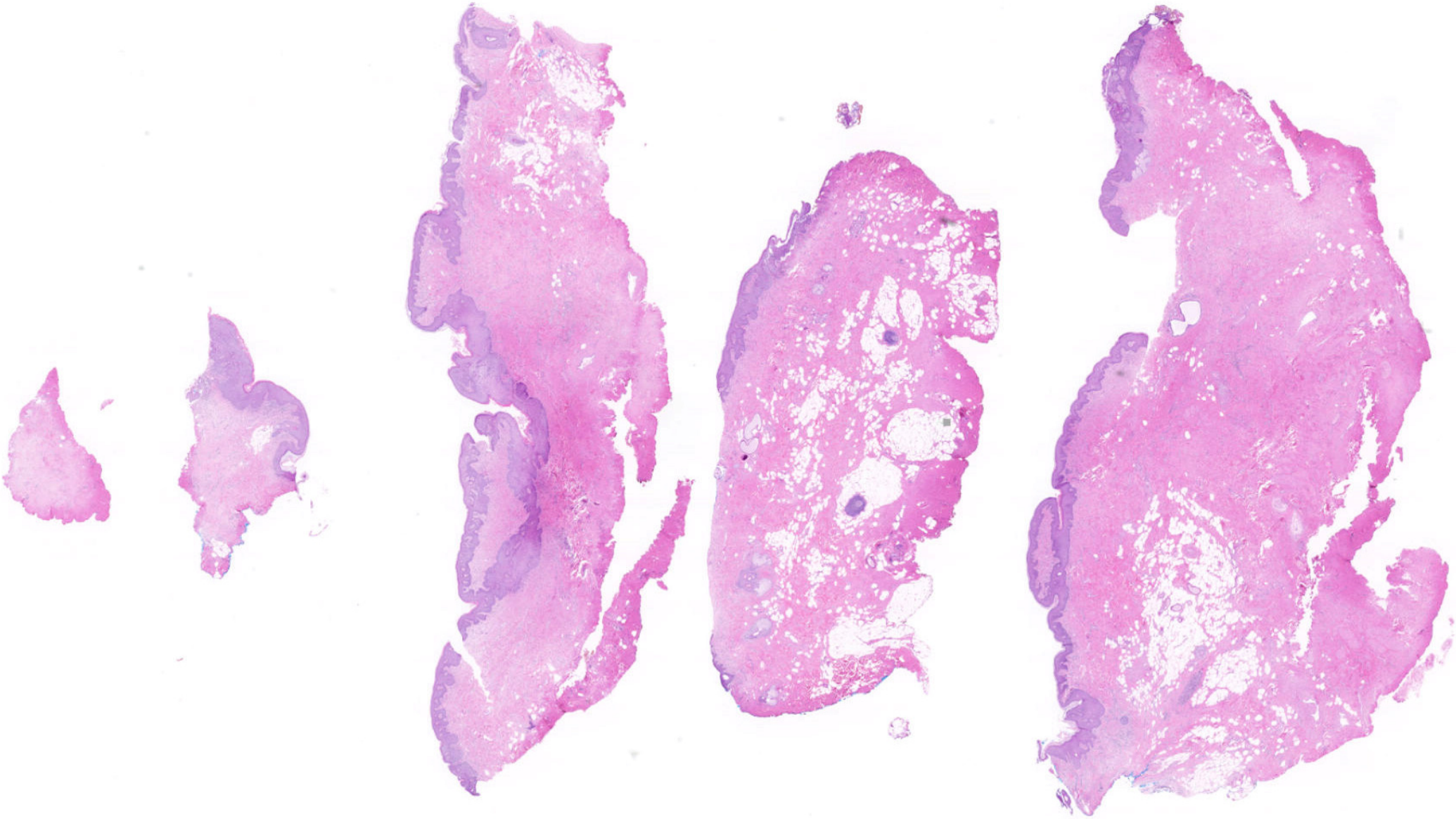

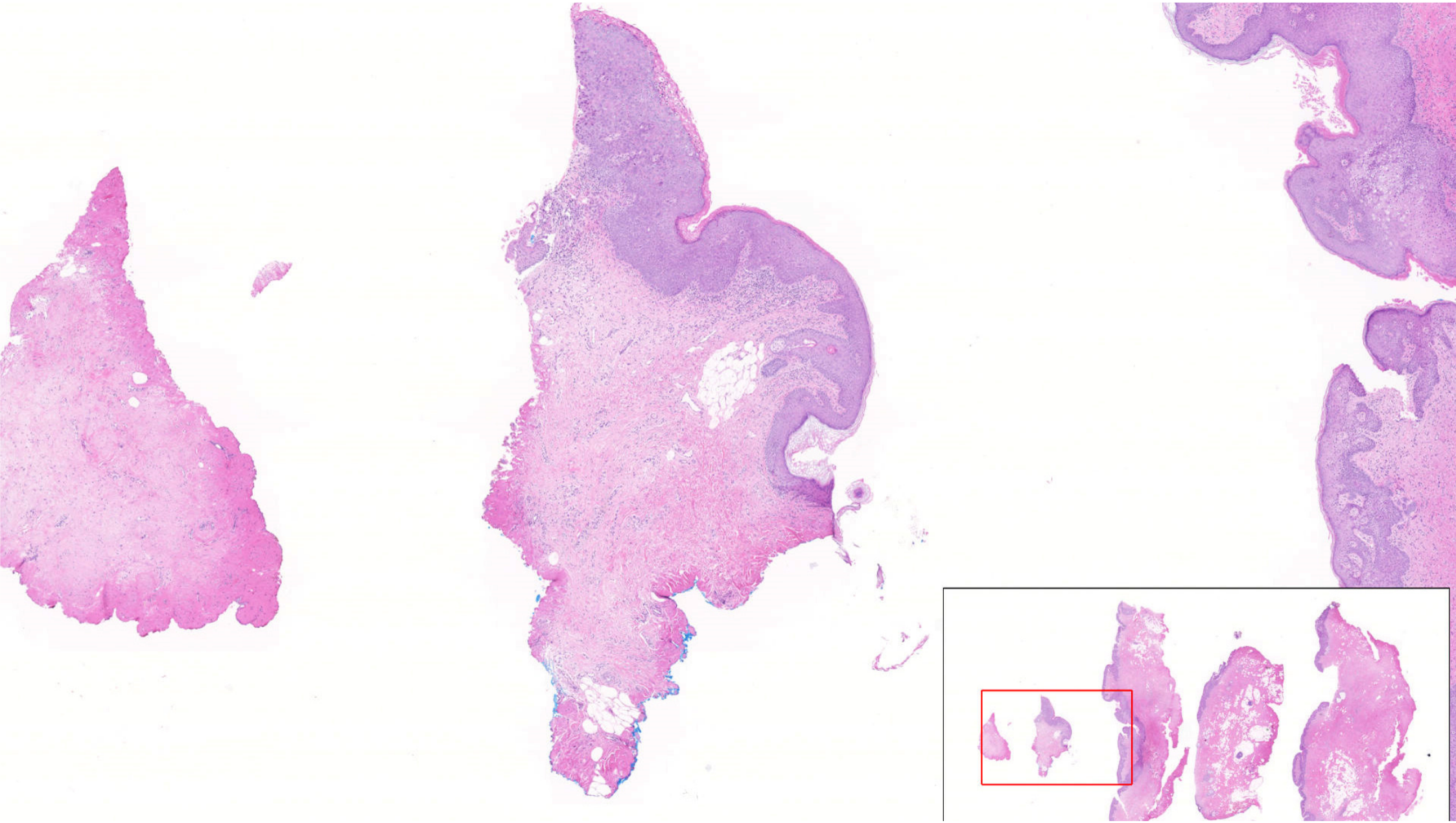

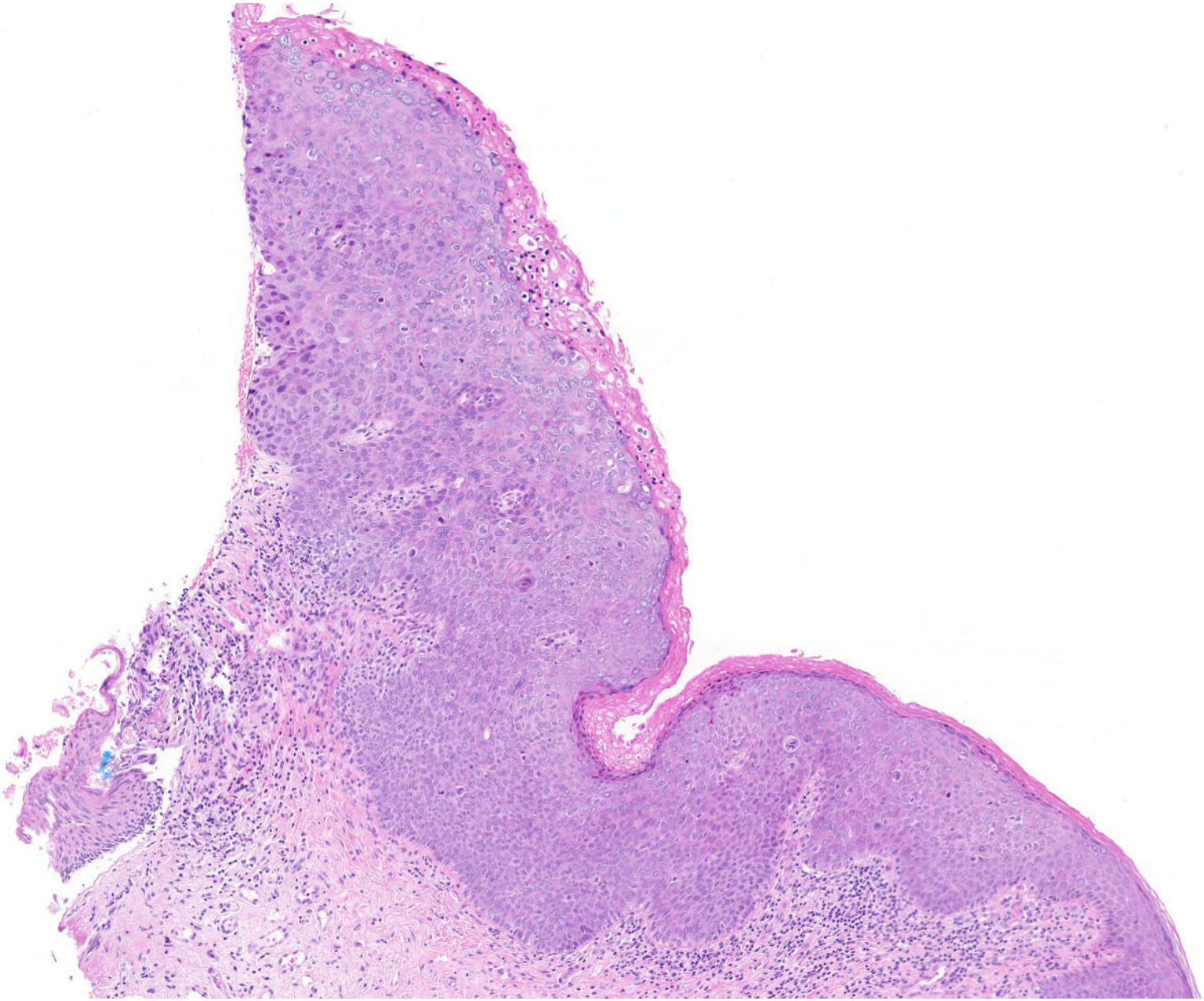



p16

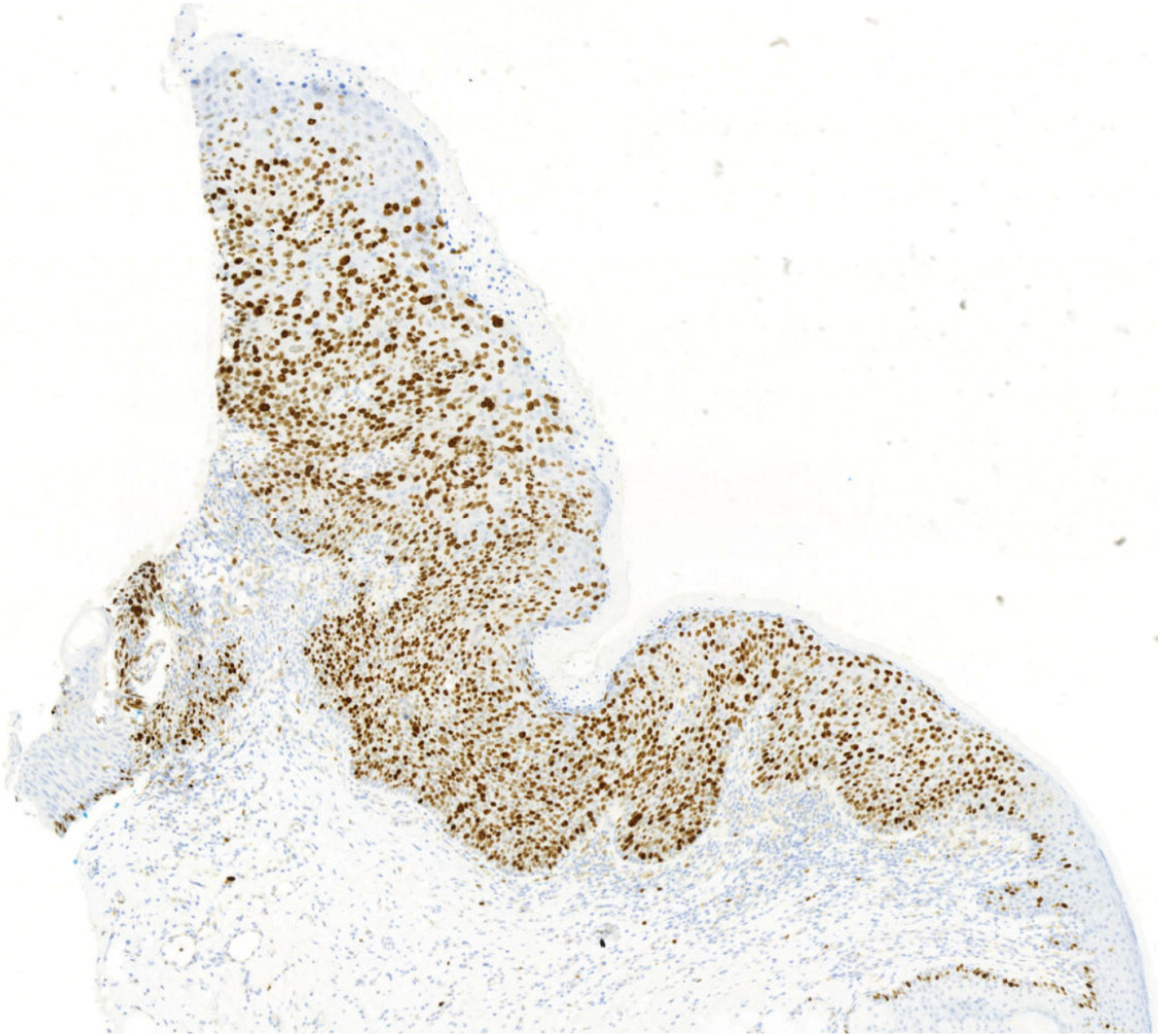

Ki67

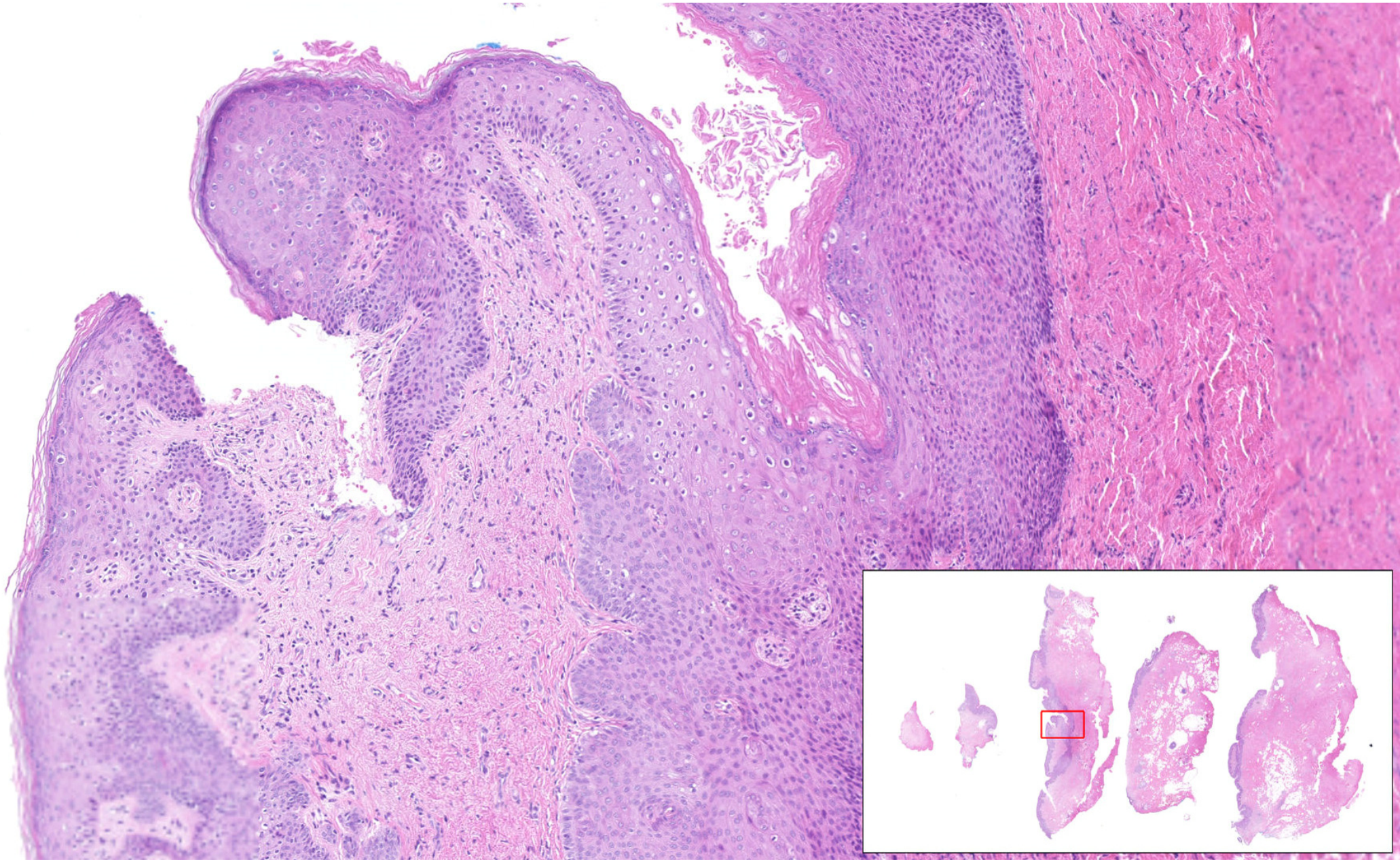

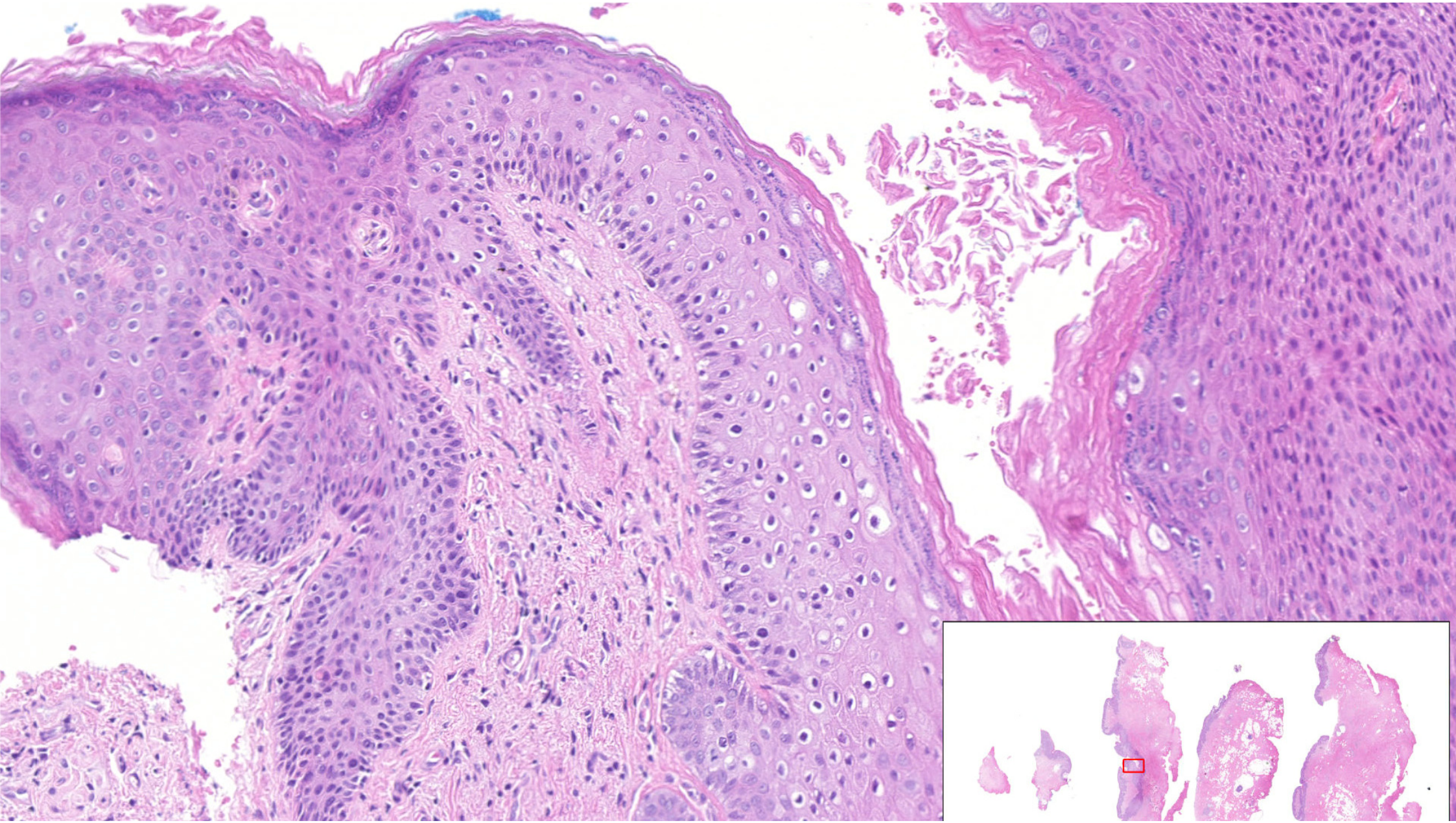

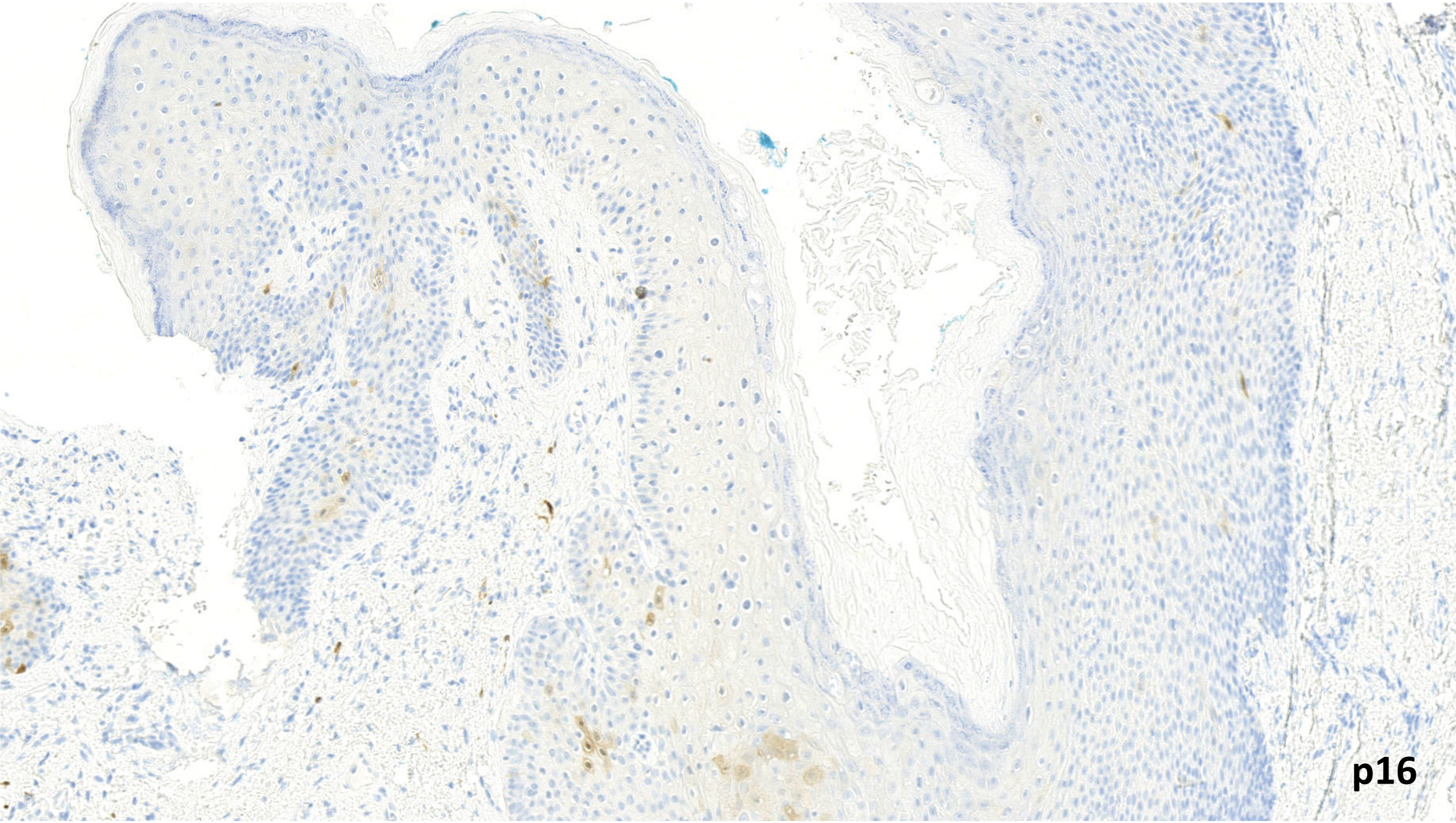
p16

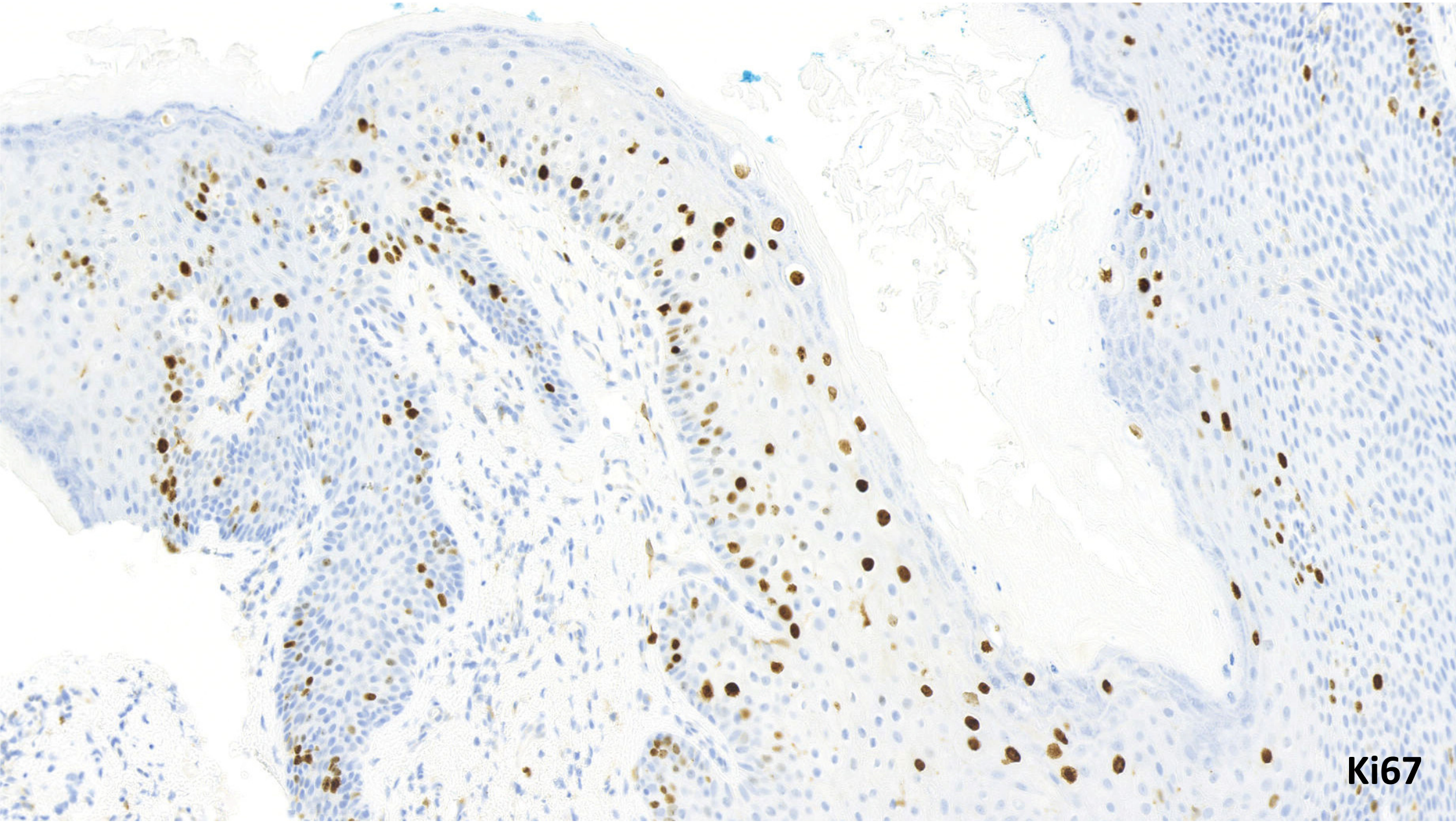
Ki67

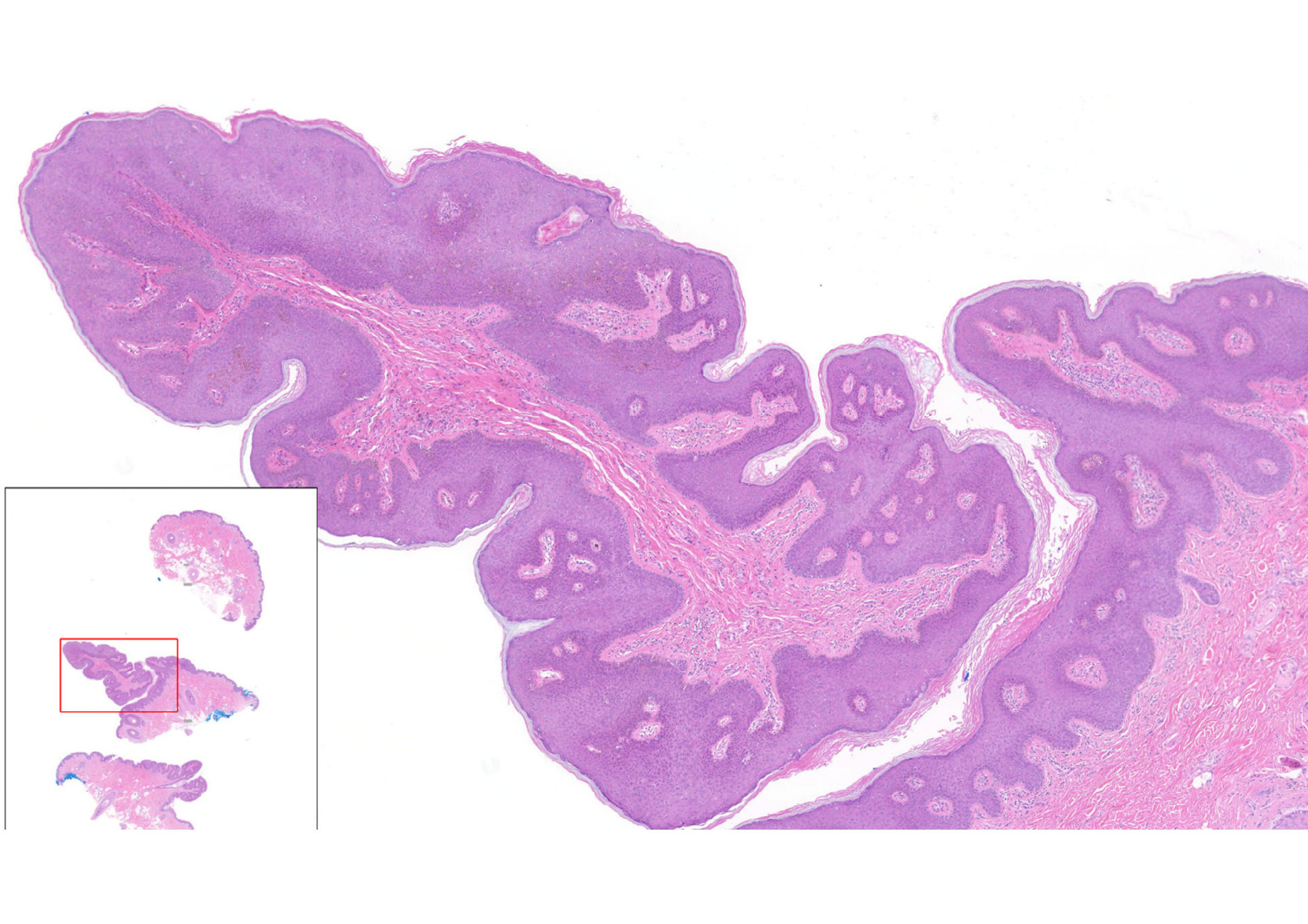

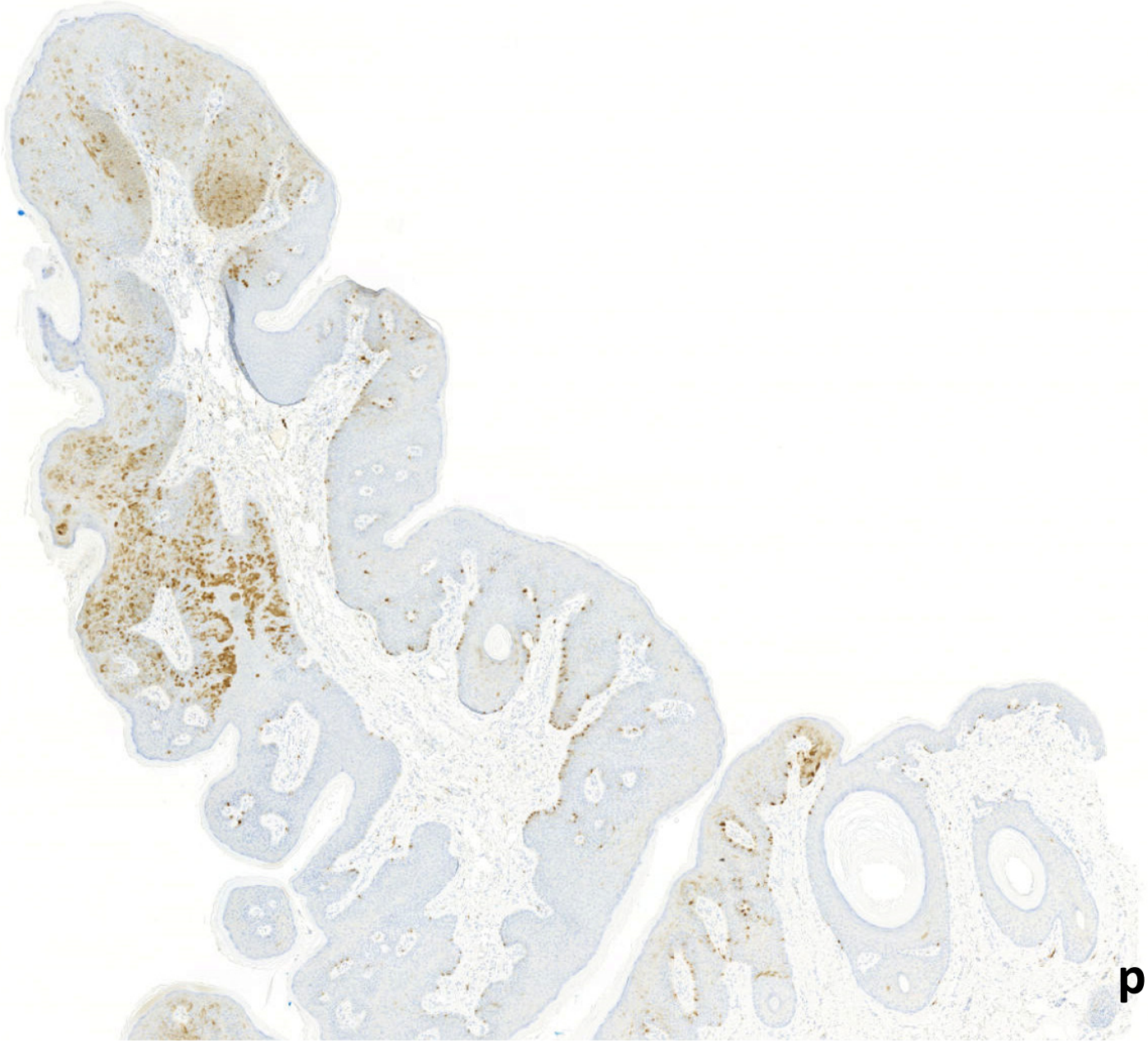
p16

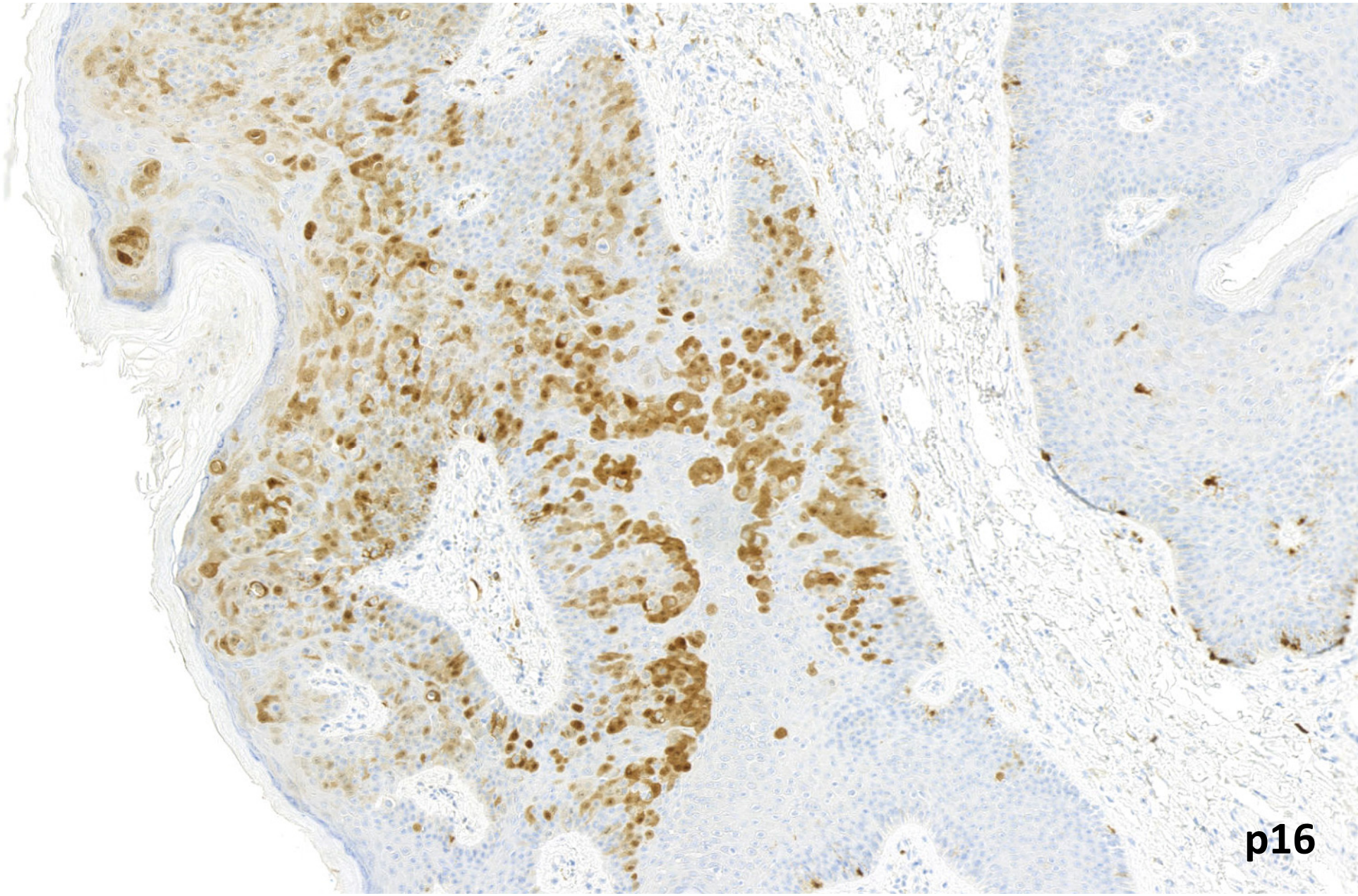
p16

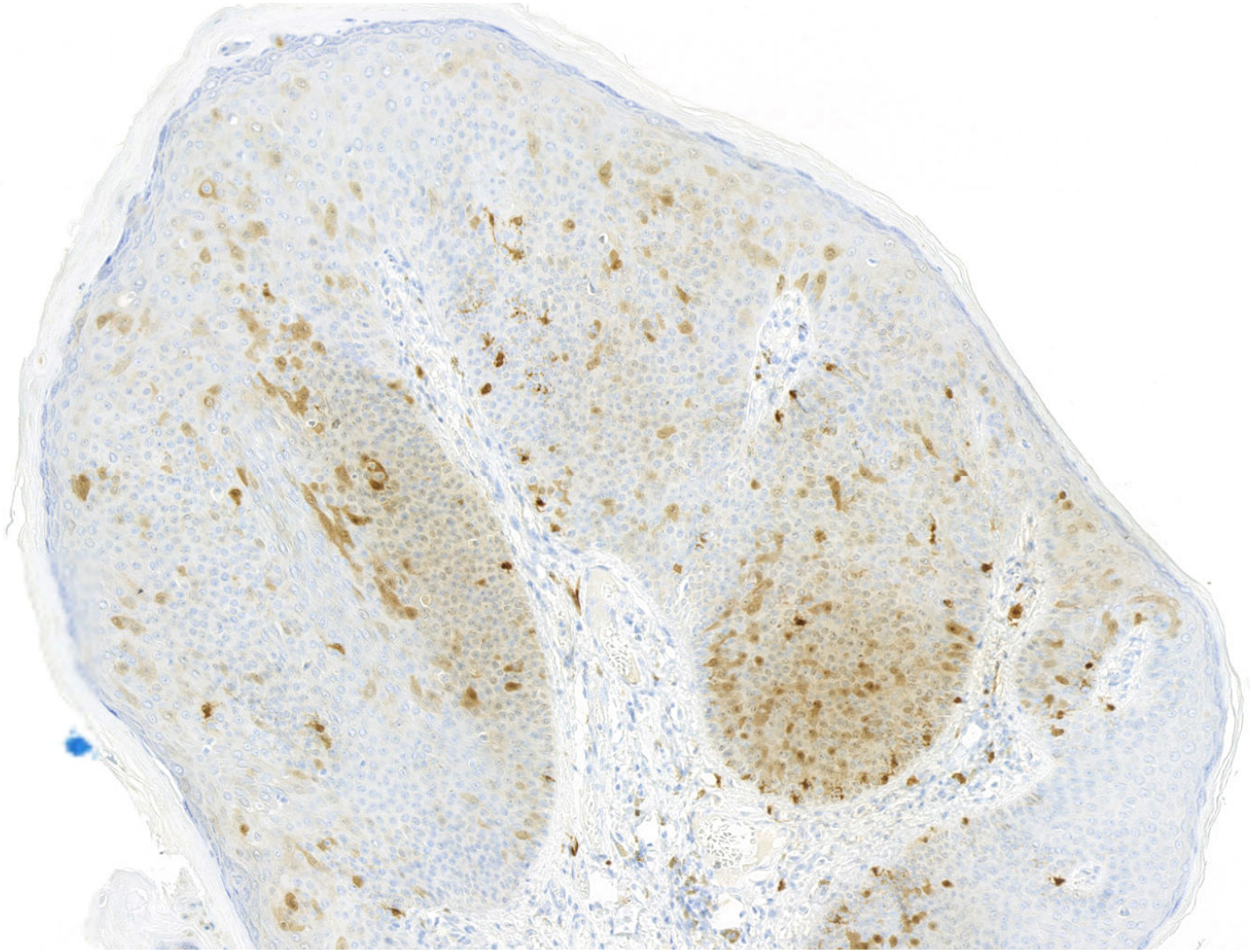

p16

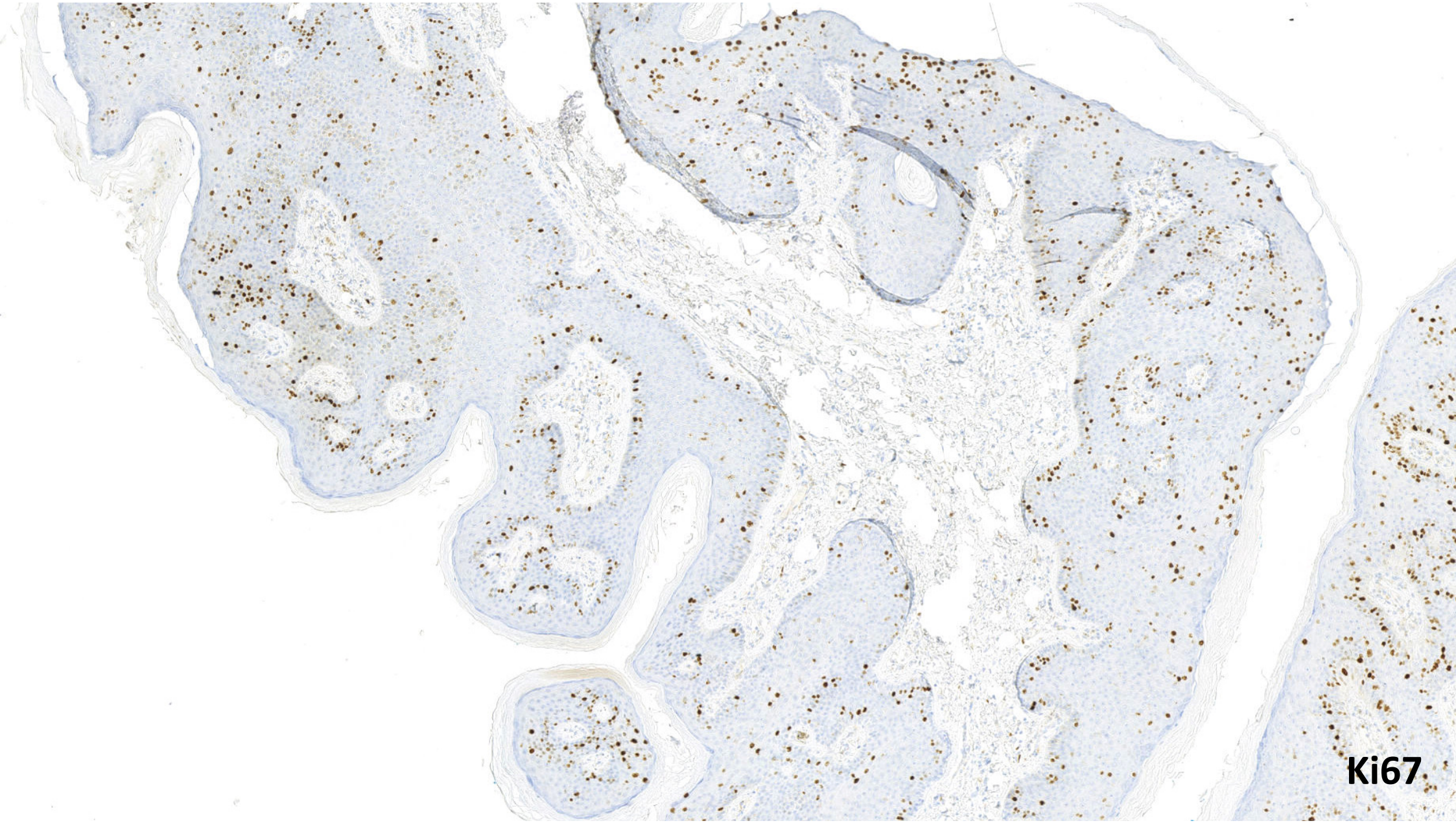
Ki67

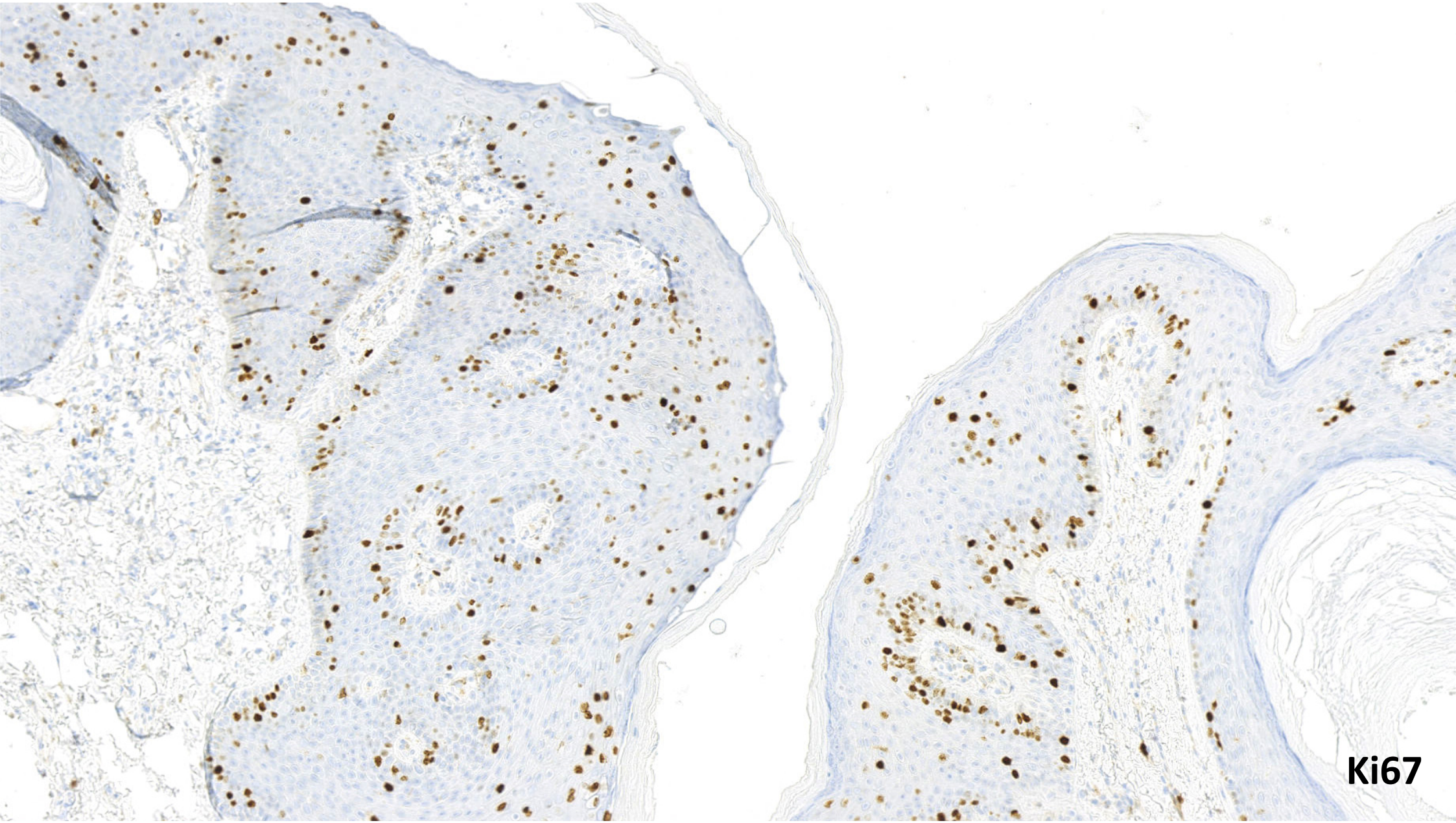
Ki67

Diagnosis

Combined HSIL and Squamous cell papillomata (LSIL)

Mixed p16 staining pattern, with suprabasal Ki67 positivity in both areas, consistent with mixed high-risk and low-risk HPV infection

HPV-related Squamous Lesions

- Lesions associated with high-risk HPV infection are ‘block’ positive for p16 with accompanying suprabasal Ki67 positivity
- This applies to both low-grade and high-grade SIL
- Lesions associated with low-risk HPV infection are p16 negative or patchily non-’block’ positive, with basal keratinocyte sparing
- Ki67 is upregulated in areas of viral DNA replication providing a useful marker of low-risk HPV infection (low-grade SIL) in the absence of p16