

HPV and HPV-associated Lesions of the Cervix

THE UNIVERSITY of EDINBURGH

Simon Herrington
Professor of Pathology
Consultant Pathologist

Outline

- HPV Biology
- HPV and Squamous Neoplasia
- HPV and Glandular Neoplasia

History



- 1976: Papillomavirus suggested as cause of cervical cancer (zur Hausen)
- 1983-1984: HPV 16/18 genome cloned from cervical cancers
- 1999: HPV DNA present in 99.7% of cervical cancers
- 2006: Vaccine introduced

http://nobelprize.org/nobel_prizes/medicine/laureates/2008/hausen-lecture.html

Human Papillomavirus Infection is Common

- Transmitted by intimate contact
- An estimated 80% of sexually active women will be exposed to the virus by age 50
- Most infections will regress spontaneously after 6-12 months
- Over time, persistent infection can lead to cancer and other HPV-related diseases
- Epithelial lesions are an uncommon consequence of a common infection

In Women, Peak Exposure to Human Papillomavirus Occurs in Late Teens and Early Twenties

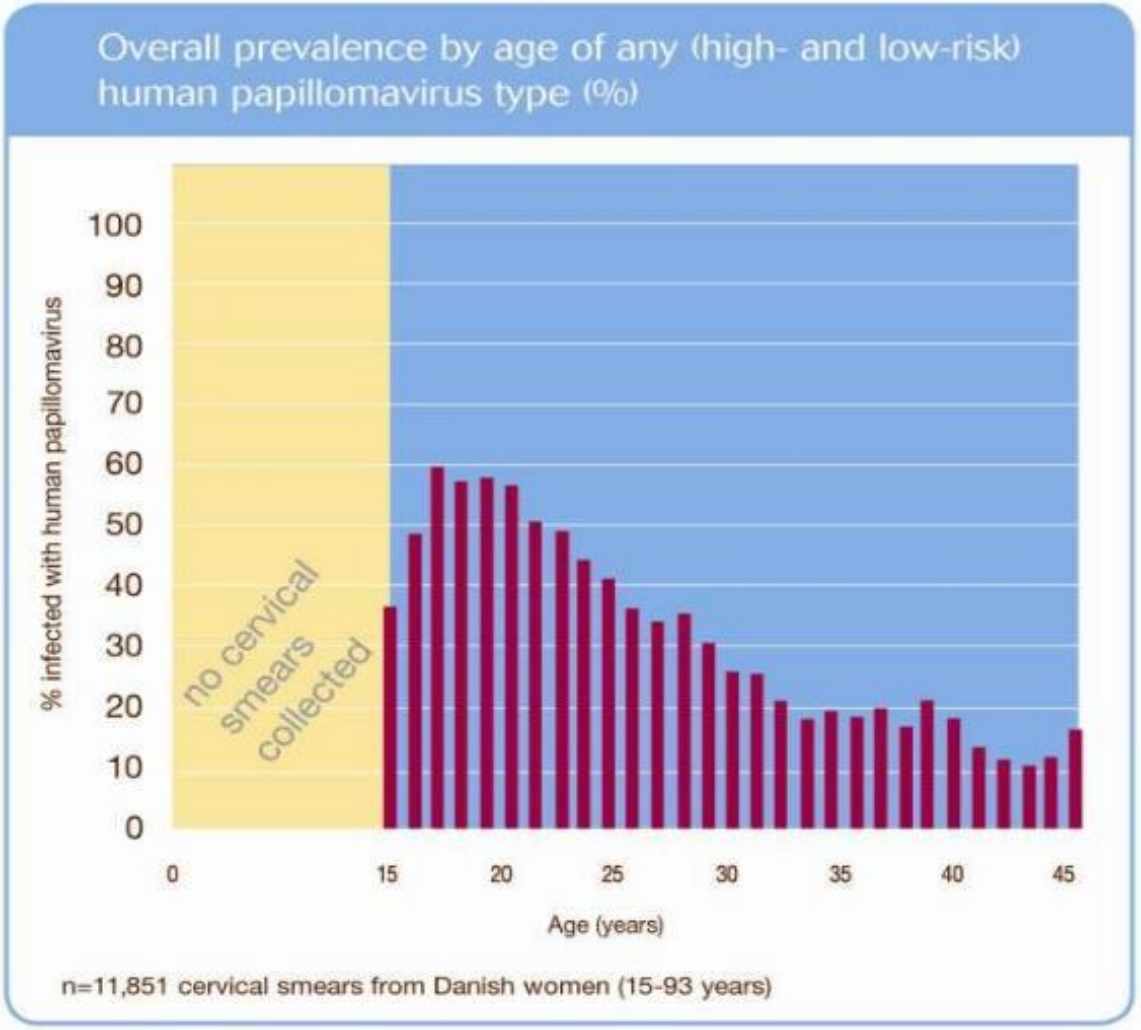

Human Papillomaviruses

- Non-enveloped, double-stranded DNA viruses
- 8 kb circular genome
- At least 200 genotypes
  - pave.niaid.nih.gov/

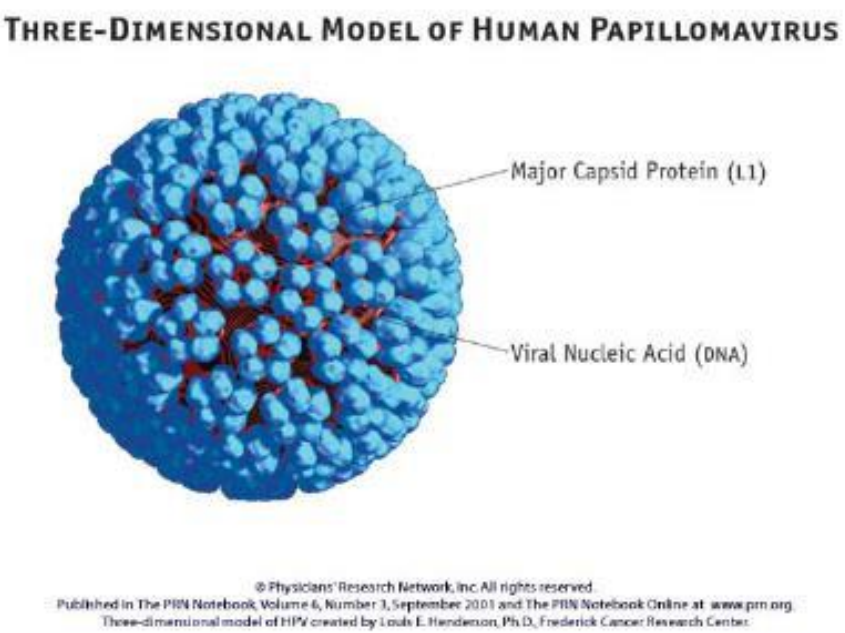

- Epitheliotropic
- High-risk vs low-risk HPV types
- Require squamous differentiation for replication

Phylogenetics

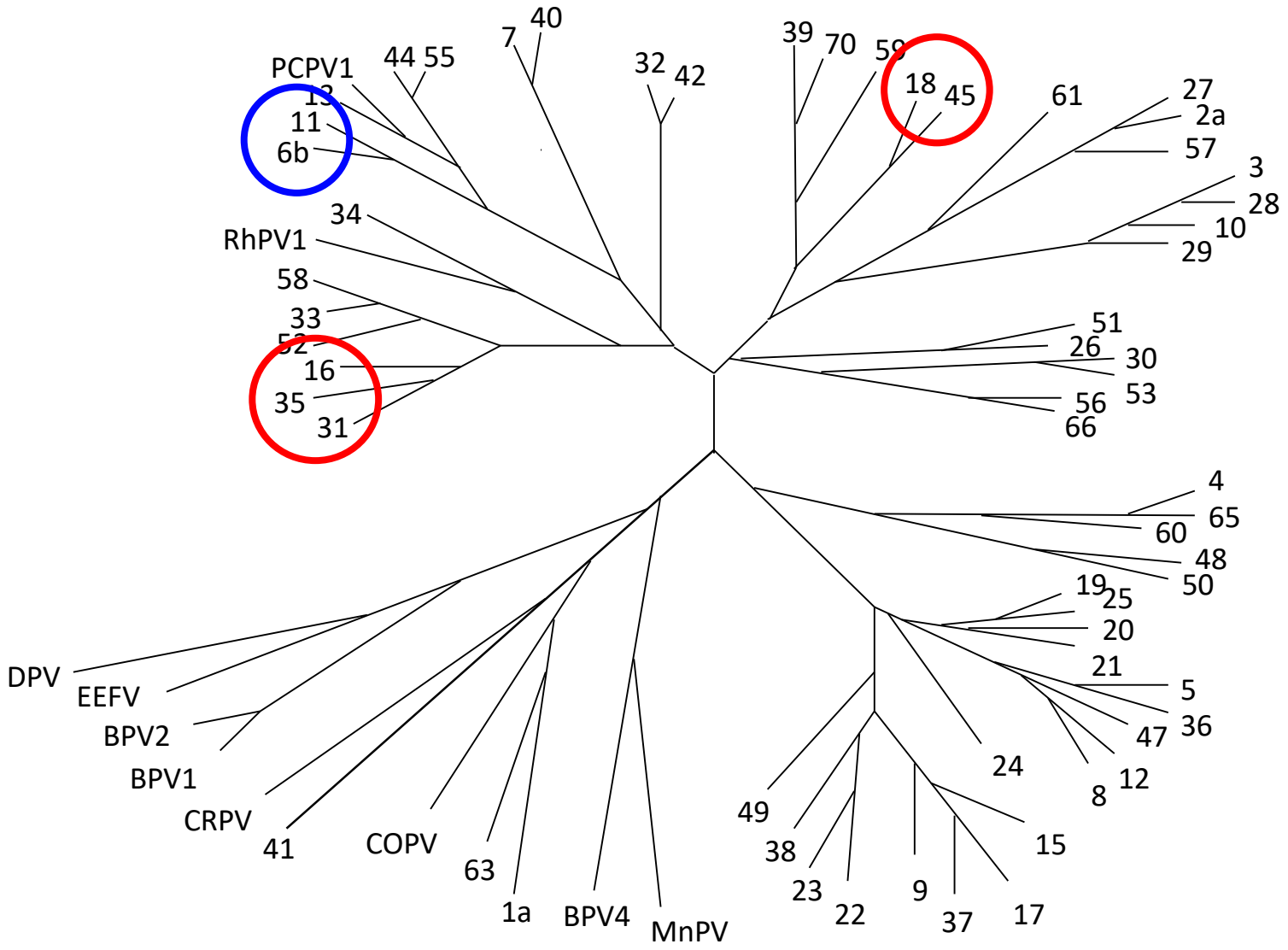

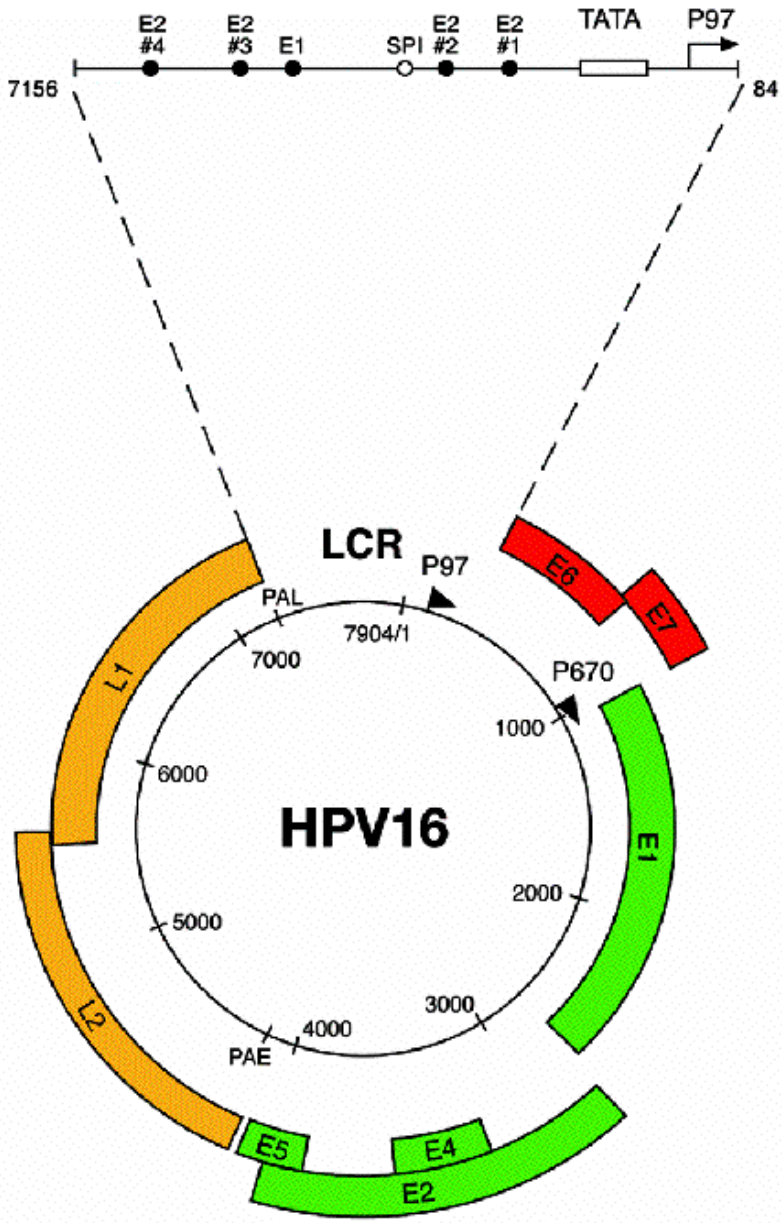

Molecular Organisation

Doorbar J *Clin Sci* 2006;110:525-41

The Papillomavirus Life Cycle

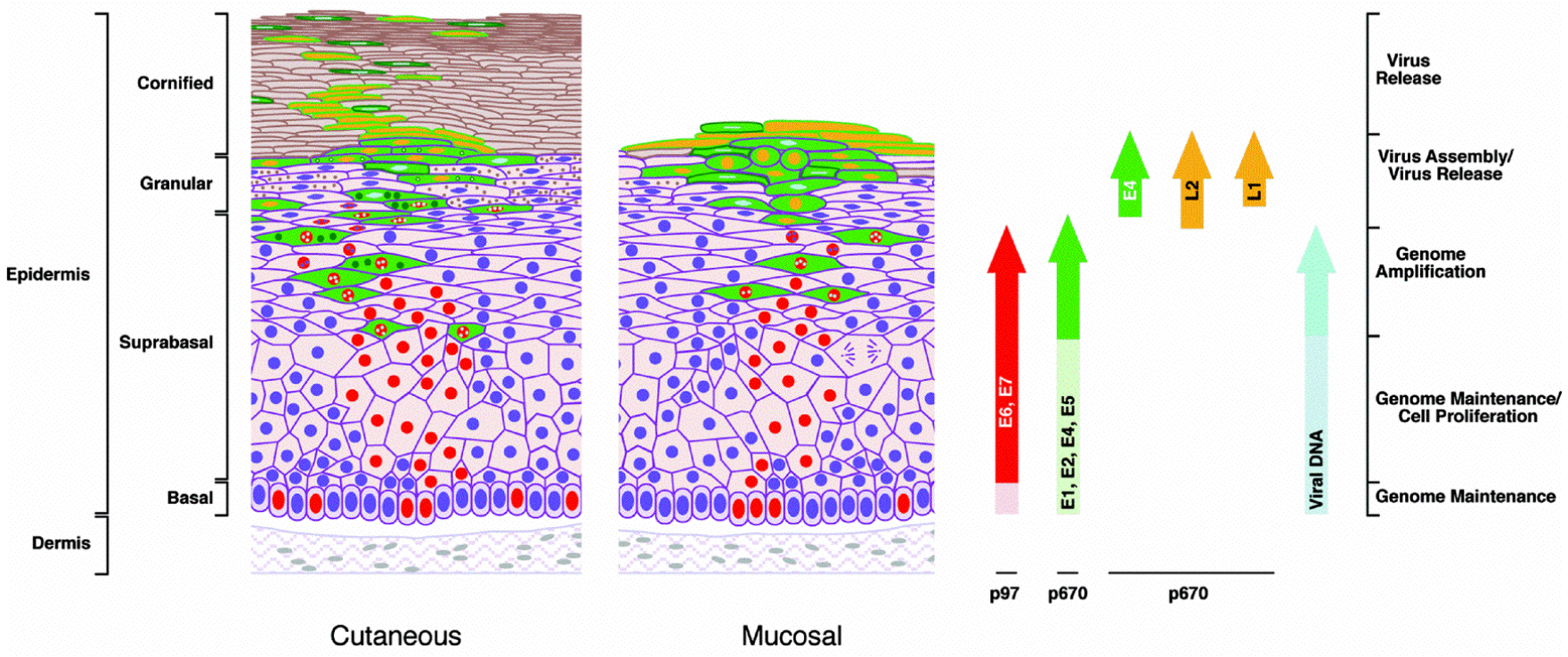

Doorbar J *Clin Sci* 2006;110:525-41

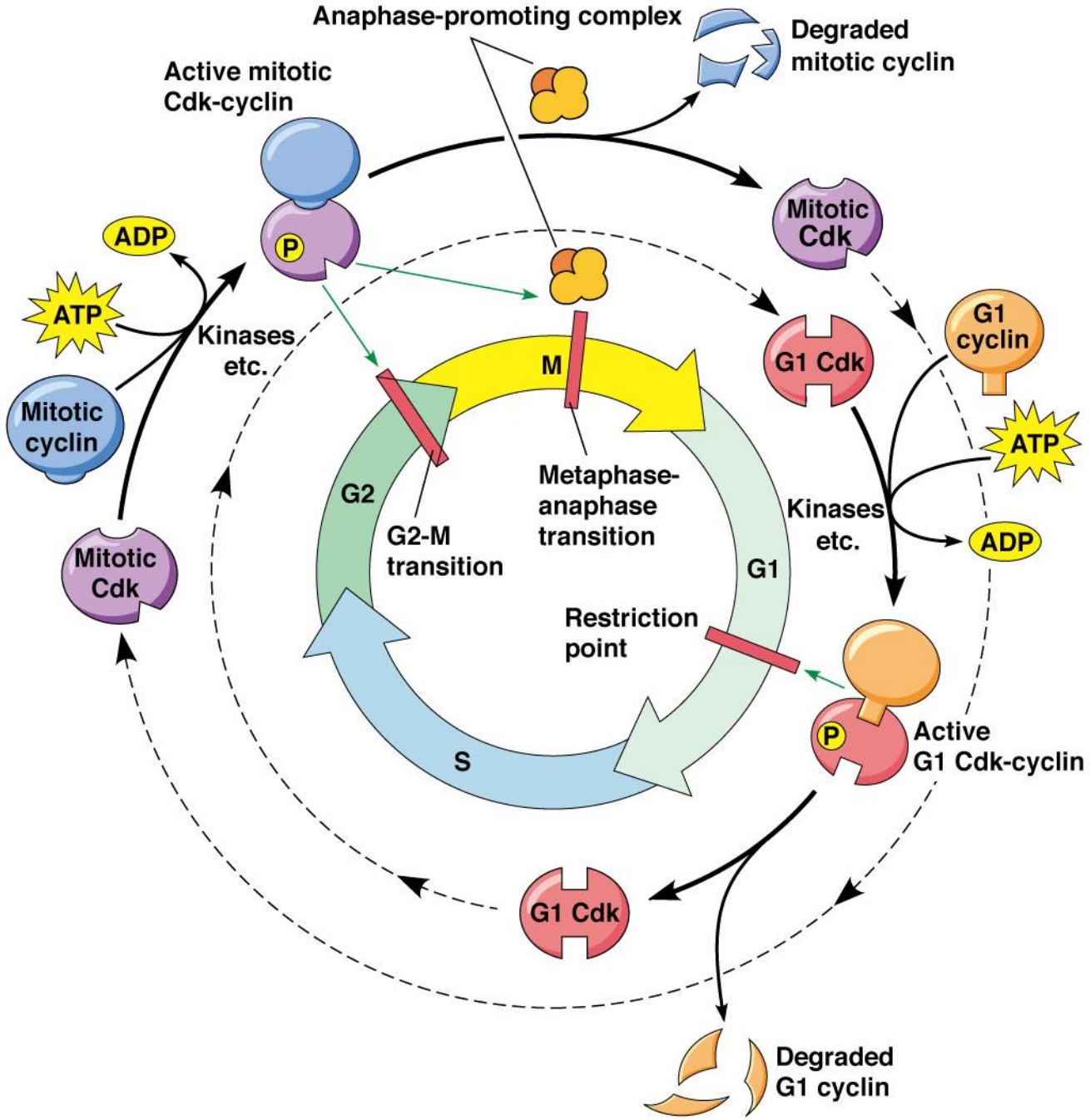

© 2012 Pearson Education, Inc.

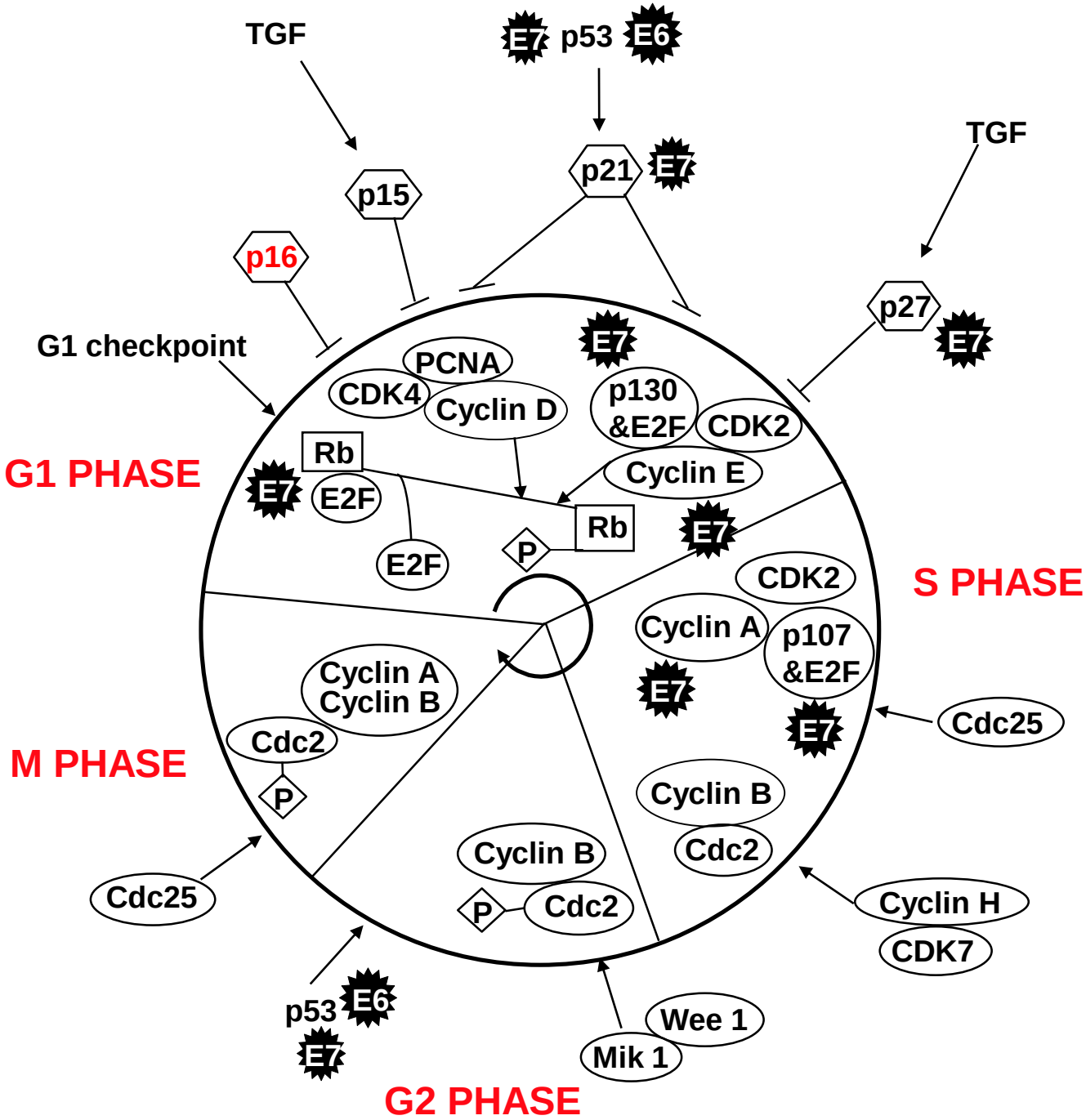
TGF
E7
p53
E6
TGF
p21
E7
p15
p16
p27
E7
G1 checkpoint
E7
PCNA
CDK4
Cyclin D
p130
&E2F
CDK2
Cyclin E
G1 PHASE
Rb
E7
E2F
Rb
E7
E2F
P
CDK2
S PHASE
Cyclin A
p107
&E2F
E7
E7
Cdc25
Cyclin A
Cyclin B
Cdc2
M PHASE
P
Cyclin B
Cdc2
Cyclin B
Cdc2
P
Cdc25
Cyclin H
CDK7
p53
E6
E7
Wee 1
Mik 1
G2 PHASE

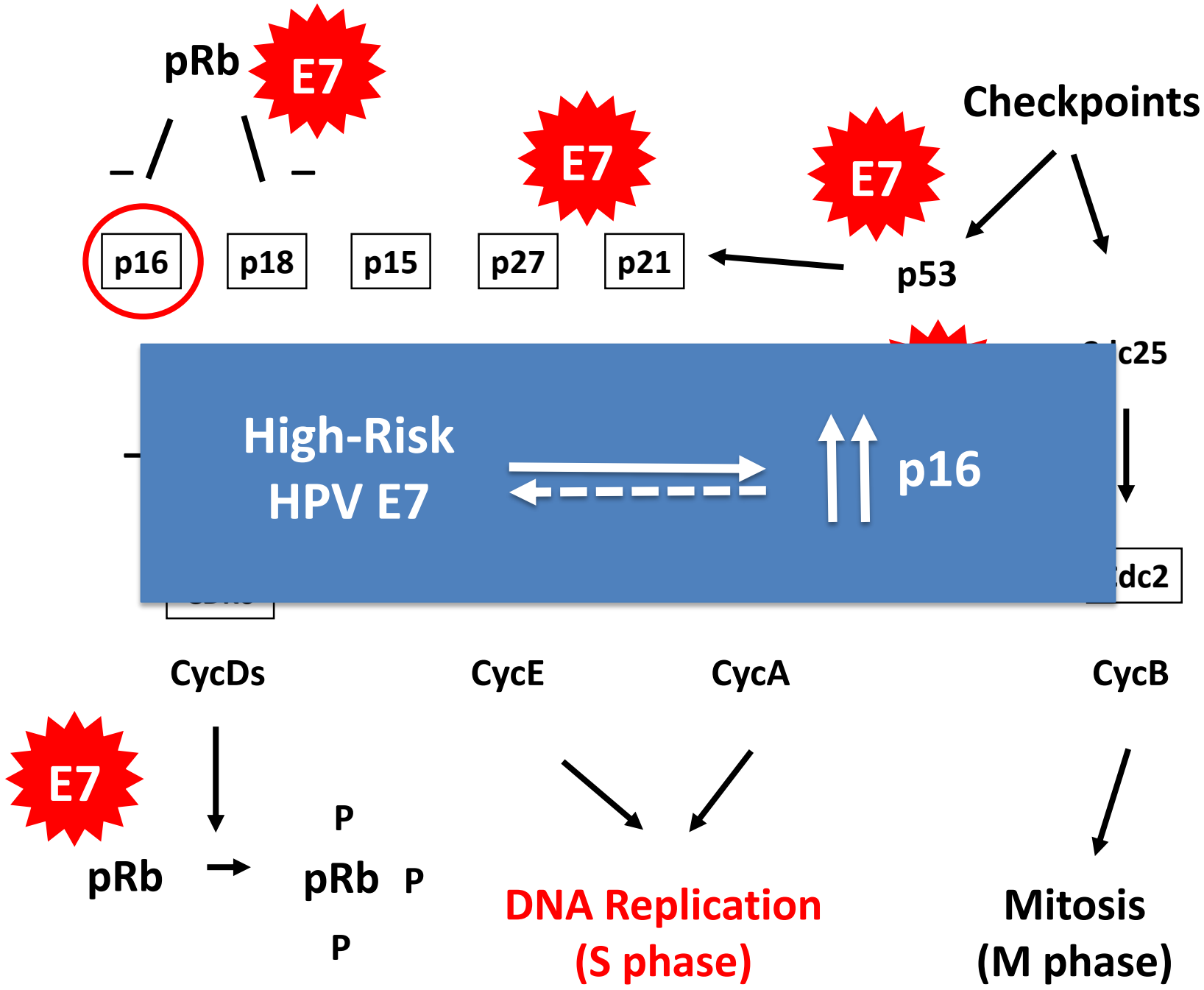
pRb
E7
E7
E7
Checkpoints
p16
p18
p15
p27
p21
p53
High-Risk
HPV E7
p16
CycDs
CycE
CycA
CycB
E7
pRb
P
pRb
P
P
DNA Replication
(S phase)
Mitosis
(M phase)

Block-positive p16



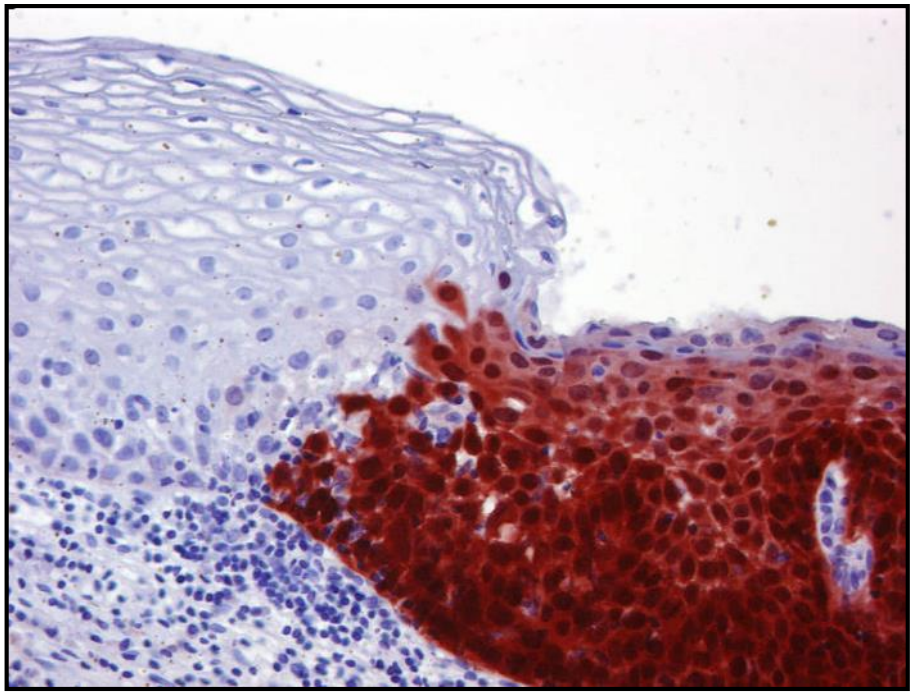

HPV and Squamous Neoplasia

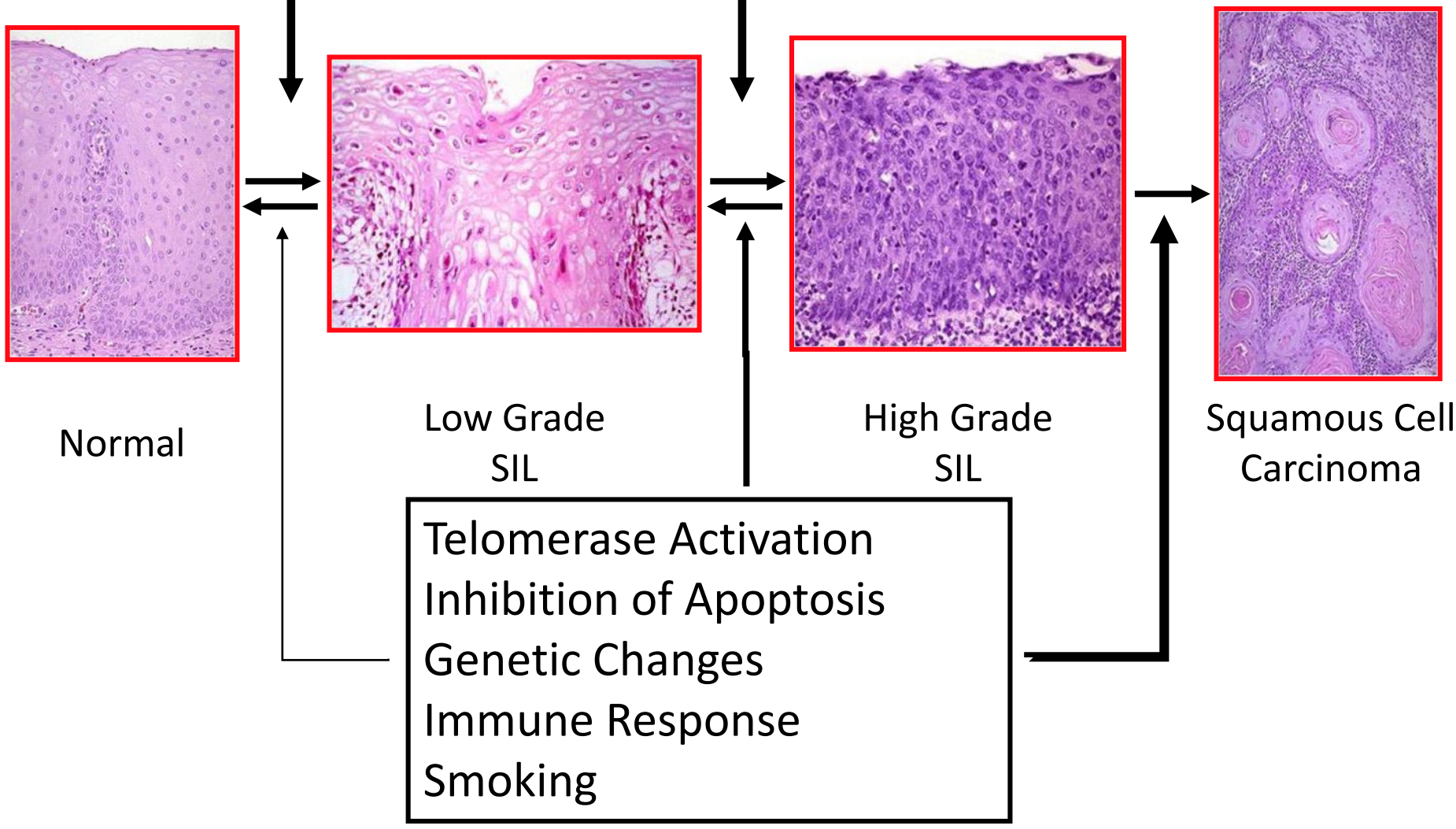

HPV and Neoplastic Progression

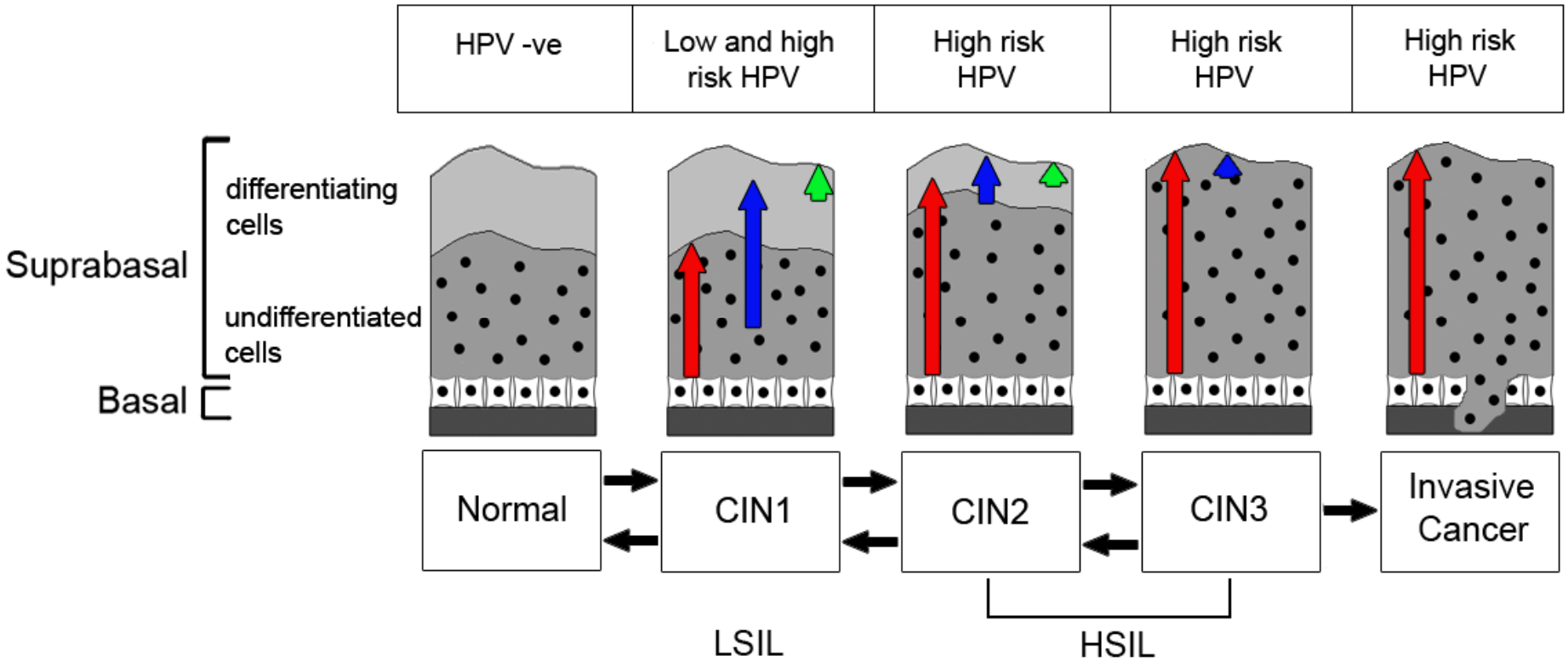

p16^{INK4A} Immunohistochemistry

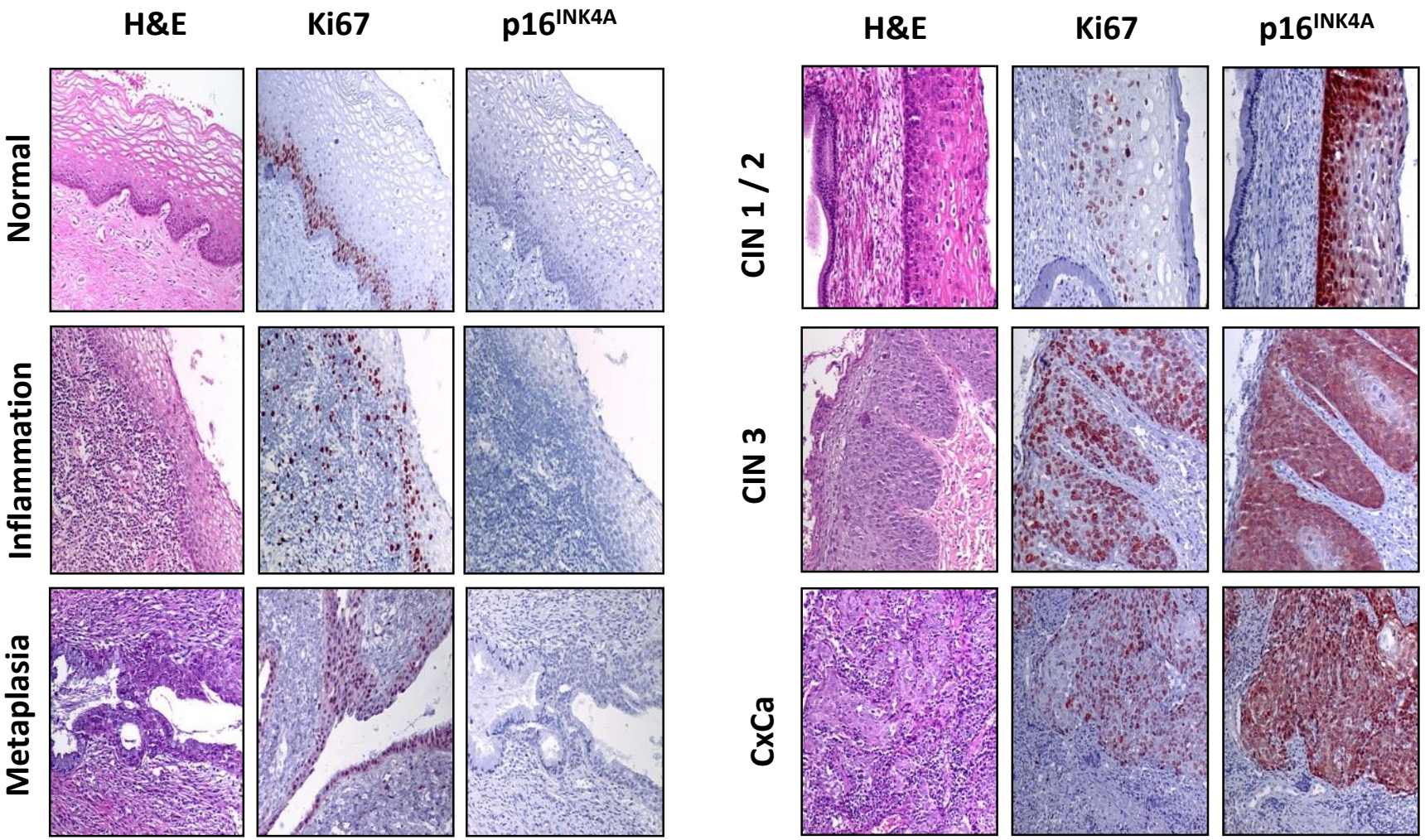

Klaes R et al Am J Surg Pathol 2002;11: 1389-99

What Governs Progression?

- HPV type
  - High-risk HPV types, particularly 16 and 18
- Persistence of HPV infection
- Up-regulation of E6/E7
  - Loss of capacity to replicate viral DNA
- HPV integration
  - Chromosome sites random
  - Viral breakpoint consistent (E1/E2)

Where does HPV infection occur?

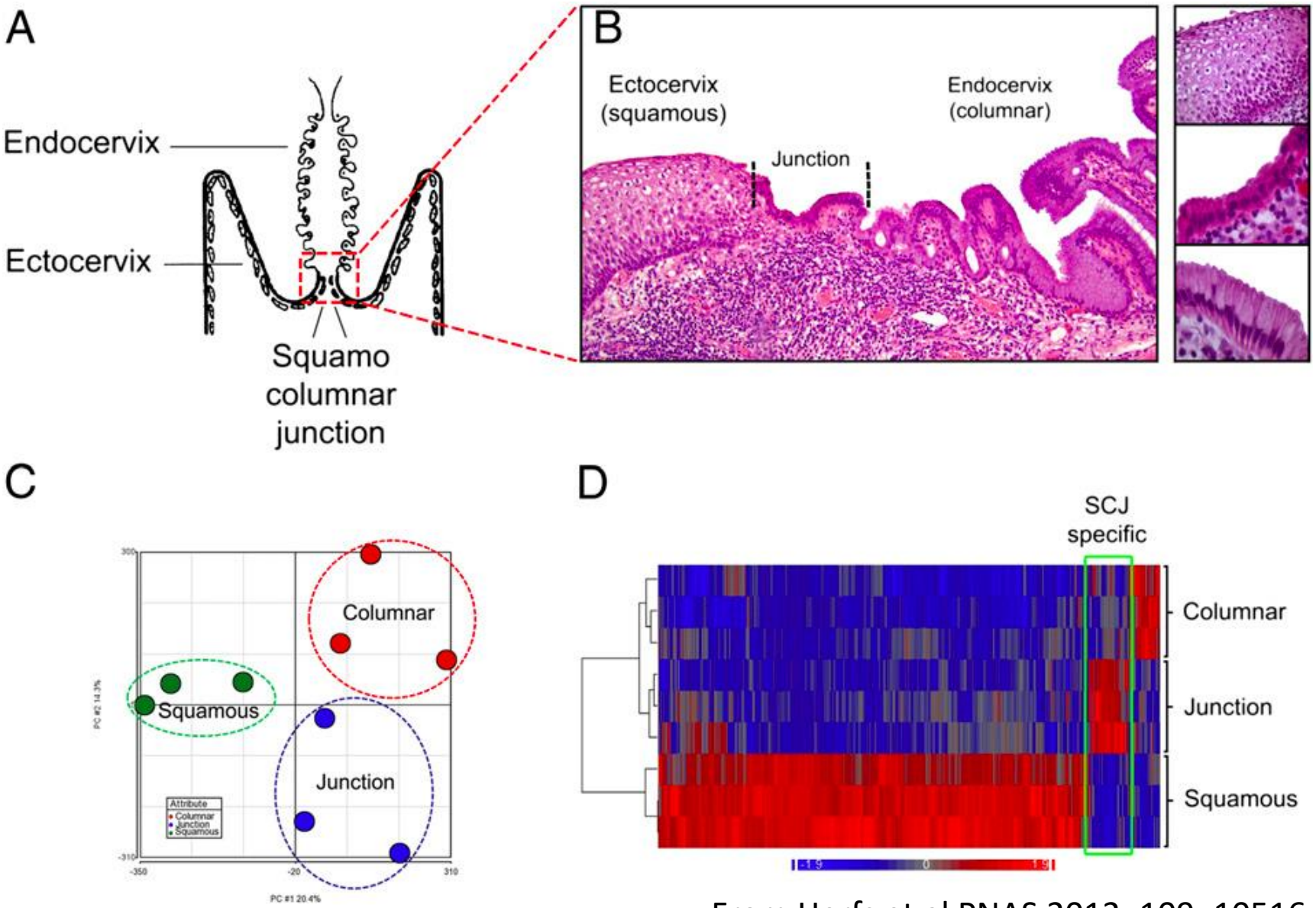

From Herfs et al PNAS 2012; 109: 10516-21

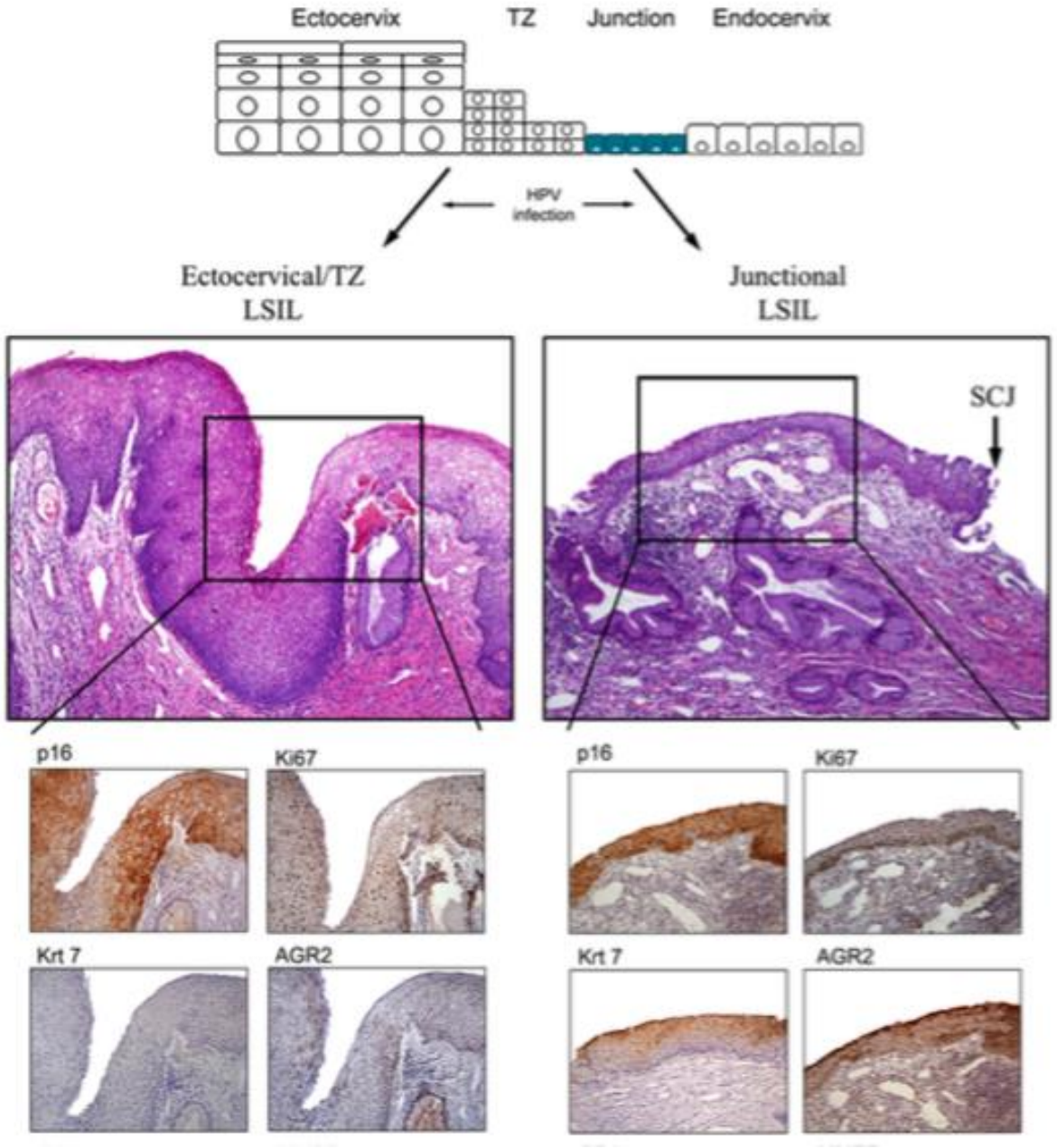

From Herfs et al Am J Surg Pathol 2013; 37: 1311-18

Cytokeratin 7 as a Predictive Marker

- Squamocolumnar junction cells express cytokeratin 7
- LSILs arising in these cells may be more likely to progress to HSIL
- Cytokeratin 7 may therefore be a predictive marker of LSIL progression
- However, this is an emerging area, with no clear consensus
- ‘Larger cohorts using consensus-diagnosed LSIL are needed to confirm these results before CK7 may be considered for clinical validation’

Paquette et al Am J Surg Pathol 2016;40:236–243

HPV-associated Neoplasia

- High vs low-risk HPV types
- Productive vs abortive/transforming infection
- Up-regulation of E6/E7 expression key
- p16 protein expression is a surrogate marker of high-risk HPV E7 expression
- Infection of SCJ cells may produce more clinically significant lesions

Cervical Epithelial Lesions

Squamous cell tumours and precursors

- Squamous intraepithelial lesions
  - Low-grade squamous intraepithelial lesion (HPV only, CIN 1)
  - High grade squamous intraepithelial lesion (CIN 2, CIN 3)
- Squamous cell carcinoma (keratinising, non-keratinising etc)

Glandular tumours and precursors

- Adenocarcinoma in situ (High grade CGIN)
- Adenocarcinoma
  - Endocervical adenocarcinoma, usual type
  - Mucinous carcinoma, NOS
    - Gastric type (including adenoma malignum / minimal deviation adenocarcinoma)
    - Intestinal type
    - Signet-ring cell type
  - Villoglandular adenocarcinoma
  - Endometrioid adenocarcinoma
  - Clear cell adenocarcinoma
  - Serous adenocarcinoma
  - Mesonephric adenocarcinoma
  - Adenocarcinoma admixed with neuroendocrine carcinoma

Cervical Epithelial Lesions

Squamous cell tumours and precursors

- Squamous intraepithelial lesions
  - Low-grade squamous intraepithelial lesion (HPV only, CIN 1)
  - High grade squamous intraepithelial lesion (CIN 2, CIN 3)
- Squamous cell carcinoma (keratinising, non-keratinising etc)

Glandular tumours and precursors

- Adenocarcinoma in situ (High grade CGIN)
- Adenocarcinoma
  - Endocervical adenocarcinoma, usual type
  - Mucinous carcinoma, NOS
    - Gastric type (including adenoma malignum / minimal deviation adenocarcinoma)
    - Intestinal type
    - Signet-ring cell type
  - Villoglandular adenocarcinoma
  - Endometrioid adenocarcinoma
  - Clear cell adenocarcinoma
  - Serous adenocarcinoma
  - Mesonephric adenocarcinoma
  - Adenocarcinoma admixed with neuroendocrine carcinoma

Red = associated with high-risk HPV
Blue = not associated with high-risk HPV
Black = uncertain

Park et al, Am J Surg Pathol 2011; 35: 633-636

p16 as a Surrogate Marker of High-Risk HPV Infection

- p16 overexpression reflects pRb pathway disruption and/or senescence, not just HPV infection

- In lower anogenital squamous intraepithelial lesions
  - Discrimination between high-grade SIL and mimics
  - ?? Triage of 'CIN 2'
  - Not for diagnosis of low-grade SIL
  - Only 'block-type' positivity should be considered positive

    Darragh et al Int J Gynecol Pathol 2013; 32: 76-11

- In lower genital tract tumours
  - Strong diffuse p16 positivity supports an HPV-associated aetiology
  - Endometrioid endometrial adenocarcinomas can be diffusely positive
  - Serous carcinomas are typically diffusely positive
  - Context is important and p16 should be used as part of a panel

Problems

- **p16 positive low-grade lesions**
- p16 negative high-grade lesions?
  - Gene deletion
  - Gene silencing
- Tendency to up-grade – p16 does NOT grade lesions

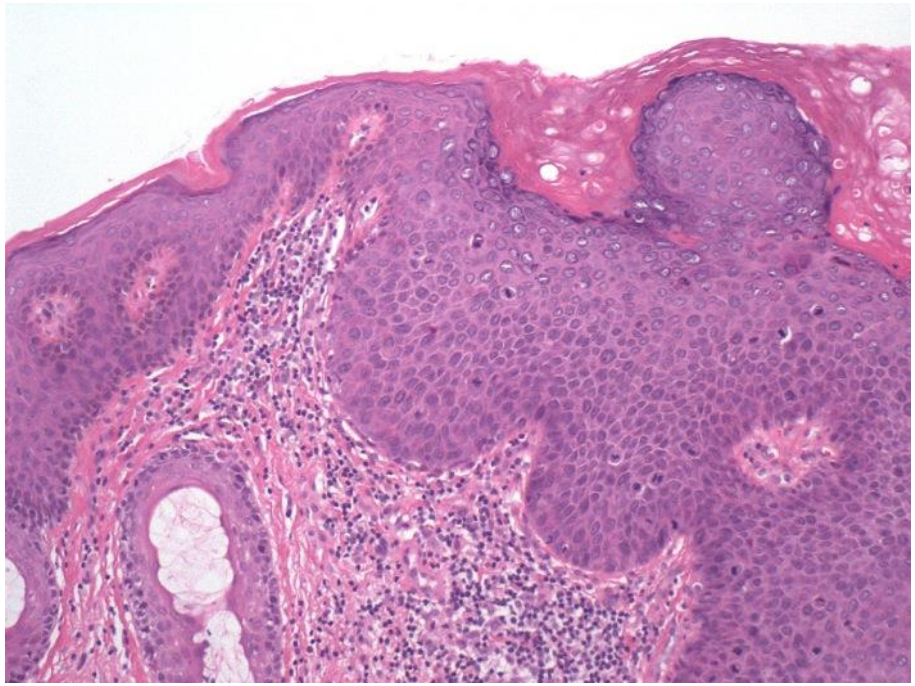

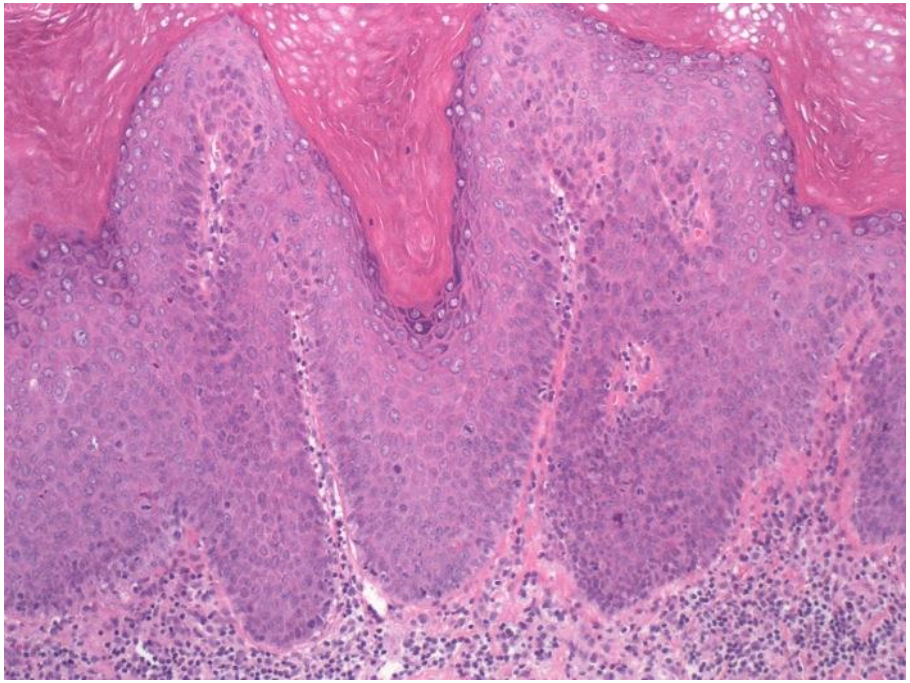

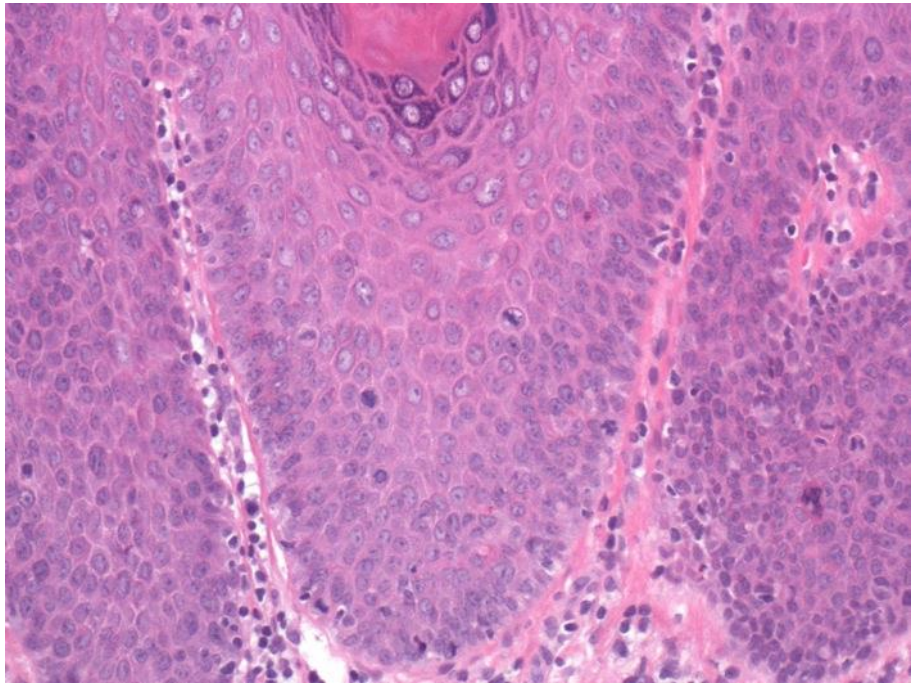

HSIL
(Usual-type VIN)

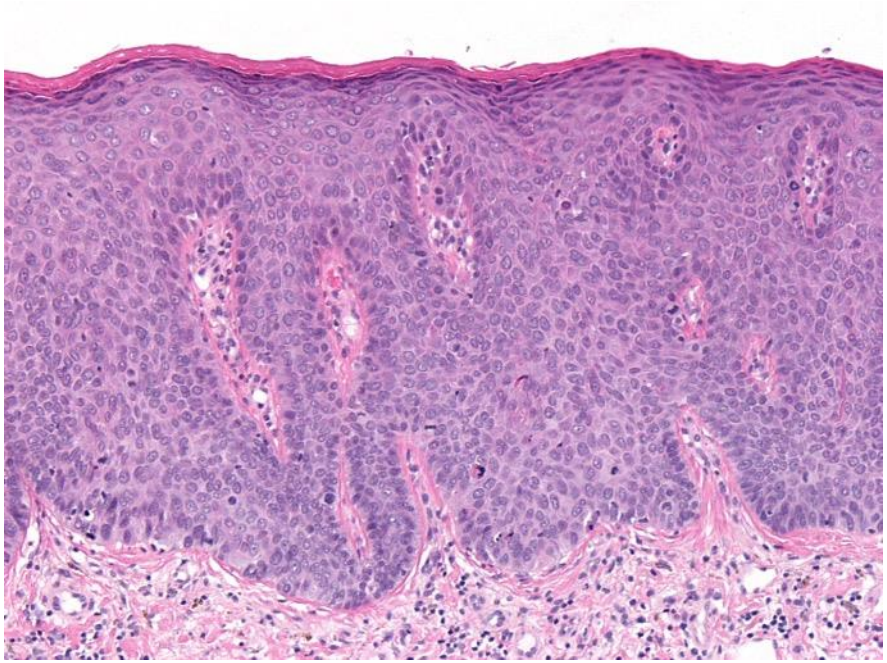

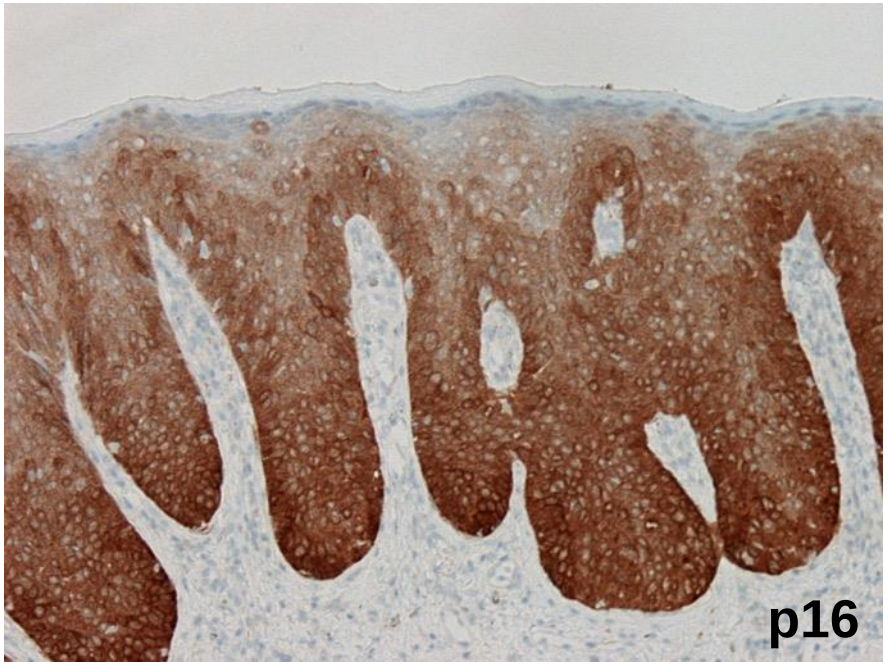

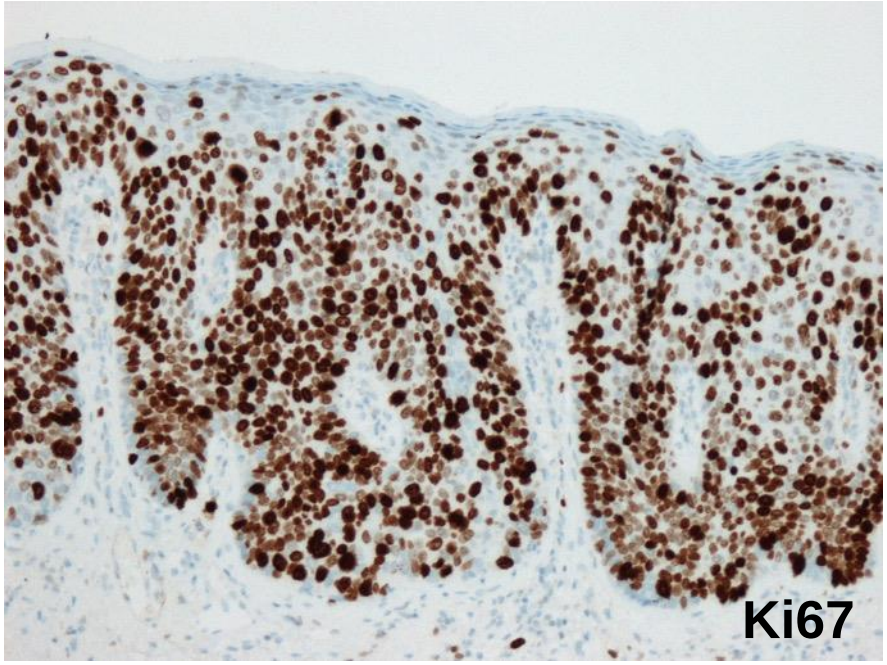

HSIL
(Usual-type VIN)



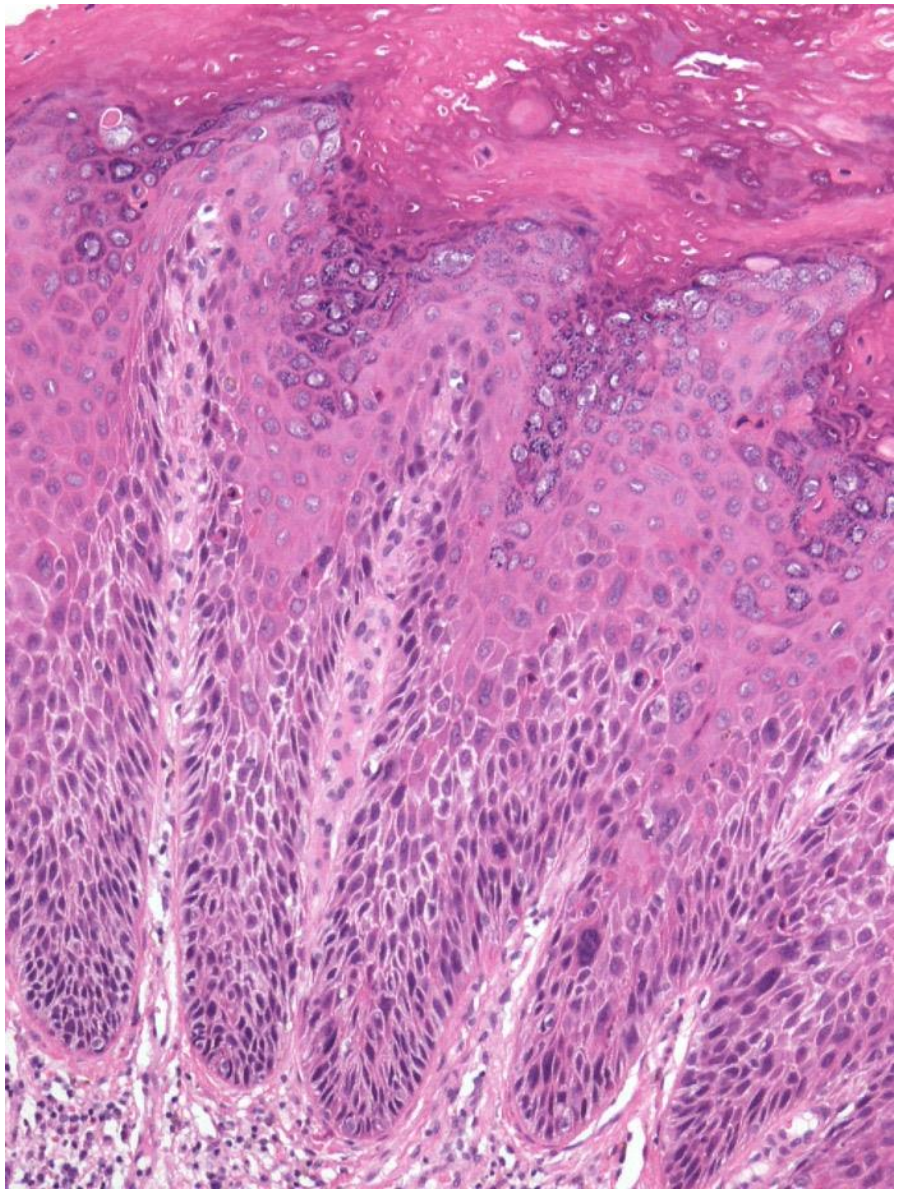

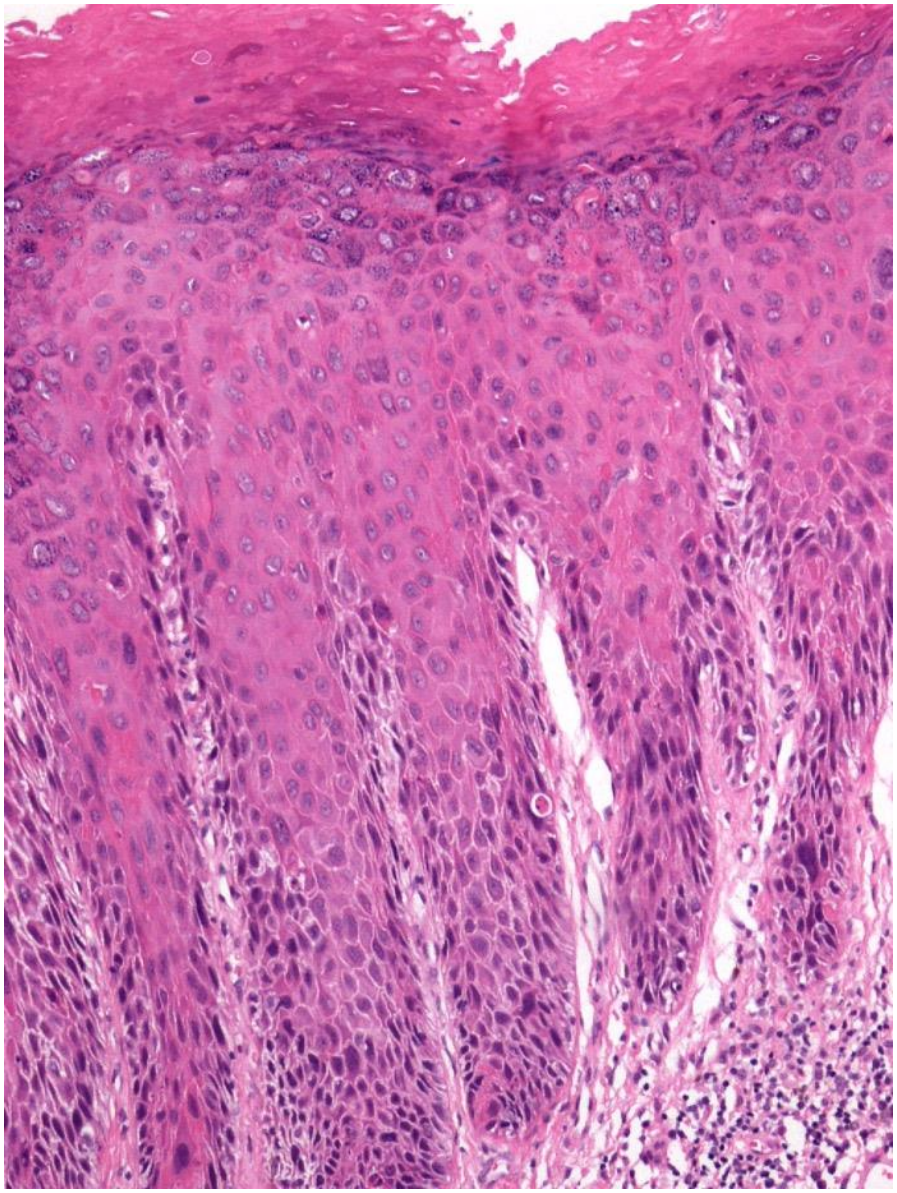

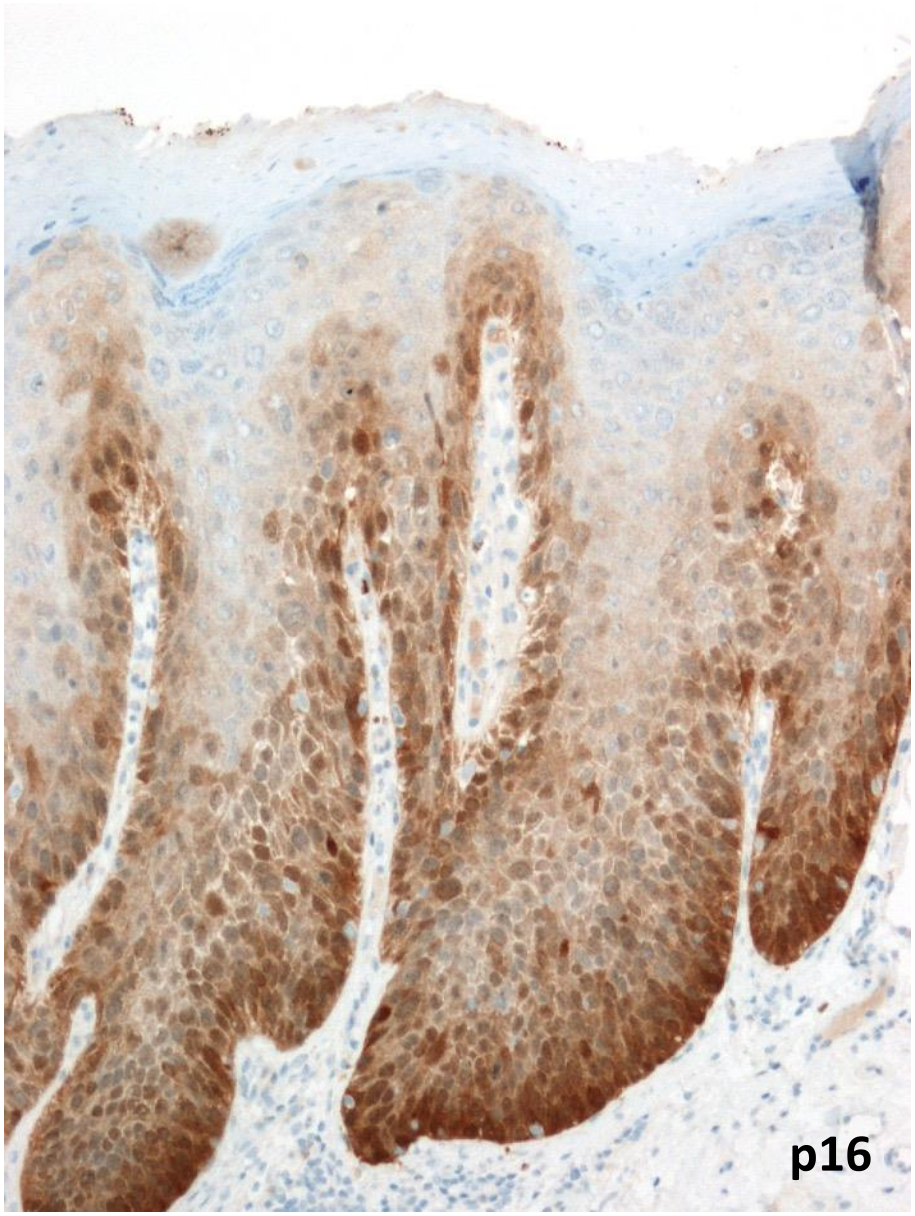
p16

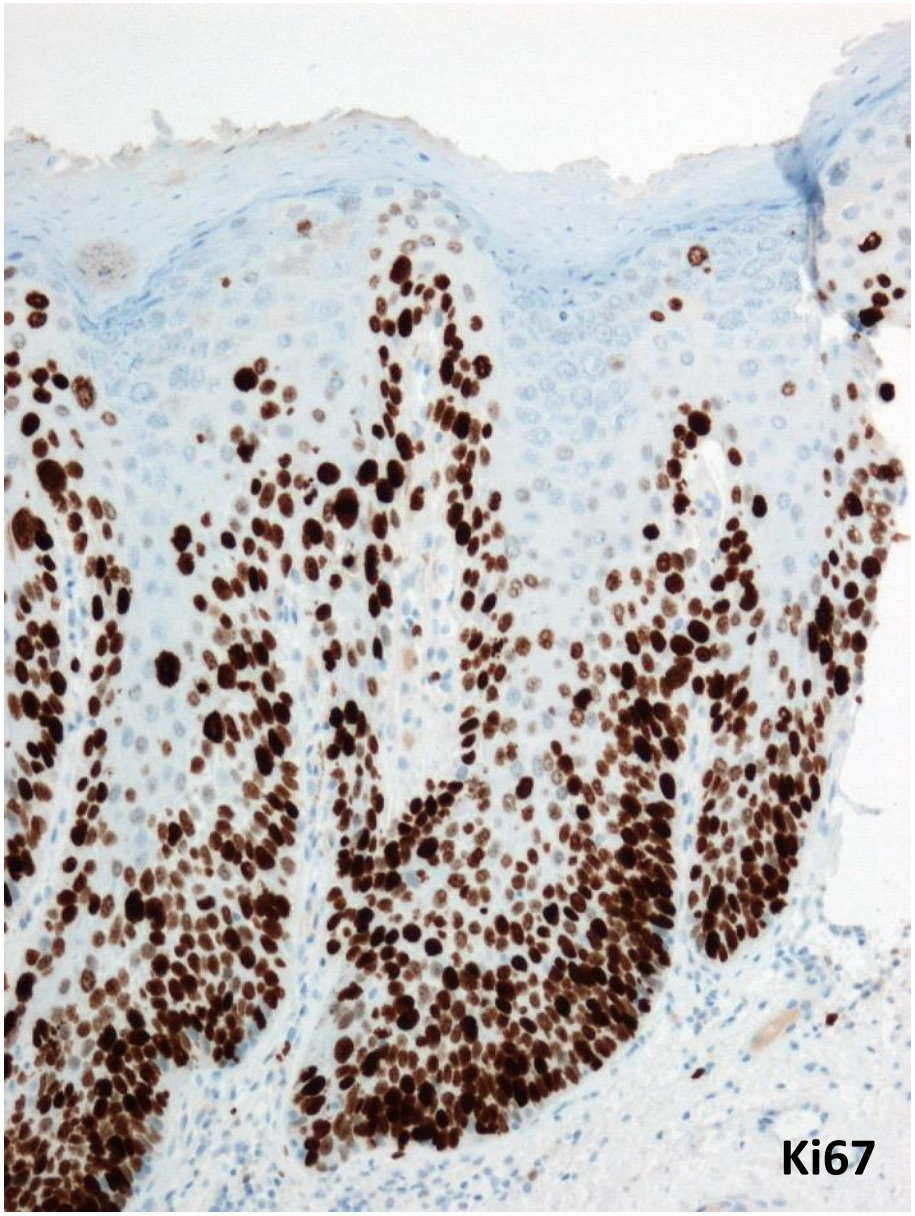
Ki67

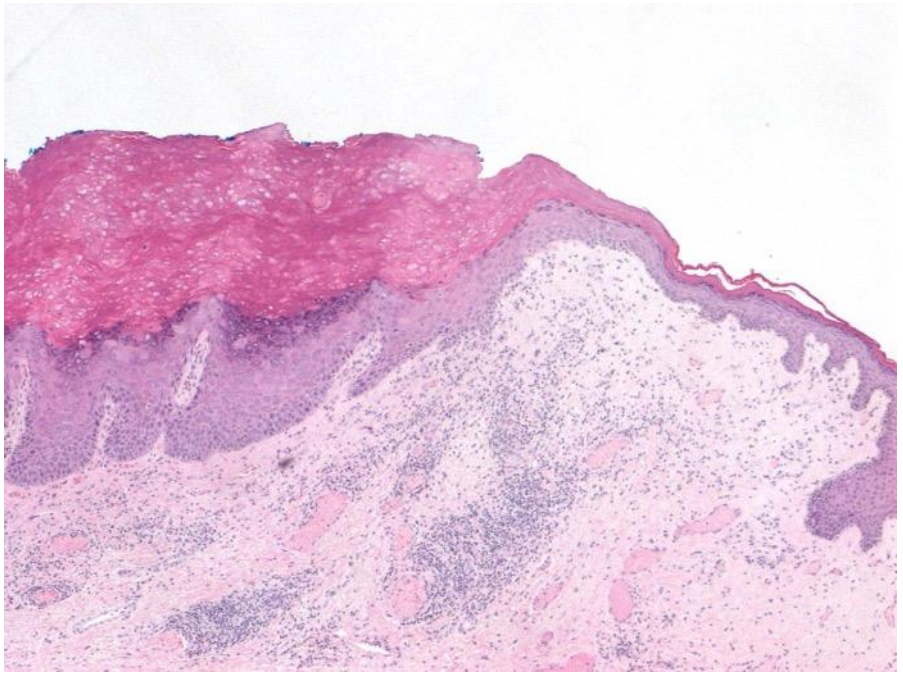

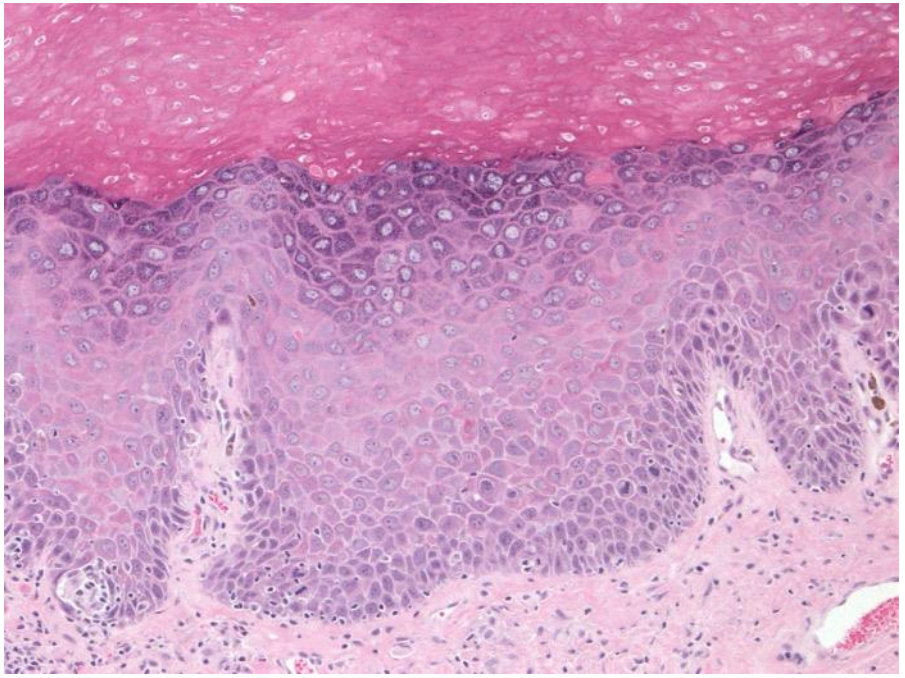

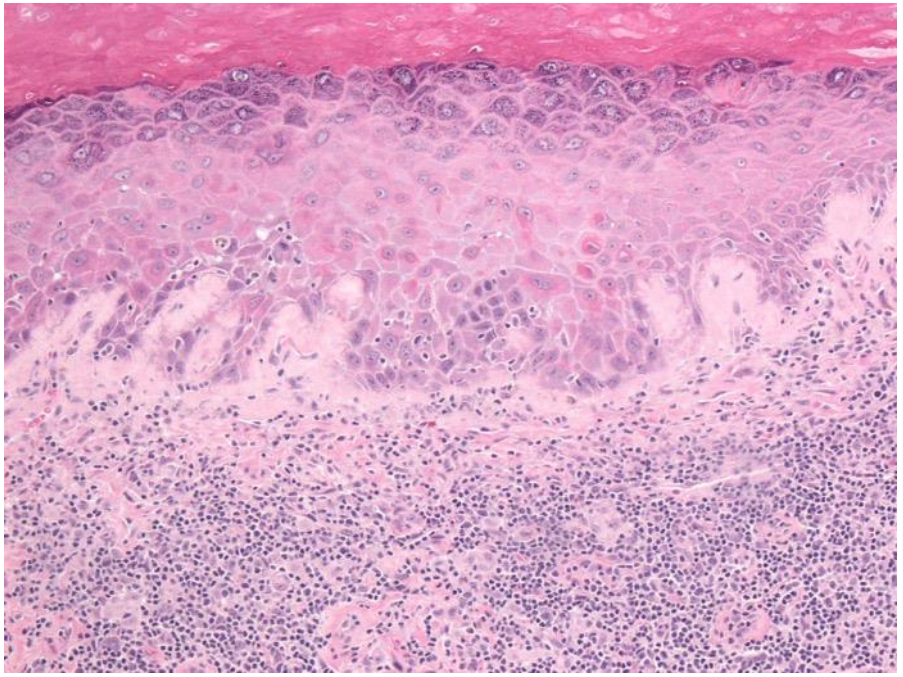

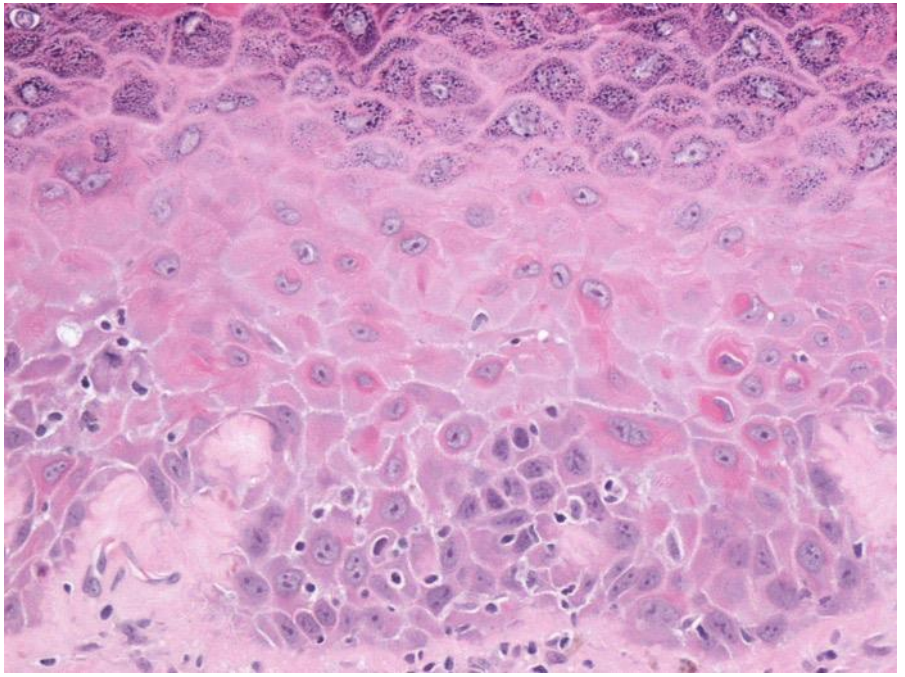

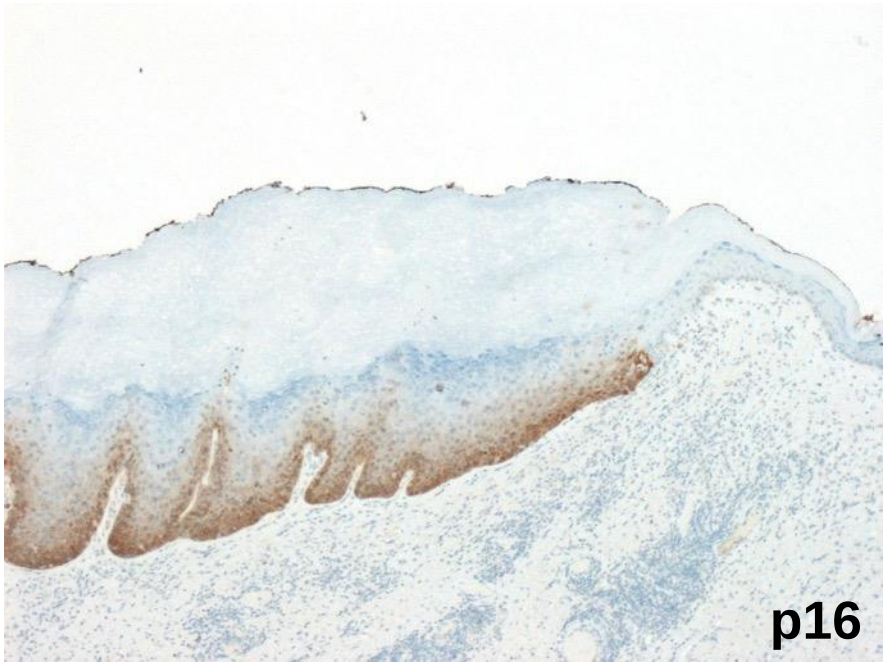
p16

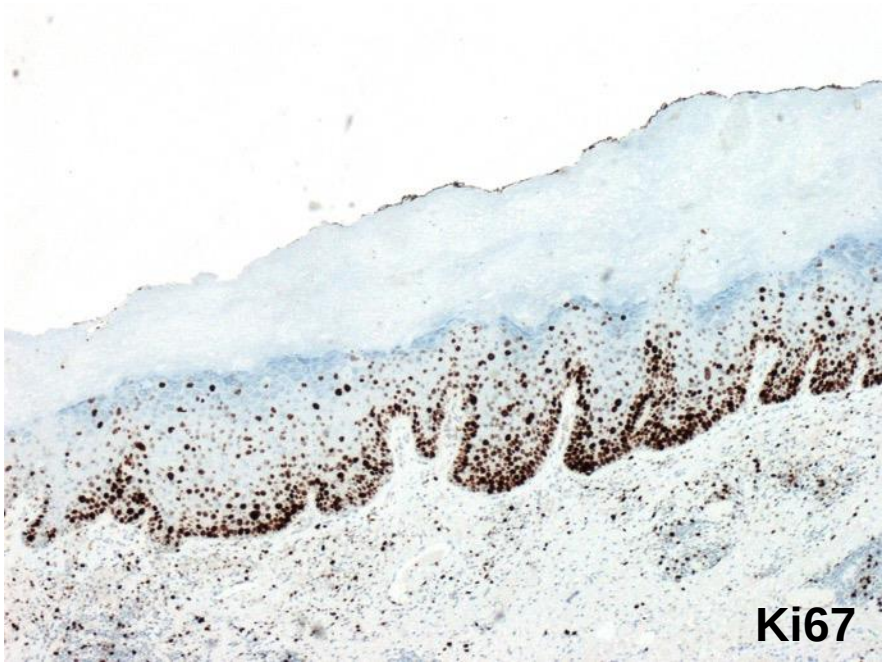
Ki67

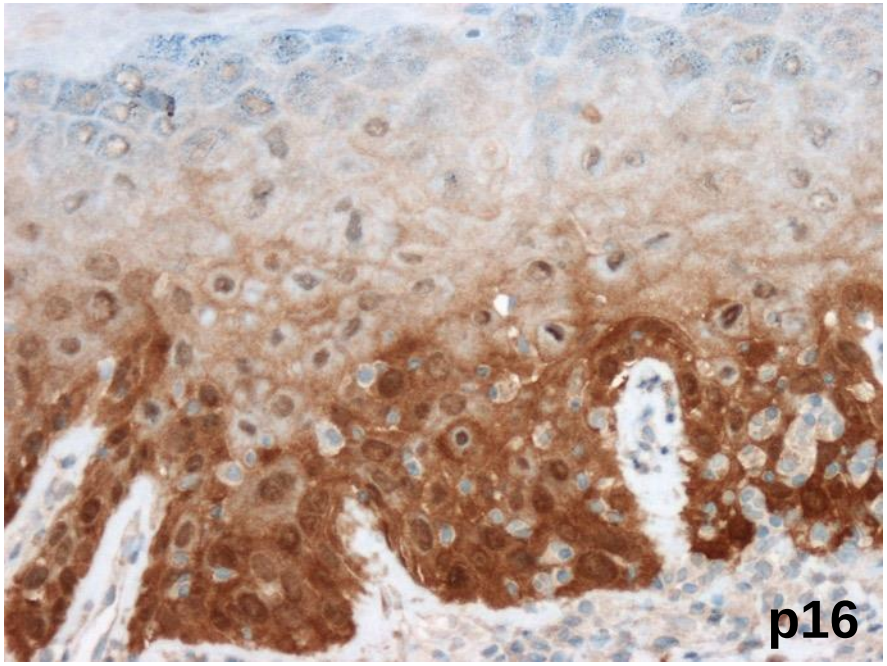
p16

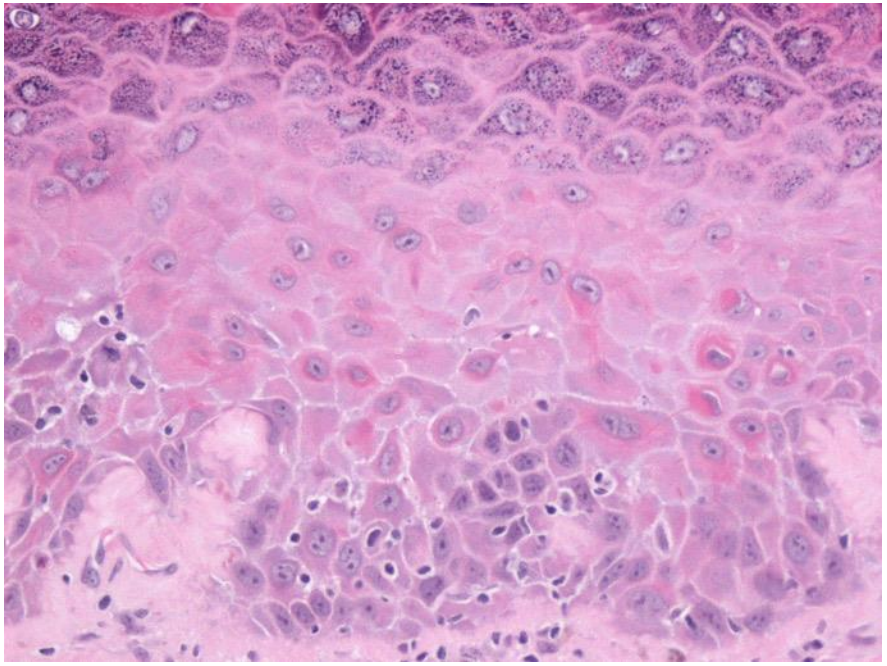

HPV and Glandular Neoplasia

- Endocervical epithelium does not support HPV replication
- Productive infection does not occur
- HPV-related lesions of the endocervical epithelium are neoplastic
- They most likely arise from reserve cell or junctional cell infection, possibly with early HPV integration

H&E

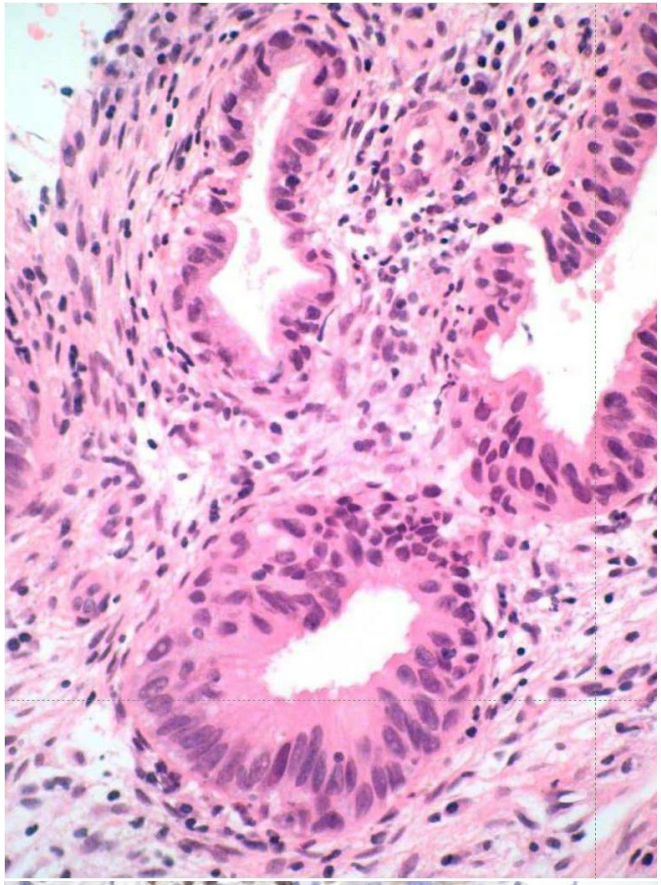

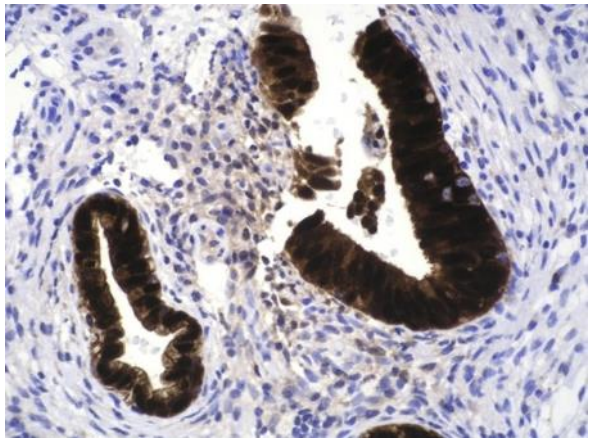

p16

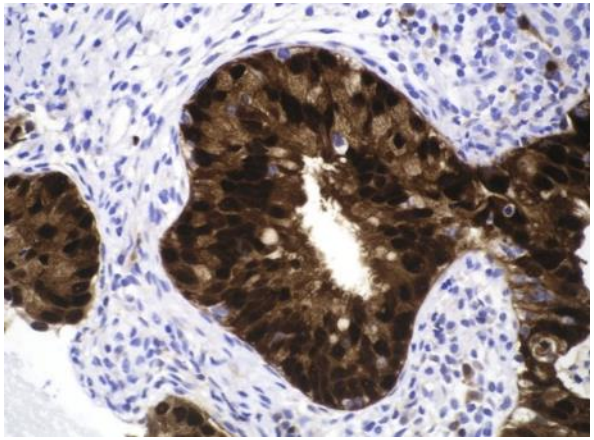

p16

Bcl-2

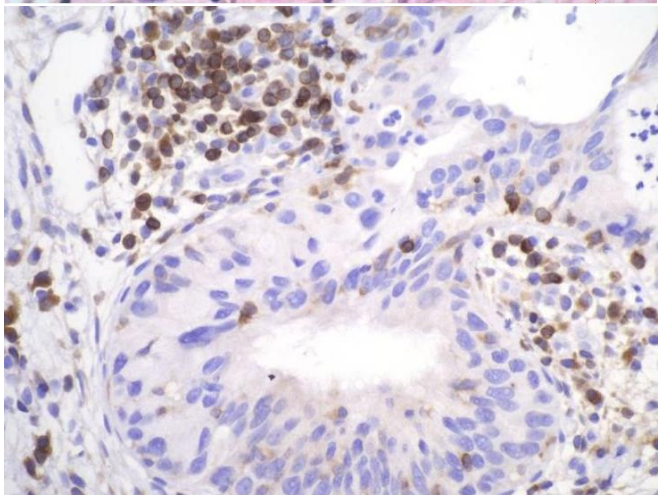

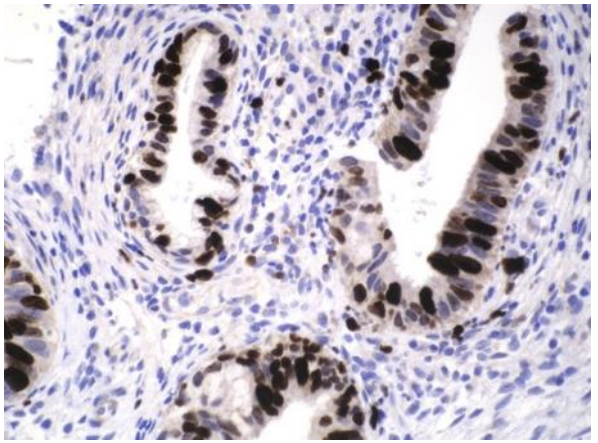

Ki67

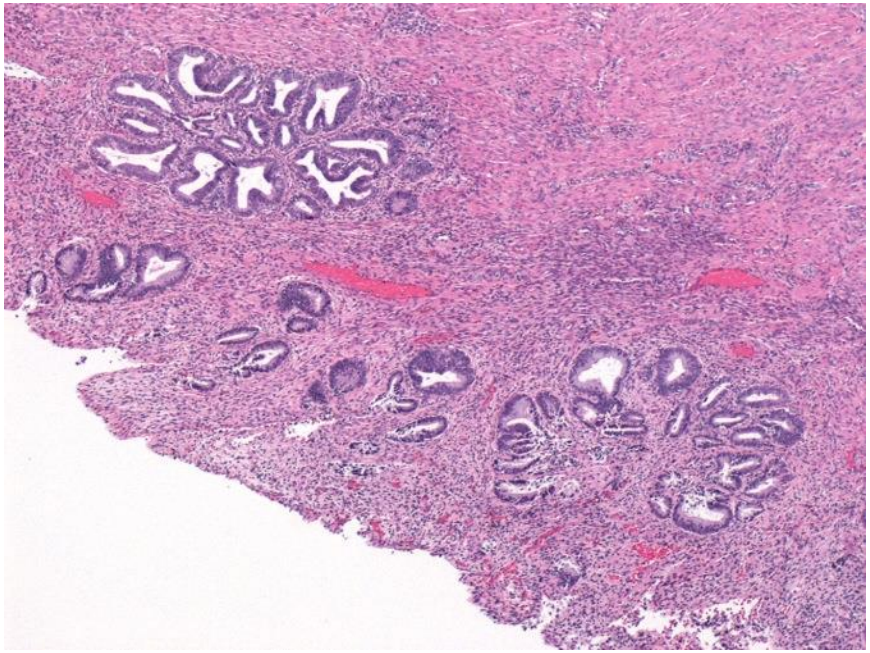

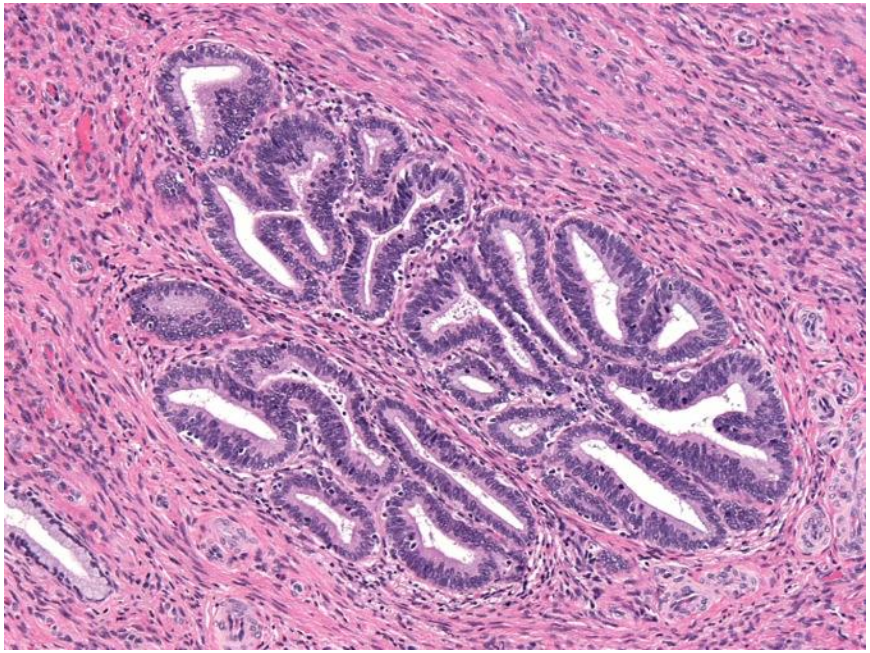

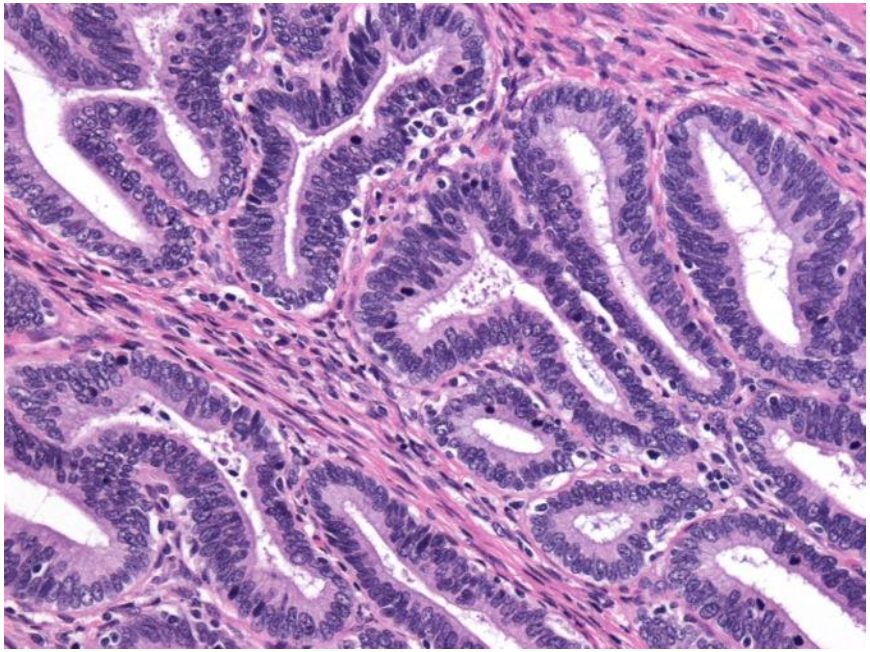

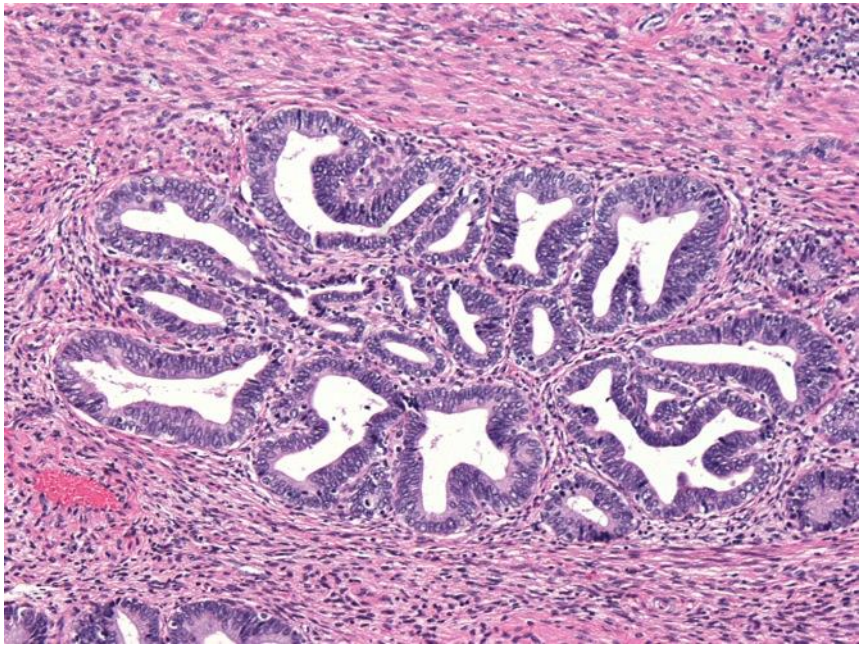

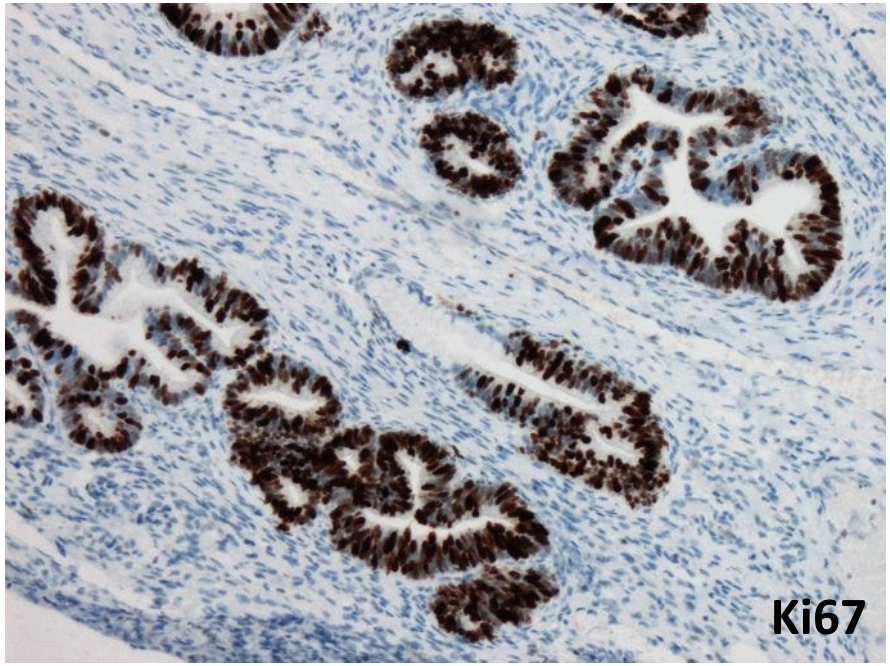
Ki67

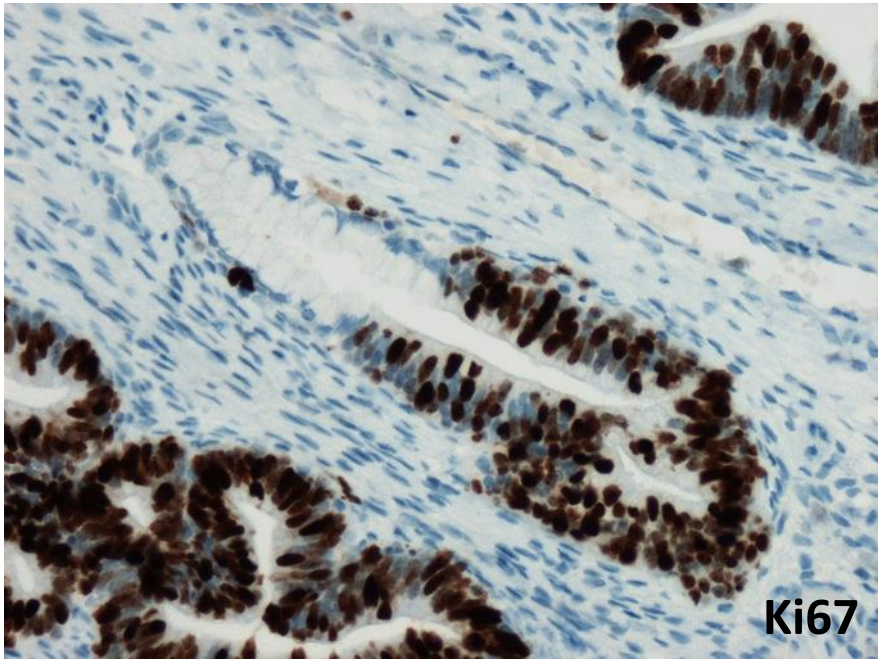
Ki67

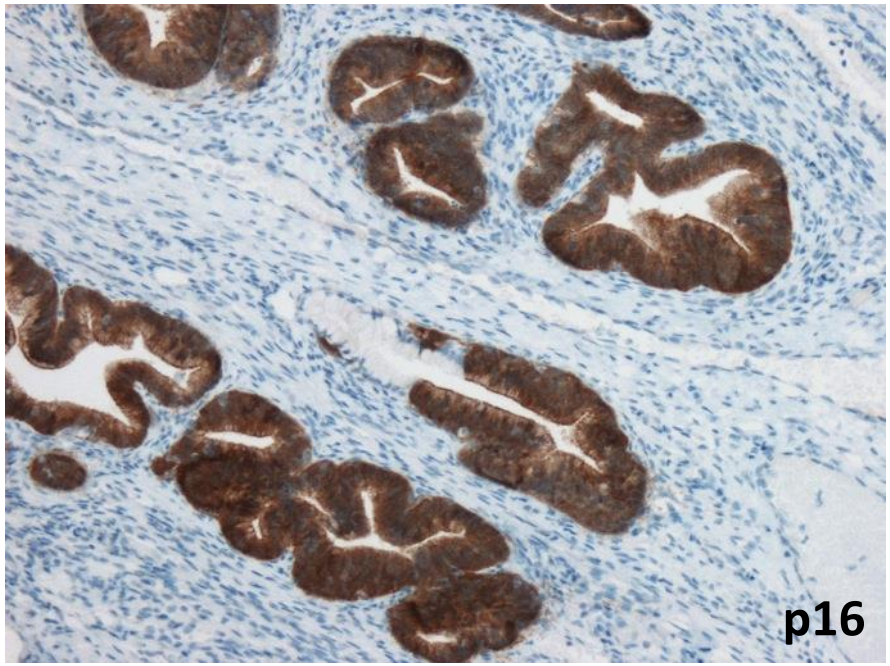
p16

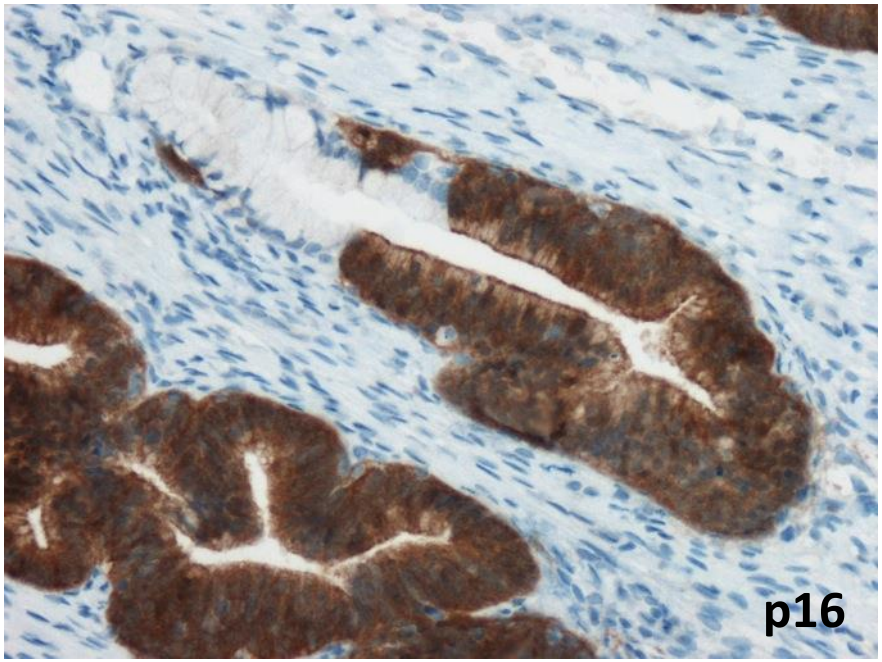
p16

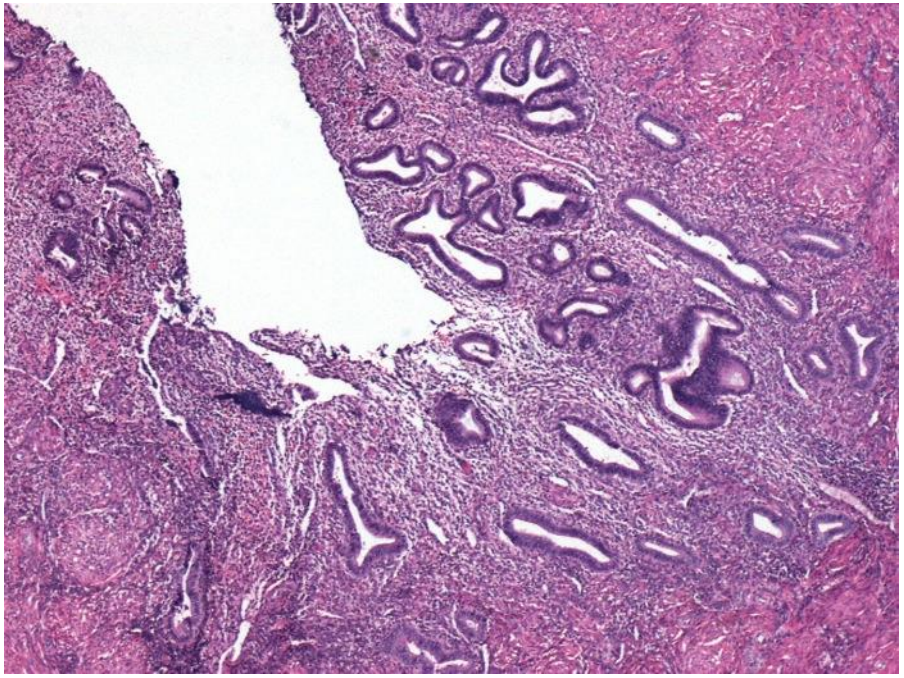

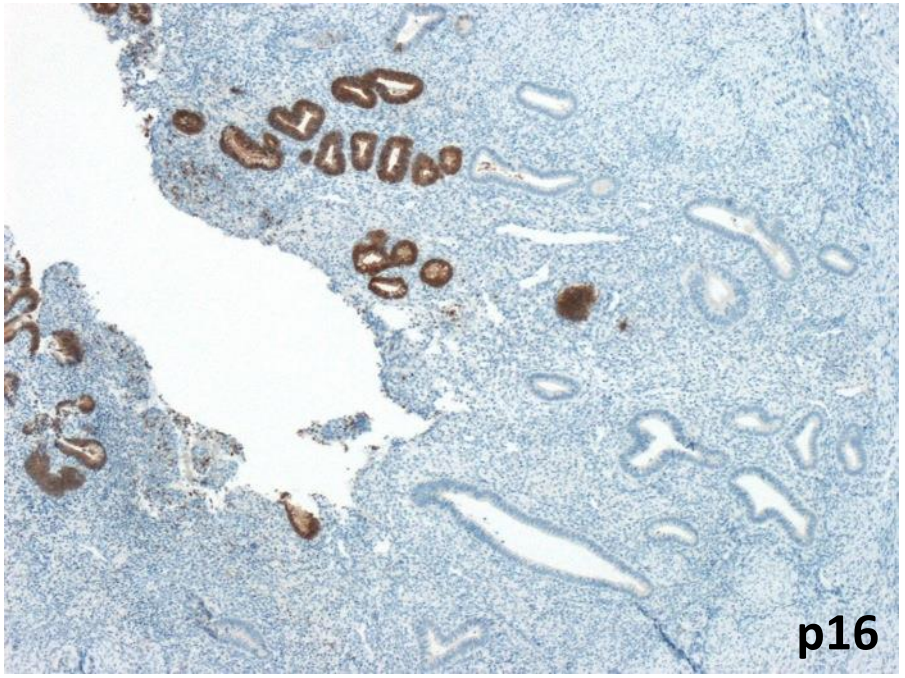
p16

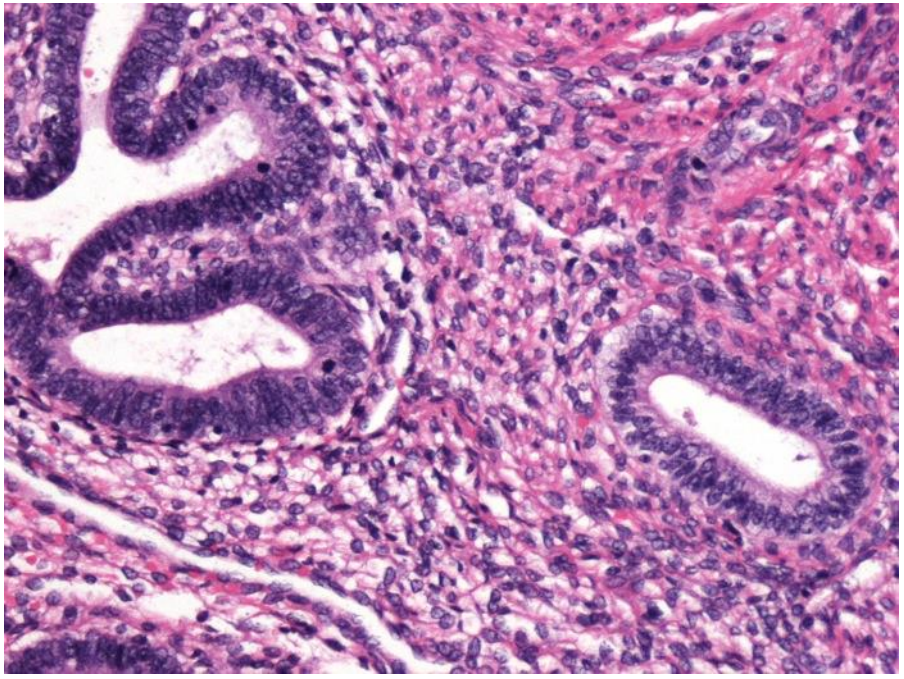

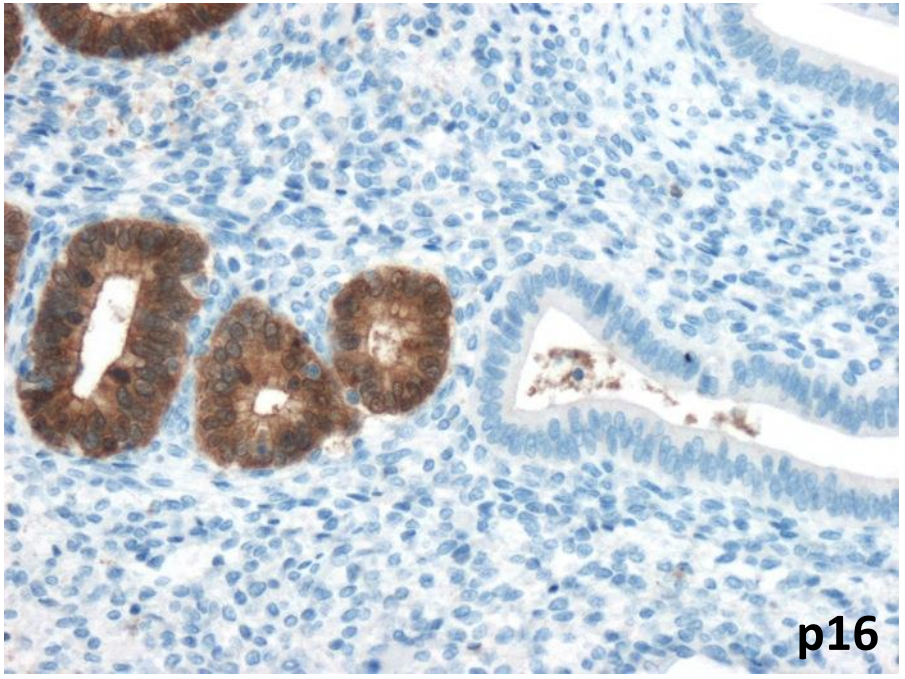
p16

Summary

- HPV infection dominates lower genital tract pathology
- Squamous lesions are associated with both low- and high-risk HPV infection
- Glandular lesions are associated only with high-risk HPV infection
- p16 and Ki67 immunohistochemistry are useful for the diagnosis and stratification of HPV-related lesions of the lower genital tract



