Case 1

- Female aged 54
- Previously treated CIN 2 and CIN 3
- 2 months of postcoital bleeding
- Mass in vagina, suspicious of malignancy
- Vaginal biopsy and subsequent LETZ of cervix

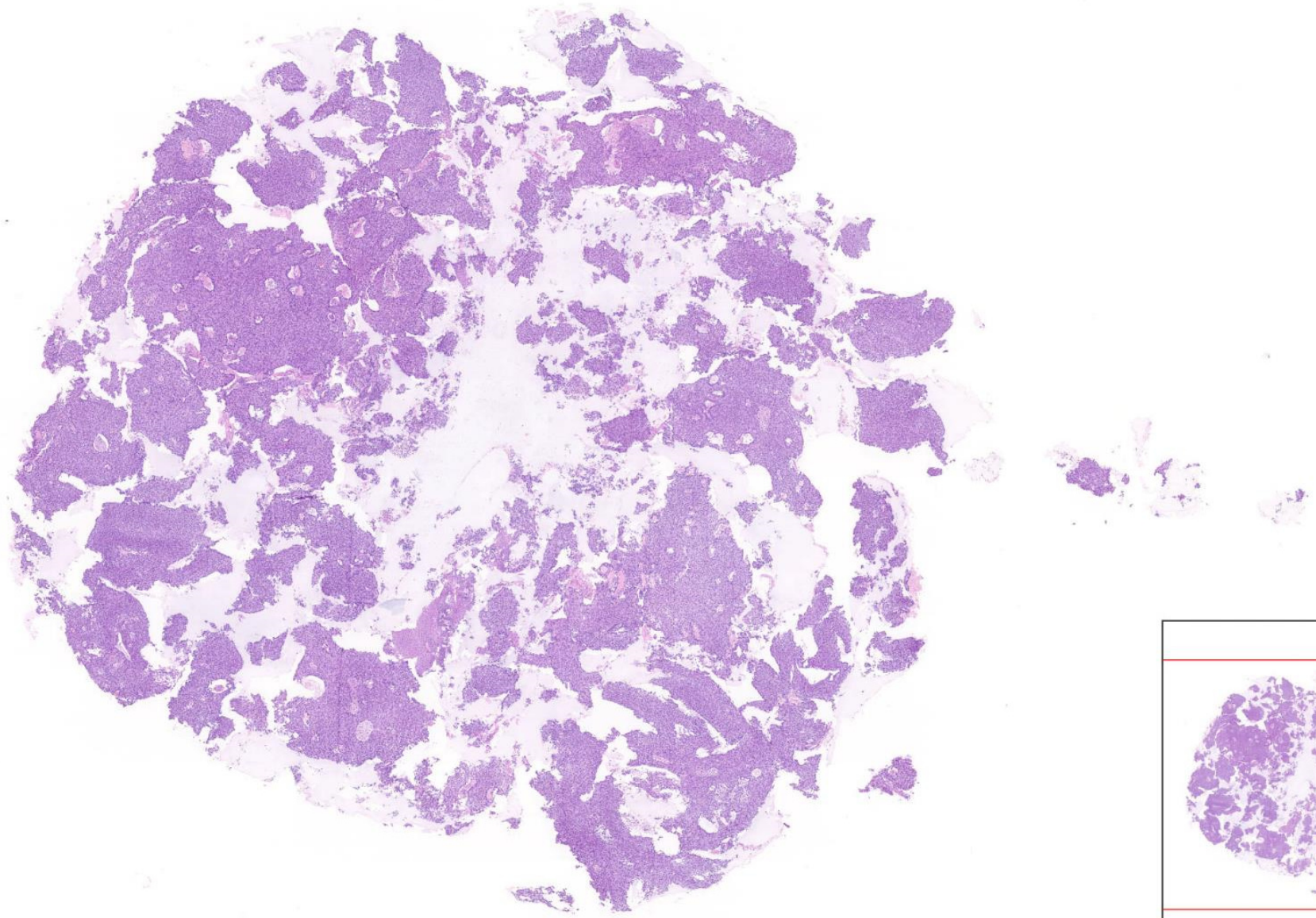

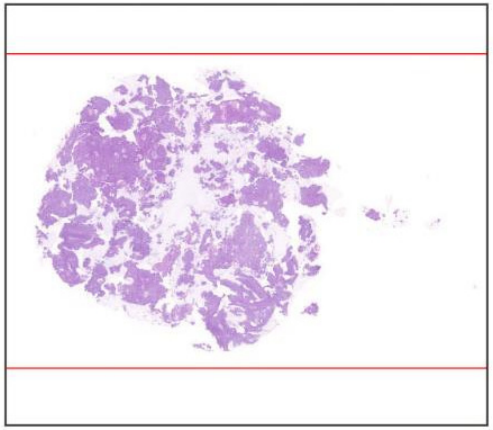

2.5 mm

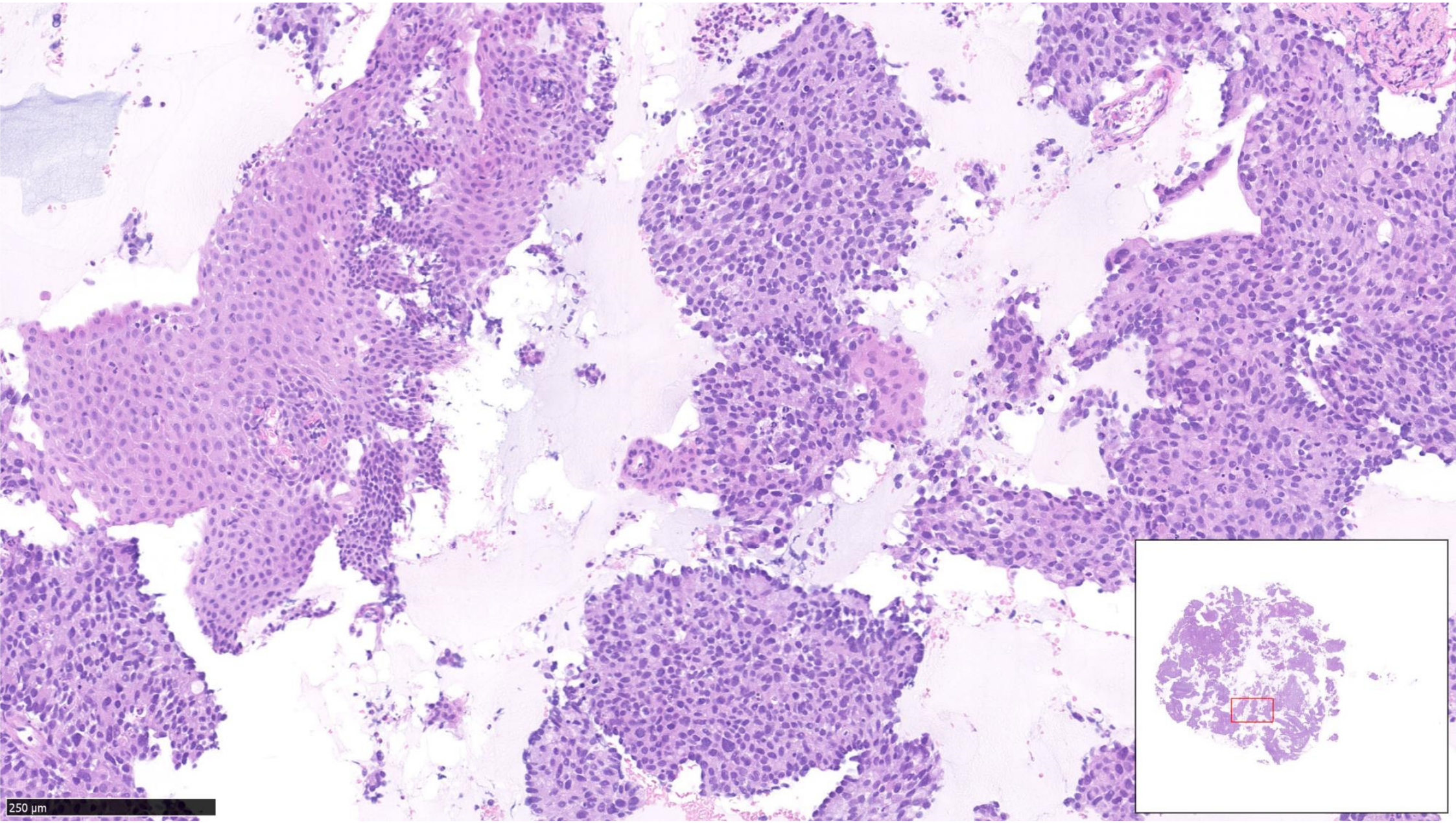
250 µm

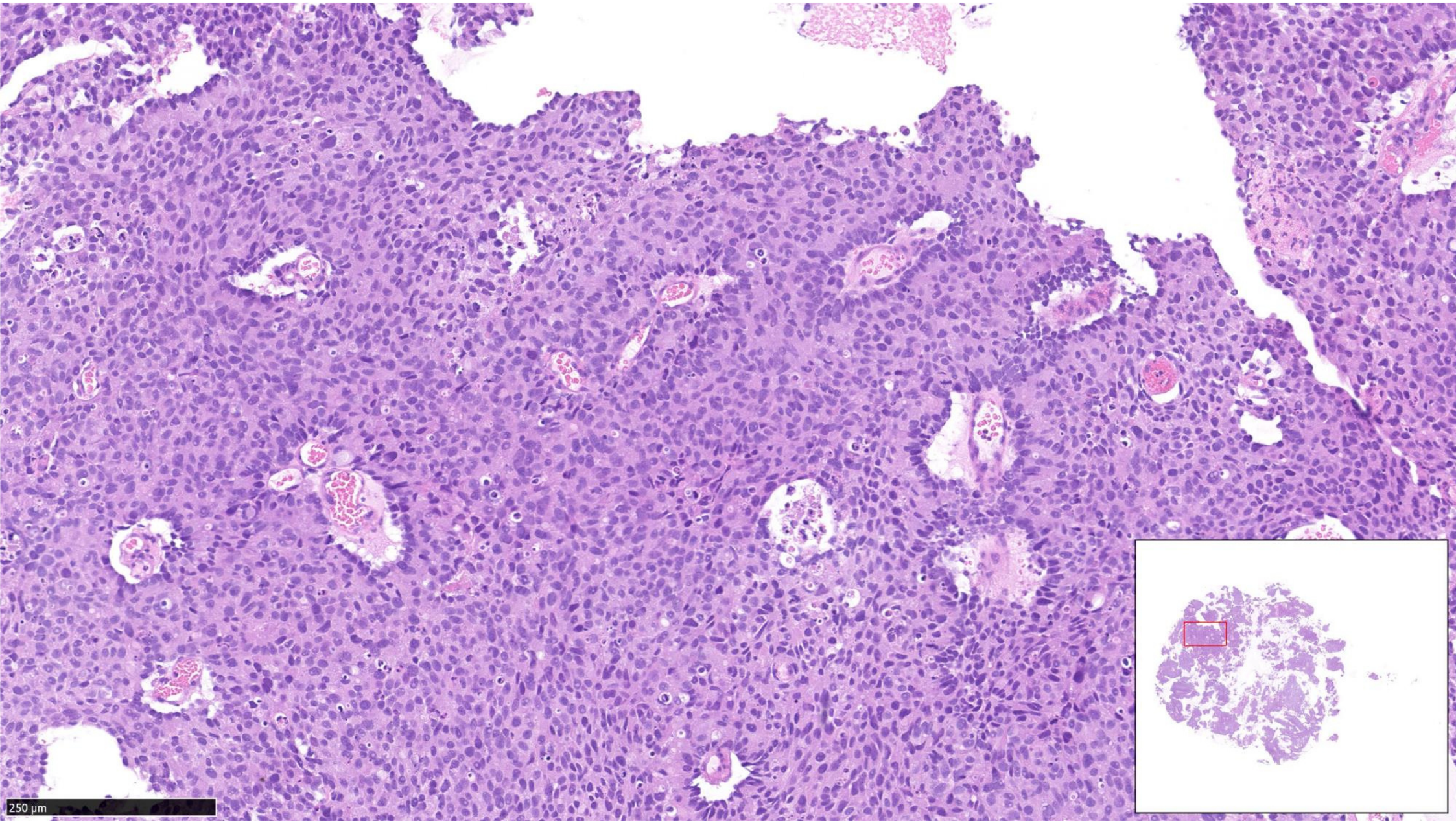
250 µm

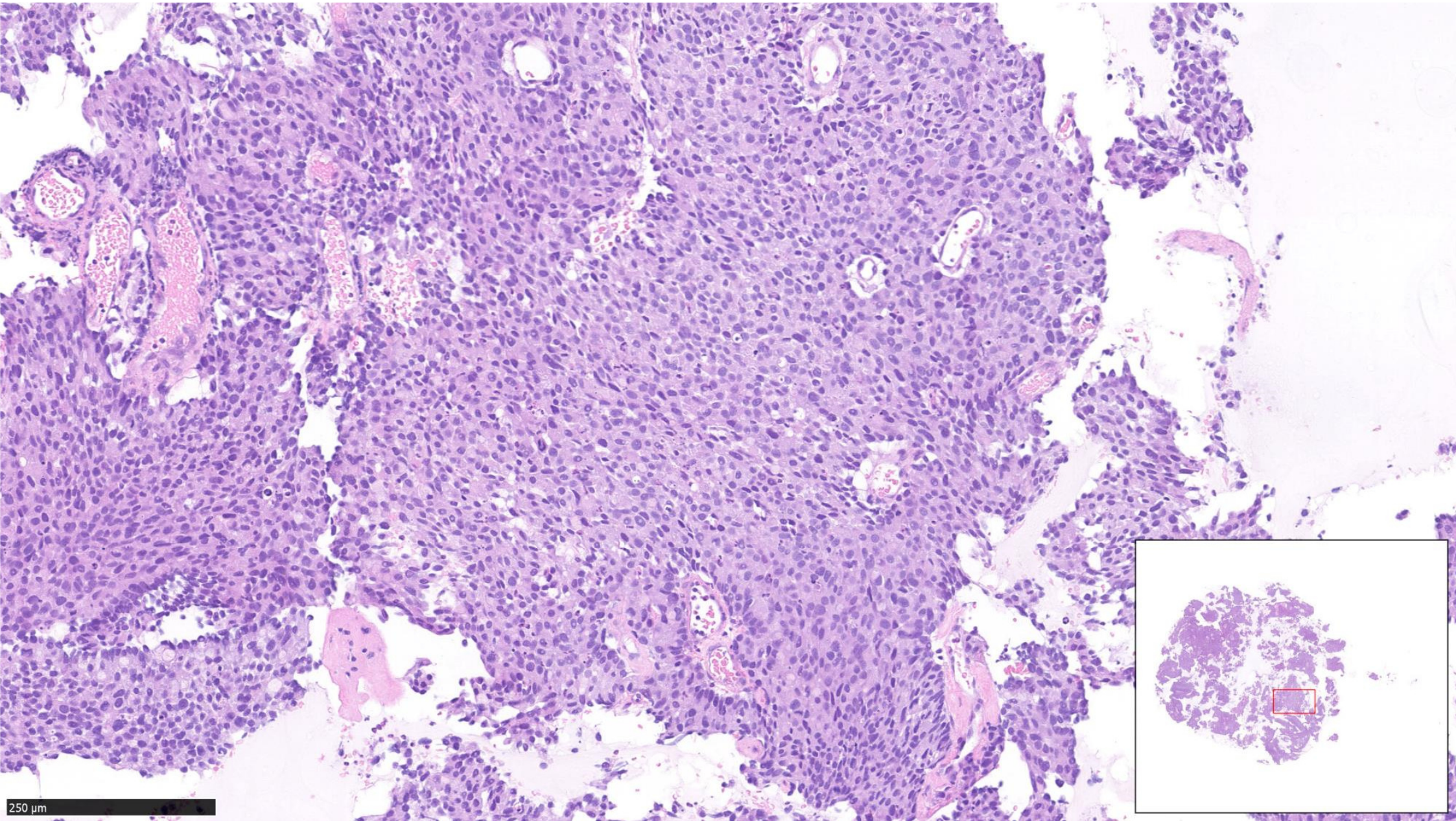
250 µm

Diagnosis?

Cervical Excision

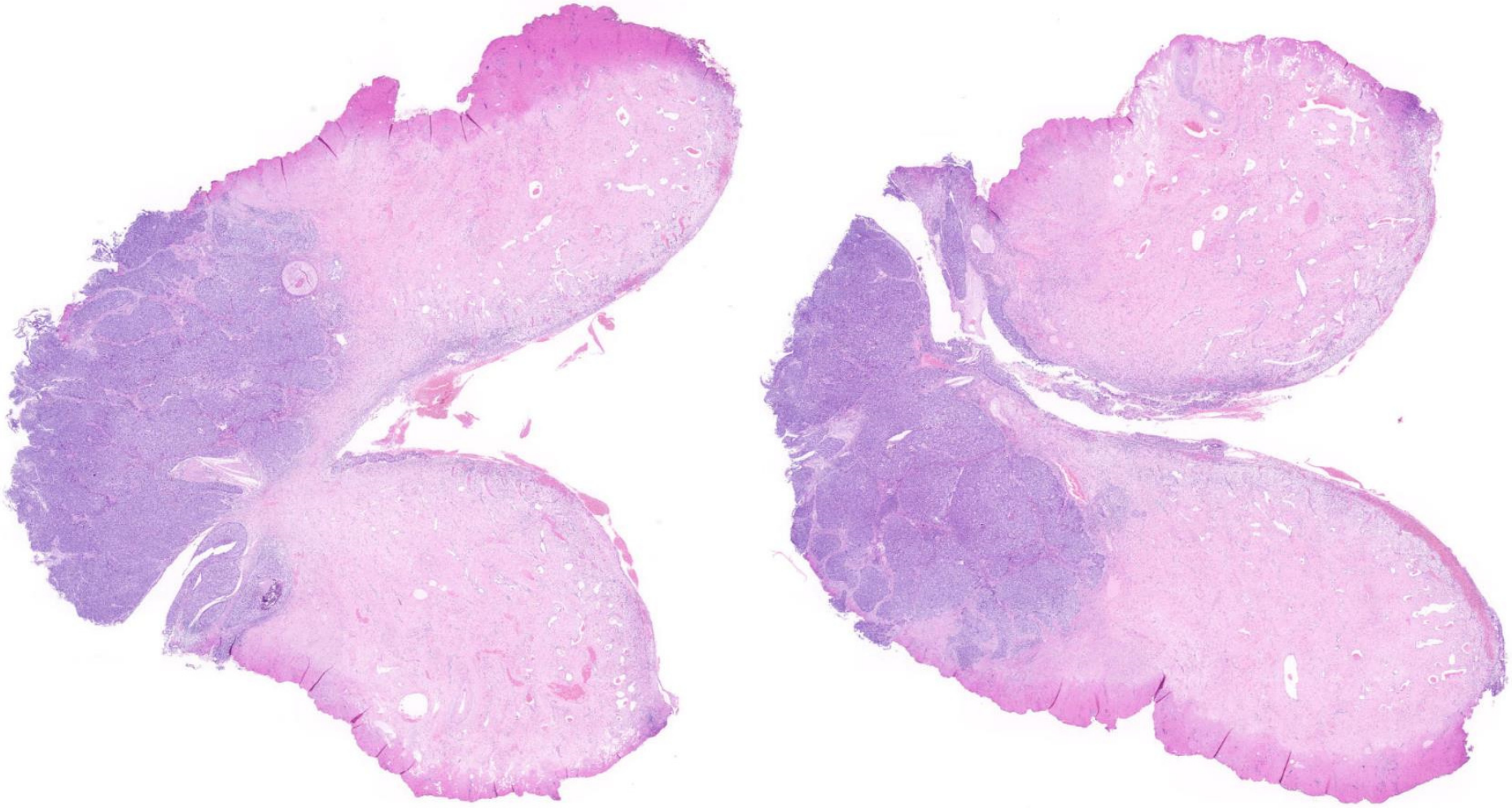
2.5 mm

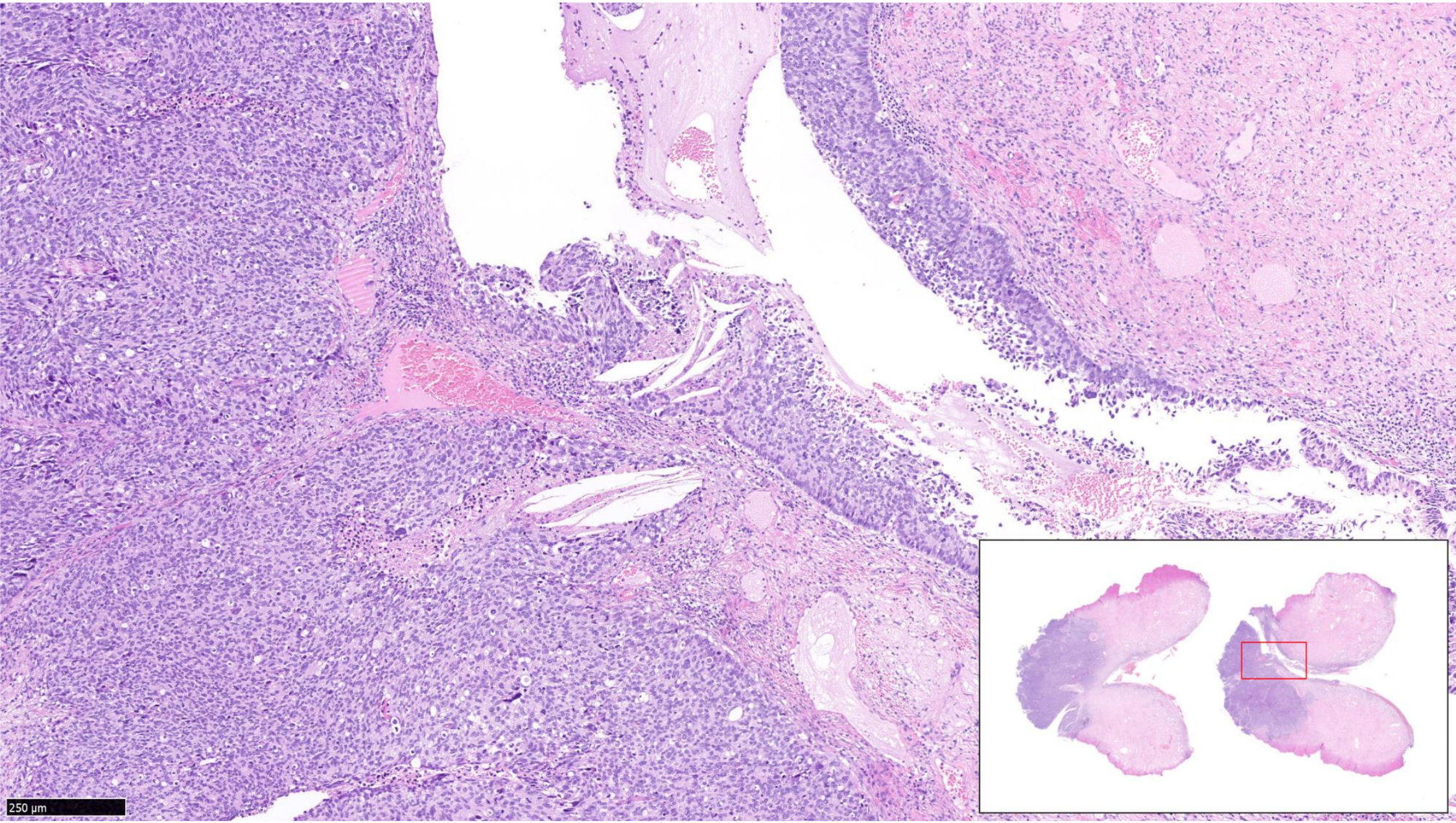
250 µm

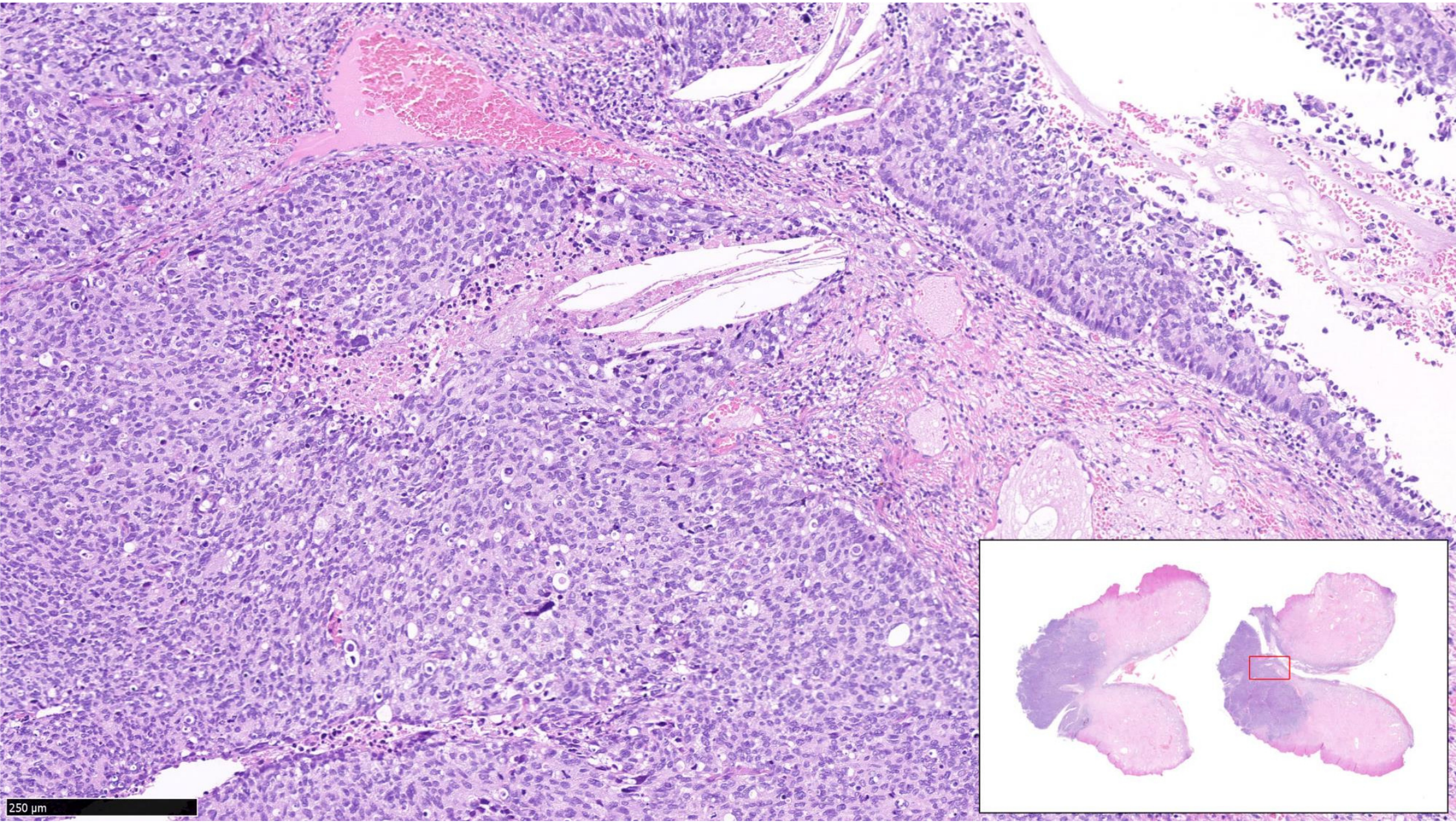
250 µm

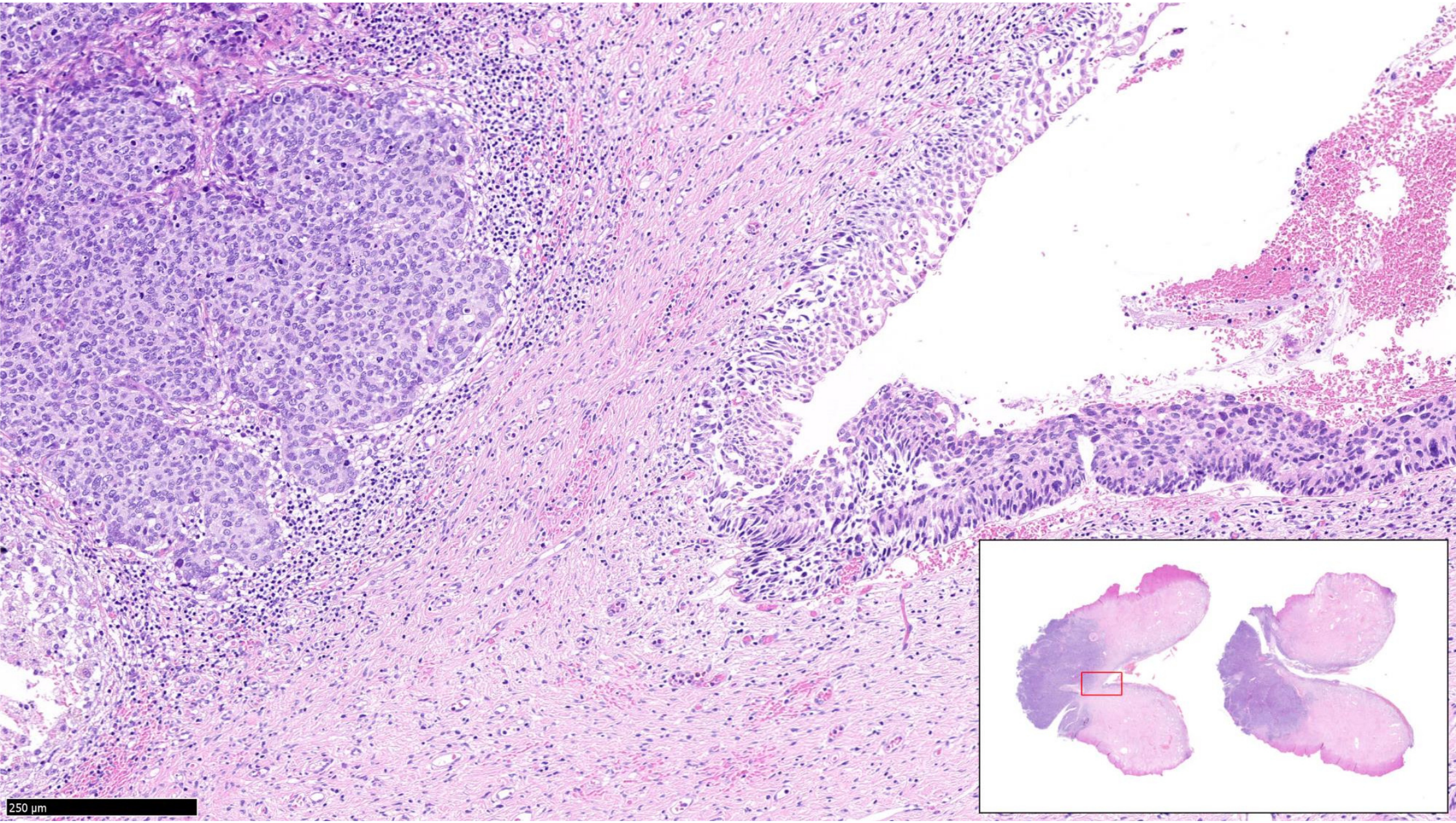
250 µm

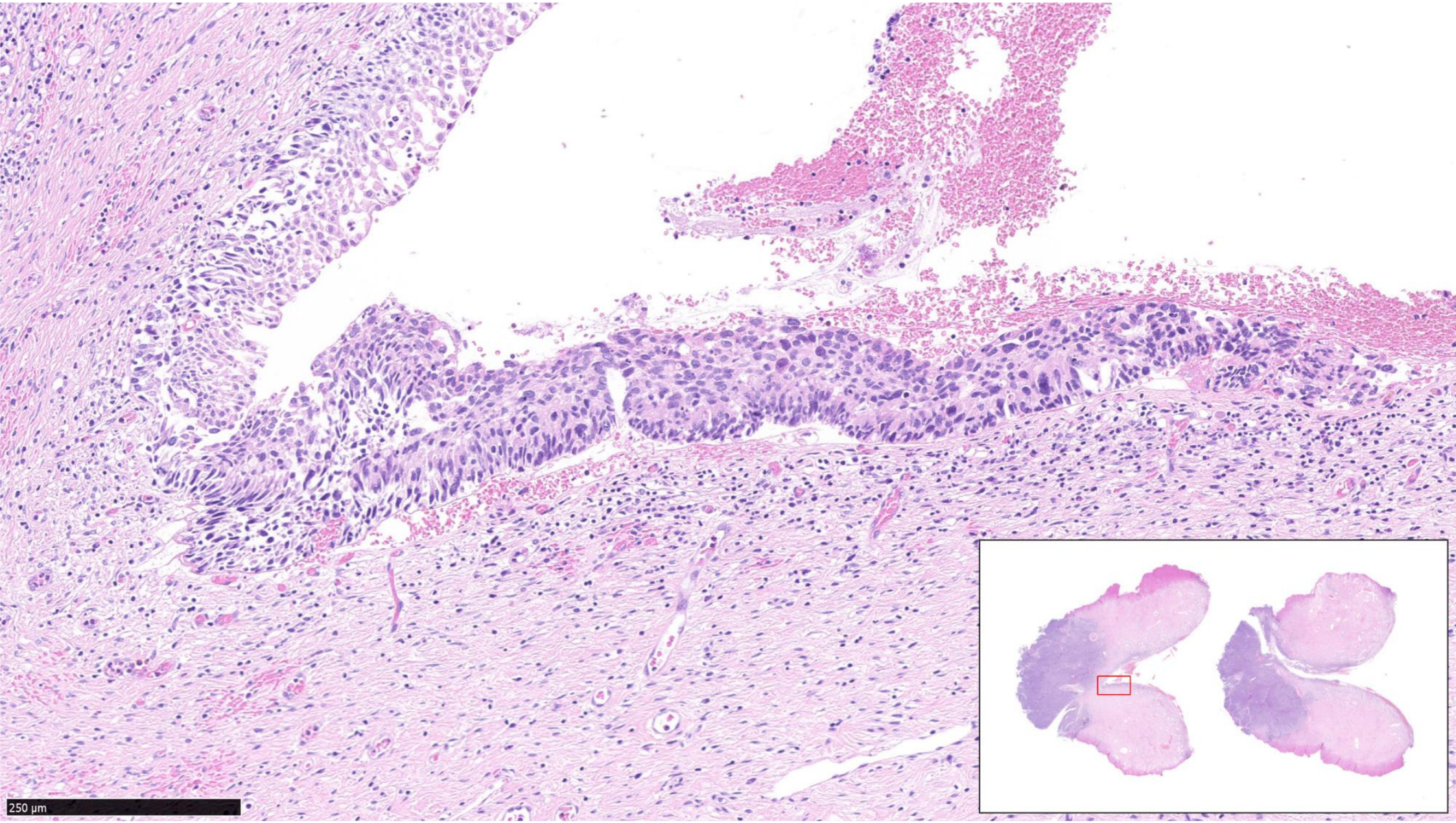
250 µm


p16
2.5 mm

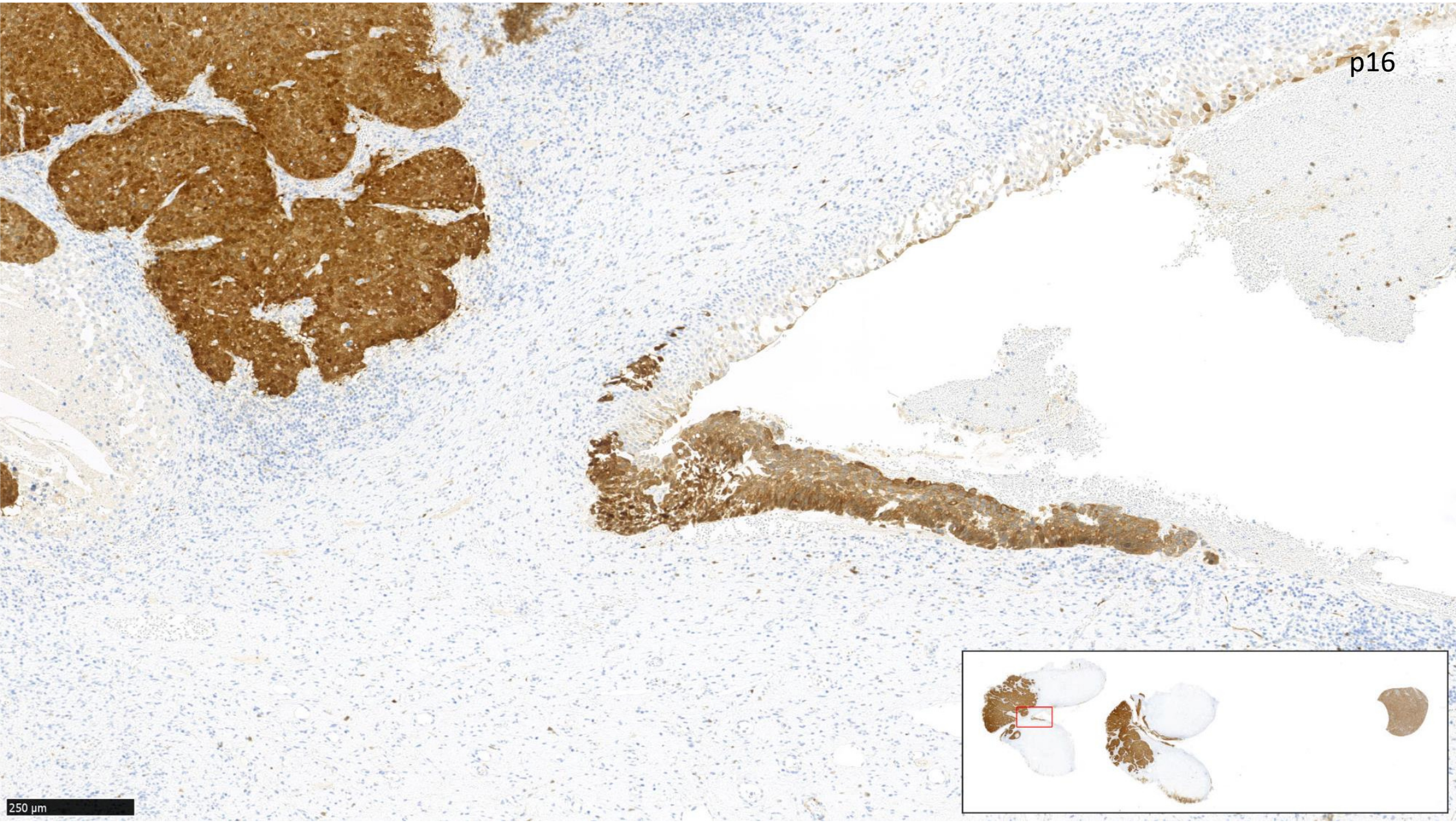
p16
250 µm

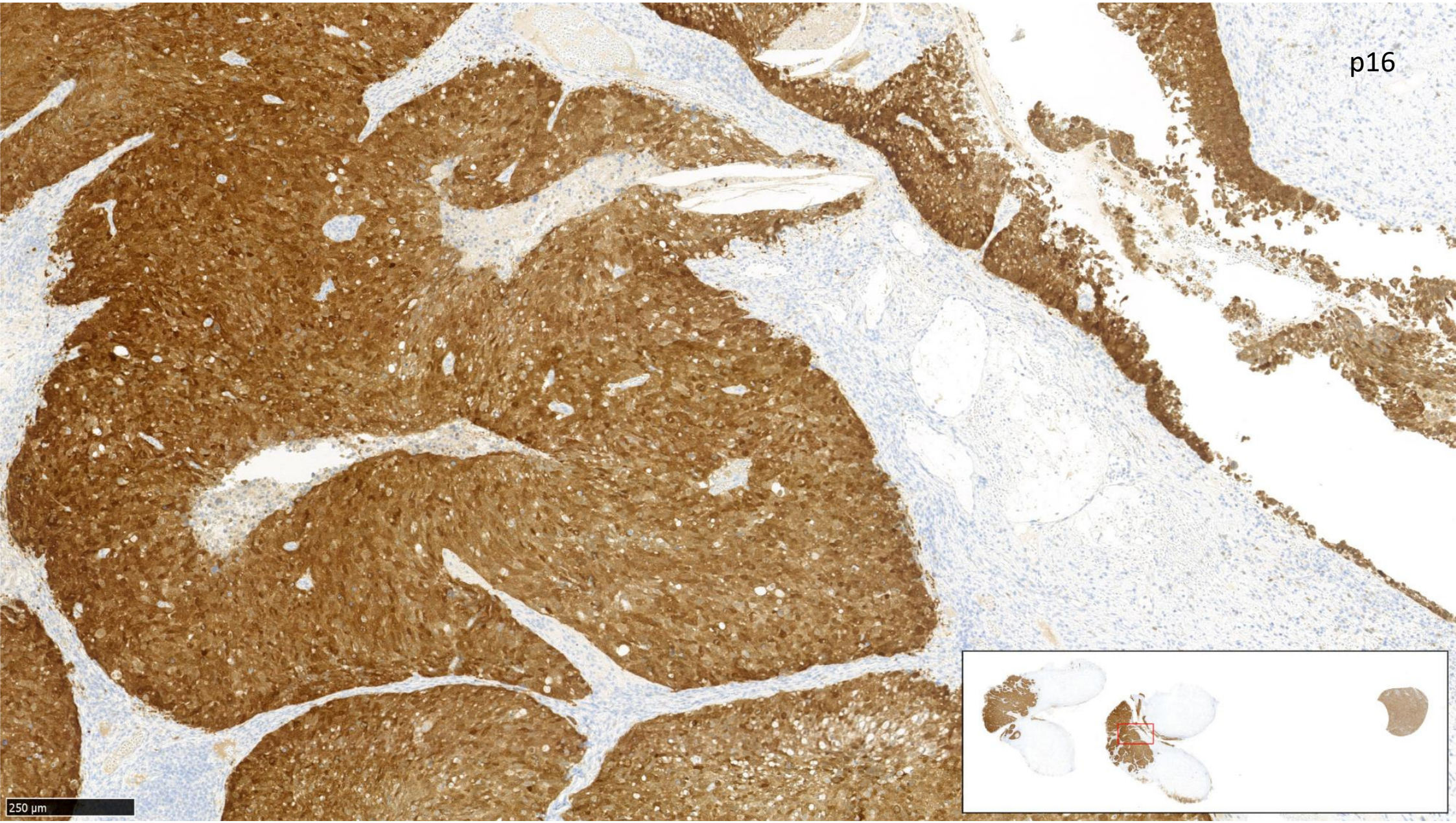
p16
250 µm


Cam5.2
2.5 mm

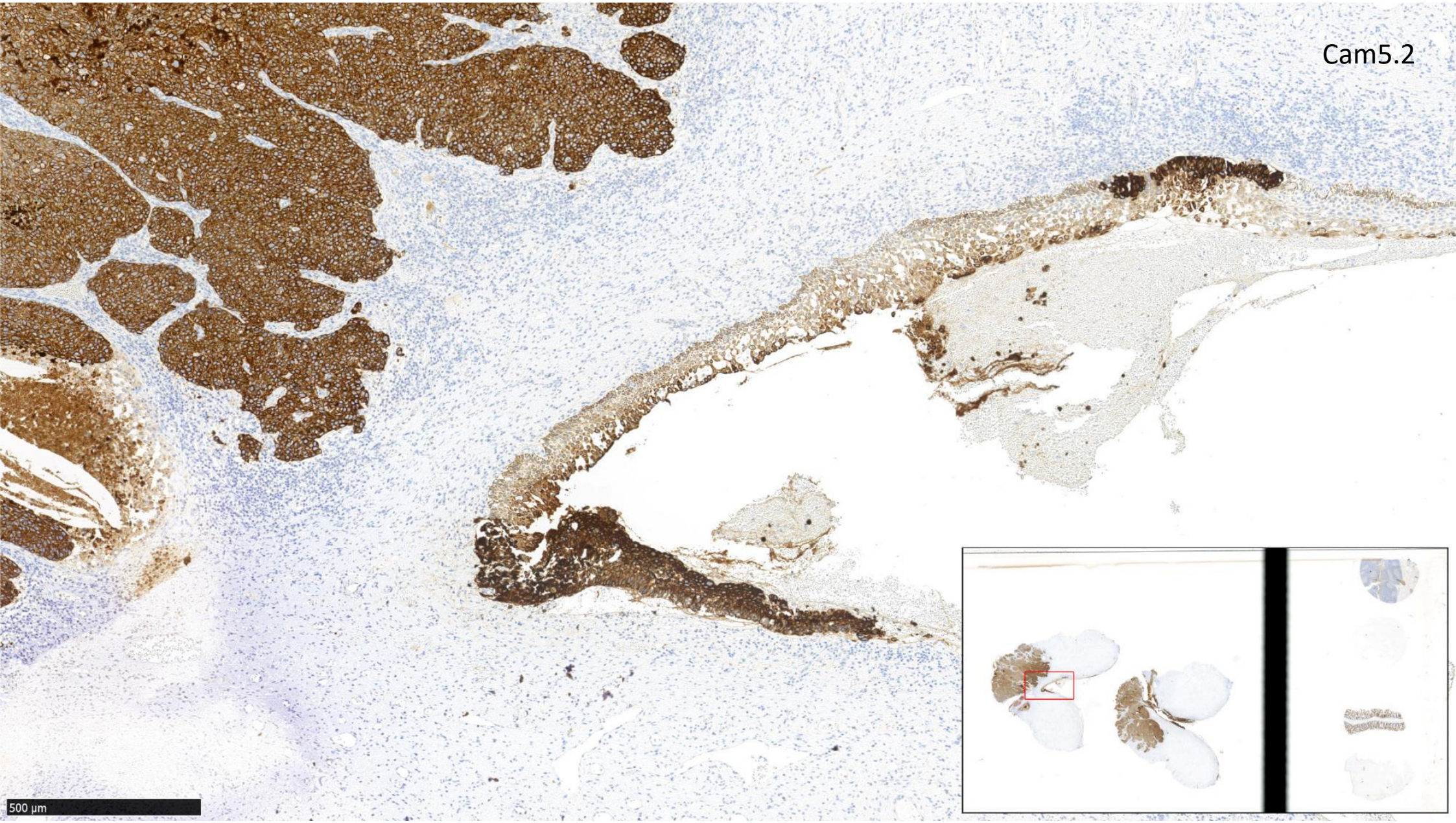
Cam5.2
500 µm


CK5/6
2.5 mm

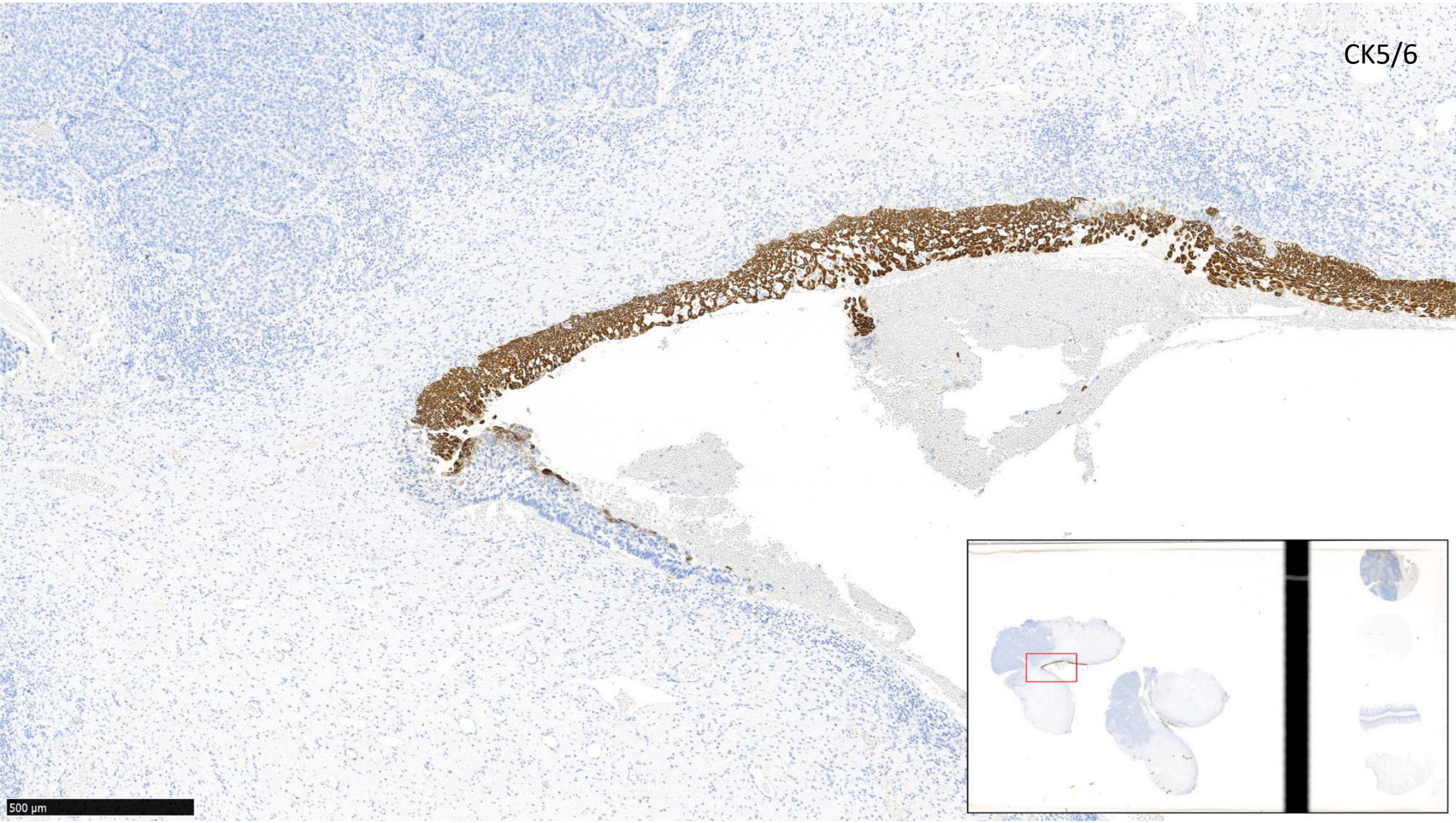
CK5/6
500 µm

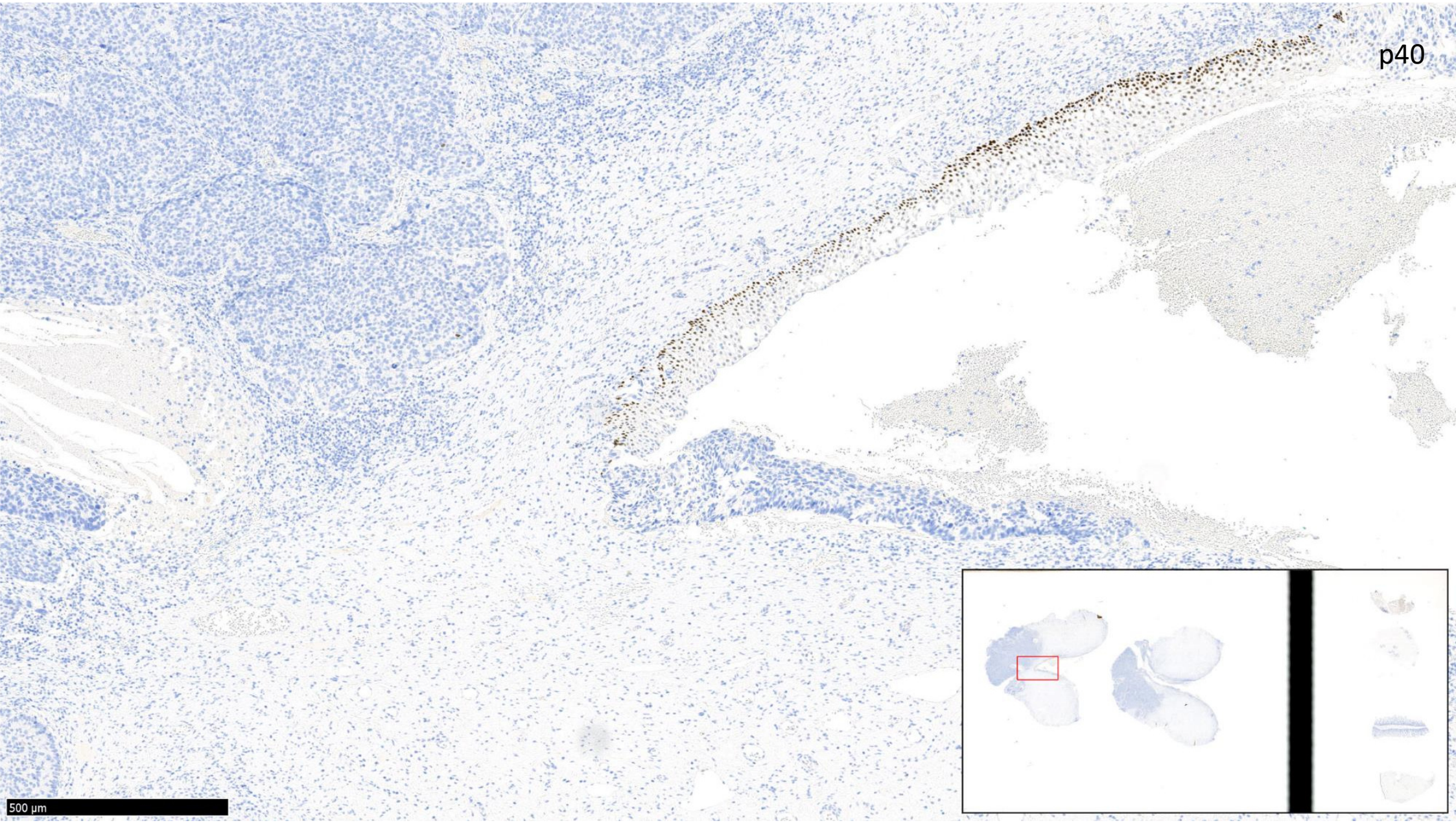
p40
500 µm

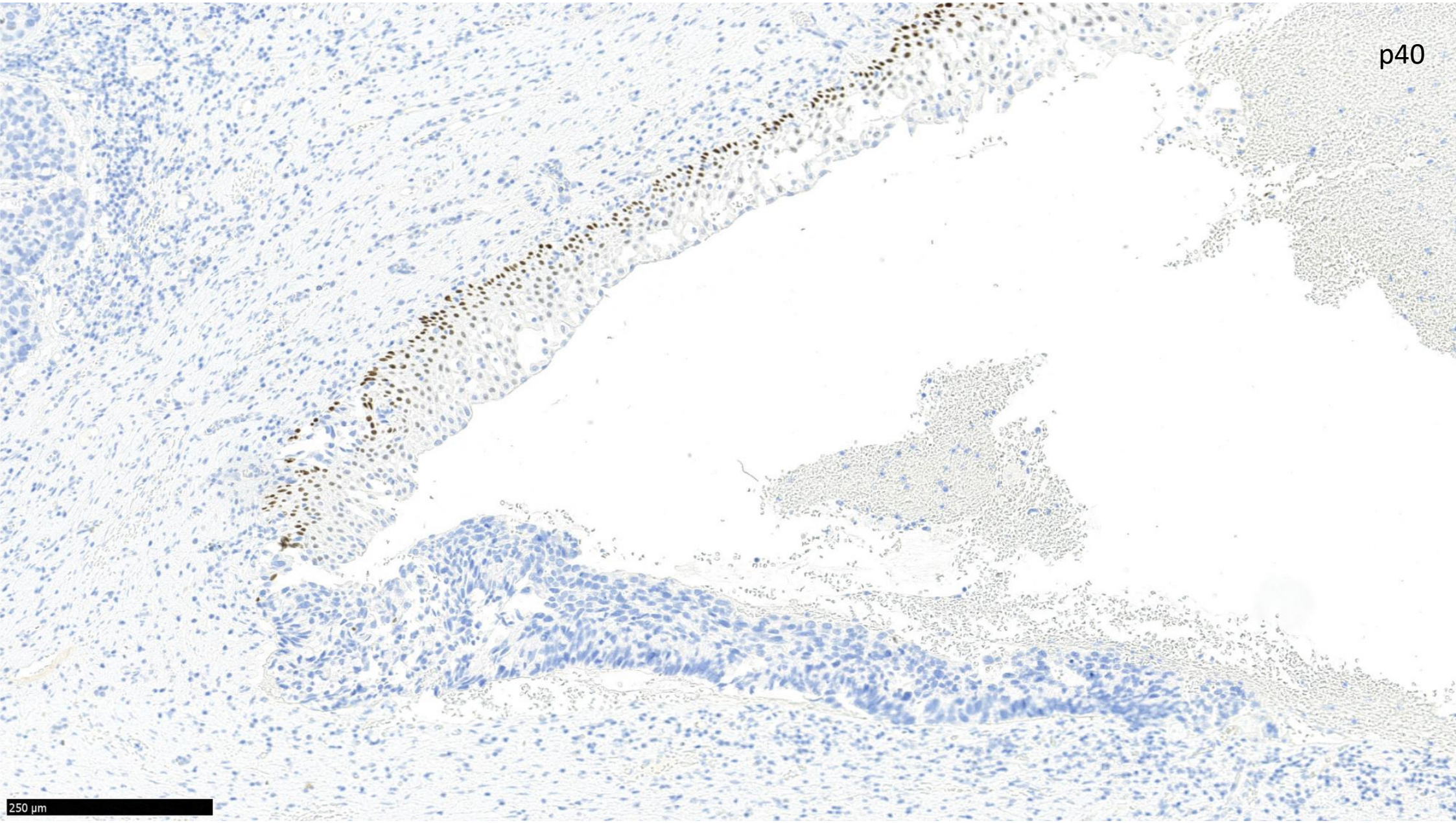
p40
250 µm

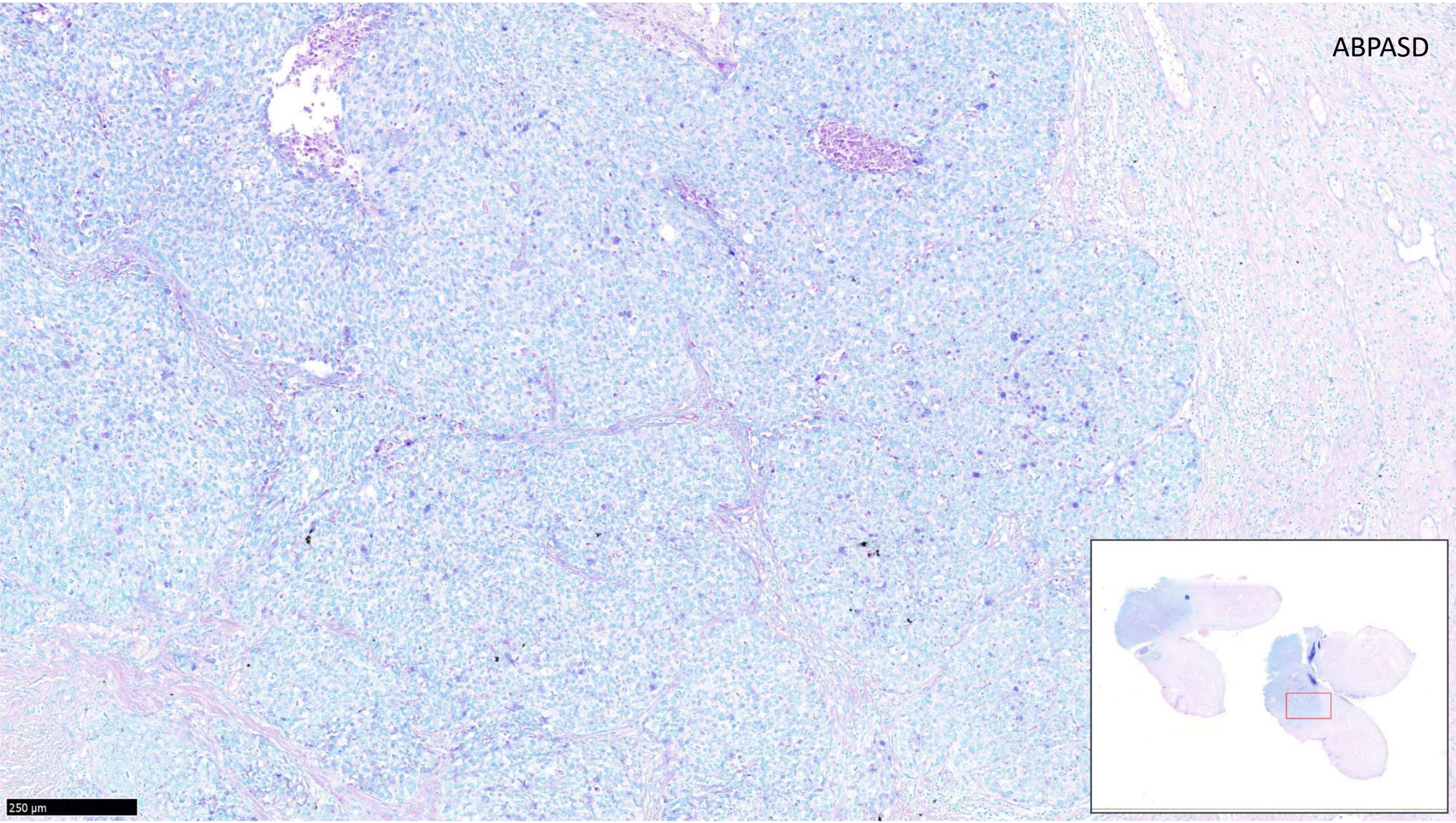
ABPASD
250 µm

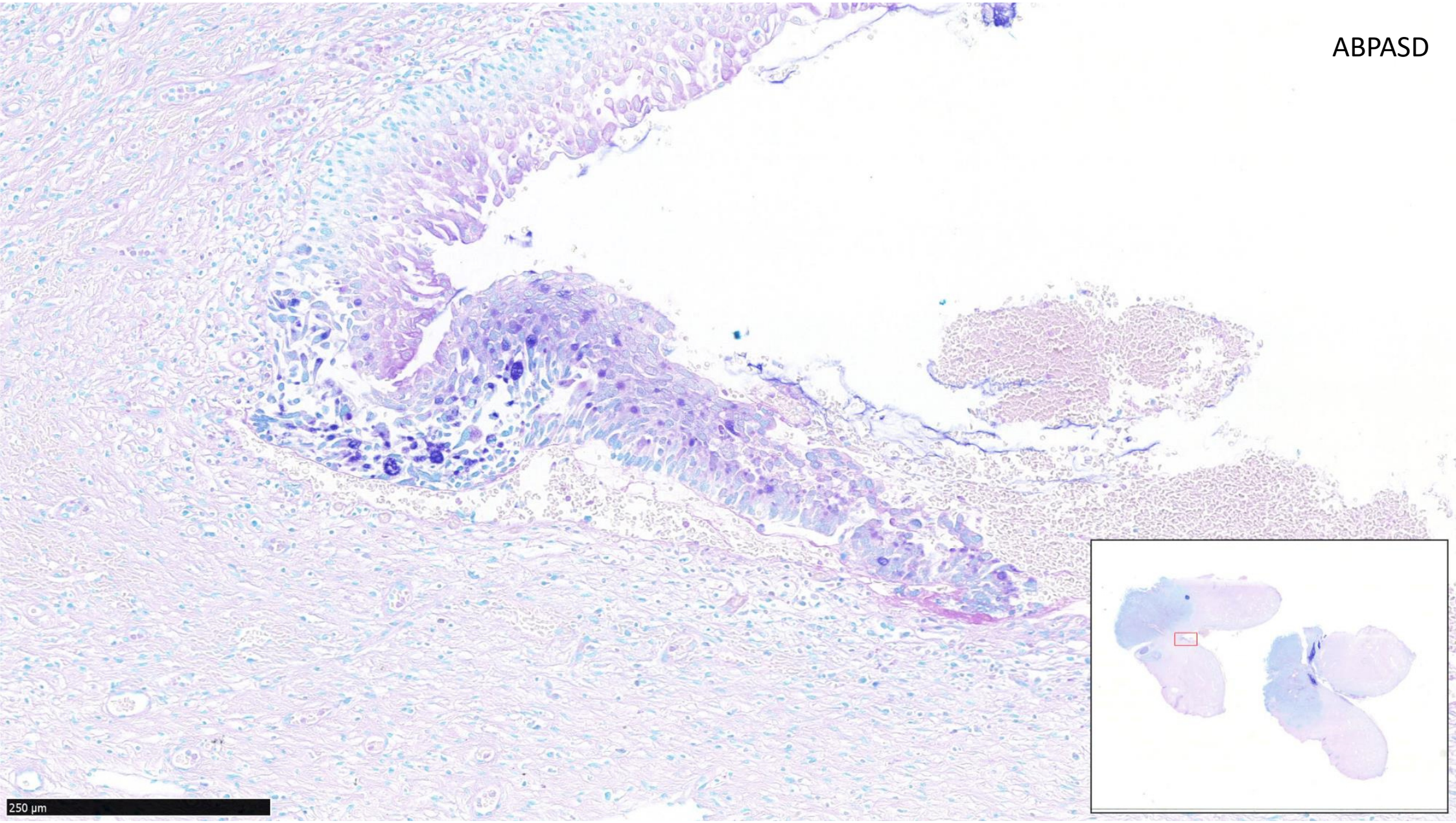
ABPASD
250 µm

Diagnosis

Invasive Stratified Mucin-producing Carcinoma and Stratified Mucin-producing Intraepithelial Lesion (SMILE)

Lastra R et al Am J Surg Pathol. 2016; 40:262–9
Onishi J et al Hum Pathol. 2016 55:174–81

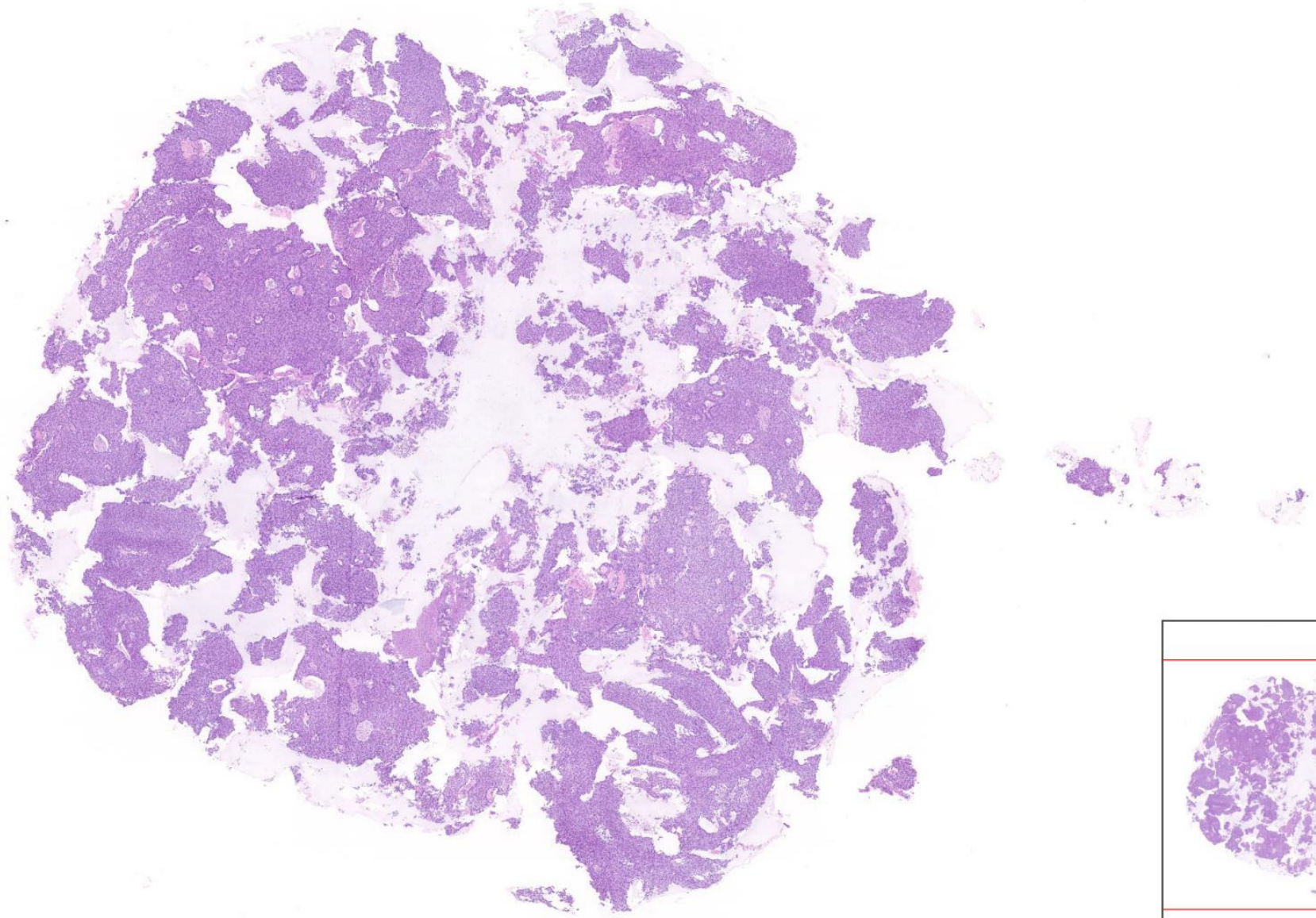

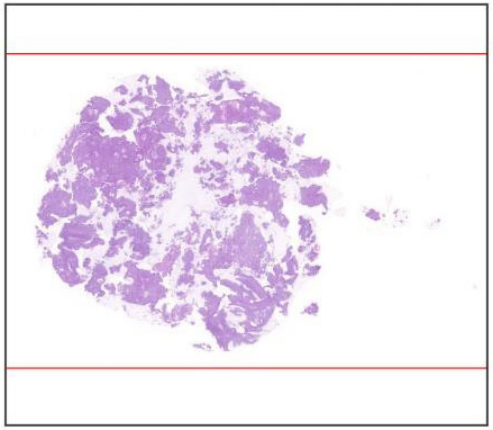

2.5 mm


p16
500 µm


Cam5.2
500 µm

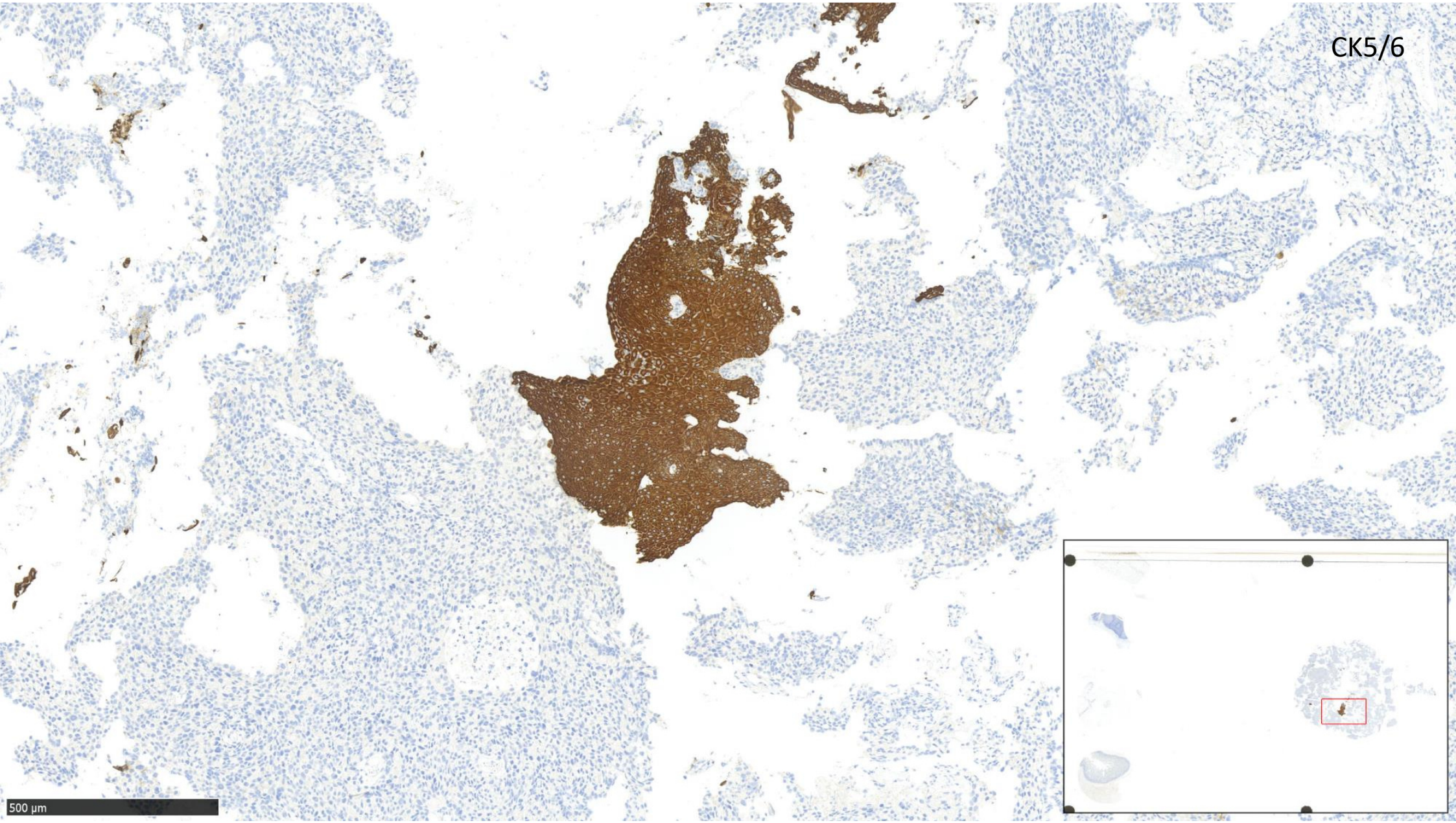
CK5/6
500 µm

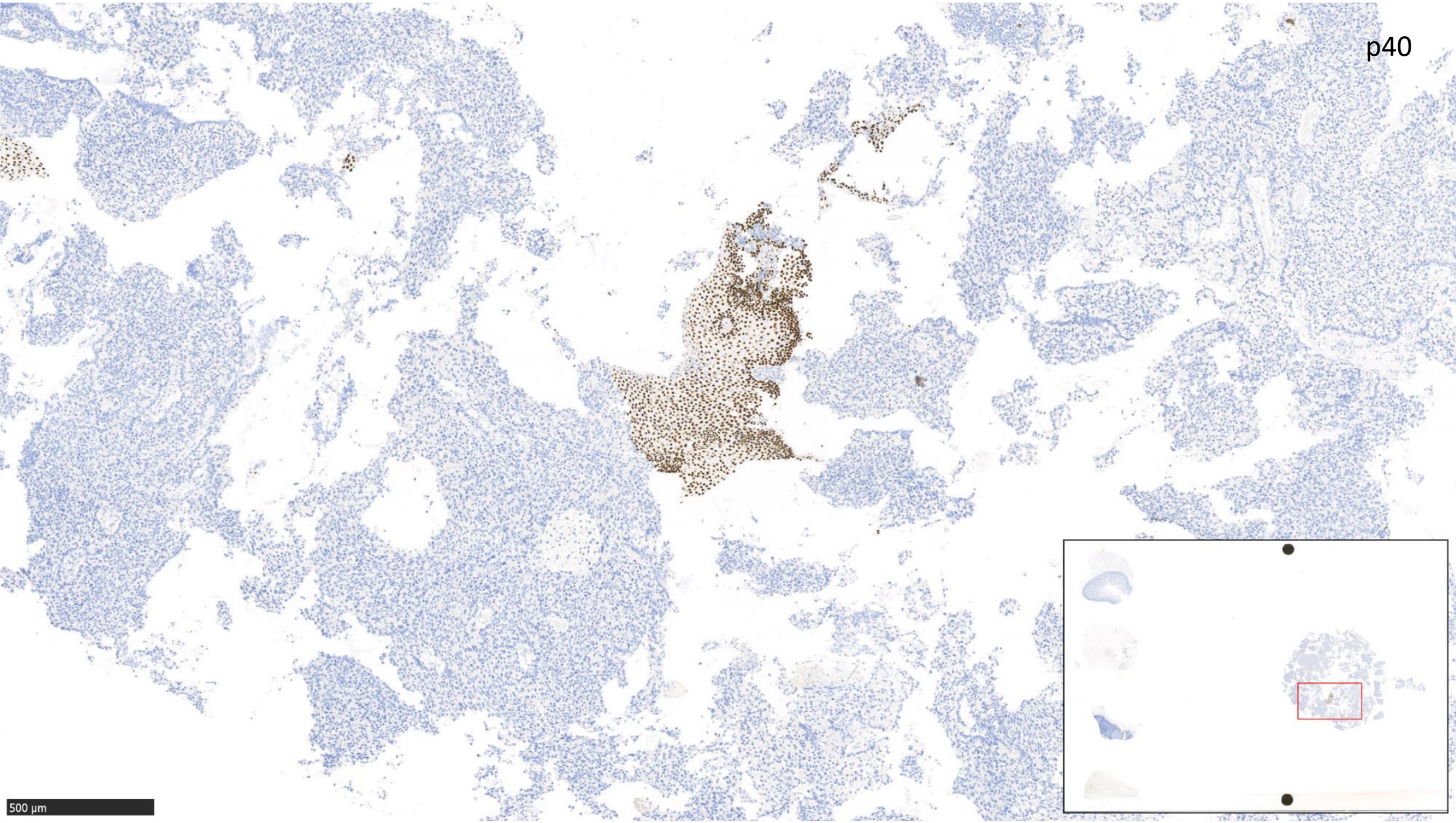
p40
500 µm

SMILE and ISMC

- Variant patterns of adenocarcinoma in situ and adenocarcinoma of usual type
- SMILE consists of stratified epithelium with cells containing mucin in the form of discrete vacuoles or as cytoplasmic clearing throughout all cell layers.
- Nuclear atypia, hyperchromasia, mitoses and apoptotic bodies are usually present.
- p16 immunohistochemistry is positive and there is a high Ki-67 proliferation index.
- Often occurs in association with HSIL and/or AIS but may rarely appear as an isolated finding

SMILE and ISMC

- 445 patients with HSIL, AIS, SMILE or invasive carcinoma
- 250 had only intraepithelial lesions, 195 invasive carcinomas
- 12 cases of SMILE identified
- 9 had associated carcinoma, 3 of these ISMC
- Immunoprofile (both SMILE and ISMC)
  - Cam5.2 positive – diffuse
  - p16 positive – diffuse
  - IMP3 positive – focal
  - p63 – ‘almost negative or only focally positive’

Onishi J et al Hum Pathol. 2016 55:174–81

Diagnosis

Invasive Stratified Mucin-producing Carcinoma (ISMC) and Stratified Mucin-producing Intraepithelial Lesion (SMILE)

Lastra R et al Am J Surg Pathol. 2016; 40:262–9
Onishi J et al Hum Pathol. 2016 55:174–81

Case

- Female aged 49
- Intermenstrual bleeding
- Smear negative
- Friable growth on cervix, 2 cm, bleeds easily on touch
- Cervical biopsies x 3

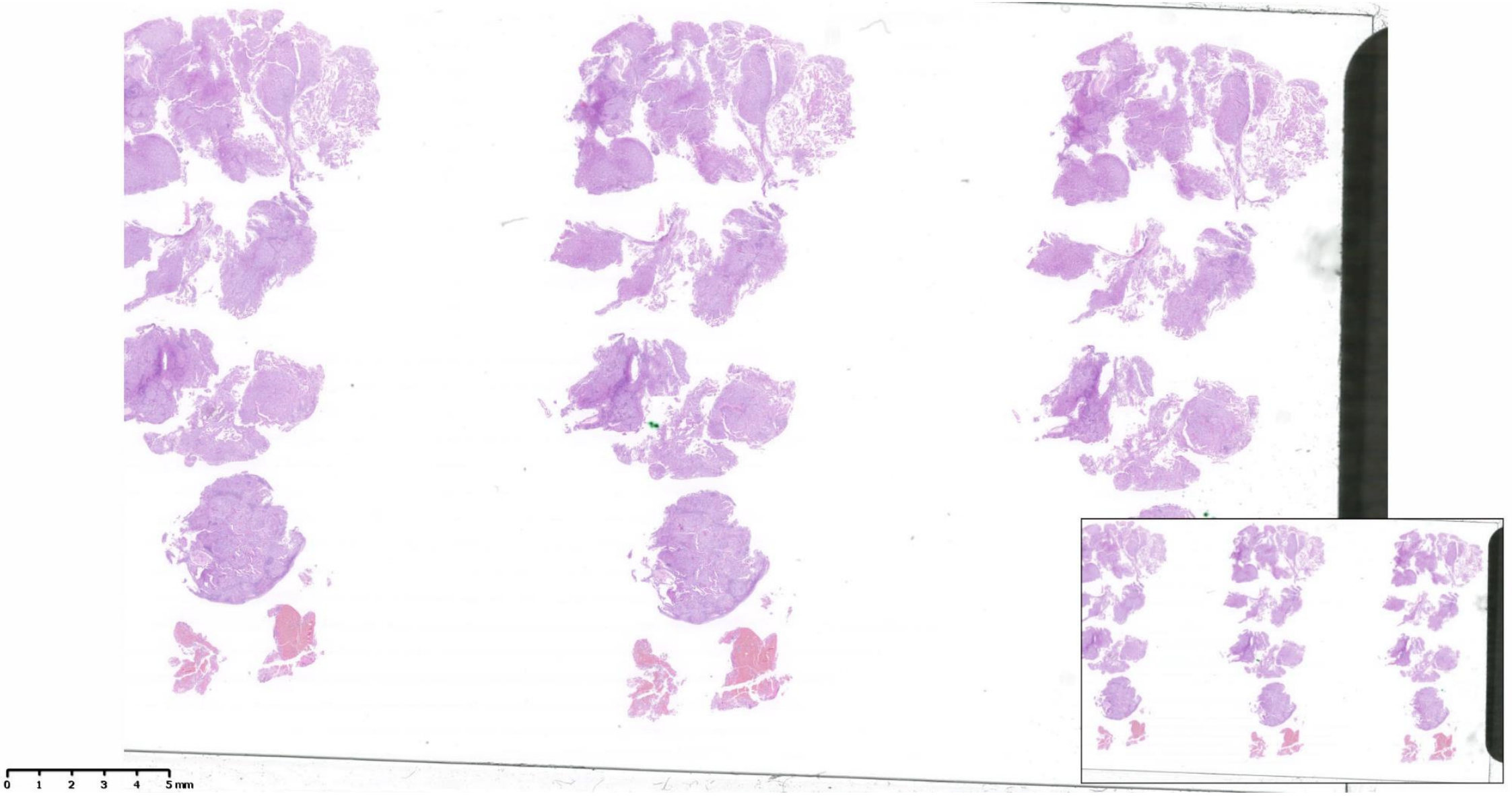
0 1 2 3 4 5 mm

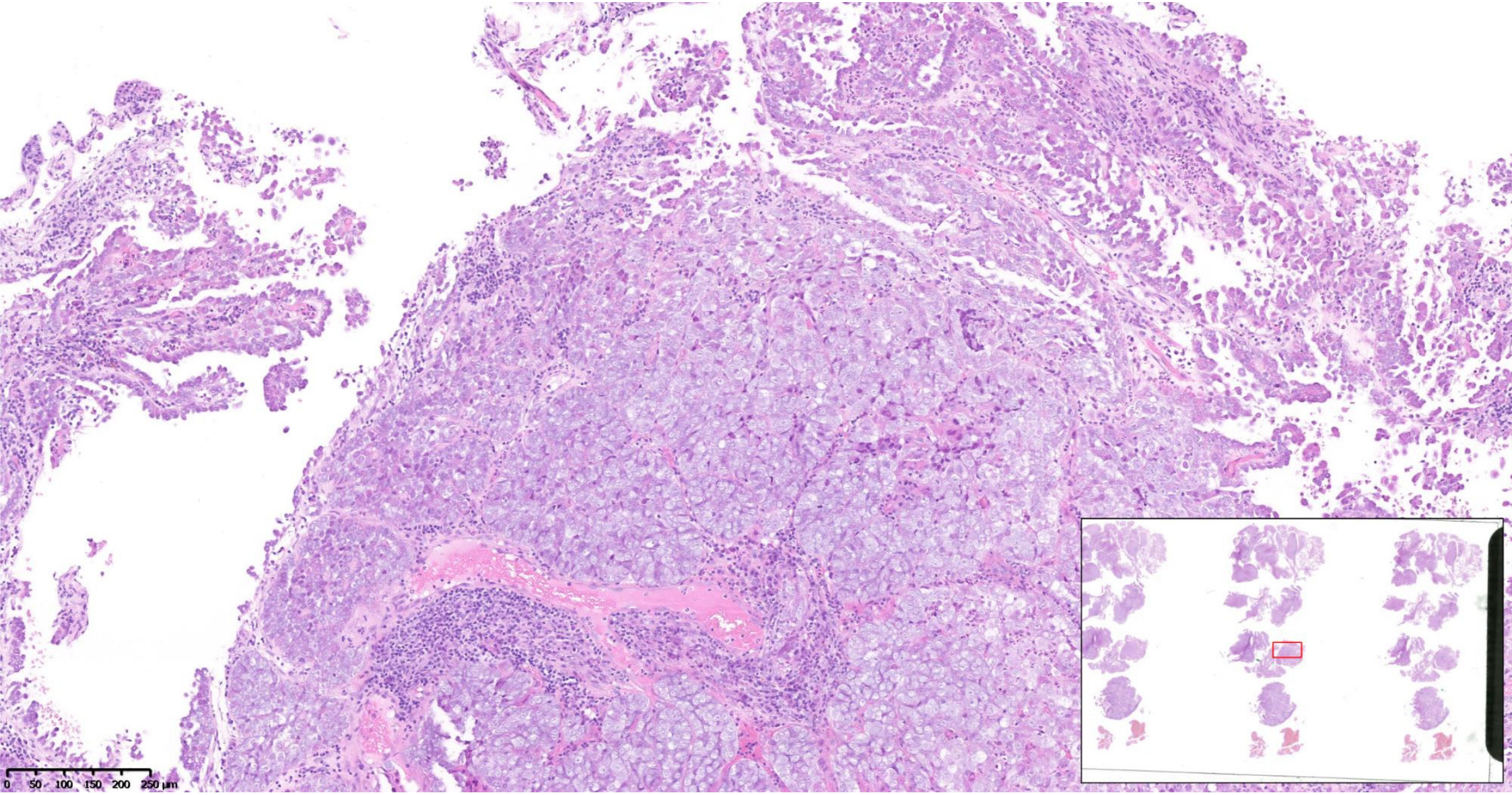
0 50 100 150 200 250 µm

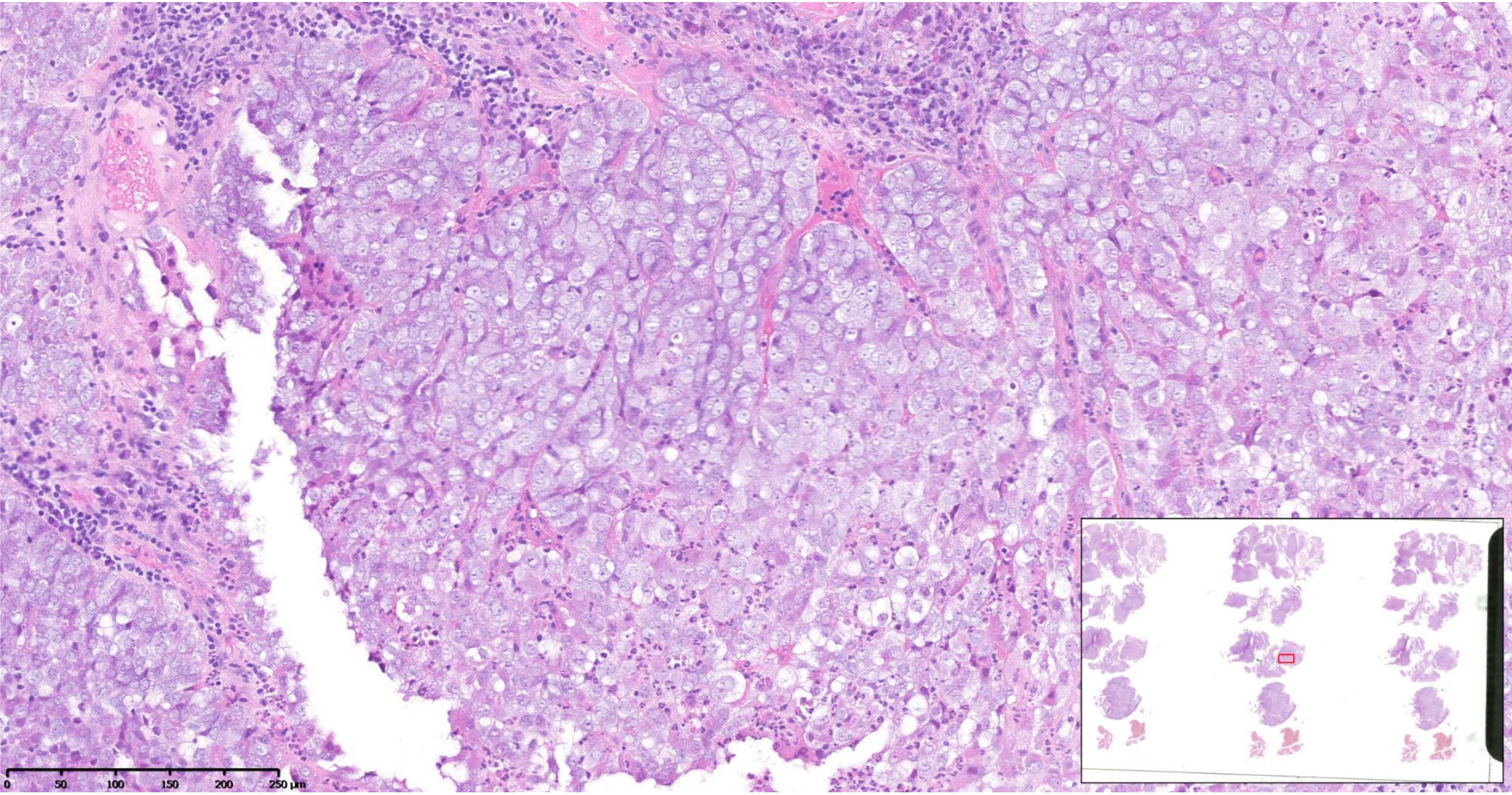
0
50
100
150
200
250 µm

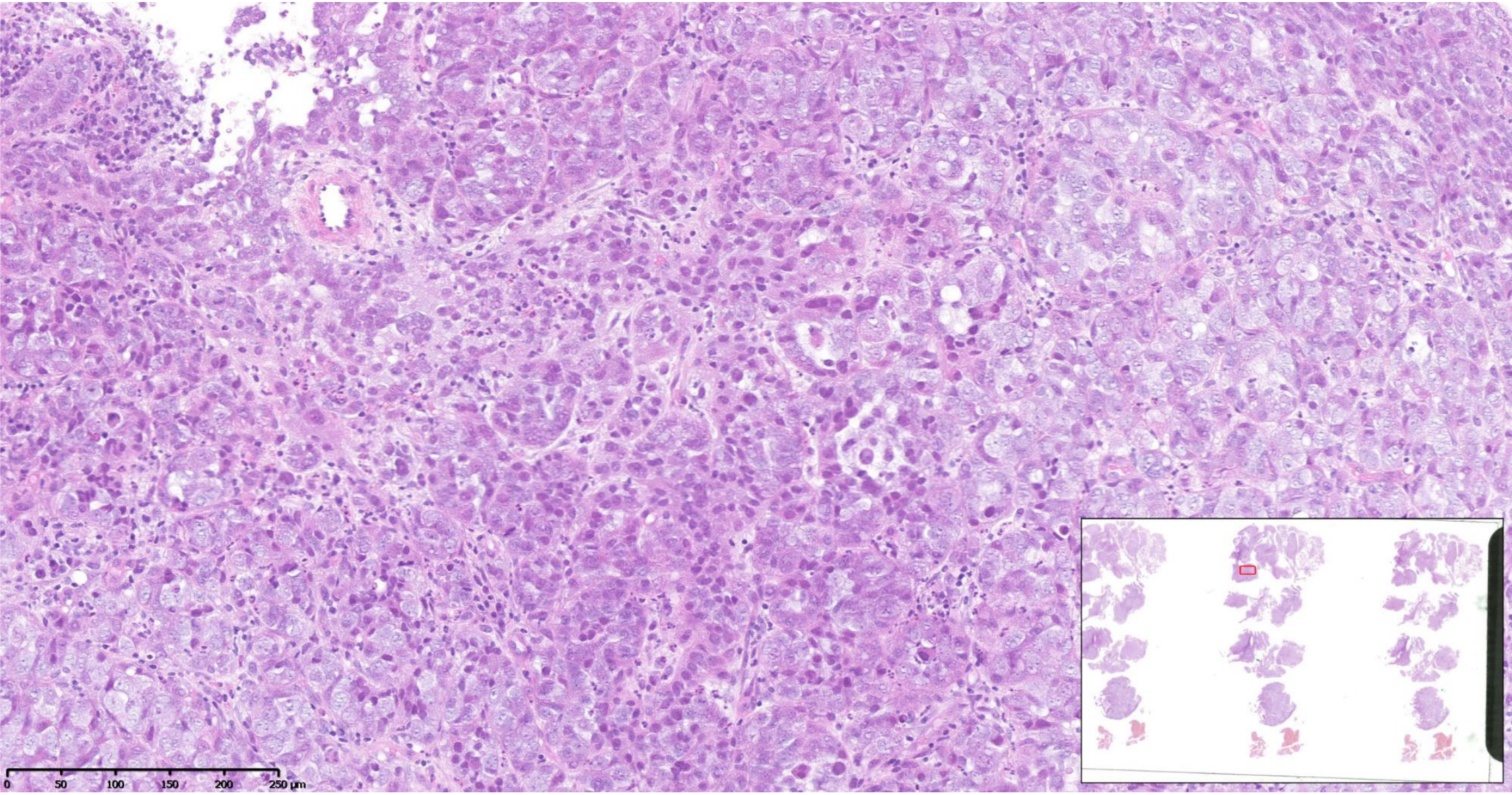
0
50
100
150
200
250 µm

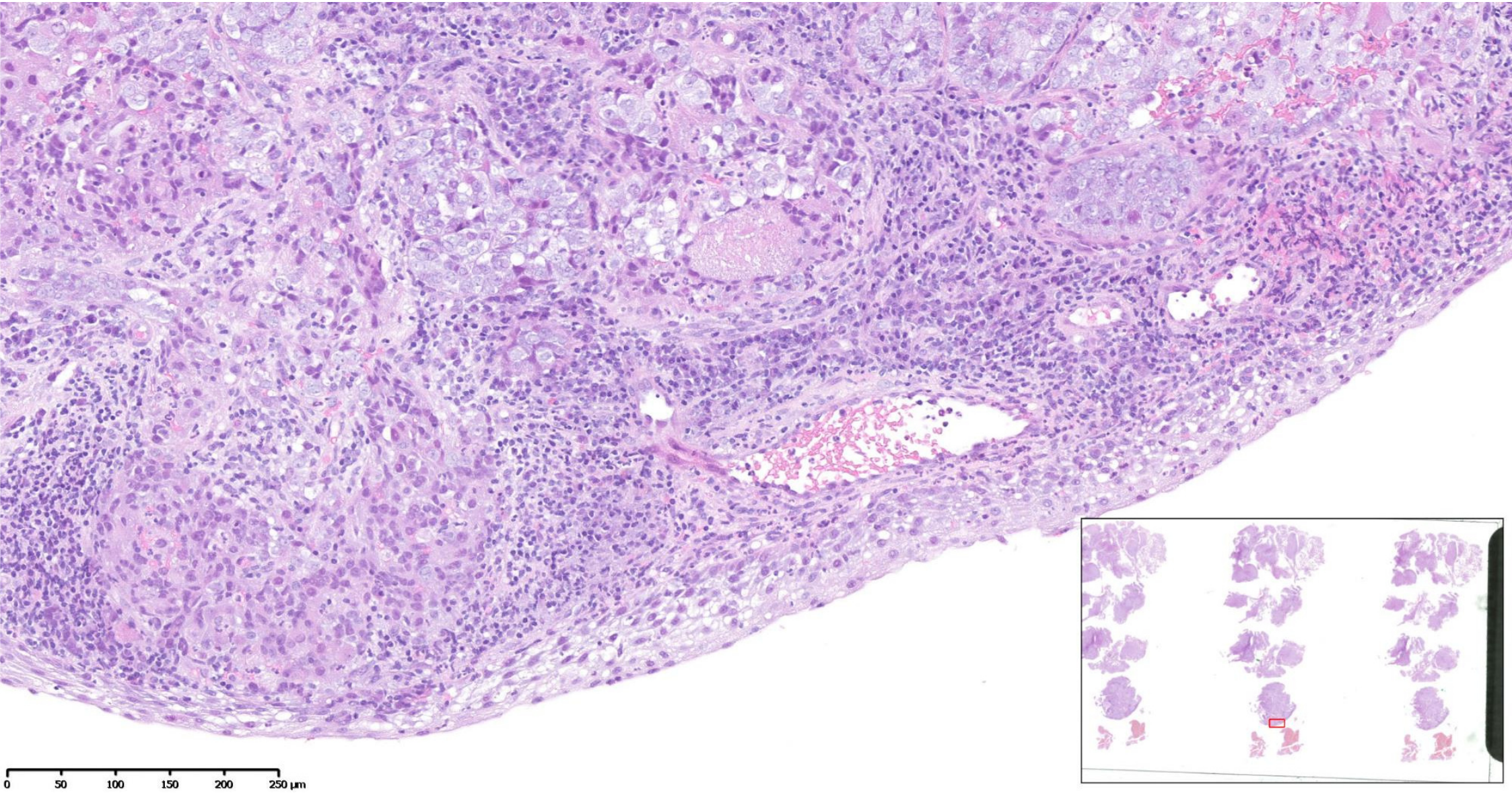
0
50
100
150
200
250 µm

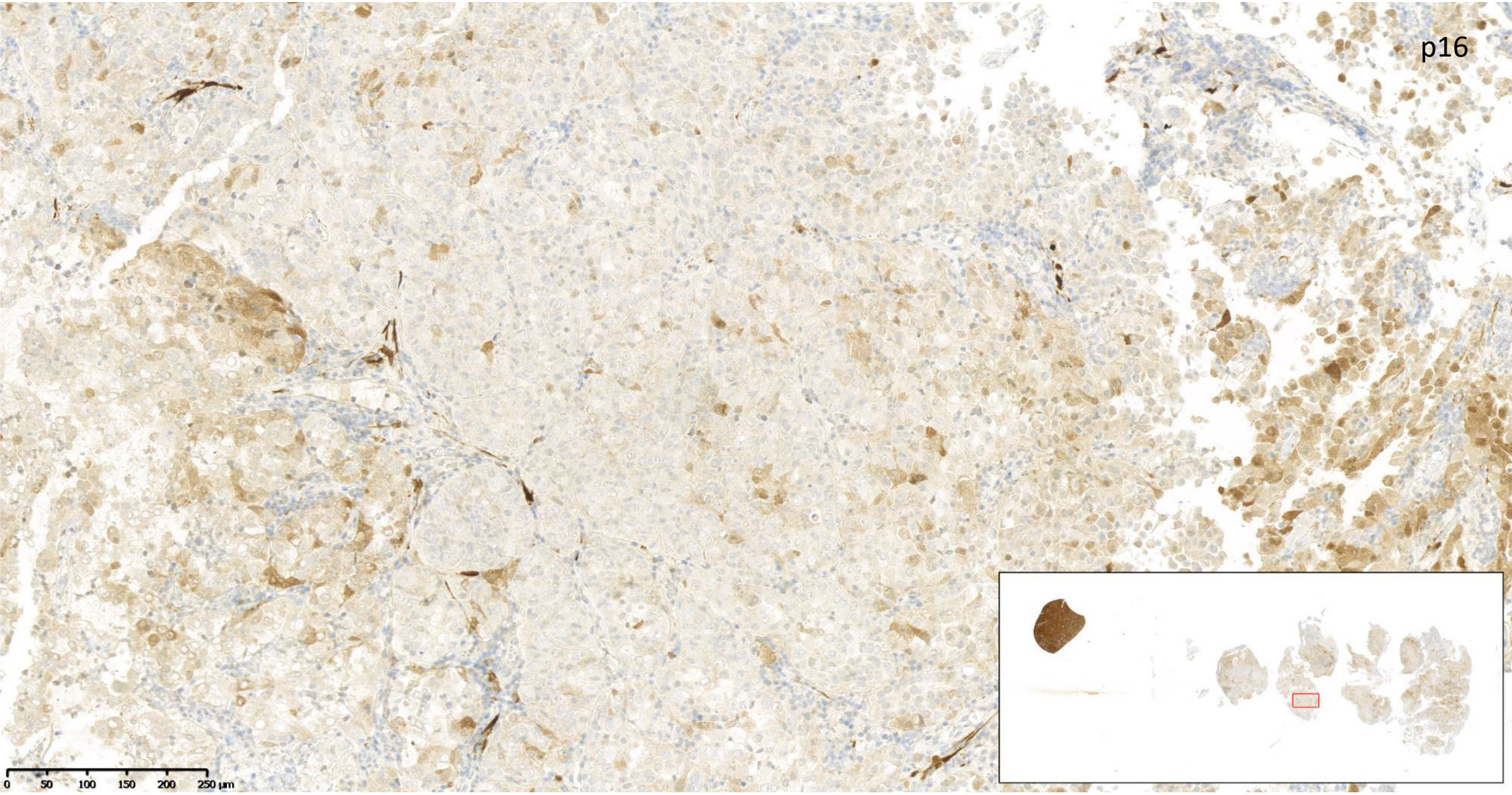
p16
0 50 100 150 200 250 µm

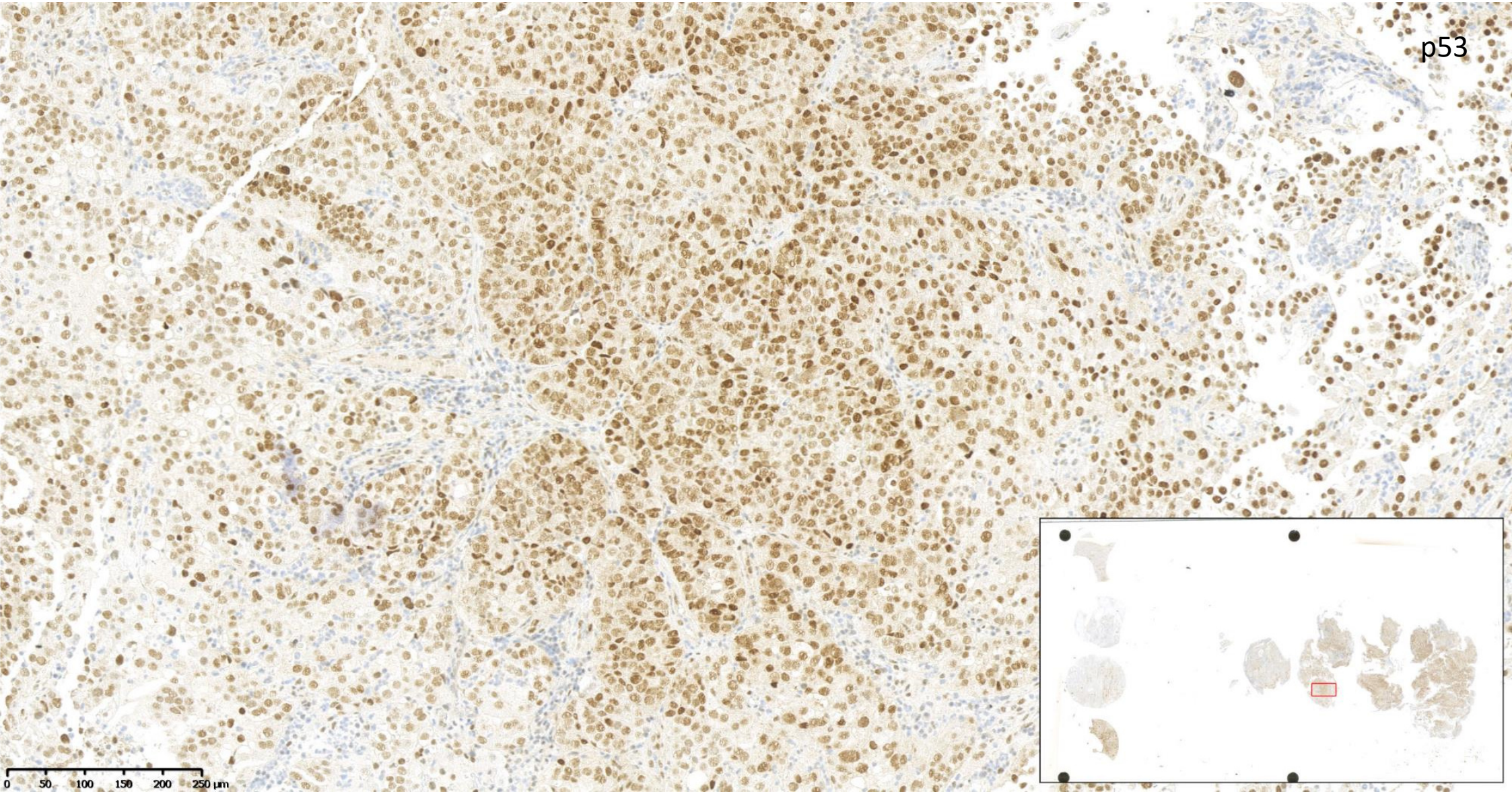
p53
0 50 100 150 200 250 µm

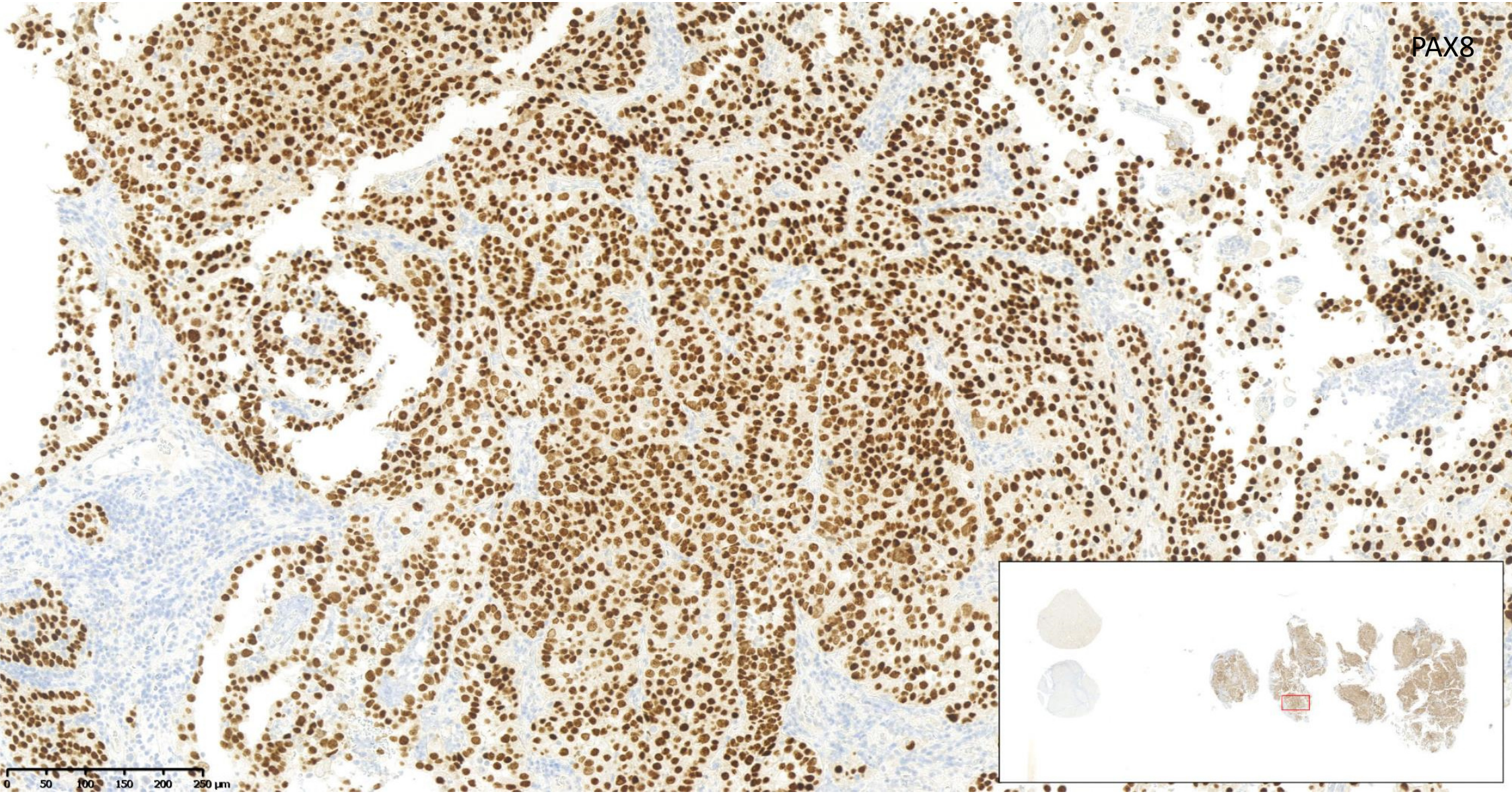
PAX8
0 50 100 150 200 250 µm

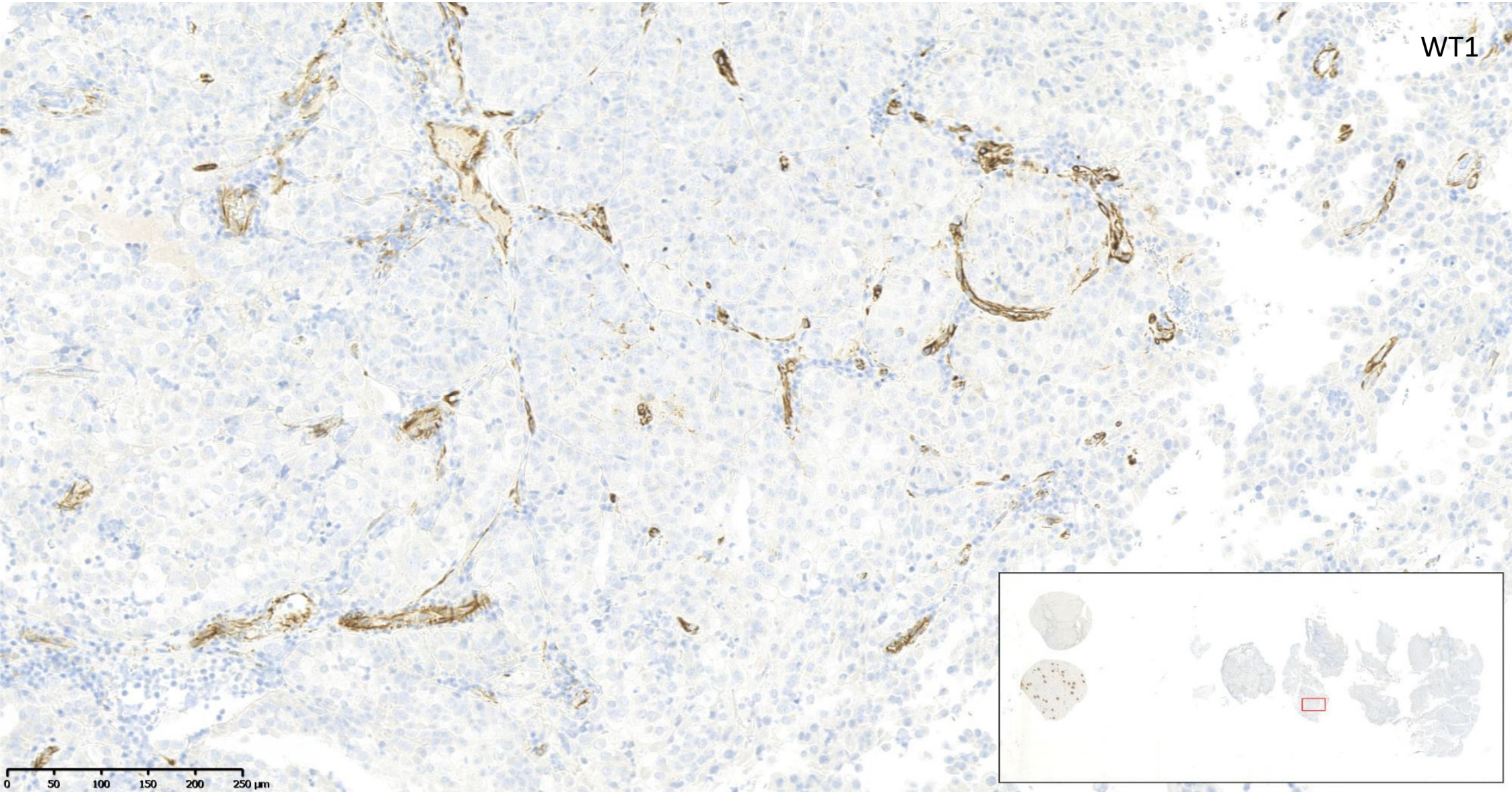
WT1
0
50
100
150
200
250 µm

Subsequent operation

- Wertheim’s hysterectomy
- Pelvic and para-aortic lymph node dissection
- Omental biopsy
- Findings
  - Cervical tumour 29 mm in diameter
  - Lymph nodes negative
  - Omentum negative

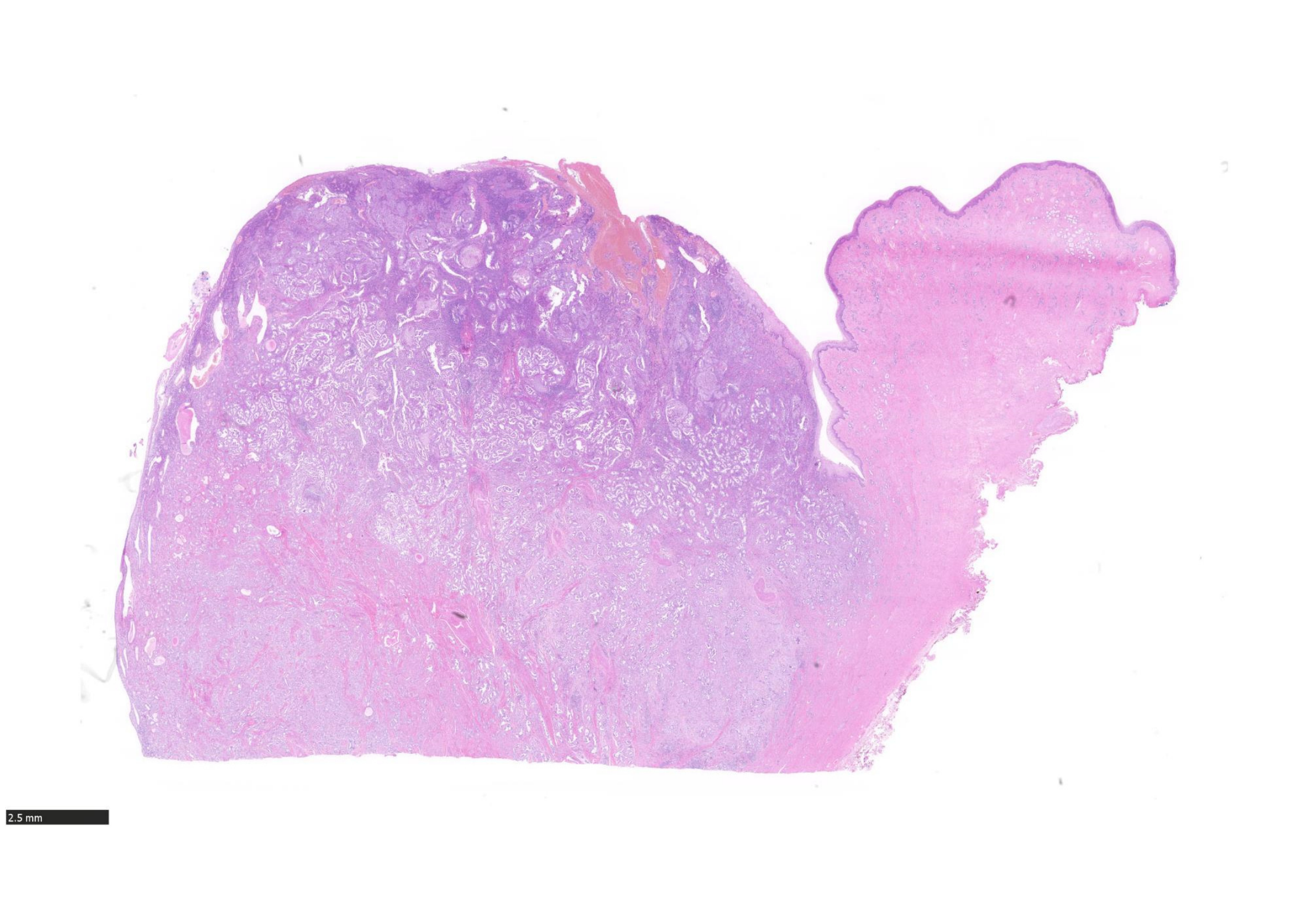
2.5 mm

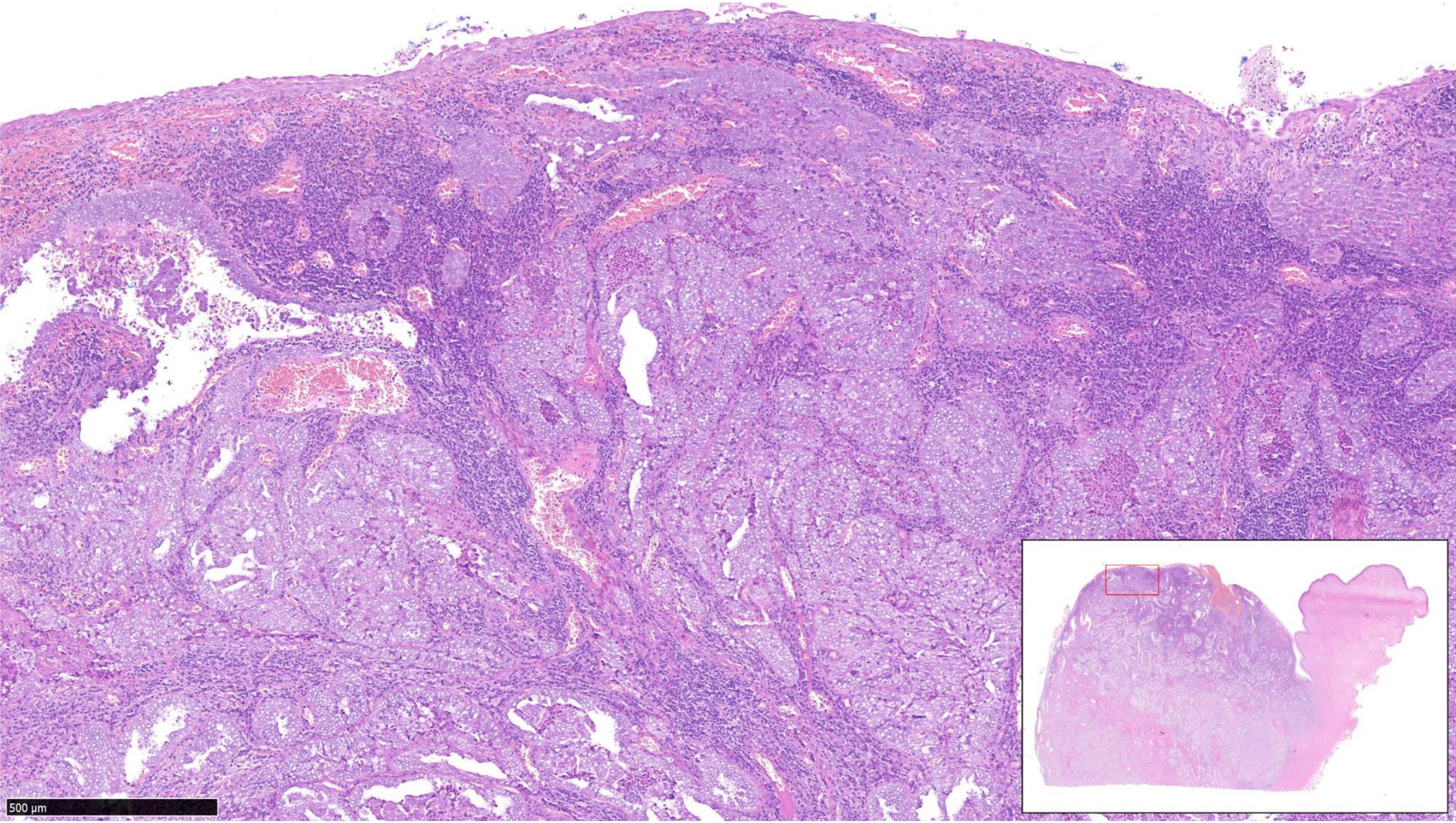
500 µm

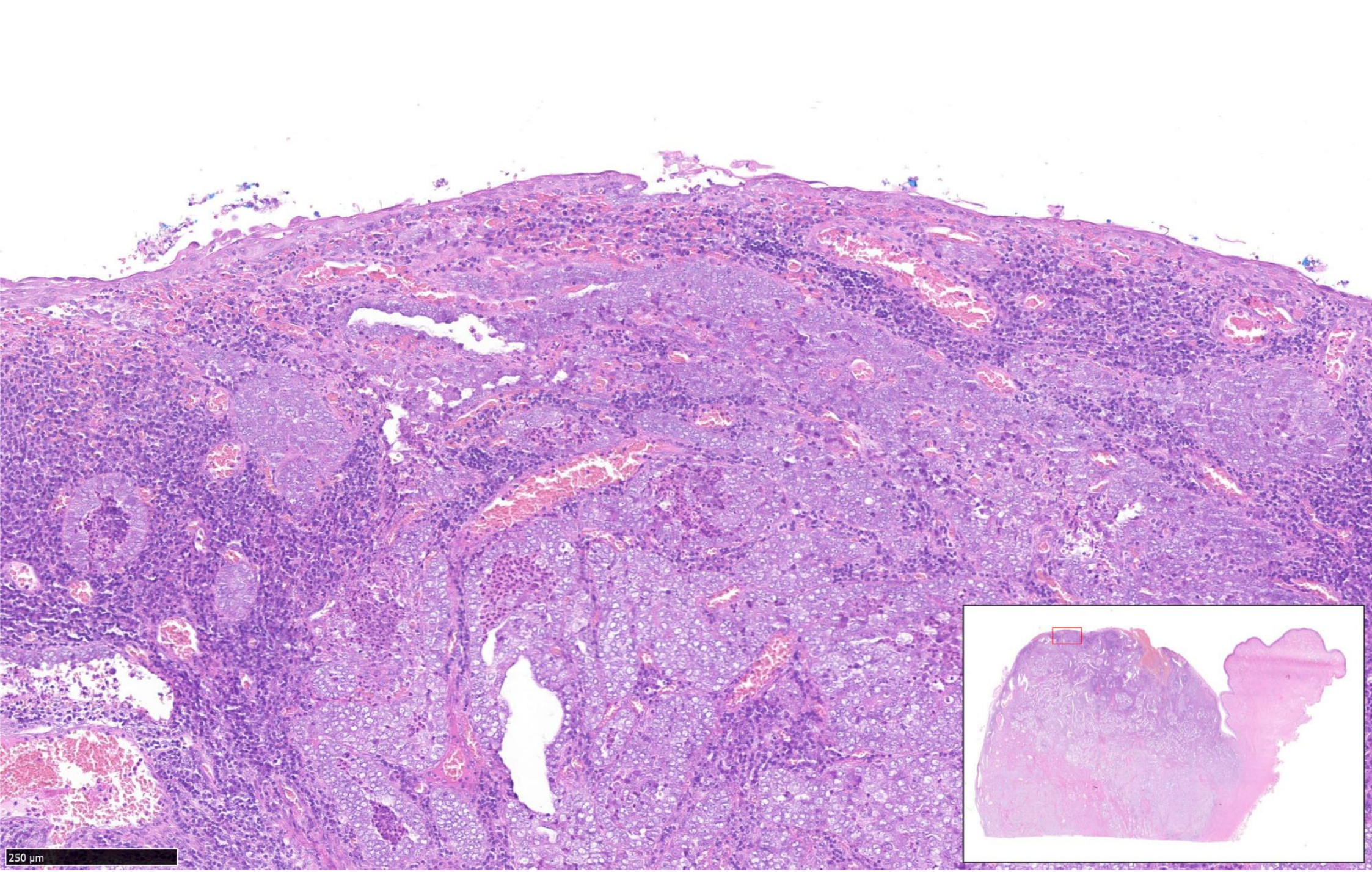
250 µm

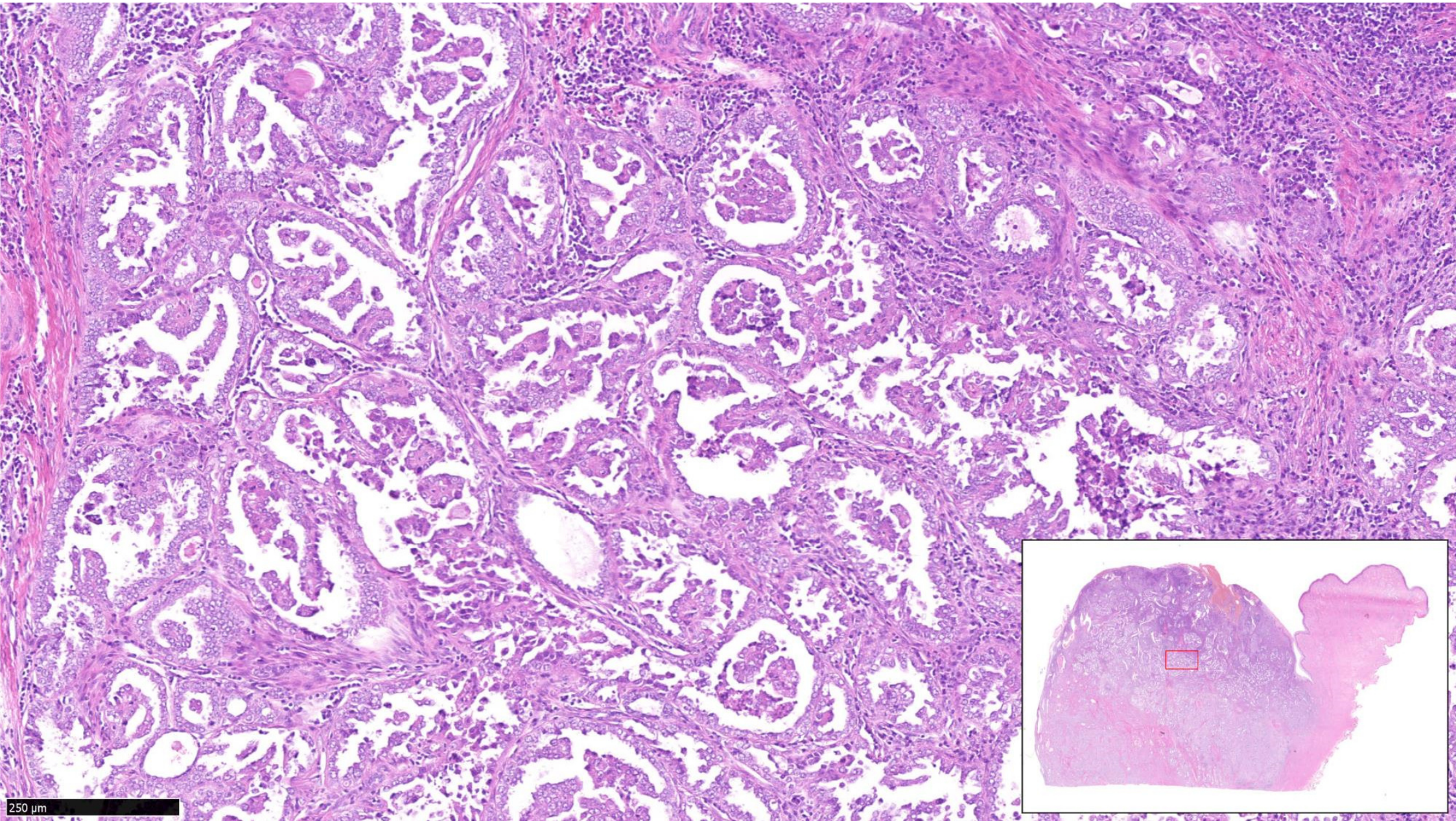
250 µm

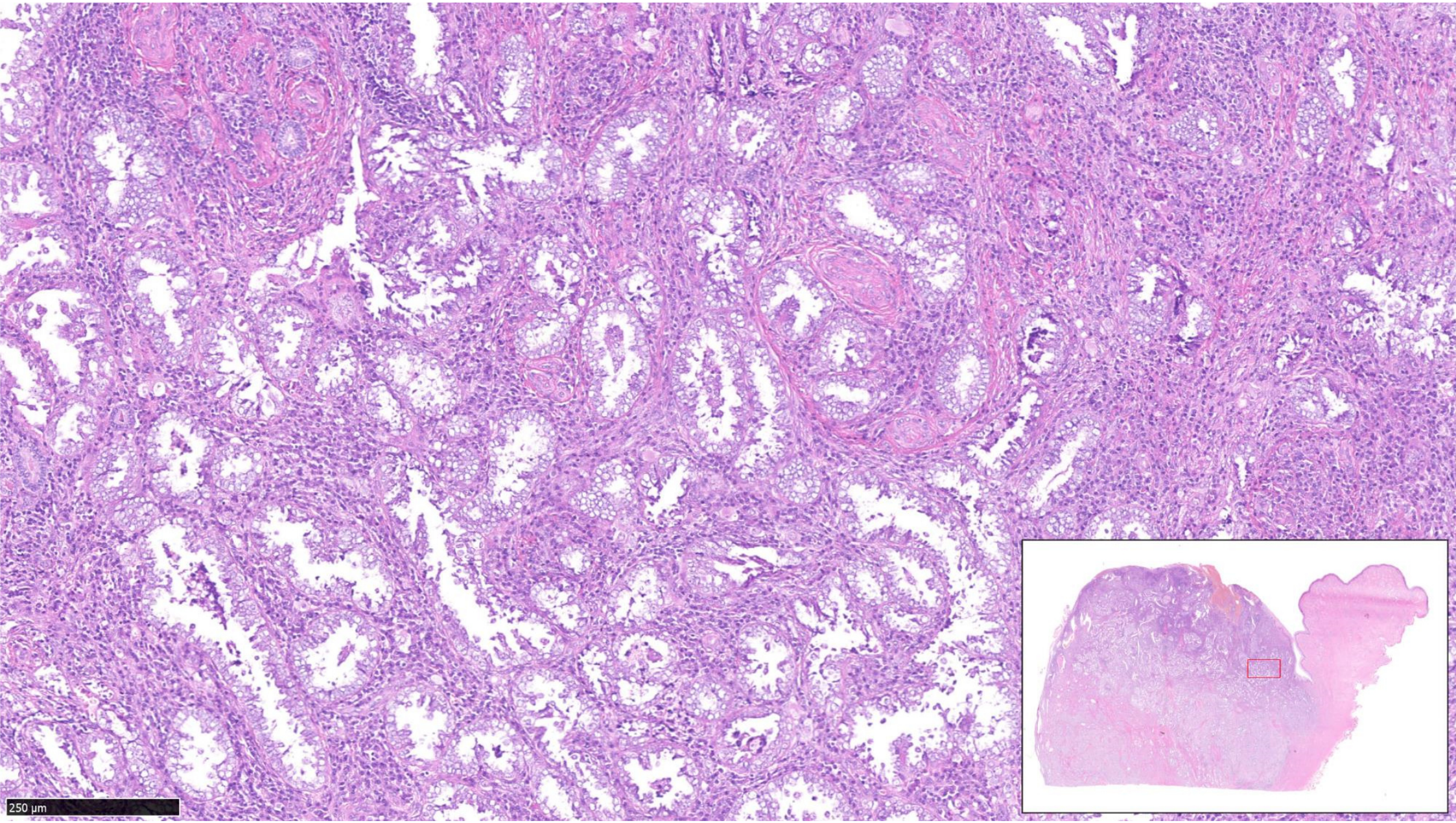
250 µm

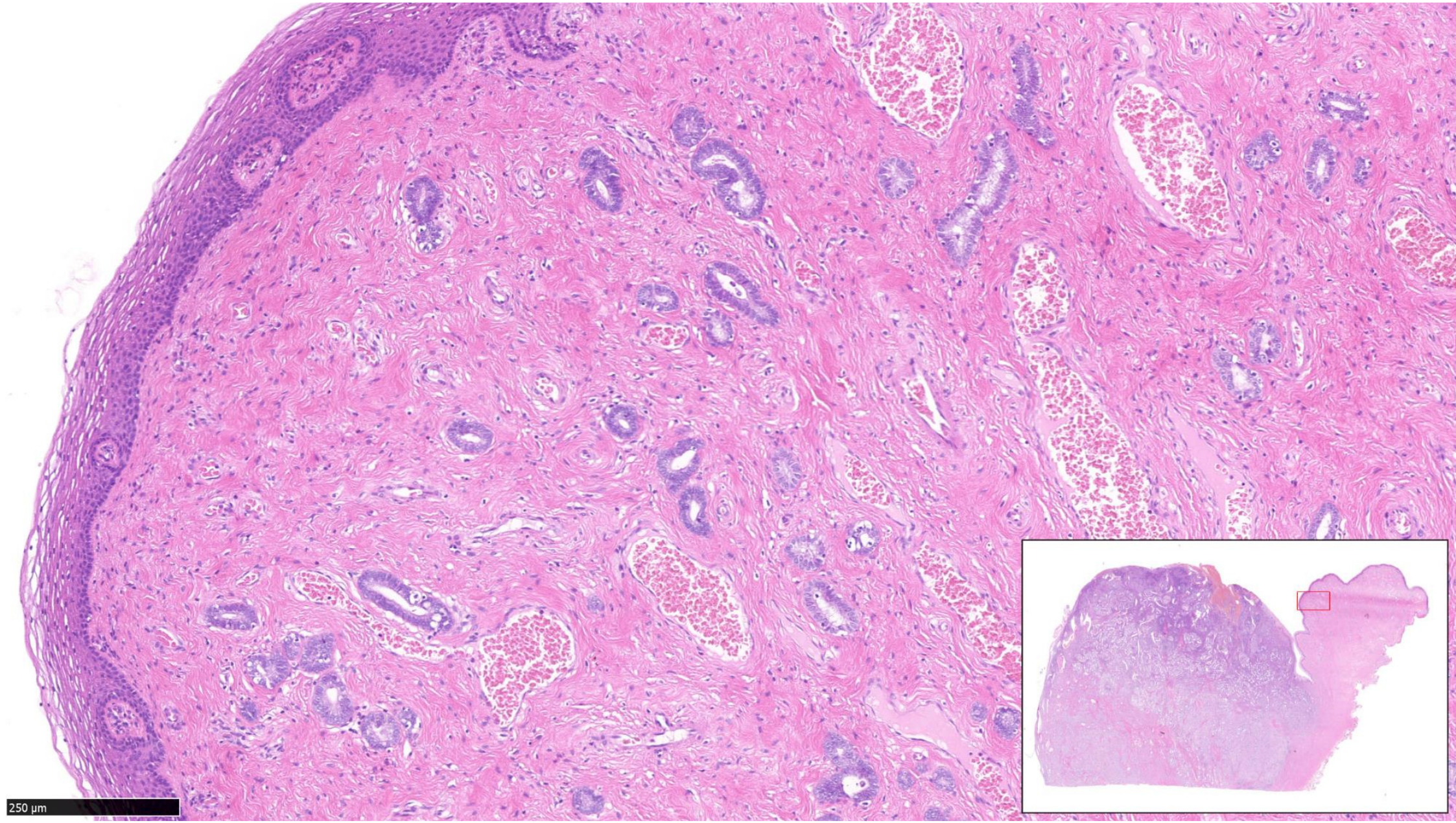
250 µm

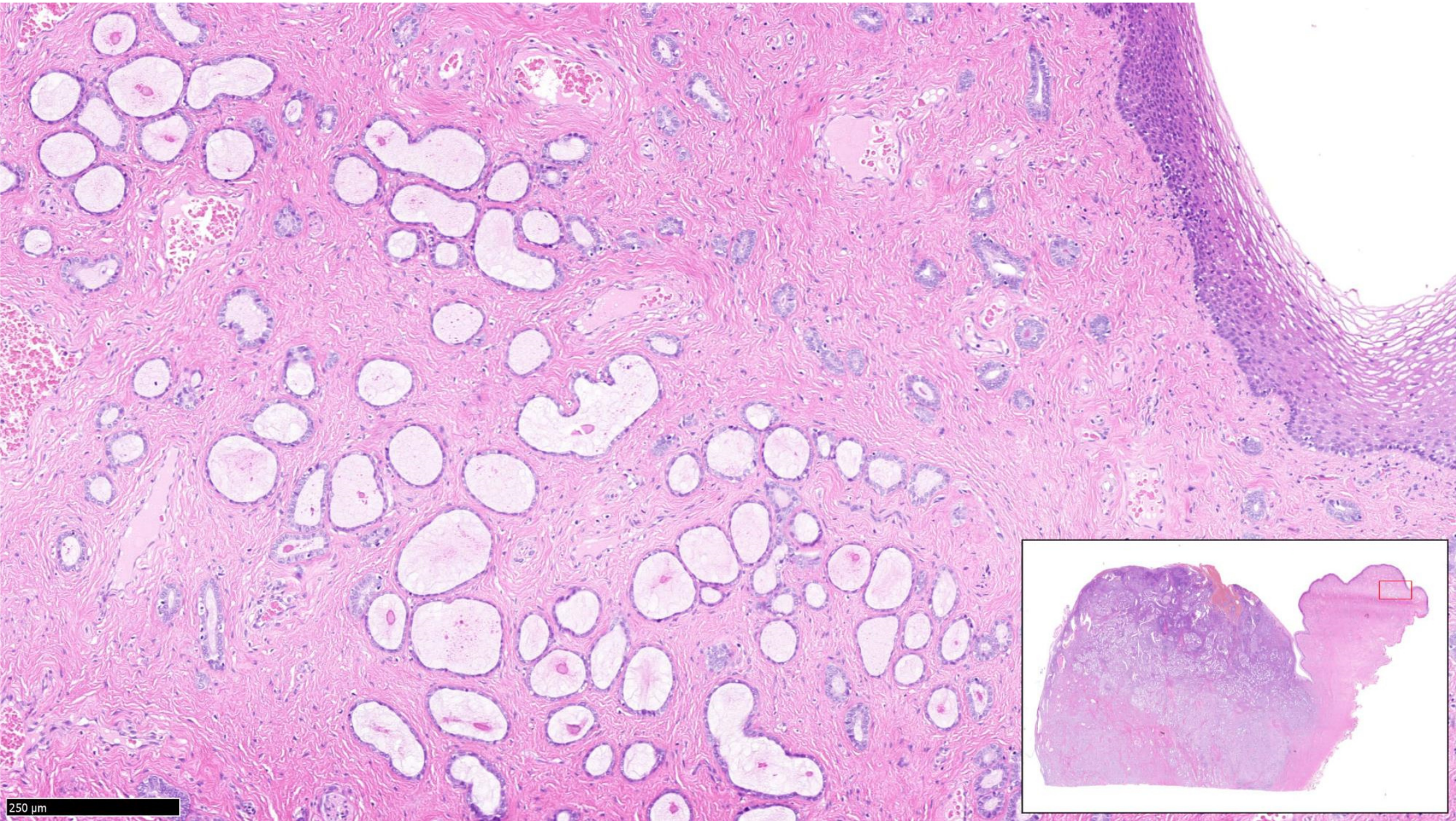
250 µm

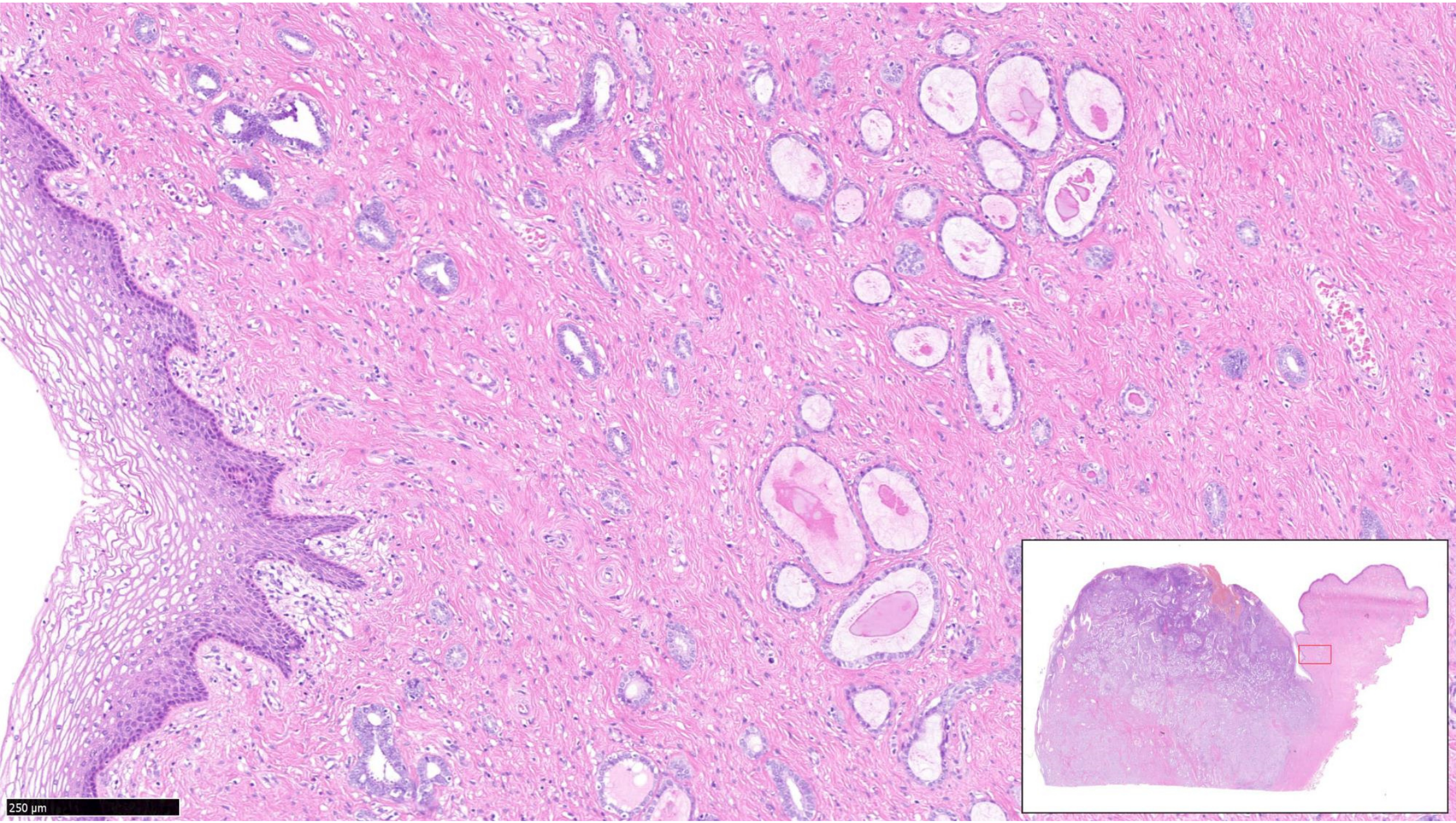
250 µm

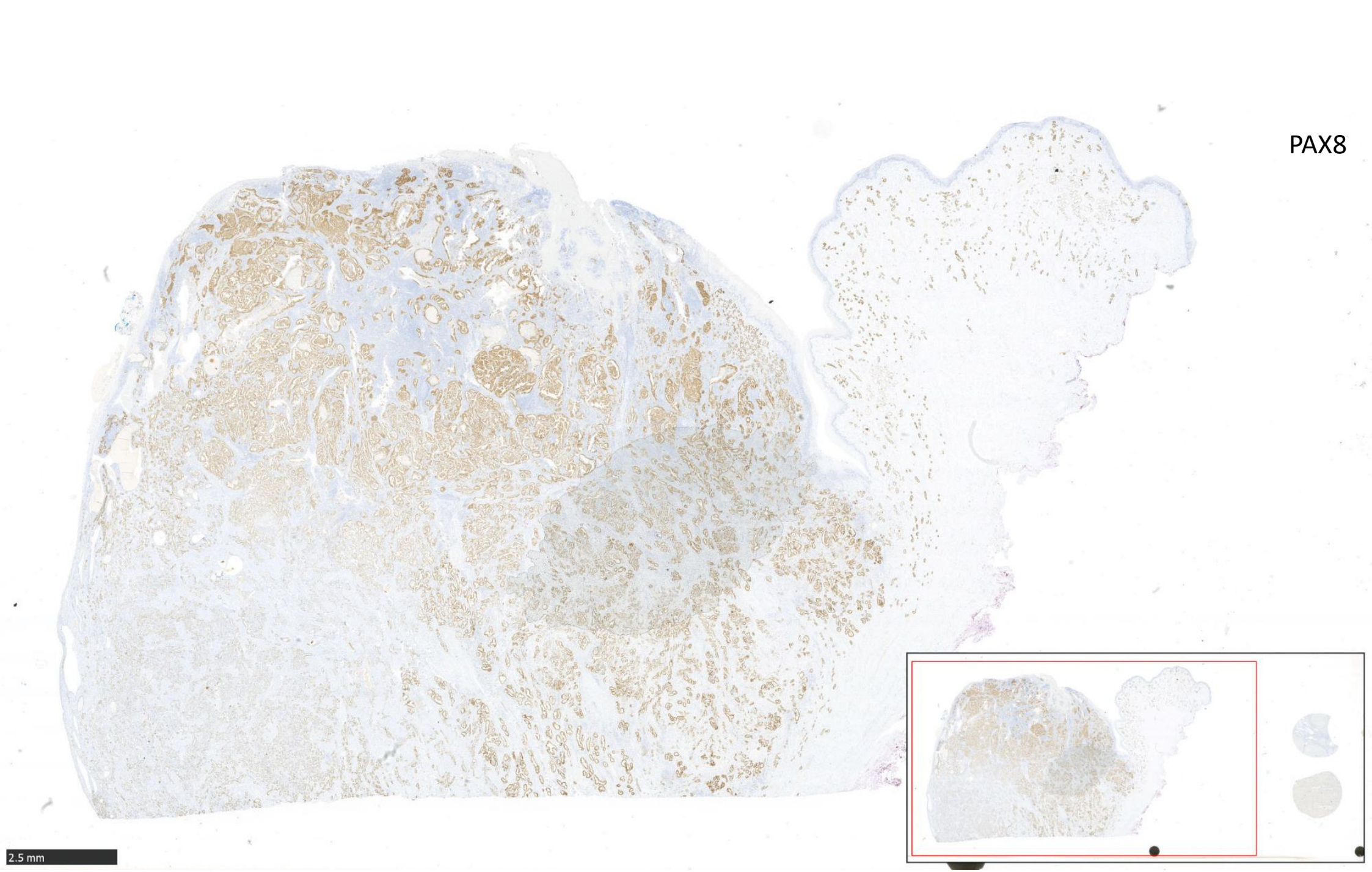
PAX8
2.5 mm

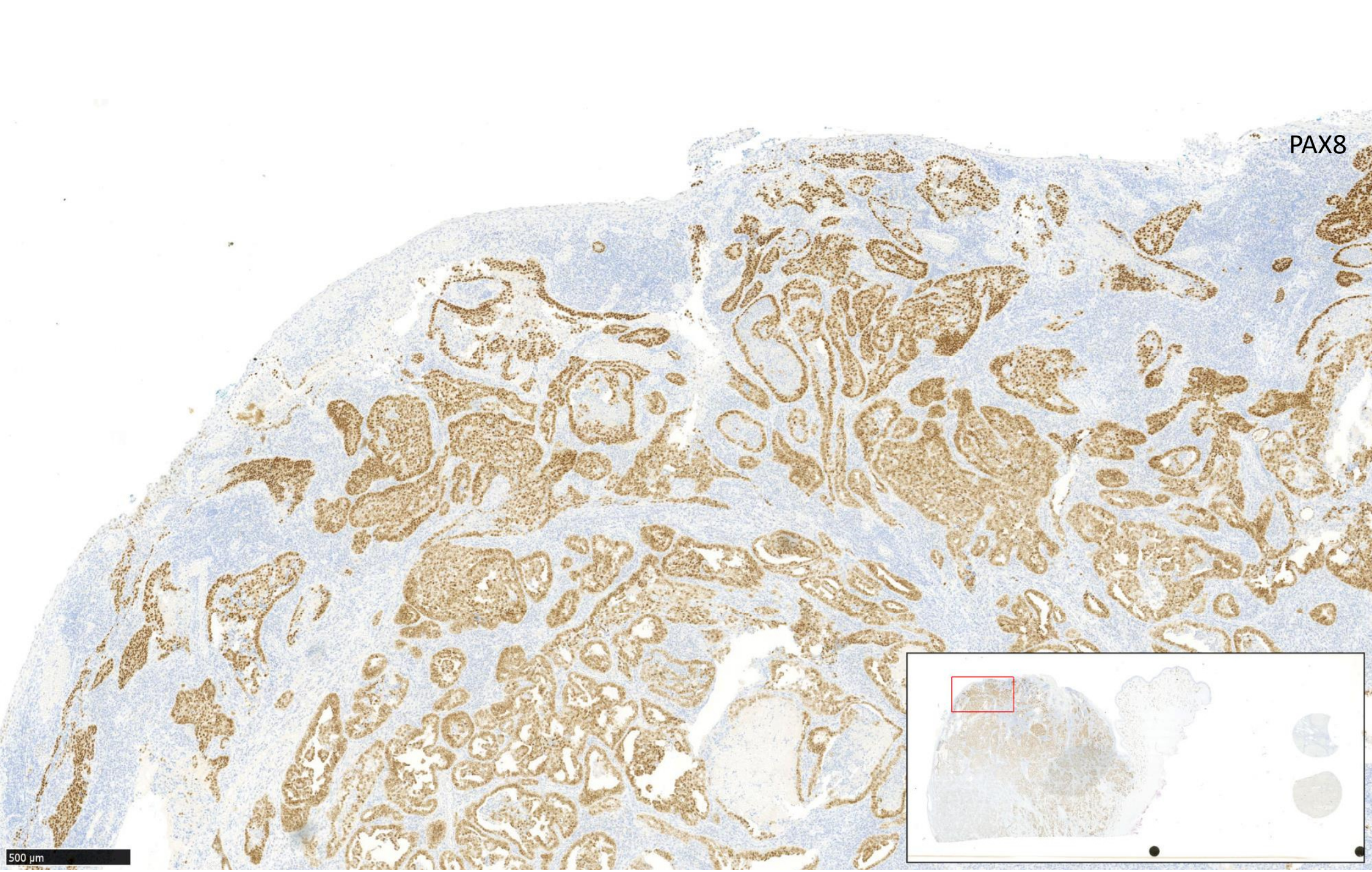
PAX8
500 µm

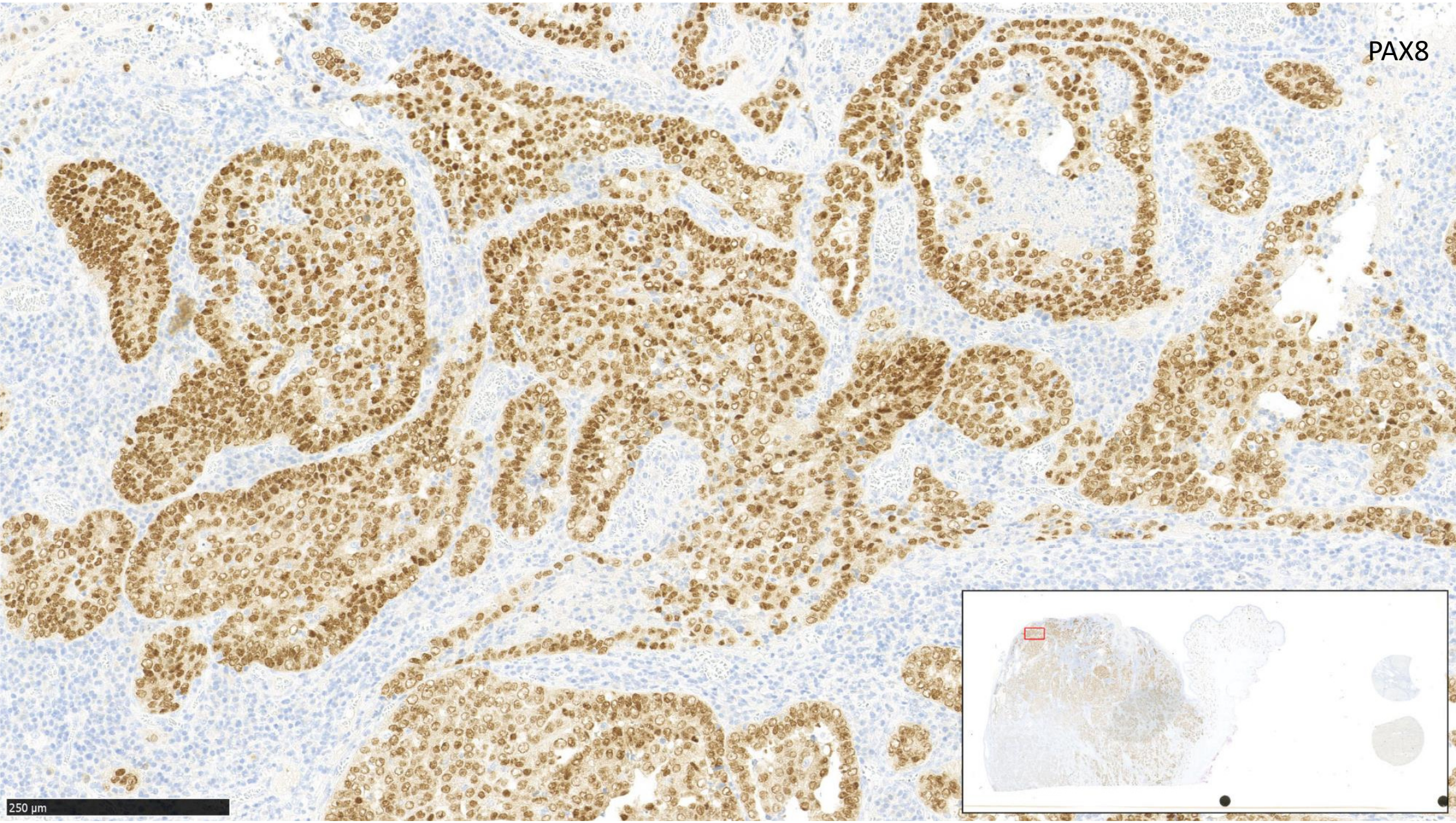
PAX8
250 µm

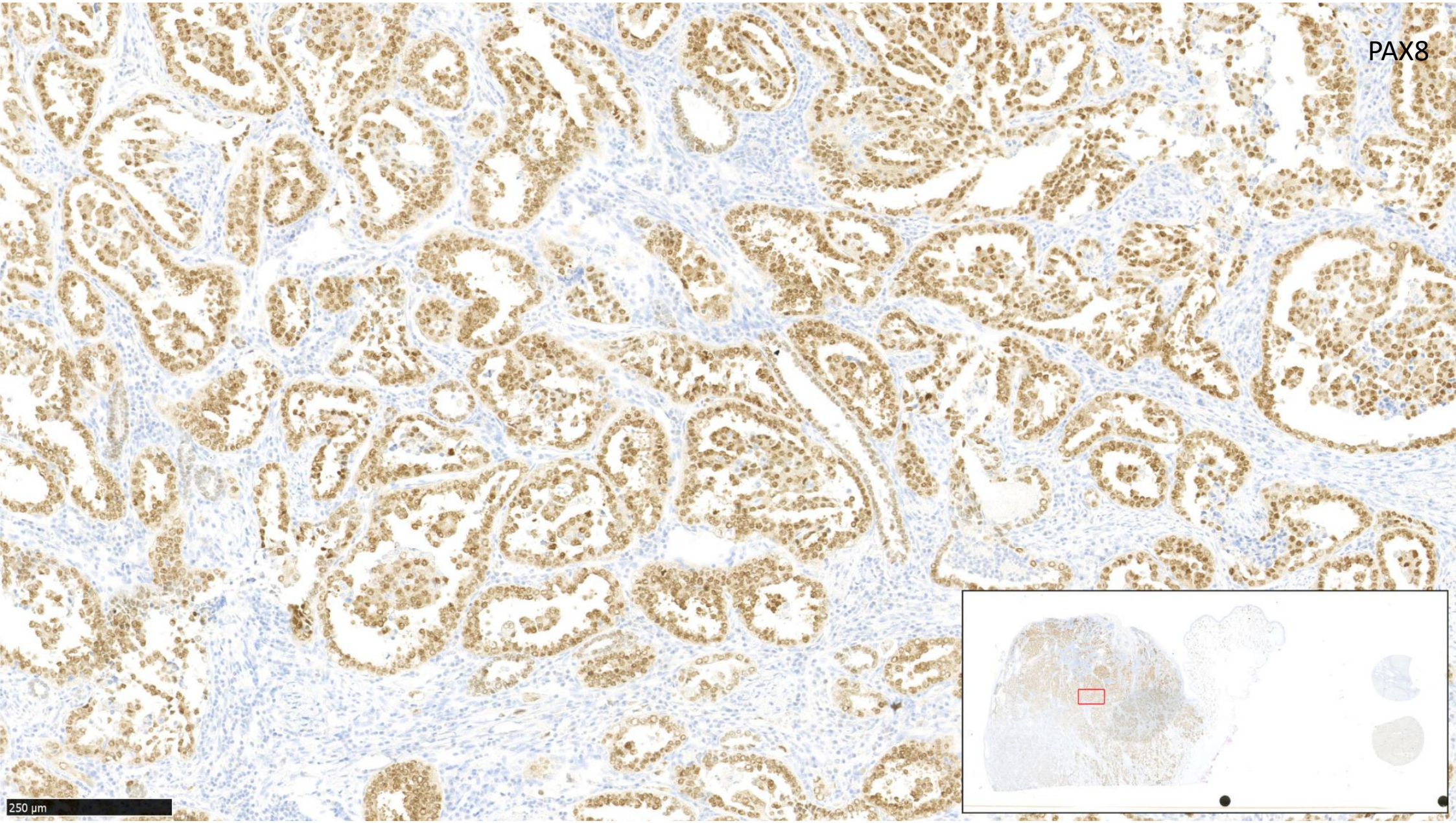
PAX8
250 µm

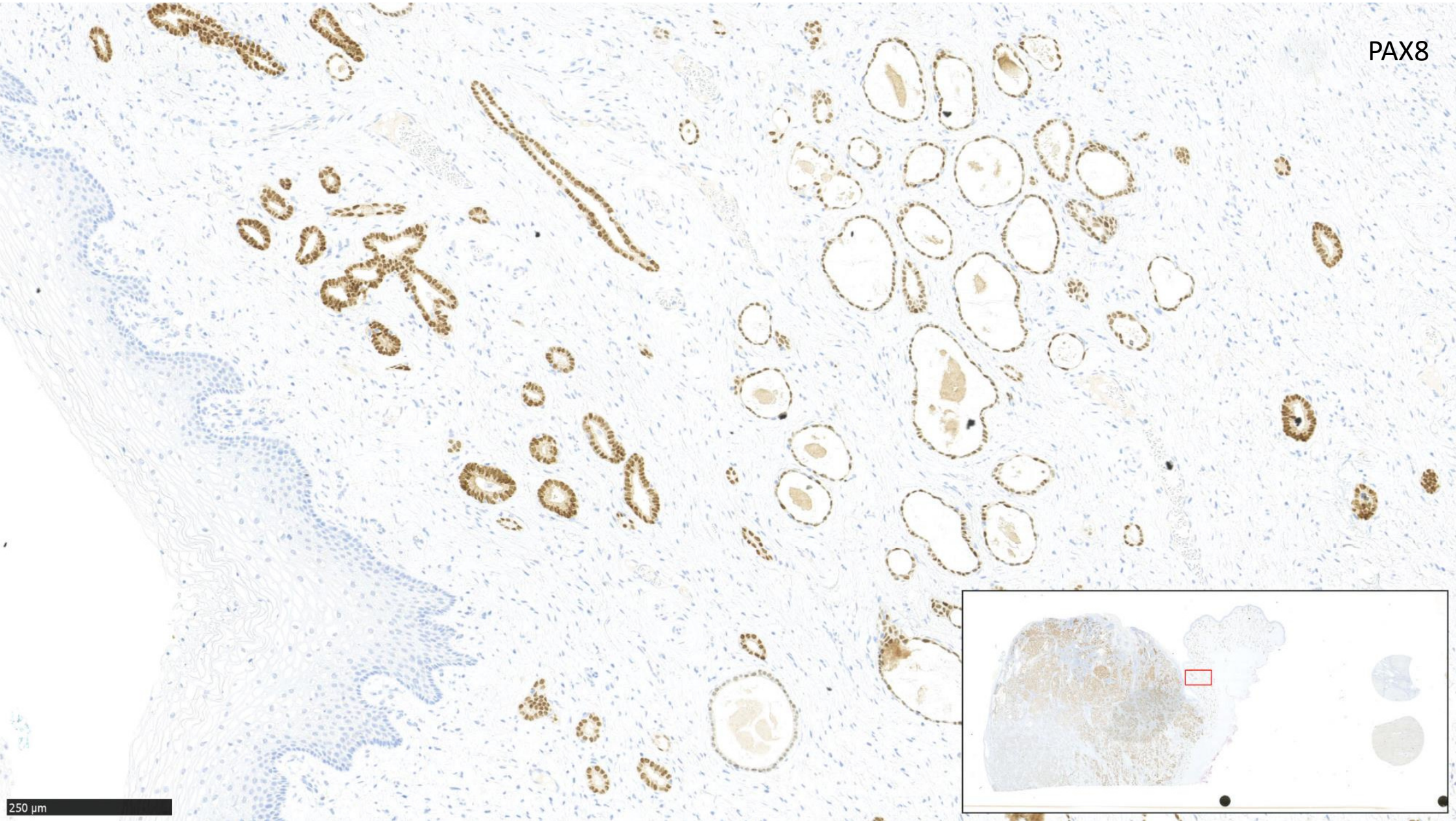
PAX8
250 µm

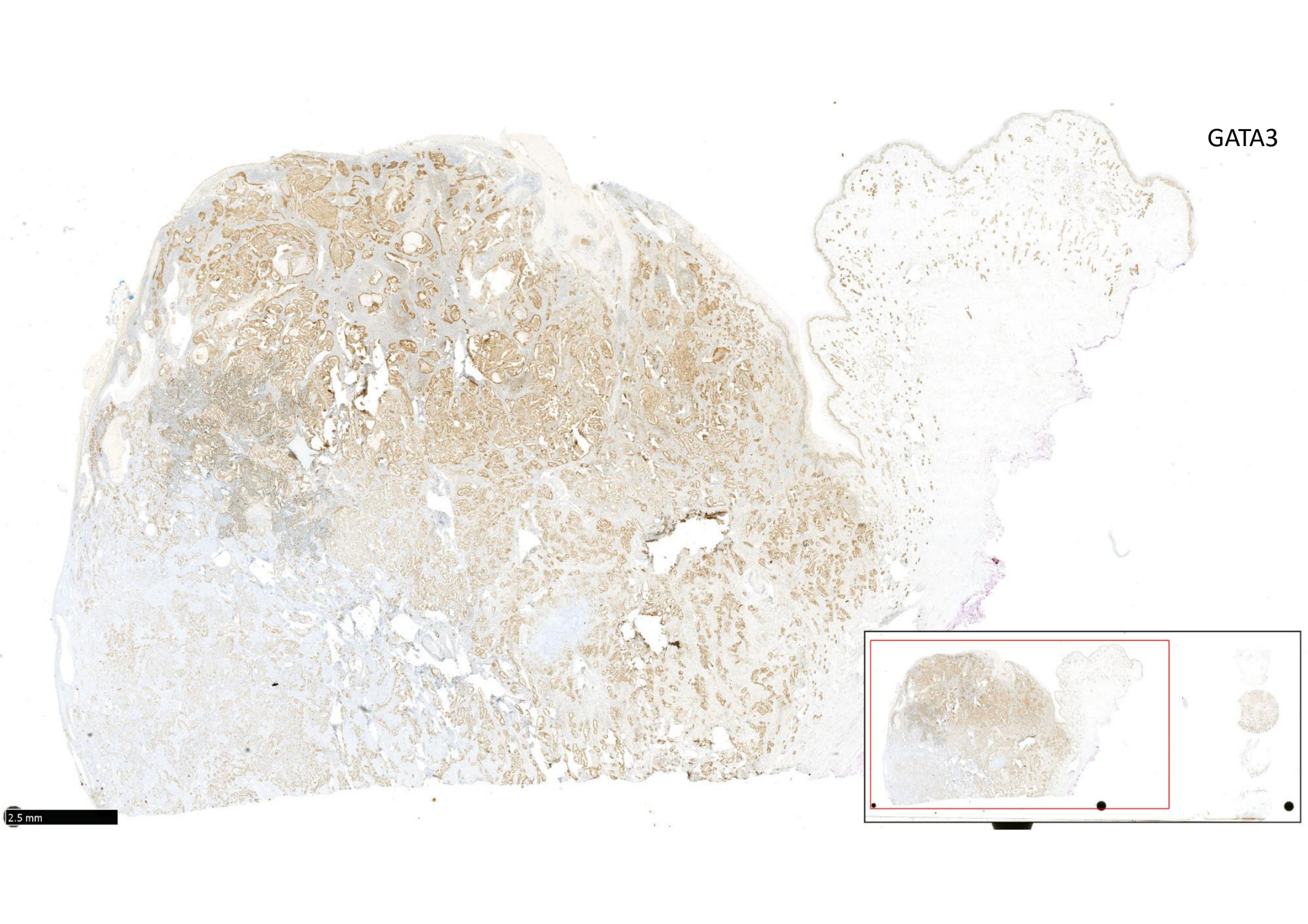
GATA3
2.5 mm

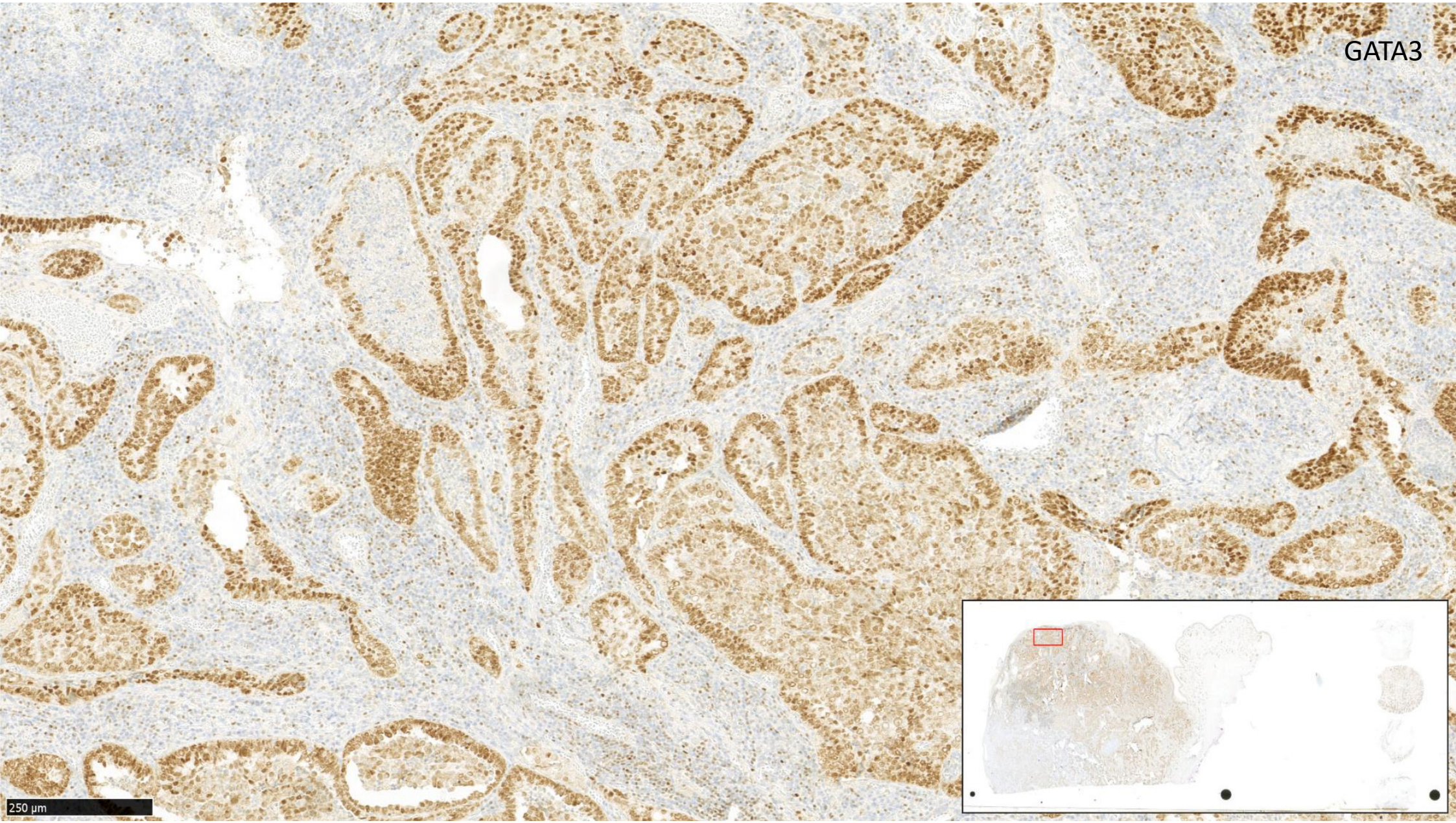
GATA3
250 µm

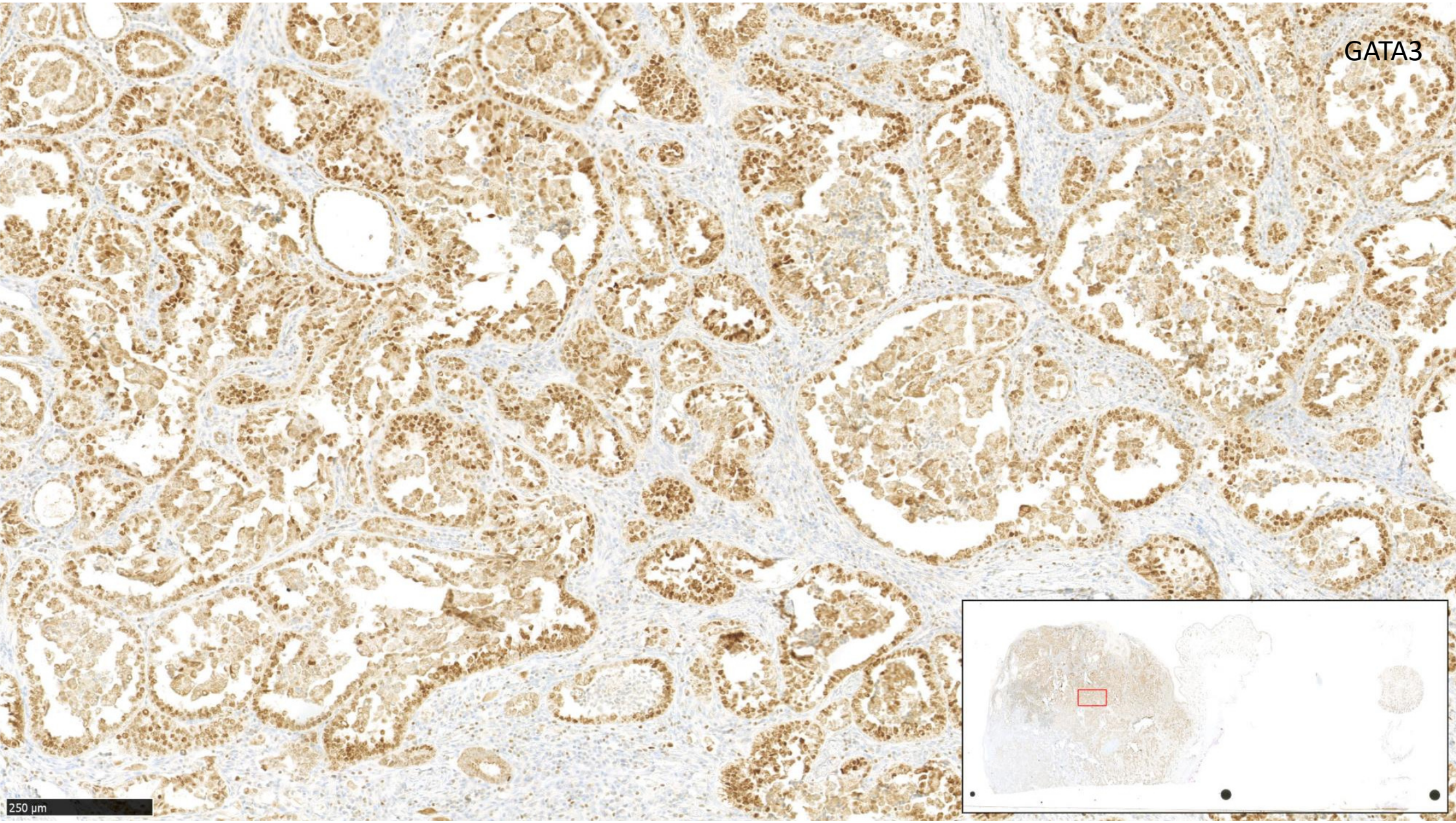
GATA3
250 µm

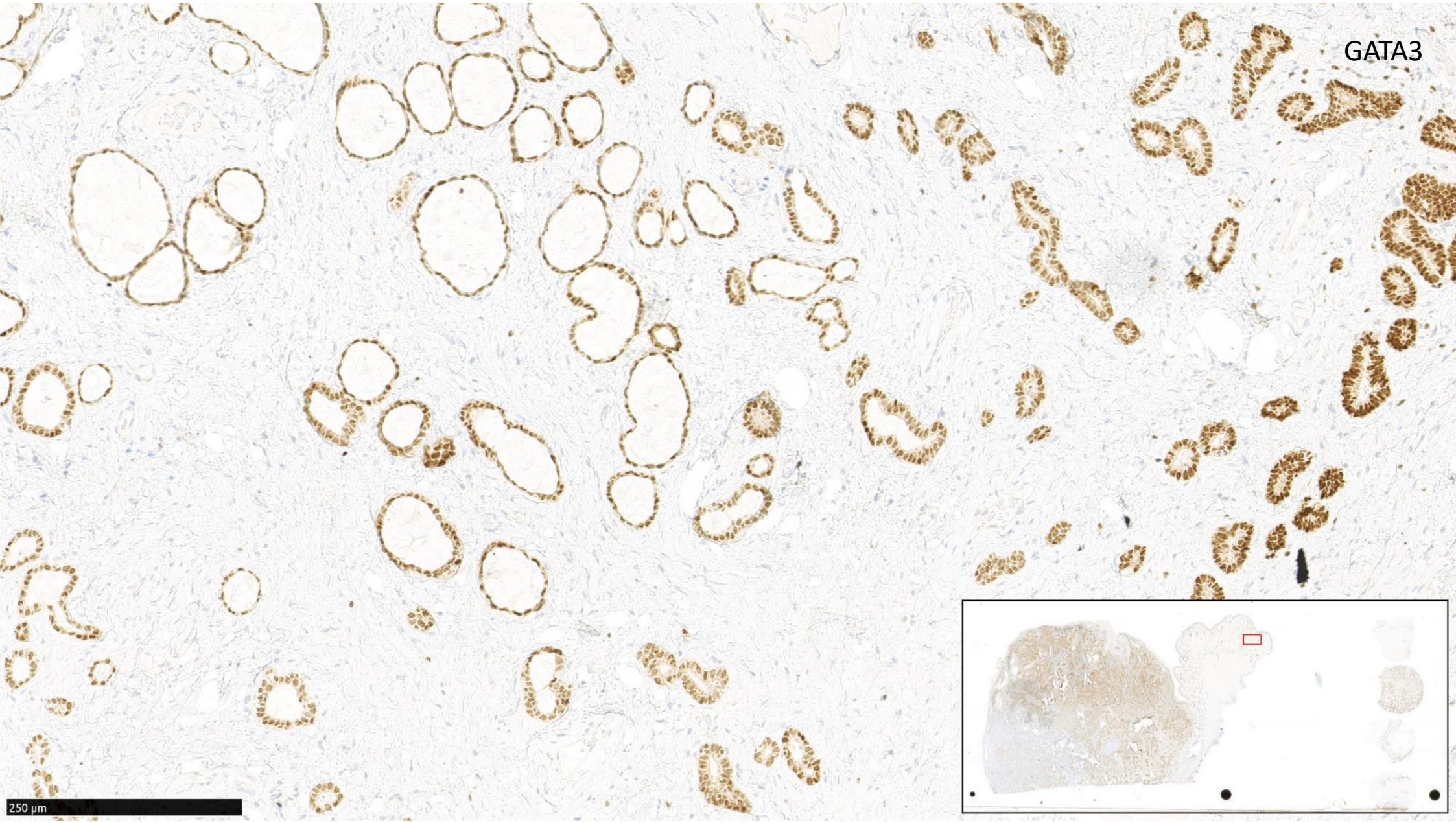
GATA3
250 µm


p53
2.5 mm

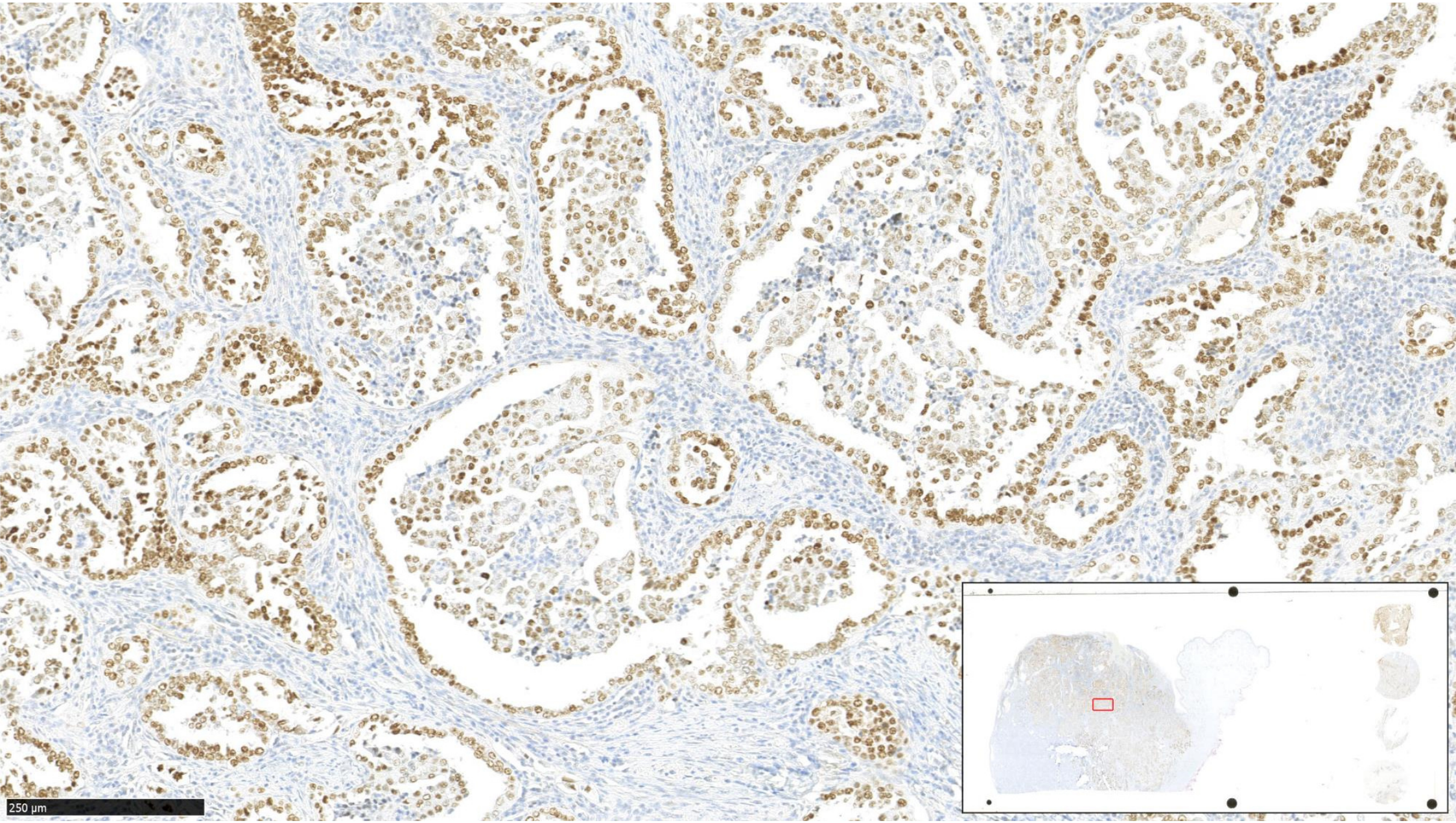
250 µm

Diagnosis

Mesonephric Carcinoma of the Cervix

Mesonephric Lesions of the Cervix

- Mesonephric duct remnants
- Mesonephric hyperplasia
  - Lobular
  - Diffuse
- Mesonephric carcinoma
- Malignant mixed mesonephric tumour

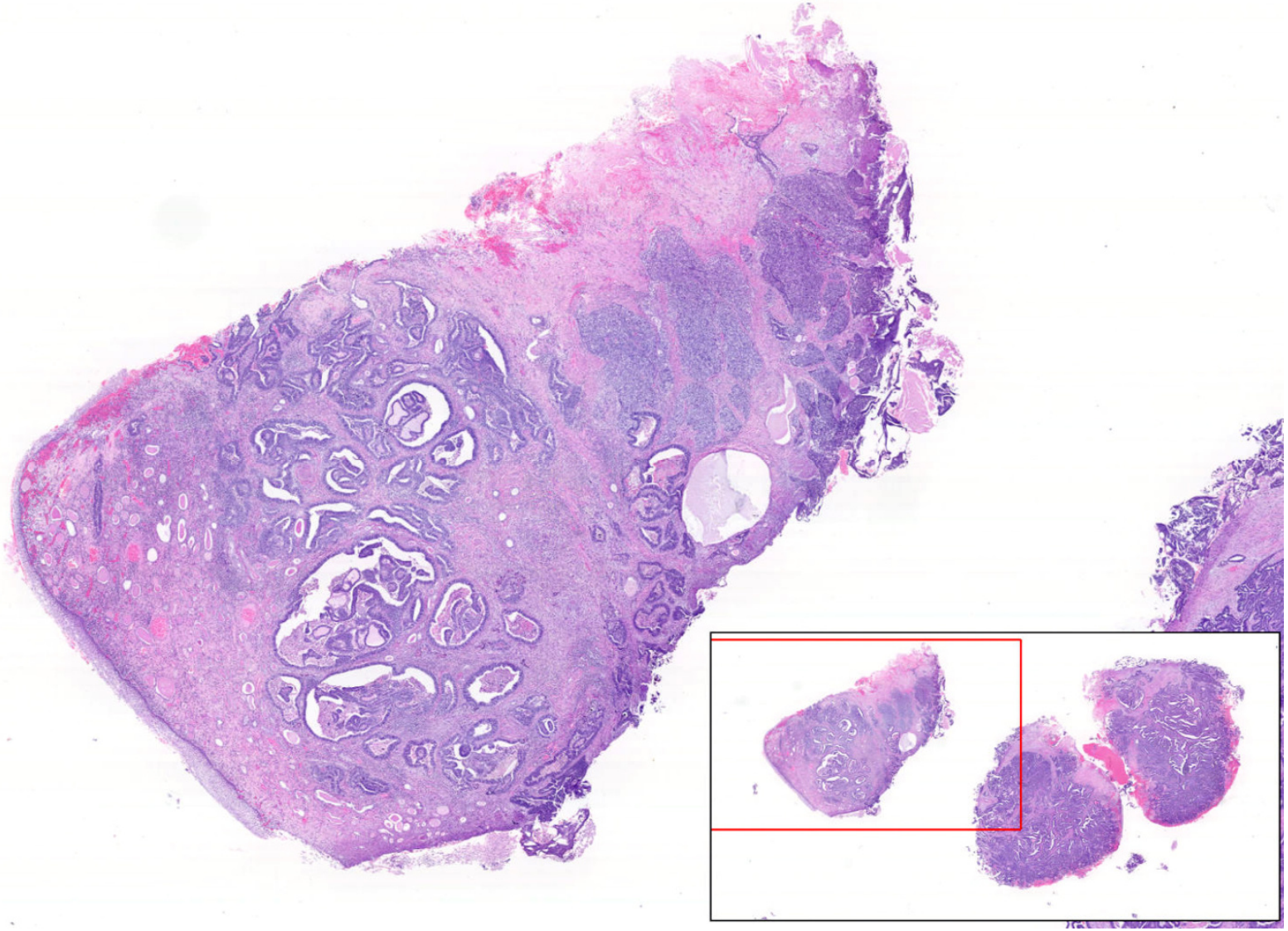

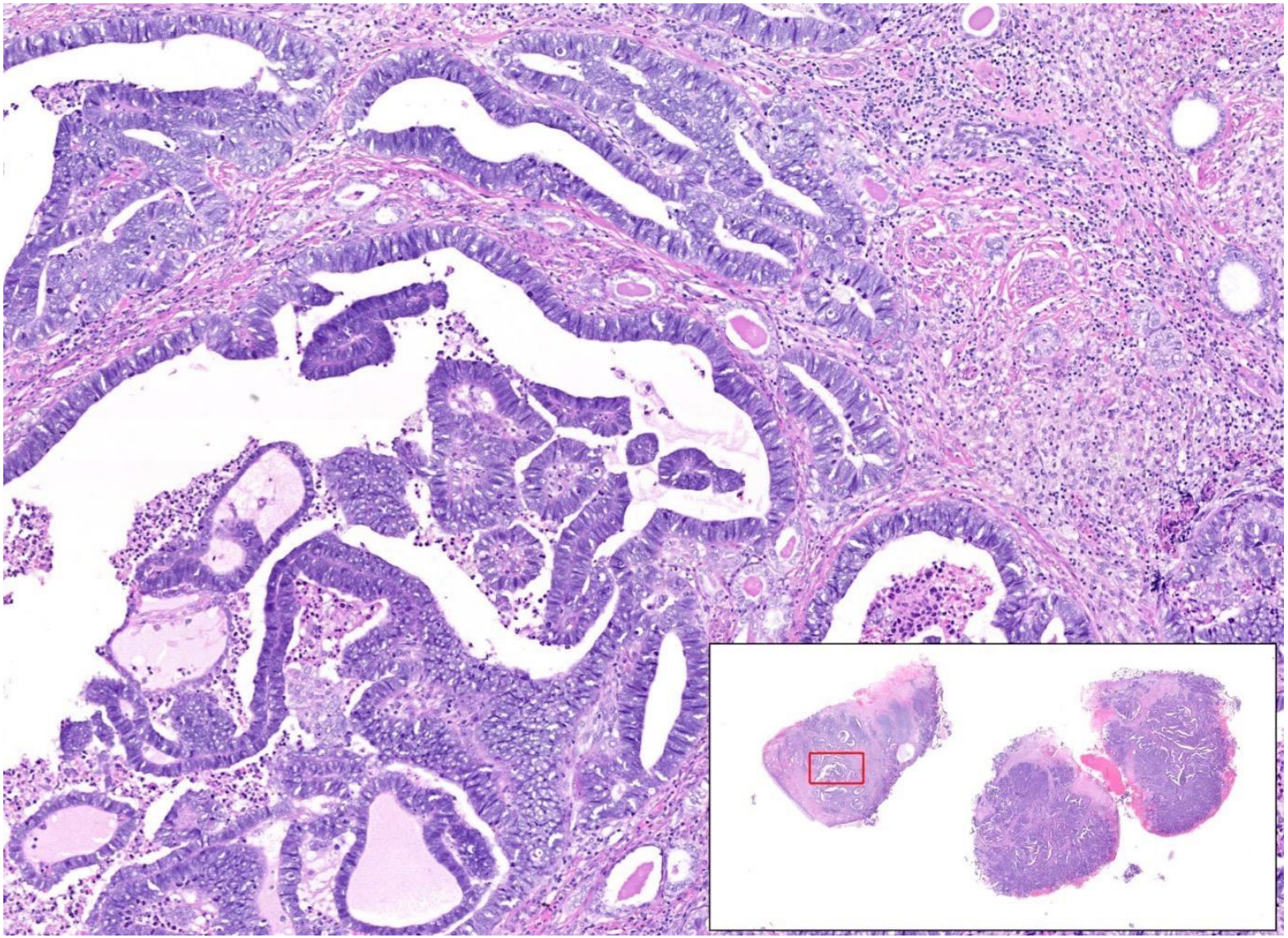

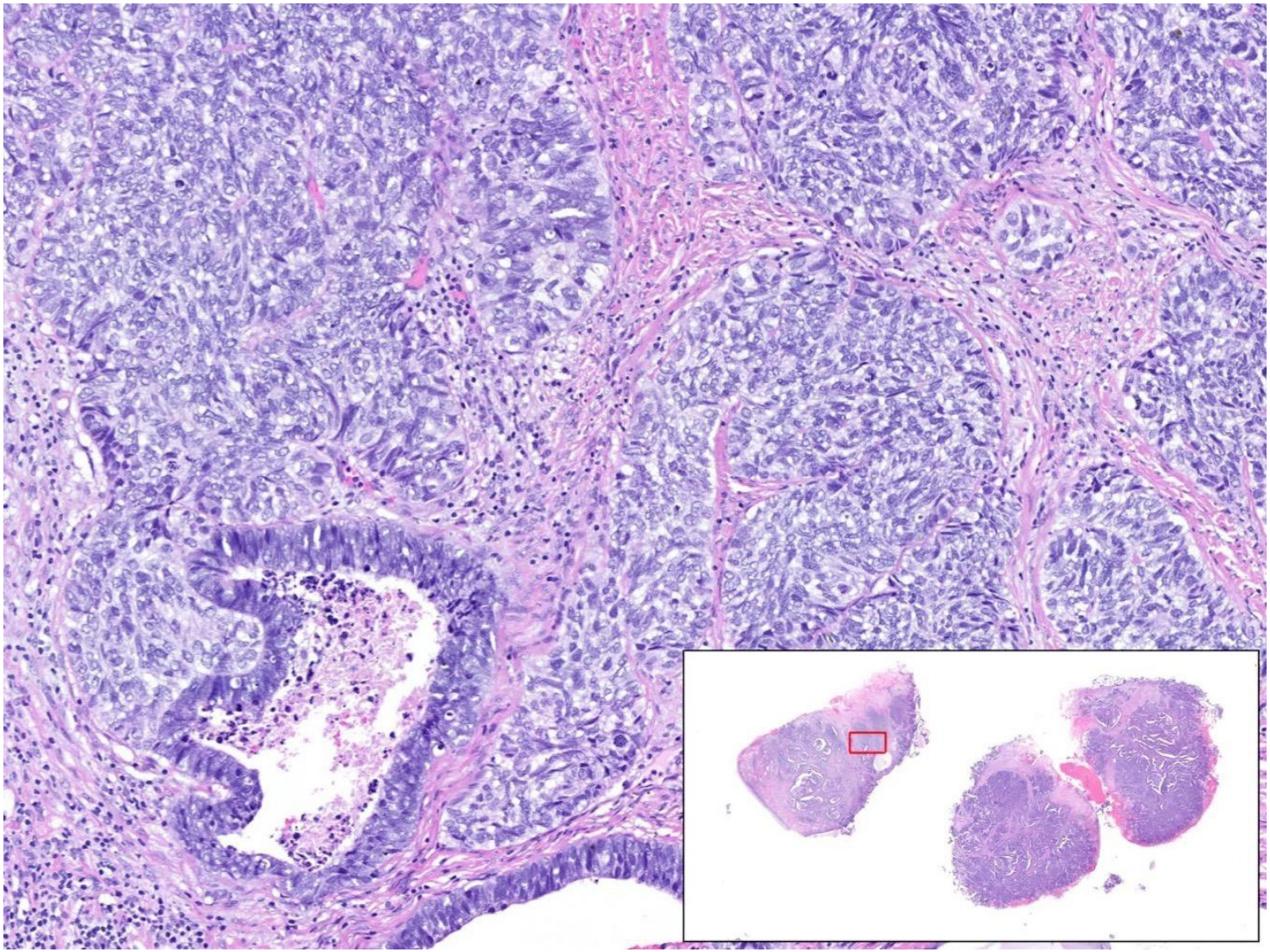

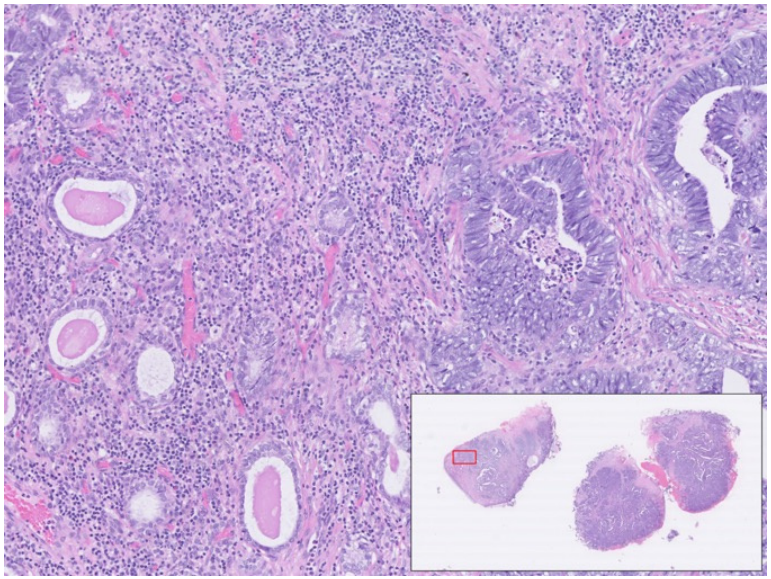

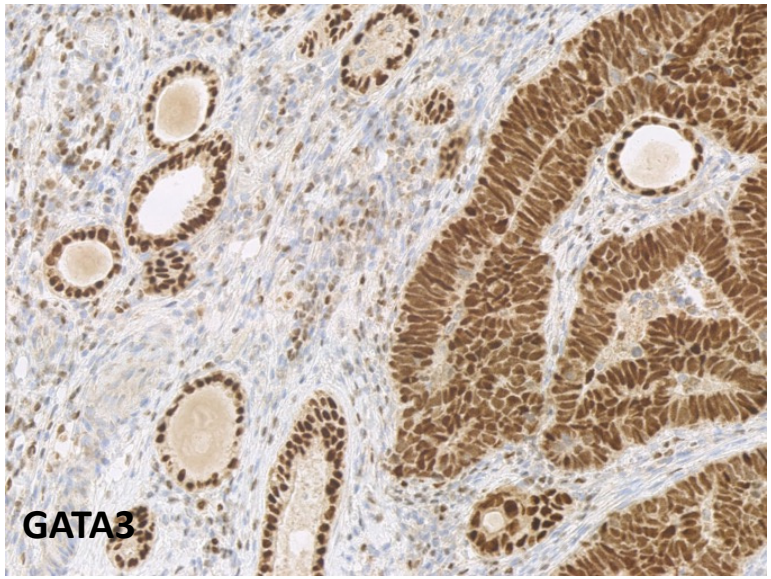
GATA3

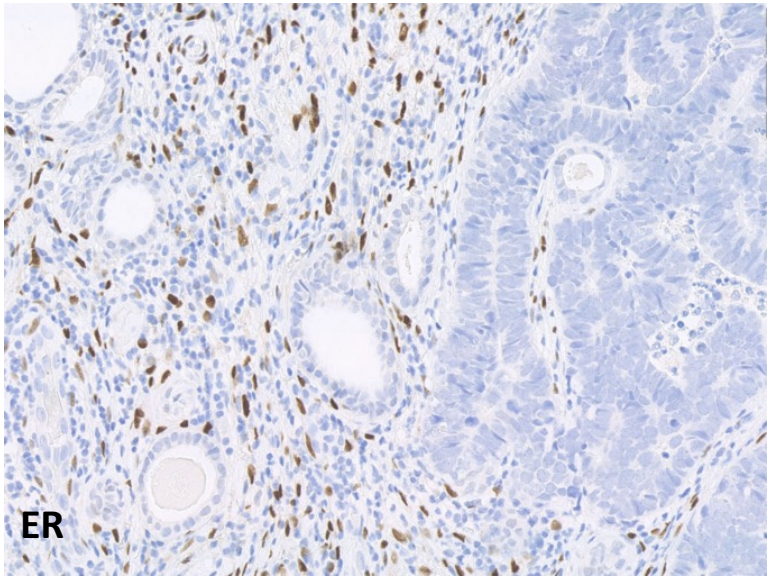
ER

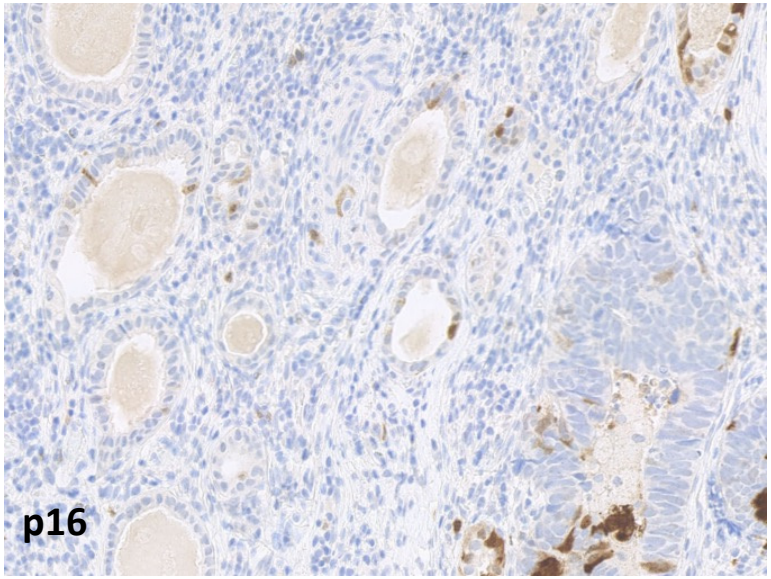
p16

Mesonephric Carcinoma with Glandular and Solid Elements

Mesonephric Lesions of the Cervix

- GATA3 positive
  - But 20% (23/113) carcinoarcomas also stained
- Calretinin, CD10 and p16 less useful
- Typically TTF1 negative

Howitt BE et al Am J Surg Pathol 2015; 39: 1411-9
Roma AA et al Int J Gynecol Pathol 2015; 34: 480-6
Pors et al Am J Surg Path 2018; 42: 1596-1606

Diagnosis

Mesonephric Carcinoma of the Cervix