

Benign Lesions of the Cervix

THE UNIVERSITY of EDINBURGH

Simon Herrington
Professor of Pathology
Consultant Pathologist

Outline

- Benign squamous lesions
- Benign glandular lesions
- Mesenchymal lesions
- Inflammatory lesions

WHO Classification of tumours of the uterine cervix

Epithelial tumours	
Squamous cell tumours and precursors	
Squamous intraepithelial lesions	
Low-grade squamous intraepithelial lesion	8077/0
High-grade squamous intraepithelial lesion	8077/2
Squamous cell carcinoma, NOS	8070/3
Keratinizing	8071/3
Non-keratinizing	8072/3
Papillary	8052/3
Basaloid	8083/3
Warty	8051/3
Verrucous	8051/3
Squamotransitional	8120/3
Lymphoepithelioma-like	8082/3
Benign squamous cell lesions	
Squamous metaplasia	
Condyloma acuminatum	
Squamous papilloma	8052/0
Transitional metaplasia	
Glandular tumours and precursors	
Adenocarcinoma in situ	8140/2
Adenocarcinoma	8140/3
Endocervical adenocarcinoma, usual type	8140/3
Mucinous carcinoma, NOS	8480/3
Gastric type	8482/3
Intestinal type	8144/3
Signet-ring cell type	8490/3
Villoglandular carcinoma	8263/3
Endometrioid carcinoma	8380/3
Clear cell carcinoma	8310/3
Serous carcinoma	8441/3
Mesonephric carcinoma	9110/3
Adenocarcinoma admixed with neuroendocrine carcinoma	8574/3
Benign glandular tumours and tumour-like lesions	
Endocervical polyp	
Müllerian papilloma	
Nabothian cyst	
Tunnel clusters	
Microglandular hyperplasia	
Lobular endocervical glandular hyperplasia	
Diffuse laminar endocervical hyperplasia	
Mesonephric remnants and hyperplasia	
Arias Stella reaction	
Endocervicosis	
Endometriosis	
Tuboendometrioid metaplasia	
Ectopic prostate tissue	
Other epithelial tumours	
Adenosquamous carcinoma	8560/3
Glassy cell carcinoma	8015/3
Adenoid basal carcinoma	8098/3
Adenoid cystic carcinoma	8200/3
Undifferentiated carcinoma	8020/3
Neuroendocrine tumours	
Low-grade neuroendocrine tumour	
Carcinoid tumour	8240/3
Atypical carcinoid tumour	8249/3
High-grade neuroendocrine carcinoma	
Small cell neuroendocrine carcinoma	8041/3
Large cell neuroendocrine carcinoma	8013/3
Mesenchymal tumours and tumour-like lesions	
Benign	
Leiomyoma	8890/0
Rhabdomyoma	8905/0
Others	
Malignant	
Leiomyosarcoma	8890/3
Rhabdomyosarcoma	8910/3
Alveolar soft-part sarcoma	9581/3
Angiosarcoma	9120/3
Malignant peripheral nerve sheath tumour	9540/3
Other sarcomas	
Liposarcoma	8850/3
Undifferentiated endocervical sarcoma	8805/3
Ewing sarcoma	9364/3
Tumour-like lesions	
Postoperative spindle-cell nodule	
Lymphoma-like lesion	
Mixed epithelial and mesenchymal tumours	
Adenomyoma	8932/0
Adenosarcoma	8933/3
Carcinosarcoma	8980/3
Melanocytic tumours	
Blue naevus	8780/0
Malignant melanoma	8720/3
Germ cell tumour	
Yolk sac tumour	
Lymphoid and myeloid tumours	
Lymphomas	
Myeloid neoplasms	
Secondary tumours	

[a] The morphology codes are from the International Classification of Diseases for Oncology (ICD-O) {463B}. Behaviour is coded /0 for benign tumours, /1 for unspecified, borderline or uncertain behaviour, /2 for carcinoma in situ and grade III intraepithelial neoplasia, and /3 for malignant tumours; [b] The classification is modified from the previous WHO histological classification of tumours {1413} taking into account changes in our understanding of these lesions. In the case of neuroendocrine neoplasms, the classification has been simplified to be of more practical utility in morphological classification; * These new codes were approved by the IARC/WHO Committee for ICD-O.

Benign Squamous Lesions

- Squamous metaplasia
- Condyloma acuminatum (including squamous papilloma)
- Atrophic changes (including ‘transitional metaplasia’)

Human Papillomaviruses

- Non-enveloped, double-stranded DNA viruses
- 8 kb circular genome
- At least 200 genotypes
  - pave.niaid.nih.gov/

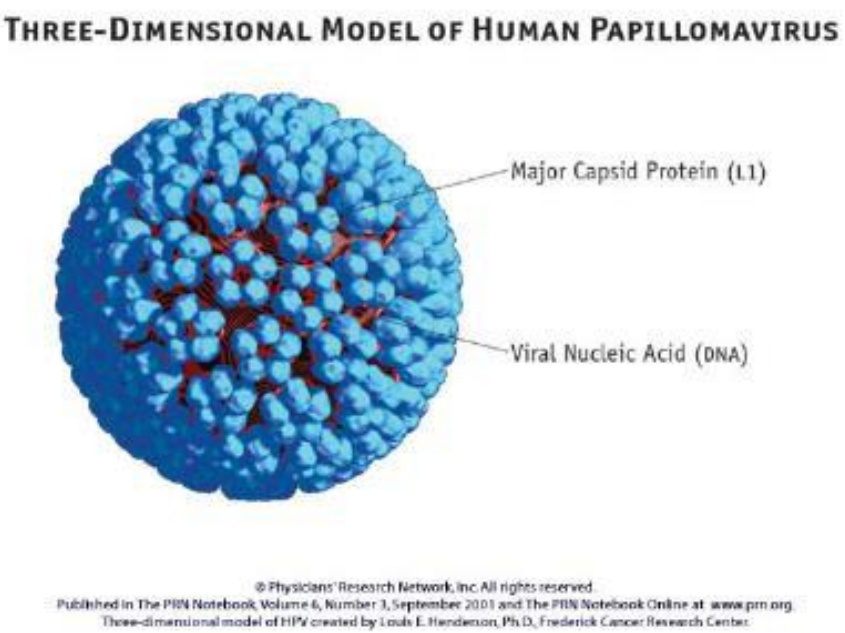

- Epitheliotropic
- High-risk vs low-risk HPV types
- Require squamous differentiation for replication

The Papillomavirus Life Cycle

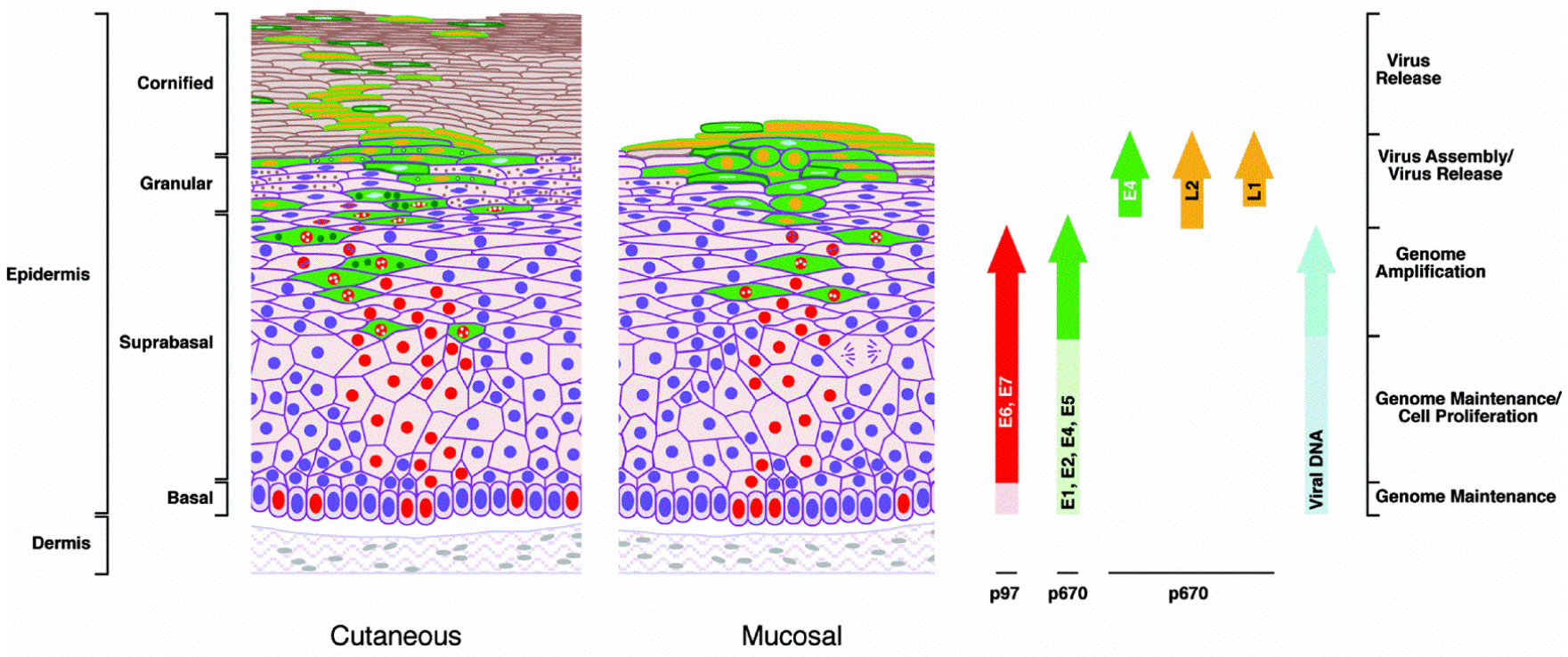

Doorbar J *Clin Sci* 2006;110:525-41

Cervical Lesion 1

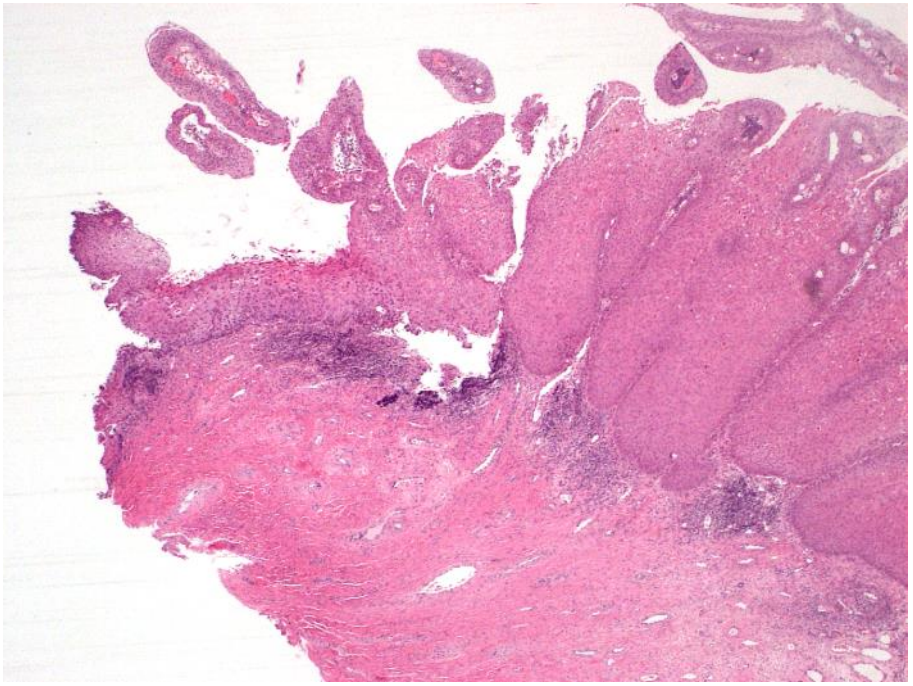

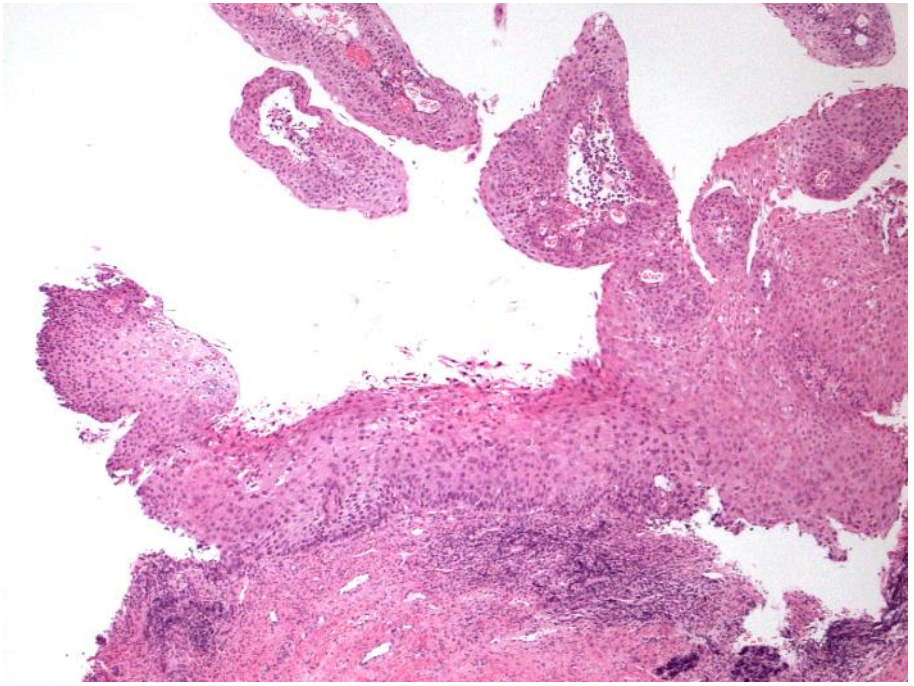

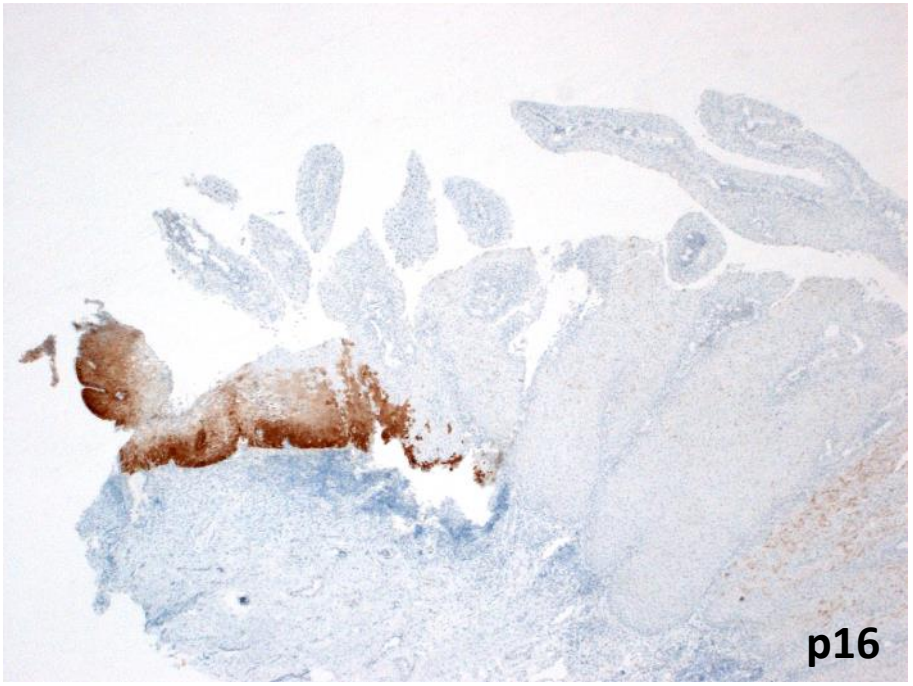
p16

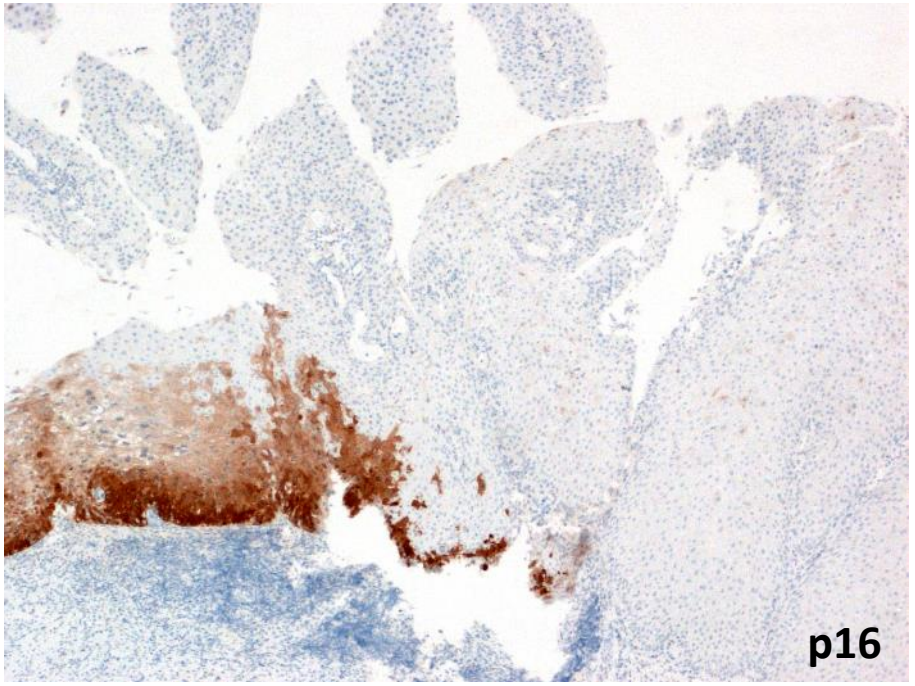
p16

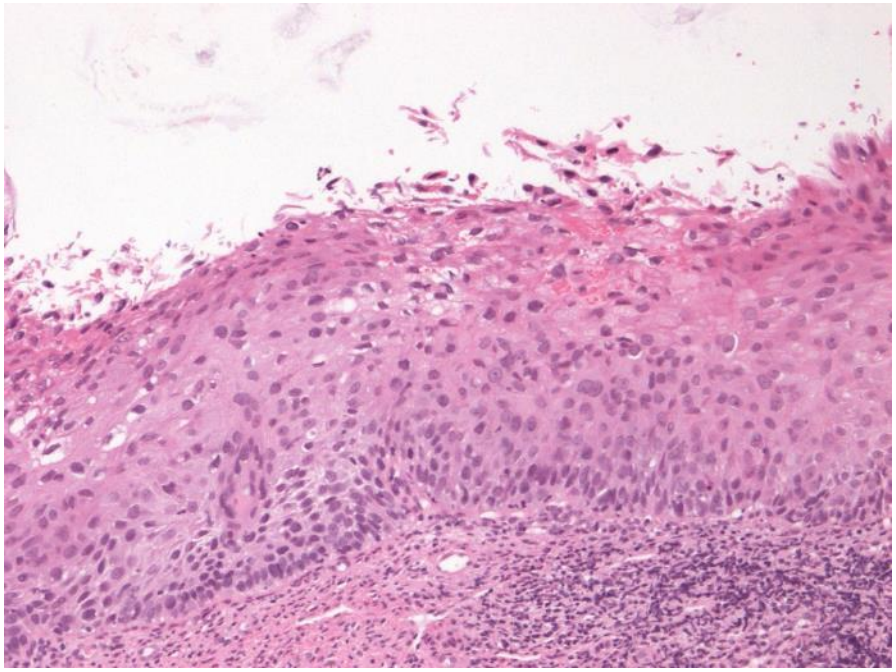

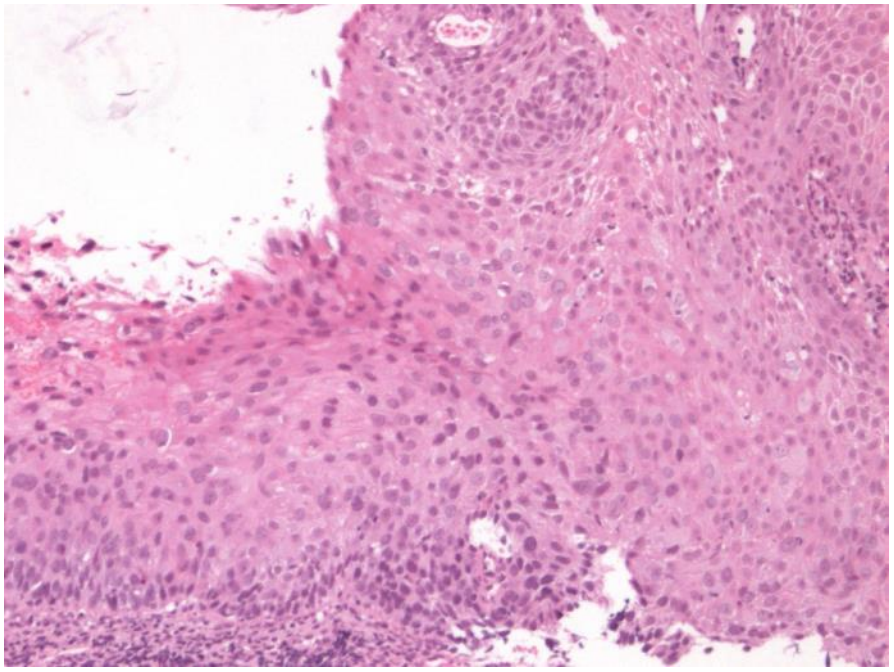

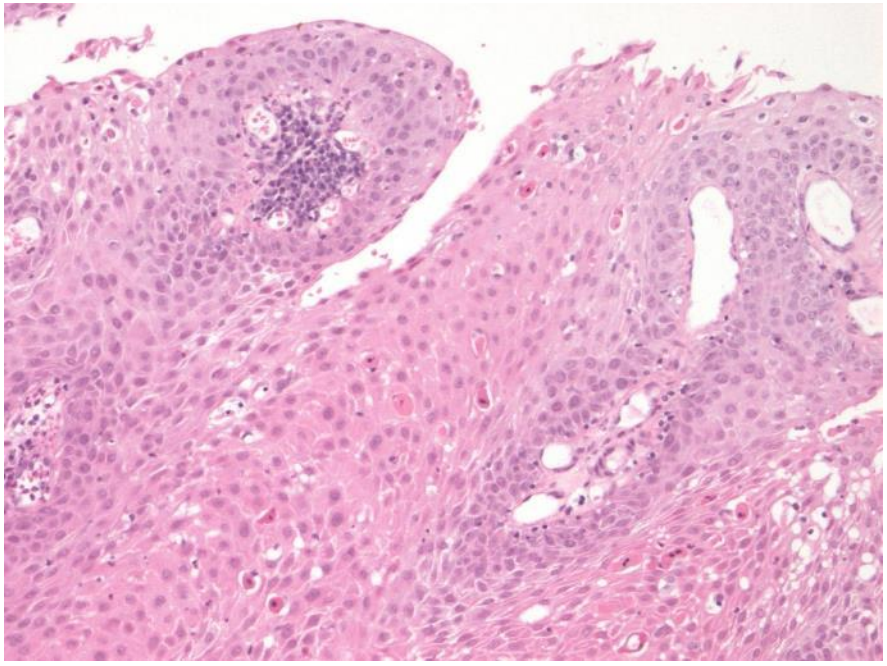

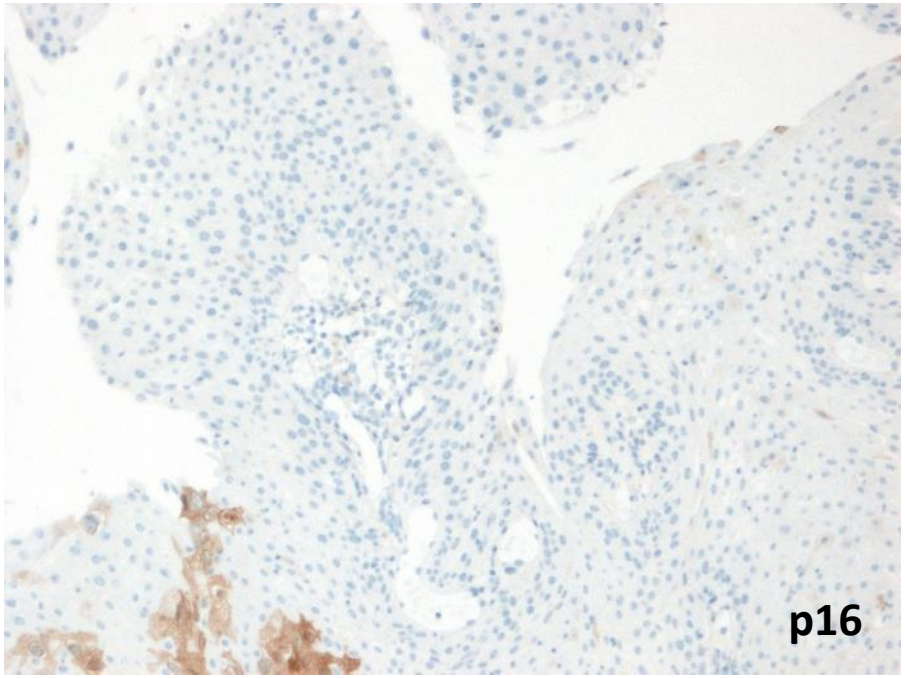
p16

Cervical Lesion 2

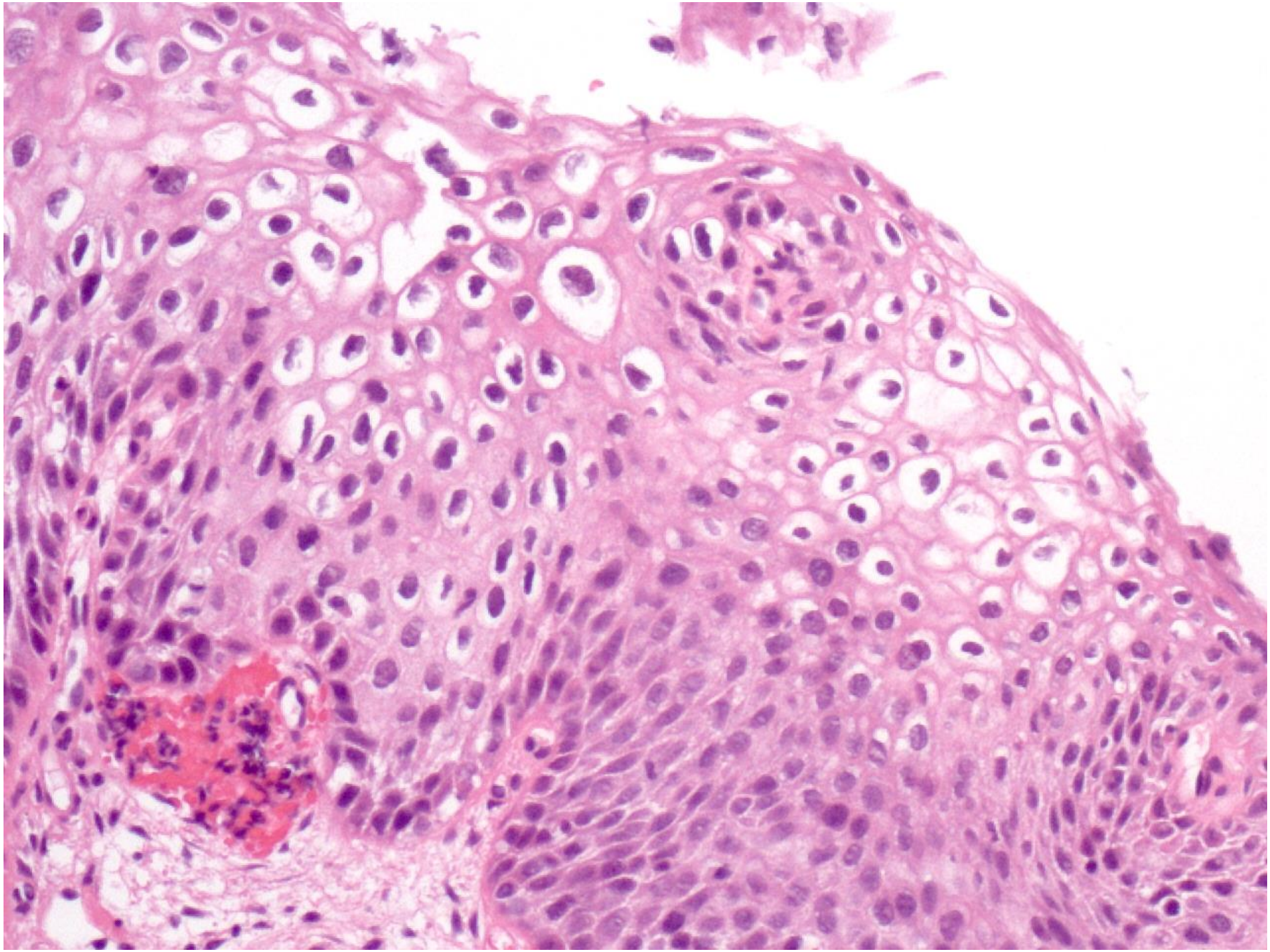

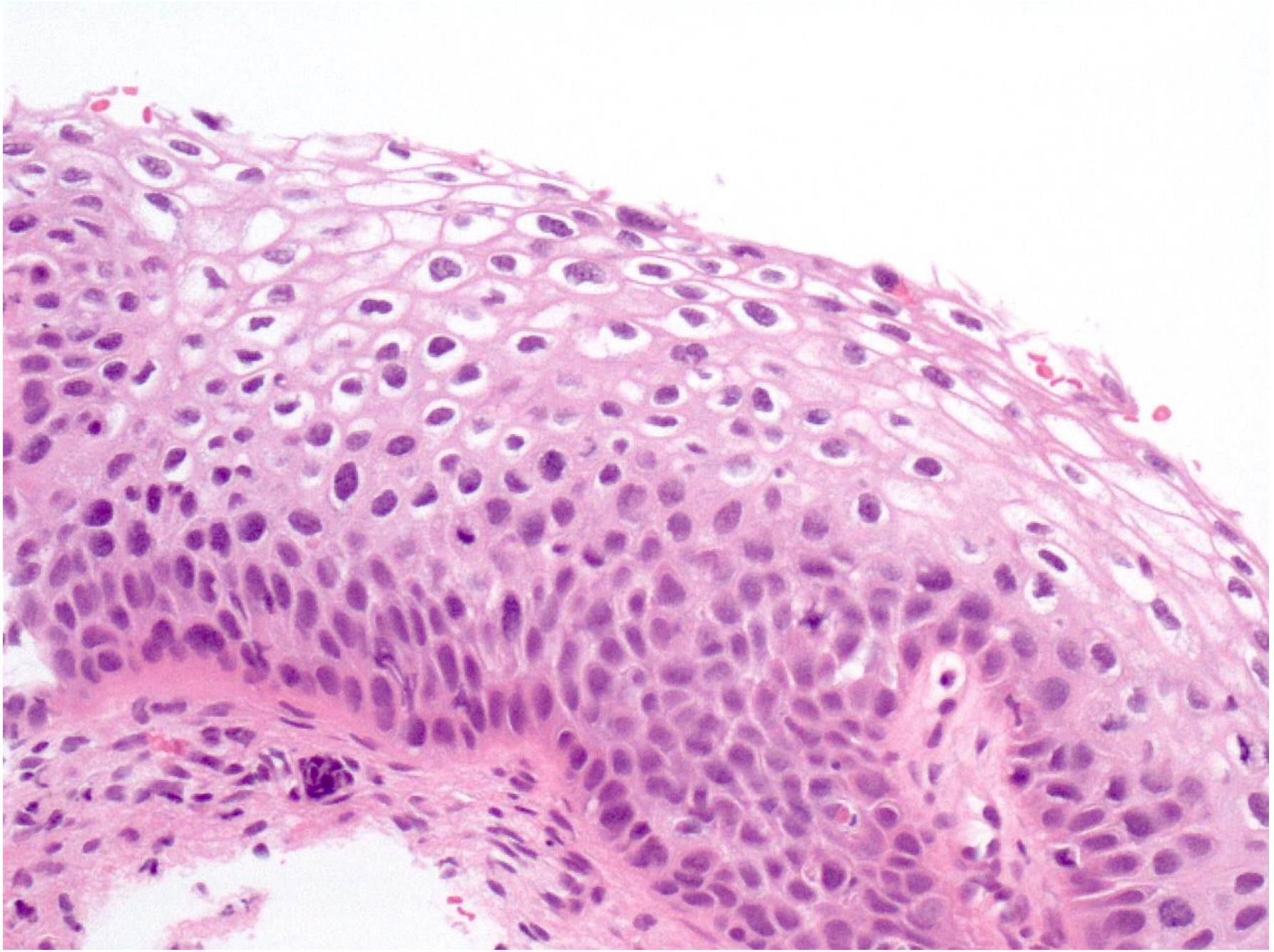

Cervical Lesion 3

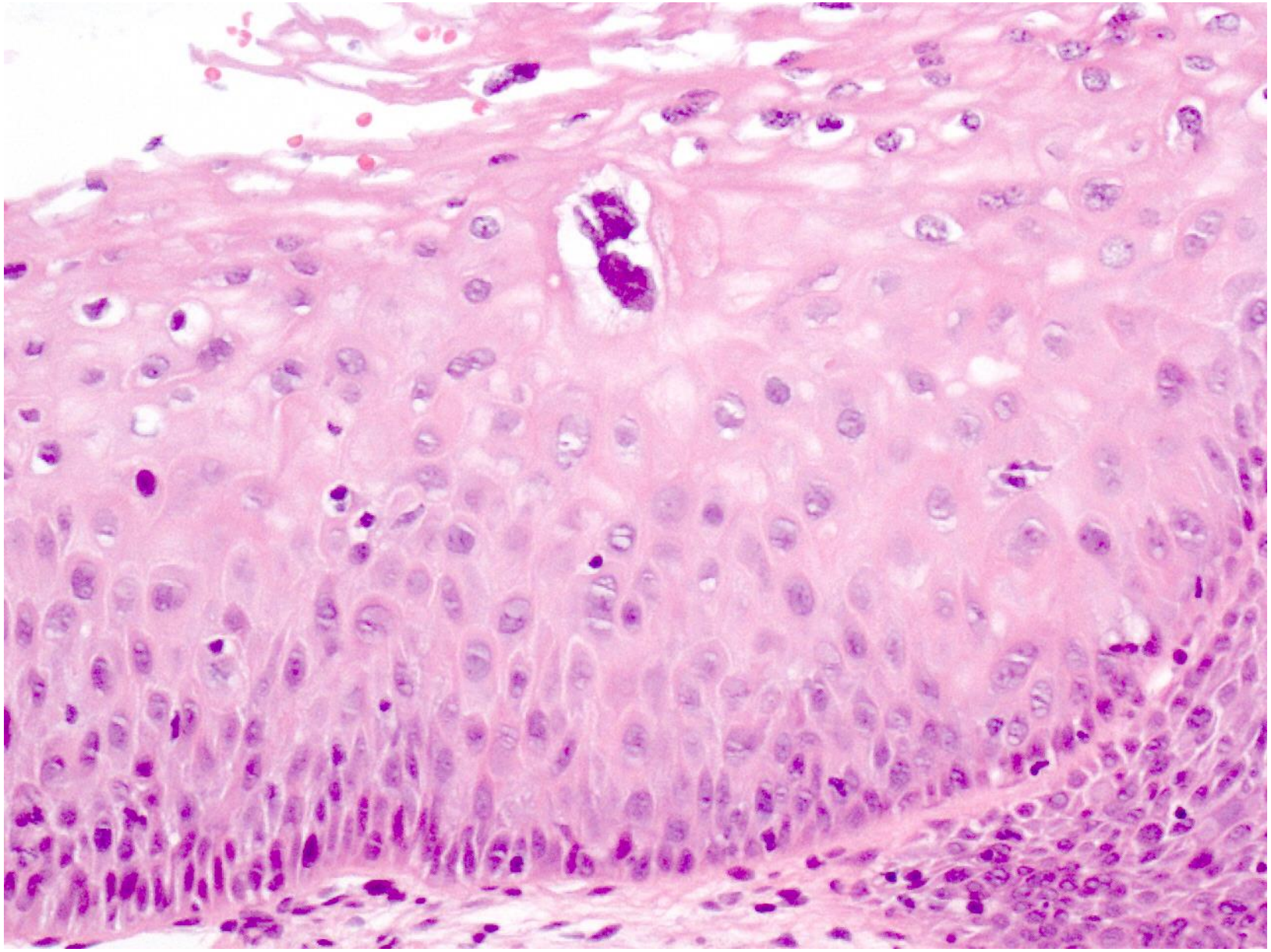

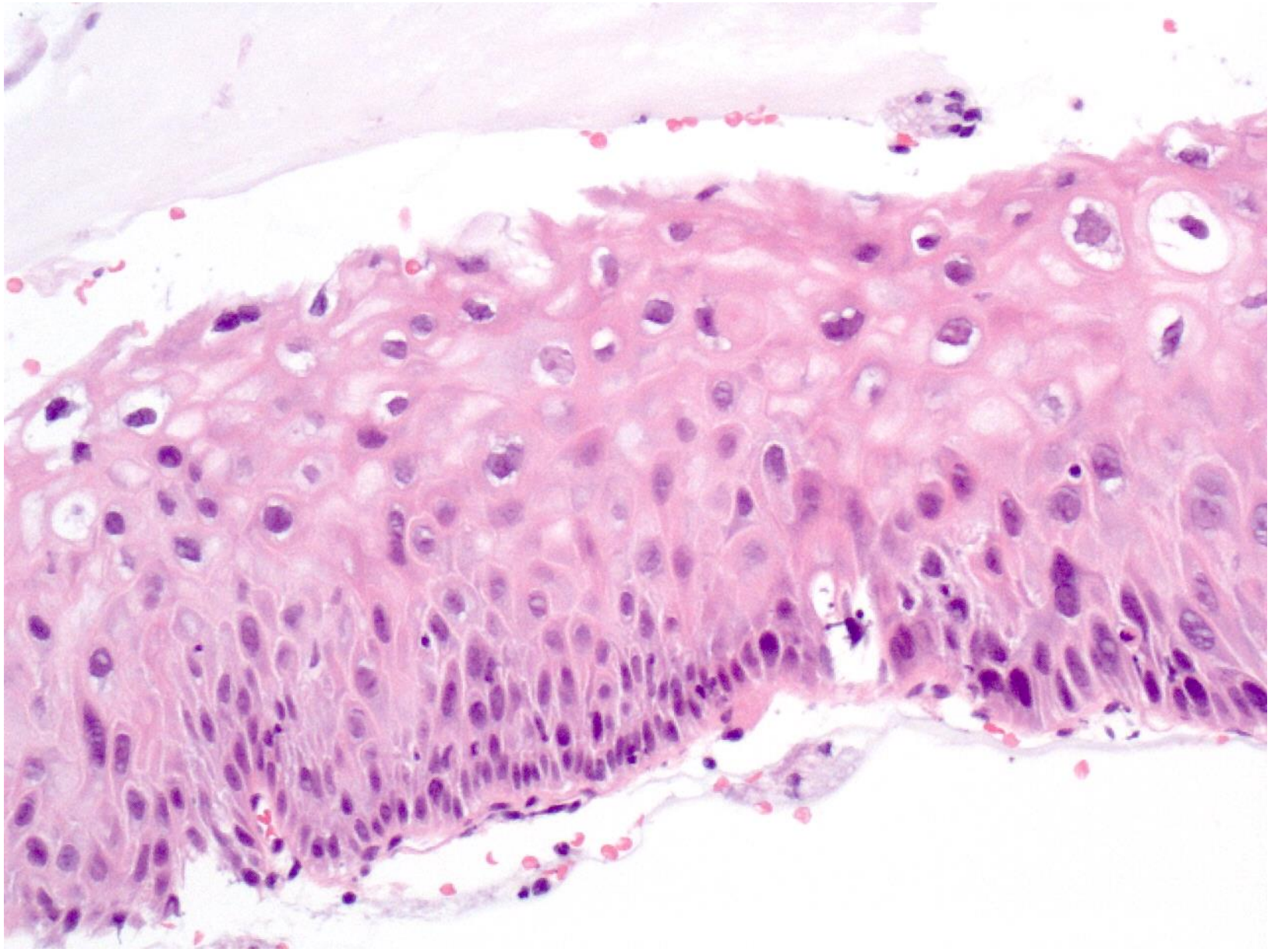

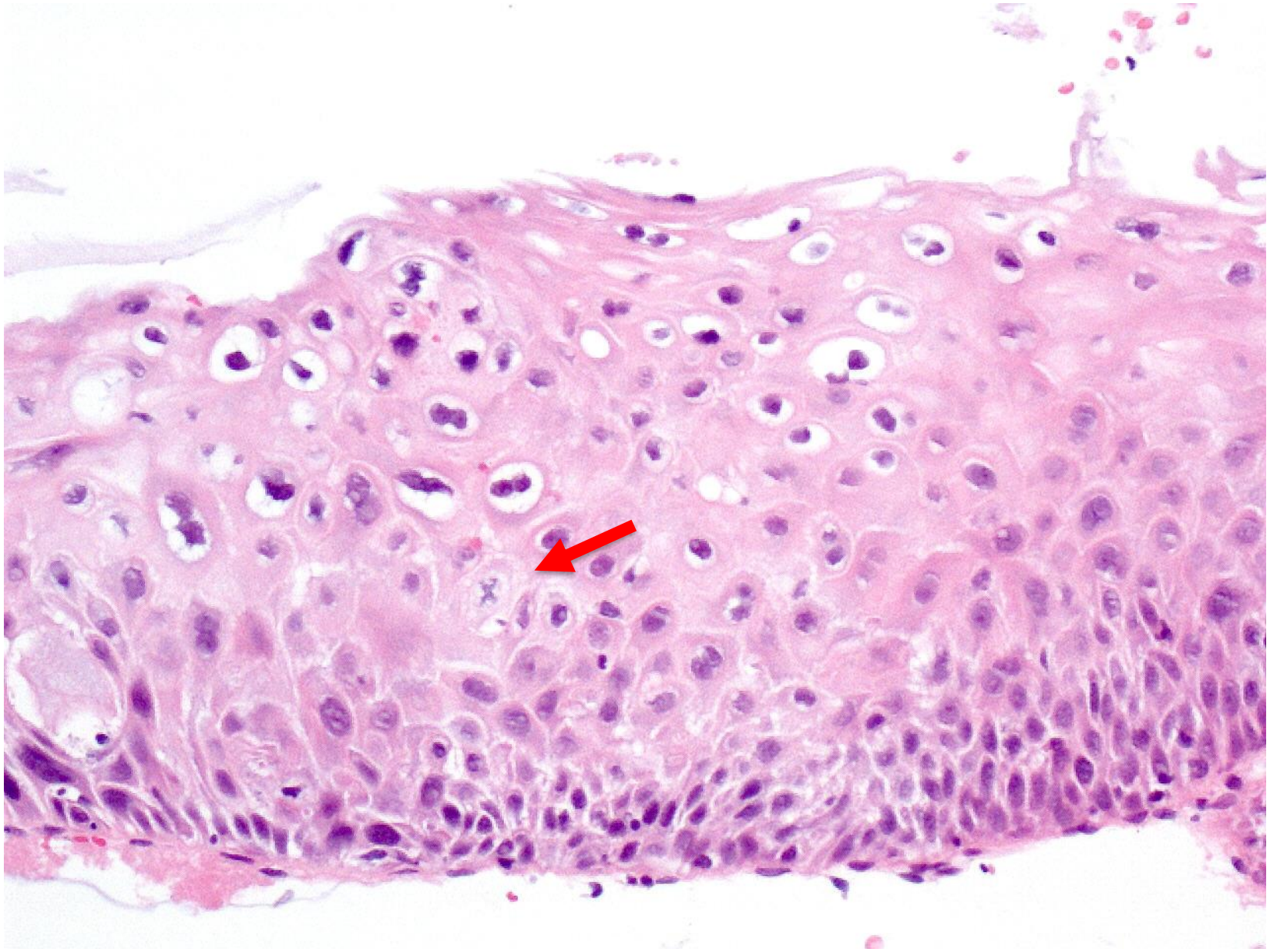

Vulval Lesion

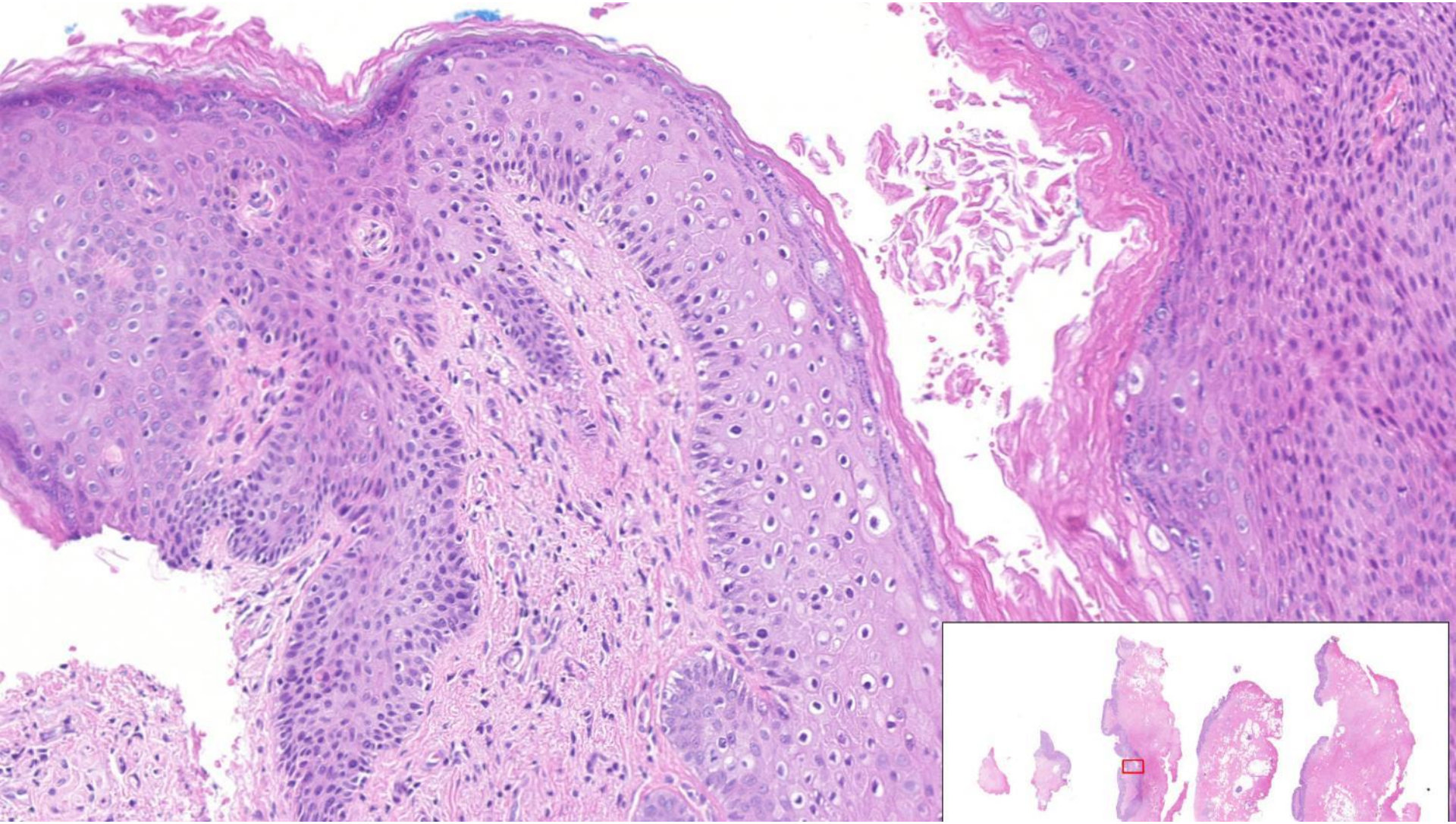

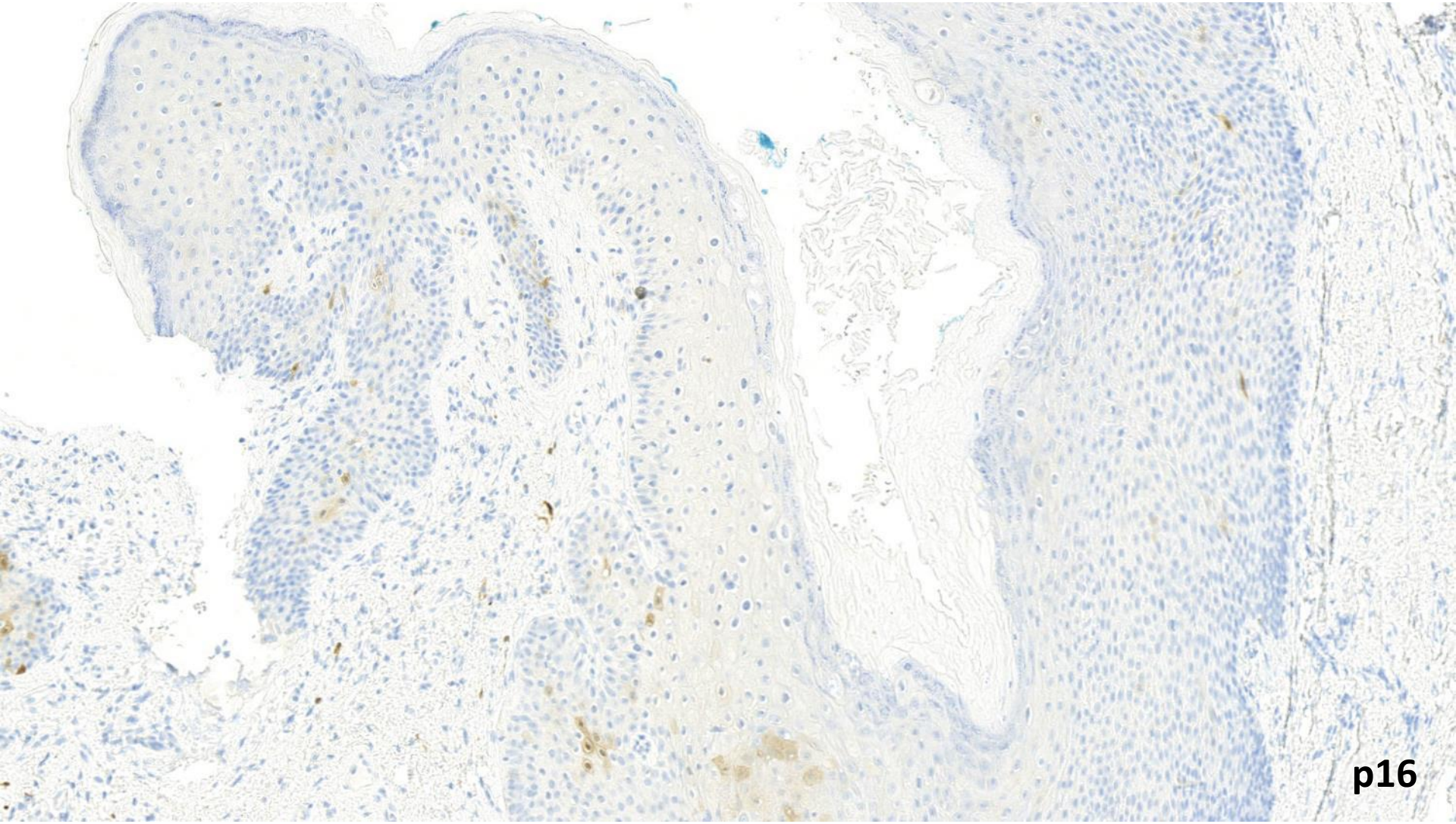
p16

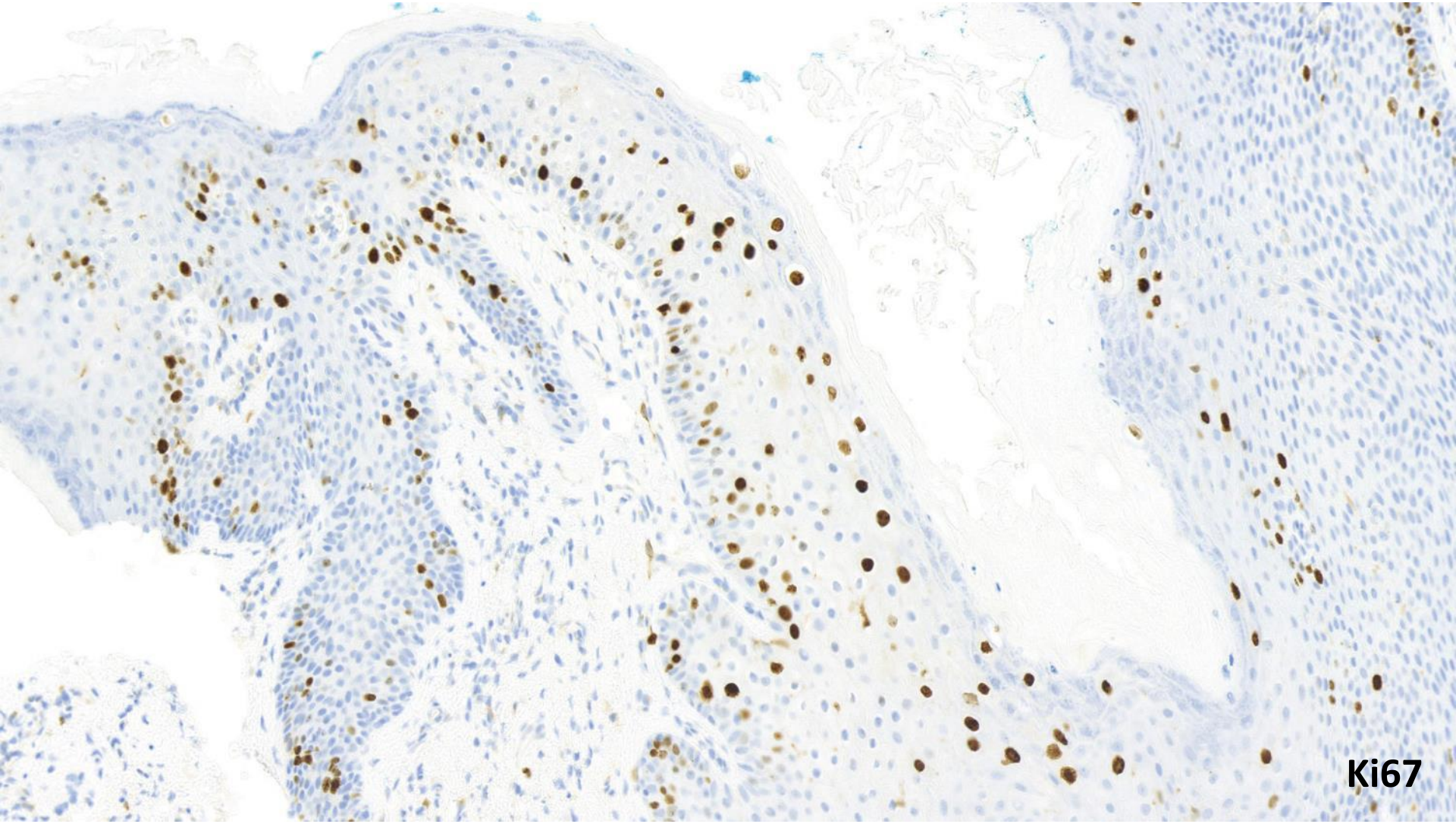
Ki67

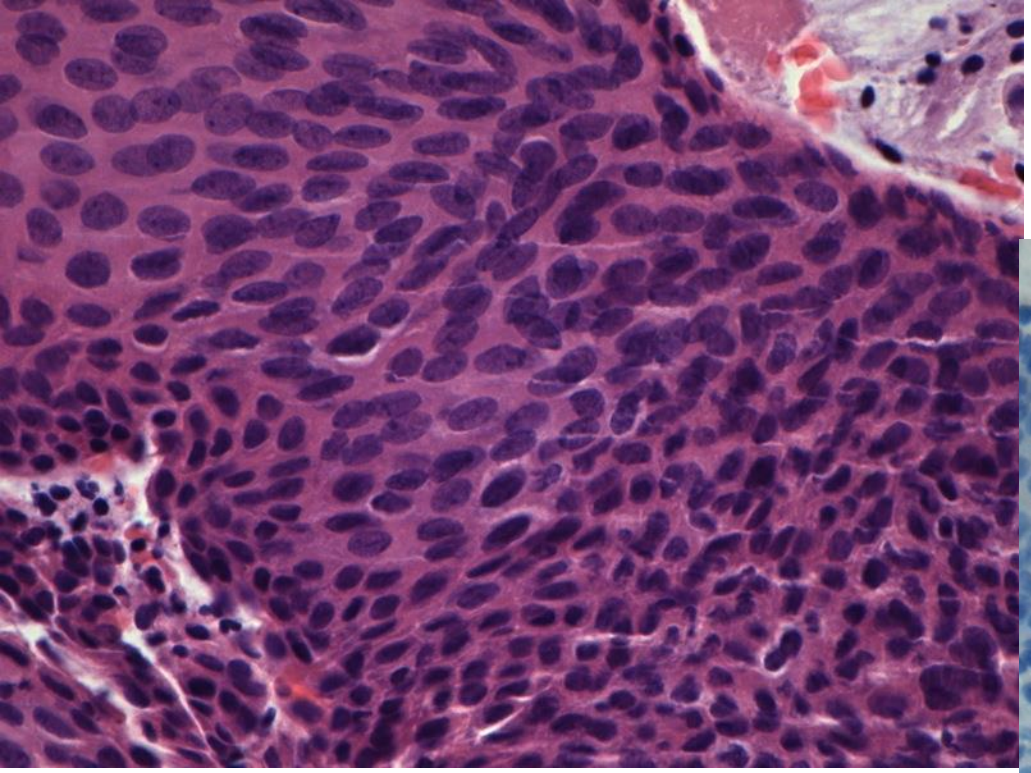

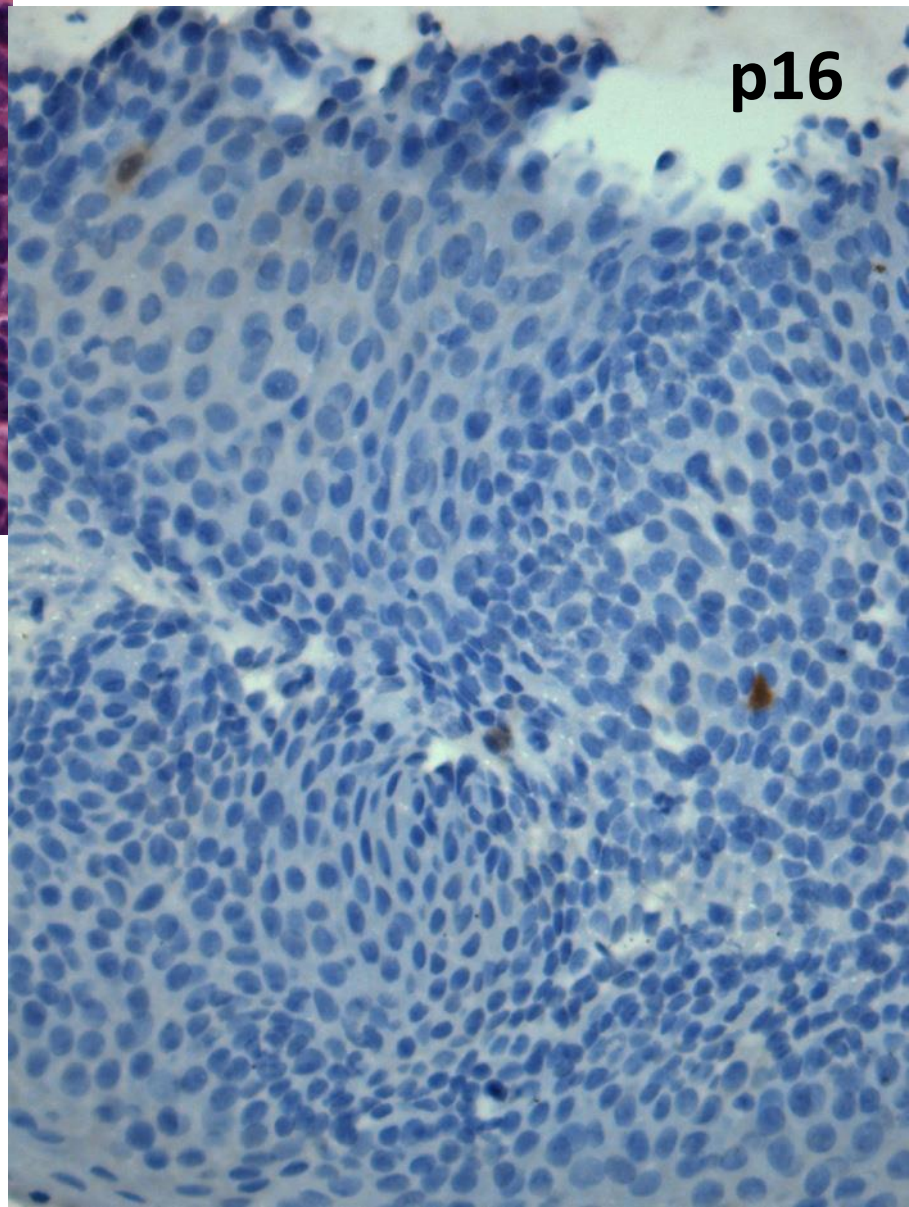

‘Transitional Metaplasia’

Benign Glandular Lesions

- Endocervical polyp
- Müllerian papilloma
- Nabothian cysts
- Tunnel clusters
- Lobular endocervical glandular hyperplasia (LEGH)
- Diffuse laminar endocervical hyperplasia
- Mesonephric remnants and hyperplasia
- Arias Stella reaction
- Endocervicosis
- Tuboendometrioid metaplasia
- Endometriosis
- Ectopic prostate tissue
- Microglandular hyperplasia

Case 1

- 58 year old female
- Hysterectomy for atypical endometrial hyperplasia
- Section from the upper endocervix

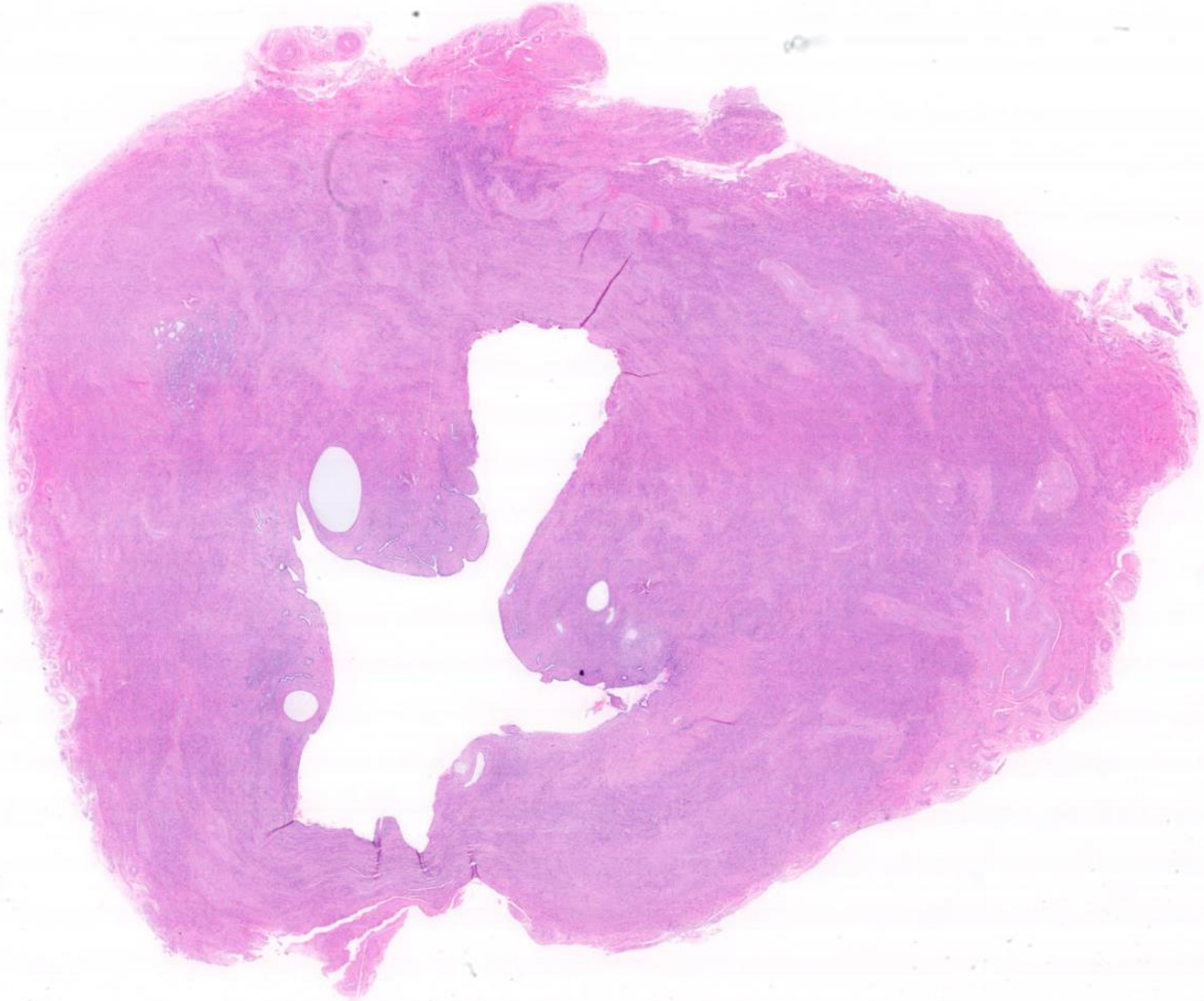

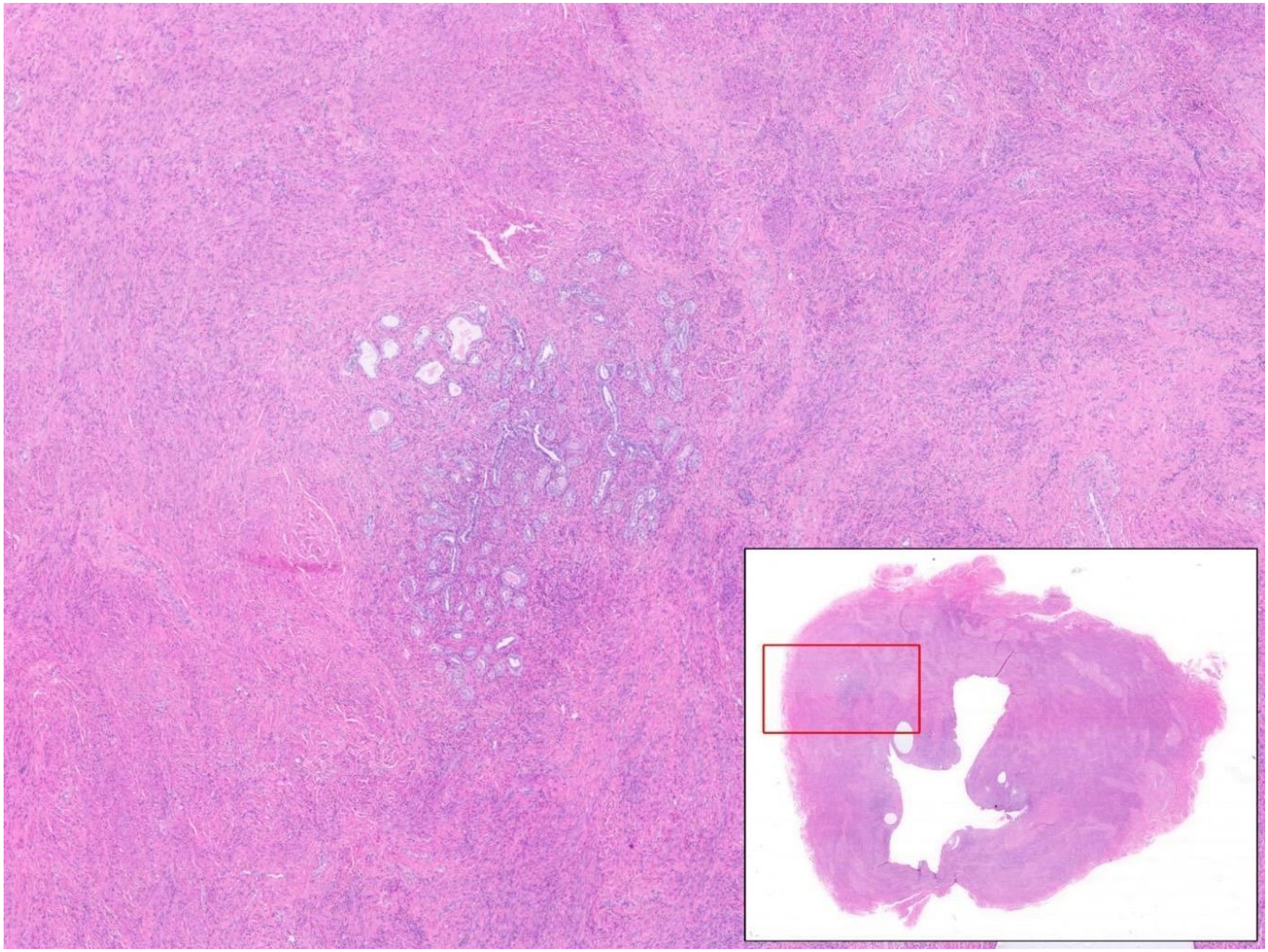

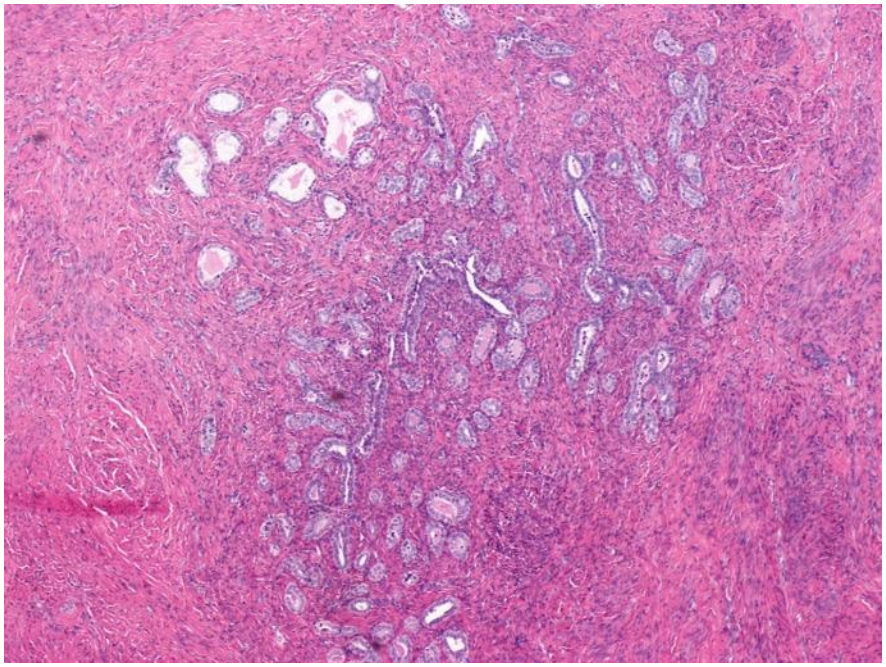

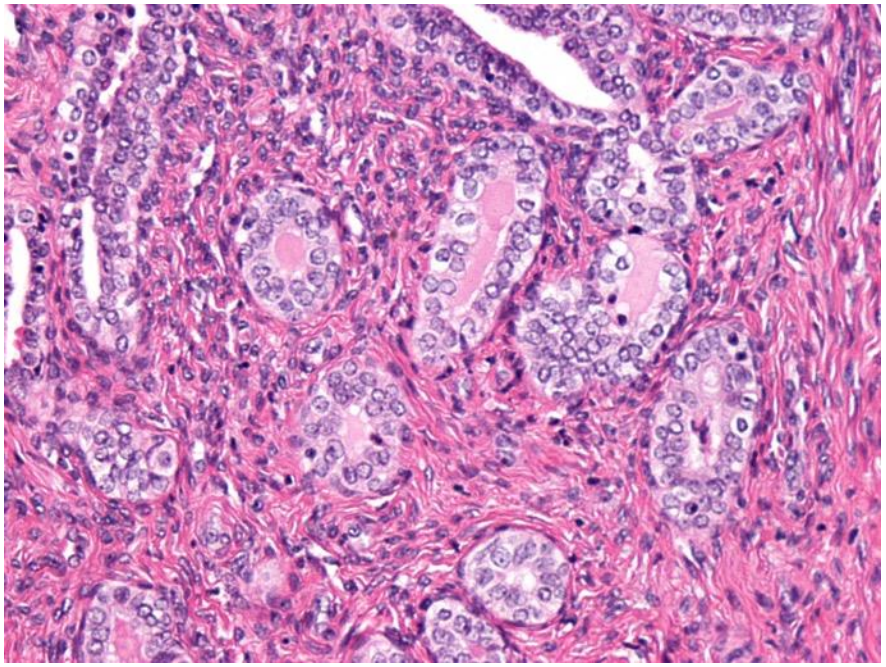

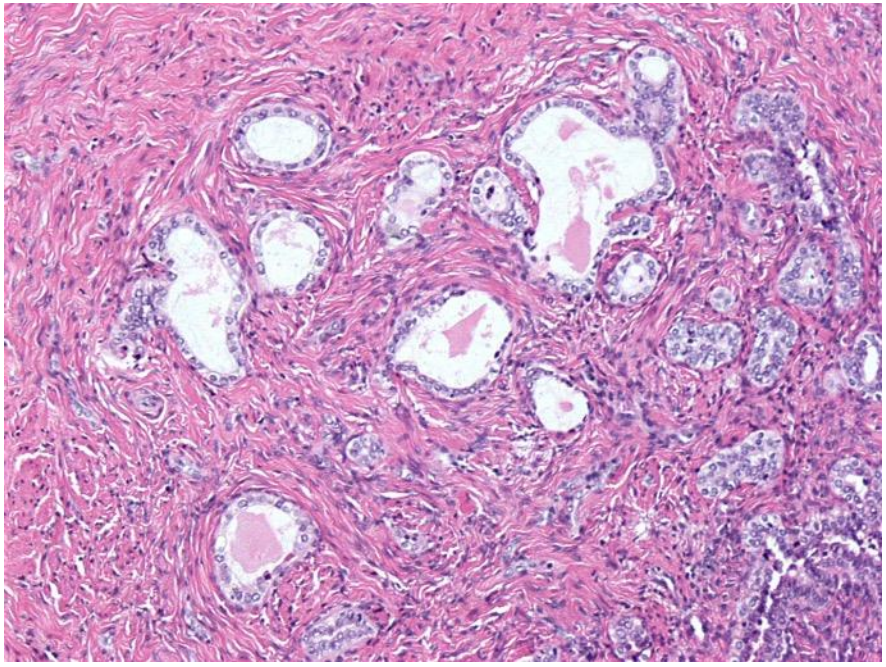

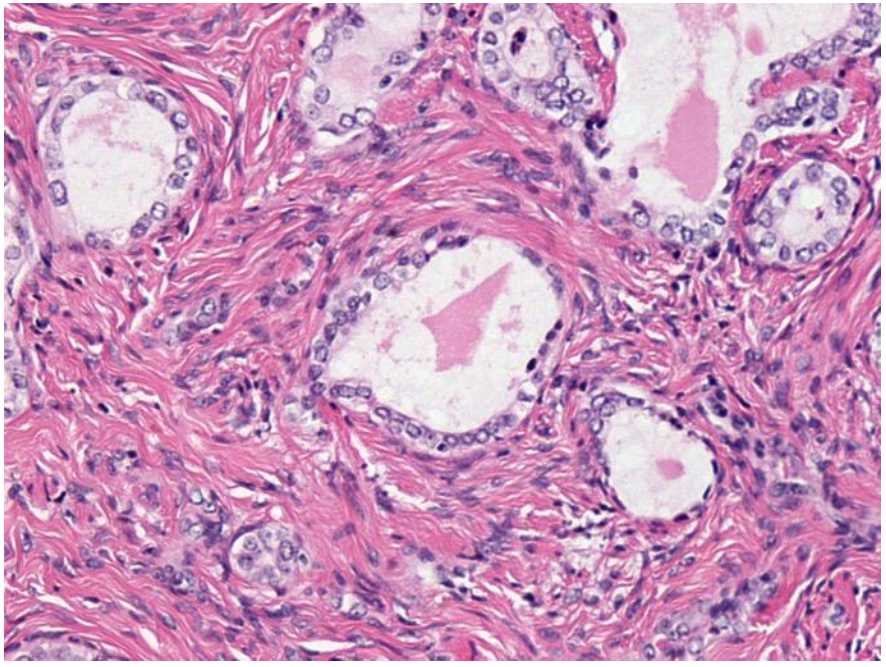

Diagnosis

Mesonephric Duct Remnants

Seidman JD & Tavassoli FA. Mesonephric hyperplasia of the uterine cervix: a clinicopathologic study of 51 cases. Int J Gynecol Pathol 1995; 14: 293-299

Case 2

- 21 year old female
- Superficially invasive cervical squamous cell carcinoma on previous biopsy
- Now 14 weeks pregnant
- Further excision

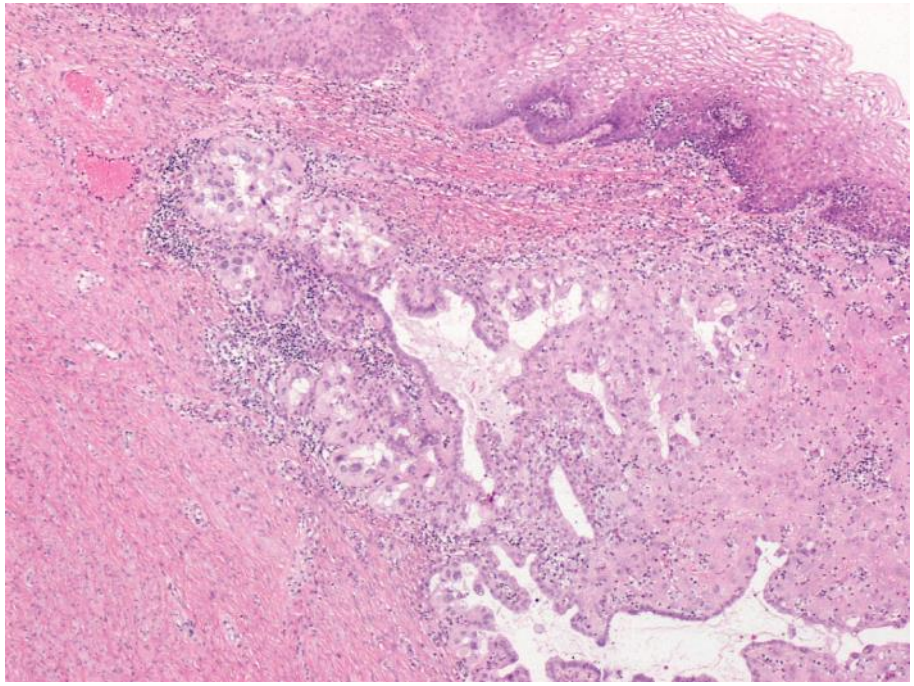
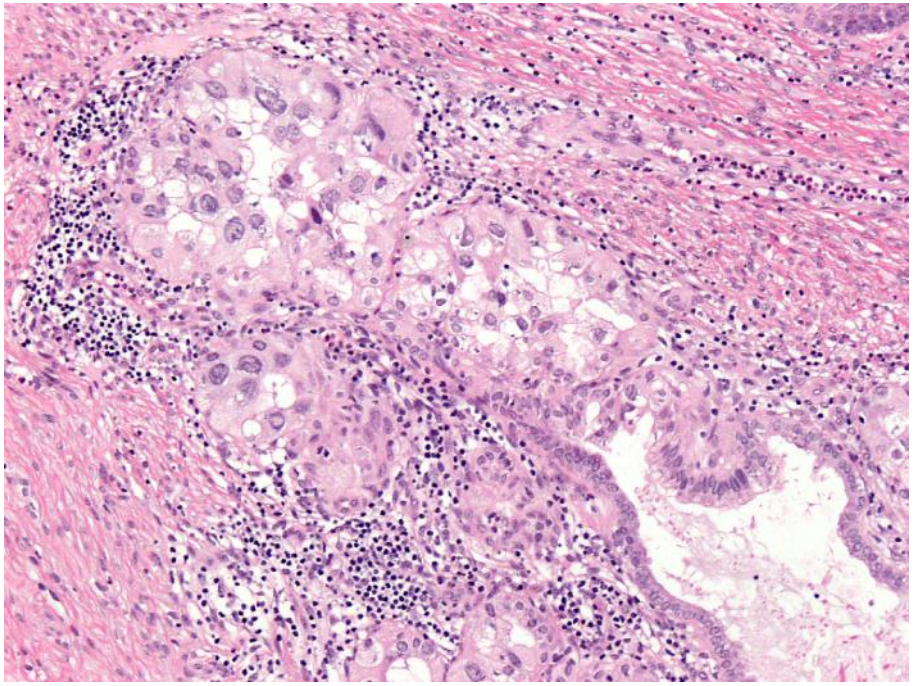
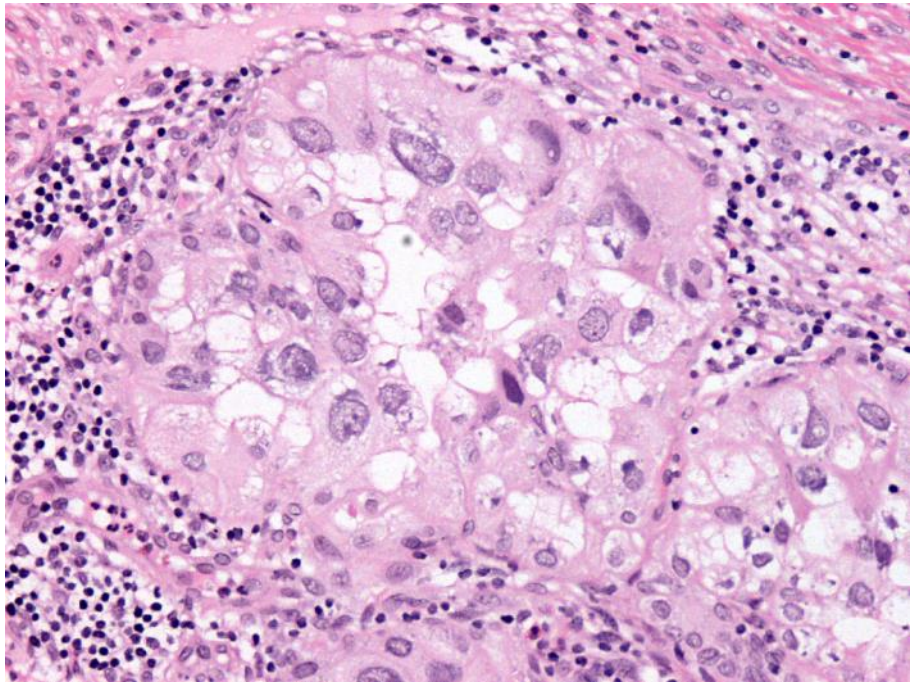
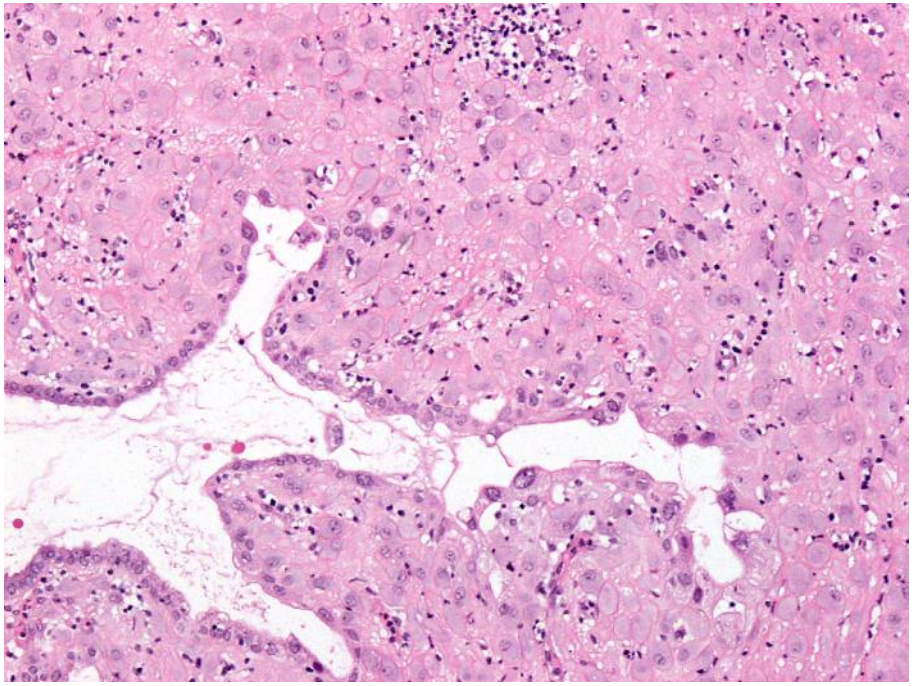

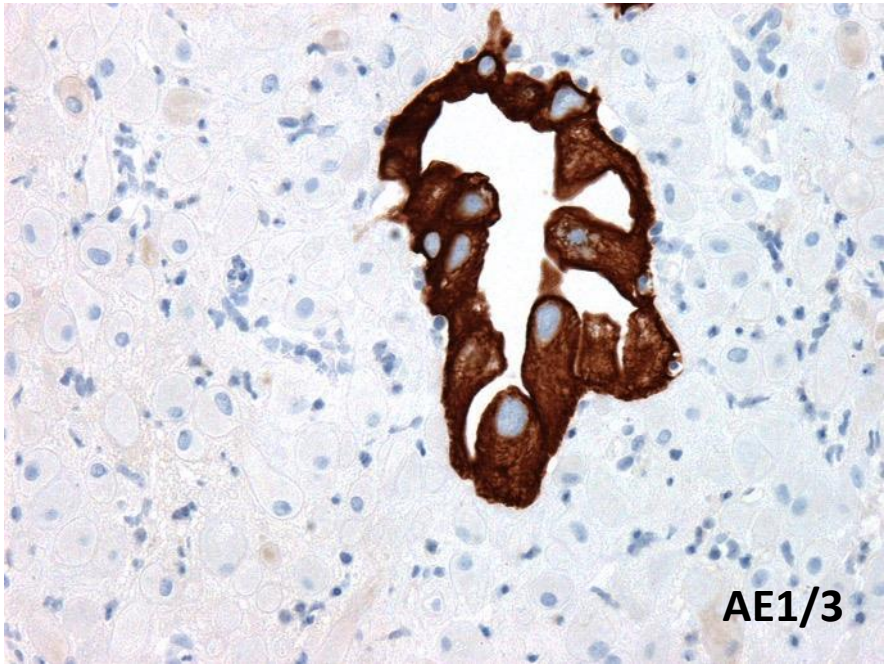
AE1/3

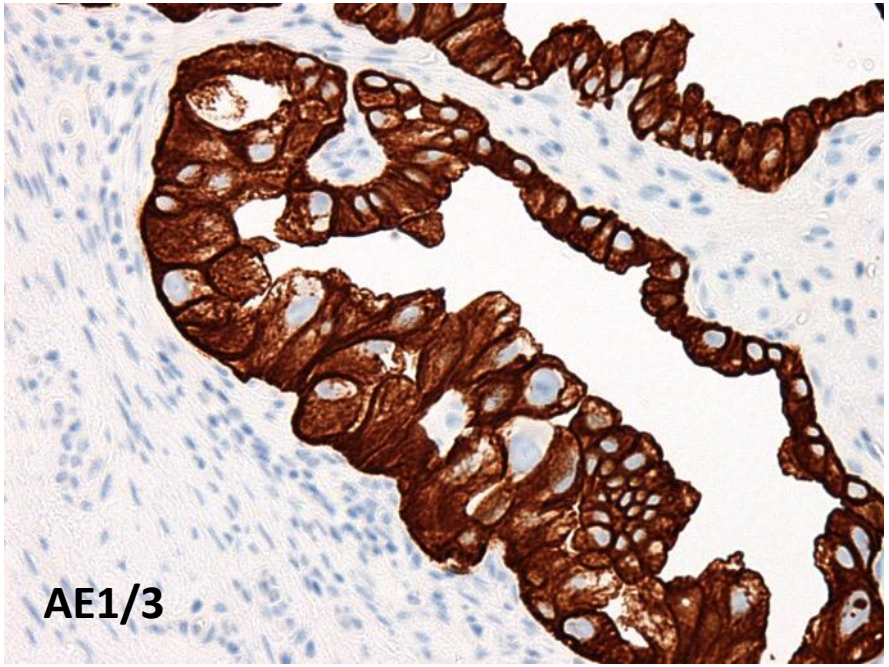
AE1/3

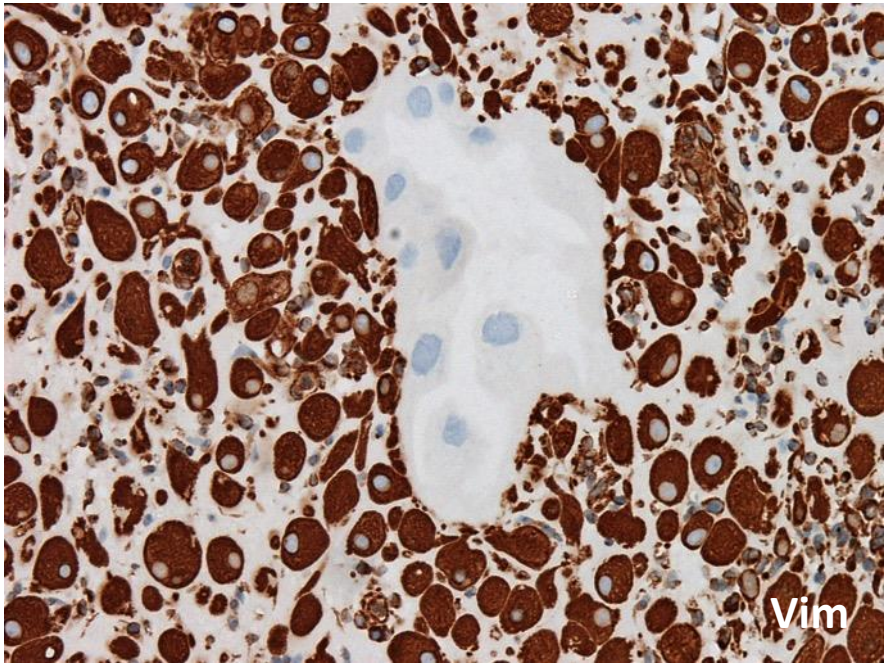
Vim

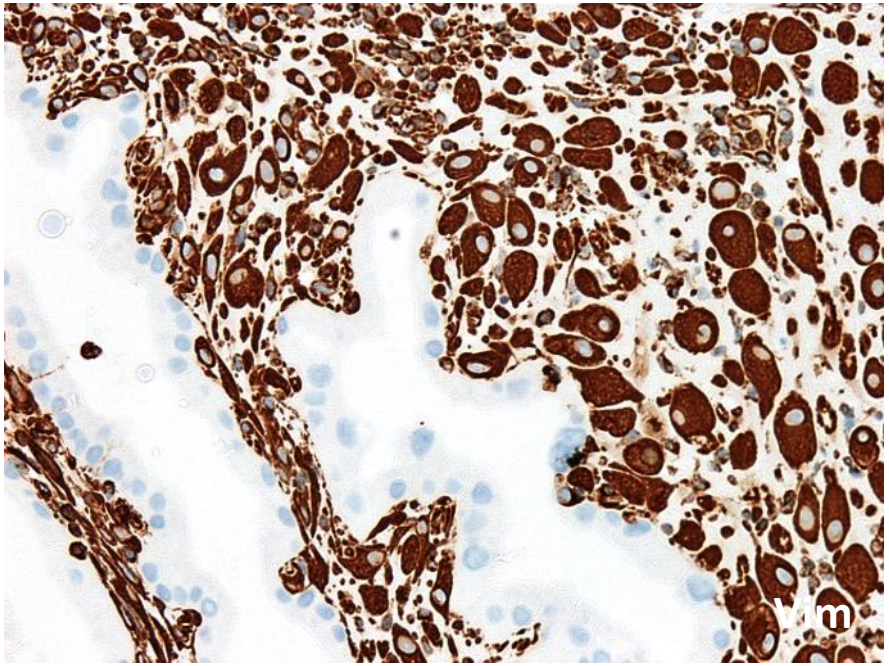
Vim

Diagnosis

Cervical Arias-Stella and Decidual Reactions

Nucci MR & Young RH. Arias-Stella reaction of the endocervix: a report of 18 cases with emphasis on its varied histology and differential diagnosis. Am J Surg Pathol 2004; 28: 608-612

Case 3

- Female aged 35
- Previous loop excision for HSIL showed focal stromal invasion
- Positive margins
- Further loop performed

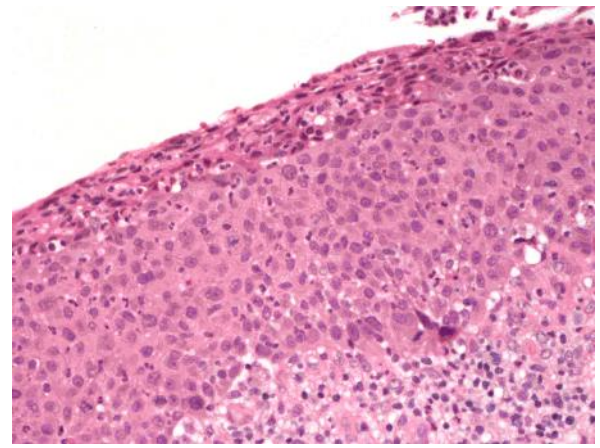
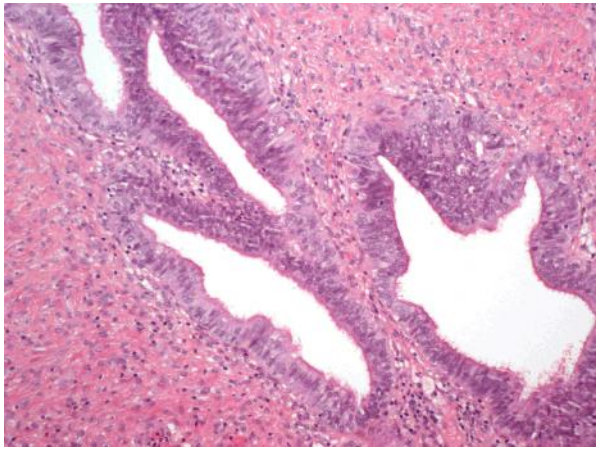
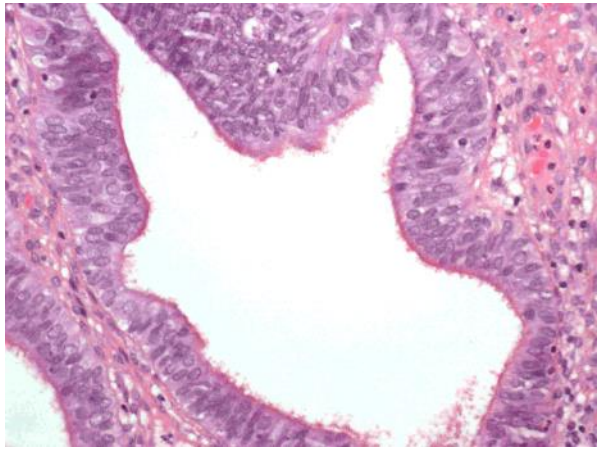
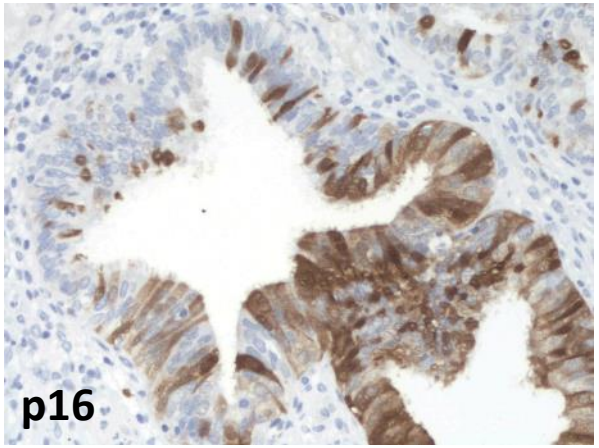
p16
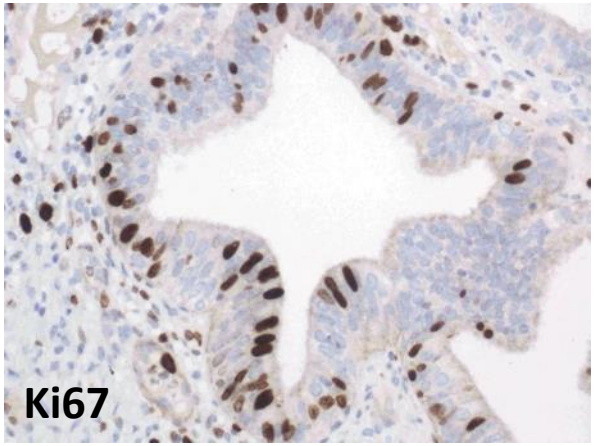
Ki67
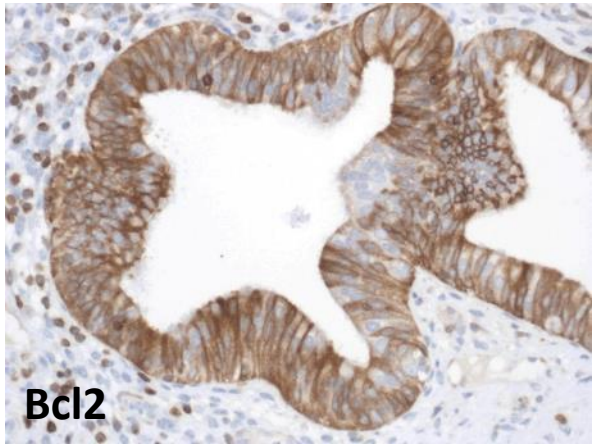
Bcl2
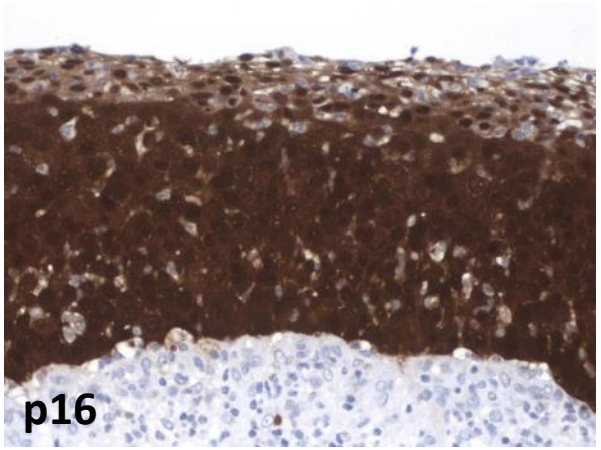
p16
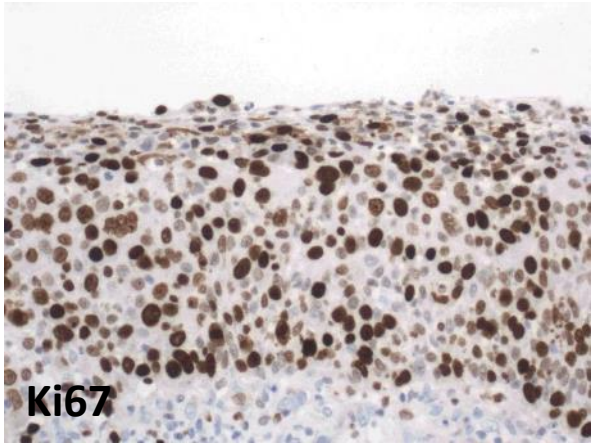
Ki67
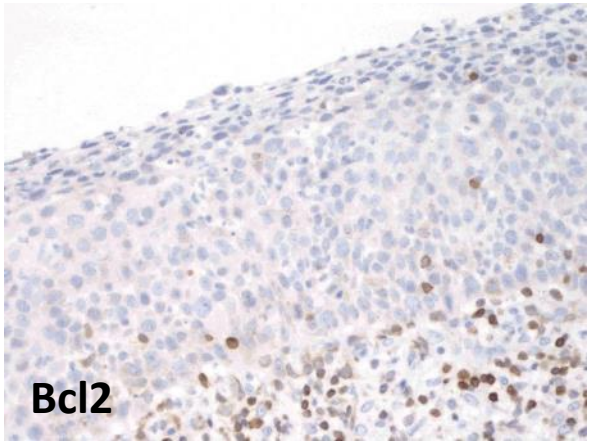
Bcl2

H&E

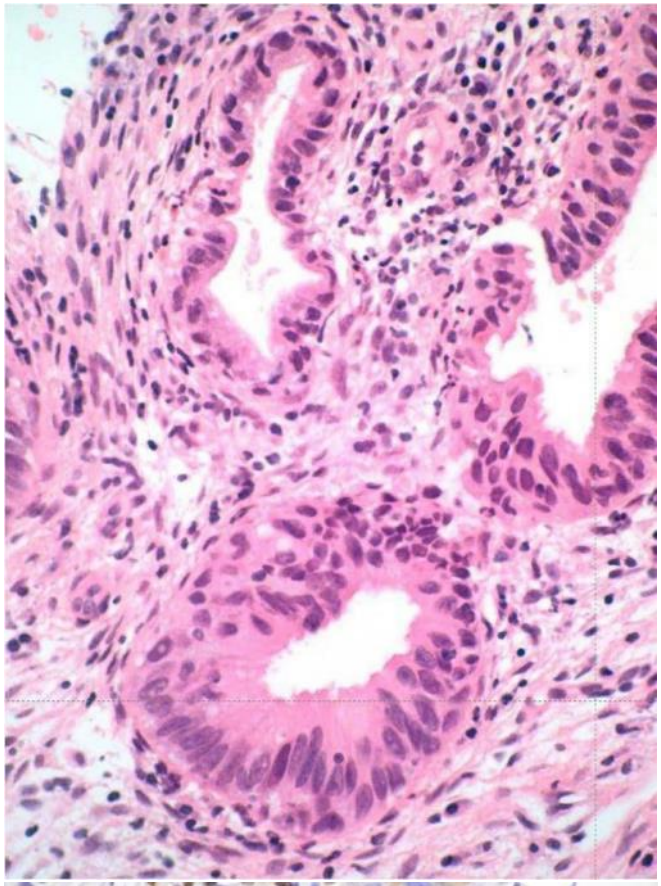

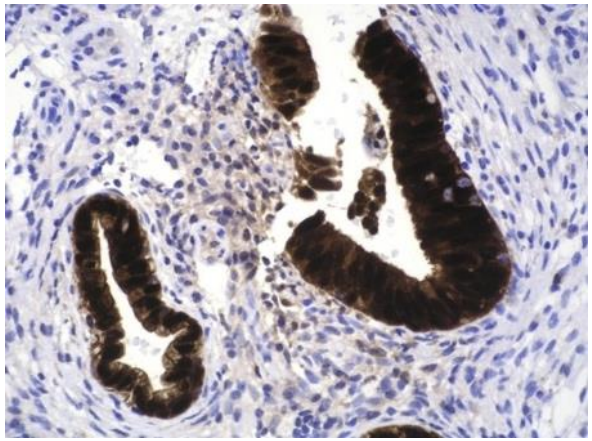

p16

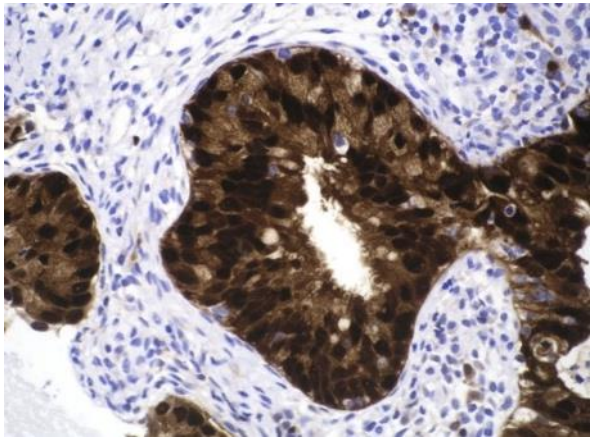

p16

Bcl-2

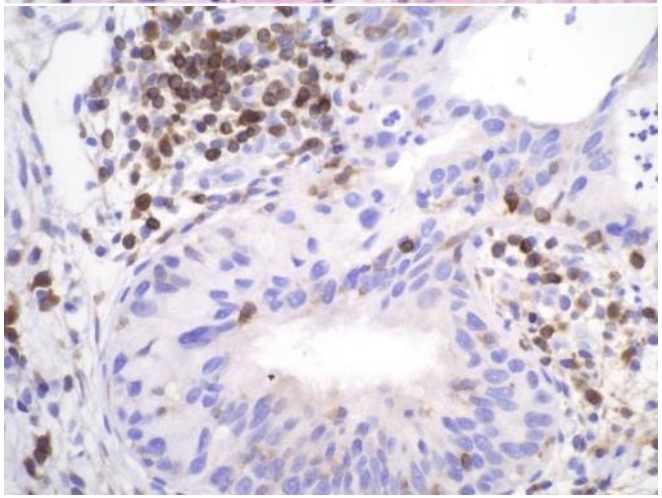

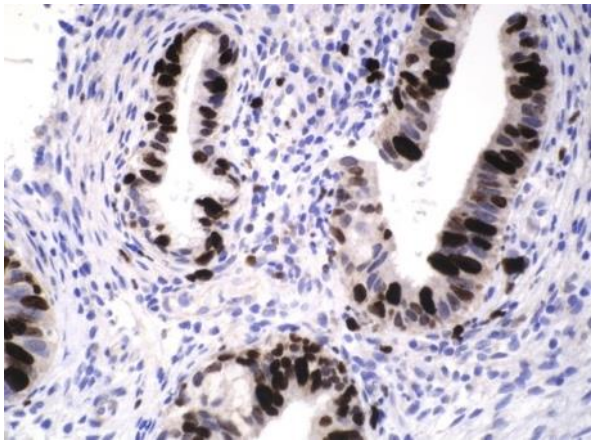

Ki67

Case 4

- Female aged 28
- Incidental finding in cervical loop specimen

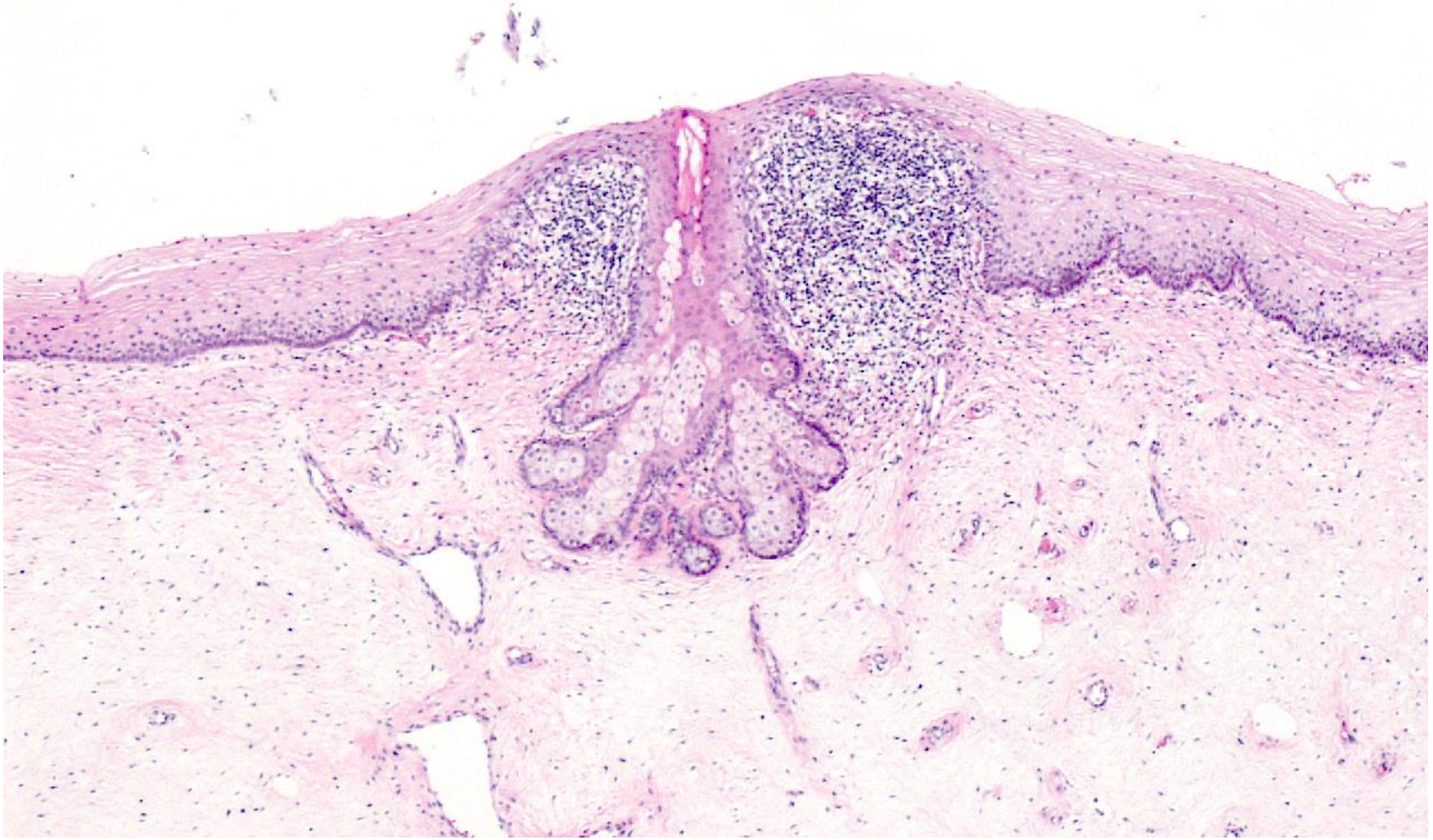



Mesenchymal and Inflammatory Lesions

- Mesenchymal lesions
  - Leiomyoma
  - Other benign tumours
- Inflammatory lesions
  - Infections
  - Vasculitis
  - Lymphoma-like lesion

Cervical Infections

- Human Papillomavirus (HPV)
- Herpes simplex virus (HSV)
- Epstein-Barr virus (EBV)
- Molluscum contagiosum
- Syphilis
- Chlamydia and Lymphogranuloma venereum
- Granuloma inguinale
- Mycoplasma
- Chancroid
- Tuberculosis
- Trichomoniasis
- Amoebiasis
- Schistosomiasis

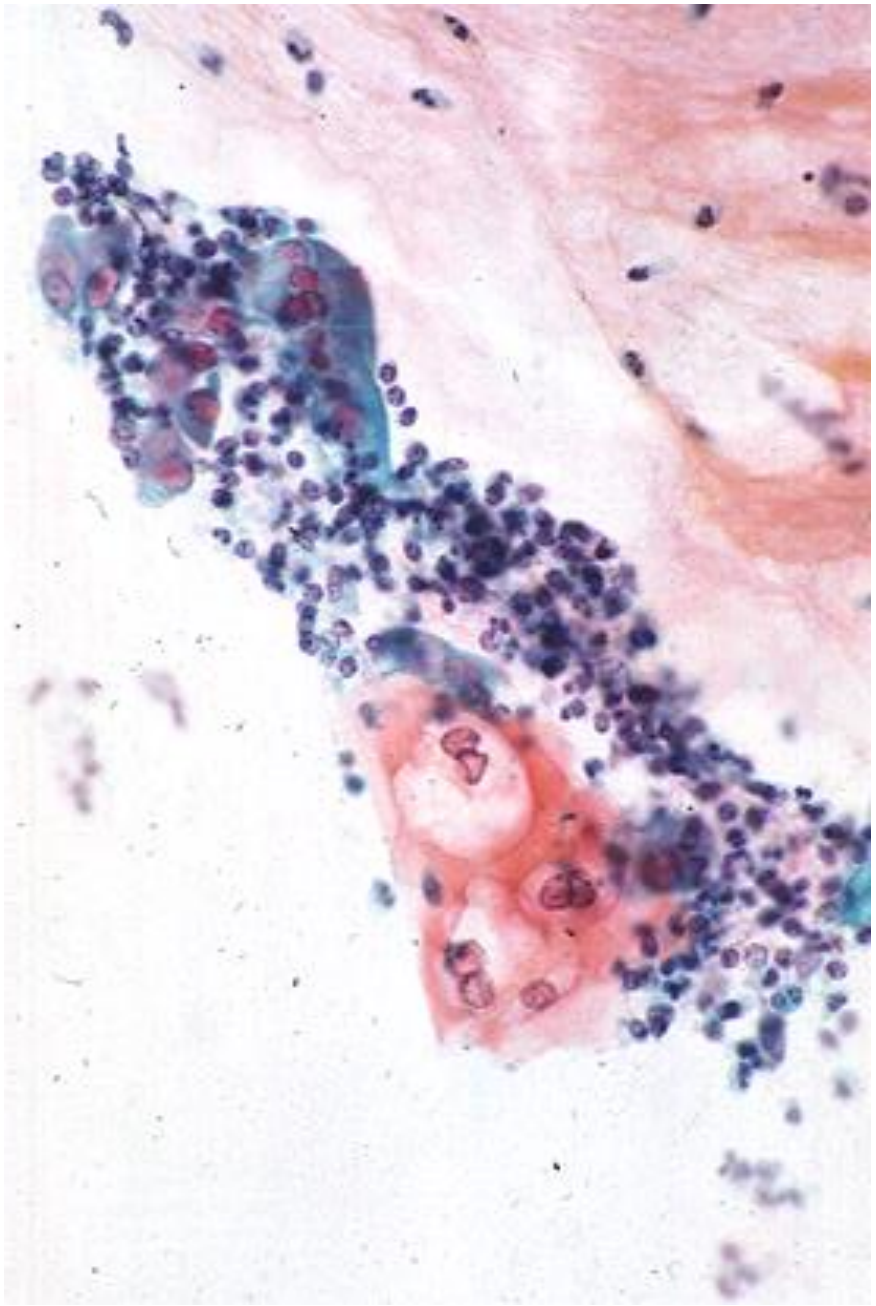

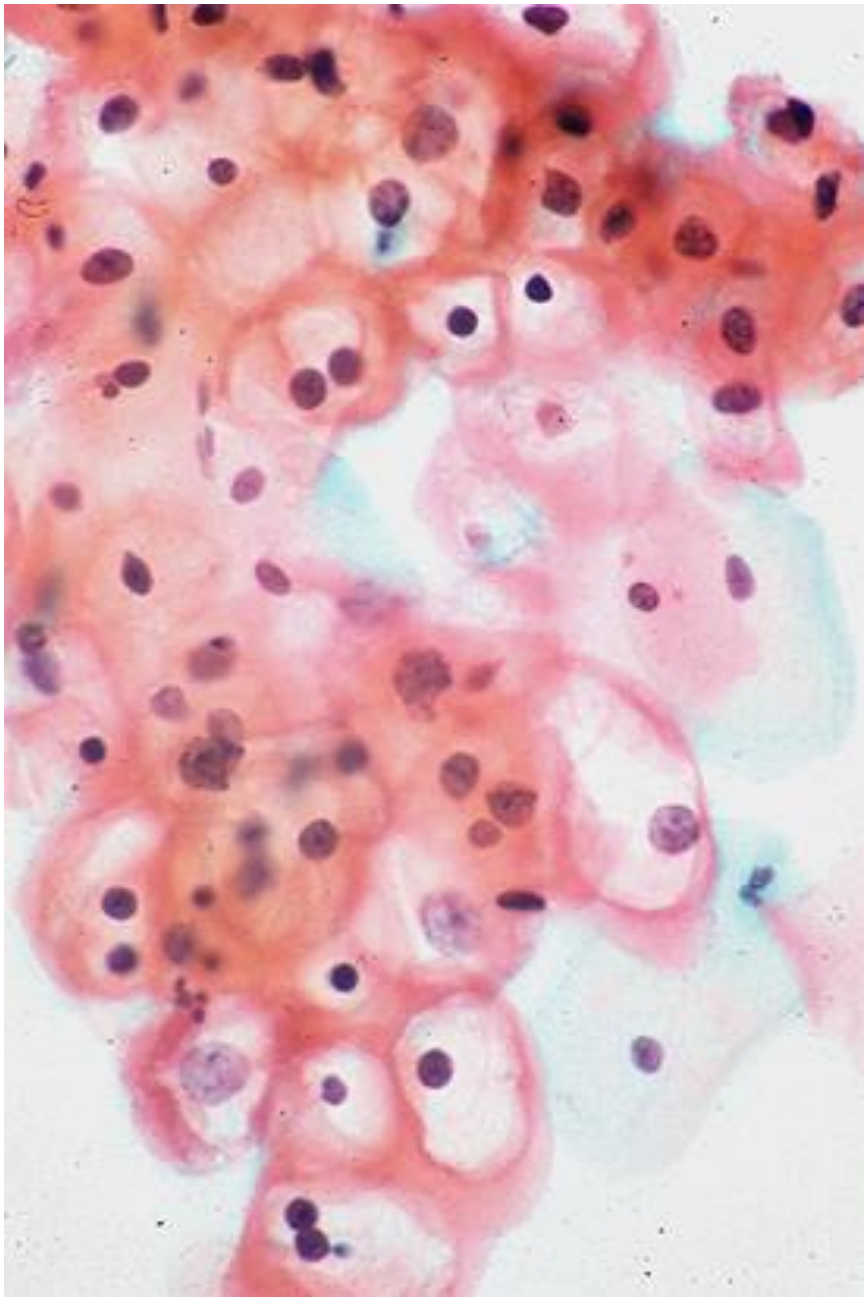

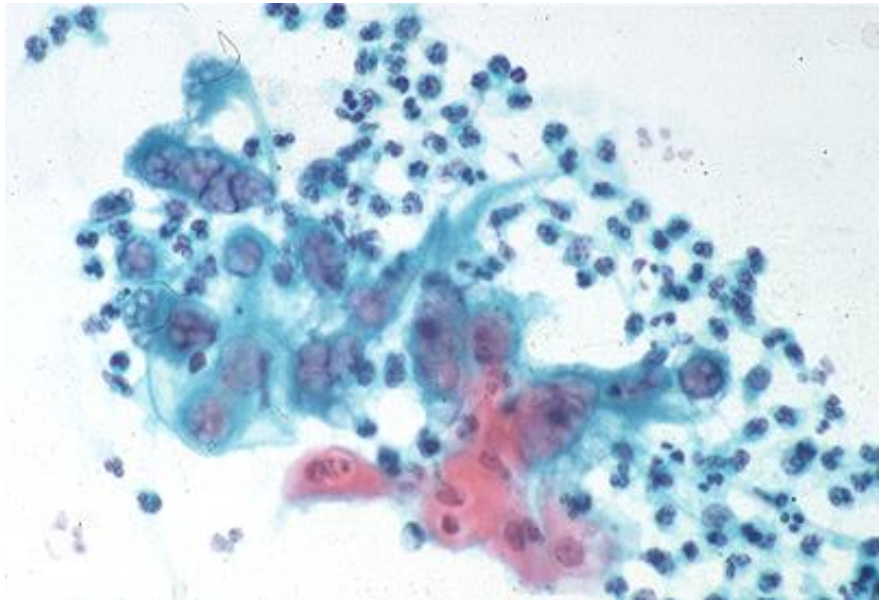

Herpes simplex

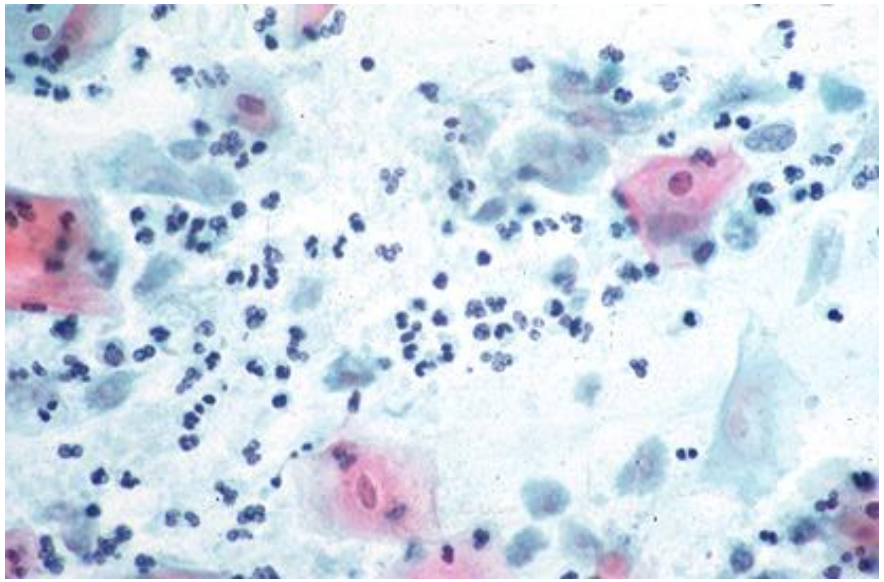

Trichomonas

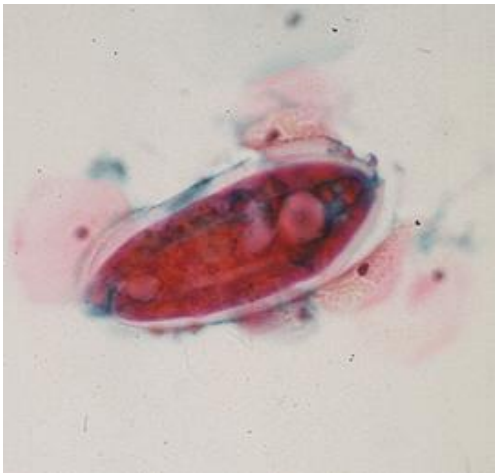

Schistosoma

Case 5

- Female aged 56
- Cervical smears – low grade x 2
- Rheumatoid arthritis on methotrexate

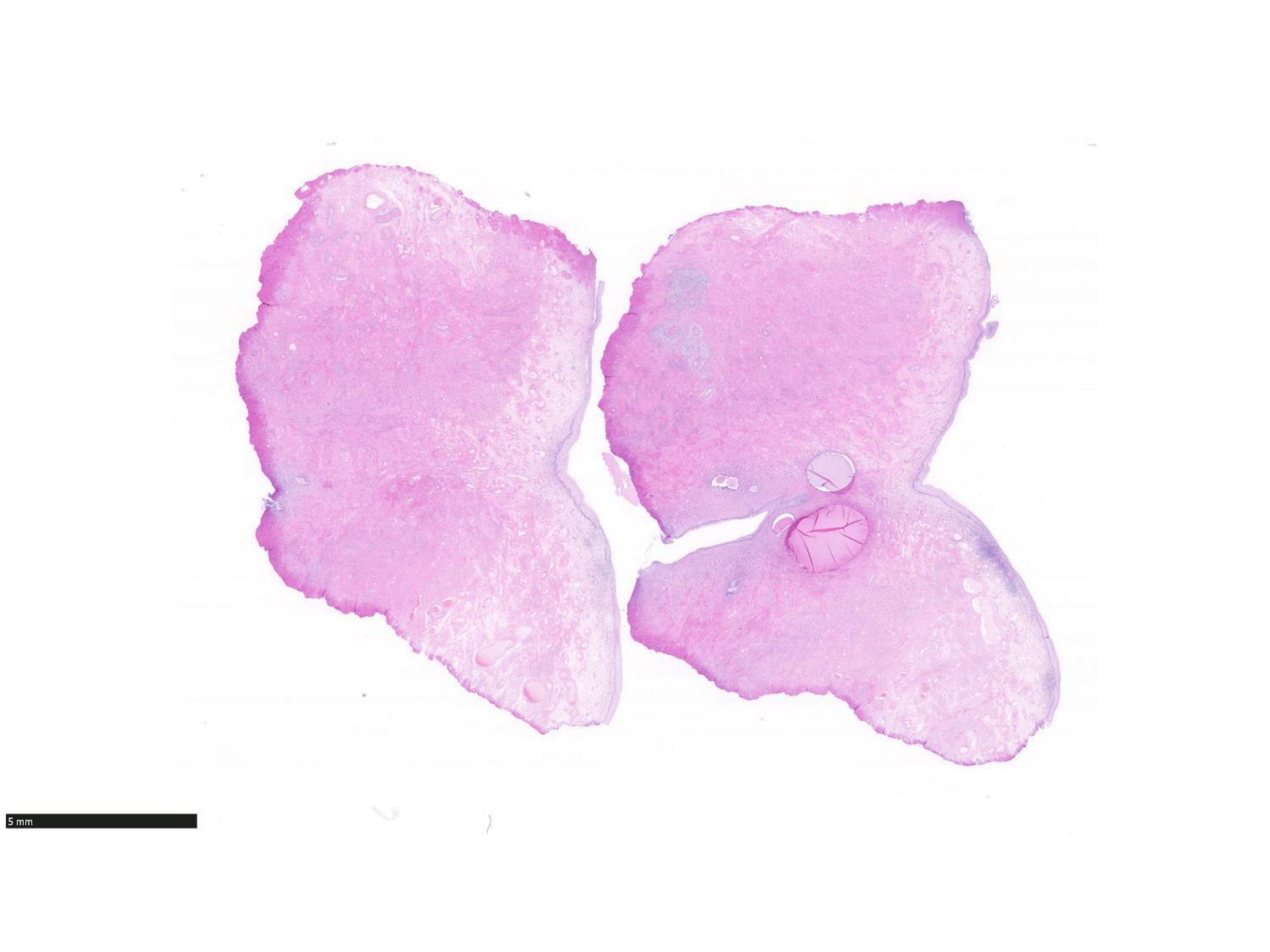
5 mm

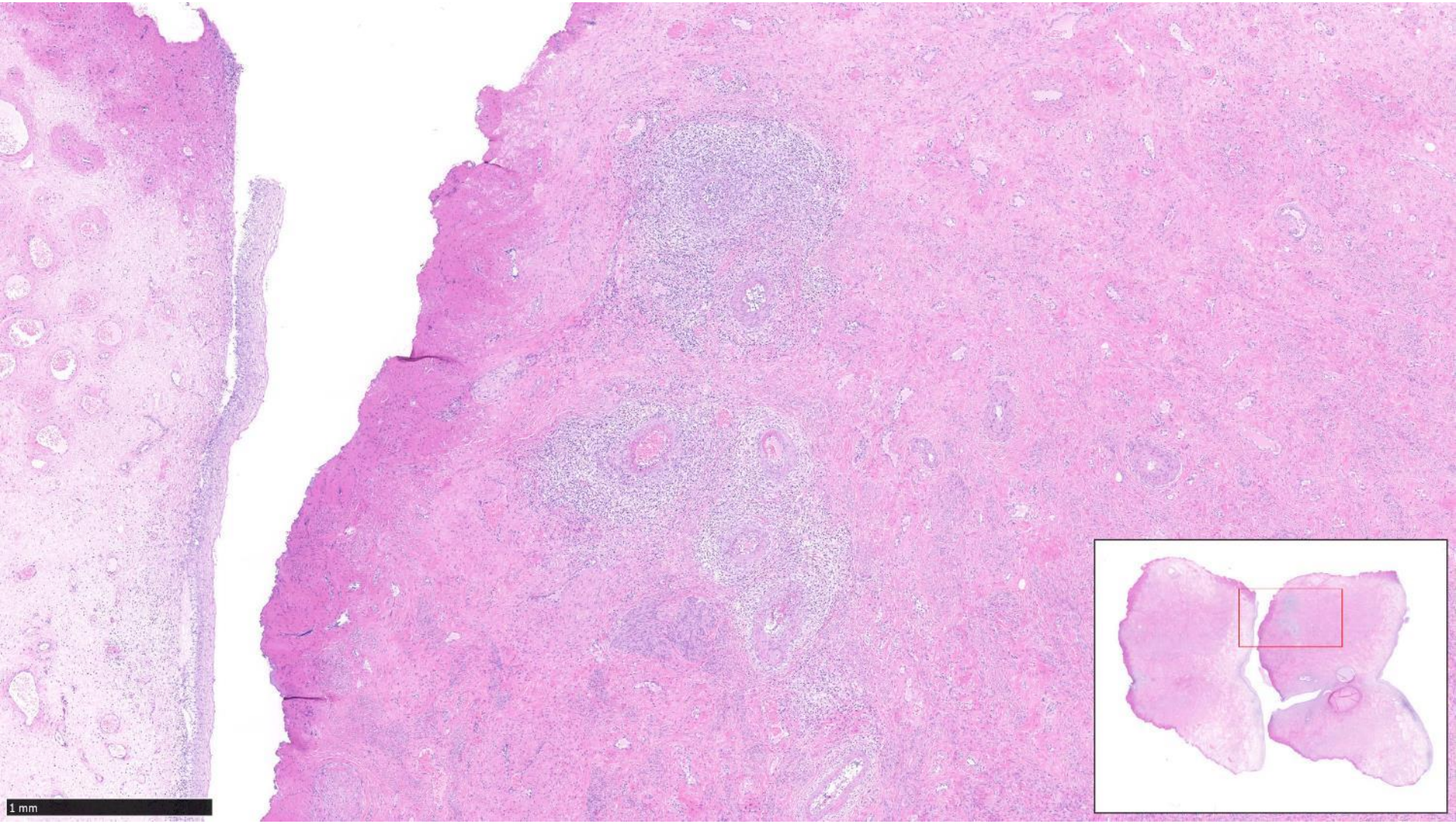
1 mm

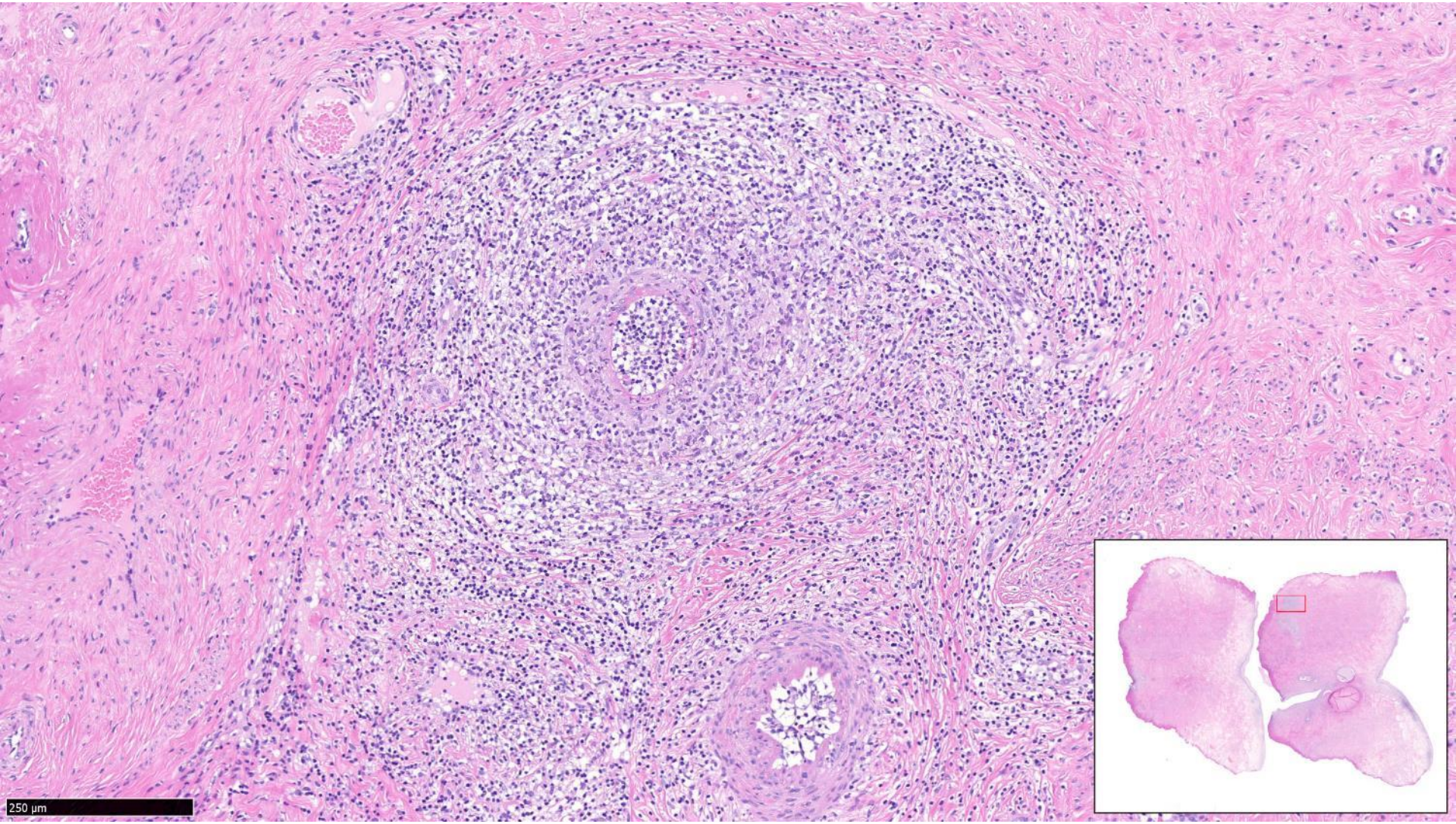
250 µm

Diagnosis

Cervical Vasculitis

? Related to Rheumatoid Arthritis

Summary

- Benign squamous lesions
  - Most are HPV related
  - HPV biology supports 2-tier grading system
- Benign glandular lesions
  - Mesonephric remnants
  - Tuboendometrioid metaplasia
- Mesenchymal lesions
  - Leiomyoma
- Inflammatory lesions
  - Vasculitis

