TECHNOLOGY TRANSFER IN DIAGNOSTIC PATHOLOGY
10TH CENTRAL EUROPEAN REGIONAL MEETING

Gynecological Pathology

ORGANIZED BY THE HUNGARIAN DIVISION OF THE INTERNATIONAL ACADEMY OF PATHOLOGY



Slide seminar:Precursor lesions

Sigurd F. Lax

JOHANNES KEPLER UNIVERSITY LINZ

LKH Graz II
Academic Teaching Hospital of the Medical University Graz
Pathology

KAGes

Case 1: Clinical History

- 72-year-old female with postmenopausal bleeding.
- Family history of breast and colon cancer.
- TVUS: endometrium 11mm thick; right adnexal mass, cystic, 5 cm diameter.
- A pipelle procedure was performed.

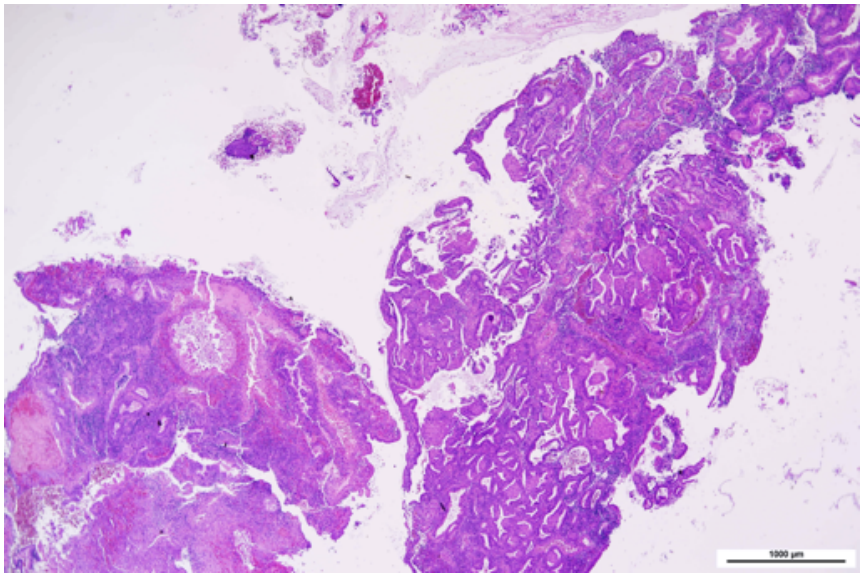

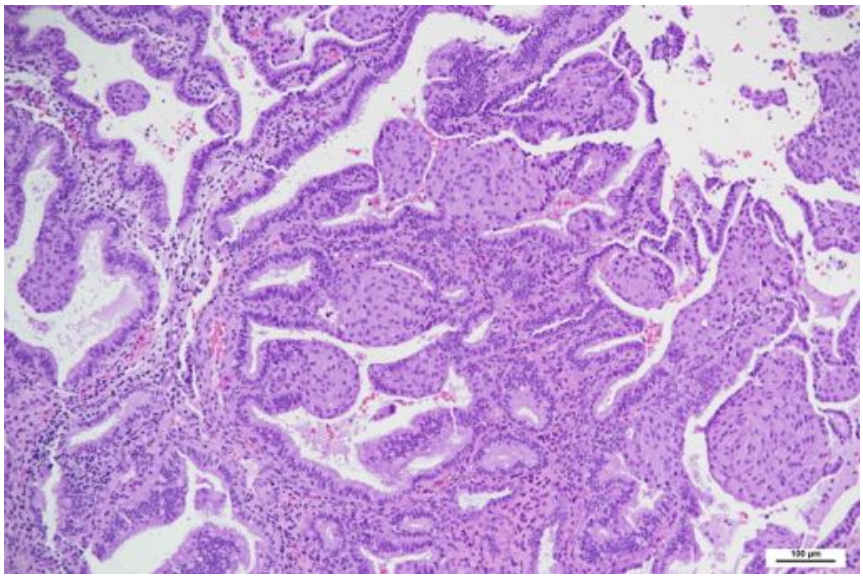

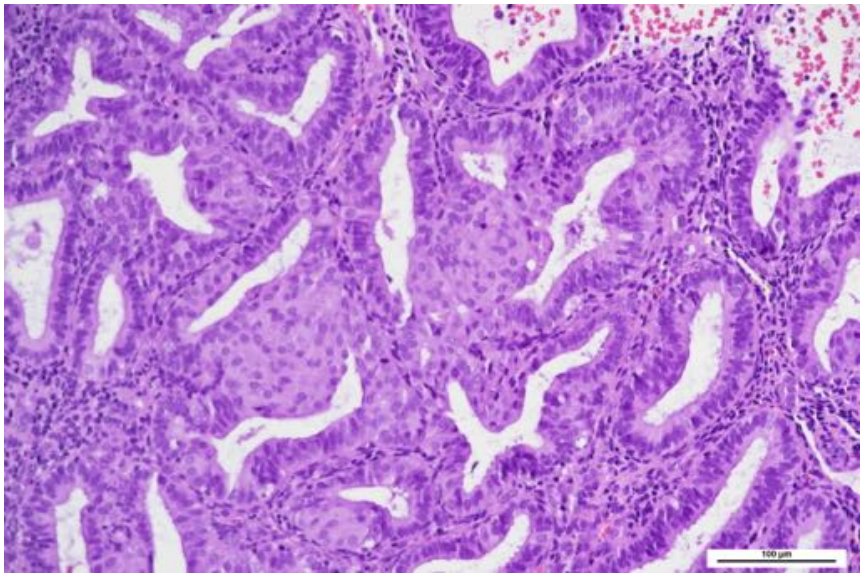

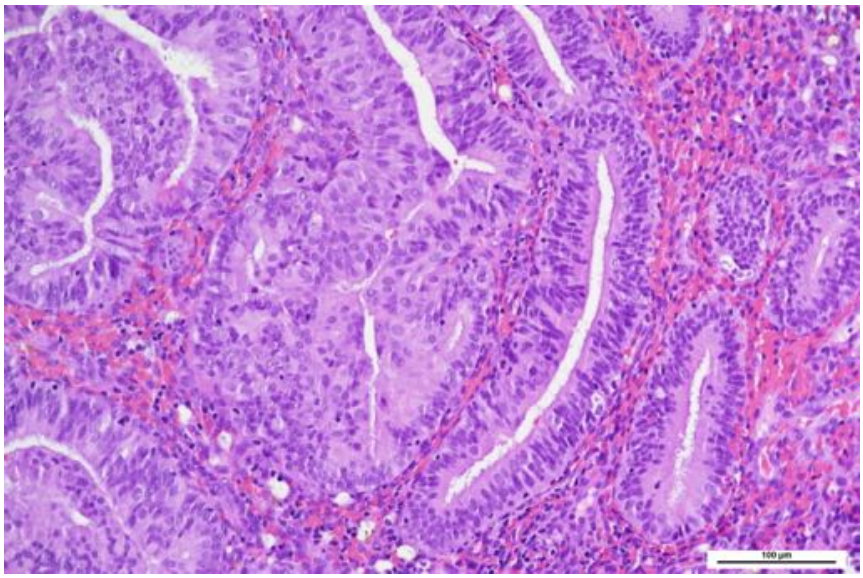

Diagnosis

- **Atypical endometrial hyperplasia (AEH/EIN)**

  (with squamous morules)

Diagnostic criteria

- Increased number of glands with increased glandular to stromal ratio
- Atypical glandular epithelium with loss of polarity
- Contrast of the atypical epithelium to the epithelium of adjacent inactive glands
- Lack of confluent growth
- Caveat: Squamous morules not AEH criterion

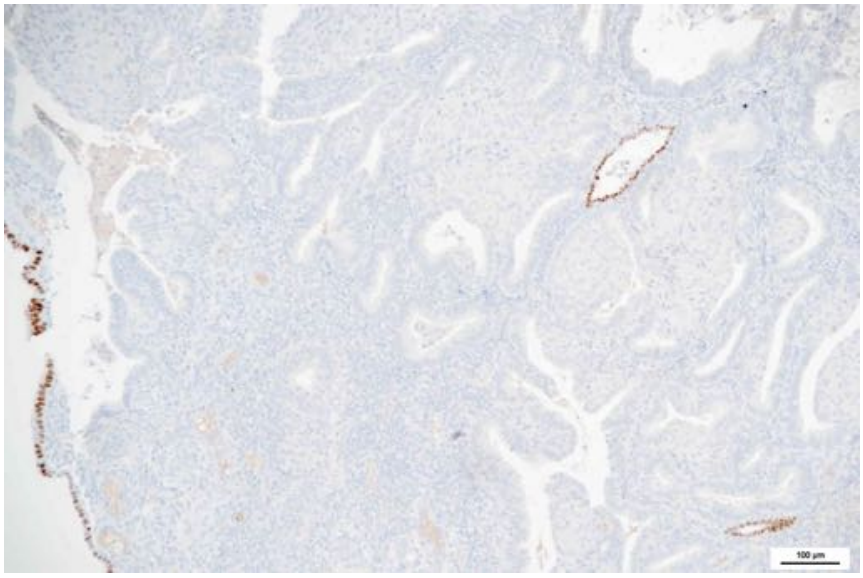

Pax-2

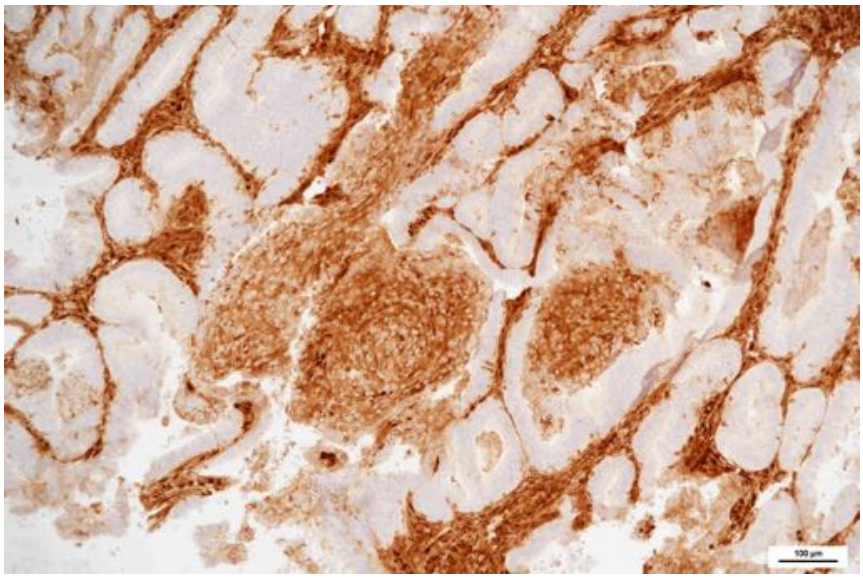

PTEN

Differential Diagnosis

- Endometrial hyperplasia without atypia:
  - Lack of atypia
  - Less complexity
- Well differentiated endometrioid carcinoma
  - Confluent growth with maze-like or cribriform pattern
  - Desmoplastic stromal reaction
  - Myometrial invasion

Follow up

- Hysterectomy and bilateral salpingo-oophorectomy about 3 months later.
- Endometrium: residual atypical hyperplasia.
- Right ovary: atypical proliferative endometrioid tumor (endometrioid Borderline tumor), 9.5 cm in largest diameter.

Synchronous Endometrioid Tumours of Uterus und Ovary

- Up to 10% of ovarian endometrioid tumors associated with endometrioid carcinoma or atypical hyperplasia in endometrium
- Question of origin, problem of staging
- Size of tumors and other criteria (myometrial invasion, lymphangiosis, serosa of ovary etc.) need to be taken into consideration (Scully)
- Proof by molecular analysis (clonality analysis: mutational spectrum/signatures, CNA by NGS)

BRIEF COMMUNICATION

Massively Parallel Sequencing-Based Clonality Analysis of Synchronous Endometrioid Endometrial and Ovarian Carcinomas

Anne M. Schultheis*, Charlotte K. Y. Ng*, Maria R. De Filippo, Salvatore Piscuoglio, Gabriel S. Macedo, Sonia Gatius, Belen Perez Mies, Robert A. Soslow, Raymond S. Lim, Agnes Viale, Kety H. Huberman, Jose C. Palacios, Jorge S. Reis-Filho, Xavier Matias-Guiu, Britta Weigelt

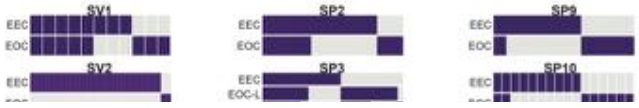

- 23 cases of synchronous endometrioid endometrial and ovarian carcinomas, histologically and clinically well documented
- 22 showed a clonal relationship, one Lynch case did not

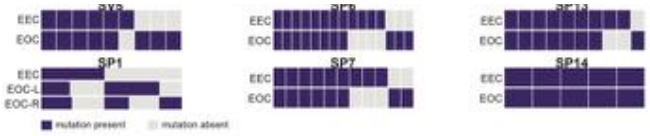

JNCI J Natl Cancer Inst (2016) 108(6): djv427

Take Home Message

- Recognition of atypia and metaplastic changes (morula)
- Metaplasia may occur in atypical lesions
- Distinction from invasive carcinoma
- Concurrence of atypical lesions of the endometrium and the ovaries in about 10% of cases (most likely “metastatic” since clonal)

CASE 2

Case 2: Clinical History

- 65-year-old female with postmenopausal bleeding.
- TVUS: endometrium 8.5 mm thick

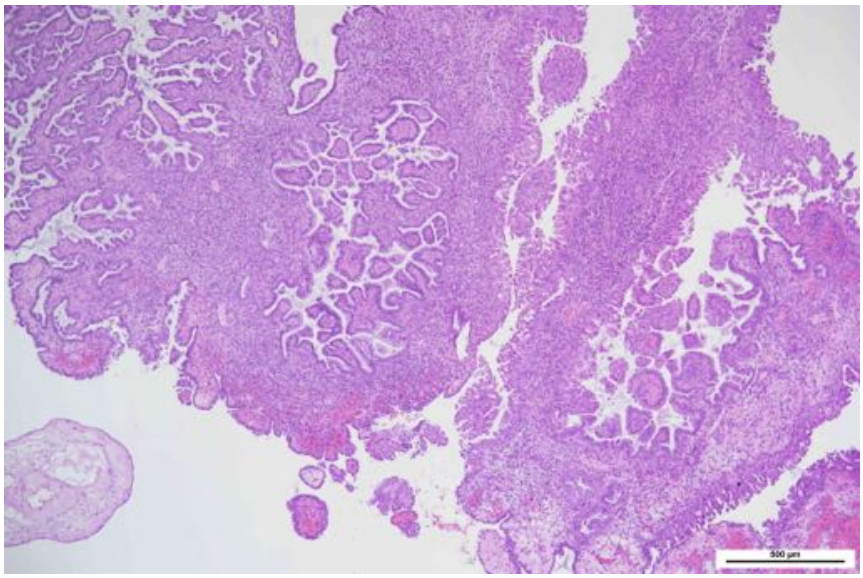

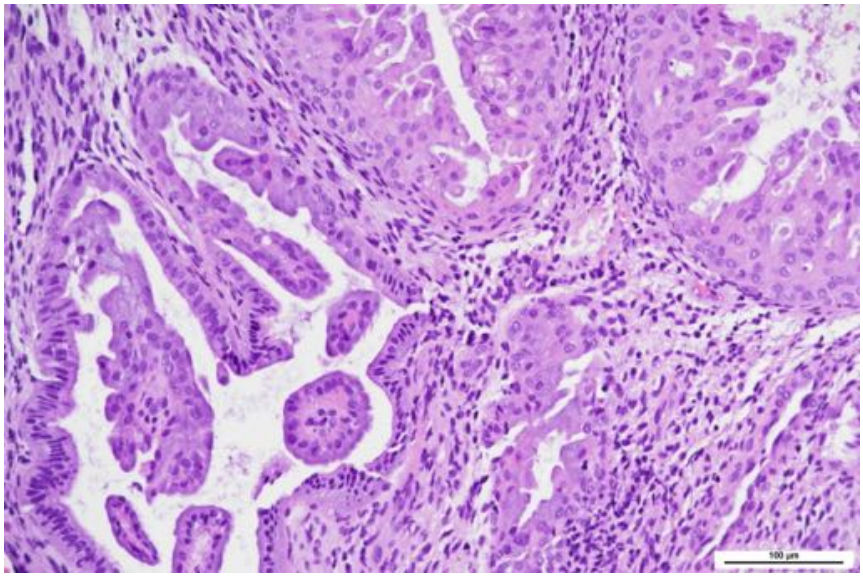

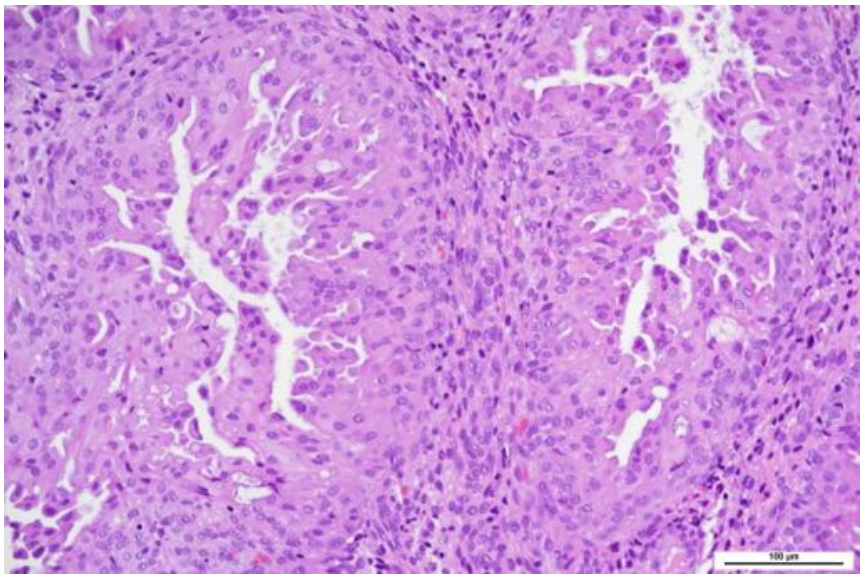

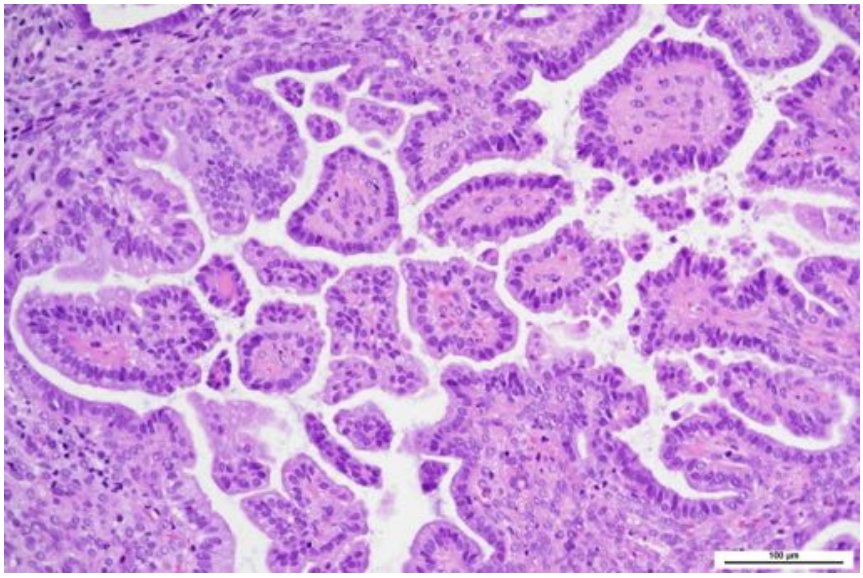

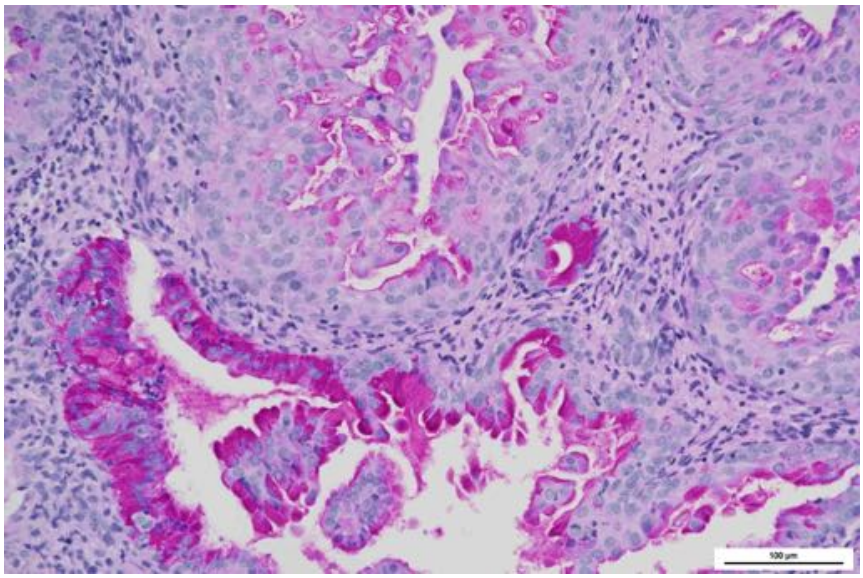

Immunohistochemistry

- PTEN positive
- Pax-2 positive
- ER positive
- Ki67 low
- P53 wild type

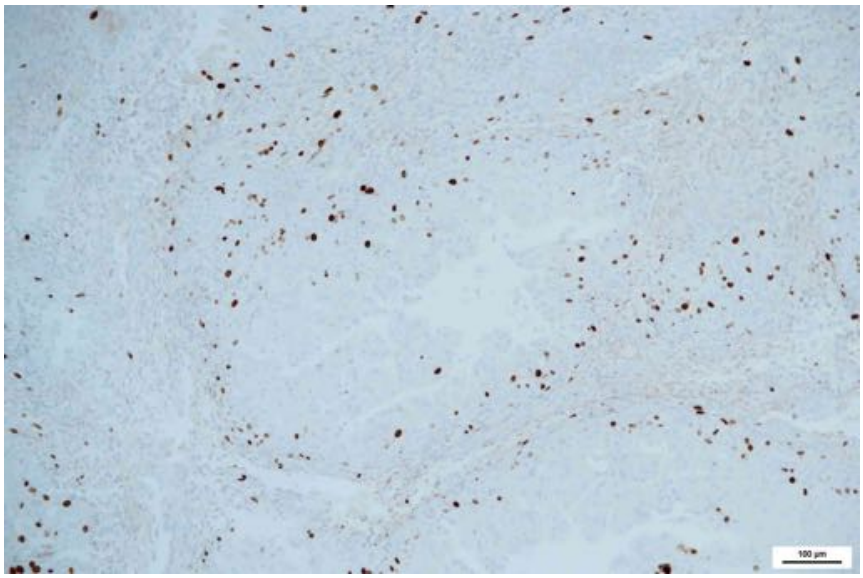

Ki67

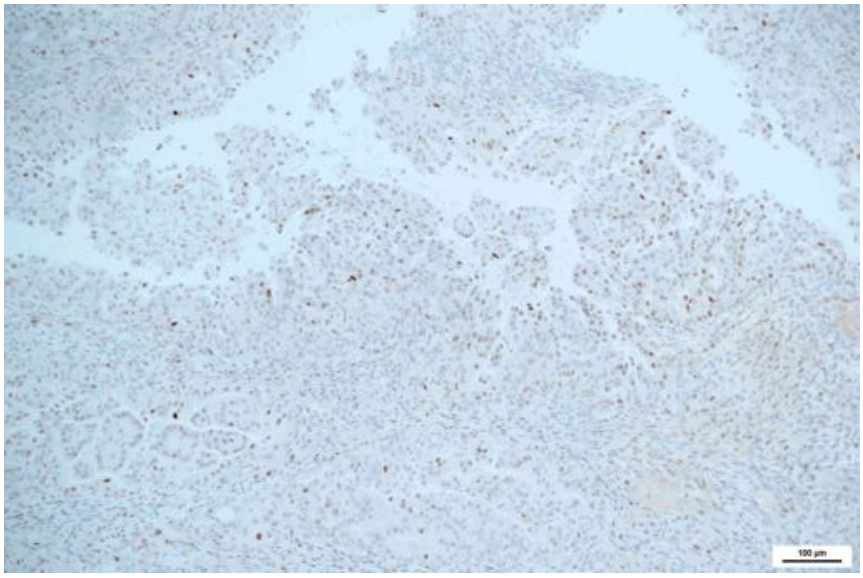

p53

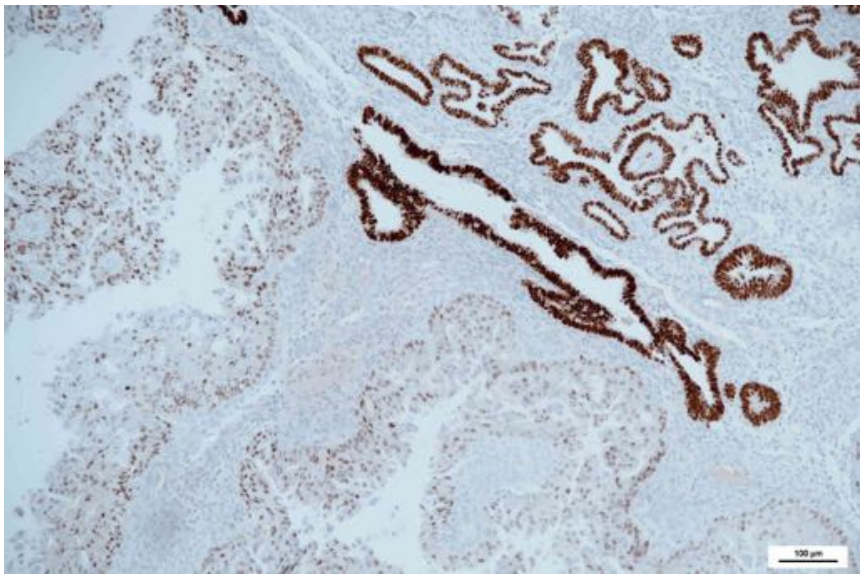

Pax2

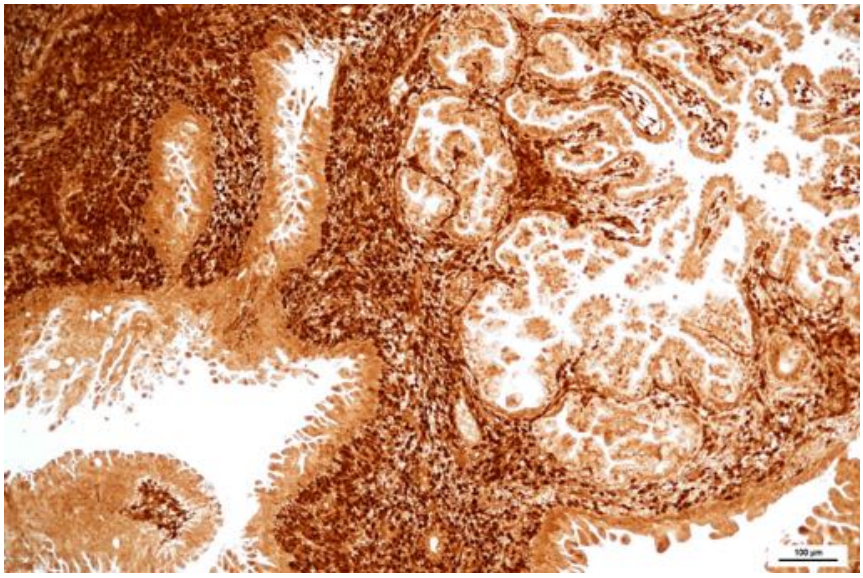

PTEN

Diagnosis

- **Papillary mucinous proliferation and papillary syncytial metaplasia**

Diagnostic criteria

- Polypous endometrium
- Papillary structures without rigidity or confluence, covered by bland looking epithelium
- Lack of atypia of the syncytial epithelium

Mucinous Endometrial Epithelial Proliferations: A Morphologic Spectrum of Changes with Diverse Clinical Significance

Marisa R. Nucci, M.D., Chaya J. Prasad, M.D., Christopher P. Crum, M.D., George L. Mutter, M.D.
Department of Pathology, Division of Women's and Perinatal Pathology, Brigham and Women's Hospital and Harvard Medical School, Boston, Massachusetts

Type	Criteria	Atypia	Carcinoma in follow up
A	inconspicuous or micropapillary changes and tufting	absent	0
B	microglandular pattern	absent	65%
C	complex villous or cribriform structure	present	100%

Modern Pathol 12: 1137-42, 1999

WHO 2014

- Mucinous carcinoma
  - If confluent pattern present, even with little or no atypia
- Atypical mucinous glandular proliferations
  - For other lesions not meeting these criteria

A few more examples

- Mucinous and /or papillary endometrial lesions with various degree of complexity



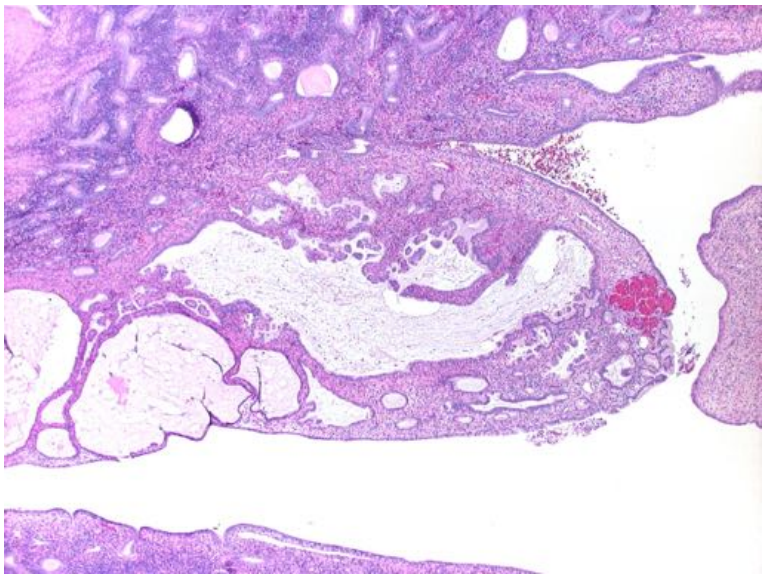

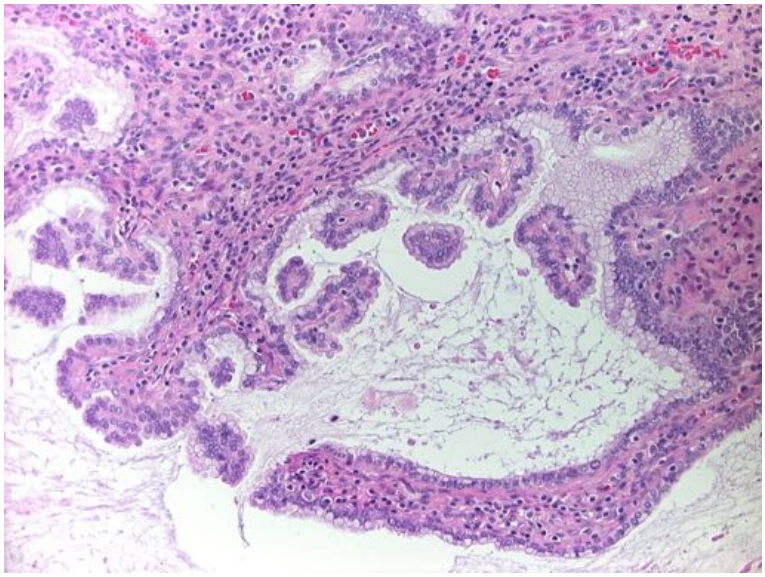

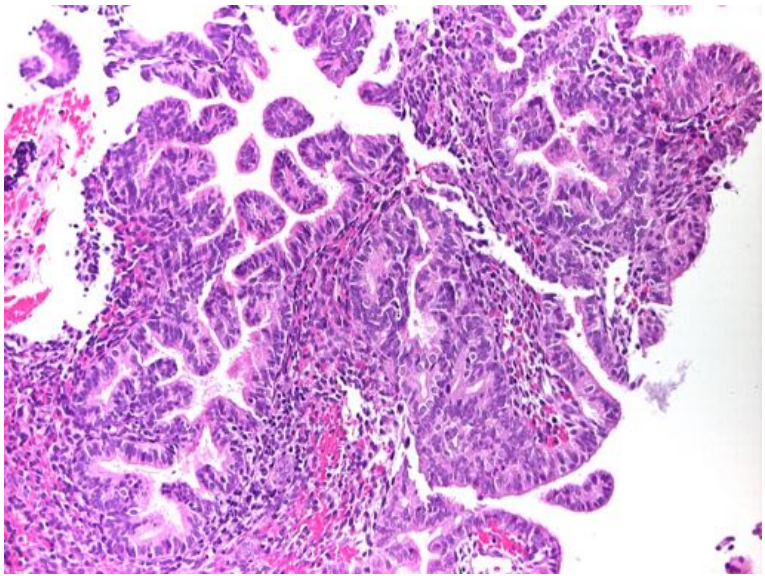

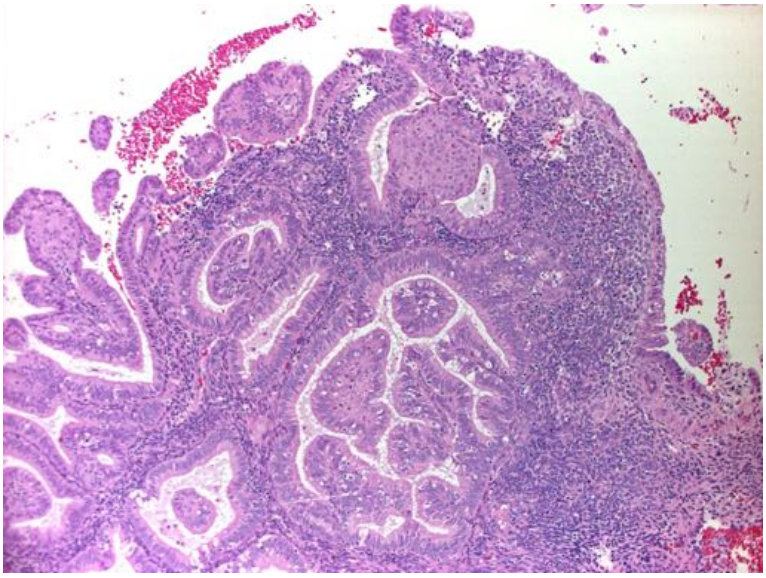

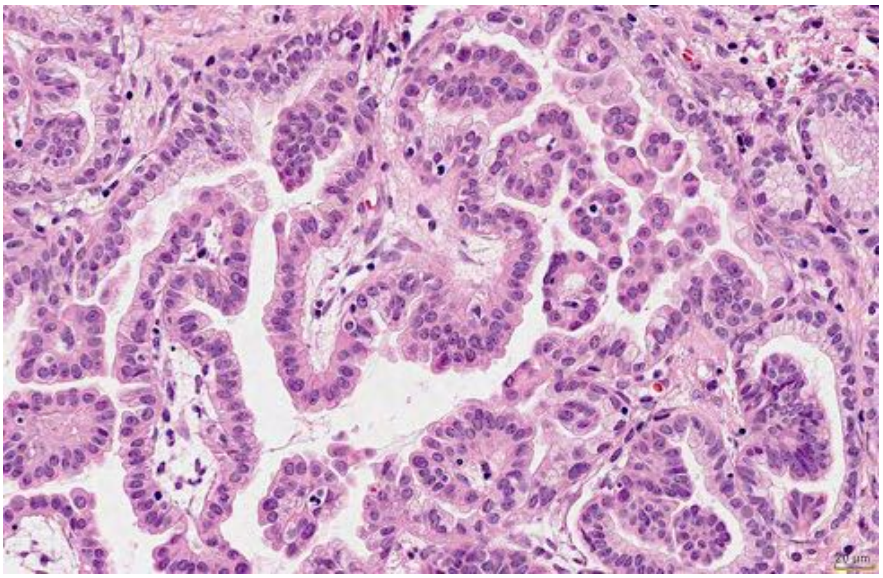

Cave: complexity

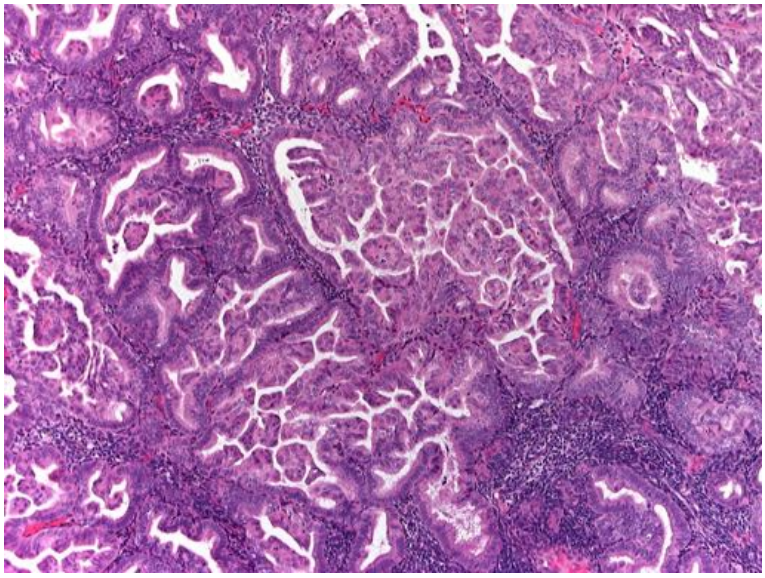

Cave: complexity

Differential Diagnosis

- Atypical endometrial hyperplasia
  - Complex glandular pattern
  - unequivocal nuclear atypia
- Well differentiated endometrioid carcinoma
  - Confluent growth with maze-like or cribriform pattern; desmoplastic reaction
- Serous carcinoma
  - High grade cellular atypia; detachment of cells

Follow up

- Inconspicuous after 34 months (also TVUS)

Take Home Message

- Papillary changes may occur in neoplastic and non-neoplastic endometrium
- Papillae are not criterium for carcinoma but carcinomas may show papillary architecture
- If you find papillae rule out cancer
- Association with mucinous differentiation
- “papillary hyperplasia”
- Papillary syncytial metaplasia: regeneration