TECHNOLOGY TRANSFER IN DIAGNOSTIC PATHOLOGY
10TH CENTRAL EUROPEAN REGIONAL MEETING

Gynecological Pathology

ORGANIZED BY THE HUNGARIAN DIVISION OF THE INTERNATIONAL ACADEMY OF PATHOLOGY



Precursor lesions of endometrial cancer

Sigurd F. Lax

JOHANNES KEPLER UNIVERSITY LINZ

LKH Graz II
Academic Teaching Hospital of the Medical University Graz
Pathology

KAGes

This morning in Graz



27.6.1989, close to Sopron



It continued in August 1989



Today a quiet site of memory



Outline

- Endometrial hyperplasia:
  - Classification
  - Differential diagnosis
- Metaplasia
- Papillary (mucinous) lesions
- Serous endometrial intraepithelial carcinoma

Endometrial Carcinoma (WHO 2014)

- Endometrioid adenocarcinoma, usual type
- Endometrioid adenocarcinom, variant types
  - with squamous differentiation
  - With secretory differentiation
  - Villoglandular
  - Ciliated cell type
- Mucinous carcinoma
- Serous endometrial intraepithelial carcinoma
- Serous adenocarcinoma
- Clear cell adenocarcinoma
- Neuroendocrine carcinoma
- Mixed carcinomas
- Undifferentiated carcinoma
  - Dedifferentiated carcinoma

Endometrioid and related

Non- endometrioid

Biological Model of Endometrial Carcinoma

- **Type 1 (Estrogen-related)**
  - Endometrial hyperplasia
  - Younger age (55-65)
  - ER / PR positive (80%)
  - Low stage at diagnosis
  - Favorable prognosis
  - Recurrence, metastases infrequent
  - Endometrioid carcinoma
  - MSI; mutant PTEN, K-RAS, ARID1A, ß-catenin, PIK3CA, p53
- **Type 2 (Estrogen-unrelated)**
  - Atrophic endometrium, EIC
  - Higher age (70+)
  - ER / PR negative (80-90%)
  - High stage at diagosis
  - Recurrence, metastases frequent
  - Unfavorable prognosis
  - Serous carcinoma
  - MSS; mutant p53, PIK3CA, FBXW7, PPP2R1, cyclin E

Type 1 and Type 2 Endometrial Carcinoma

- **Type 1 (Estrogen-related)**
- **Type 2 (Estrogen-unrelated)**





Pathogenetic Model for endometrioid Carcinoma: "Adenoma-Carcinoma Sequence"

Driven by estrogens

PTEN **K-ras**

Gatekeeper Pathway **ß-catenin** **PIK3C** **p53**

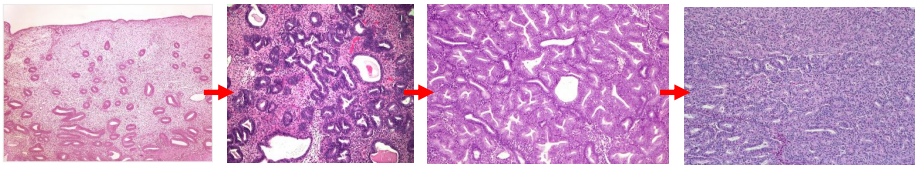

Normal endometrium → **Hyperplasia** → **Atypical Hyperplasia** → **Endometrioid carcinoma**

Caretaker Pathway **MMR Deficiency/MSI**

Lax, Virchows Archiv, 2004

Pathogenetic Model for Serous Carcinoma: de novo tumorigenesis

Unrelated to estrogens

Cyclin E IMP-3 p16 Cyclin E IMP-3 p16

p53 E-cadherin p53 FBXW7

PPP2R1

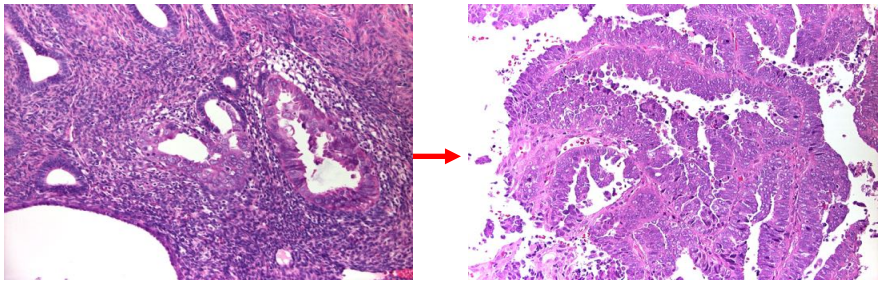

Serous endometrial intraepithelial Carcinoma (SEIC)

Serous Carcinoma

Lax, Virchows Archiv, 2004

Endometrial hyperplasia

WHO 2003

- Nonatypical hyperplasia
  - Simple
  - Complex (adenomatous)
- Atypical hyperplasia
  - Simple
  - Complex

WHO 2014

- Hyperplasia without atypia
- Atypical hyperplasia/ Endometrioid intraepithelial neoplasia

Disordered proliferative phase endometrium

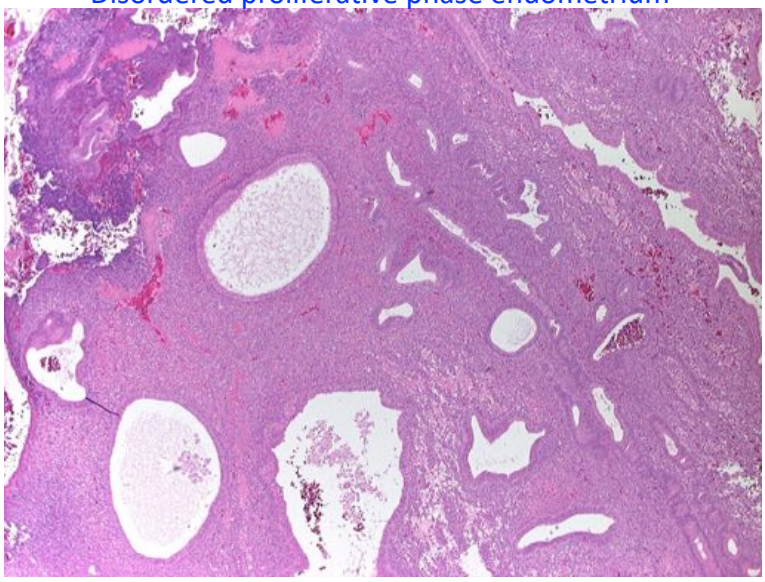

Fragmentation due to break down

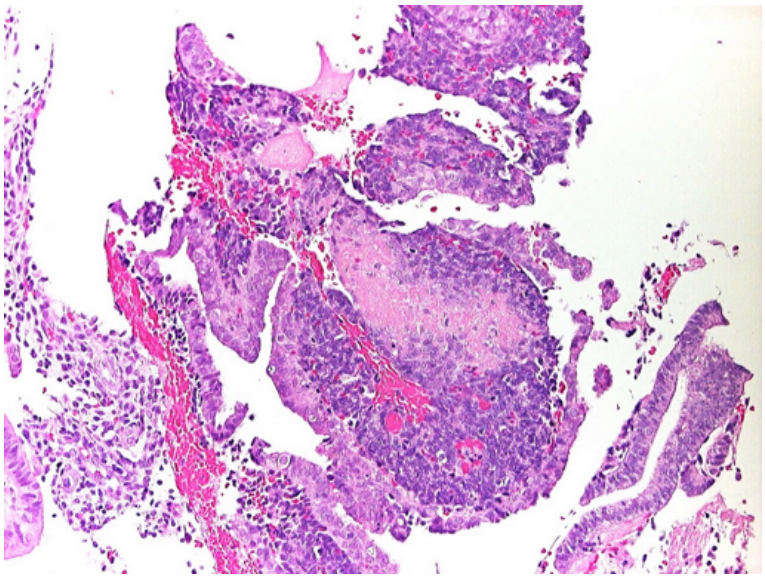

Hyperplasia without Atypia

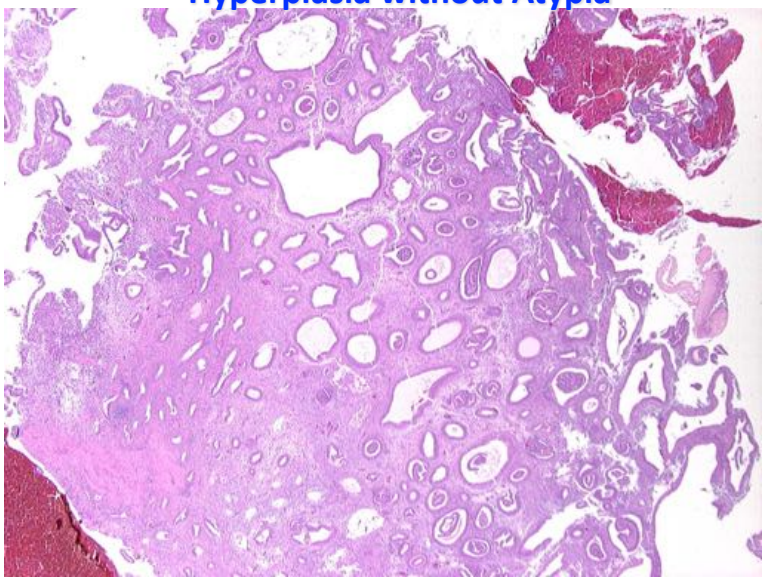

Hyperplasia without Atypia

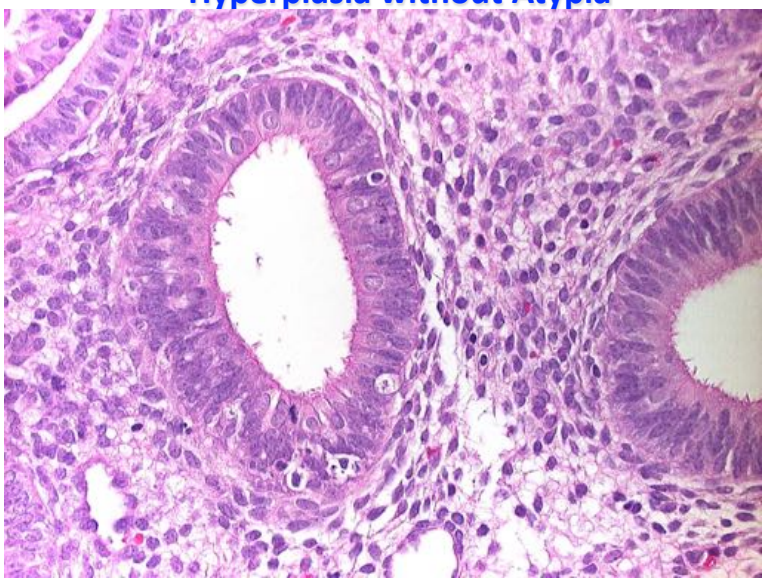

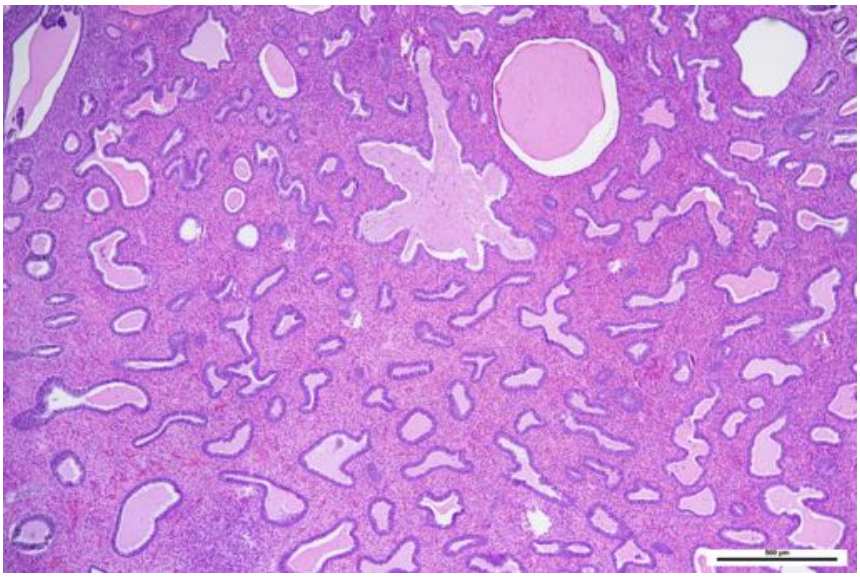

Hyperplasia without Atypia

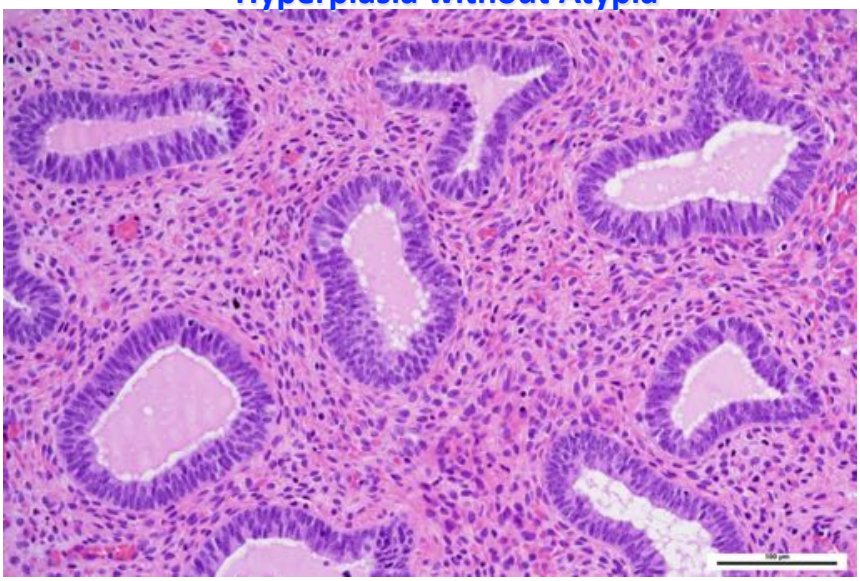

Atypical hyperplasia

- Focal or diffuse thickening of endometrium
- Densely packed tubular or branched glands with cytological changes
- Glands back to back with reduced stroma
- Nuclear atypia:
  - enlarged nuclei with variation in size and shape
  - Loss of polarity
  - Interobserver variability

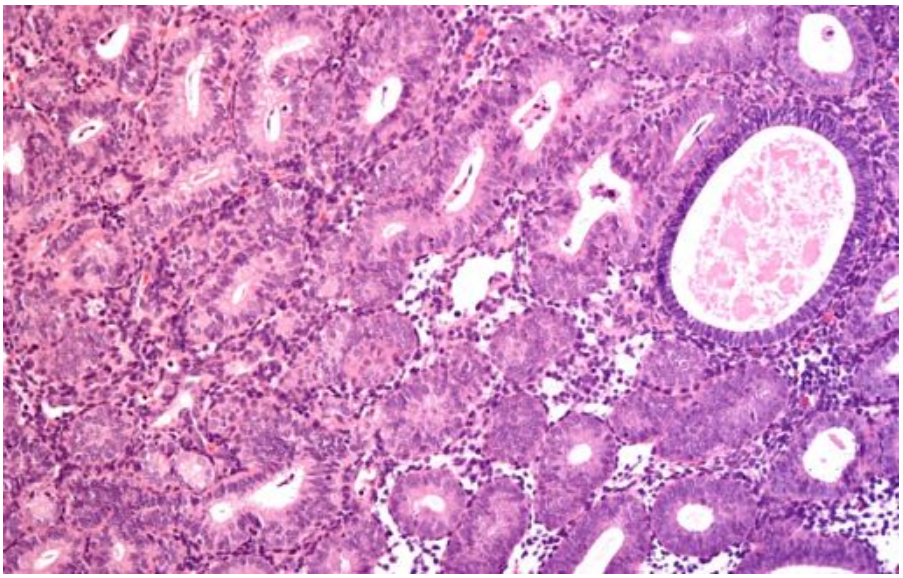

Atypical Hyperplasia

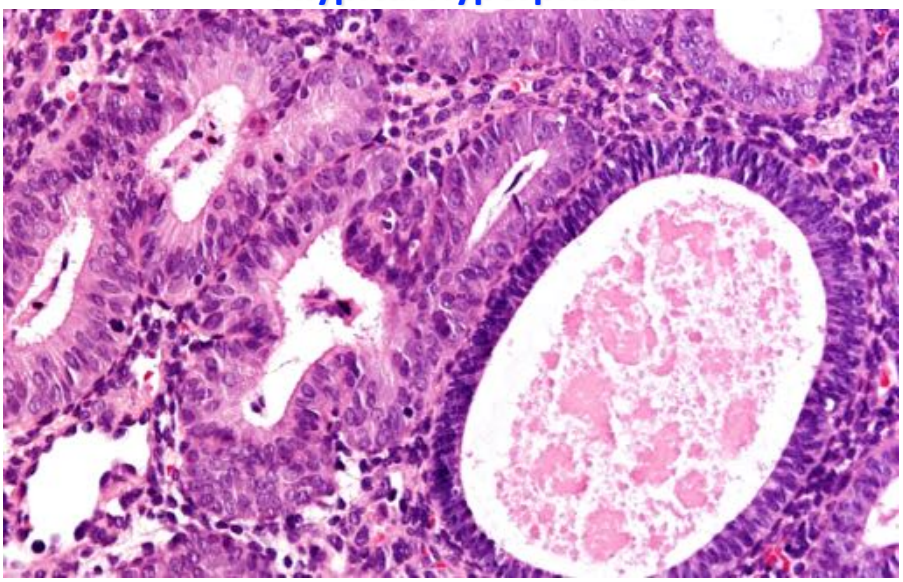

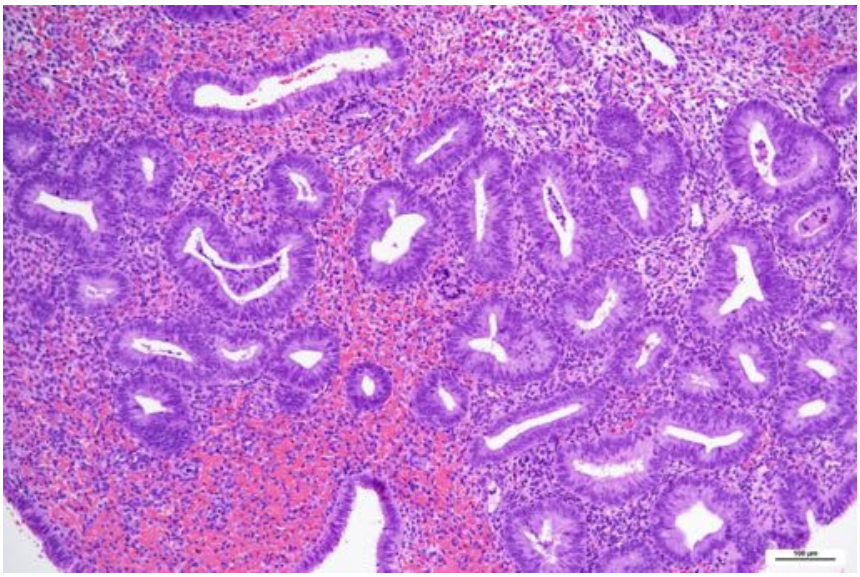

Atypical Hyperplasia

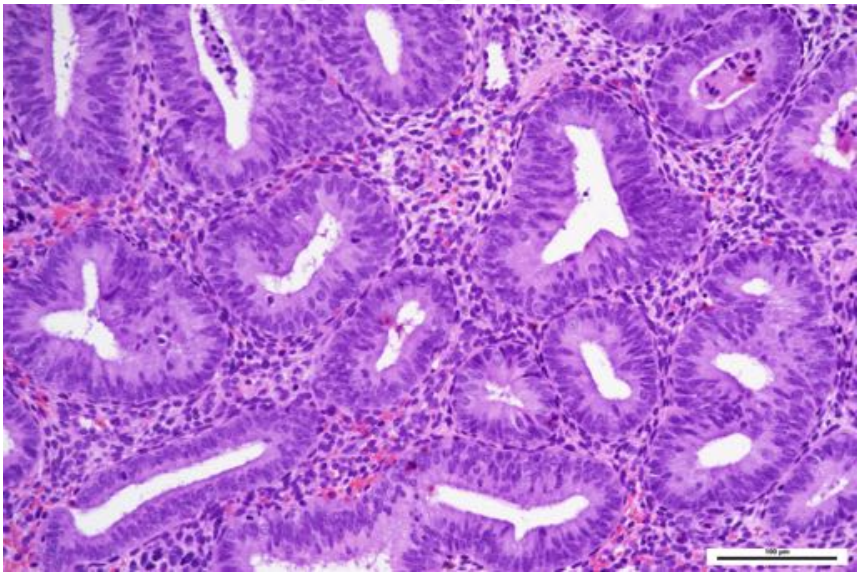

EIN Concept and Terminology

Mutter, Baak 2000

- Architecture: area of glands>stroma (VPS<55%)
- Cytologic alteration: cytology differs between architecturally crowded focus and background
- Size >1mm
- Exclude mimics: benign conditions with overlapping criteria (basalis, secretory, polyps, repair, disruption artifact, cystic atrophy, lower uterine segment etc.)
- Exclude cancer: mazelike or " rambling" glands, significant cribriforming, solid epithelial areas

The EIN Concept



- VPS strongest predictor of progression
- VPS<55%: special importance of nuclear pleomorphism
- D-score (=VPS/standard deviation of shortest nuclear axis /outer surface of glands)

Focal lesions seem to be significant

Clinical outcome in diagnostically ambiguous foci of 'gland crowding' in the endometrium

Eric C Huang, George L Mutter, Christopher P Crum and Marisa R Nucci

Division of Women's and Perinatal Pathology, Department of Pathology, Brigham and Women's Hospital, Harvard Medical School, Boston, MA, USA

- Not all 3 criteria of EIN fulfilled, particularly atypia
- 143 cases with follow up 1 yr and>: AEH/EIN in 19%, carcinoma in 4%
- Term underscores importance of follow up

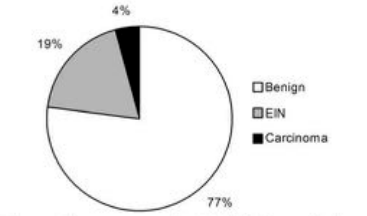

Figure 5 Follow-up outcome after initial 'gland crowding' (143 total cases).

Modern Pathology (2010) 23, 1486–1491; doi:10.1038

Joint Loss of PAX2 and PTEN Expression in Endometrial Precancers and Cancer

Nicolas M. Monte[1], Kaitlyn A. Webster[1], Donna Neuberg[2], Gregory R. Dressler[3], and George L. Mutter[1]

Table 2. Proportion of endometrial tissue samples showing loss of PAX2 and PTEN protein expression, by diagnosis

	Normal proliferative, $N = 191$	Intraepithelial neoplasia (EIN), $N = 52$	Cancer, $N = 62$	Kruskal-Wallis P^*
PAX2 null	35.6%	71.2%	77.4%	<0.0001
PTEN null	49.2%	44.2%	67.7%	0.064
Joint PAX2 and PTEN null	20.9%	30.8%	54.8%	<0.0001
Joint PAX2 and PTEN Expression	36.1%	15.4%	9.7%	<0.0001
McNemar χ^2 test of agreement of PAX2 and PTEN loss†	$P = 0.004$	$P = 0.008$	$P = 0.201$	
Pearson's χ^2†	$P = 0.048$	$P = 0.822$	$P = 0.335$	

- Common and separate loss of PTEN and Pax2
- Loss of PTEN: early but carcinoma>> EIN
- Loss of Pax2: early (intraepithelial neoplasia>>normal)

Cancer Res, 2010

Loss of PTEN / Pax2 in Normal Proliferiative Endometrium



Monte et al., Cancer Res 2010

- Frequent (35 / 49%), but only in a few glands
- Mostly all epithelia of a gland involved
- Without confluence (no clonal expansion)

AEH

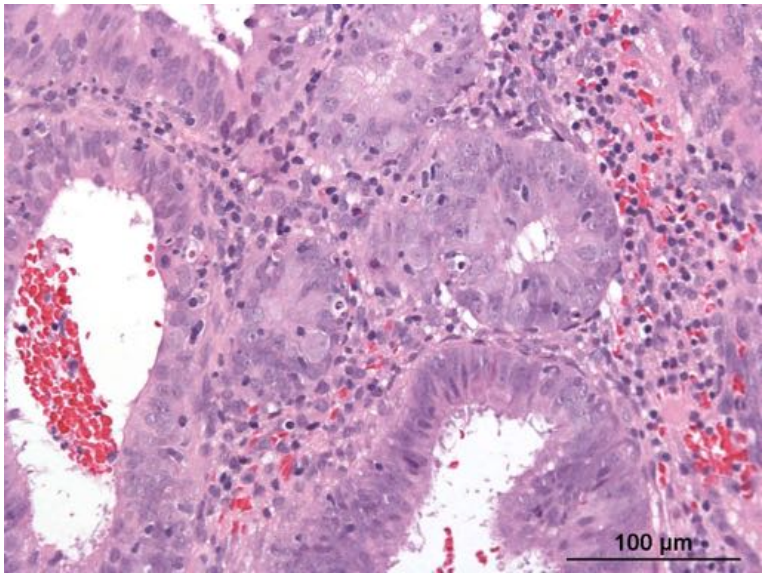

PTEN Loss in AEH

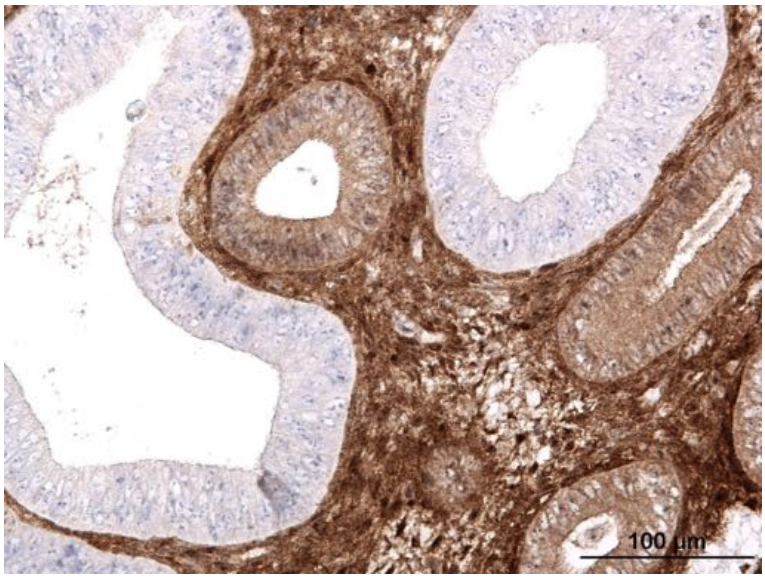

Pax-2 Loss in AEH

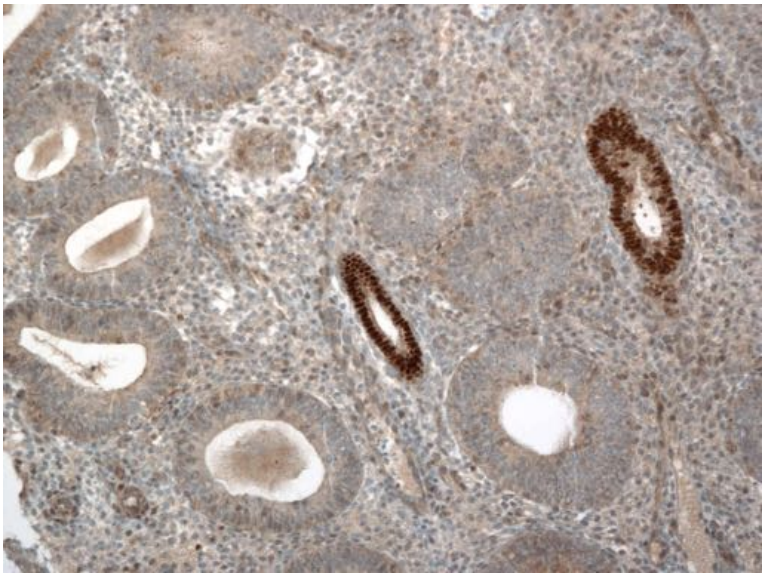

PTEN/Pax-2 Loss in AEH/EIN

- Pax2 negativity in 80%
- PTEN negativity in 50%
- Combined Pax2/PTEN negativity in 30%
- About 15% of AEH have retained staining
- Diagnostic aid (immunohistochemistry)
- Does not replace histology

Monte et al., Cancer Res, 2010

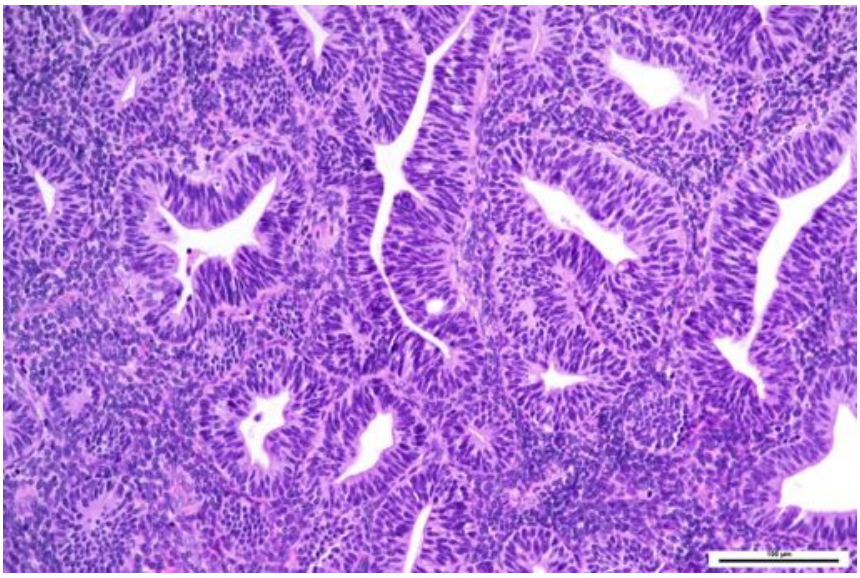

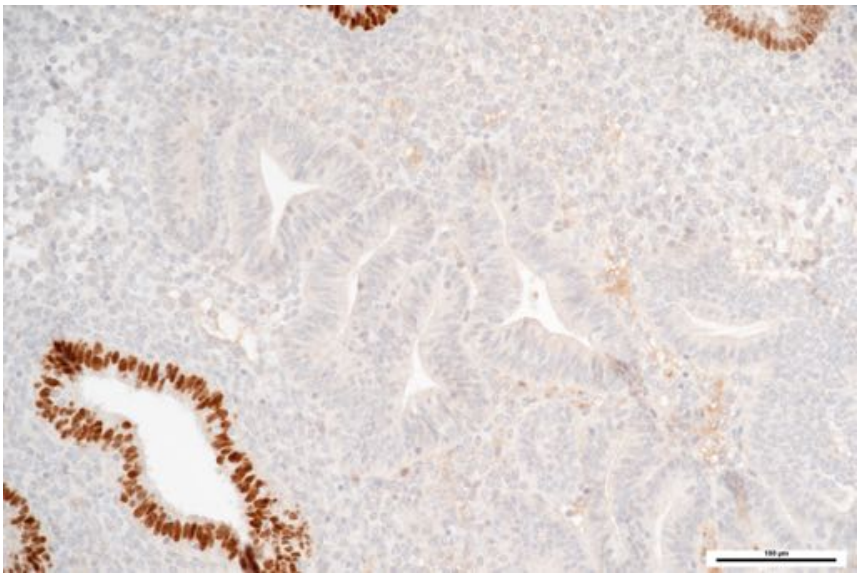

Pax2

Prediction of myoinvasive carcinoma

- Extreme glandular crowding (>95% of area covered) and
- Cribriform foci of any size
- Seem to have the highest predictive value for subsequent hysterectomy

Mittal 2014

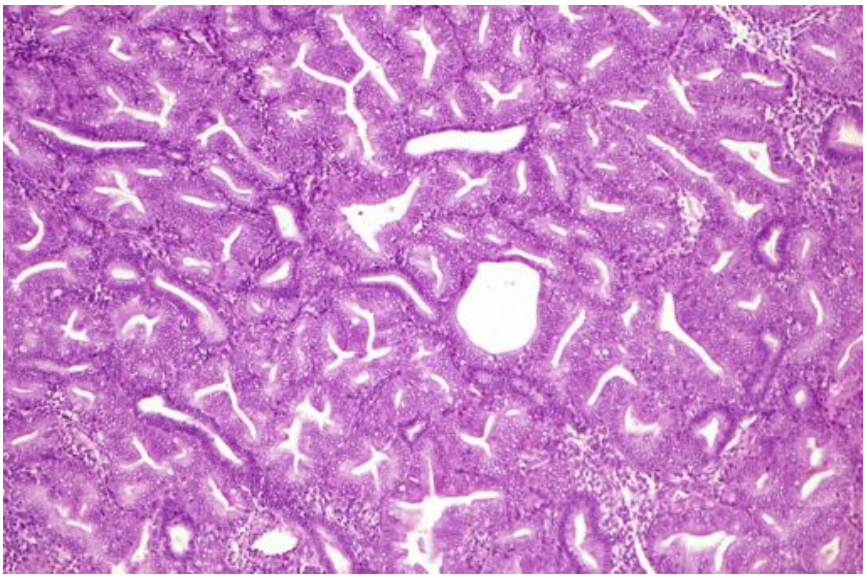

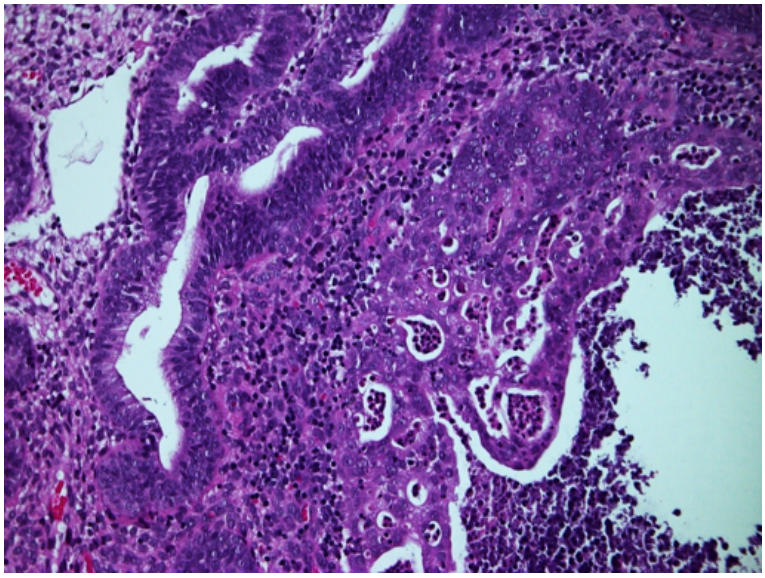

Metaplasia

- Different types of cytoplasmic differentiation
- Not in normal endometrium: “change”
- Reaction on hormonal stimulation, hyperplasia, endometritis, polyps, trauma etc.
- Focal or diffus, with/ without hyperplasia
- Mixture of different types possible
- Per se no precursor; clinical management depends on underlying lesion

Types of metaplasia

- Squamous
- Eosinophilic
- Papillary syncytial
- Ciliated (tubal)
- Secretory,
- Hob nail
- Mucinous

Papillary syncytial metaplasia associated with breakdown

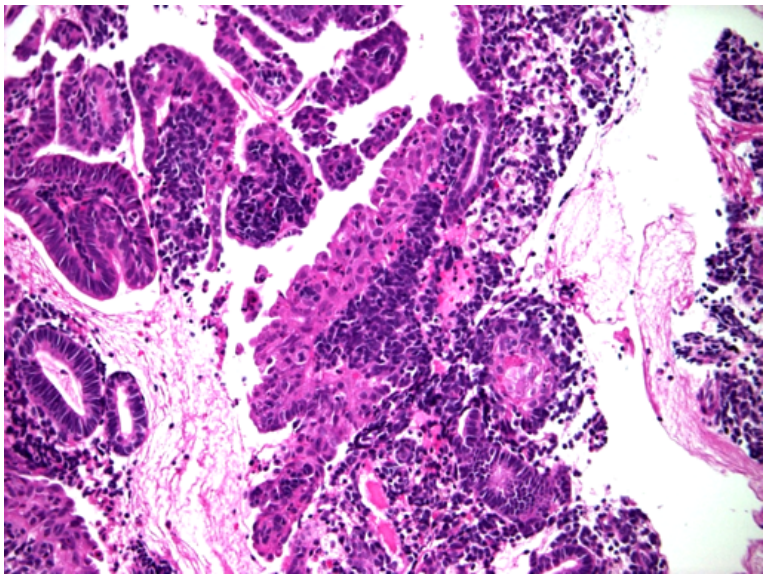

Eosinophilic and tubal changes may concur

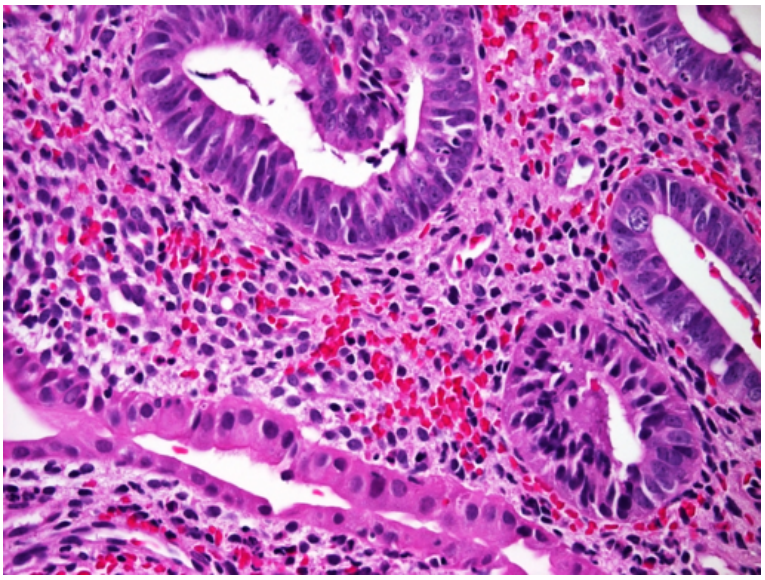

Endometrial hyperplasia with extensive ciliae (”tubal changes“)

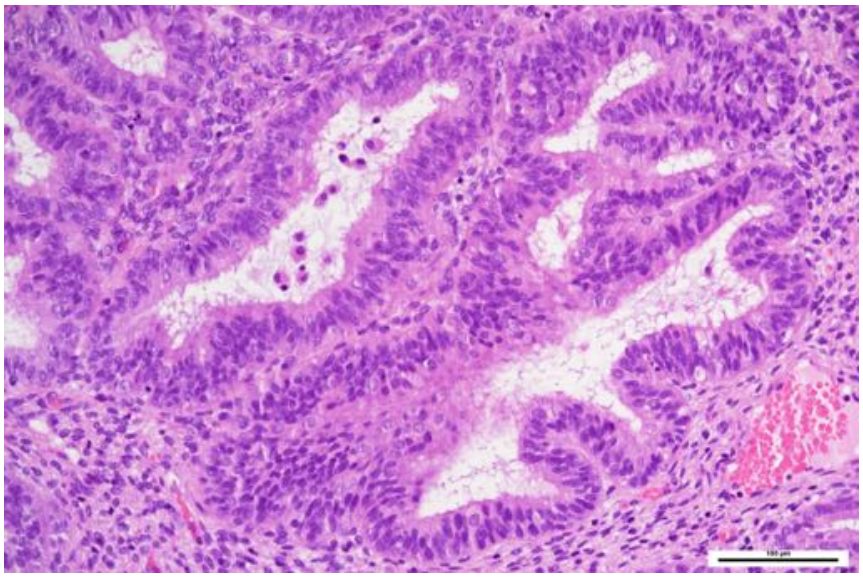

Endometrial hyperplasia with mucinous changes

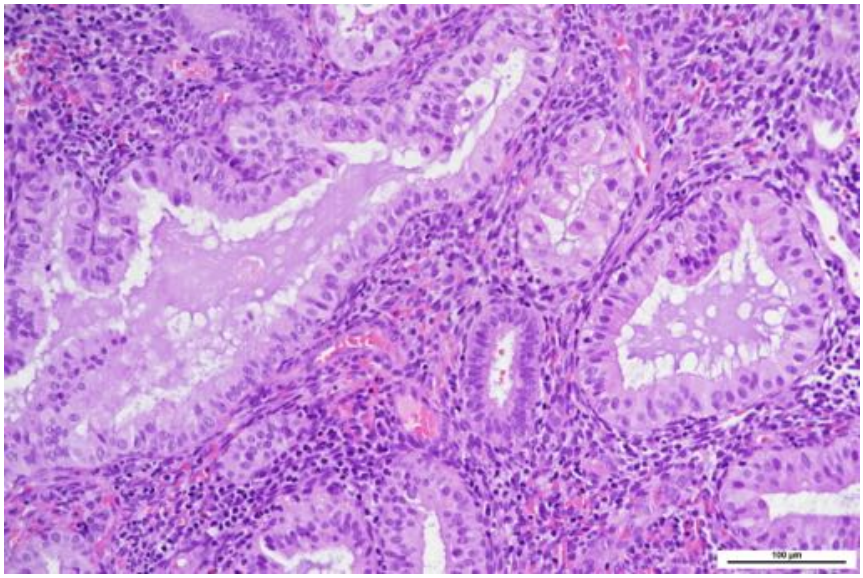

Squamous metaplasia associated with endometrial hyperplasia

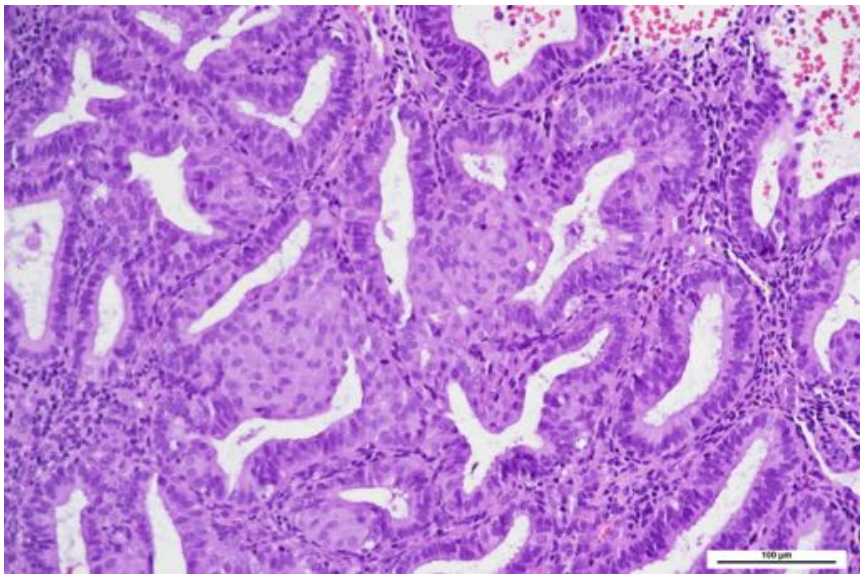

Mucinous Endometrial Epithelial Proliferations: A Morphologic Spectrum of Changes with Diverse Clinical Significance

Marisa R. Nucci, M.D., Chaya J. Prasad, M.D., Christopher P. Crum, M.D., George L. Mutter, M.D.
Department of Pathology, Division of Women's and Perinatal Pathology, Brigham and Women's Hospital and Harvard Medical School, Boston, Massachusetts

Type	Criteria	Atypia	Carcinoma in follow up
A	inconspicuous or micropapillary changes and tufting	absent	0
B	microglandular pattern	absent	65%
C	complex villous or cribriform structure	present	100%

Modern Pathol 12: 1137-42, 1999

Papillary proliferations+/-mucinous

- Distinct from usual endometrial hyperplasia by architecture and cellular differentiation
- Mucinous differentiation not always present
- Architecture may also be cribriform
- Simple and complex lesions
- Complex lesions seem to be involved in:
  - Increased frequency of K-RAS mutations (50%)
  - Frequent association with mucinous carcinoma

Yoo 2012, Alomari 2013, Rawish 2017, Liu 2019

WHO 2014

- Mucinous carcinoma
  - If confluent pattern present, even with little or no atypia
- Atypical mucinous glandular proliferations
  - For other lesions not meeting these criteria

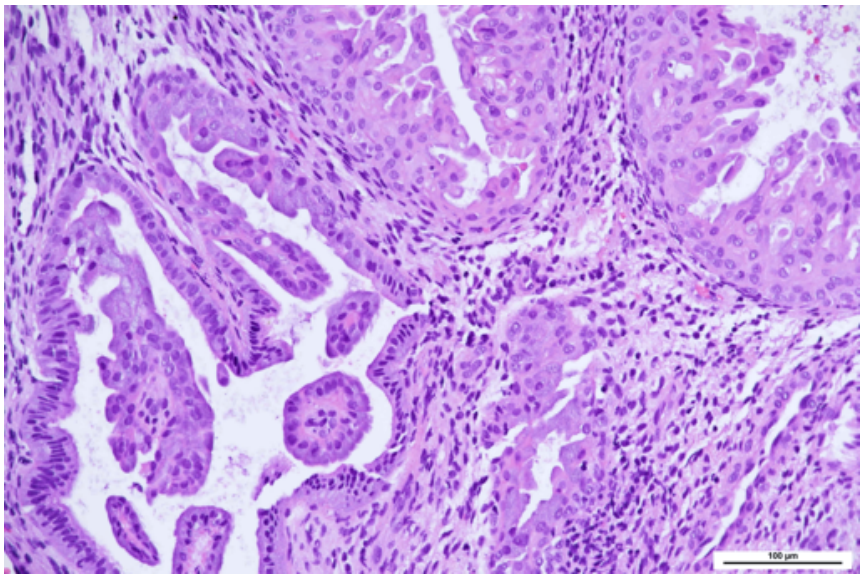

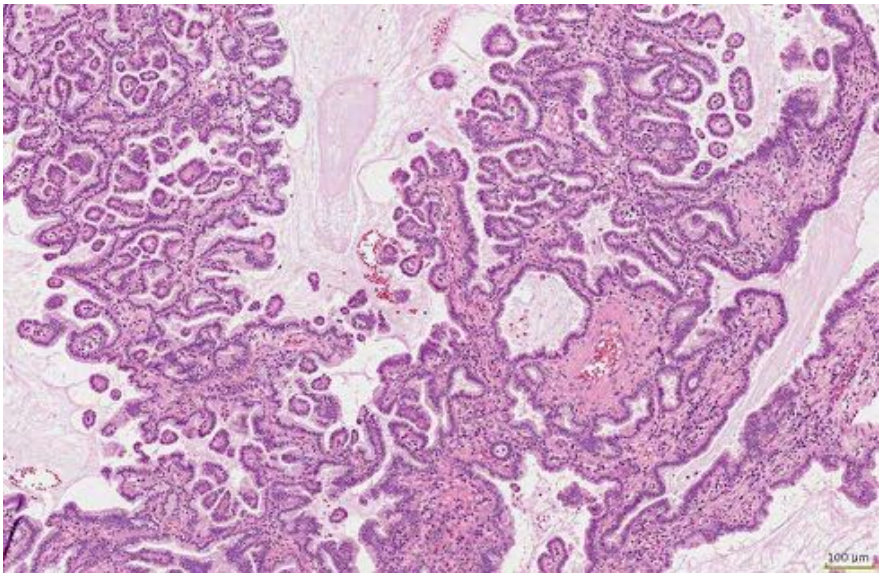

89 year-old female: curetting

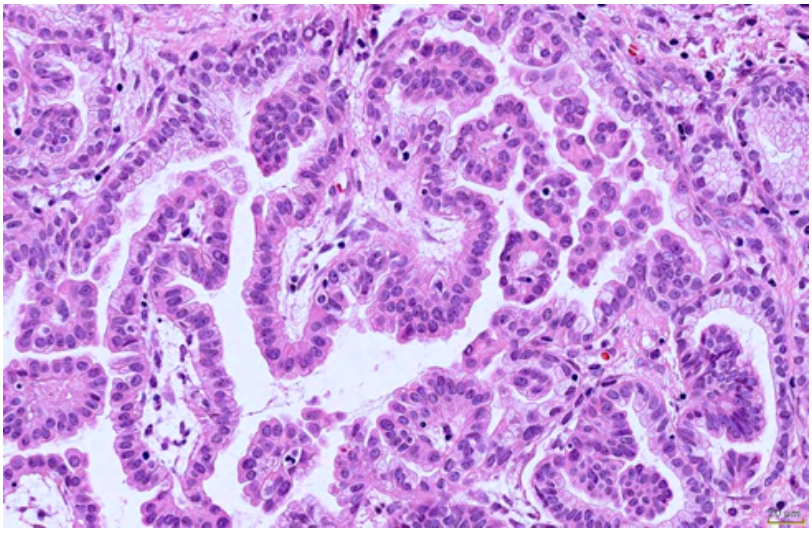

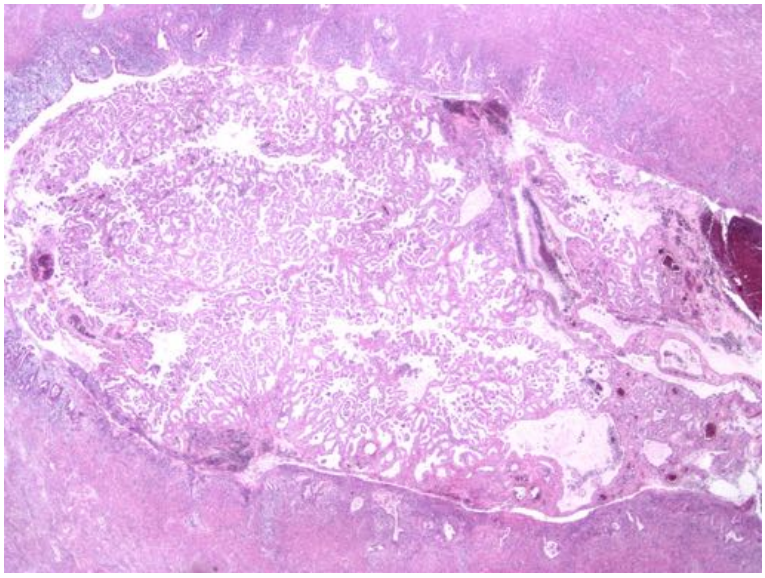

Hysterectomy of the same patient

Caveat: Telescope phenomenon in benign endometrium

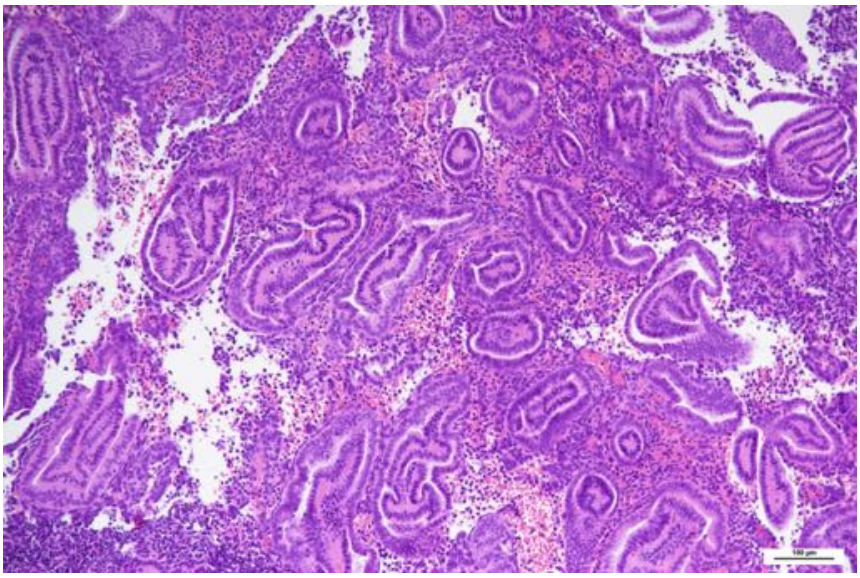

Papillary proliferations/changes

- Papillary changes may occur in neoplastic and non-neoplastic endometrium
- Papillae are not criterium for carcinoma but carcinomas may show papillary architecture
- If you find papillae rule out cancer
- Association with mucinous differentiation
- “papillary hyperplasia”
- Papillary syncytial metaplasia: regeneration

Distinction between AEH/WDEC

- Best evidence for invasion: Myoinvasion
- Best evidence for stromal invasion:
  - Stromal disappearance between adjacent glands: Significant solid, cribriform, maze-like or villoglandular architecture
  - Stromal desmoplastic response
- Stromal foam cells: suggestive, not diagnostic
- Papillary growth and extensive squamous metaplasia may also occur in benign lesions

Endometrioid carcinoma, G1: Confluent growth, cribriform

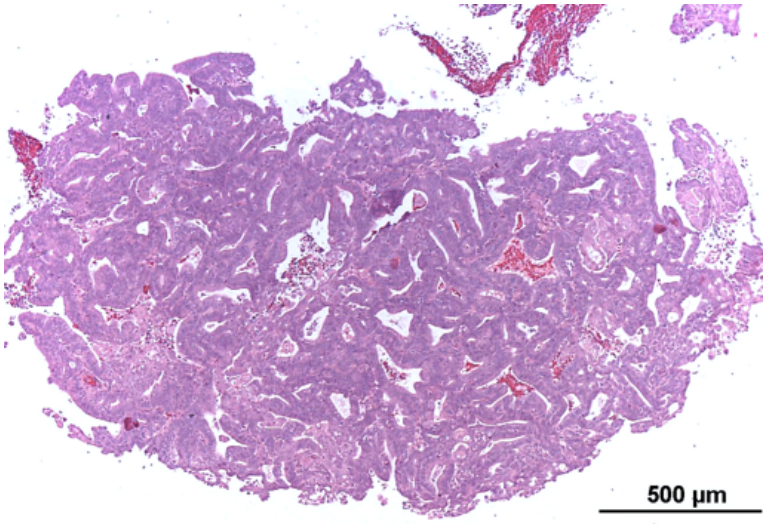

Endometrioid carcinoma, G1: Confluent growth, maze-like pattern

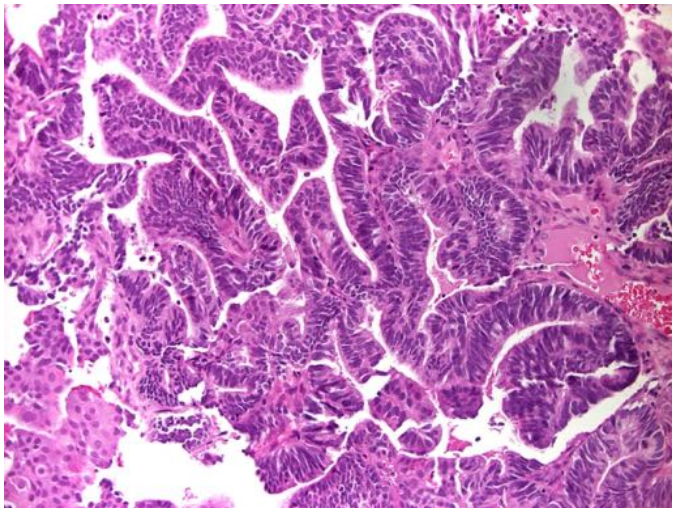

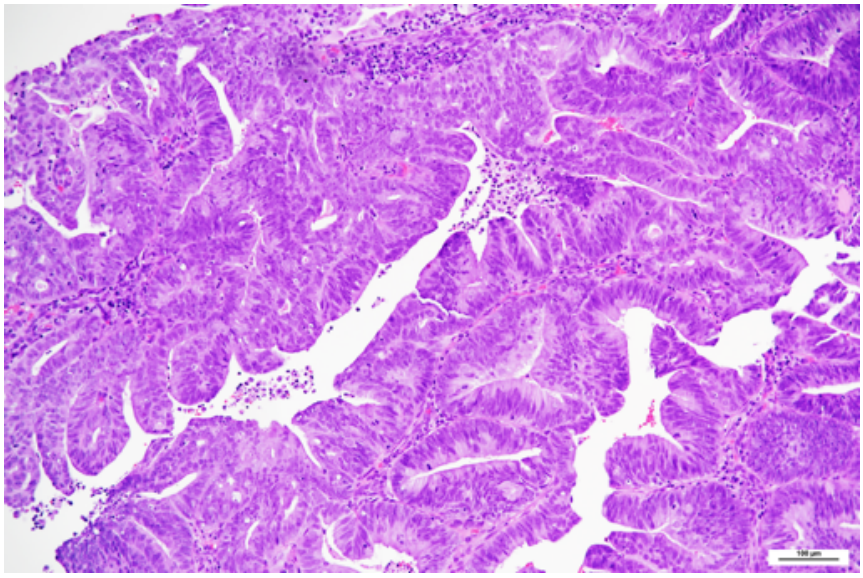

Confluent pattern with squamous morules: diagnostic challenge

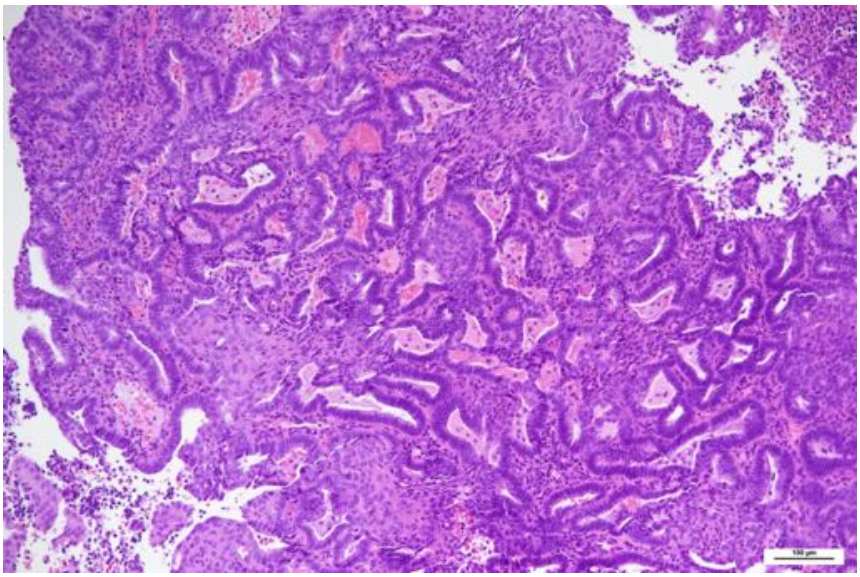

Endometrioid carcinoma, G1: Invasive growth with desmoplasia

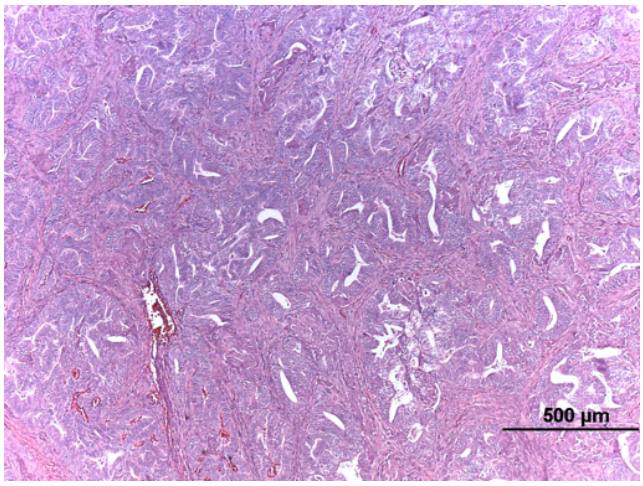

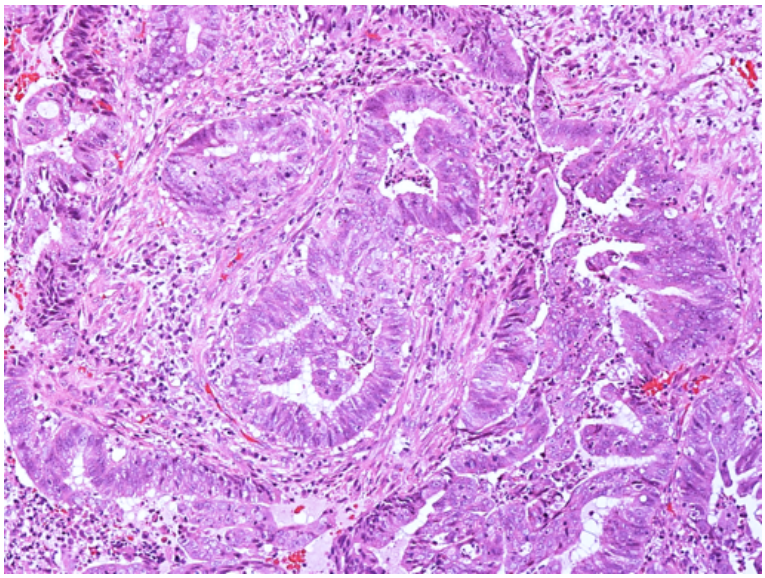

Minimal deviation pattern

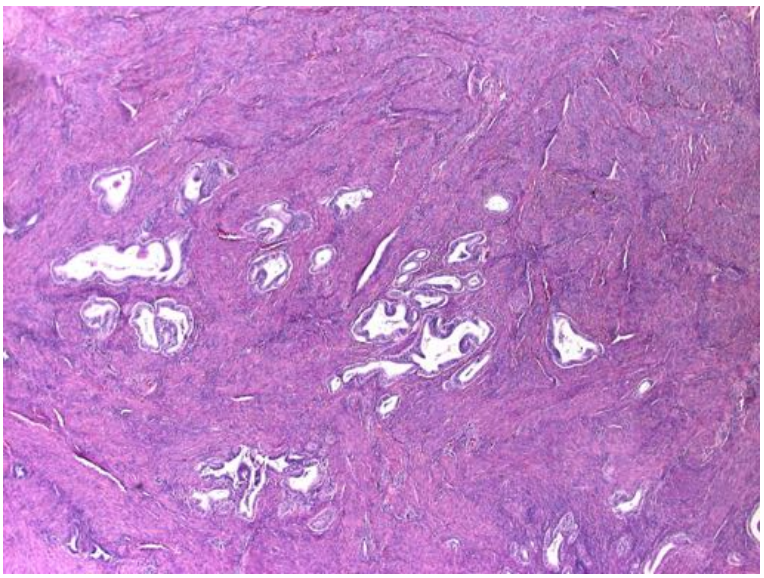

Serous Endometrial Intraepithelial Carcinoma (SEIC)

- Considered as non-invasive carcinoma, not as typical precursor
- “superficial spread“ of serous carcinoma
- Distinction from minimally invasive SC difficult
- In up to 2/3 of cases extrauterine disease
- Mutant TP53 pattern typical: all or null
- Cyclin E1 overexpression
- High Ki67

SEIC

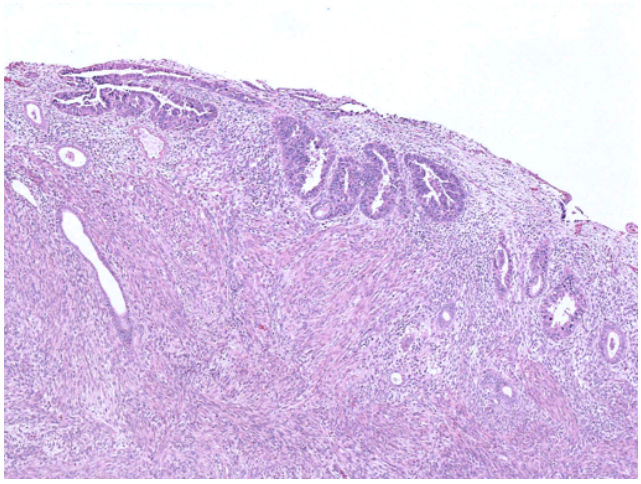

SEIC

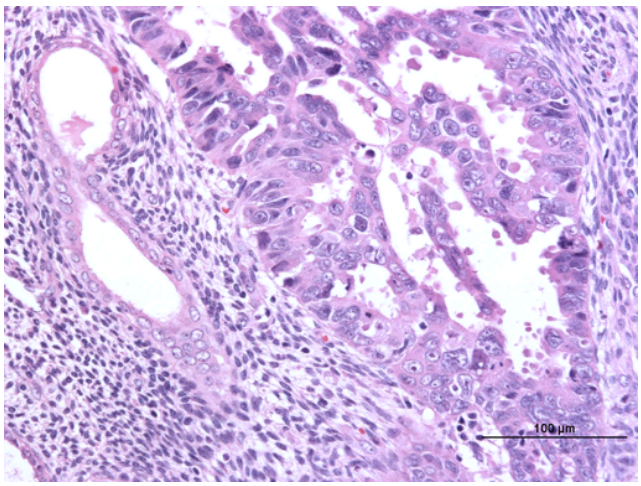

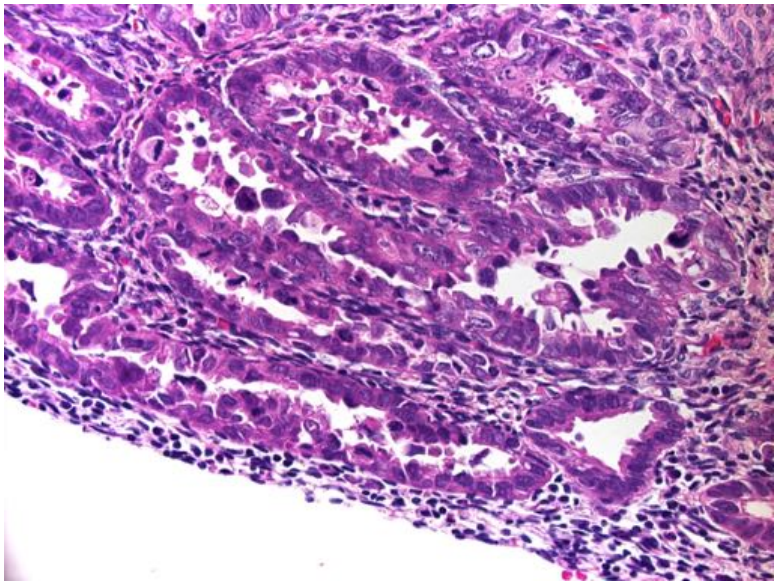

SEIC: Mutant P53 and high Ki67

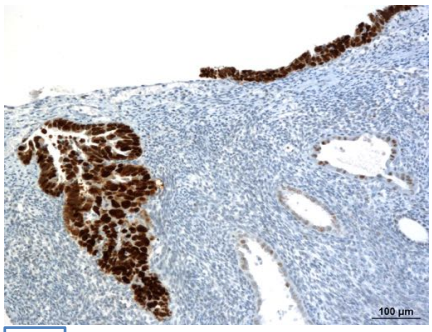

p53

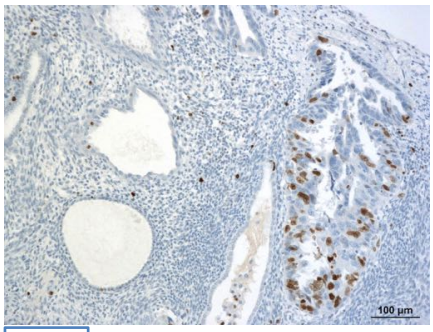

Ki-67

Thank you for your attention!




