TECHNOLOGY TRANSFER IN DIAGNOSTIC PATHOLOGY
10TH CENTRAL EUROPEAN REGIONAL MEETING

Gynecological Pathology

ORGANIZED BY THE HUNGARIAN DIVISION OF THE INTERNATIONAL ACADEMY OF PATHOLOGY



Ovarian Mucinous Tumours and Metastases

Sigurd F. Lax

JOHANNES KEPLER UNIVERSITY LINZ

LKH Graz II
Academic Teaching Hospital of the Medical University Graz
Pathology

KAGes

Epithelial tumours of the ovary

- Serous tumours
- Mucinous tumours
- Seromucinous tumours
- Endometrioid tumours
- Clear cell tumours
- Brenner tumours
- Undifferentiated carcinoma

Biological behavior

- 3 categories:
  - Benign
  - Atypically proliferating (Borderline)
  - Malignant

Distribution of epithelial ovarian tumours

	Benign	Borderline	Malignant	Total
Serous	31 %	5.5%	16.5%	53%
Mucinous	24%	4%	4%	32%
Endometrioid	<0.5%	0.5%	5.5%	6%
Clear cell		0.2%	2.5%	3%
Urothelial	3.1%			3%
Total	58%	10%	32%	

Blaustein, Pathology of the female genital tract, 2004

Pathogenetic model of ovarian carcinoma

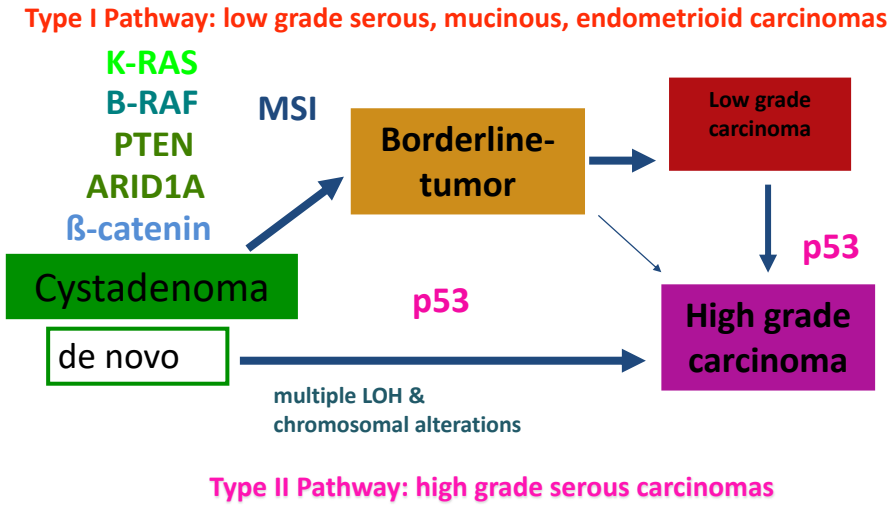

Pathogenesis of ovarian carcinomas

- Adenoma-carcinoma Sequence
  - Low grade serous (B-RAF, K-RAS)
  - Mucinous (K-RAS)
  - Endometrioid (PTEN, ARID1A)
  - Clear cell (ARID1A)
  - Sero-mucinous (ARID1A?)
- De novo (intraepithelial carcinoma)
  - High grade serous (p53)

Pathogenetic model for ovarian mucinous carcinomas

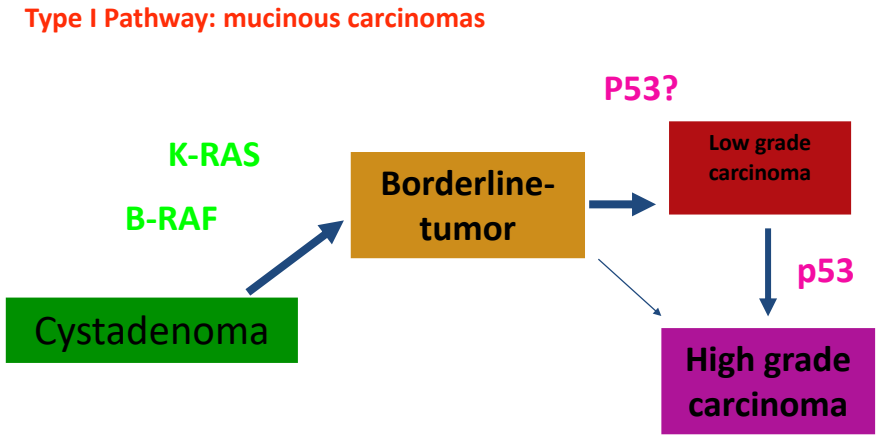

Origin of ovarian mucinous neoplasms

- Derived from surface epithelium of ovaries and inclusion cysts through metaplasia
- Development from transitional epithelium at the tuboperitoneal junction (Walthardt nests)
- Development from mucinous epithelium in teratomas

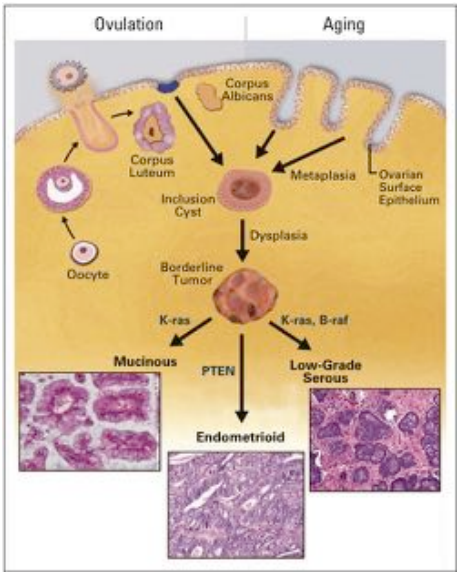

Levanon et al., JCI 2008

Tubo-peritoneal Junction

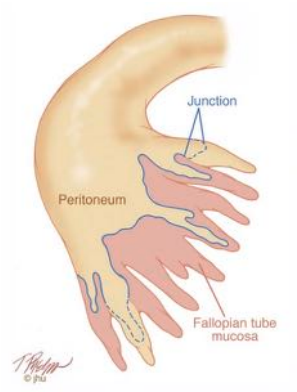

Site of transitional cell metaplasia (Walthardt nests) from which mucinous neoplams and Brenner tumors arise

Mucinous and Brenner tumours

- 25% of mucinous tumor Brenner component
- 16% of Brenner tumors mucinous component
- Walthard nests in 50% of the mucinous and 59% of the Brenner tumors compared to 28% of the controls
- A putative association remains unexplained

Seidman et al., APLM 2008

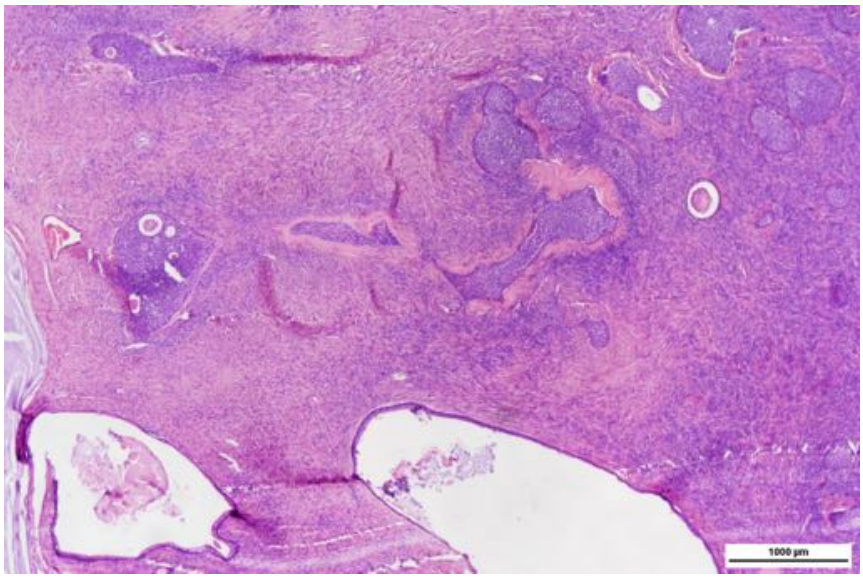

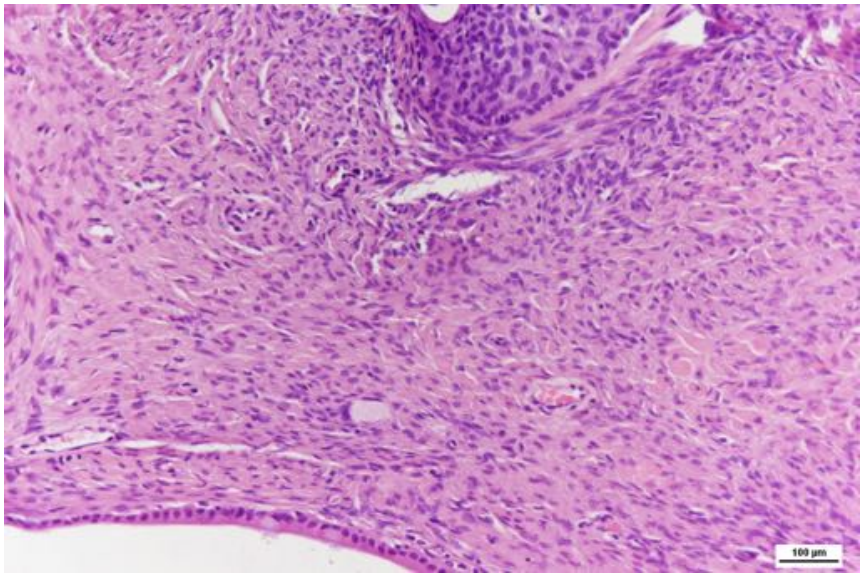
100 µm

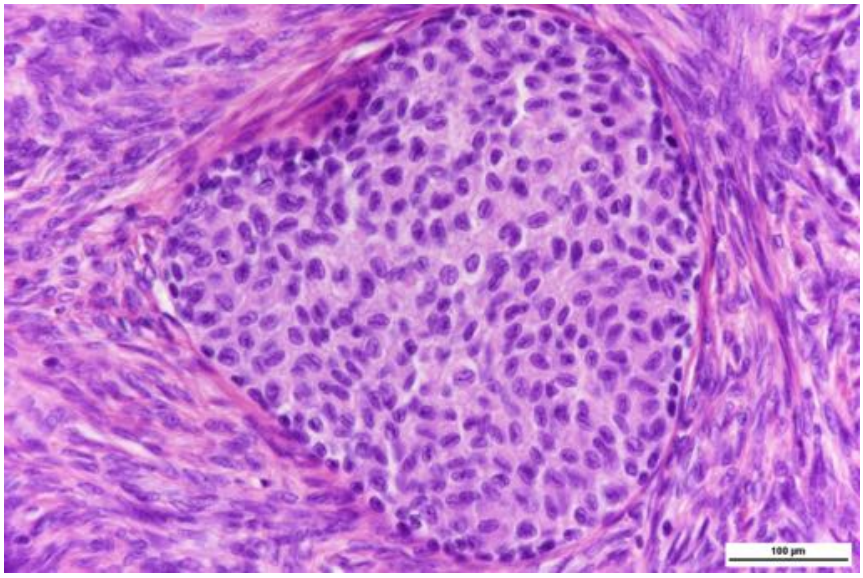
100 µm

Mucinous tumours

- Primary ovarian
  - Benign, atypically proliferating, malignant
- Metastatic
- Metastases can mimic a primary ovarian neoplasm

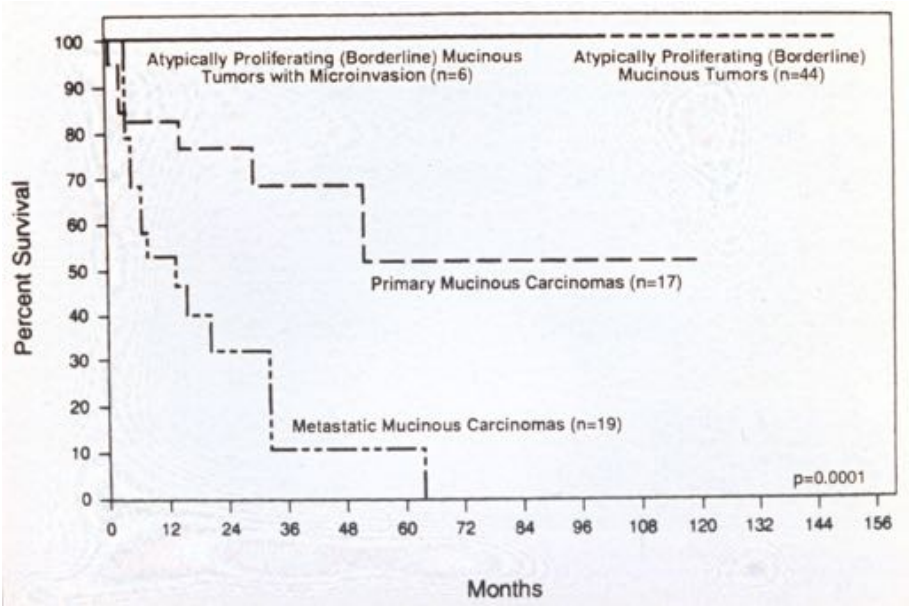

Riopel et al. Am J Surg Pathol, 1999

Mucinous tumours: General

- Gastro-intestinal differentiation (varying content of goblet cells)
- Endocervical type> seromucinous tumours
- Majority is unilateral, particularly cystadenomas and borderline tumours
- Adenoma>carcinoma sequence reflected by a mixture of benign, atypical proliferating and malignant areas within the same tumour
- Borderline tumours: non-atypical areas

Mucinous cystadenoma

- Less frequent than serous cystadenoma
- Bilateral in ca. 10-20%
- Multilocular

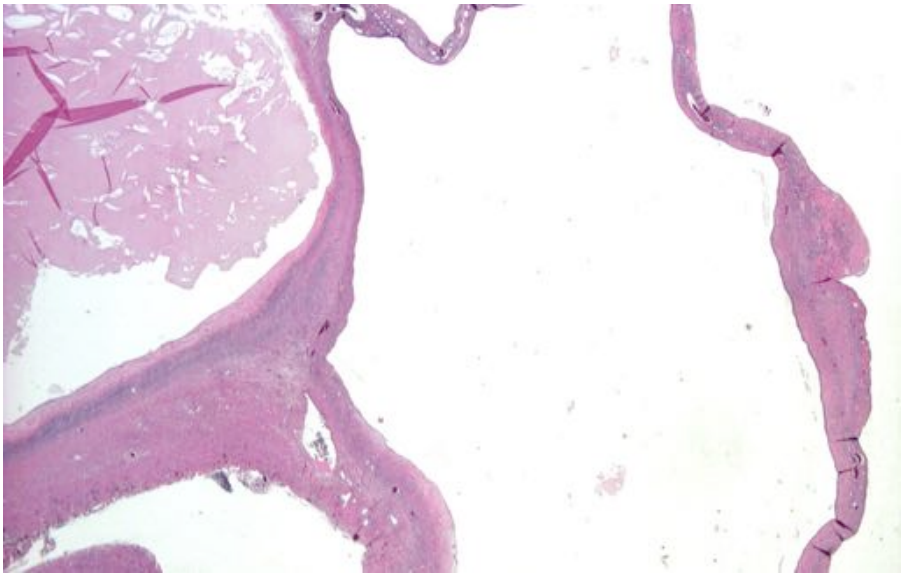

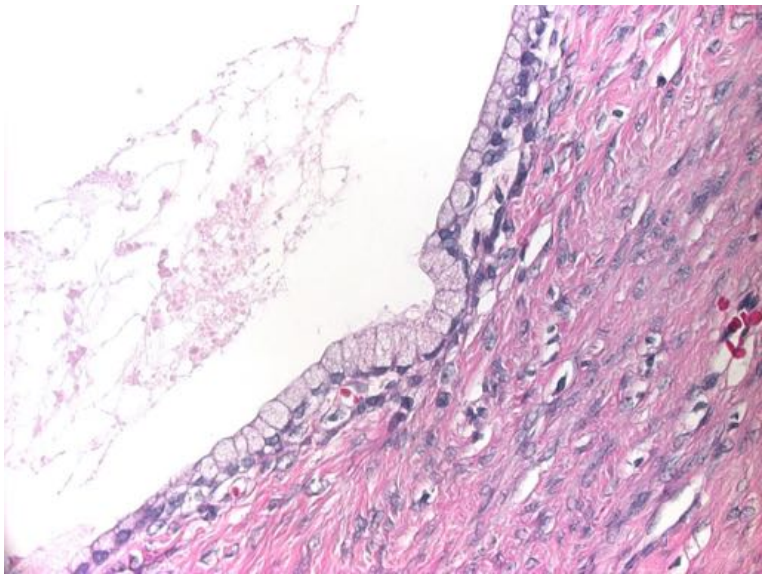

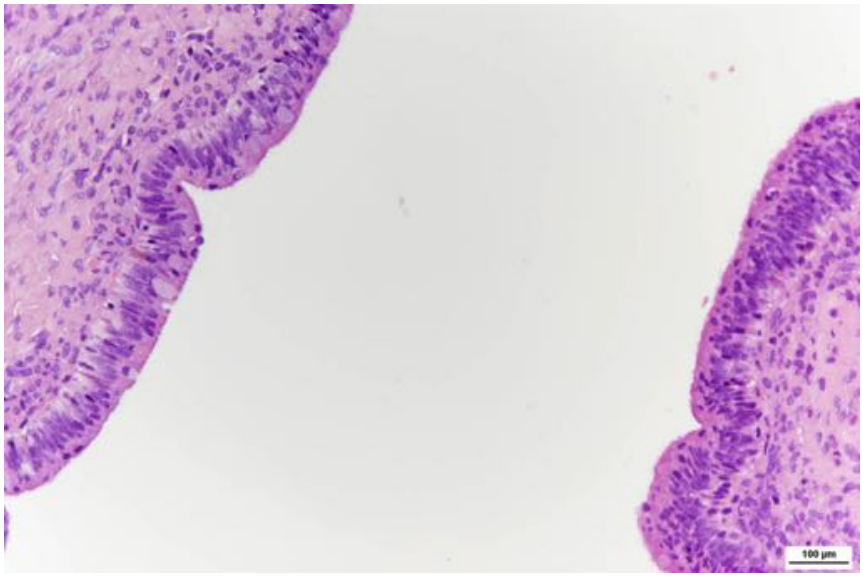
100 µm

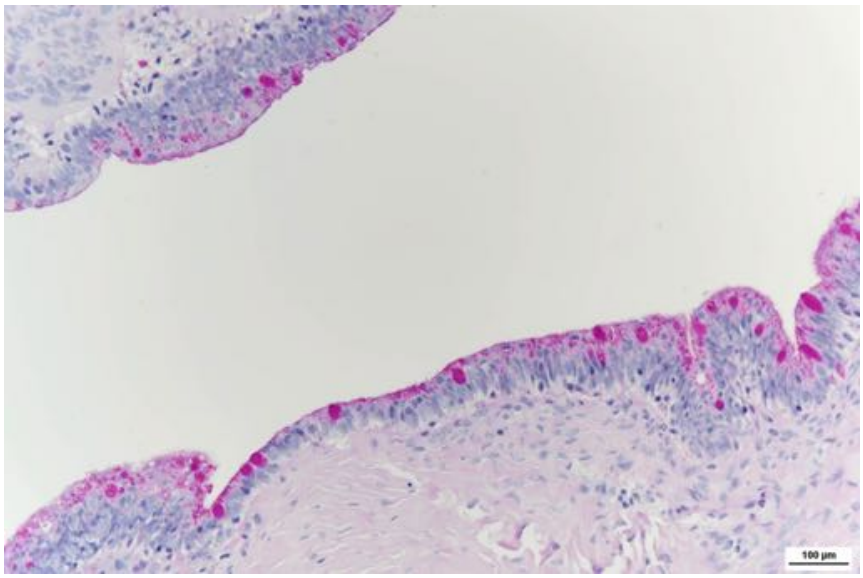
100 µm

Mucinous Borderline Tumors

- Most unilateral (stage I)
- Extraovarian disease uncommon
- Recurrences very rare if completely removed, also in case of intraepithelial carcinoma (IEC)
- Cave: Metastases from mucinous cystic lesions of the appendix and from intestinal carcinomas may "occur as" mucinous BLT
- Pseudomyxoma peritonei (PP) rare (most are in fact metastatic neoplams)



36 year-old female: a mucinous cystadenoma was removed 3 years ago

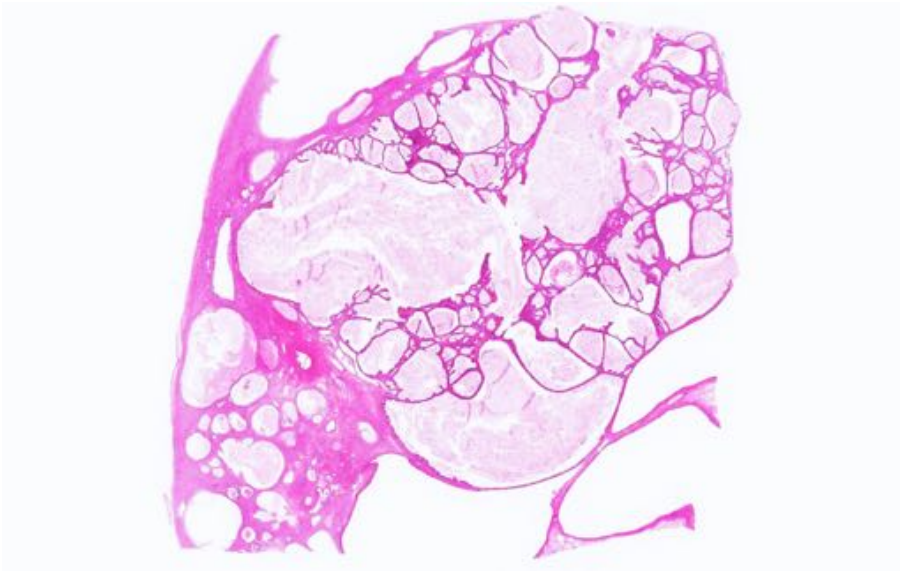

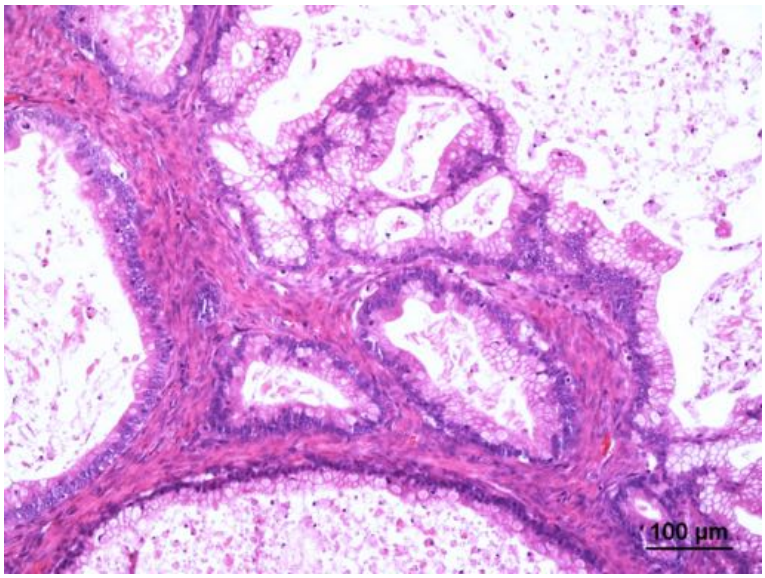
100 µm

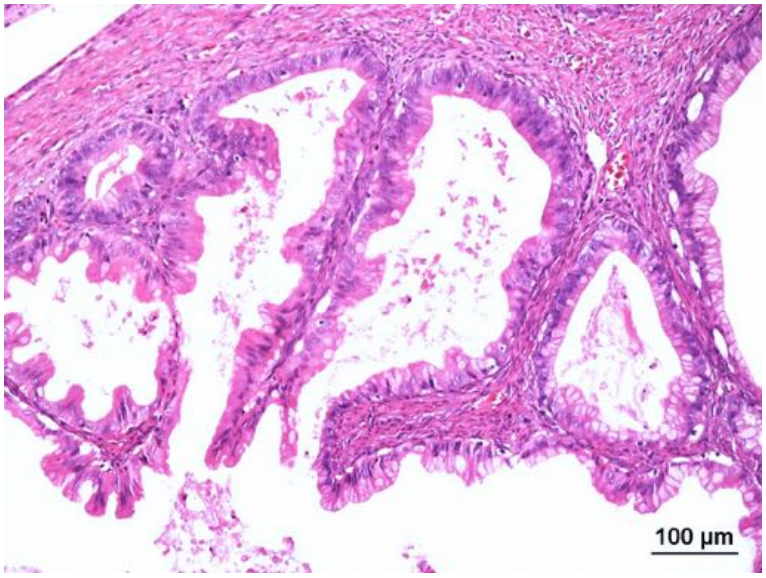
100 µm

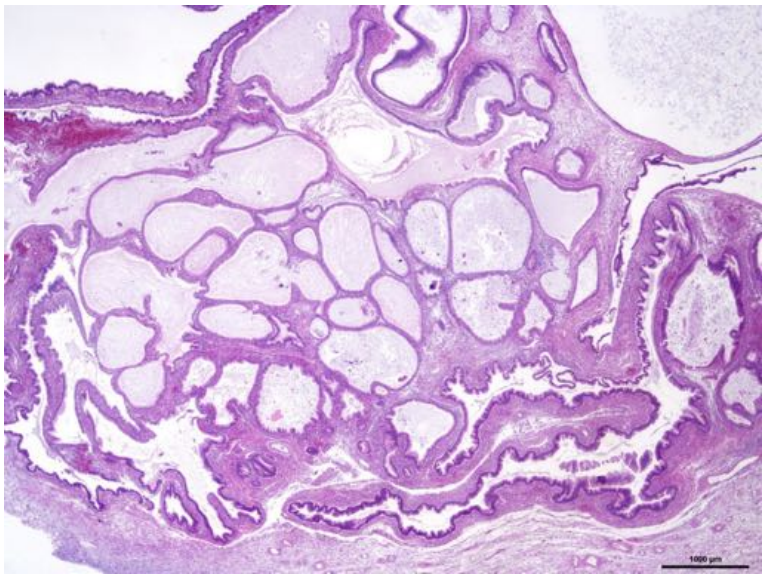

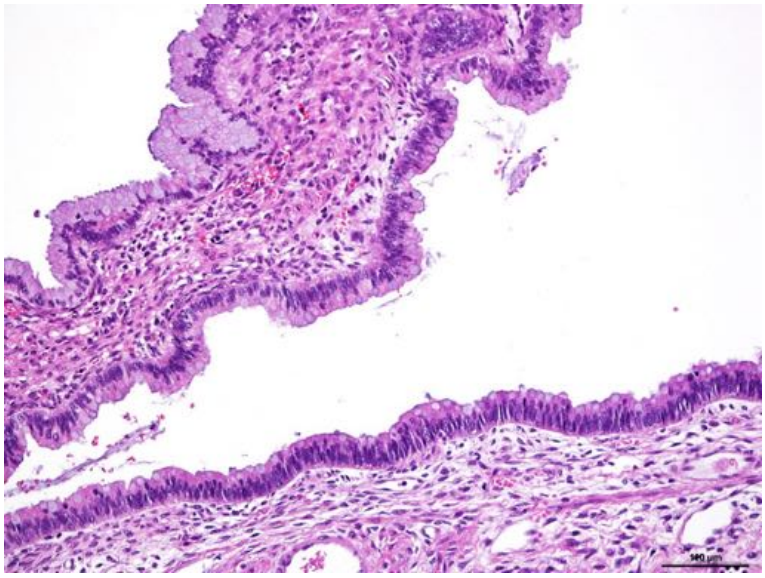

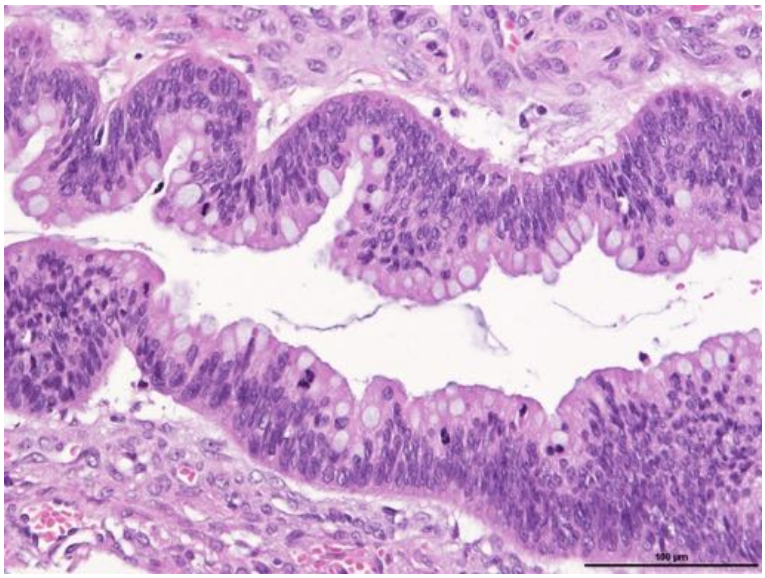

Diagnostic Criteria

- Cellular atypia and proliferation of the mucinous epithelium
- Pseudostratification with elongated hyperchromatic nuclei
- Pseudopapillae and papillae
- Mitoses

Mucinous Borderline Tumors

- No prognostic impact:
  - Intraepithelial carcinoma
  - Microinvasion (≤ 5 mm)
- Important: Exclusion of
  - Metastasis mimicking a borderline tumour
  - Invasion > 5mm

APMT with intraepithelial carcinoma

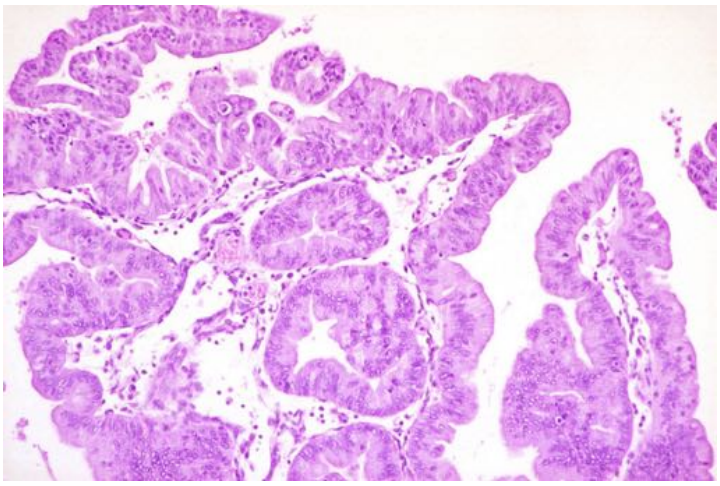

APMT with intraepithelial carcinoma

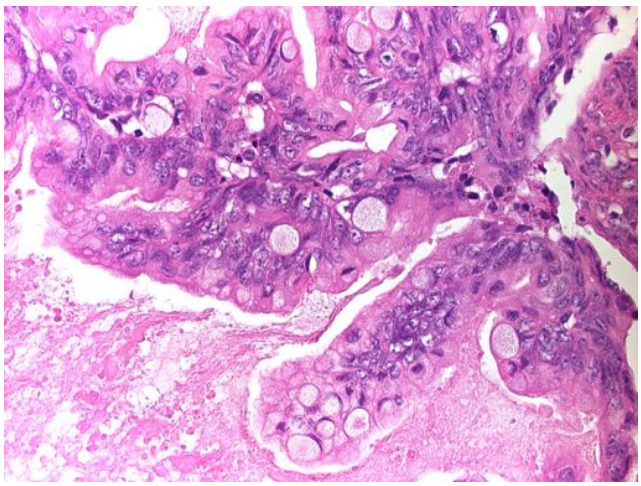

Mucinous Borderline Tumors: Diagnostic Challenge

- Invasion
- Origin: Primary versus Metastasis (Differential Diagnosis)

Pattern of Invasion of Mucinous Tumors

- Confluent (cribriform or back to back glands)
  - Most frequent in mucinous carcinoms
- Infiltrative (small nests in spaces, desmoplastic stromal reaction)
- Nodular
  - Typical for metastases
    (Pancreas, colon, upper GI tract, biliary system)

Invasion: maze-like pattern

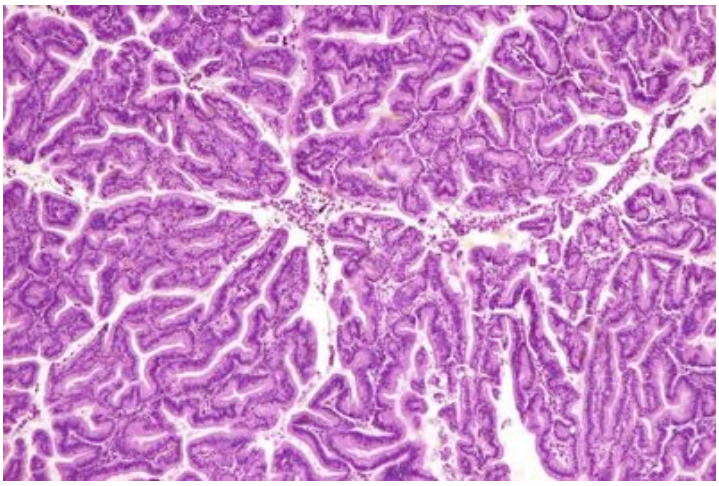



Mucinous carcinoma

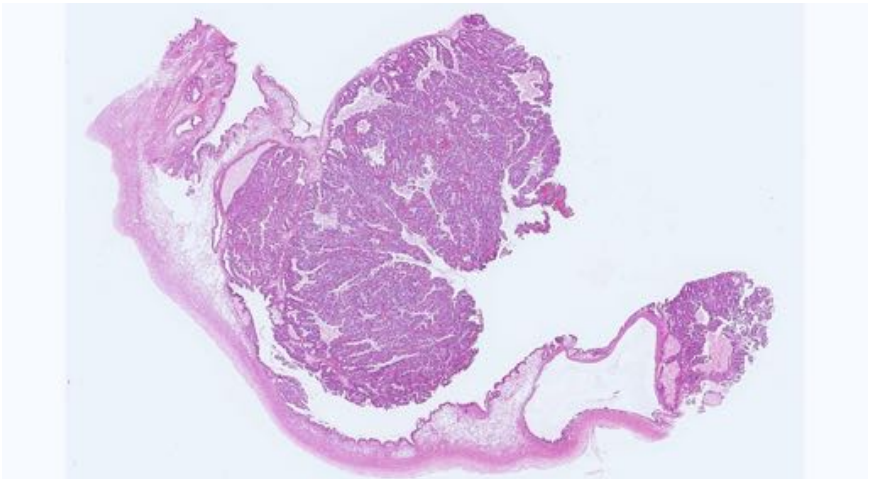

Confluent growth pattern

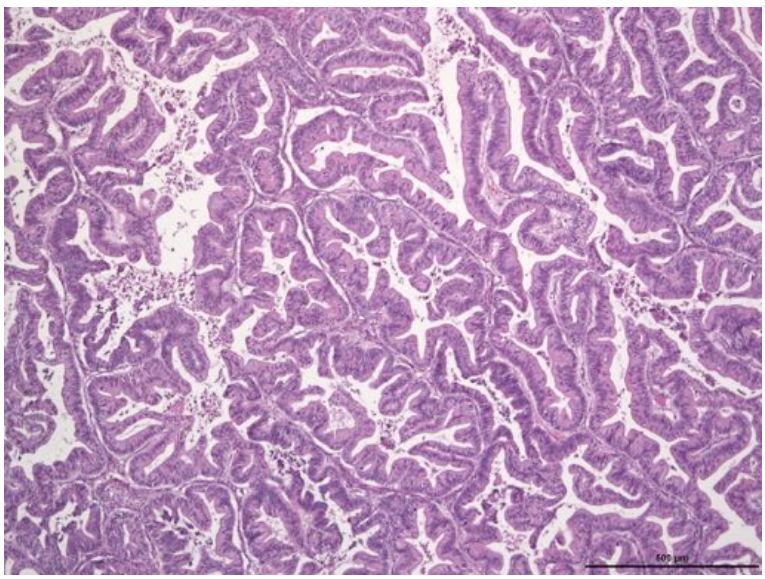

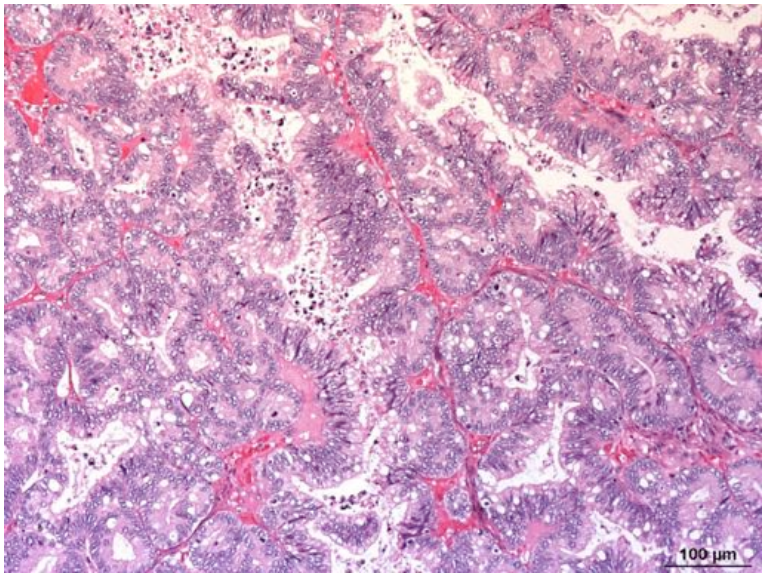
100 µm

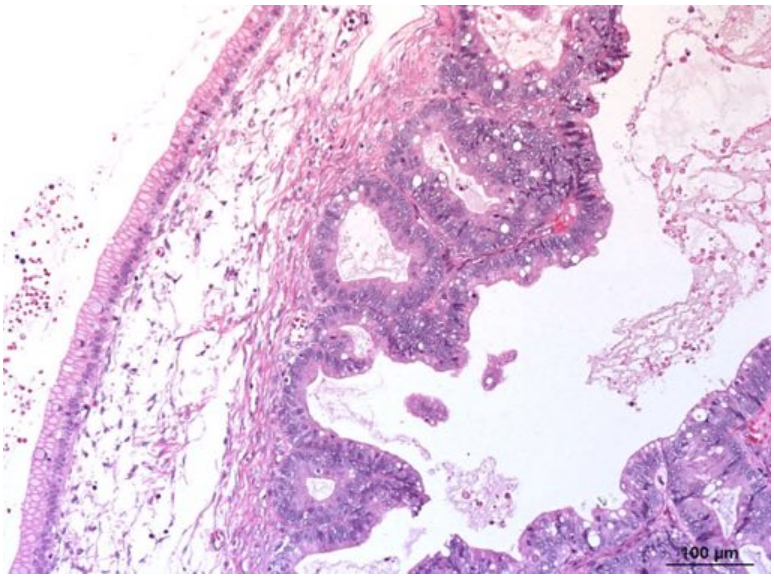
100 µm

Infiltrative growth pattern

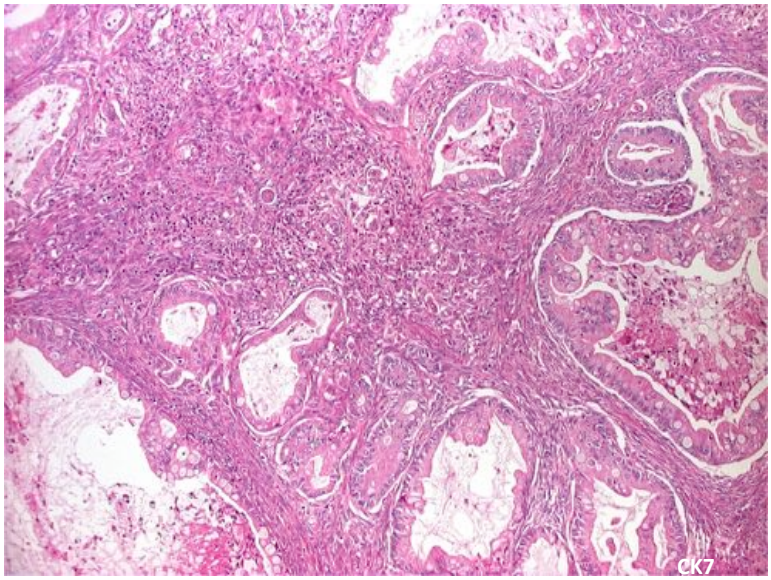

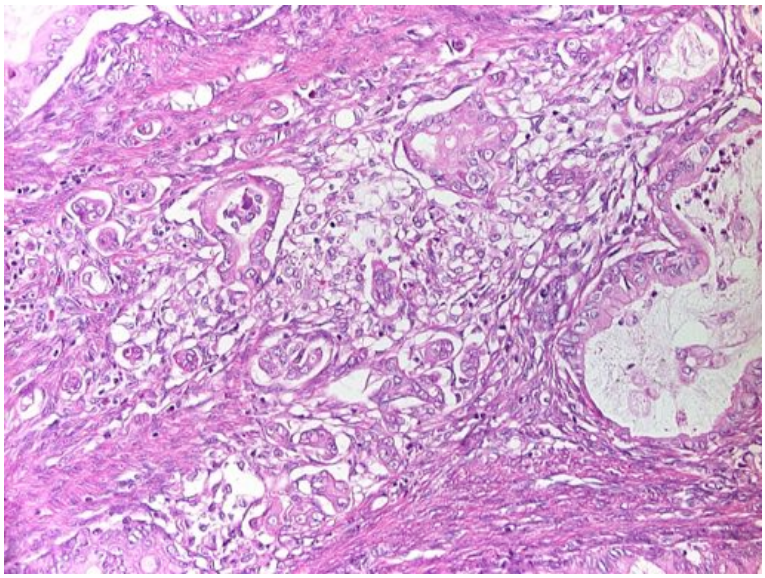

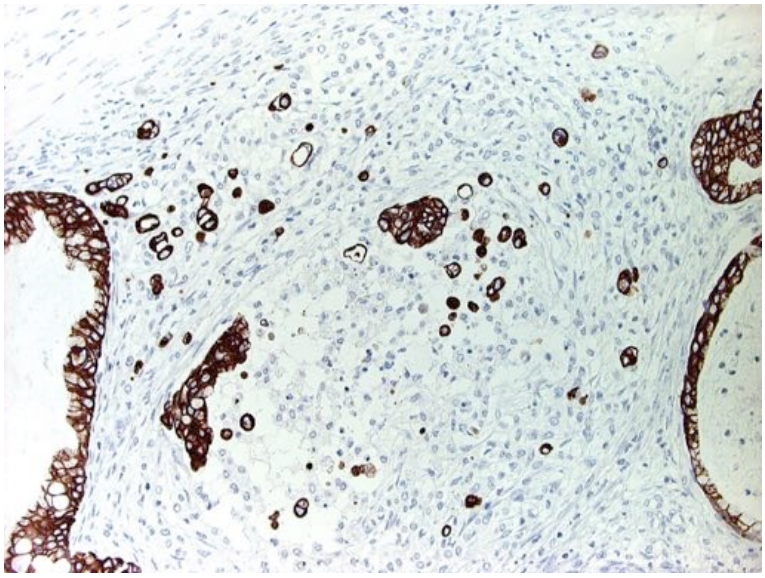

CK 7

Pseudomyxoma ovarii

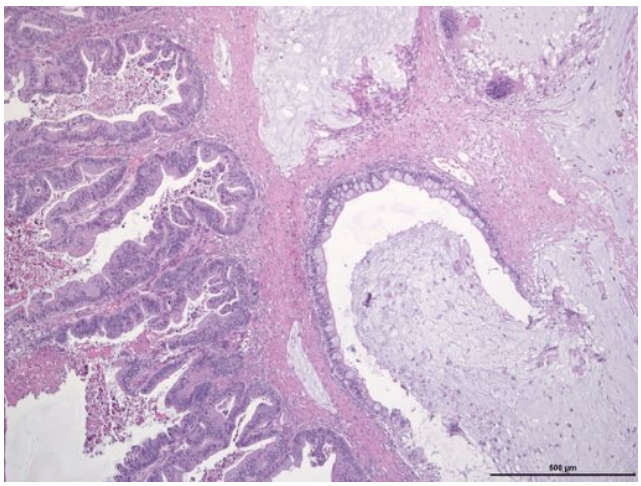

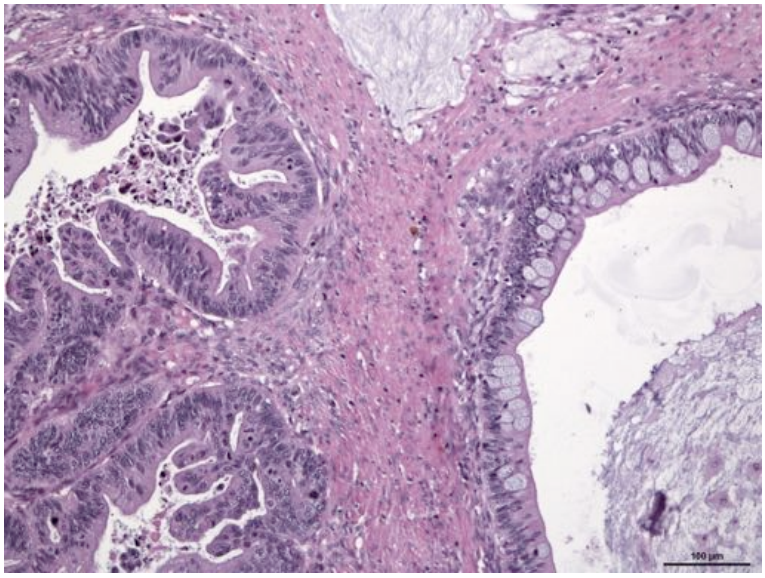

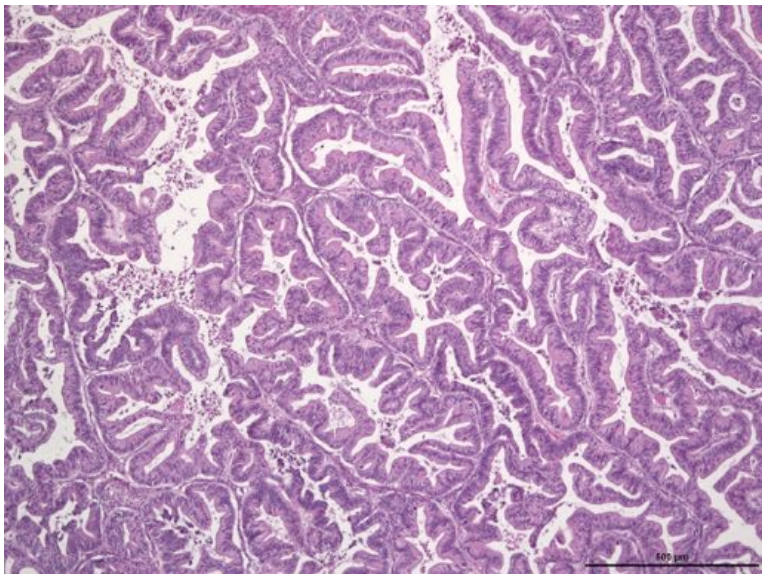

Immunohistochemistry: Mucinous

- ER, PR negative
- WT-1 negative
- CK7 positive
- CK20, cdx2 variable
- P53 frequently positive in carcinomas (mutant pattern) due to frequent mitoses

Immunhistochemistry for Typing

WT-1

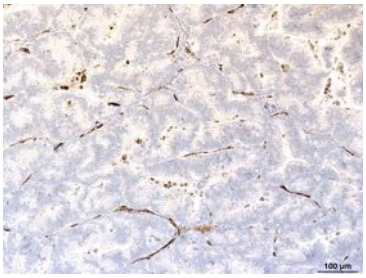

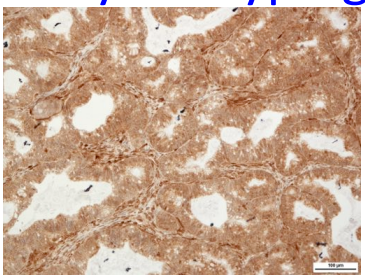

PTEN

CK7

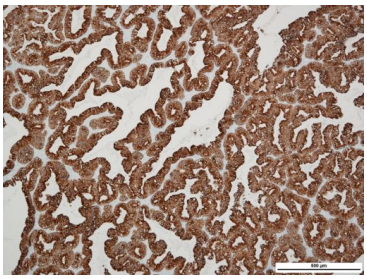

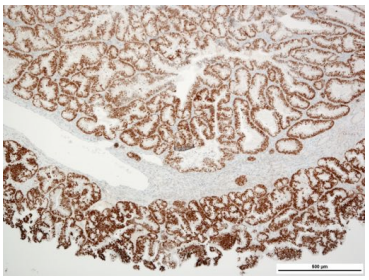

CDX2

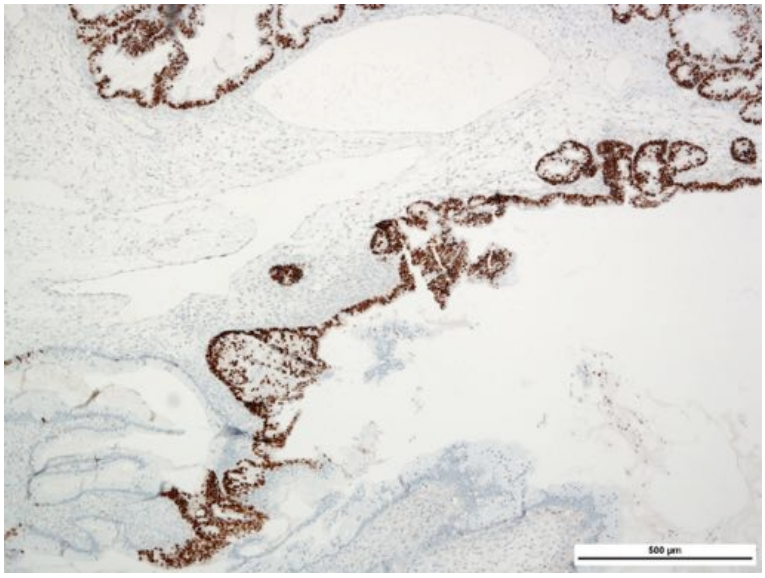

p53

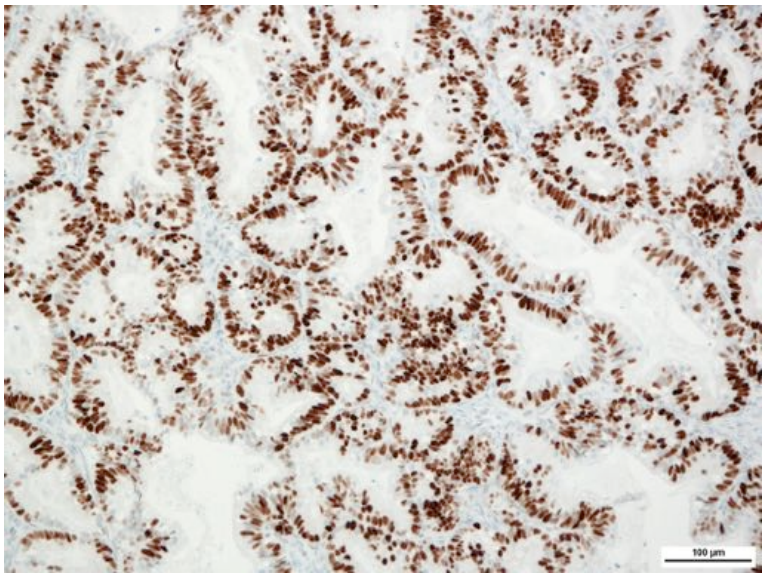

p53

Ovarian Mucinous Tumors Associated With Mature Cystic Teratoma

- Derived from gastrointestinal or sinunasal/bronchial epithelium
- CK7/CK20 pattern heterogenous, also CDX2 and villin expression vary
- CK7-/CK20+ pattern frequently associated with pseudomyxoma ovarii
- Primary ovarian mucinous neoplasms may be CK7-/CK2+/CDX2+

Microinvasion

- Largest diameter of the biggest invasive focus: 5mm

Riopel et al. Am J Surg Pathol, 1999

APMT: Intramural Nodules

- Cellular nodules in the wall of APMT/BLT
- Extremely rare
- Size from few mm to few cm
- 2 types:
  - Neoplastic (carcinosarcom-a or anaplastic carcinoma-like) with spindle, rhabdoid or pleomorphic cells
  - Reactive (pseudotumour-like with foreign body giant cells)
- Cytokeratin positive or negative
- Outcome may be favorable

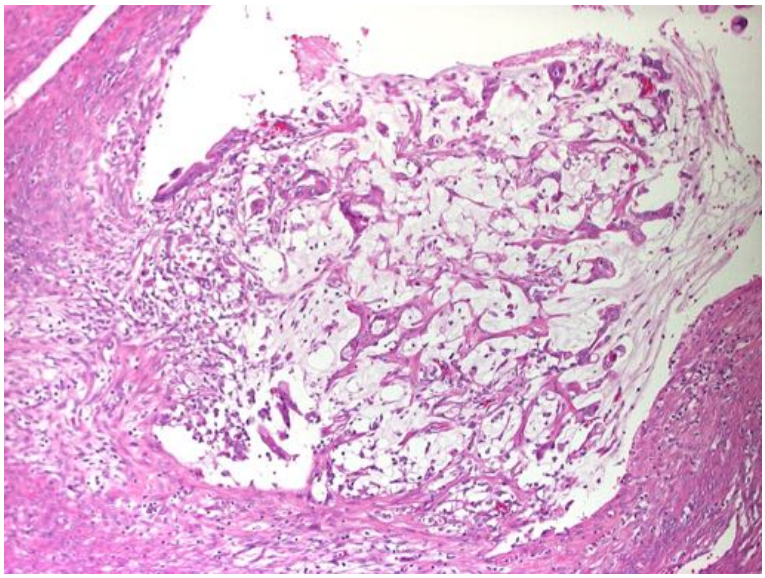

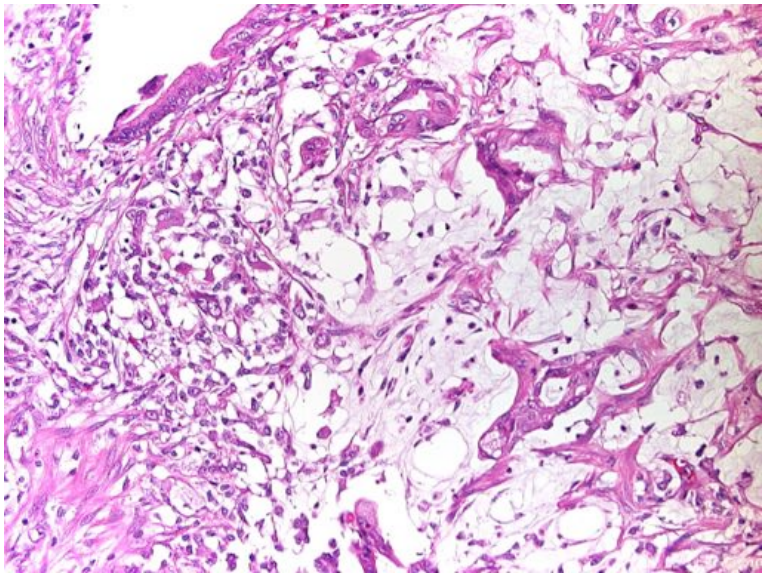

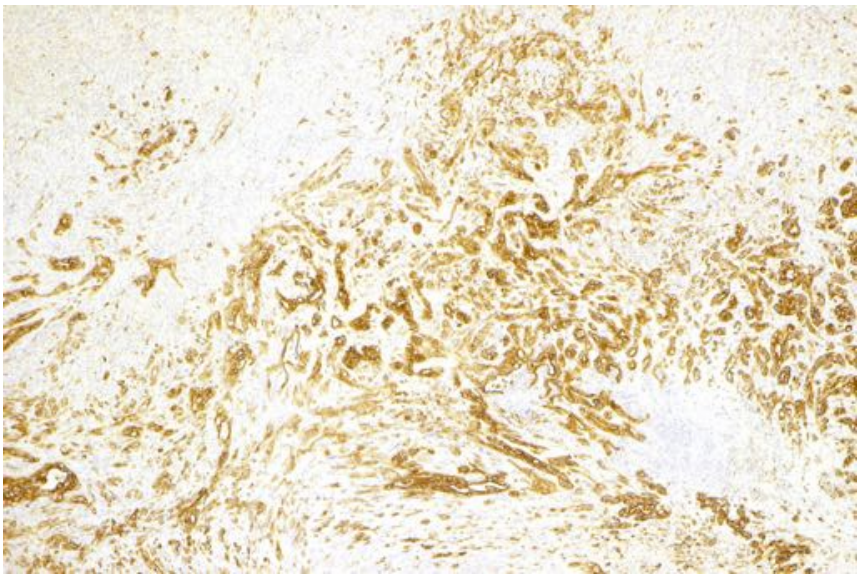

CK (AE1/AE3)

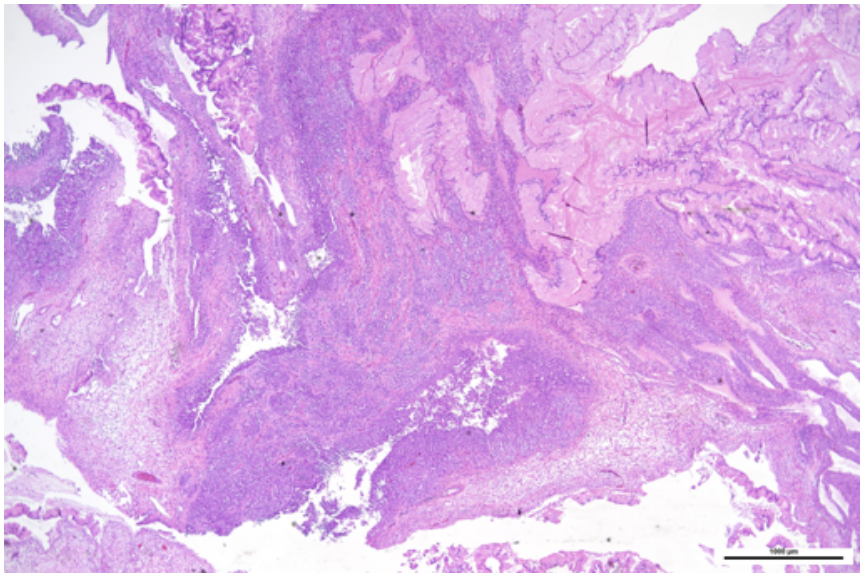

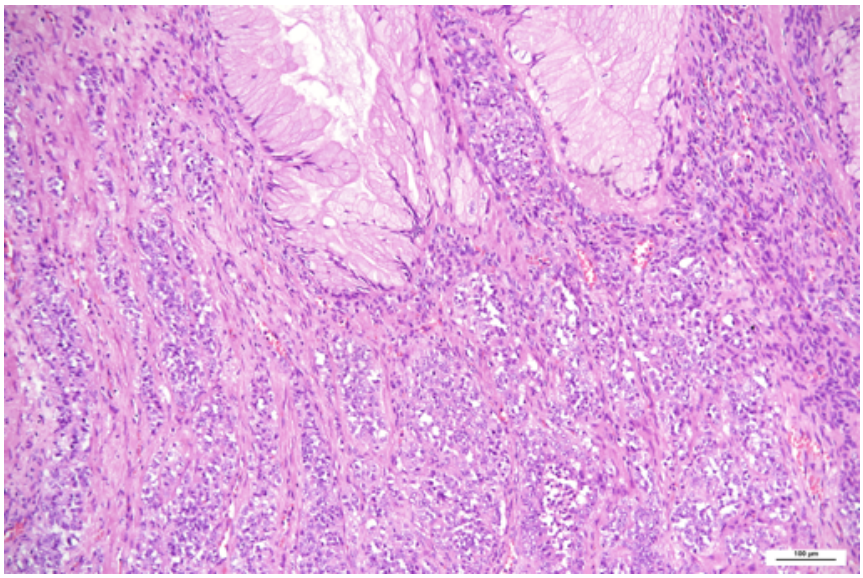

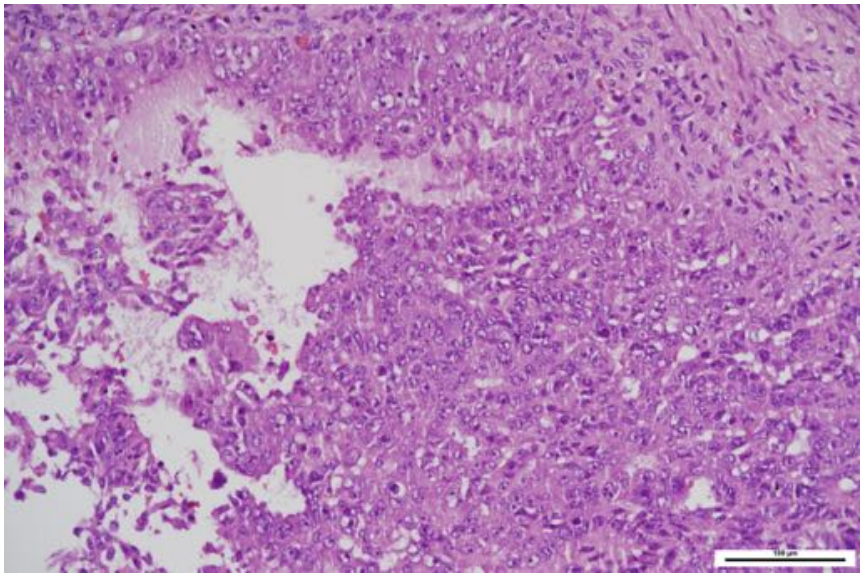

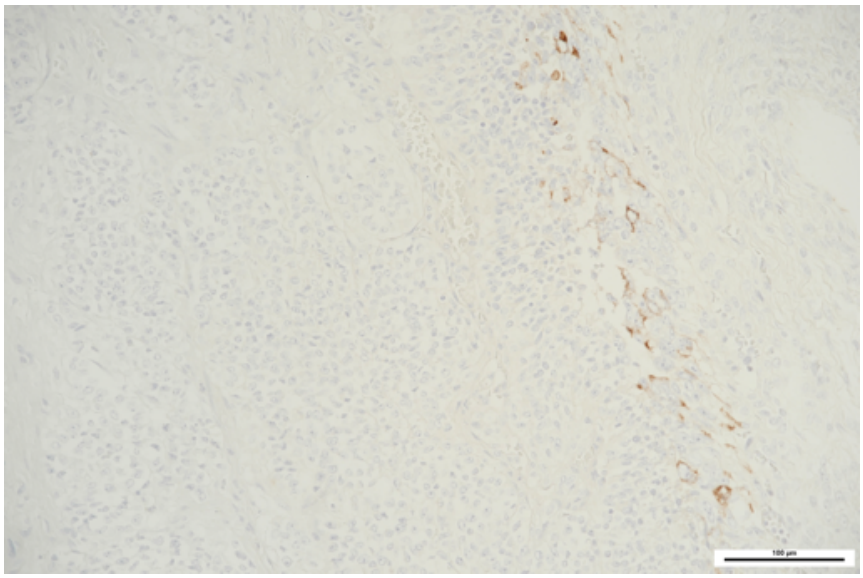

CK7

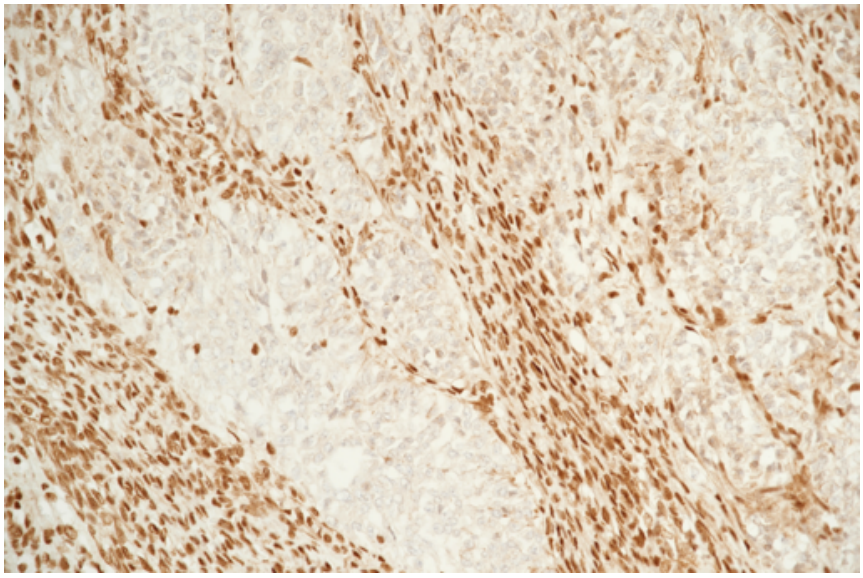

SMARCB1

Differential Diagnosis: Metastases

- Most frequent in “Western” countries: Colorectal adenocarcinoma
- Carcinomas of the pancreato-biliary system
- Historical: Gastric adenocarcinoma, diffuse type (“Krukenberg tumor”)
- Carcinomas of breast (invasive lobular ca)
- Mucinous tumors of the appendix
- Imitation of primary ovarian tumors

Metastases

- Gastrointestinal tract 73 %
  - Upper GI (stomach, pancreatobiliary)
  - Lower GI (colorectum)
  - Adenocarcinoma, neuroendocrine tumours (NET)
- Uterus 10%
  - Endometrium
  - Cervix
- Breast 13%

Metastases to the ovary

- diagnosed
  - before (18 %),
  - synchronously (33 %)
  - after (49 %) the primary tumor was identified
- 25 % were single,
- 40 % were unilateral
- 47 % were ≥13 cm
- Therefore, always consider a metastasis

Lobo et al., VIAR 2017

Mucinous ovarian tumors: Important gross and microscopic features

Tumor type	Diameter (cm)	Bilateral	Atypia +++	Necrosis
BLT (incl. IEC)	20	6%	15%	17%
BLT with microinvasion	17	0	13%	13%
Invasive carcinoma	18	21%	75%	58%
Metastatic carcinoma	8	51%	71%	23%
p- value	<0.0001	<0.0001	<0.0001	<0.002

Riopel et al. Am J Surg Pathol, 1999

Criteria for Differential Diagnosis of Primary and Metastatic Ovarian Tumors

Features	Primary	Metastasis
Extraovarian tumor in history	(+)	+++
Mucin deposits outside the ovary	(+)	+++
Bilaterality	(+)	++
Size >15 cm	++	+/-
Gross tumor on the ovarian surface	+/-	+
Microscopic surface involvement	+/-	+++
Nodular pattern	(+)	+++
Association with Brenner tu, teratoma, adenofibroma	+	-
Association with endometriotic cyst or endometriosis	+	-

Lee and Young: Am J Surg Pathol 27 (3), 2003

Seidman's rule: DD mucinous tu

- all bilateral mucinous carcinomas metastatic
- unilateral mucinous carcinomas <10 cm metastatic
- unilateral mucinous carcinomas >10 cm as primary
- correctly classified 90% of the neoplasms

- Does not work properly on other metastases

Seidman et al., AJSP 2003

Clue for DD: Pattern of invasion

Confluent: primary ovarian

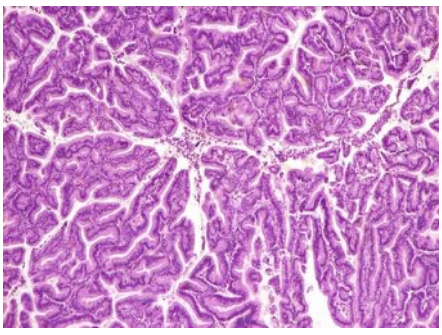

Nodular: metastasis

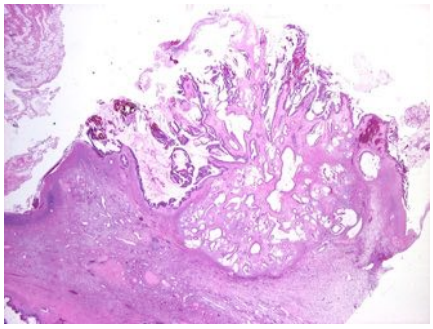

Nodular Invasion: Metastatic Adenocarcinoma from Colon

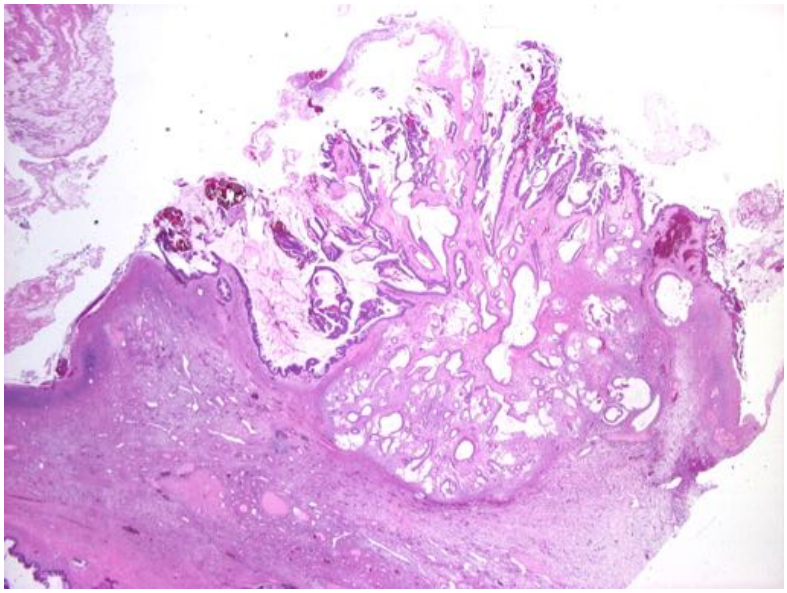

Nodular Invasion: Metastatic Adenocarcinoma from Colon

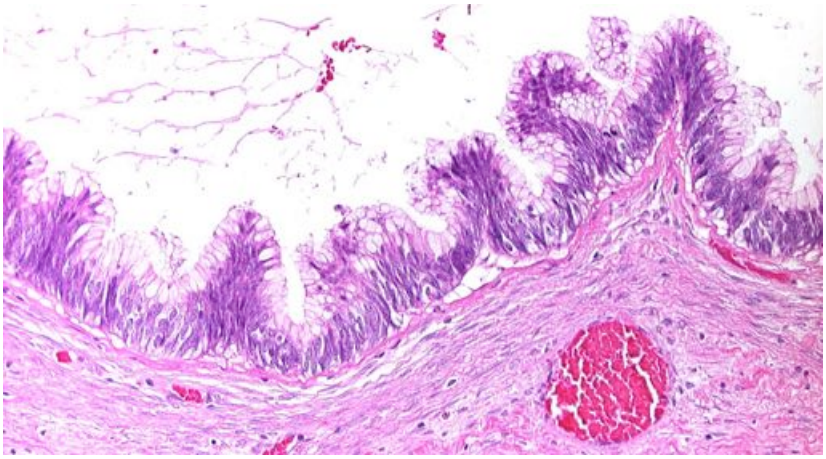

Nodular Invasion: Metastasis of Pancreatic Adenocarcinoma

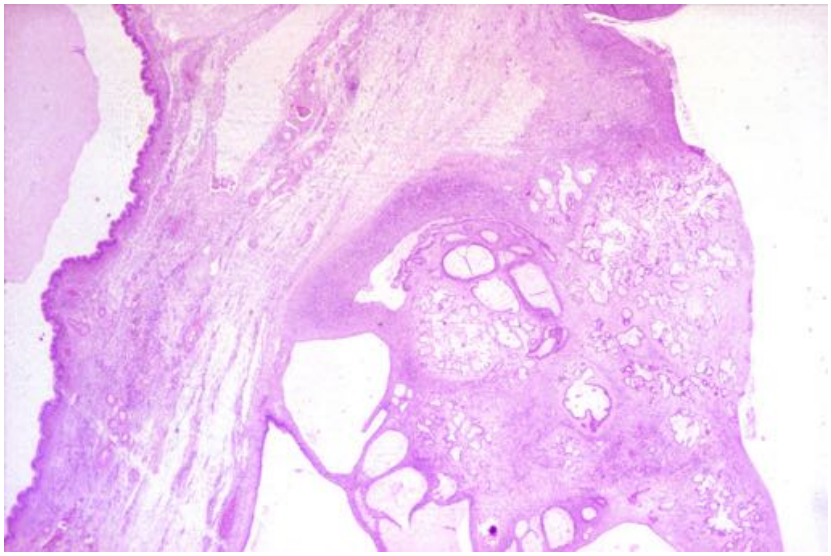

Nodular Invasion: Metastasis of Pancreatic Adenocarcinoma

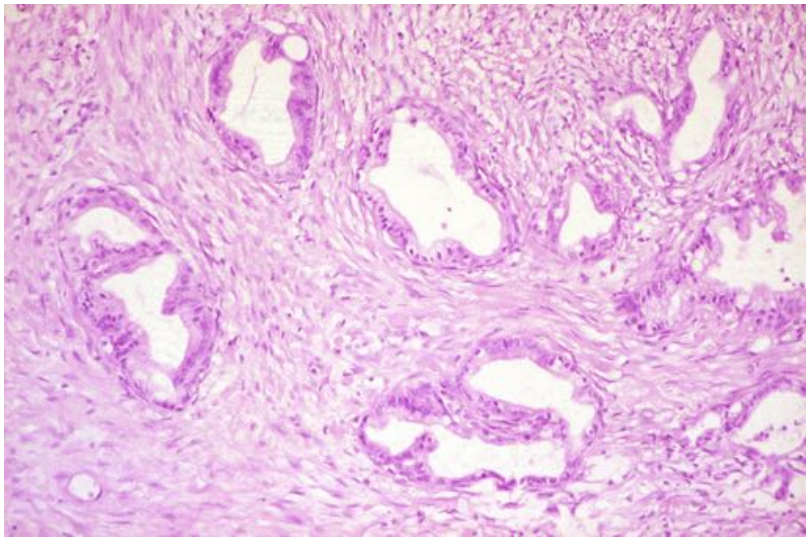

Metastatic Adenocarcinoma from Colon

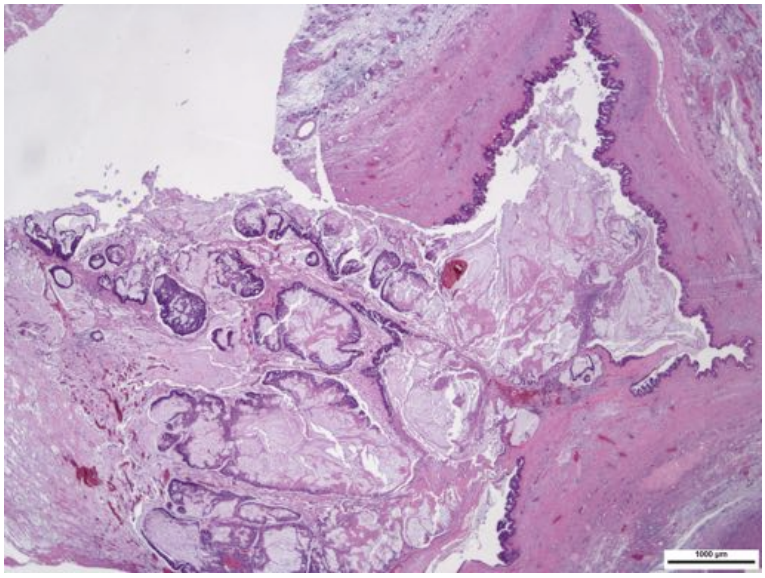

Metastatic Adenocarcinoma from Colon

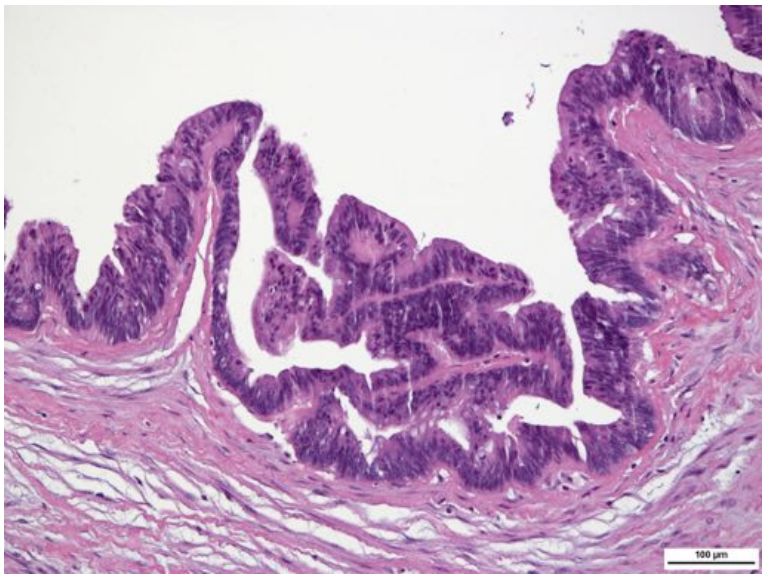

Immunohistochemistry for DD

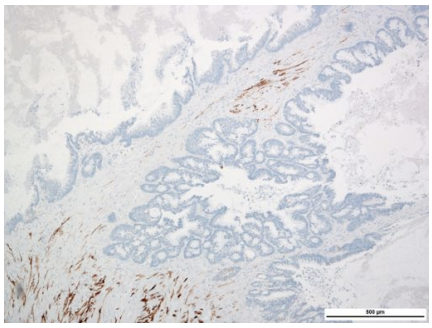

CK7

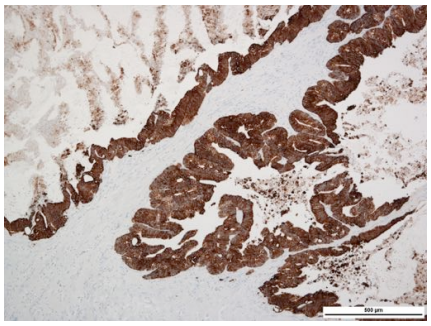

CK20

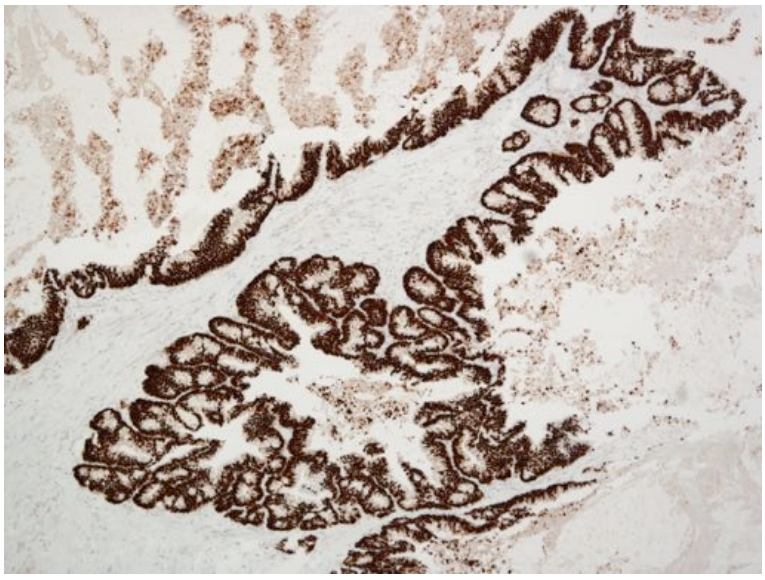

CDX2

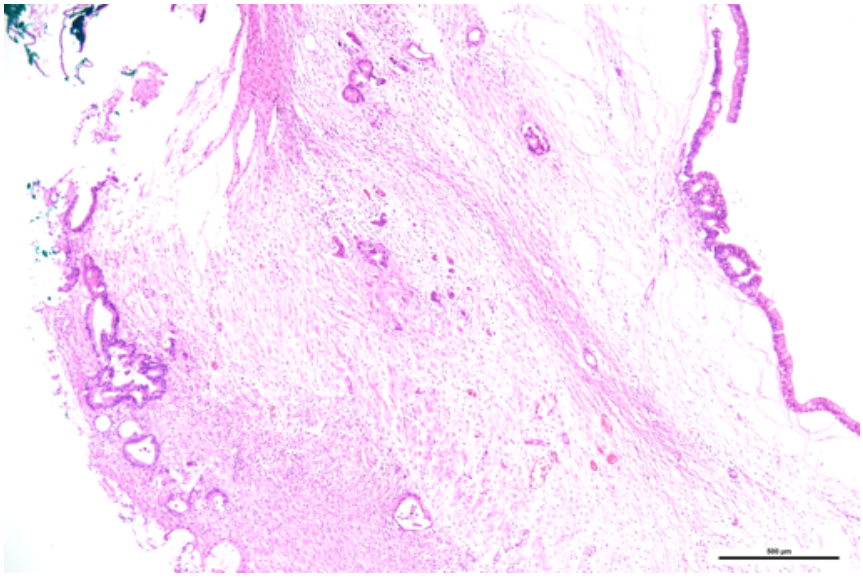

62 yr. old F, left adnexal mass, 10 cm

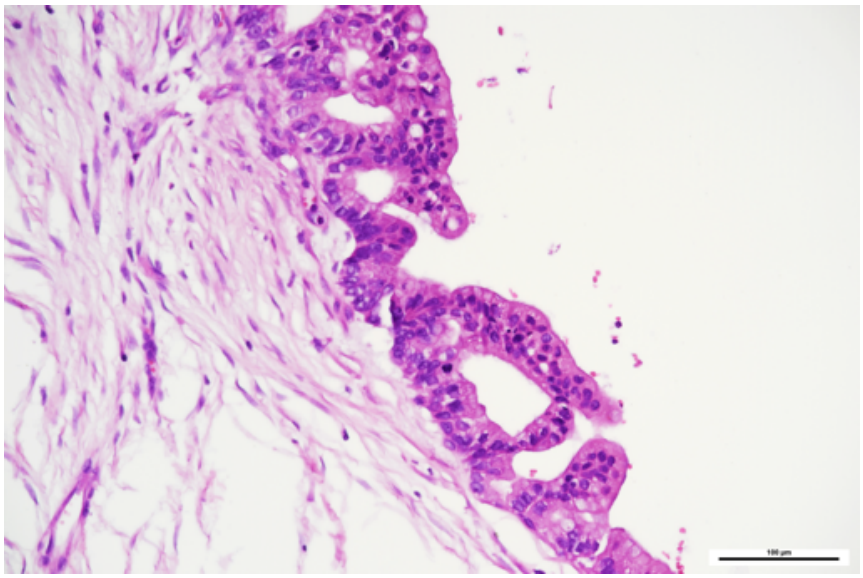

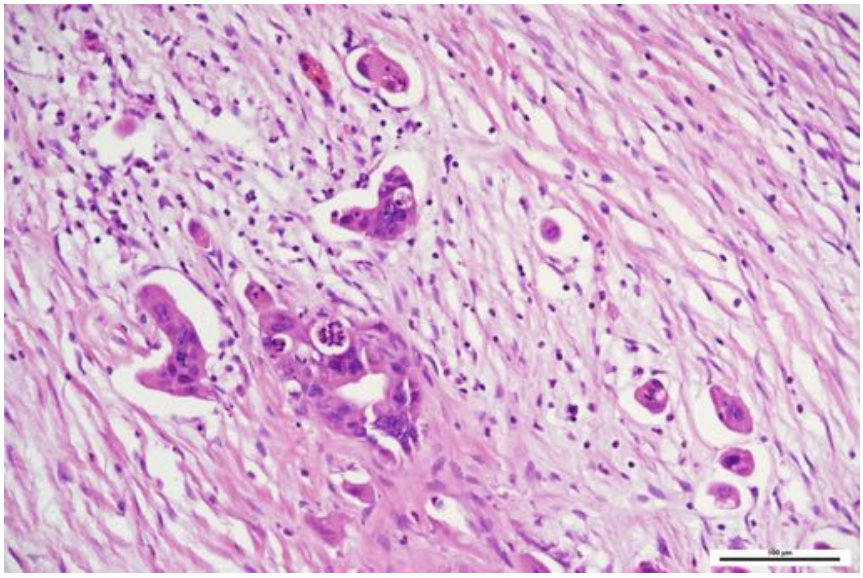

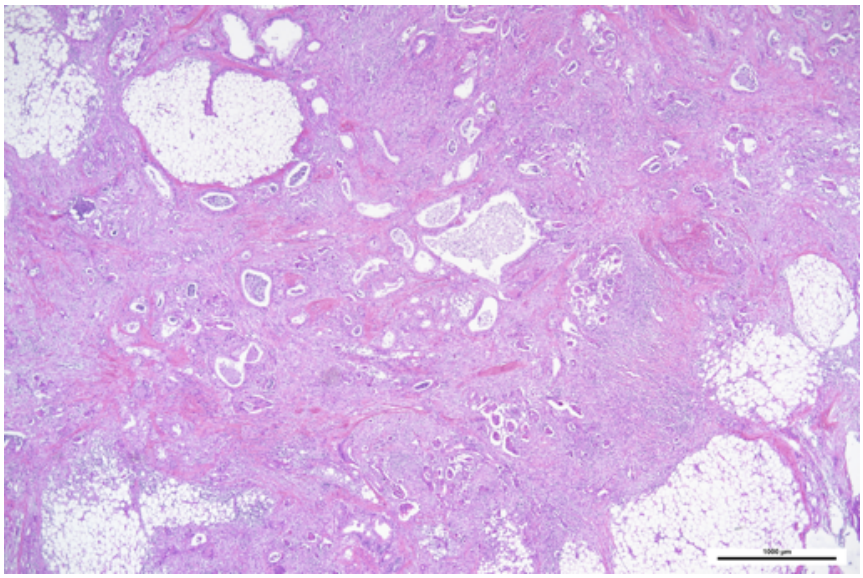

Omental disease

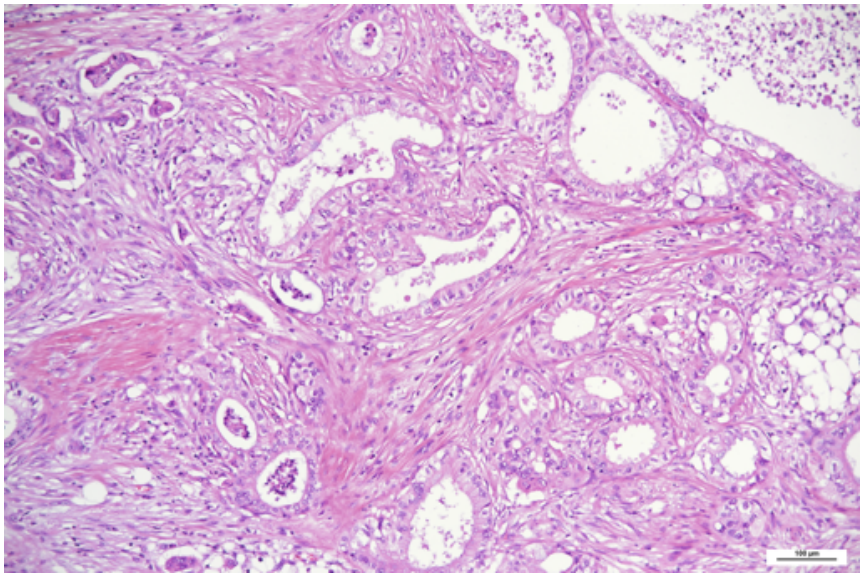

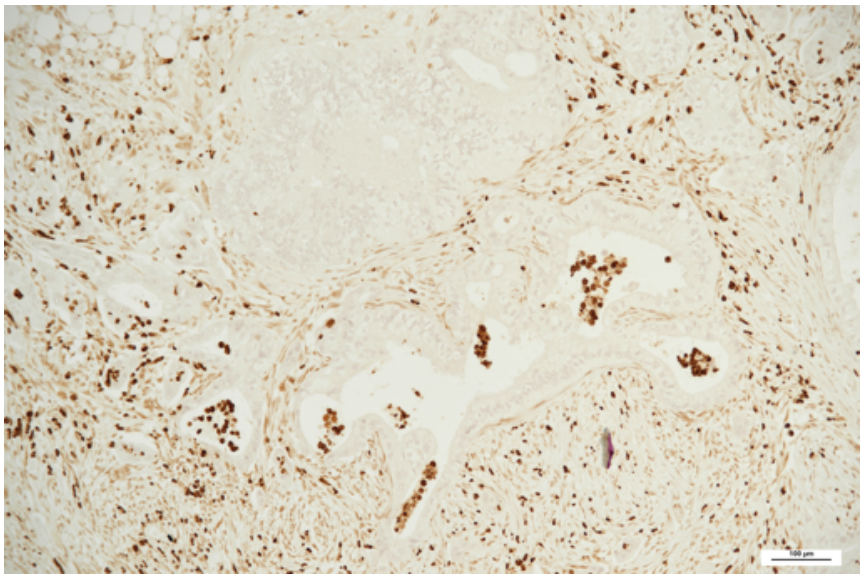

History of pancreatic cancer: metastasis or 2nd primary DPC4 (SMAD4)

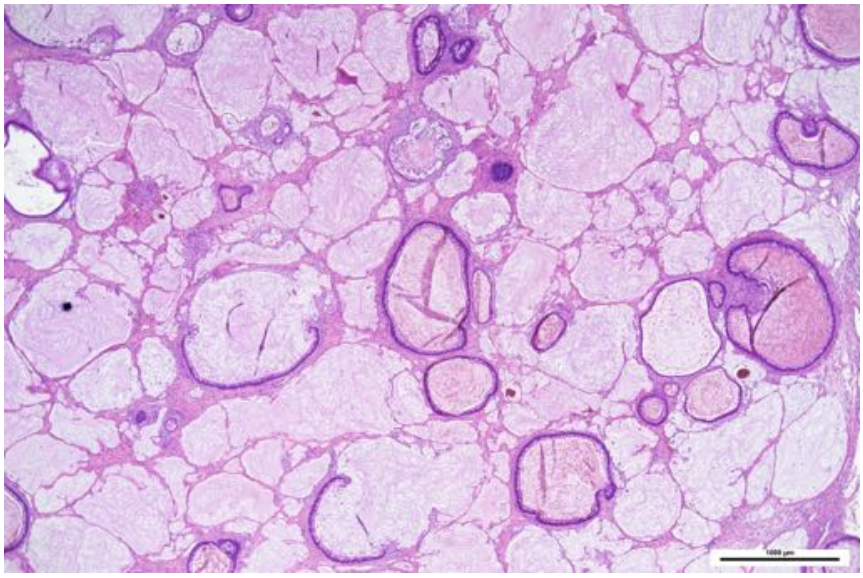

32 yr. old F, right adnexal mass

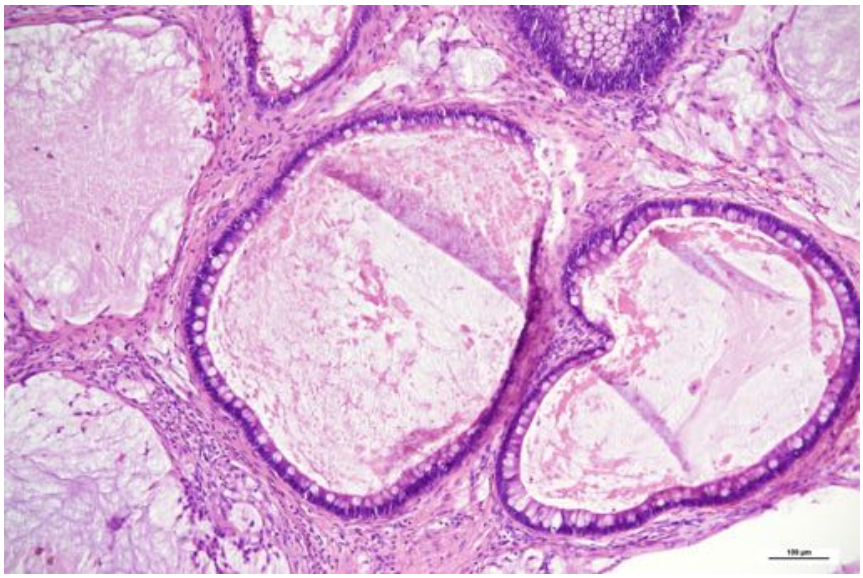

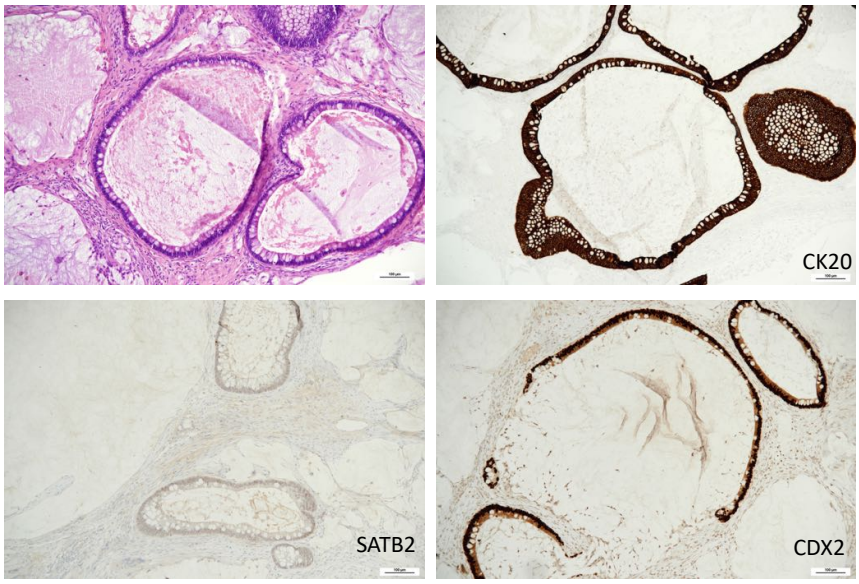

Metastases as Look alikes

Metastasis	Look alike
Colorectal adenocarcinoma	Endometrioid / mucinous carcinoma
Mucinous neoplasm appendix	Mucinous borderline tumor
Ductal adenocarcinoma pancreas	Mucinous borderline tumor/ carcinoma
Breast carcinoma	Endometrioid carcinoma, NET
Signet ring cell carcinoma	Fibroma

Synchronous Mucinous Tumours of Ovary and Appendix

- Rare; usually low grade appendiceal mucinous neoplasm (LAMN)
- Ipsilateral cystic ovarian tumour (right)
- Continuous spread considered
- Ruptur usually not found (healed)
- Pseudomyxoma peritonei und pseudomyxoma ovarii: unusual for primary mucinous neoplasms (except association with teratoma)

Take Home message

- Mucinous ovarian tumors develop from various sources with distinct molecular profile
- Primary ovarian carcinomas show a maze-like pattern, metastases a nodular pattern
- Metastases may mimick borderline tumors
- Immunohistochemistry is helpful but varies

Thank you very much for your attention!



