TECHNOLOGY TRANSFER IN DIAGNOSTIC PATHOLOGY
10TH CENTRAL EUROPEAN REGIONAL MEETING

Gynecological Pathology

ORGANIZED BY THE HUNGARIAN DIVISION OF THE INTERNATIONAL ACADEMY OF PATHOLOGY



Slide seminar: Epithelial neoplasia

Sigurd F. Lax

JOHANNES KEPLER UNIVERSITY LINZ

LKH Graz II
Academic Teaching Hospital of the Medical University Graz
Pathology

KAGes

Clinical History

- 55 year-old female, St. P. breast cancer
- Left-sided colitis with colonoscopy 1 year and 2 weeks ago
- TVUS: right adnexal cystic mass, 10 cm, suspicious of malignancy; nodular structures in the cul de sac and plenty of ascites
- CA 125 elevated (36)
- Laparotomy: pseudomyxoma peritonei; right ovarian lesion ruptured>>frozen section

Gross



- 14 x 12 x 4 cm ruptured multicystic ovary with viscous mucous.
- Fallopian tube 7 cm long.

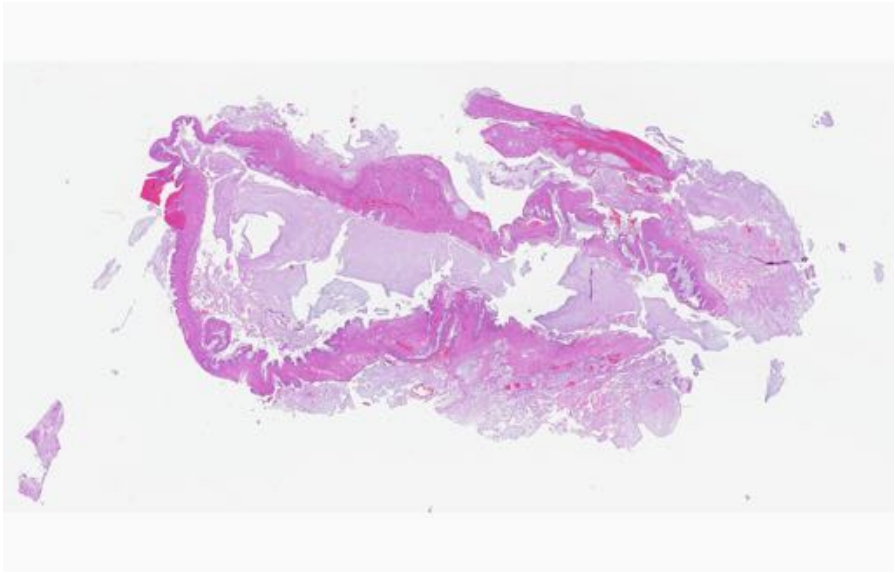

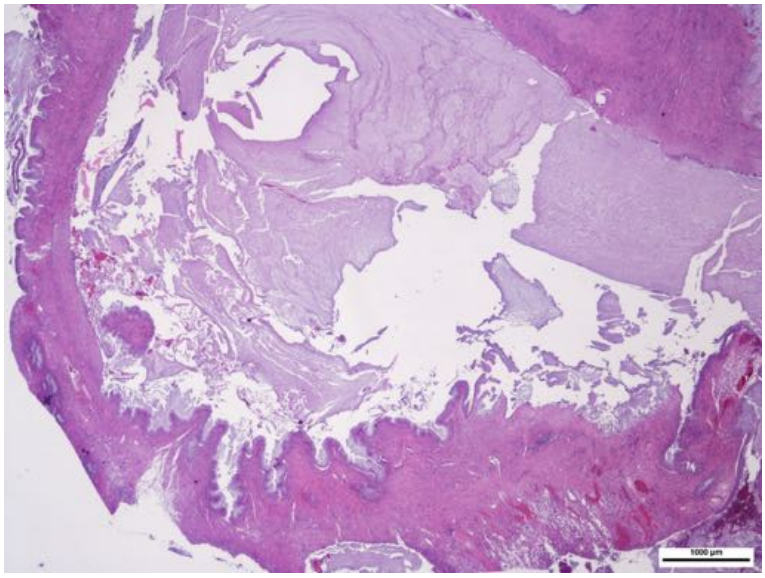

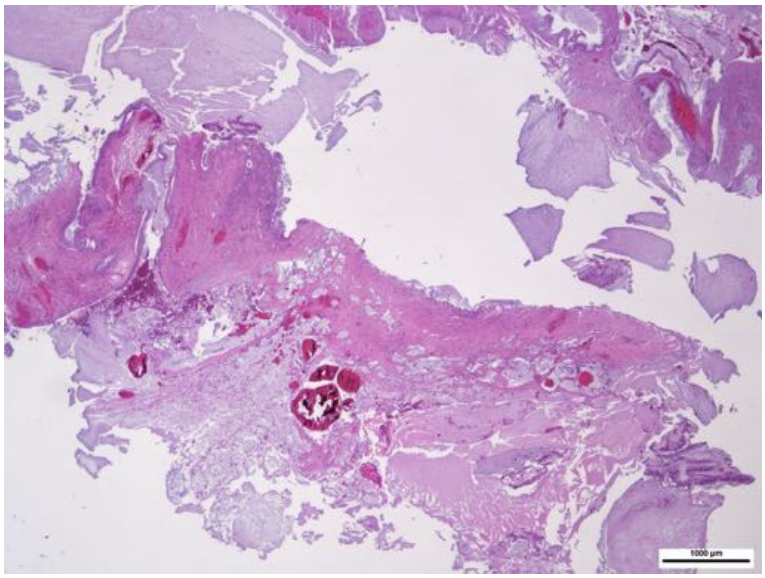

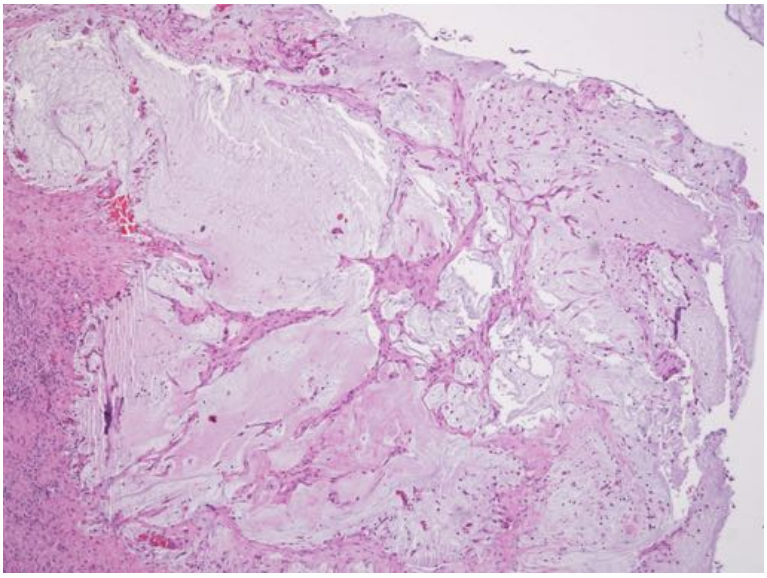

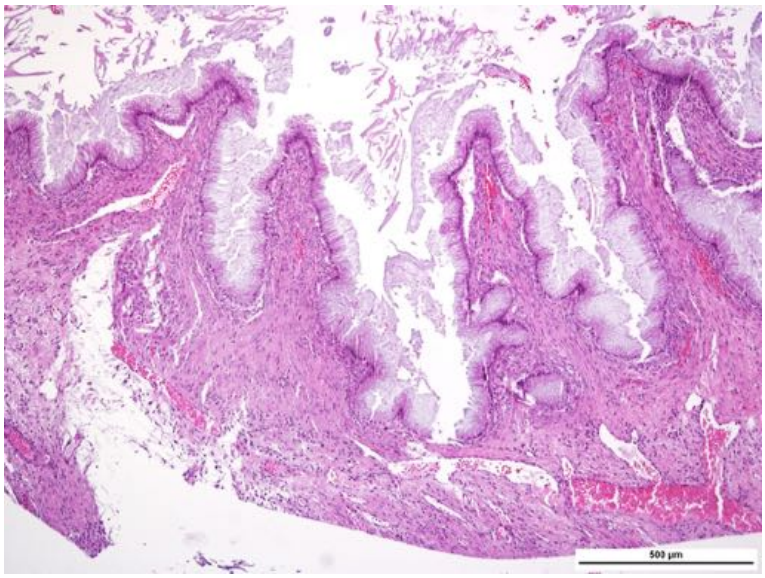
500 µm

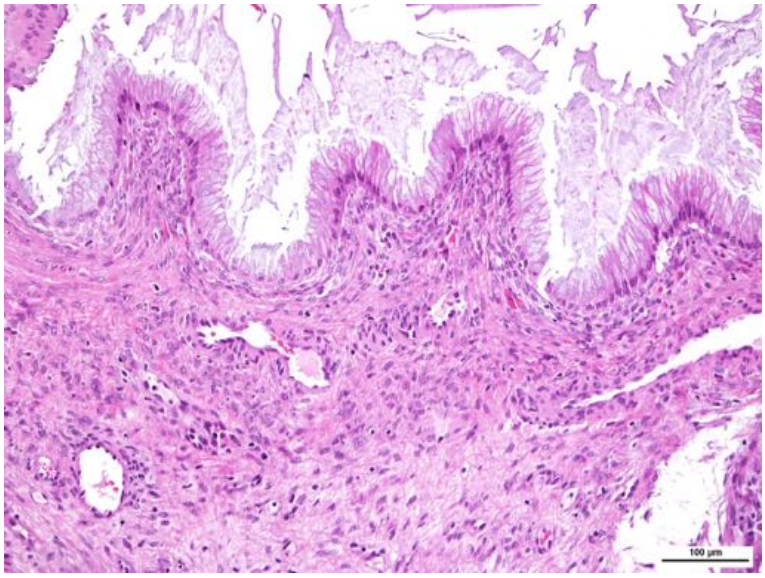

Intraoperative frozen section

- What would be your diagnosis during frozen section?
- Do you ask the surgeon for further information?

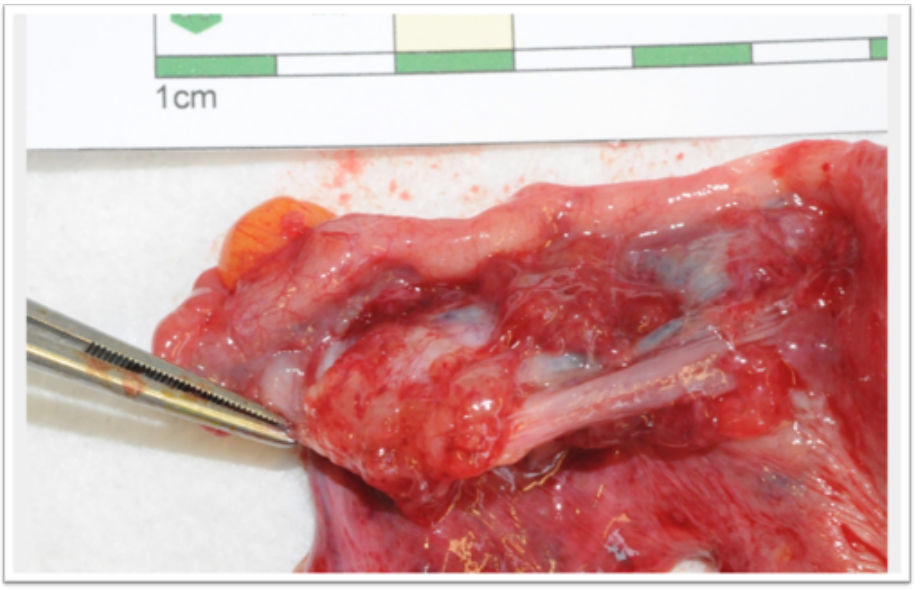

Appendix

Appendix





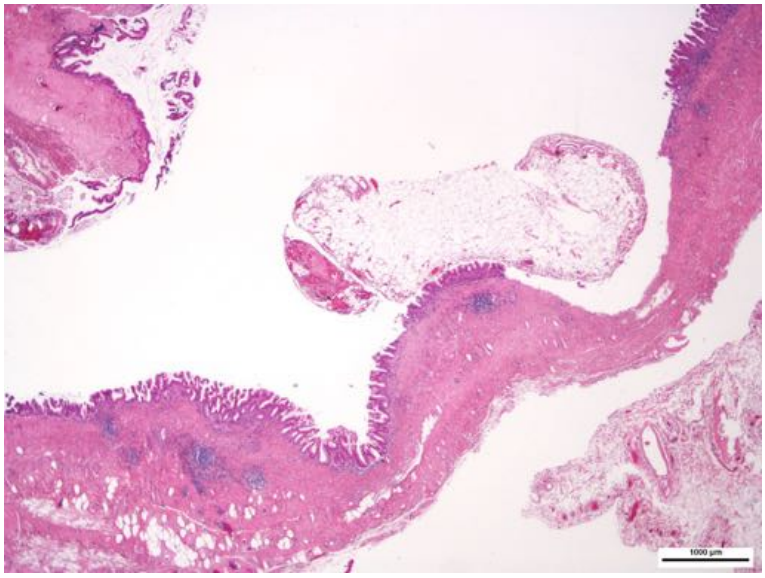

Appendix

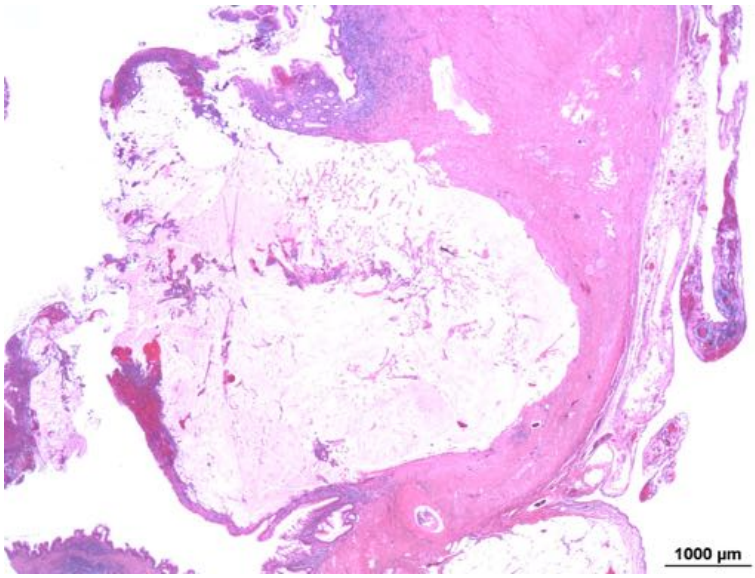

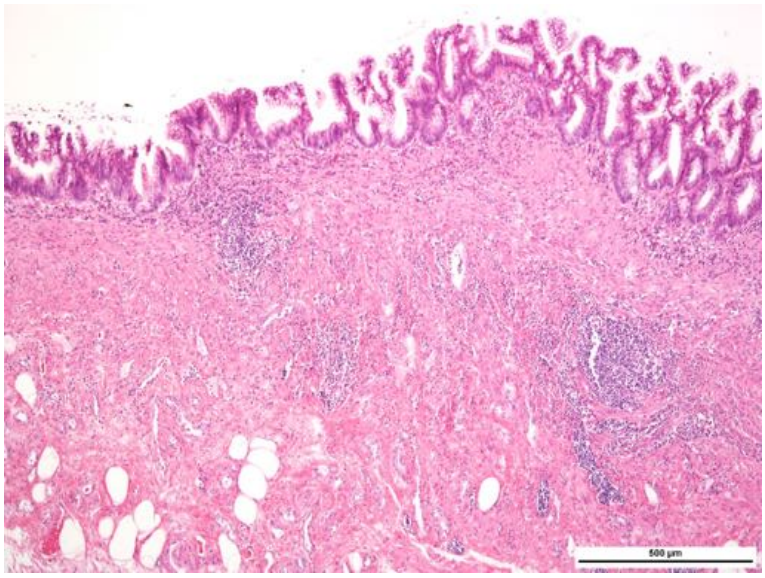

Appendix

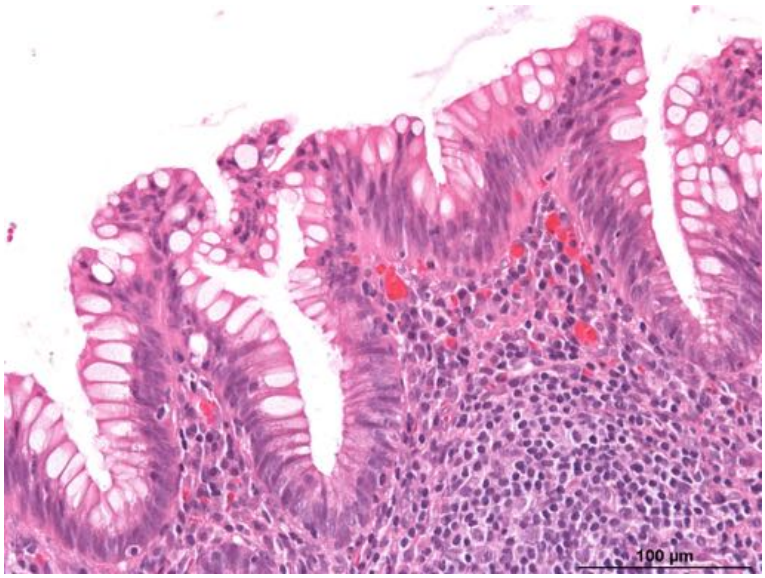

Your diagnosis?

- Any further information you would like to have?

Histological Findings

- Ovary:
  - Multicystic mucinous lesion with bland epithelium
  - Mucin in the (ovarian) stroma (pseudomyxoma ovarii) and on the surface
- Appendix:
  - Mucinous lesion with loss of the layers of the wall
  - Mucus protruding through wall of appendix

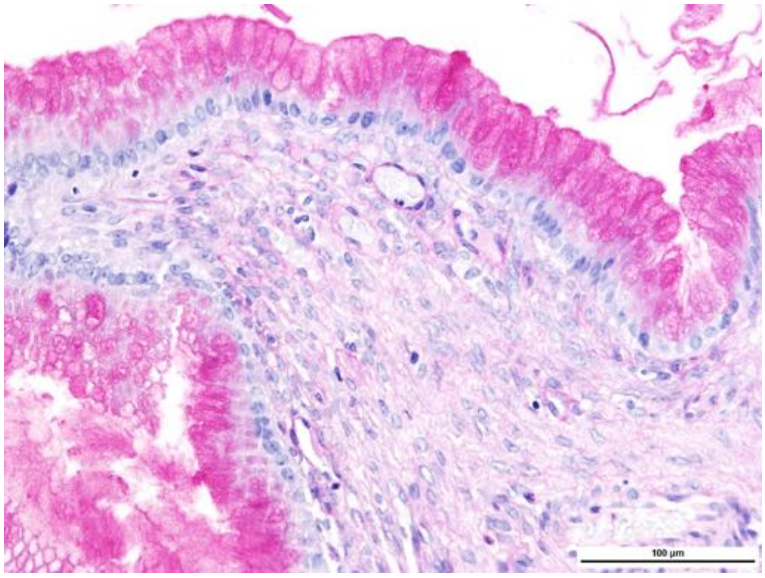

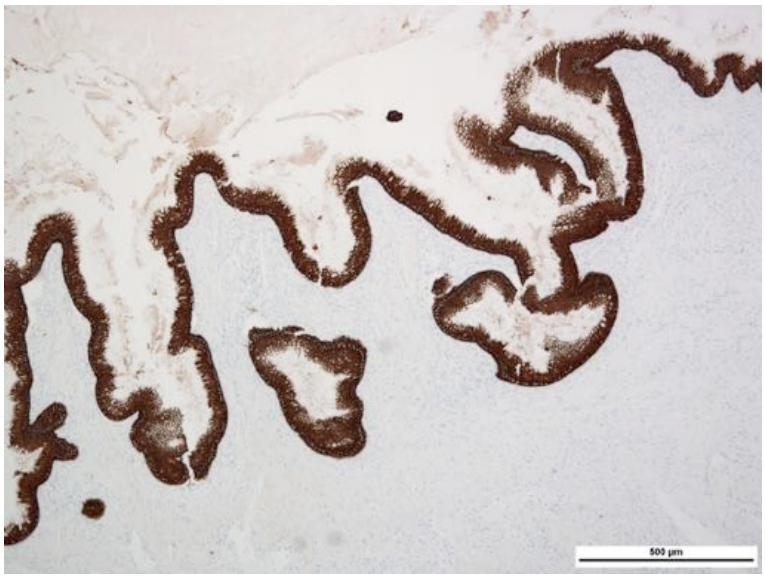

CK20

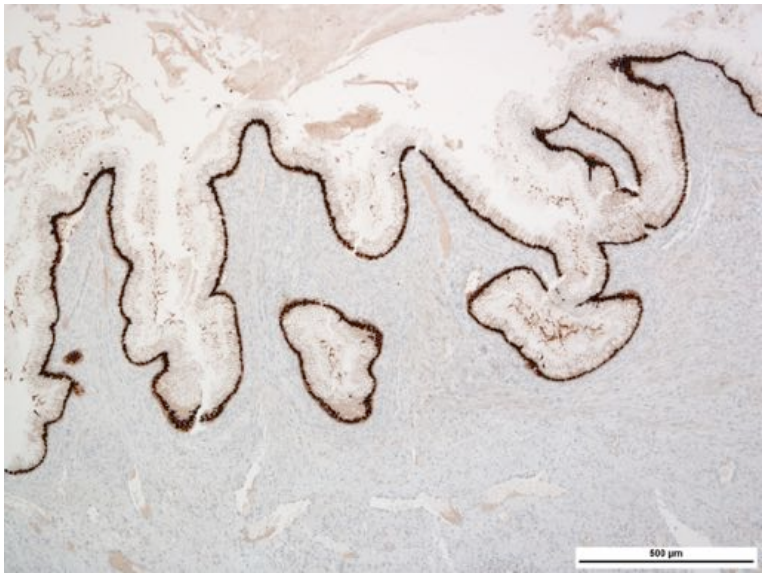

CDX2

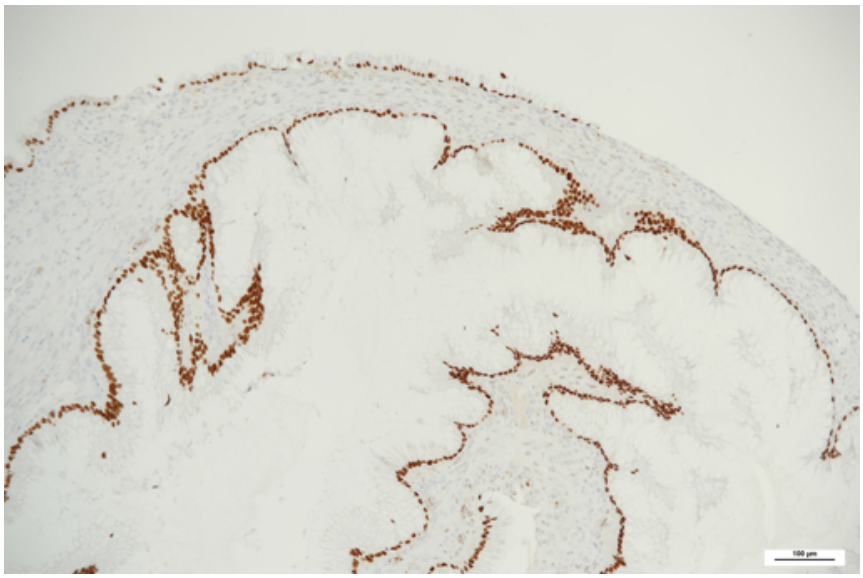

SATB2

Immunohistochemistry

- CK7 negative
- CK20 positive
- CDX2 positive
- SATB2 positive

Diagnosis

- Mucinous cystic ovarian tumour associated with pseudomyxoma peritonei, metastasis from a low grade appendiceal mucinous neoplasm (LAMN).

Differential Diagnosis

- Mucinous cystadenoma
- APMT/ borderline tumour
- Metastasis from a mucinous carcinoma

Diagnostic criteria: Ovary

- Cystic tumour with mucinous epithelium.
- Abundant goblet cells (intestinal differentiation).
- Mucin lakes in the stroma (pseudomyxoma ovarii).
- Mucin deposits on the ovarian surface (pseudomyxoma peritonei).

Colonoscopy
19.1.2010



Appendix



Coecum

Colonoscopy
26.4.2011



Valvula



Coecumboden

Synchronous Mucinous Tumours of Ovary and Appendix

- Rare
- Typical: Ipsilateral cystic ovarian tumour
- Continuous spread considered
- Ruptur usually not found (healed)
- Appendiceal tumour:
  - Low grade appendiceal mucinous neoplasm (LAMN)
  - Appendiceal adenocarcinoma

Pseudomyxoma peritonei

- Unusual for primary mucinous neoplasms of the ovary (except for association with teratomas), the same is the case for pseudomyxoma ovarii
- Serrated polyps of the appendix typically maintain the mucosal architecture, are not associated with mucin dissection through the wall or pseudomyxoma peritonei

Appendiceal mucinous neoplasm

- Appendiceal neoplasm characterized by mucinous epithelial proliferation with extracellular mucin and pushing tumour margins
- Low grade appendiceal mucinous neoplasm
- High grade appendiceal mucinous neoplasm
  - micropapillary features, cribriforming, piling up of epithelial cells with high-grade features

LAMN

- >50% extraappendiceal spread
- No recurrence if confined to appendix
- Extra appendiceal: short term prognosis good but long term prognosis poor (100% 3 year, 45% 10 year survival)
- Bulky peritoneal disease affects prognosis

Misdraji et al., 2003

Synchronous Mucinous Tumours of Ovary and Appendix

- K-ras mutations
- Allelic loss for 18q, 5q, 6q, 17p
- 16 cases with identical K-ras mutation
- Identical allelic loss, progression in ovary 1x
- Isolated lesions of ovary and appendix without pseudomyxoma peritonei

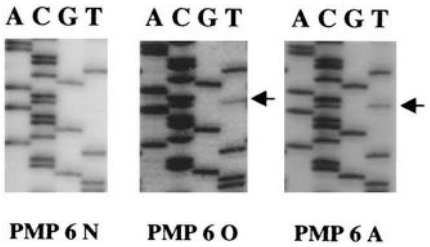

Szych et al., AJP, 1999

Synchronous Mucinous Tumors of the Appendix and the Ovary Associated with Pseudomyxoma Peritonei: A Clinicopathologic Study of Six Cases with Comparative Analysis of c-Ki-ras Mutations. Cuatrecasas, Miriam M.D.; Matias-Guiu, Xavier M.D.; Prat, Jaime M.D., F.R.C.Path. AJSP, 1996; 739-46.

Case	Ovary		Appendix	
	C-12	C-13	C-12	C-13
1	–	–	–	–
2	+ (Asp)	–	+ (Asp)	–
3	+ (Asp)	–	+ (Asp)	–
4	+ (Asp)	–	+ (Asp)	–
5	+ (Asp)	–	+ (Asp)	–
6	+ (Val)	–	+ (Val)	–

C-12, codon 12; C-13, codon 13; +, tumor with point mutation; –, tumor with no mutation detected; Asp, GGT → GAT (Gly → Asp) transition; Val, GGT → GTT (Gly → Val) transversion.

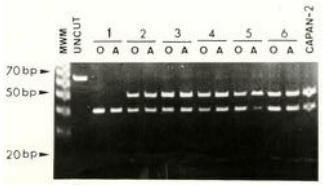

- 6 cases
- RFLP: K-ras
- Identical mutations in ovarian and appendiceal lesions
- Clonal nature of both lesions>related

Follow up

- 5 years
- Complete removal of the mucous and the tumour during 1st operation (R-0)
- Recurrence after 3 ½ years (no further information)

Another case

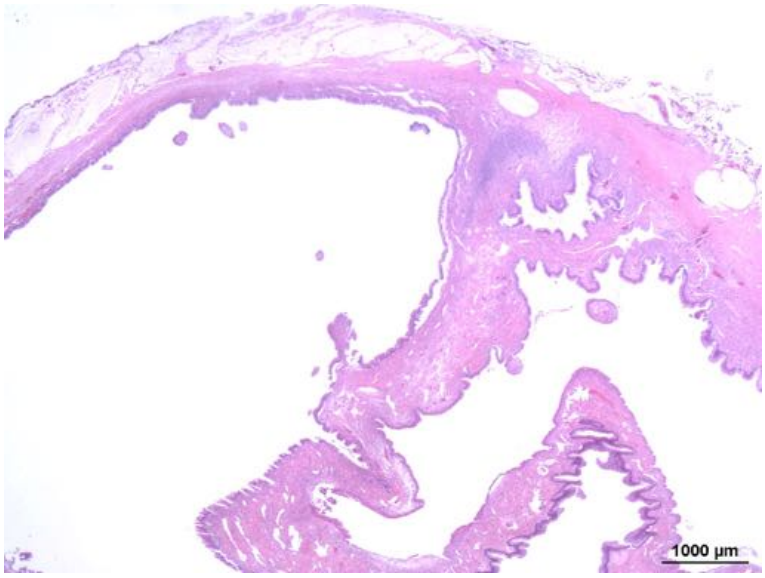

79 year-old female, 19 cm cystic ovarian tumour right adnexae

Vermiform Appendix: Site of origin

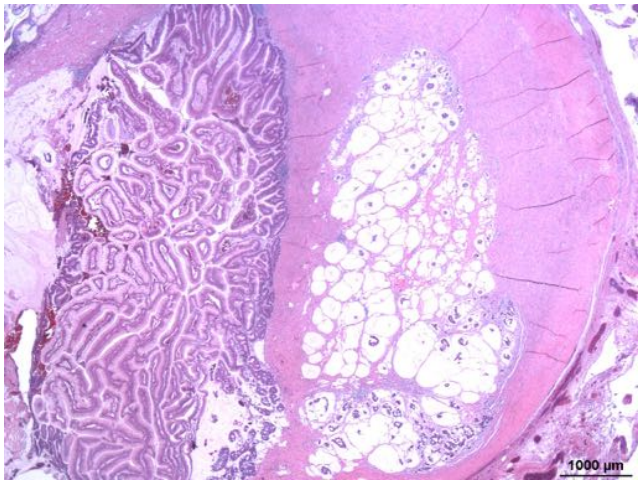

Mucinous adenocarcinoma of the vermiform appendix, associated with a villoglandular adenoma

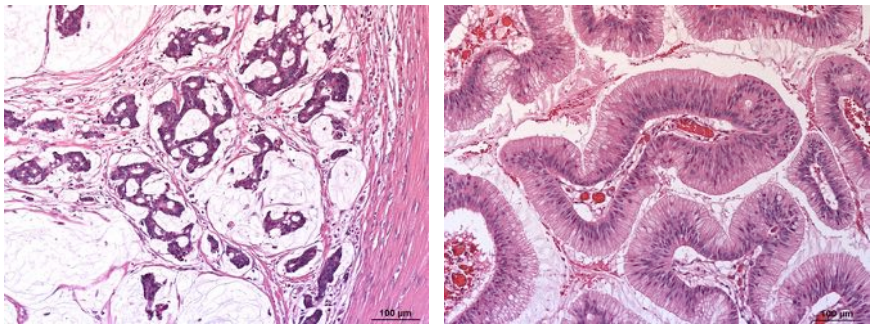

Take Home Message

- LAMN and other appendiceal neoplasms may cause cystic ovarian metastasis
- May resemble MBLT/APMT
- Not every mucinous tumour in the ovary is an ovarian primary
- Appendectomy is usually performed if a mucinous ovarian tumour (not only APMT) is diagnosed intraoperatively