Medical University of Graz

Case Report: Metaplastic papillary tumour of the fallopian tube, a rare entity - analyzed by NGS

Sandra Sunitsch*, Francesca Sarocchi, Peter Regitnig, Luca Abete * Presenting author
Diagnostic & Research Institute of Pathology, Medical University of Graz, Neue Stiftingtalstraße 6, 8010 Graz, Austria

Background

Metaplastic papillary tumour (MPT) is an extremely rare lesion of the fallopian tube. Only 12 cases of tubal MPT have been documented in the previous literature to date. Tubal MPT has been related to pregnancy because it is found upon examination of fallopian tube segments removed for sterilization postpartum. This lesion is morphologically characterized by a papillary growth pattern and lacks cytological atypia. Debate exists whether this lesion represents a true neoplasm or a metaplastic proliferative lesion.

Patient

We report the case of a 35 year old woman with a MPT of the fallopian tube. The lesion was detected, incidentally in the fallopian tube, which was removed for sterilization postpartum.

Methods

The fallopian tubes were removed postpartum for sterilization, macroscopically described, grossed and routinely stained with H&E according to standard protocol. Immunohistochemistry (IHC) was performed on a Dako Autostainer with an antibody against androgen receptor due to eosinophilic appearance. Additionally a Low Density Whole Genome Copy Number Variation analysis and a Comprehensive Cancer Panel (409 genes) were performed according to our standard protocol.

Results

Histological examination revealed an exophytic lesion within the tubal lumen of the right salpinx, involving only part of the mucosa. The proliferation showed a papillary configuration with loose fibrovascular connective tissue. Epithelial lining consisted of one to two layers of plump, non-ciliated cuboidal cells with eosinophilic cytoplasm mostly in pseudopapillary or papillary architecture. Additionally, scant, intraluminal mucin was observed. Some tufts also contained fibrovascular cores showing small blood vessels. The whole area was surrounded by a dense lymphocytic infiltration. Androgen receptor immunoreactivity of MPT cells was reduced compared to that of normal tubal epithelium. Performing a Low Density Whole Genome Copy Number Variation could not detect any copy number variation. Furthermore, the Comprehensive Cancer Panel did not demonstrate any mutations in 409 investigated genes.

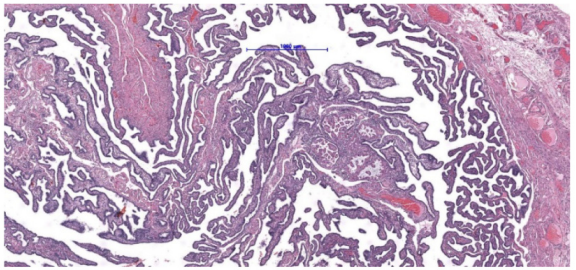

1a: Overview

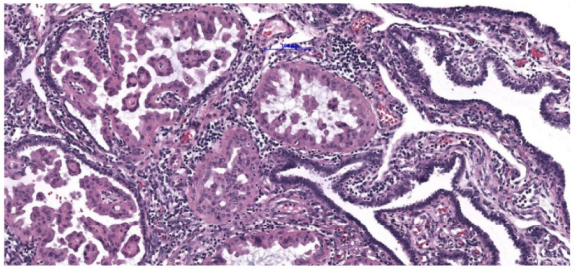

1b: Detail: Papillary configuration with loose fibrovascular connective tissue and dense lymphocytic infiltrate

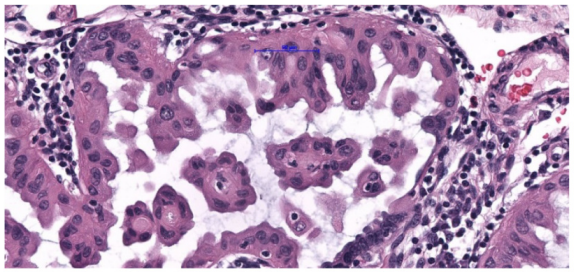

1c: Detail: Epithelial lining consists of one to two layers of plump, non-ciliated cuboidal cells with eosinophilic cytoplasm

Discussion

MPT is an exceedingly rare lesion, due to its rarity and small size, this lesion can be a diagnostic challenge. Only a few examples of this extremely rare lesion have been described in the literature as incidental microscopic finding in segments of fallopian tubes removed during the postpartum period. All reported cases have shown no progression, recurrence or metastases. The fact, that we could not demonstrate any copy number variation or any mutation in the Comprehensive Cancer Panel suggests a metaplastic nature of this lesion.

Hence, we remark the importance not to misdiagnose this entity as serous borderline tumour, STIC or serous carcinoma to avoid overtreatment.