Precursor lesions
Case 8

Pavel Dundr

Department of Pathology, 1st Faculty of Medicine Charles University and General University Hospital in Prague



History

- 58-year-old female
- May 2018 – HSIL in the cytology specimen (screening)
- July 2018 - Cone biopsy (LEEP) – HSIL, AIS, suspicious invasion, positive margin
- Sep 2018 – reconisation (LEEP) – LSIL, free margin
- Jan 2019 – hysterectomy with bilateral salpingectomy

Macroscopy

- Uterine cervix: crater-shaped
- Uterine corpus: subserosal leiomyoma (15 mm in diameter)
- Left Fallopian tube: length 55 mm, diameter 3-4 mm
- Right Fallopian tube: length 60 mm, diameter 3-4 mm

Processing of the Fallopian tube

SEE-FIM

- The entire Fallopian tube is processed
- Profylactic salpingectomy
- Ovarian cancer (HGSC)

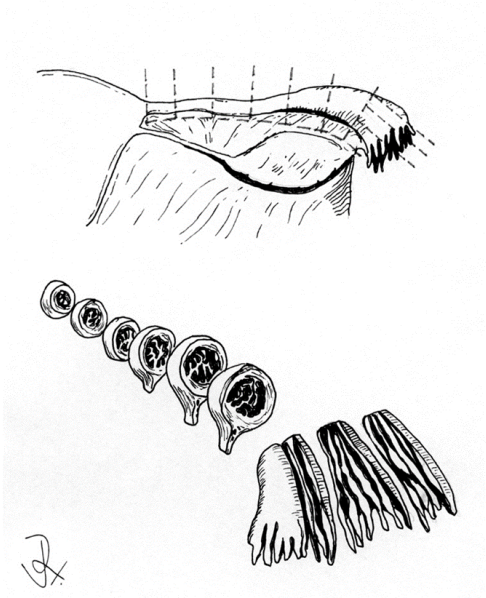

Modified SEE-FIM

- The entire fimbria are processed
- 3 additional transversal sections from different FT areas
- Other indications

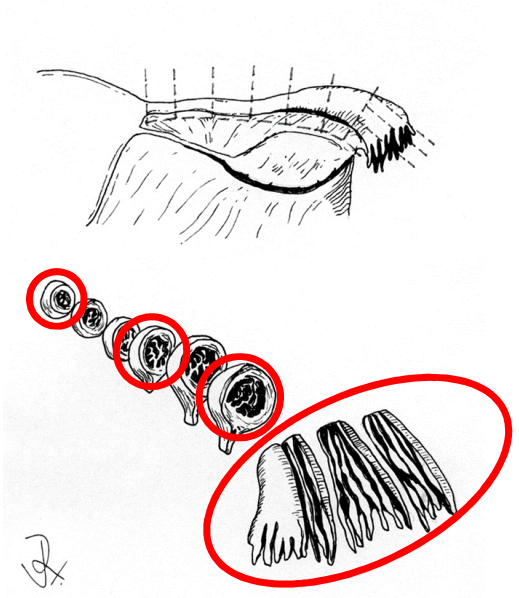

Microscopy – left FT

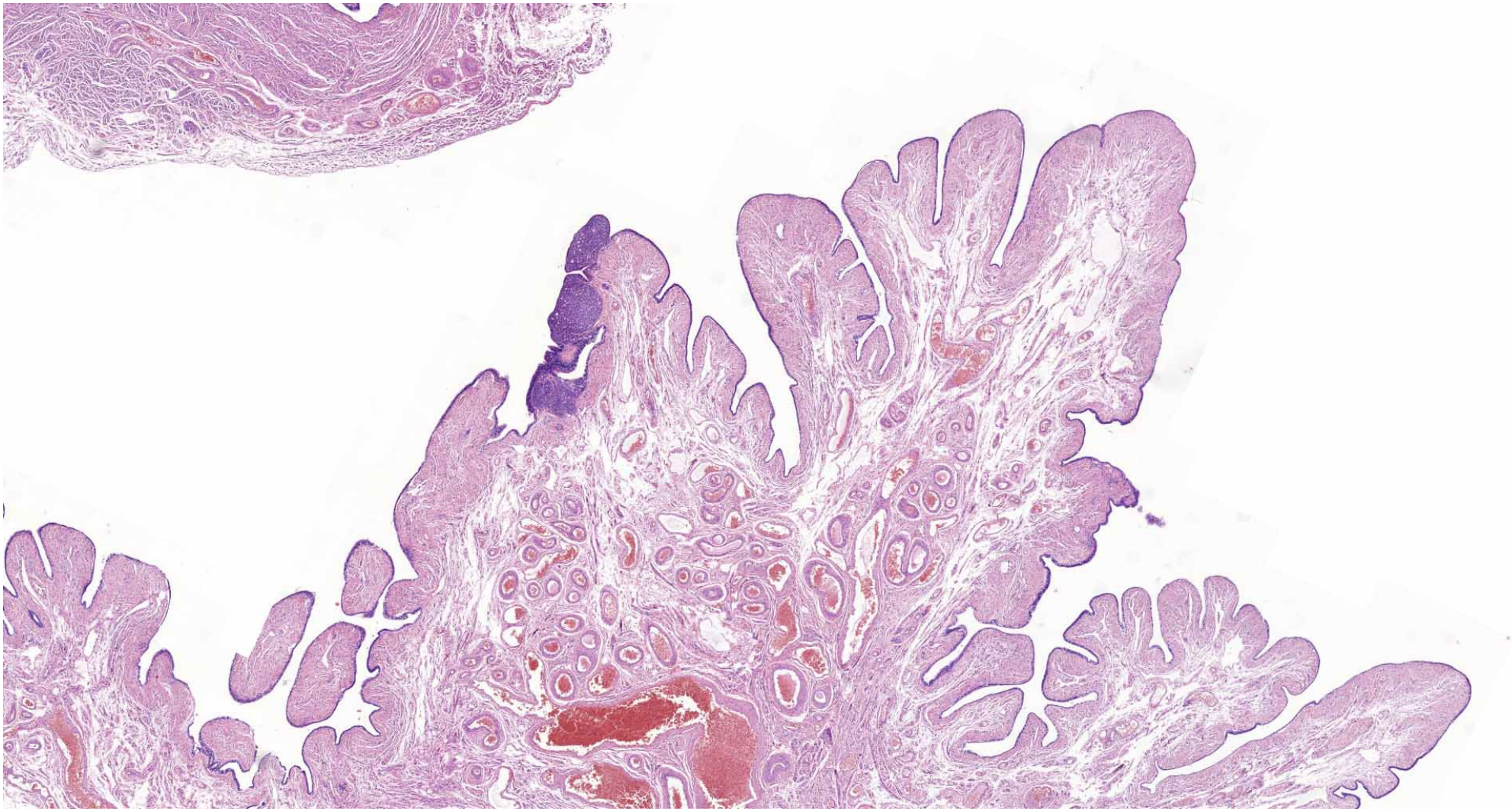

Microscopy – left FT

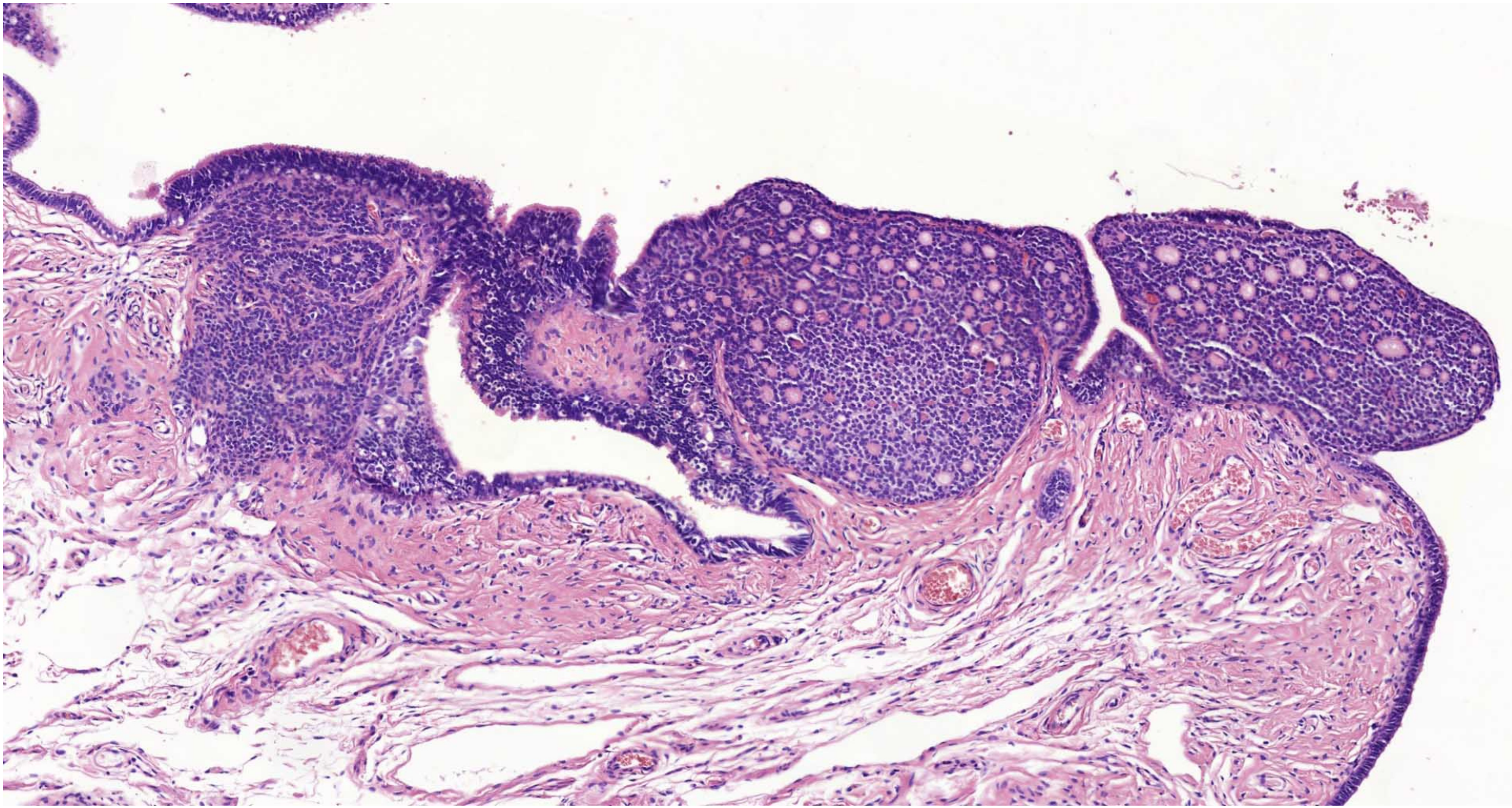

Microscopy – left FT

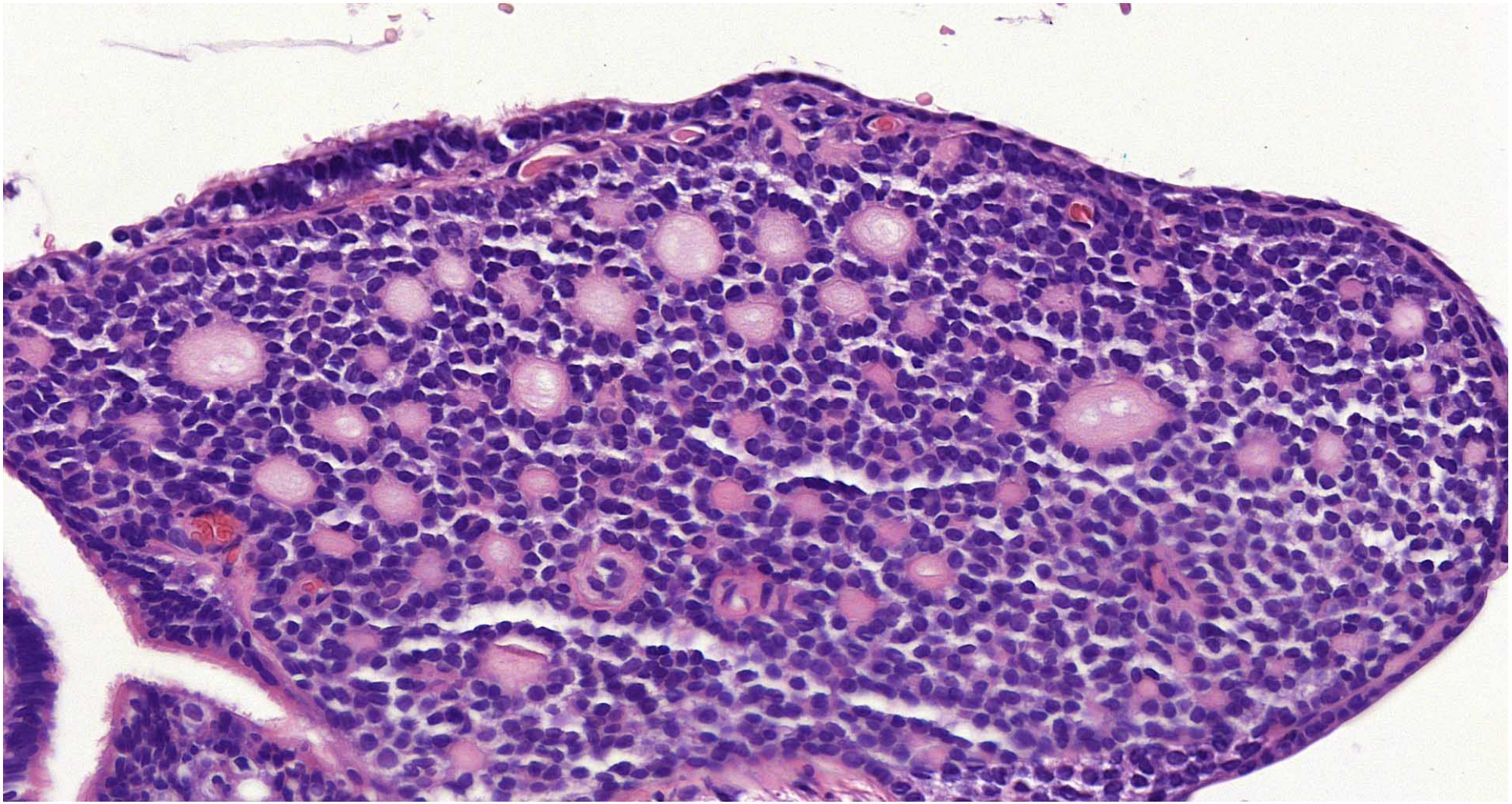

Microscopy – right FT

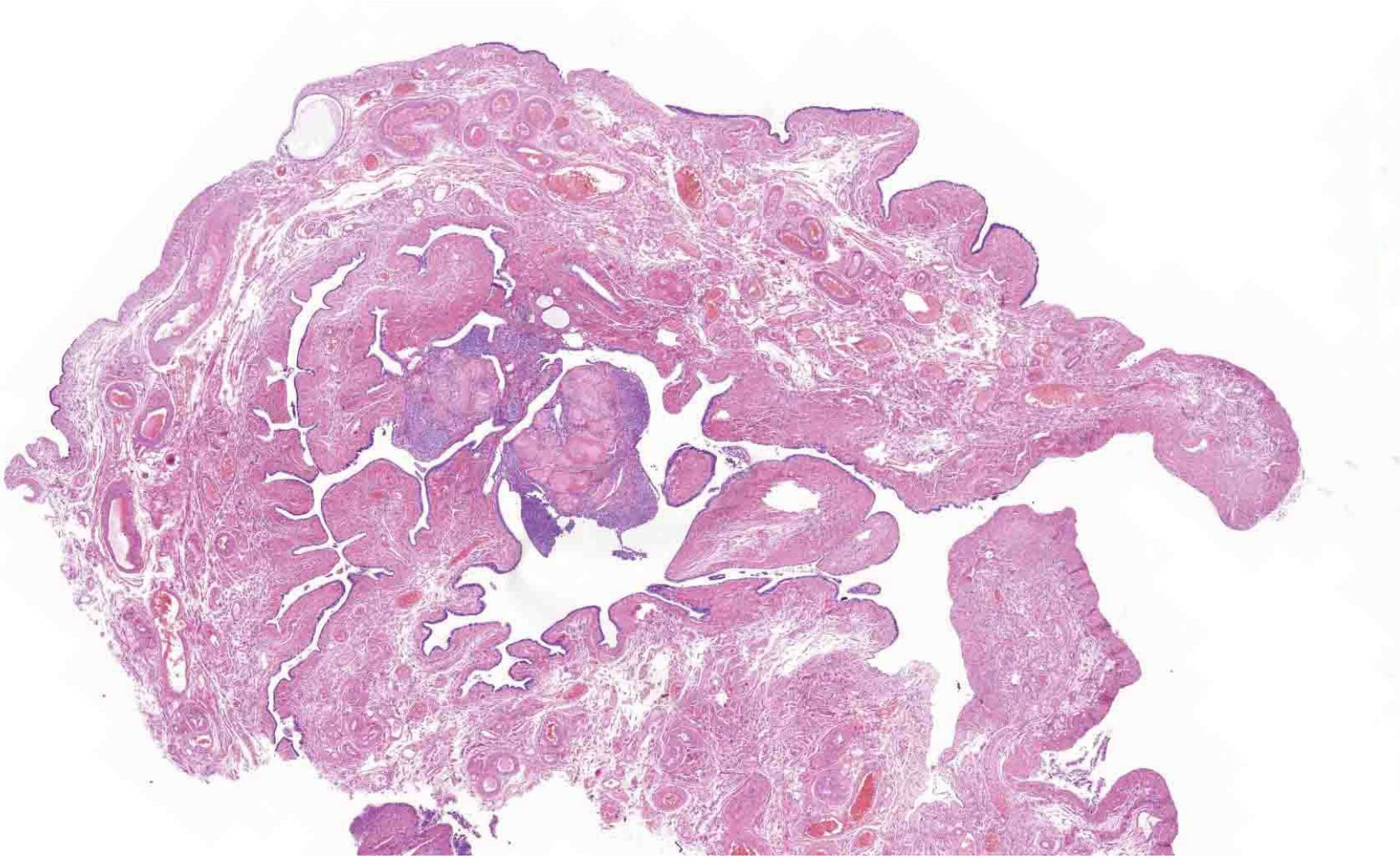

Microscopy – right FT

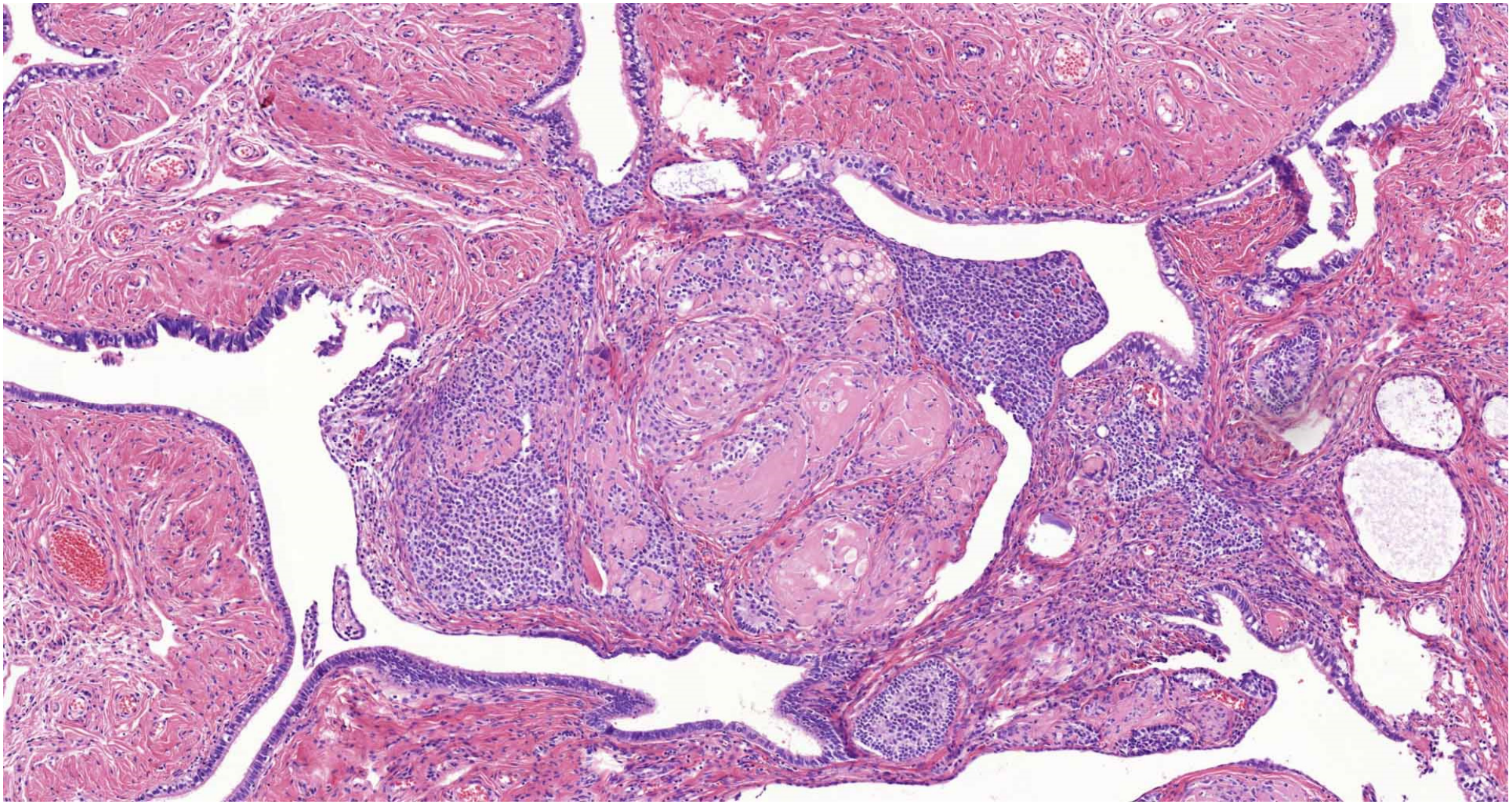

Microscopy – right FT

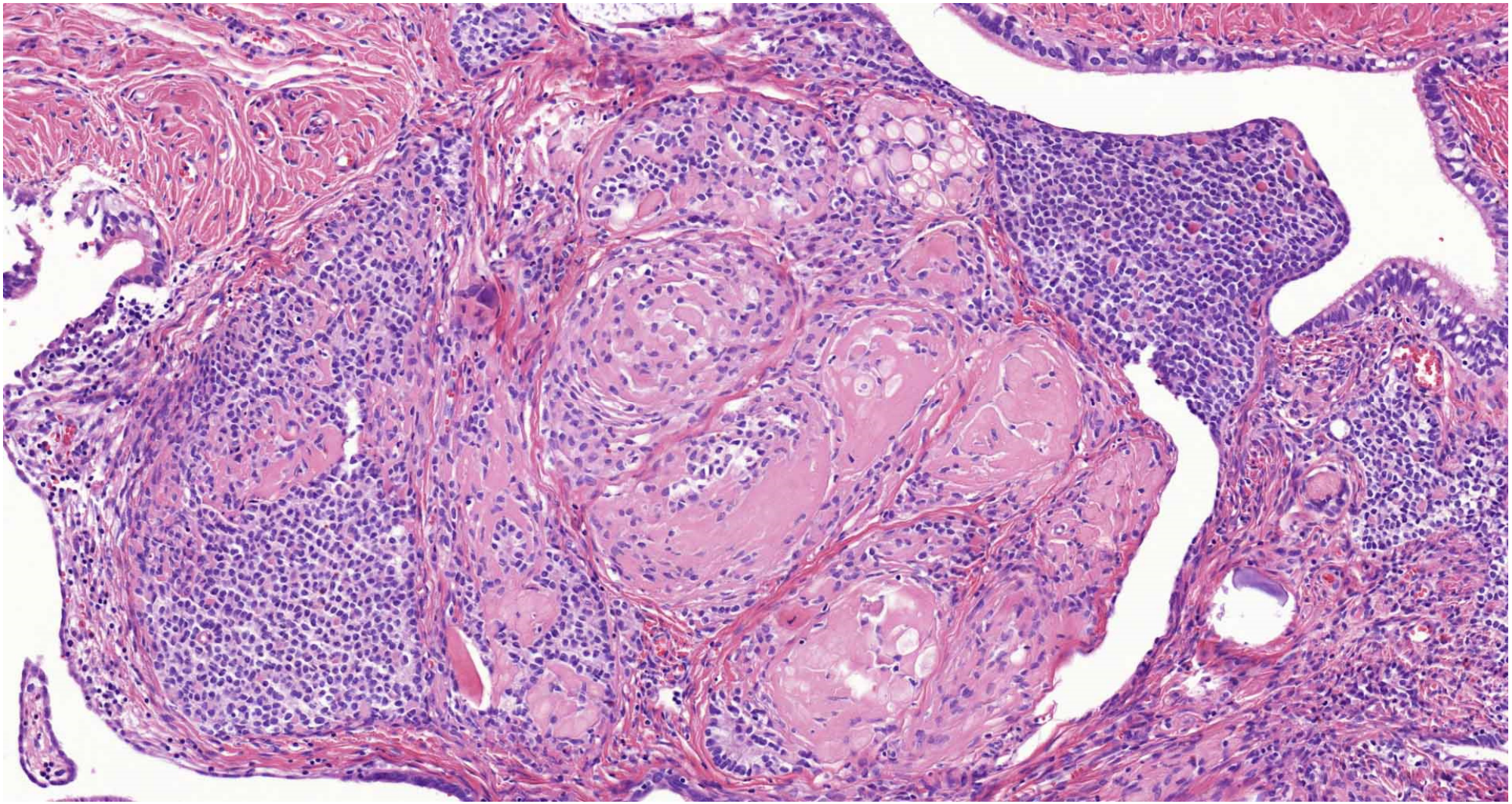

Diagnosis?

Immunohistochemical findings

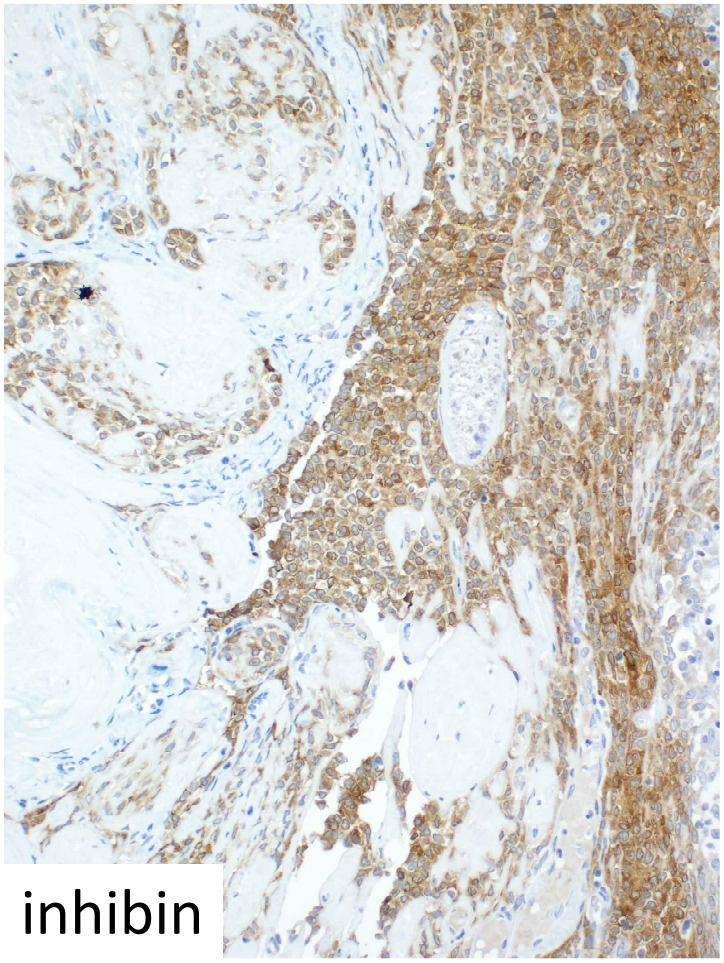

inhibin

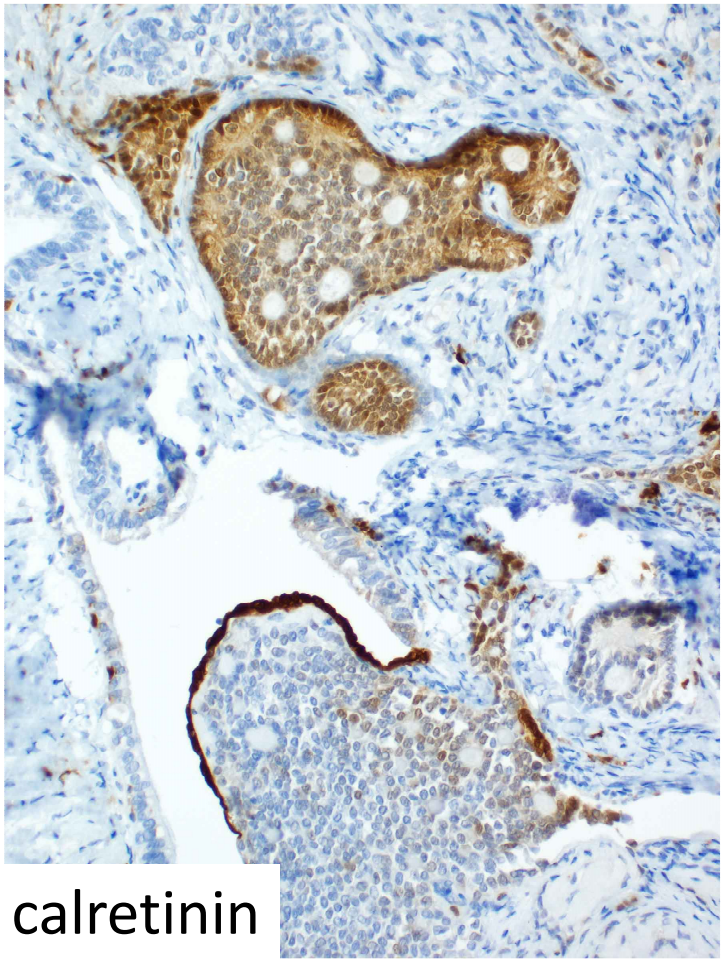

calretinin

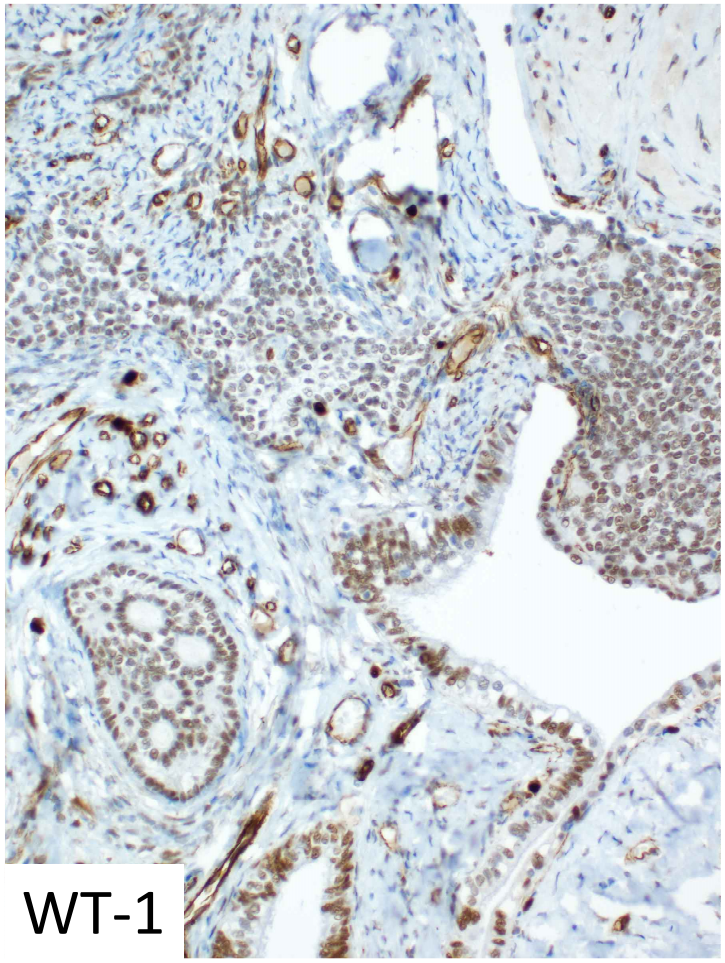

WT-1

Immunohistochemical findings

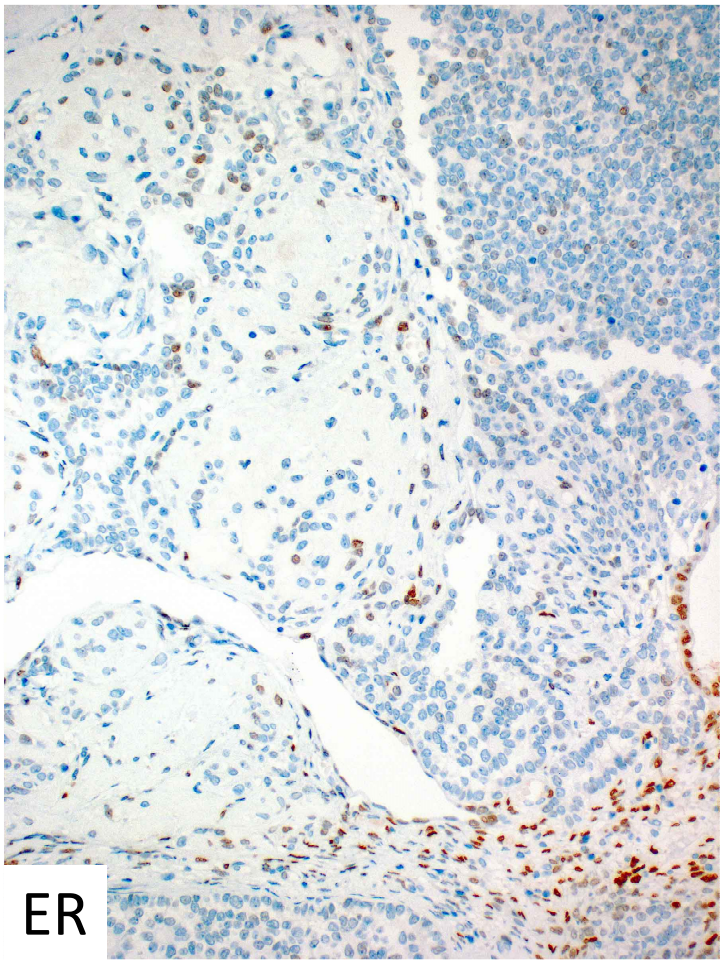

ER

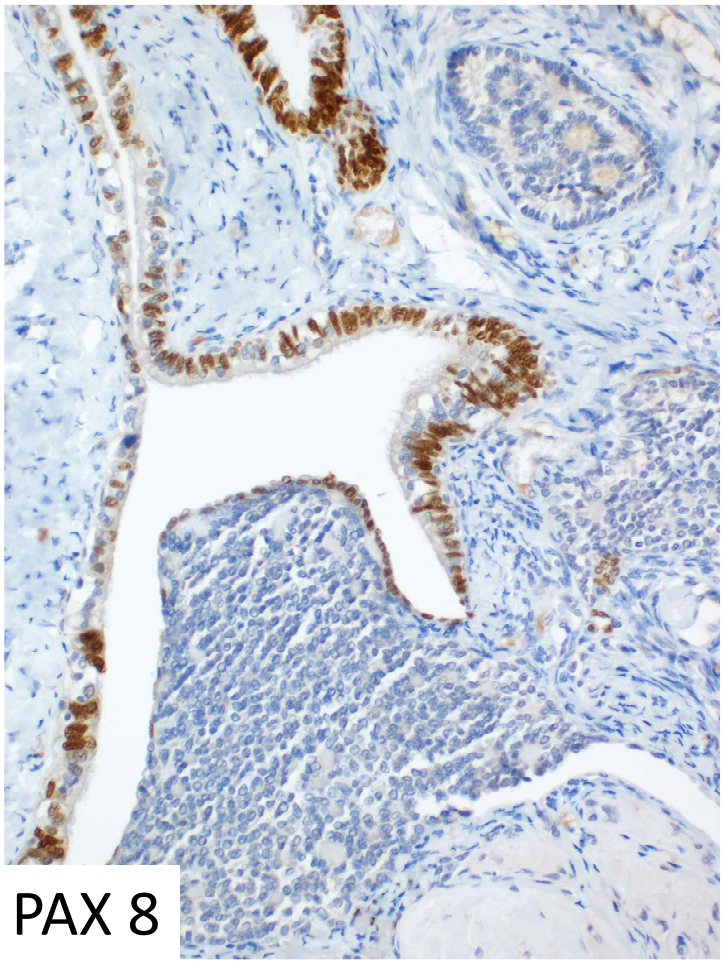

PAX 8

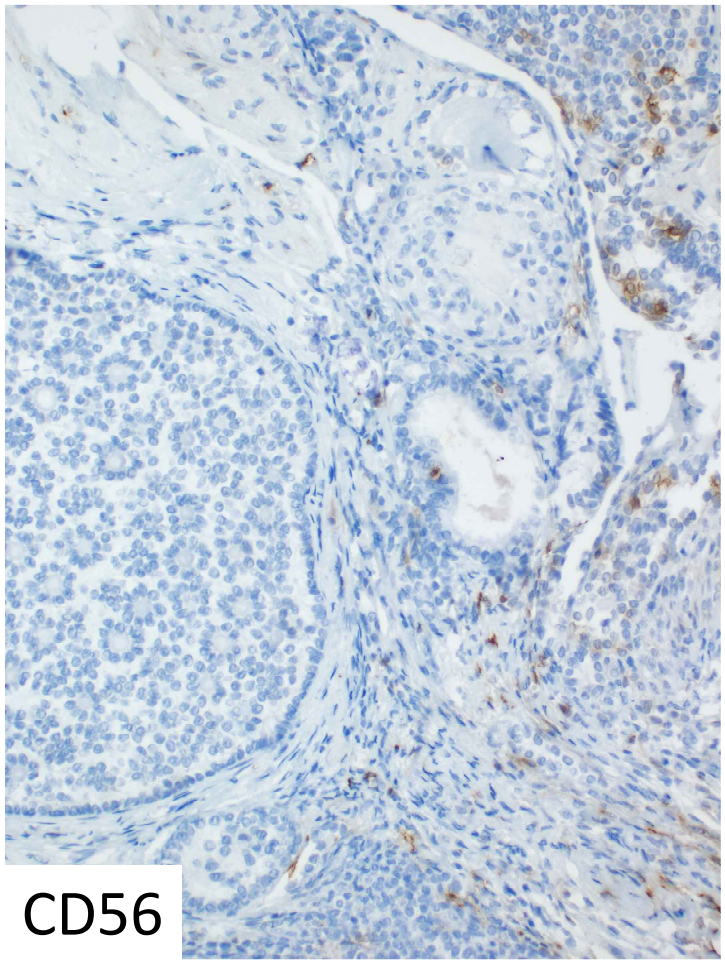

CD56

Immunohistochemical findings - summary

Inhibin	+++
WT-1	+++
Calretinin	++
ER	-+
PR	-+
PAX8	-
actin	-
S-100	-
CD 56	-

Molecular findings

ABL1	BLM	CDKN2B	ESR1	FH	HNF1B	KIF5B	MRE11A	PALB2	QKI	SOX2	VHL
ABL2	BRAF	CDKN2C	ESR2	FOXL2	HRAS	KIT	MSH2	PAX5	RAD50	SOX9	WISP3
AKT1	BRCA1	CLTC	EZH2	FOXP1	CHD2	KMT2A	MSH6	PDGFRA	RAD51	SPEN	WT1
AKT2	BRCA2	CREBBP	FAM175A	GATA1	CHD4	KMT2C	mTOR	PDGFRB	RAF1	SPTA1	XPO1
AKT3	BRD4	CTNNA1	FAM46C	GATA2	CHEK1	KMT2D	MUTYH	PDK1	RARA	SRC	ZBTB2
ALK	BRIP1	CTNNB1	FANCA	GATA3	CHEK2	KRAS	MYC	PIK3C2B	RB1	STAT3	ZNF217
APC	BTK	CYP19A1	FANCC	GATA4	IDH1	LYN	MYCL1	PIK3CA	RET	STAT4	ZNF703
AR	EMSY	DAXX	FANCD2	GATA6	IDH2	LZTR1	MYCN	PIK3CB	RICTOR	STK11	
ARAF	CCDC6	DDR2	FANCE	GNA11	IGF1R	MAP2K1	NACC2	PIK3CG	RIT1	SUFU	
ARID1A	CCND1	DICER1	FANCF	GNA13	IGF2	MAP2K2	NBN	PIK3R1	ROS1	SYK	
ARID1B	CCND2	DNMT3A	FANCG	GNAQ	IKZF1	MAP2K4	NCOA4	PIK3R2	RUNX1	TAF1	
ARID2	CCND3	DPYD	FANCL	GNAS	IRF2	MAP3K1	NF1	PMS2	RUNX1T1	TBX3	
ATM	CCNE1	EGFR	FBXW7	GRB2	IRF4	MAPK1	NF2	POLD1	SDHA	TERT p.	
ATR	PDL1	ELK1	FGF10	GRIN2A	IRS2	MAPK3	NFKBIA	POLE	SDHB	TET2	
ATRX	CD79A	EML4	FGF14	GRM3	JAK1	MCL1	NKX2-1	POLQ	SDHC	TGFBR2	
AURKA	CD79B	EPHA3	FGF19	GSK3B	JAK2	MDM2	NOTCH1	POT1	SDHD	TOP1	
AURKB	CDH1	EPHA5	FGF23	H3F3A	JAK3	MDM4	NOTCH2	PPM1D	SF3B1	TOP2A	
B2M	CDK12	EPHA7	FGF3	H3F3B	JUN	MED12	NOTCH3	PPP2R1A	SMAD2	TP53	
BAP1	CDK4	EPHB1	FGF4	H3F3C	KAT6A	MEN1	NPM1	PPP6C	SMAD3	TPM3	
BARD1	CDK6	ERBB2	FGF6	HDAC2	KDM5A	MET	NRAS	PRKAR1A	SMAD4	TSC1	
BCL2	CDK8	ERBB3	FGFR1	HGF	KDM5C	MITF	NTRK1	PRKCI	SMARCA4	TSC2	
BCL2L1	CDKN1A	ERBB4	FGFR2	HIST1H3B	KDM6A	MLH1	NTRK2	PRKDC	SMARCB1	U2AF1	
BCL2L2	CDKN1B	ERCC3	FGFR3	HMGA2	KDR	MLH3	NTRK3	PTEN	SMO	UGT1A1	
BCL6	CDKN2A	ERG	FGFR4	HNF1A	KEAP1	MPL	PAK3	PTCH1	SOX10	VEGFA	

- In-house NGS panel
- Roche NimbleGen Seq Cap EZ protocol
- Mid Output Kit v2 (150 cycles); NextSeq (Illumina)
- 1020 kbp panel (271 genes, 725kbp of coding sequence)

Results

- **FOXL 2** - **wt** (average coverage >540x)
- **No pathogenic somatic mutations were detected exclusively in the lesions** when compared to non-lesional tissue
- Several **hereditary variants** of unknown significance detected:

Gene	Mutation RefSeq: c. RefSeq: p. dbSNP	Zygosity VAF	Impact - databases ClinVar/HGMD	Impact - *in silico* (VEP)	Gene function
FGFR4	NM_213647.2: c.1162G>A NP_998812.1:p.(G388R) rs351855	Homozygous 100%	VUS / disease associated polymorphism	Benign	Tyrosine-protein kinase MAPK and AKT1signaling pathway
NBN	NM_002485.4:c.511A>G NP_002476.2:p.(Ile171Val) rs61754966	Heterozygous 50%	VUS / disease causing	Benign	Double-strand break repair MRE11-RAD50-NBN complex
KDM5A	NM_001042603.1:c.4831G>A NP_001036068:p.(A1611T) rs200109736	Heterozygous 50%	NA / NA	Pathogenic	Histone demethylase
MLL2 (**KMT2D**)	NM_003482.3:c.941C>G NP_003473.3:p.(S314C) rs1043654062	Heterozygous 50%	VUS / NA	Likely pathogenic	Histone methyltransferase

Result: FOXL 2 – wild type

- **FOXL 2** - **wt** (average coverage >540x)

XX-19-1M

Min Coverage	298x
Max Coverage	1373x
Average	770x

XX-19-1O

Min Coverage	170x
Max Coverage	1100x
Average	543x



Diagnosis?

Microscopic extraovarian sex-cord proliferation

Microscopic extraovarian sex-cord proliferation

- 11 cases reported up to date:
  - fallopian tube (5)
  - parovarian cyst wall (3)
  - parovarian connective tissue (1)
  - pelvic side wall (1)
  - serosa of the appendix (1)

- Mimicking adult granulosa cell tumor or sex cord tumor with annular tubules

BUT

- Small size (up to 3,75 mm)
- Absence of an ovarian sex cord neoplasm
- No subsequent tumor development (?)

McCluggage WG, et al. Histopathology. 2015;66(4):555-64.
Longworth AG, et al. Int J Gynecol Pathol. 2018;37(1):35-43.
Pennacchia, IA, et al. Int J Gynecol Pathol. 2018;37(4):347-348.

Differential diagnosis

- Minor adult granulosa cell tumor (AGCT) or sex cord tumor with annular tubules (SCTATs)
- Metastatic spread of AGCT or SCTATs
- Metastasis of another tumor (small cell carcinoma, carcinoid…)
- Displaced granulosa cells from developing ovarian follicles
  - usually in vascular channels
  - sheets of cells (no architectural patterns)
- Benign conditions
  - Walthard nests
  - Mesothelial proliferations

Biological potential, clinical significance

- Microscopic extraovarian AGCTs or SCTATs? – unlikely
- Heterotopia - embryonic rests with an abnormal location due to aberrant migration
- Origin from exposed ovarian tissue at the site of ovulation
- Histogenetic origin of extraovarian AGCT?

- **Spectrum of other extraovarian sex cord-stromal proliferations:**
  - ovarian cortical stroma
  - serous adenofibroma/ cystadenofibroma-like appearance
  - Brenner adenofibroma
  - heterotopic hilus cell
- Mostly fimbrial part of FT
- Pelvic sidewall
- Parovarian connective tissue
- Appendiceal serosa

Recommended reporting

- "Microscopic extraovarian sex-cord proliferations morphologically resembling adult granulosa cell tumor and/or sex cord tumor with annular tubules"

  - Exact significance uncertain
  - Benign non-neoplastic lesion is favoured rather than a microscopic neoplasm
  - Suggest clinical follow-up with or without appropriate imaging studies and determination of serum inhibin levels