Ovarian carcinoma:
The most common mistakes in diagnosis

Pavel Dundr

Department of Pathology, 1st Faculty of Medicine, Charles University and General University Hospital in Prague





Possible mistakes in ovarian carcinoma diagnosis

- **Critical errors**

  1) Biological potential
  - benign
  - borderline
  - malignant

  2) Primary source
  - primary
  - metastatic

  (clinico-pathological correlation !!!)

- **Other errors (may be critical / serious)**

  1) Histological (tumor cell) type
  - HGSC
  - LGSC
  - endometroid
  - clear cell
  - mucinous

  2) Grading
  - endometrioid, mucinous
  - serous (absent or G2)

  3) Classification of implants in S-BTO

  4) Staging
  - pTNM / FIGO 2014

Biological potential of tumor

- **Benign vs. borderline**
  Borderline vs. malignant
  Benign vs. malignant

  Malignancy criteria may vary according to histological type!

  Invasion (expansile, infiltrative)
  EC, MC, LGSC (rarely absent in HGSC!)

- **Nuclear atypia** (HG / LG)
  E-BTO, M-BTO (BTO with intraepithelial carcinoma)
  S-BTO cannot display HG atypia!

- **Mitoses** (number, typical / atypical)

- **Still some unclear aspects:**

- Extent of invasion necessary for the diagnosis of invasive LGSC
- Classification of "invasive implants" (classical vs. extended criteria)
- WHO classification with respect to nomenclature = invasive implants = LGSC (!)
- The clinical significance of some findings (BOT with microinvasion / microinvasive carcinoma)

Biological potential - Serous tumors

- Serous cystadenoma / adenofibroma / surface papilloma
- Serous cystadenoma with focal epithelial proliferation
- S-BTO ("usual" type)
- Micropapillary S-BTO (non-invasive LGSC)
- LGSC
- HGSC

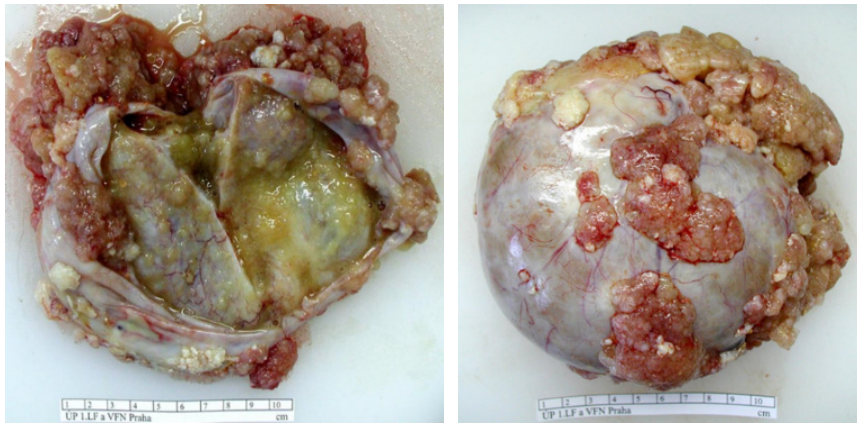

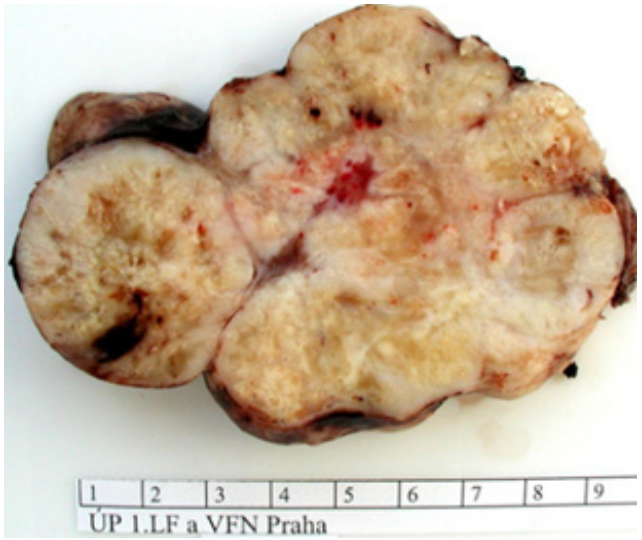

Biological potential - Serous tumors

- Population study of S-BTO from Denmark (1978-2002)
- 1259 patients with available biopsy material

- Change in diagnosis in 265/1259 (21%) tumors after revision

- 237 (19%) benign tumors (benign cystadenoma with focal epithelial proliferation)
- 16 (1.3%) carcinomas
- 12 (0.8%) BOT but not serous

Vang R et al. Am J Surg Pathol (2017); 41: 725-737.

Borderline tumors (AGO* study group)

- 803 BTO with a central review
- 92 patient (11,5 %) major diagnostic discrepancy
- - 52 (6,5%) benign tumors
- - 40 (5%) carcinomas

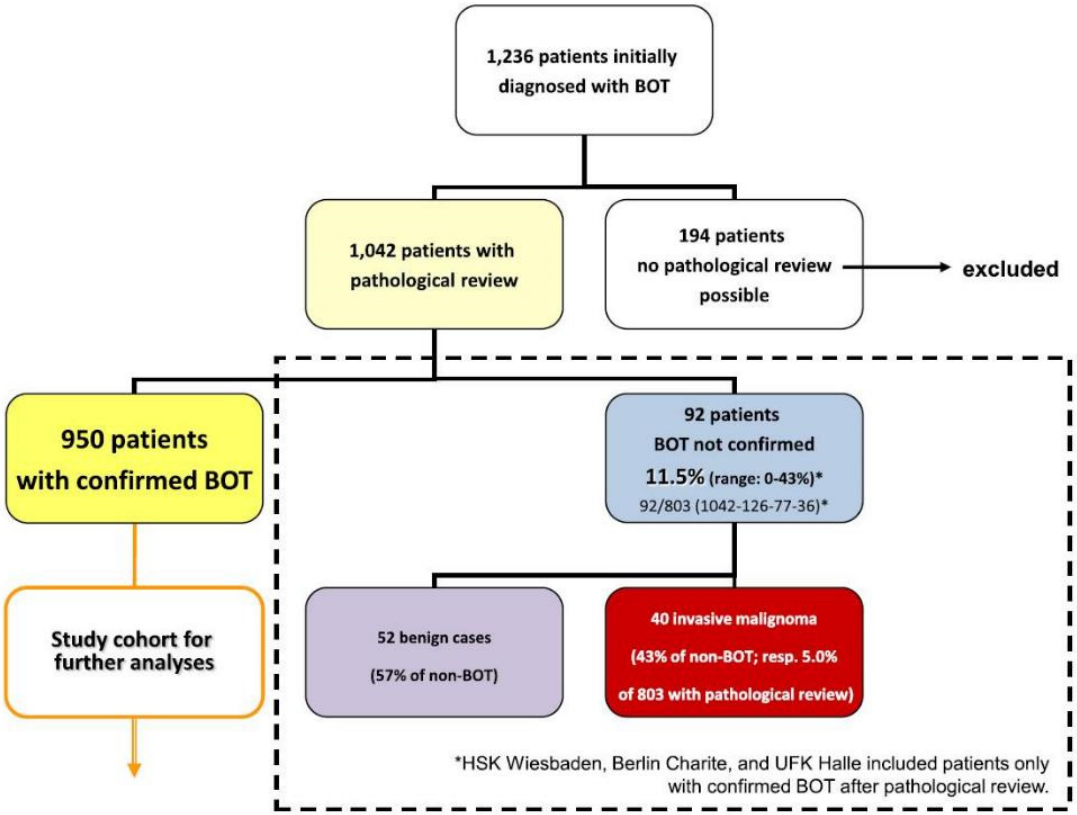

*Arbeitsgemeinschaft Gynäkologische Onkologie

du Bois A, et al. Eur J Cancer. 2013;49(8):1905-14.

Ovarian carcinoma (AGO* study group)

- AGO-OVAR11t-HISTO protocol
- 454 ovarian, tubal, or peritoneal carcinoma

- Major diagnostic discrepancy in 6.8% (31 patients):
  - 15 patients S-BTO
  - 13 patients metastasis
  - 3 nonepithelial malignant tumors

- Minor diagnostic discrepancy in 22% (100 patients):
  - favour endometroid over serous
  - favour serous over clear cell
  - favour mixed carcinoma

TABLE 1. Distribution of histological types and agreement rates between original diagnosis and central gynecopathological case review

	Original Diagnosis		Review Diagnosis		Agreement	
	n	%	n	%	n	%
Serous	309	68.1	262	57.6	229/309	74.1
Endometrioid	31	6.8	14	3.1	7/31	22.6
Clear cell	17	3.7	25	5.5	15/17	88.2
Mucinous	13	2.9	6	1.3	4/13	30.8
Mixed	20	4.4	43	9.5	10/20	50.0
Transitional cell	4	0.9	6	1.3	1/4	25.0
Undifferentiated	12	2.6	14	3.1	4/12	33.3
Unclassified	14	3.1	1	0.2	0/14	00.0
Peritoneal	18	4.0	33	7.3	13/18	72.2
Tubal	16	3.5	19	4.2	12/16	75.0
Other	n.a.	n.a.	*31*	*6.8*	n.a.	n.a.
Total	454	100	454	100	295/454	65.0

*Arbeitsgemeinschaft Gynäkologische Onkologie

Kommoss S, et al. Int J Gynecol Cancer. 2013;23(8):1376-82.

Western Australia Cancer Registry

- 1321 BOT and carcinomas
- Review of the pathology reports and clinical data
- Uncertain diagnosis in 135 cases (10.2 %)
- Possible review in 92 cases – amendment of the diagnosis in 63 (68.5%) of cases:
  - EC, TC, UC as HGSC
  - mixed ca as pure ca

Final Diagnosis (n)	Initial Diagnosis (n)
Borderline tumor (3)	Carcinoma (3)
Carcinoma	
High-grade serous (44)	Grade 2/uncertain grade serous carcinoma (14), undifferentiated/poorly differentiated carcinoma (8), carcinoma of mixed histologic type (6), possible metastasis (5), carcinoma NOS (5), grade 3 EC (2), TCC (2), grade 2 EC (1), MUCA (1)
Endometrioid (7)	Carcinoma of mixed histologic type (4), mucinous carcinoma (1), adenosquamous carcinoma (1), serous carcinoma (1)
Clear cell (3)	Carcinoma of mixed histologic type (2), metastatic carcinoma (1)
Mucinous (3)	Borderline mucinous tumor/carcinoma (2), carcinoma of mixed histologic type (1)
Low-grade serous (3)	Serous carcinoma not graded (2), carcinoma of mixed histologic type (1)

EC indicates endometrioid carcinoma; MUCA, mucinous carcinoma; NOS, not otherwise specified; TCC, transitional carcinoma.

Stewart CJR, et al. Int J Gynecol Pathol. 2017;36(4):377-385.

Epithelial ovarian tumors – consultation cases

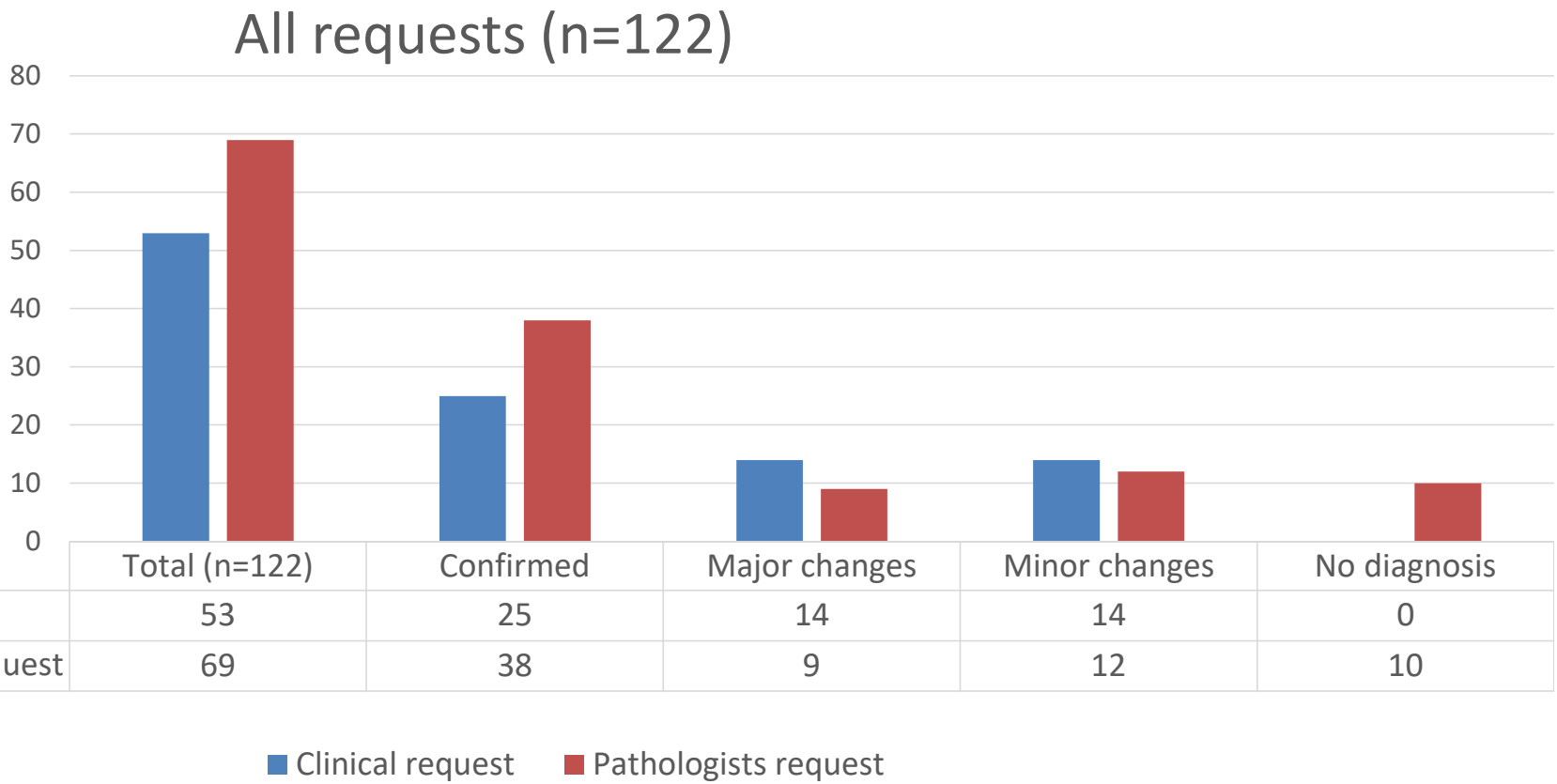

	Total (n=122)	Confirmed	Major changes	Minor changes	No diagnosis
Clinical request	53	25	14	14	0
Pathologists request	69	38	9	12	10

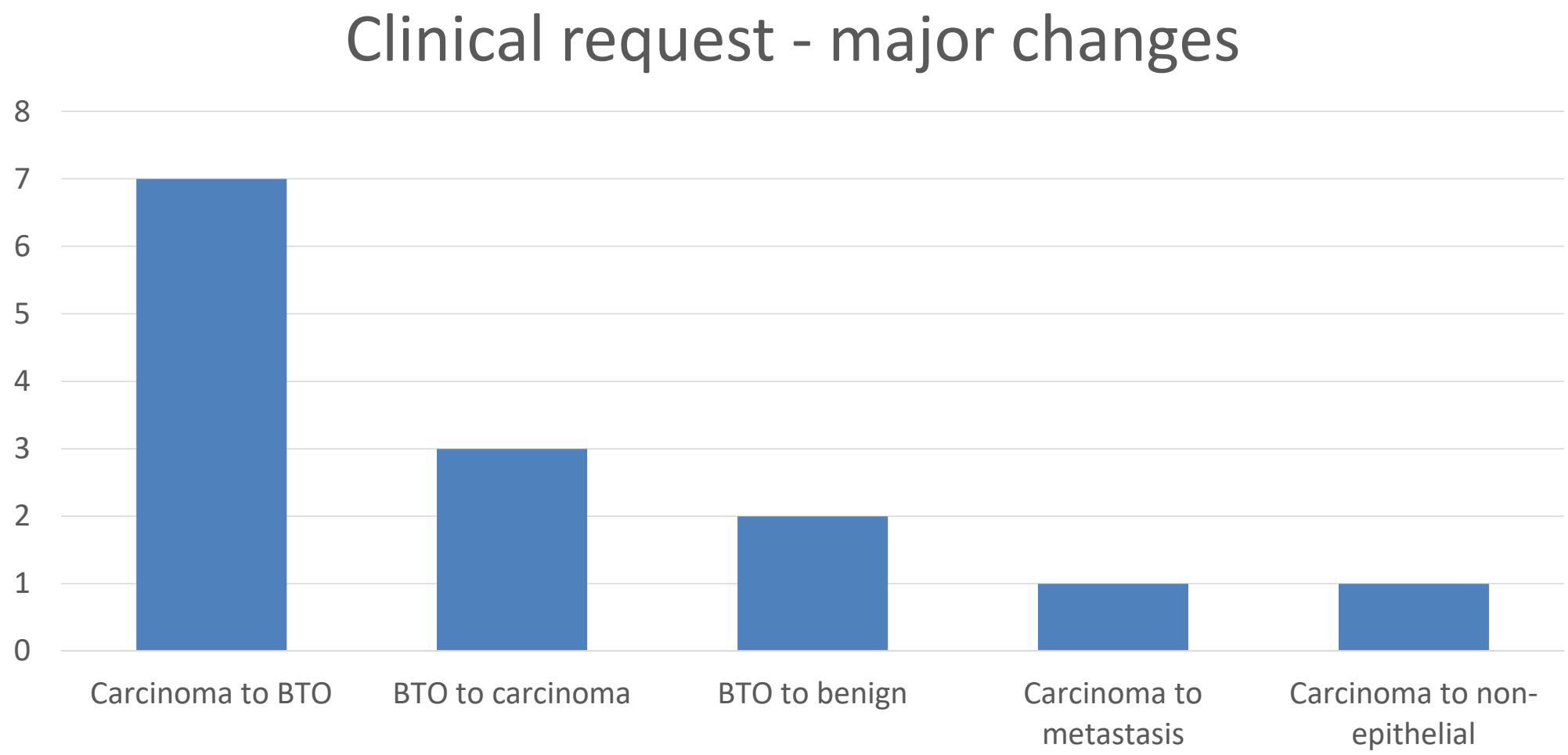
Clinical request - major changes
8
7
6
5
4
3
2
1
0
Carcinoma to BTO
BTO to carcinoma
BTO to benign
Carcinoma to metastasis
Carcinoma to non-epithelial

Clinical request - major changes

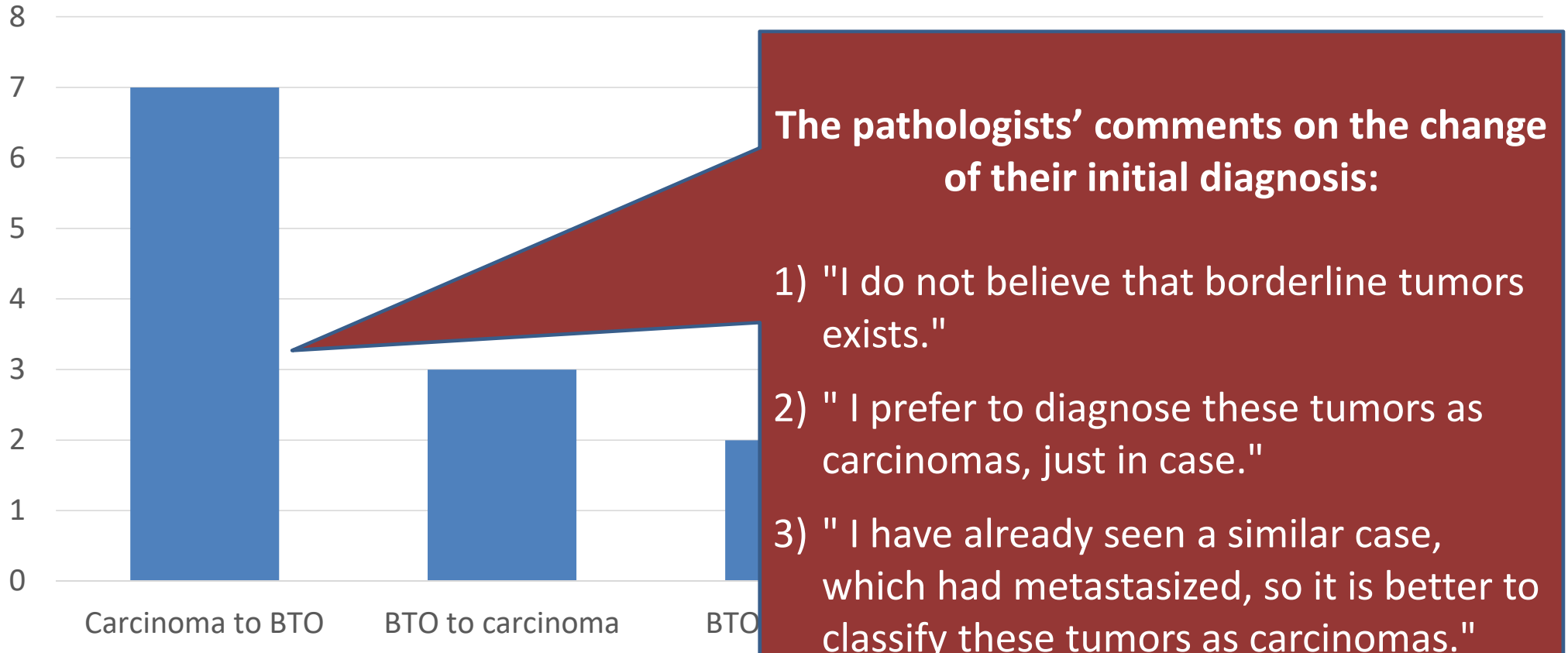

The pathologists' comments on the change of their initial diagnosis:

1) "I do not believe that borderline tumors exists."
2) " I prefer to diagnose these tumors as carcinomas, just in case."
3) " I have already seen a similar case, which had metastasized, so it is better to classify these tumors as carcinomas."

Clinical request - minor changes

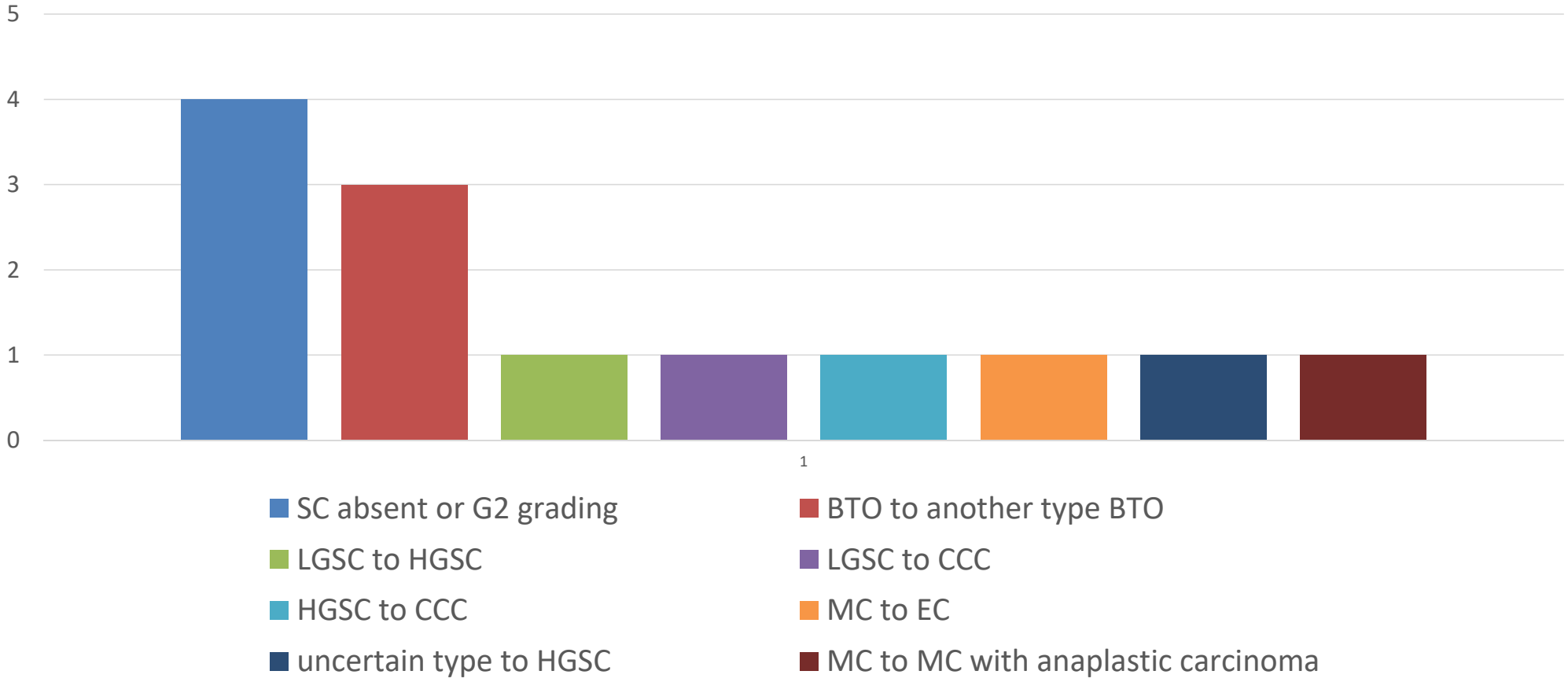

Pathologist’s request - major changes

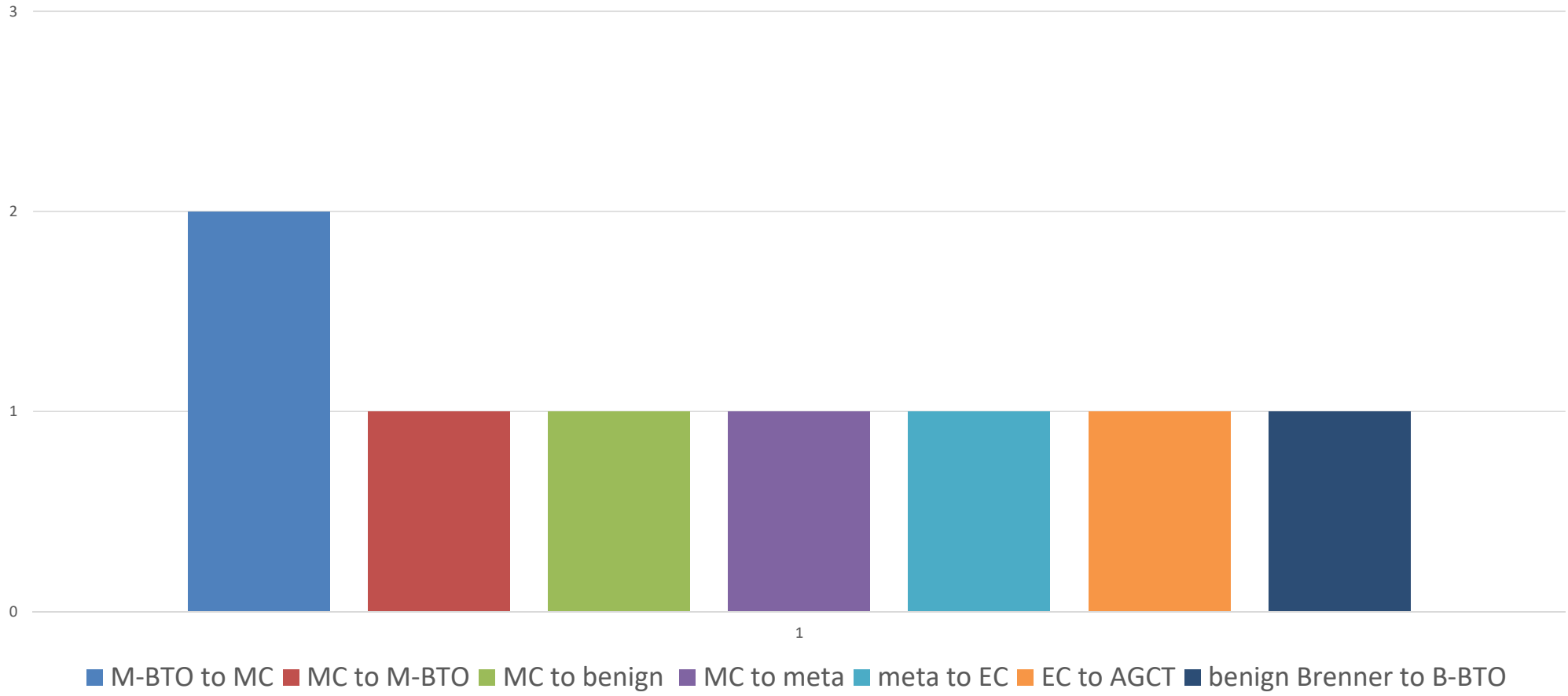

Initial diagnosis: S-BTO

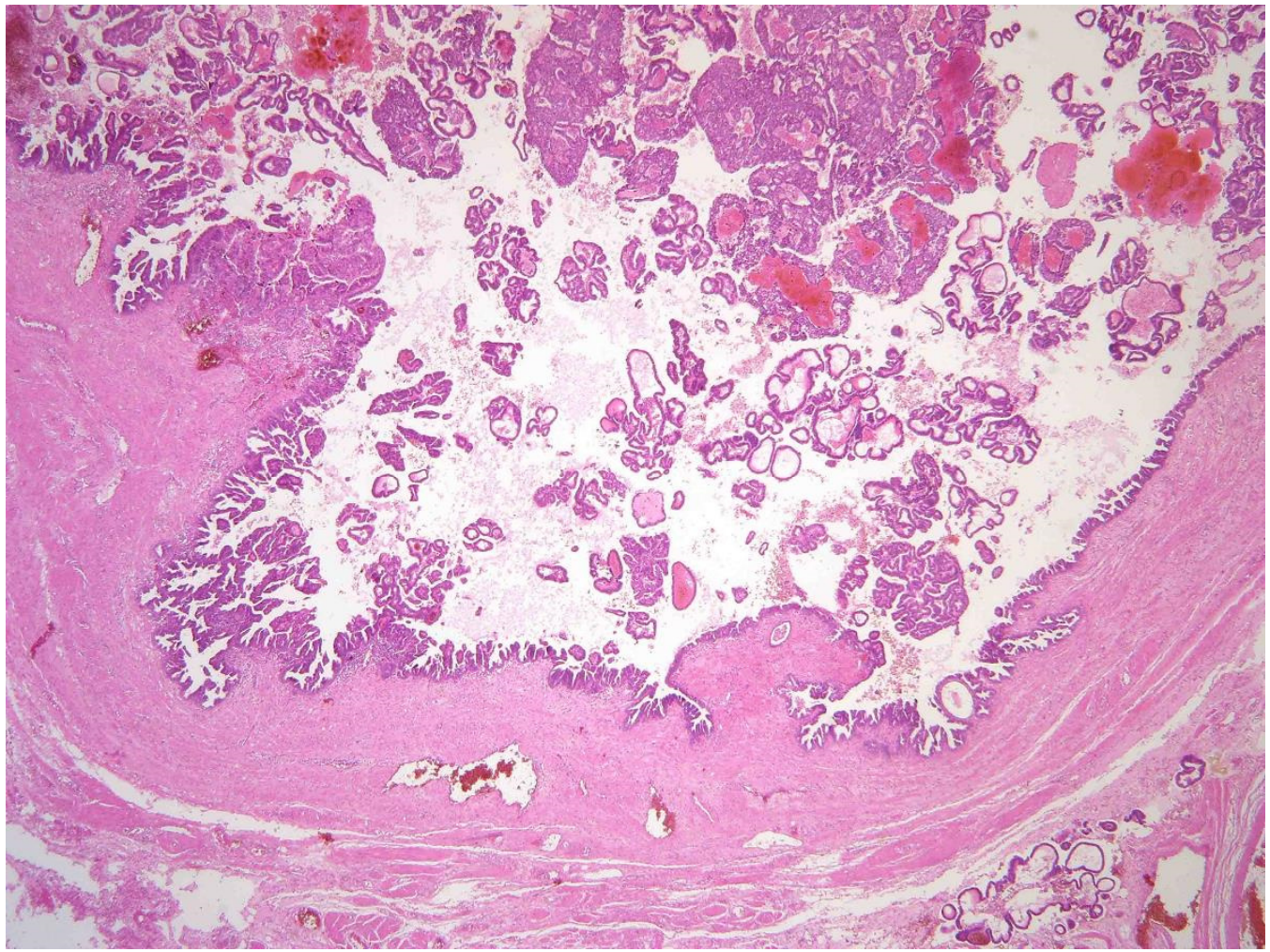

Initial diagnosis: S-BTO

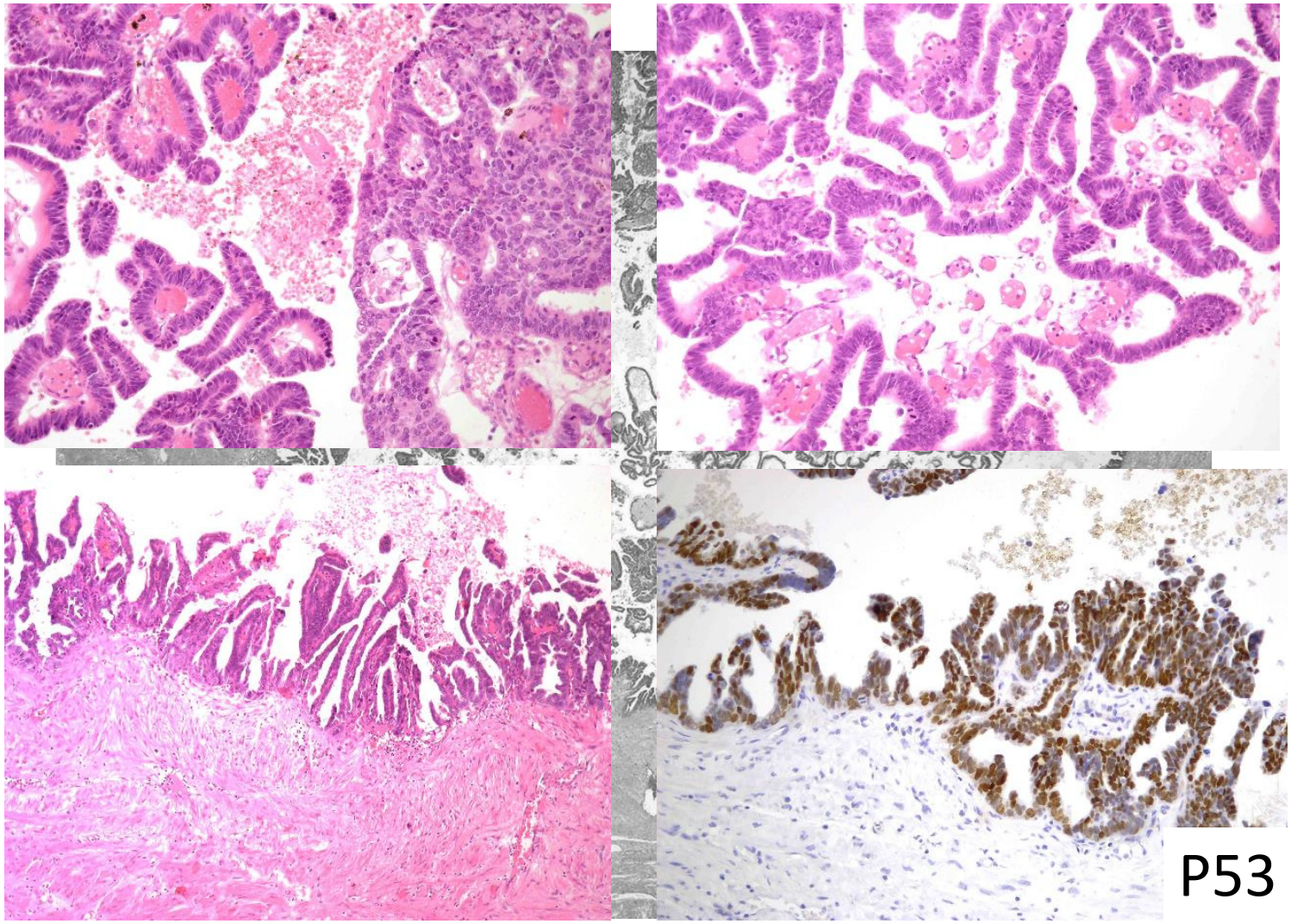

Diagnosis after a review: HGSC

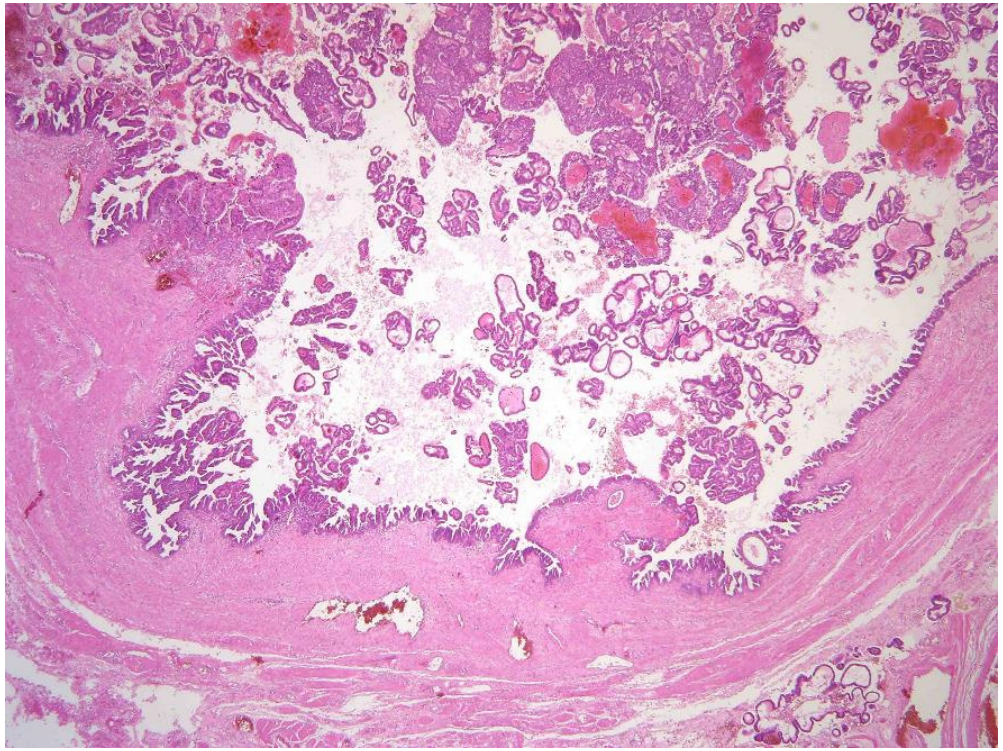

- 64-year old female
- 7/2011: S-BTO
- 1/2012: widespread abdominal cavity tumor
- 1/2012: review of the initial biopsy – HGSC
- 7/2012 DOD

Initial diagnosis: S-BTO

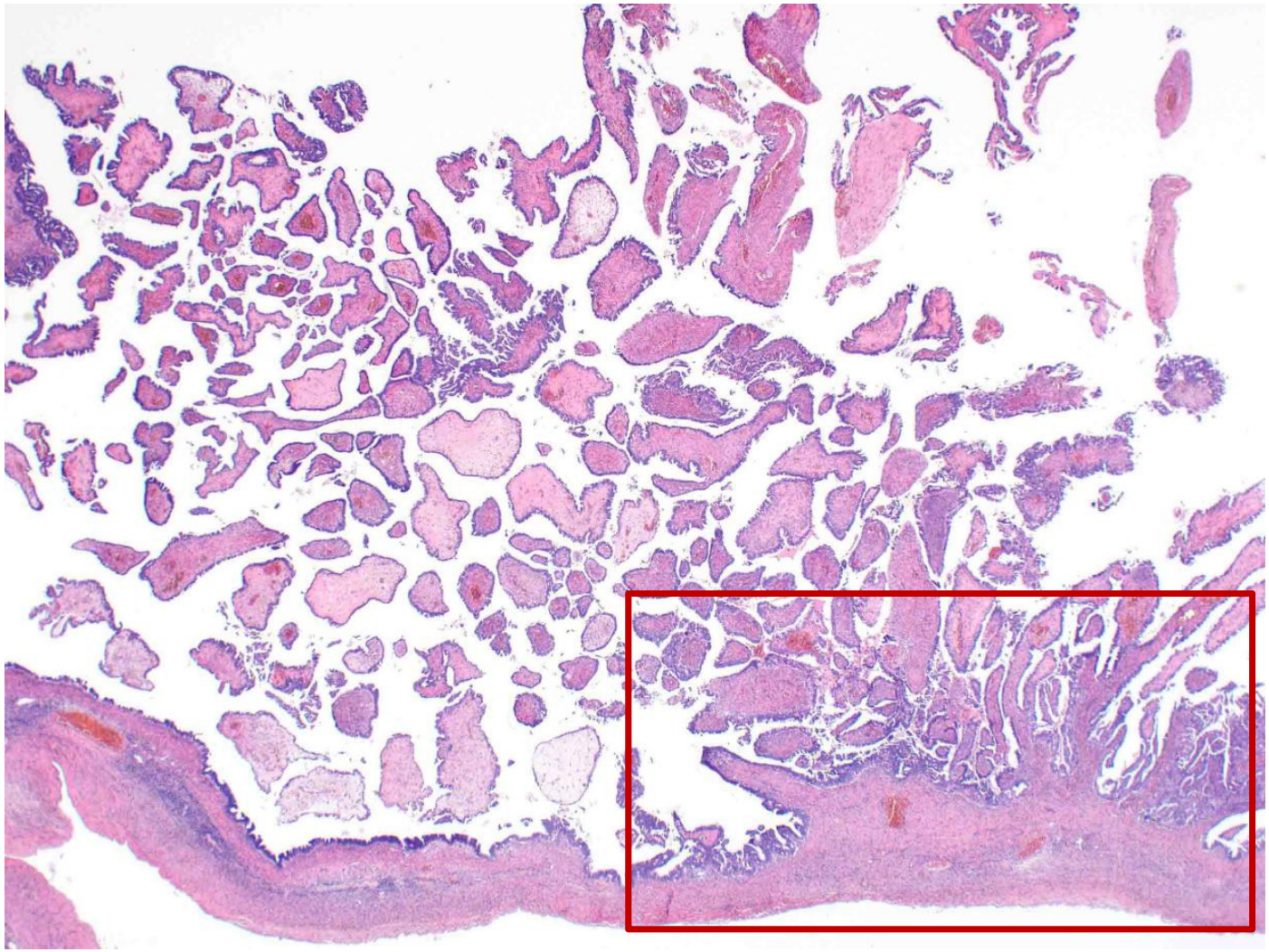

Initial diagnosis: S-BTO

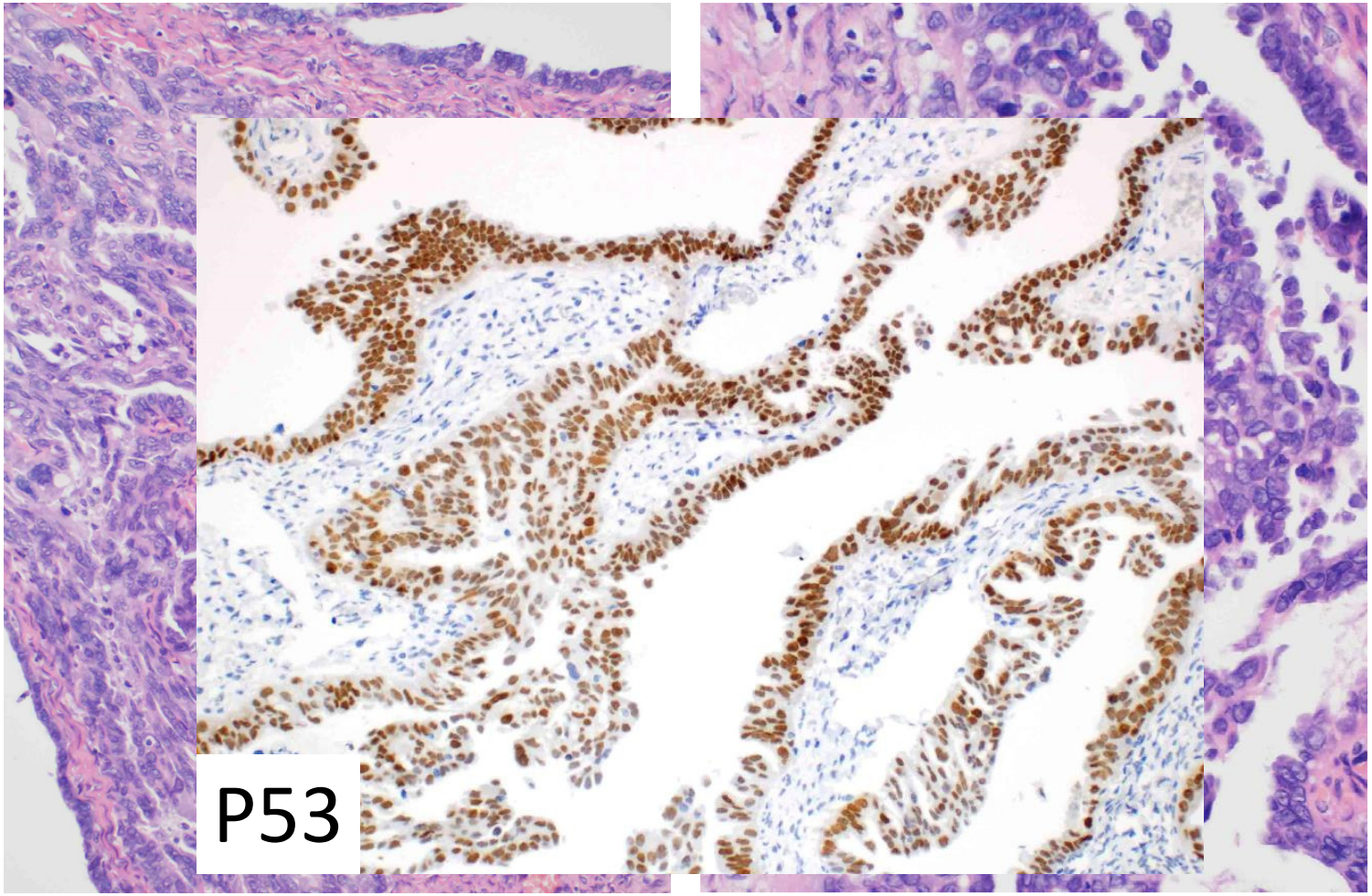

Diagnosis after a review: HGSC

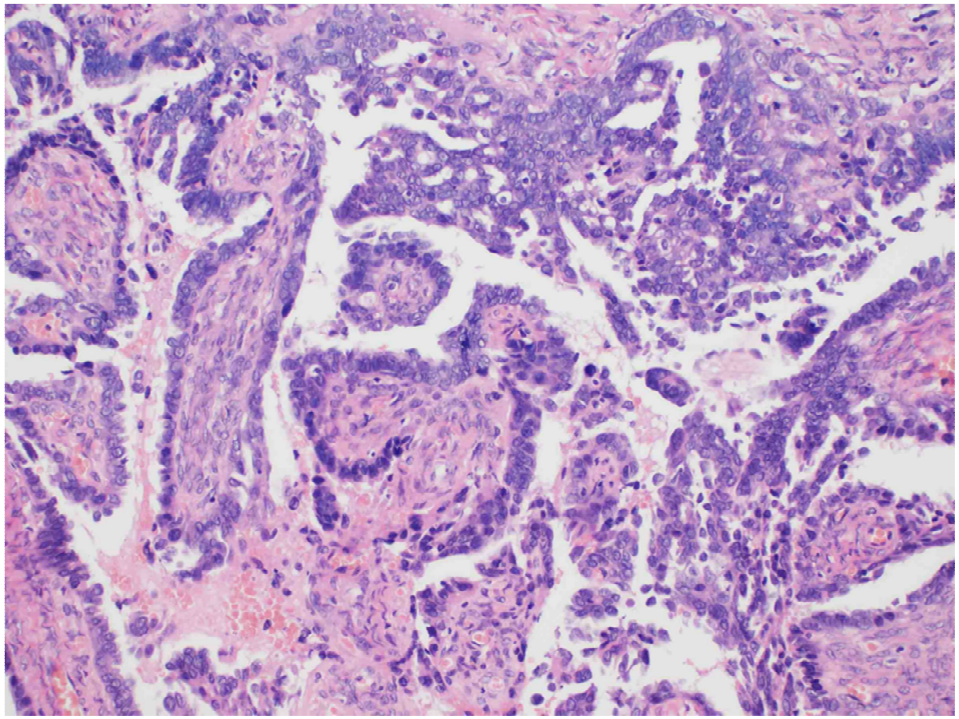

- 42-year-old female
- bilateral salpingo-oophorectomy
- dg.: serous borderline tumor
- no other treatment (2013)
- two years later (2015) presented with a widespread disease (FIGO IIIC / pT3c)
- Request for a second opinion - HGSC
- 3/2019: AWD (second relapse, Lynaparza (olaparib) maintenance treatment)

"Noninvasive" HGSC

- WHO 2014:
- "A very small proportion of HGSCs are intracystic and lack apparent invasion and in the past have erroneously been classified as borderline tumours."

- Marked nuclear atypias
- High mitotic activity
- Aberrant p53 expression

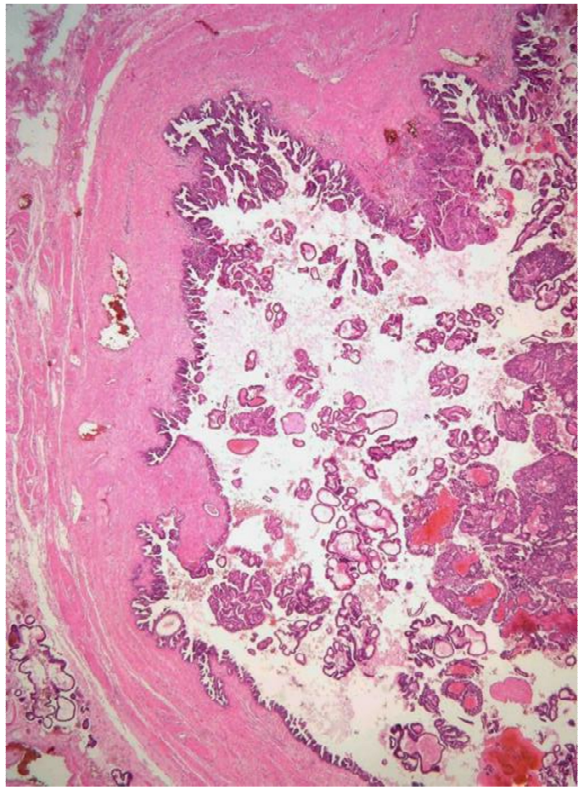

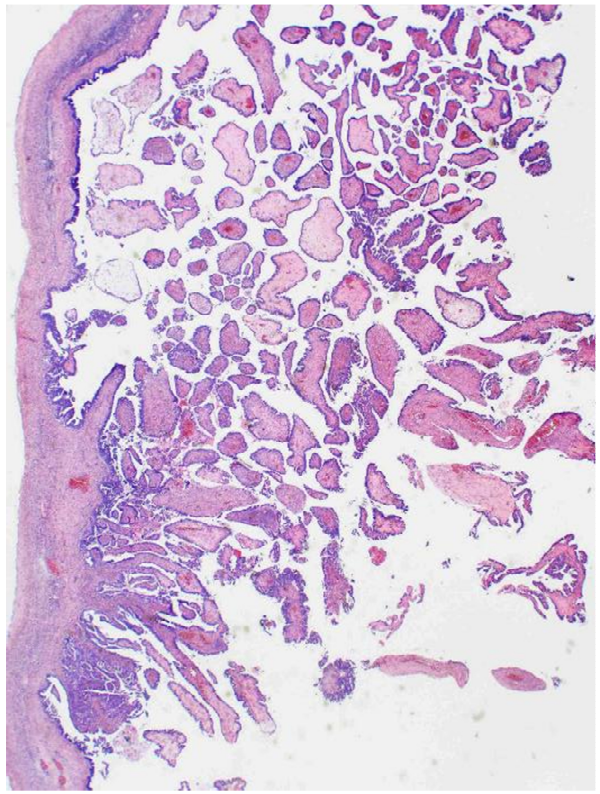

Serous cystadenoma with focal epithelial proliferation

- Foci of increased epithelial proliferation with features of S-BTO
- < 10% of the epithelial (not ovarian!) volume

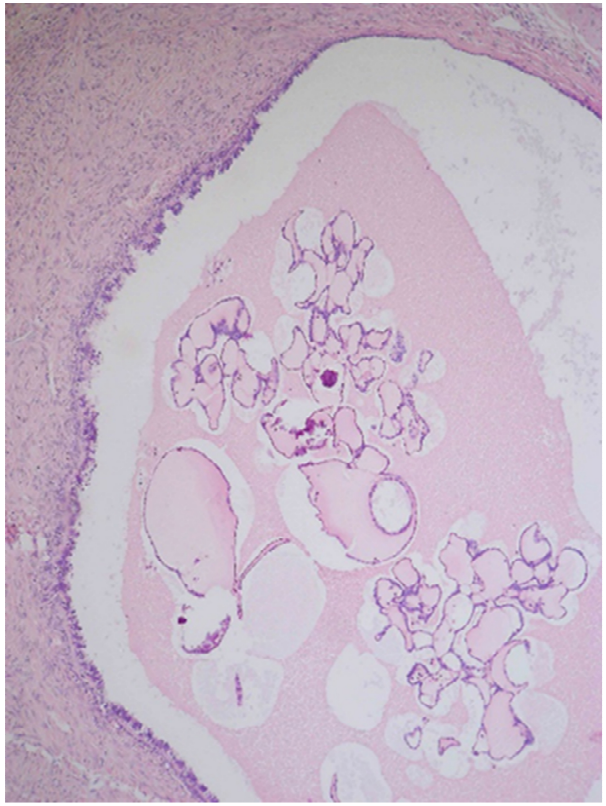

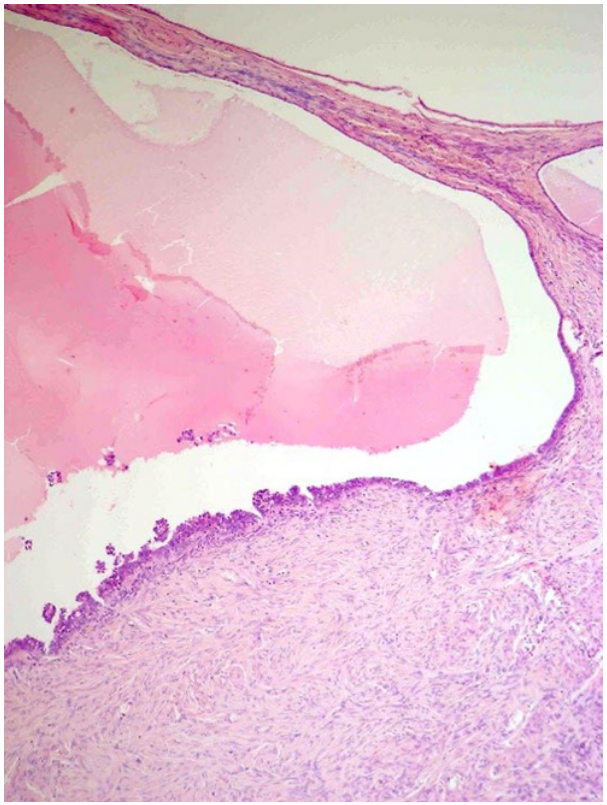

Mucinous carcinoma - Invasion patterns

- **Expansive invasion**
- architecturally complex glandular arrangements incompatible with a noninvasive process
- 1) glands with extensive branching and budding, with an exclusion of the stroma
- 2) cribriform pattern
- 3) complex papillary structures

- **Destructive (infiltrative) invasion**
- 1) unequivocal disruption of the basement membrane with edematous and/or inflammed stromal response
- 2) groups of single neoplastic cells in the stroma, usually with a stromal response

Chen S, et al. Mod Pathol 2005;18:903-911

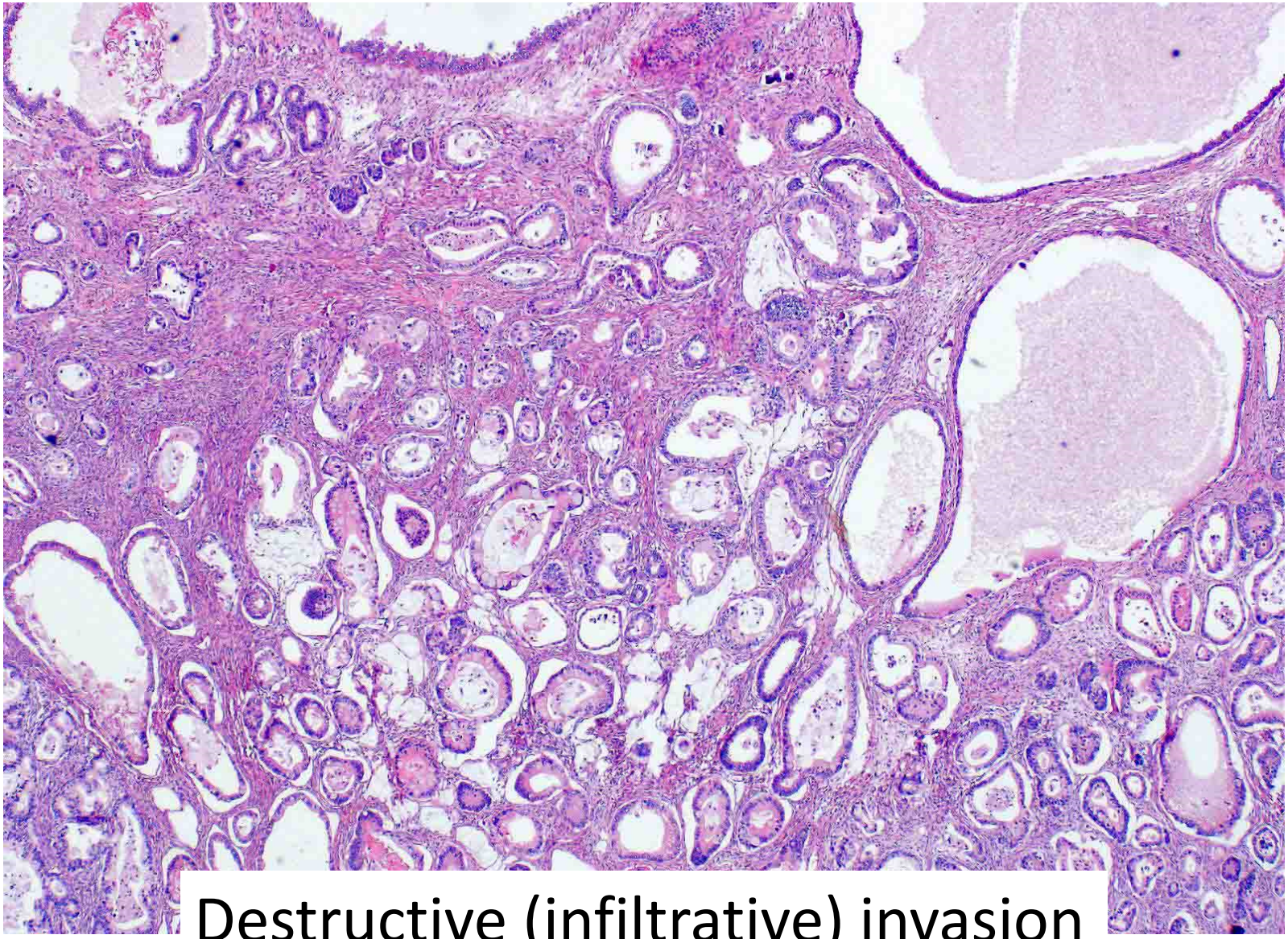

Destructive (infiltrative) invasion

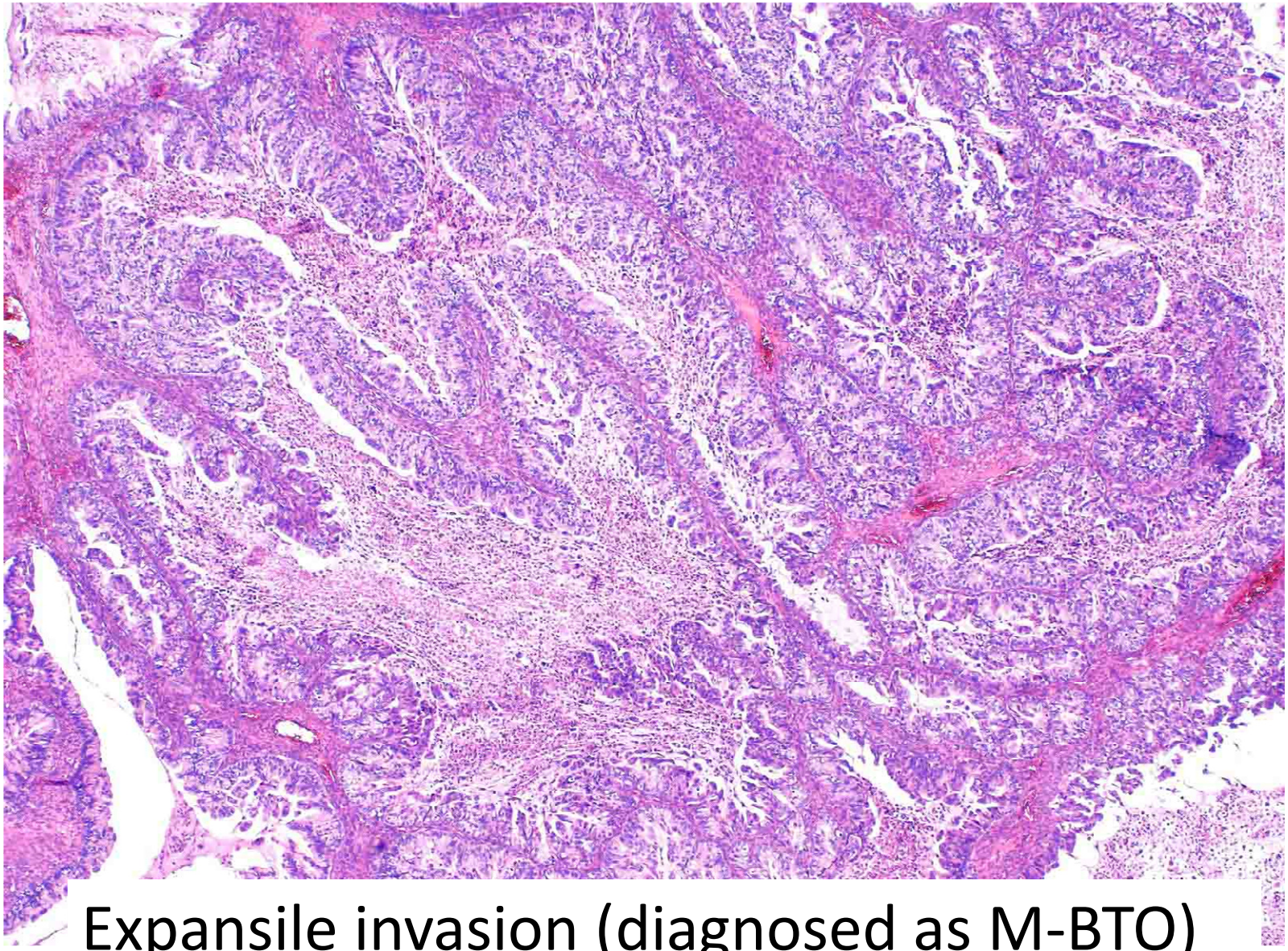

Expansile invasion (diagnosed as M-BTO)

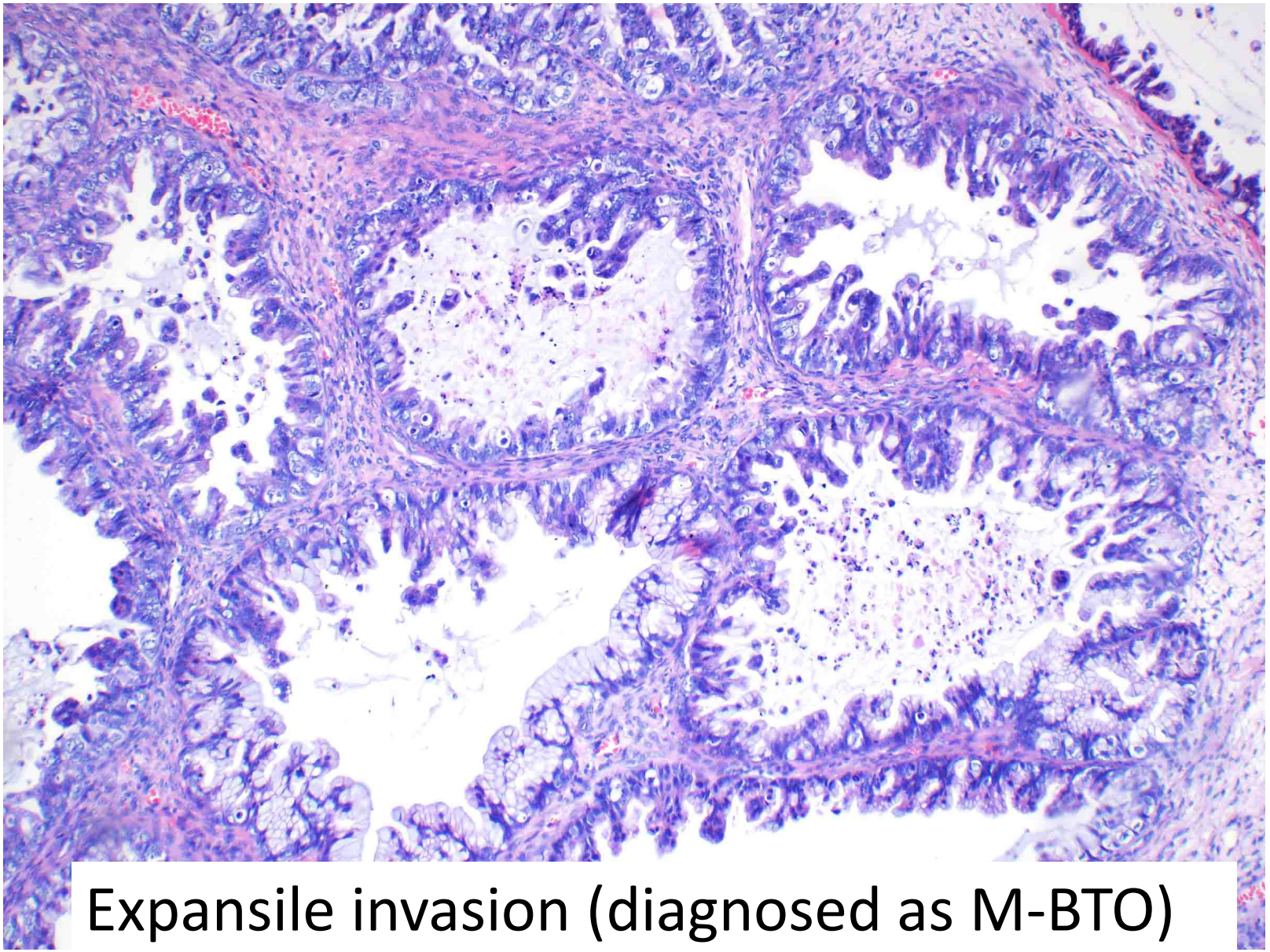

Expansile invasion (diagnosed as M-BTO)

MBT – differential diagnosis

	Primary tumor		Metastasis	
Laterality	Unilateral >95%		Bilateral in 55-60 %	
Size	Usually ≥ 10 cm		Usually < 10 cm	
Gross features	Multicystic, smooth external surface, may have areas of solid growth		Commonly multinodular, but may look like a primary tumor	
Microscopy	- Located in the stroma - Well-differentiated mucinous epithelium with signs of increased proliferation - Variable nuclear atypia - Tubular, villous, glandular, papillary		- Surface, superficial cortex and stroma - Typically infiltrative growth - Often nodules in the superficial cortex - May mimic both borderline and benign tumors - Often significant nuclear atypia	
IHC		Primary (%)	Lower GIT (%)	Upper GIT (%)
	CK7	88	24	88
	CK20	66	84	42
	CDX2	38	100	50
	PAX 8	50-70	0	0
Extraovarian spread	Usually absent		Common	

Primary vs. metastatic mucinous tumor

- Seidman (2003) - specifity 90 % (Hu - 75 %)
- **Metastasis**: bilateral tumor (any size) or unilateral tumor < 10 cm
- **Primary tumor**: unilateral, ≥ 10 cm

- Hu (2015)
- Include IHC - PAX 8
- Specifity 86 %

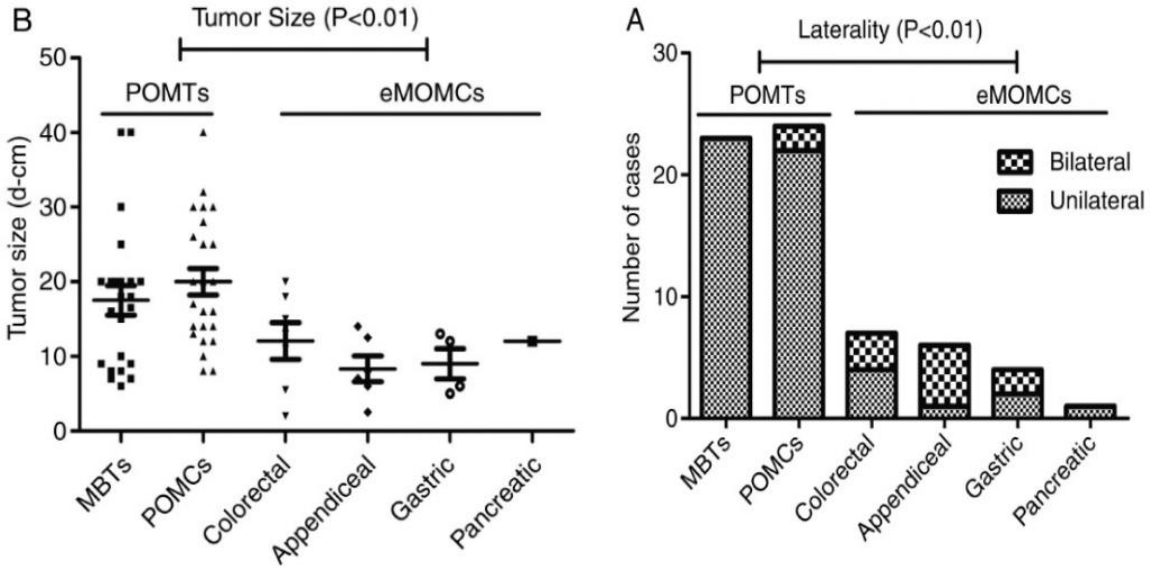

Seidman JD, et al. Am J Surg Pathol 2003;27:985–93.
Hu A, et al. J Clin Pathol. 2015 Jul;68(7):522-8.

Determination of the tumor cell type

Classification of carcinomas of the ovary

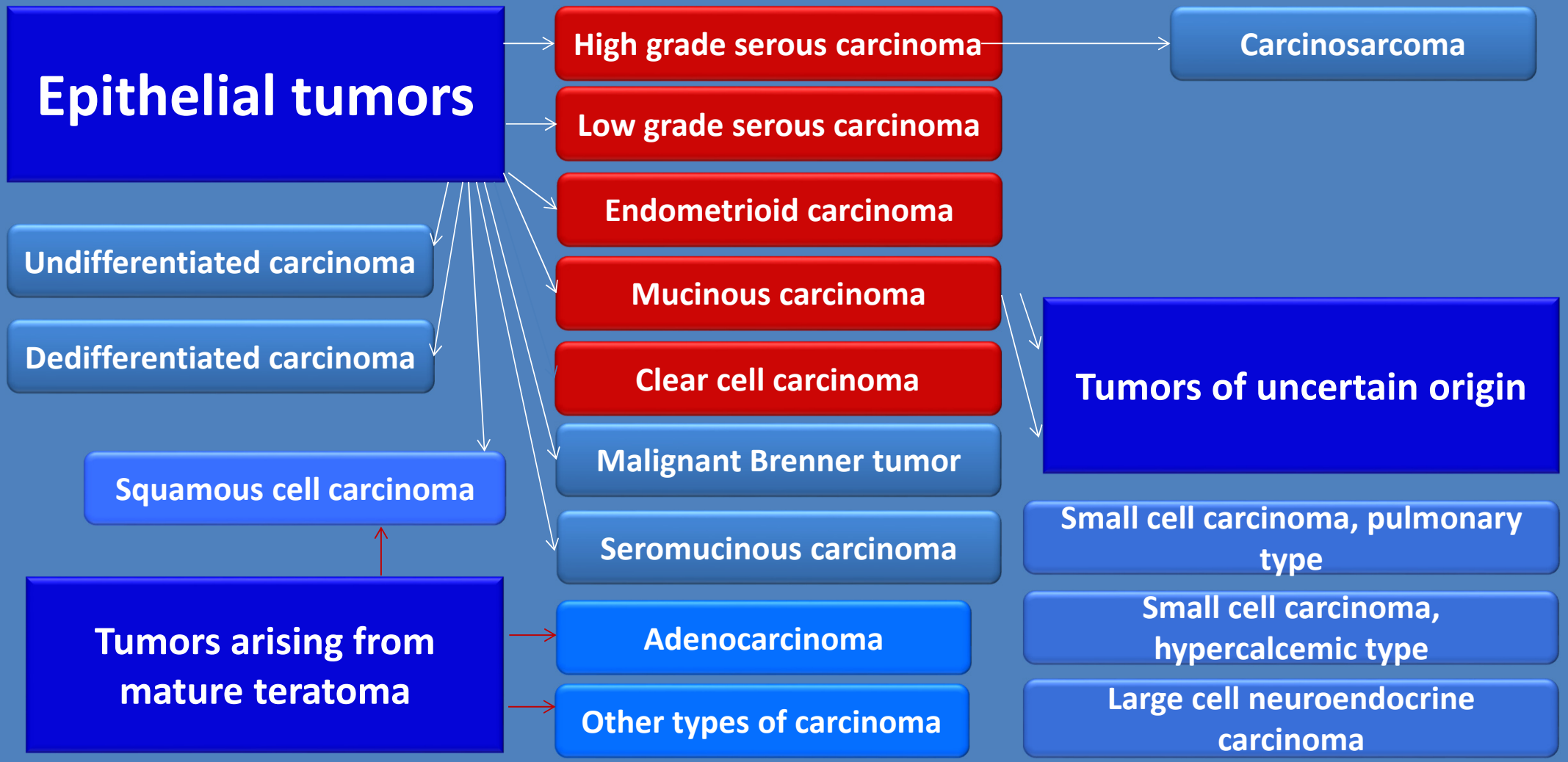

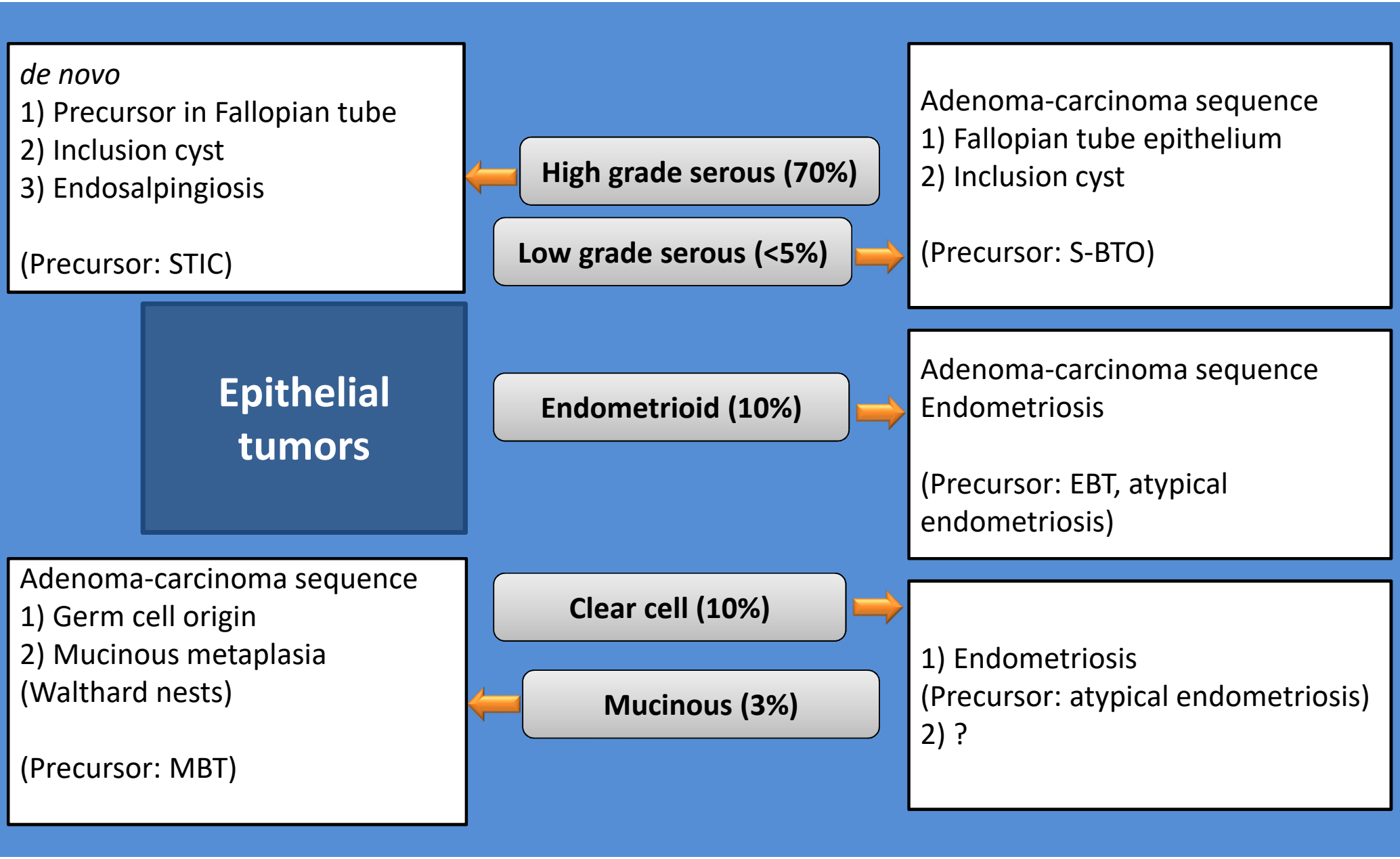
Epithelial tumors
de novo
1) Precursor in Fallopian tube
2) Inclusion cyst
3) Endosalpingiosis
(Precursor: STIC)
High grade serous (70%)
Low grade serous (<5%)
Adenoma-carcinoma sequence
1) Fallopian tube epithelium
2) Inclusion cyst
(Precursor: S-BTO)
Endometrioid (10%)
Adenoma-carcinoma sequence
Endometriosis
(Precursor: EBT, atypical endometriosis)
Clear cell (10%)
1) Endometriosis
(Precursor: atypical endometriosis)
2) ?
Mucinous (3%)
Adenoma-carcinoma sequence
1) Germ cell origin
2) Mucinous metaplasia
(Walthard nests)
(Precursor: MBT)

Determination of the tumor cell type

- Different treatment
  - surgery (chemoresistant tumors)
  - neoadjuvant chemotherapy/surgery (chemosensitive tumors)
  - new therapies (PARP inhibitors)
- Entering clinical trials
- Epidemiological studies

- Most problematic for high-grade carcinomas
- Historically esp. high-grade tumors with glandular features

→ new WHO classification

→ solid / endometrioid / transitional pattern (SET)

→ immunohistochemistry

→ molecular features

Determination of the tumor cell type

- Studies from 1984-1994 (WHO 1974 criteria)
- Concordance 56-68%
- (κ 0.46-0.55)

- Subsequent WHO classification
  LGSC / HGSC
  HGSC with SET features
  IHC
- Concordance 78-94%

TABLE 5. Validation Set: κ Statistics, and Concordance Rates for Diagnostic Agreement (N = 88)

Comparison	κ	Concordance
Original diagnosis versus local review	0.73 SE 0.06	84% (74/88)
Original diagnosis versus central review	0.69 SE 0.07	83% (73/88)
Local review versus central review	0.89 SE 0.04	94% (83/88)

99 EC cases
33 (30%) re-classified to HGSC
The importance of CEF* (80% EC had at least 1 CEF)

1626 cases (Canadian Registry)
105 re-classified (93.5% match)
Importance of IHC (4/6/8 markers - 88/91/93%)

54 cases /8 pathologists
Concordance with the central dg. in 86% (90% with IHC)
Interpersonal variability – concordance in 78% (85% with IHC)

*CEF – Confirmatory endometrioid features

Köbel M, et al. Am J Surg Pathol 2010;34:984-993)
Köbel M, et al. Int J Gynecol Pathol 2016;35:430-441
Köbel M, et al. Histopathology 2014;64:1004-1013
Lim D, et al. Am J Surg Pathol 2016;40:302-312

Determination of the tumor cell type

- Studies from 1984-1994 (WHO 1974 criteria)
- Concordance 56-68%
- (κ 0.46-0.55)

- Subsequent WHO classification
  LGSC / HGSC
  HGSC with SET features

TABLE 5. Validation Set: κ Statistics, and Concordance Rates for Diagnostic Agreement (N = 88)

Comparison	κ	Concordance
Original diagnosis versus local review	0.73 SE 0.06	84% (74/88)
Original diagnosis versus central review	0.69 SE 0.07	83% (73/88)
Local review versus central review	0.89 SE 0.04	94% (83/88)

99 EC cases
33 (30%) re-classified to HGSC
The importance of CEF* (80% EC had at least 1 CEF)

1626 cases (Canadian Registry)
105 re-classified (93.5% match)
Importance of IHC (4/6/8 markers - 88/91/93%)

Most common change in diagnosis:
Endometrioid carcinoma → HGSC

Köbel
Köbel
Köbel
Lim D, et al. Am J Surg Pathol 2016;40:302-312

*CEF – Confirmatory endometrioid features

Immunohistochemistry

	HGSC	EC	CCC	MC	LGSC
WT1, positive	97	10	1	0,6	98
TP53, aberrant	94	15	12	61	0
P16, diffuse („block“)	65	8	17	10	3
Napsin A	1,5	8	92	3,5	0
TFF3, diffuse	1,5	37	0	84	4,5
ER, positive	80	77	19	21	87
PR, positive	30	67	8	16	57
ARID1A, absence	1,3	23	41	3	6
Vimentin, diffuse	16	53	20	3	55

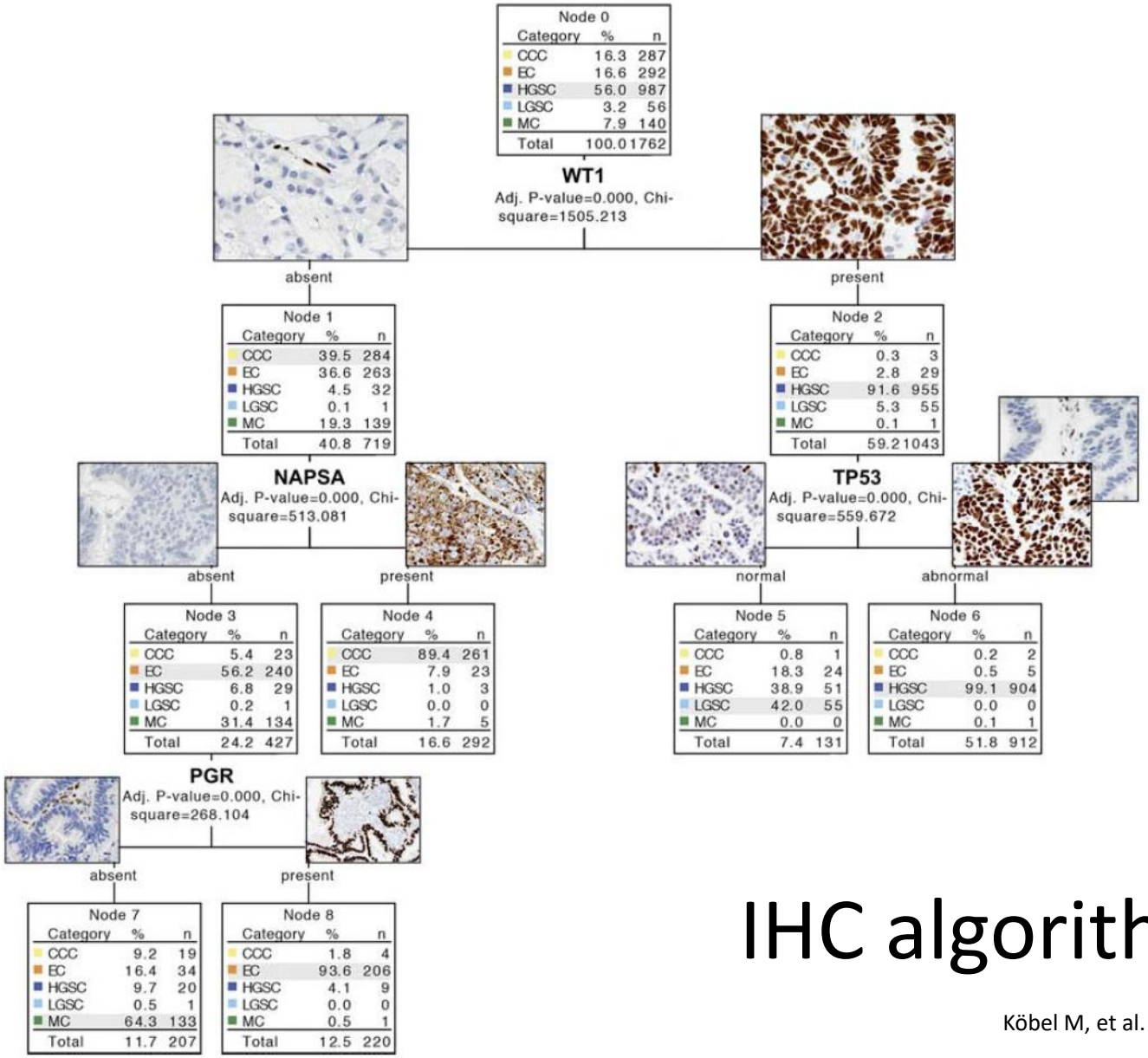

IHC algorithm

Köbel M, et al. Int J Gynecol Pathol 2016; 35:430-441

Determination of the tumor cell type

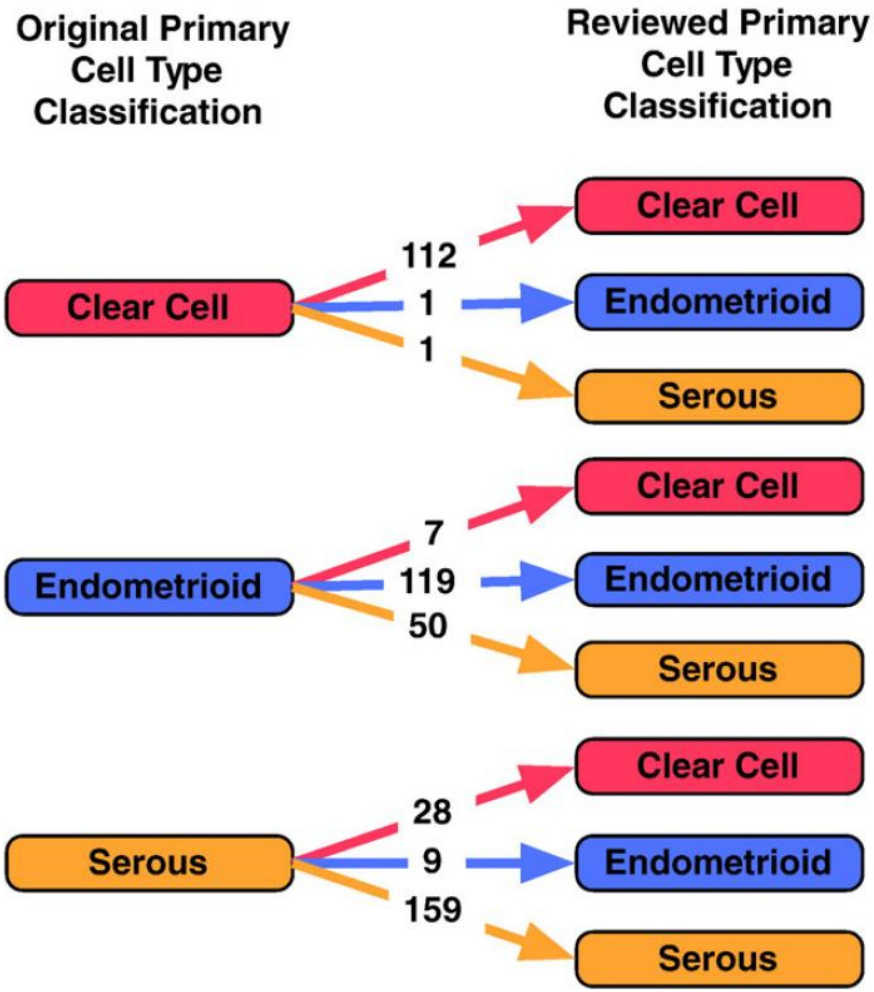

Gilks CB, et al. Hum Pathol. 2008;39(8):1239-51.

Endometrioid carcinoma vs. HGSC

- **Endometrioid carcinoma**
  - Confirmatory endometrioid features:
  - i) squamous metaplasia
  - ii) endometriosis
  - iii) adenofibromatous background
  - iv) borderline endometrioid or mixed Mullerian component

- IHC:
  - 10% WT1+
  - 15% aberrant p53
  - 8% „block“ p16
  - < 2% WT1+/aberrant p53

- **HGSC**
  - Morphologic features:
    - reclassified EC to HGSC tumors commonly SET features
    - can be endometriosis (!) – co-incidental finding
- IHC:
  - 95% WT1+
  - 95% aberrant p53
  - 65% „block“ p16
  - 92% WT1+/aberrant p53

Lim D, et al. Am J Surg Pathol 2016;40:302-312
Köbel M, et al. Int J Gynecol Pathol 2016; 35:430-441

Endometrioid carcinoma vs. HGSC

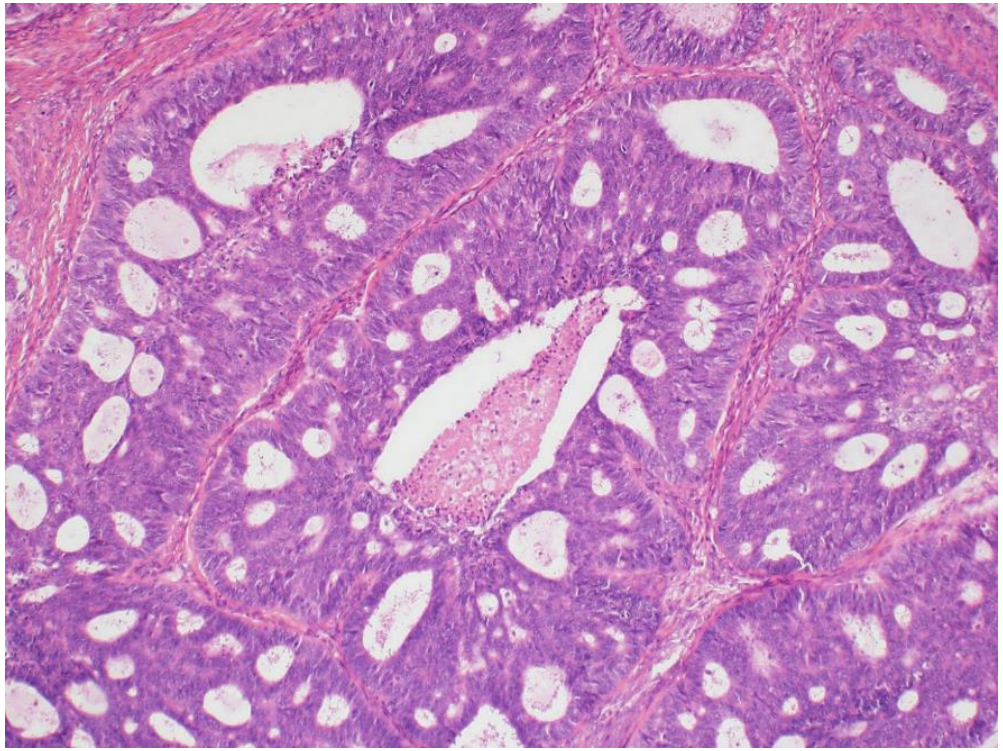

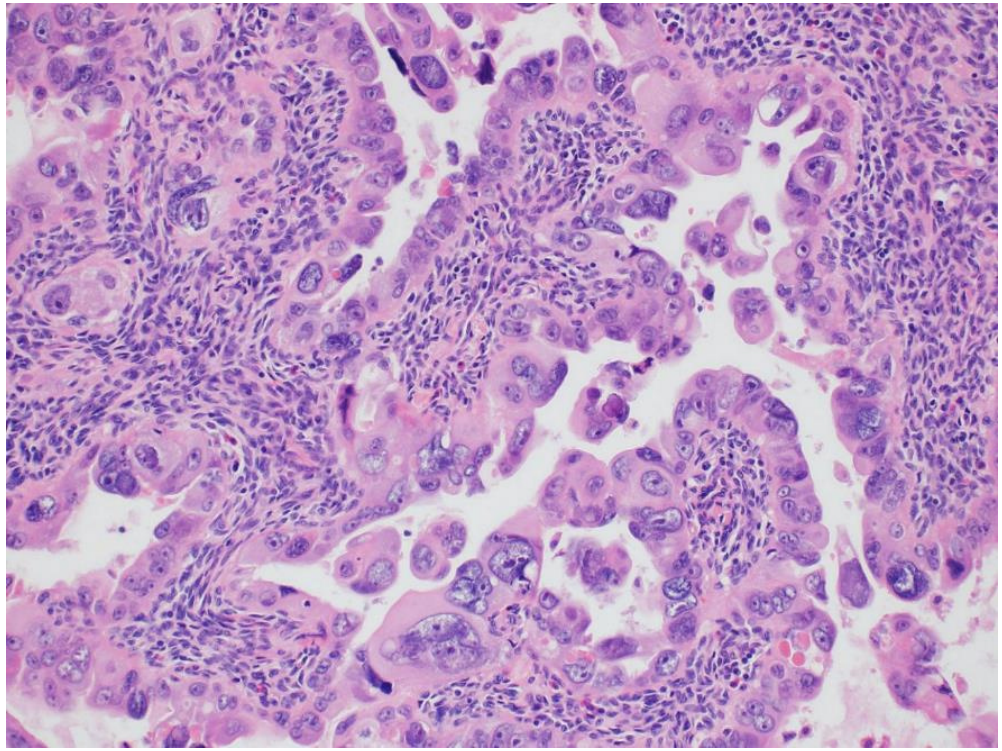

HGSC with SET pattern

- **S**olid, pseudo**E**ndometroid, **T**ransitional
- associated with BRCA mutation

- Other features:
  - increased TILs
  - higher mitotic activity
  - different metastatic pattern („pushing“ rather than „infiltrative“)
  - geographical necroses

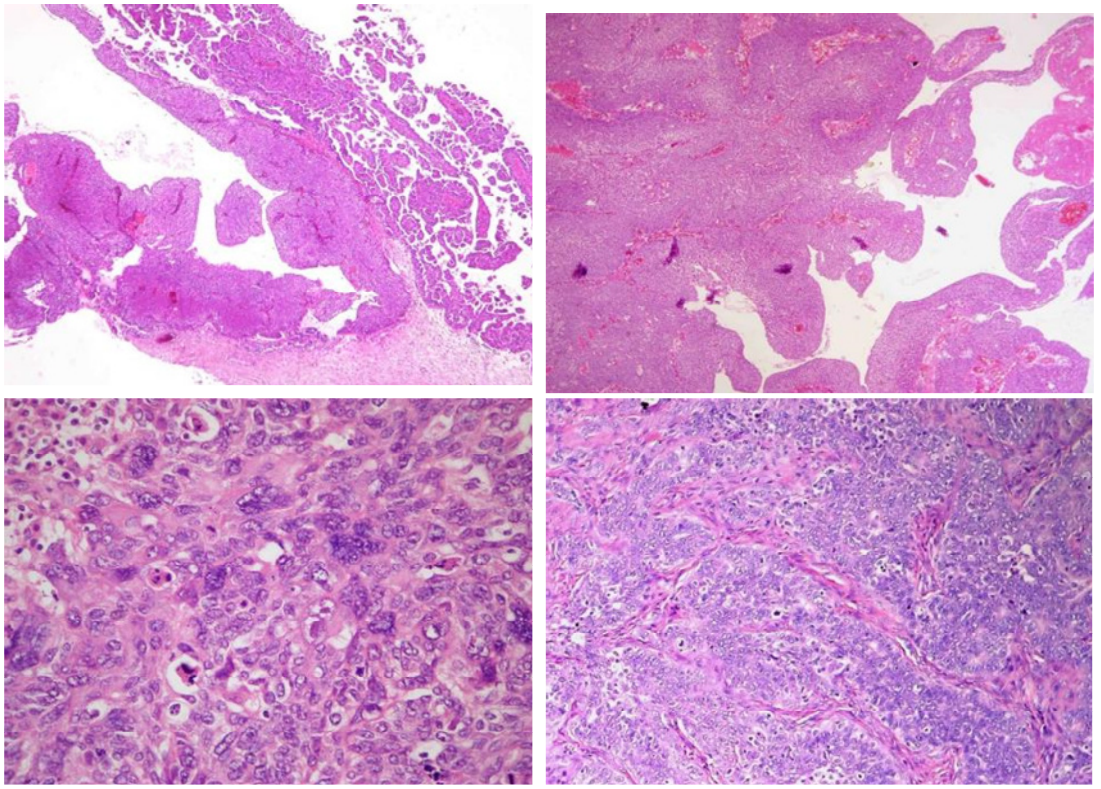

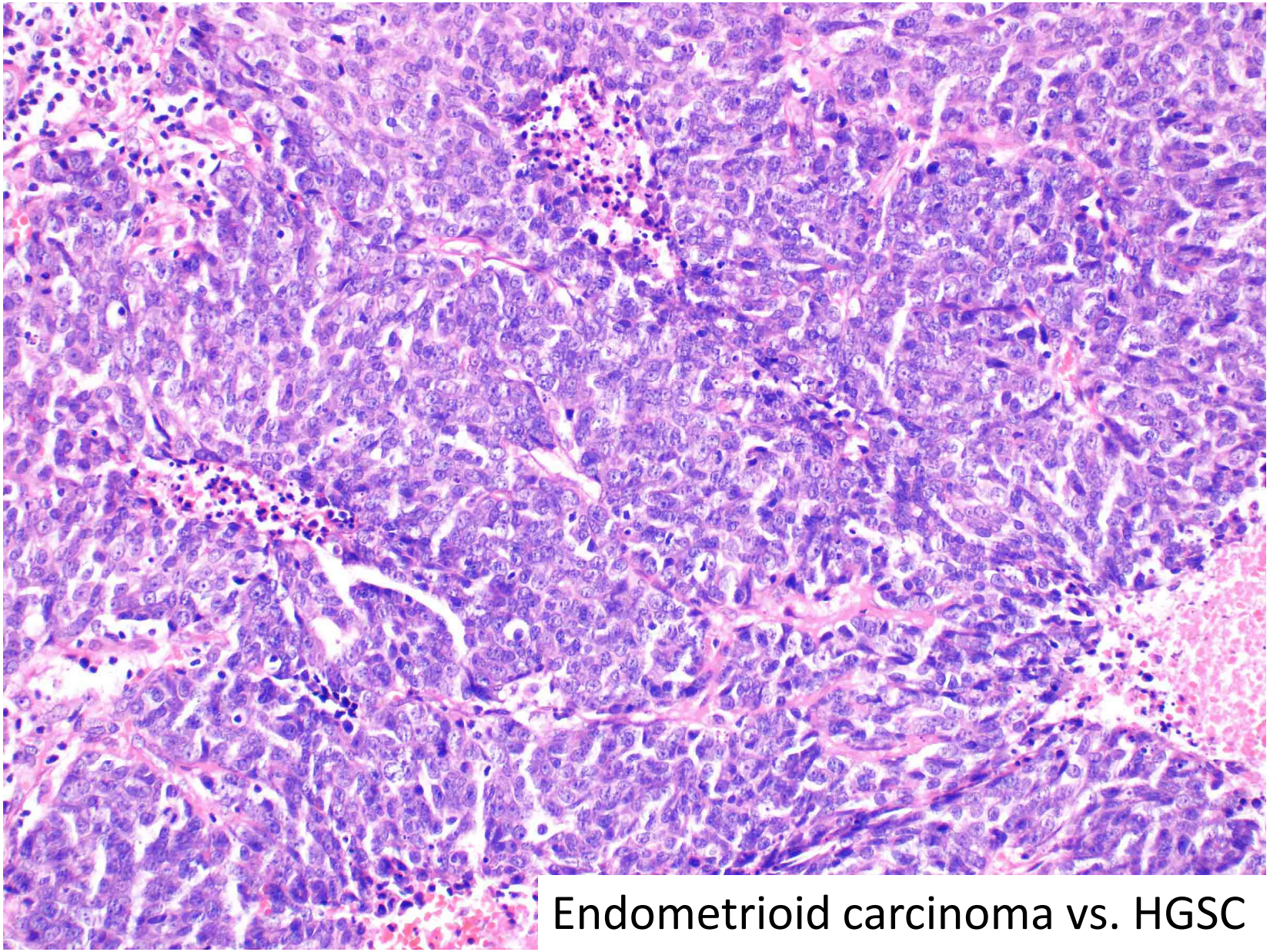

Endometrioid carcinoma vs. HGSC

LGSC vs. HGSC

	LGSC	HGSC
Nuclear features	Uniform nuclei Most G1 nuclei (<3: 1 nuclear size variability, fine chromatin, small nucleoli) There may be G2 nuclei (but not exclusively!)	Irregular nuclei G2 and G3 Significant variability in the size and shape of the nuclei, irregular chromatin, numerous prominent nucleoli
Mitoses	< 12 / 10 HPF (usually up to 3 mitoses / 10 HPF)	≥ 12 / 10 HPF
Multinucleated cells	No	Common
Necrosis	No	Common
IHC: P53 aberrant expression	rare	94 %
P16 diffuse („block“) expression	3 %	94 %
Ki-67 index	Low	High

LGSC vs. HGSC

TP53 mutation according to TCGA study in 96% HGSC (316 cases) / 14 cases (4%) wt

Re-analysis of the wt cases (panel of 5 experts):
1/14 agreement with the HGSC dg. (homozygous TP53 deletion, BRCA mutation)
1/14 agreement with the HGSC dg. (tumor arising in LGSC, no TP53 mutation)

100% HGSC mutation TP53 except HGSC originated in LGSC

TABLE 1. *Rereview diagnoses and molecular data for TP53 wild-type high-grade serous carcinomas from the TCGA study*

		Rereview pathologist					Molecular data from the TCGA(6)			
Case	TCGA*	*A*	*B*	*C*	*D*	*E*	*TP53* HD†	*BRCA*‡	No. Muts§	CNA (%)‖
1	09-2056	LGSC	HG Endo	LGSC	HGSC	HGSC	–	–	68	46
2	10-0933	Met	HG Endo	HG Endo	Met	Met	–	–	33	47
3	13-0727	HGSC¶	HGSC¶	HGSC¶	HGSC	HGSC	–	–	21	22
4	13-0755	CCC	LG/HGSC#	CCC	HGSC	HGSC	–	–	73	18
5	13-1408	HGSC	HGSC	HGSC	HGSC	HGSC	+	+	78	31
6	13-1477	LGSC	LGSC	LGSC	LGSC	LGSC	–	–	42	9
7	24-1544	Met	Met	Met	HGSC	HGSC	–	–	17	31
8	24-1565	HG Endo	HG Endo	HG Endo	HG Endo	HG Endo	–	–	25	9
9	24-2038	APST	APST	APST	APST	APST	–	–	10	11
10	25-1316	LGSC	HG Endo	LGSC	HGSC	HGSC	–	–	13	30
11	25-1328	LGSC	LGSC	LGSC	LGSC	LGSC	–	–	10	NA
12	25-2042	CCC	Adeno, NOS	HGSC	HGSC	HGSC	–	–	56	19
13	25-2408	LGSC	LGSC	LGSC	LGSC	LGSC	–	–	13	9
14	61-2095	LGSC	LGSC	LGSC	LGSC	LGSC	–	–	109	1

Vang R, et al. Int J Gyn Pathol 2015; 35:48-55

P53 – immunohistochemistry

WT (wild type)

- heterogenous expression
- Variable extent and intensity

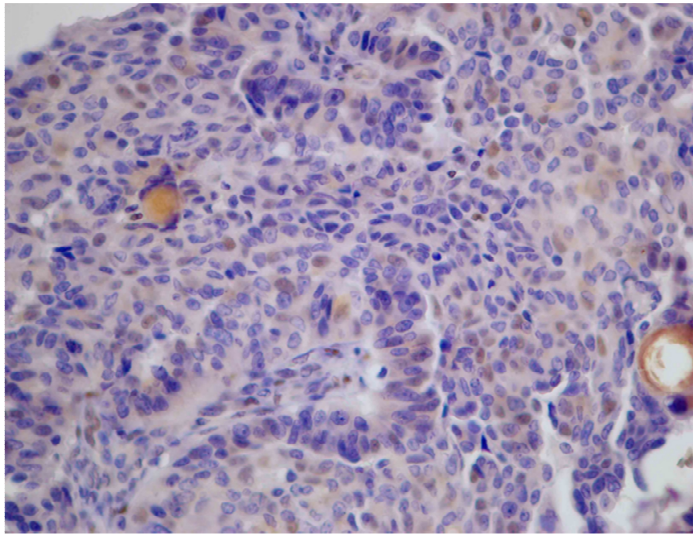

Aberrant/abnormal/mutation type

- **Nonsynonymous (missense) mutations**
- strong expression in > 75(80) %
- **Stopgain, indels**
- complete absence of staining
- cytoplasmic staining (rare)

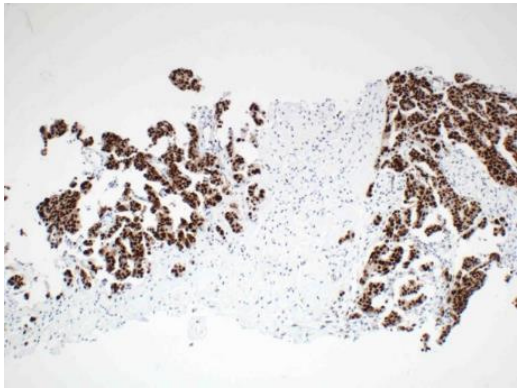

NordiQC

- Tonsil:
- > 20 % of germinal centre a weak to moderate nuclear staining
- < 10 % of the mantle zone B-cells
- lower 1/3 of squamous epithelium

- Colon:
- dispersed epithelial cells in the basal parts of the crypts a weak to moderate nuclear staining reaction
- luminal epithelial cells must be negative

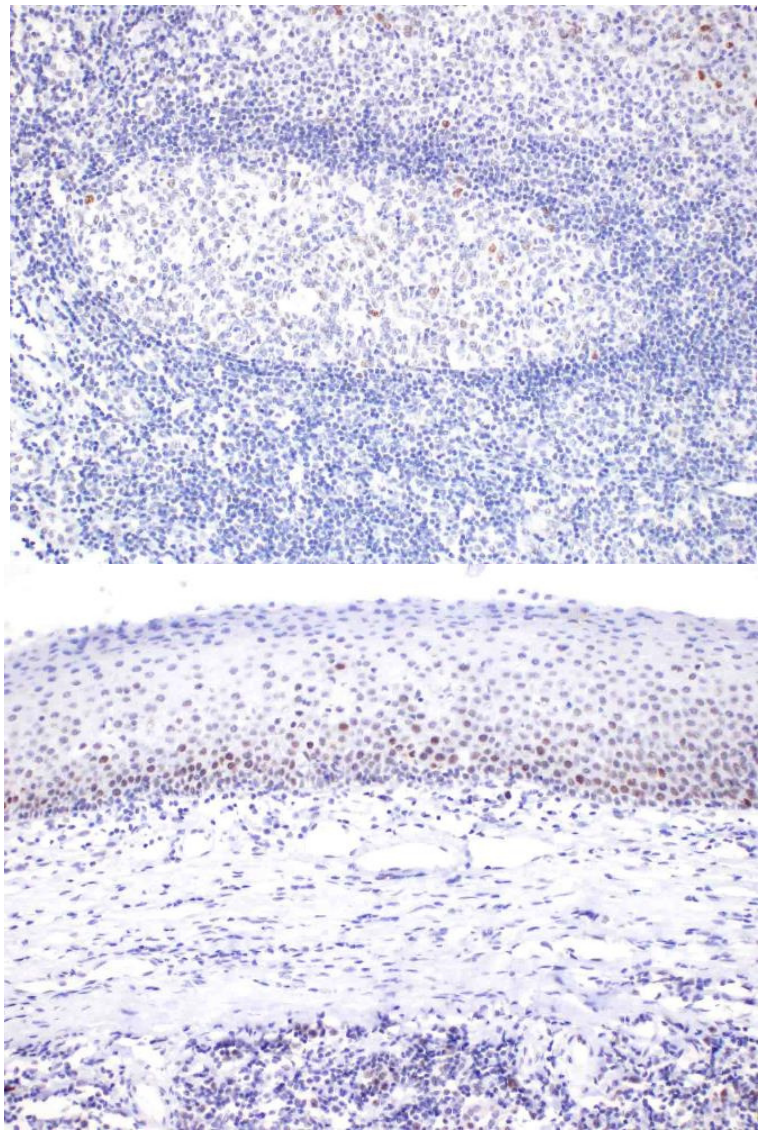

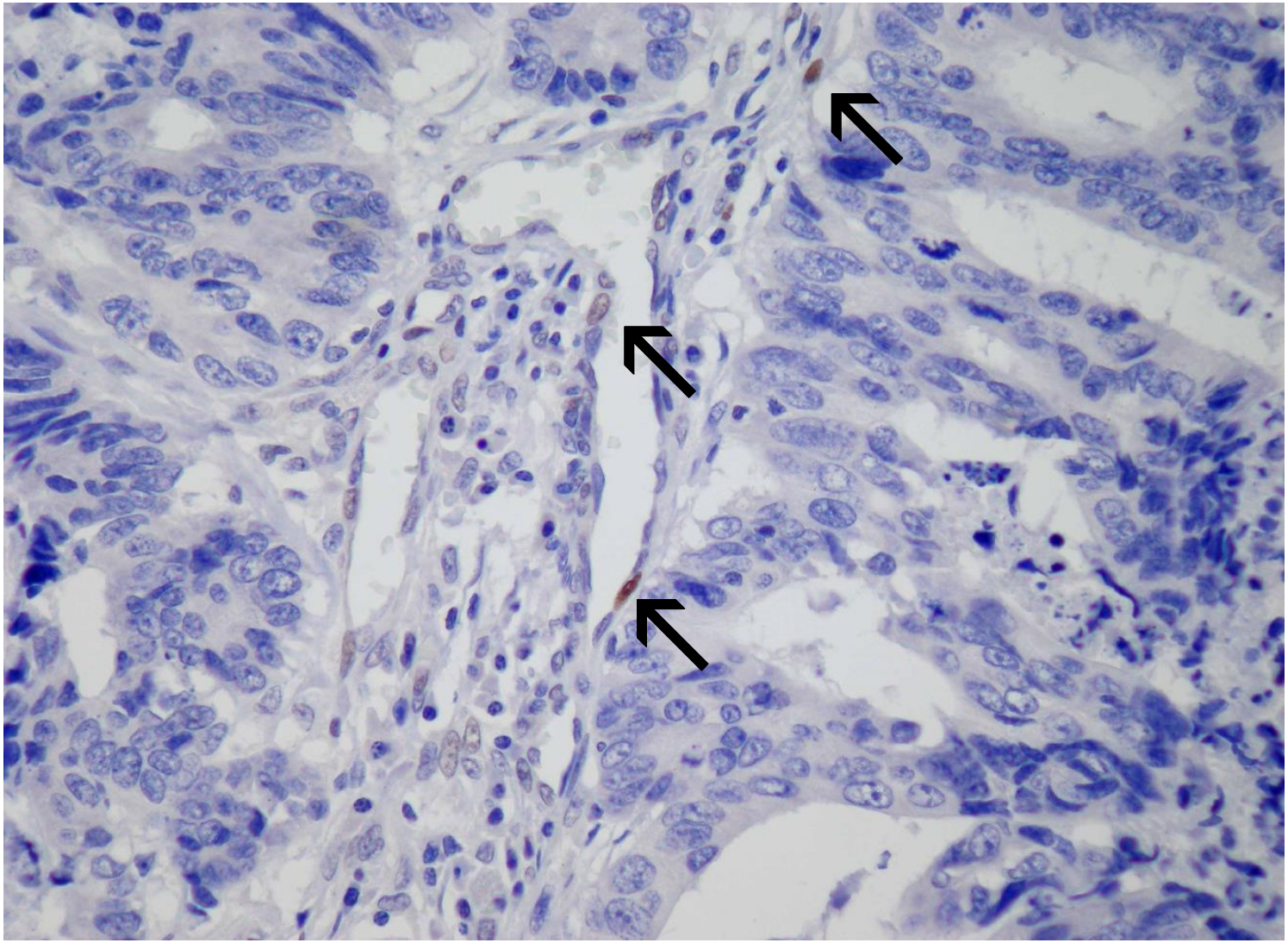

Abnormal p53 pattern – complete absence of staining

IHC p16

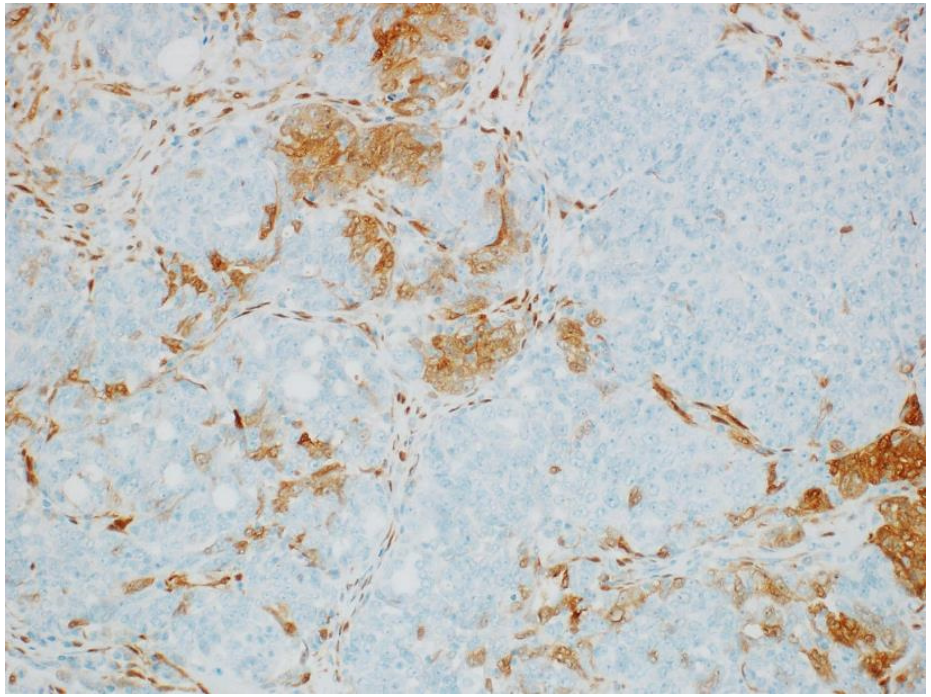

Focal heterogeneous "mosaic" positivity

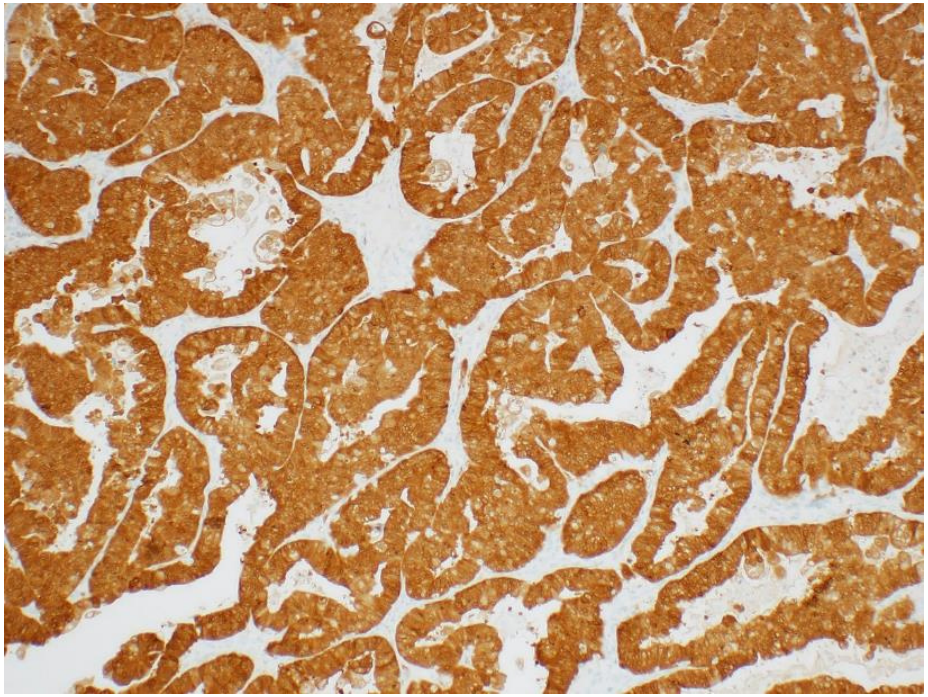

Diffuse "block" positivity

SBT - microinvasion vs. microinvasive carcinoma

- **Microinvasion (?)**
- non-destructive type of invasion
- < 5 mm in the greatest dimension
- eosinophilic cells
- low Ki-67 index
- no stromal reaction !

- **Microinvasive carcinoma**
- destructive type of invasion
- looks like small foci of LGSC
- stromal reaction
  - edema
  - myxoid changes
  - desmoplasia
- **Several patterns:**
  - micropapillary/complex papillary
  - compact cell nests
  - inverted macropapillae
  - cribriform
  - solid sheets with slit-like spaces
  - glandular and / or cystic

Ahn G, et al. Am J Surg Pathol 2016;40:1165-1176

SBT - microinvasion

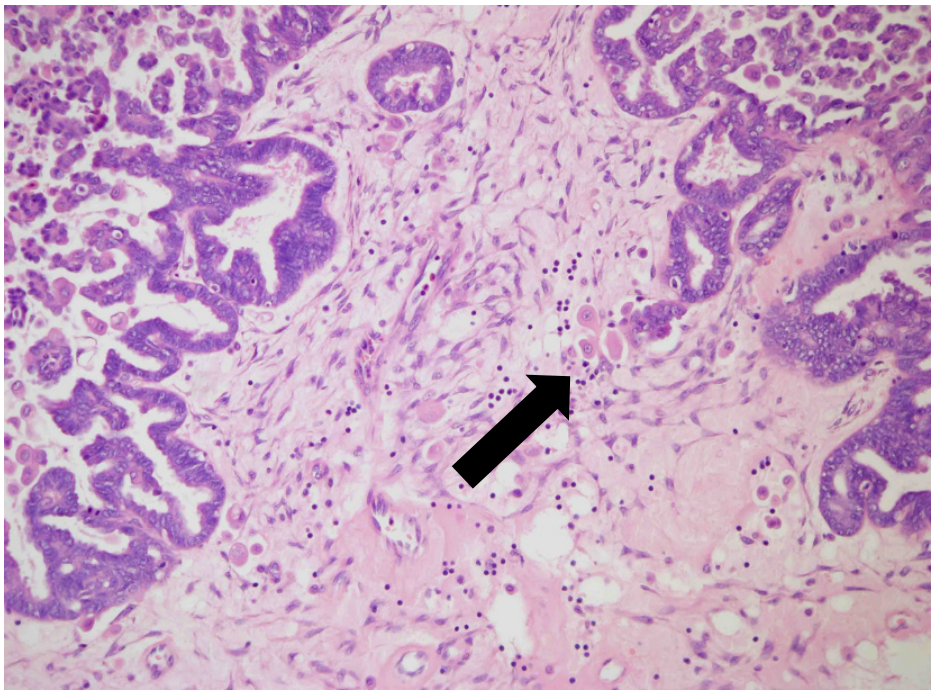

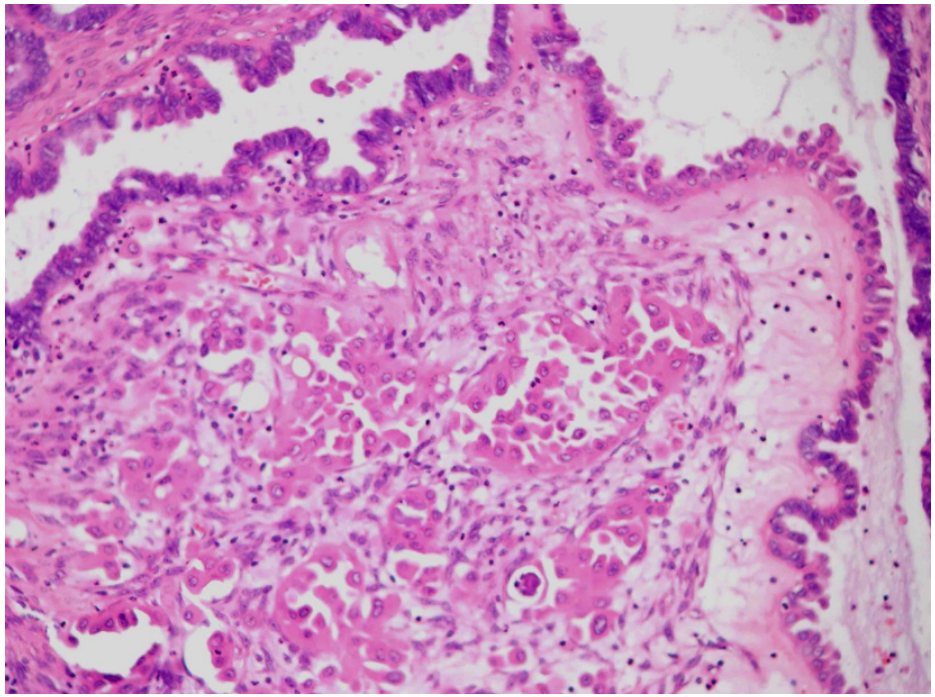

SBT with microinvasive carcinoma

- **WHO 2014:**

- " Insufficient data to comment on their clinical significance "
- suggests a cut-off of 5 mm

- **ICCR Dataset**

- "Standardized quantitative criterion for distinguishing microinvasion from frankly invasive carcinoma within a borderline tumour has not been established, and varying definitions have been used in different studies, including 1 mm, 2 mm, 3 mm, 5 mm, and 10 mm^2 as the upper limits of microinvasion"

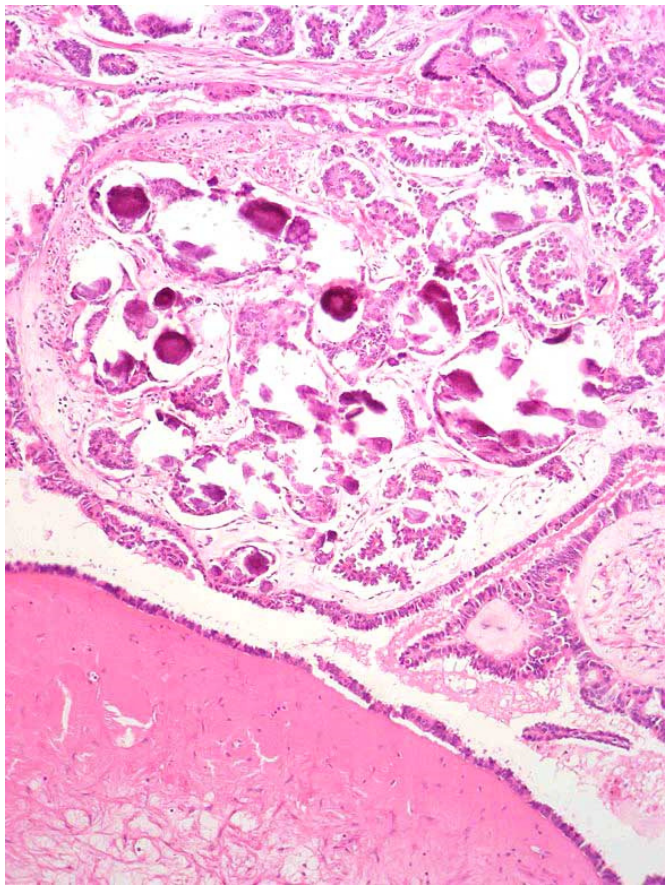

micropapillary type of invasion

SBT with microinvasive carcinoma

- Some classify as invasive LGSC (regardless of size of the invasive focus)

- Study Ahn G *et al.*:

  - 2 patients with invasion 2 and 3 mm DOD

- Limited extent of invasion
  - extensive sampling!



inverted macropapillary type of invasion

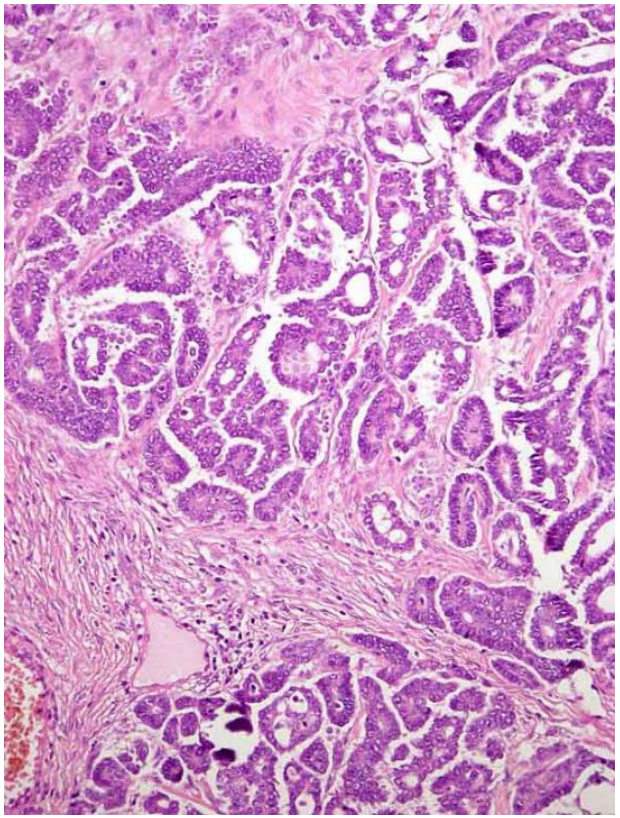

complex papillary type of invasion

Ahn G, et al. Am J Surg Pathol 2016;40:1165-1176

SBT with microinvasive carcinoma

- Some classify as invasive LGSC (regardless of size of the invasive focus)

- Study Ahn G *et al.*:
- 2 patients with invasion 2 and 3 mm DOD

- Limited extent of invasion - extensive sampling!



inverted macropapillary type of invasion

Ahn G, et al. Am J Surg Pathol 2016;40:1165-1176

SBT with microinvasive carcinoma / LGSC

- 56-year-old female
- Initial diagnosis – LGSC (Ukraine)
- The patient brought both the slides and the residual tumor tissue in a container with formalin



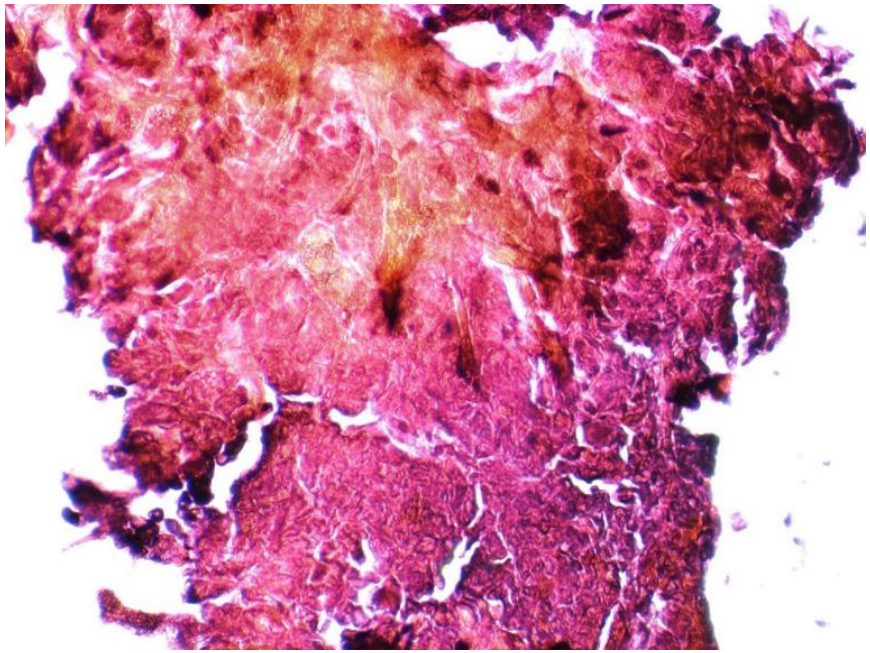

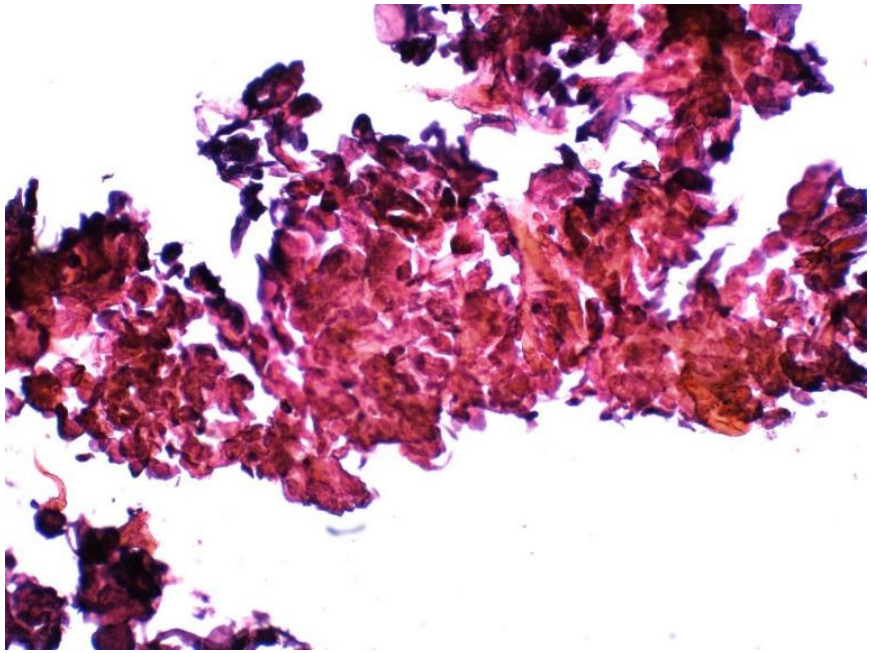

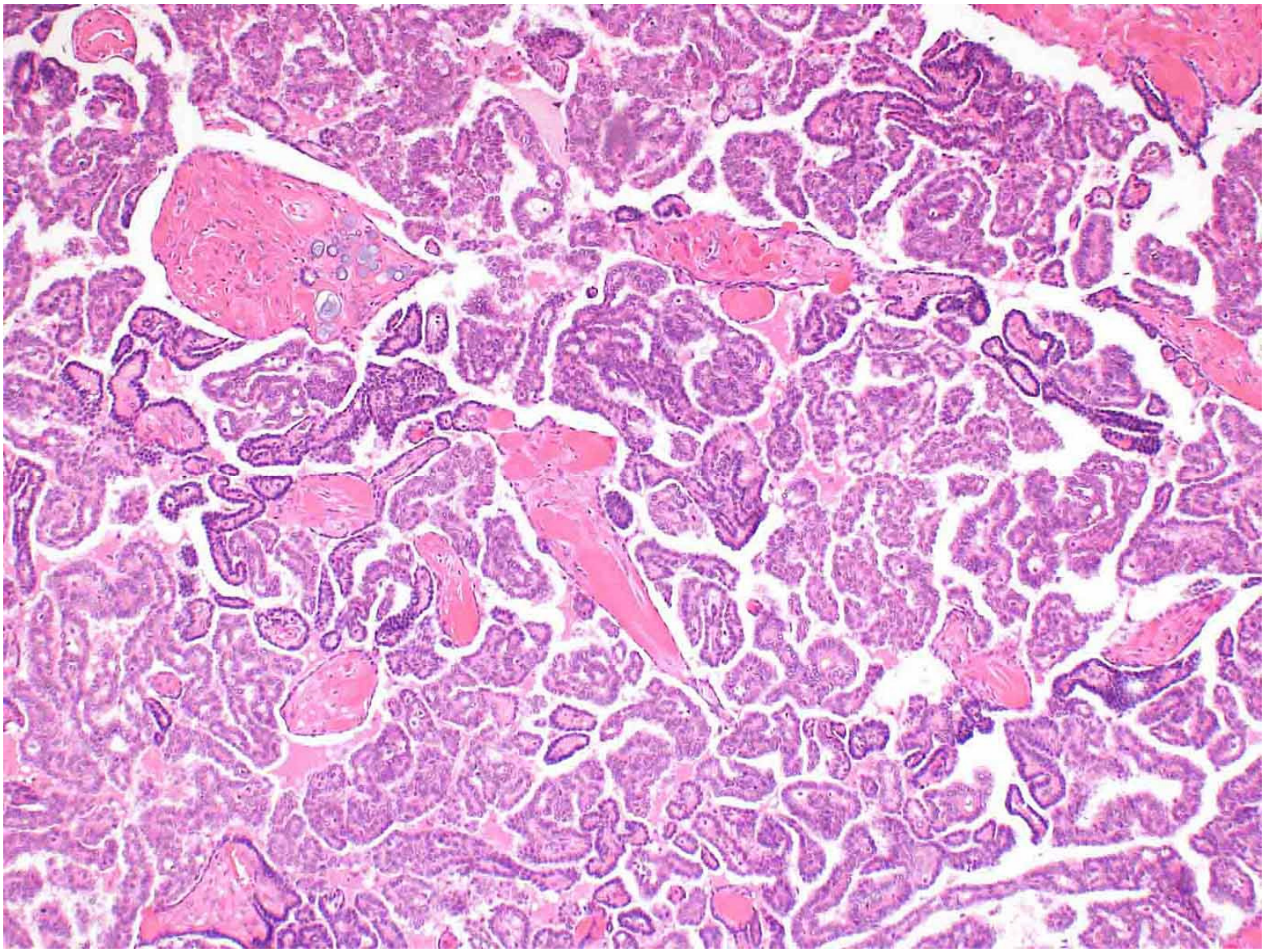

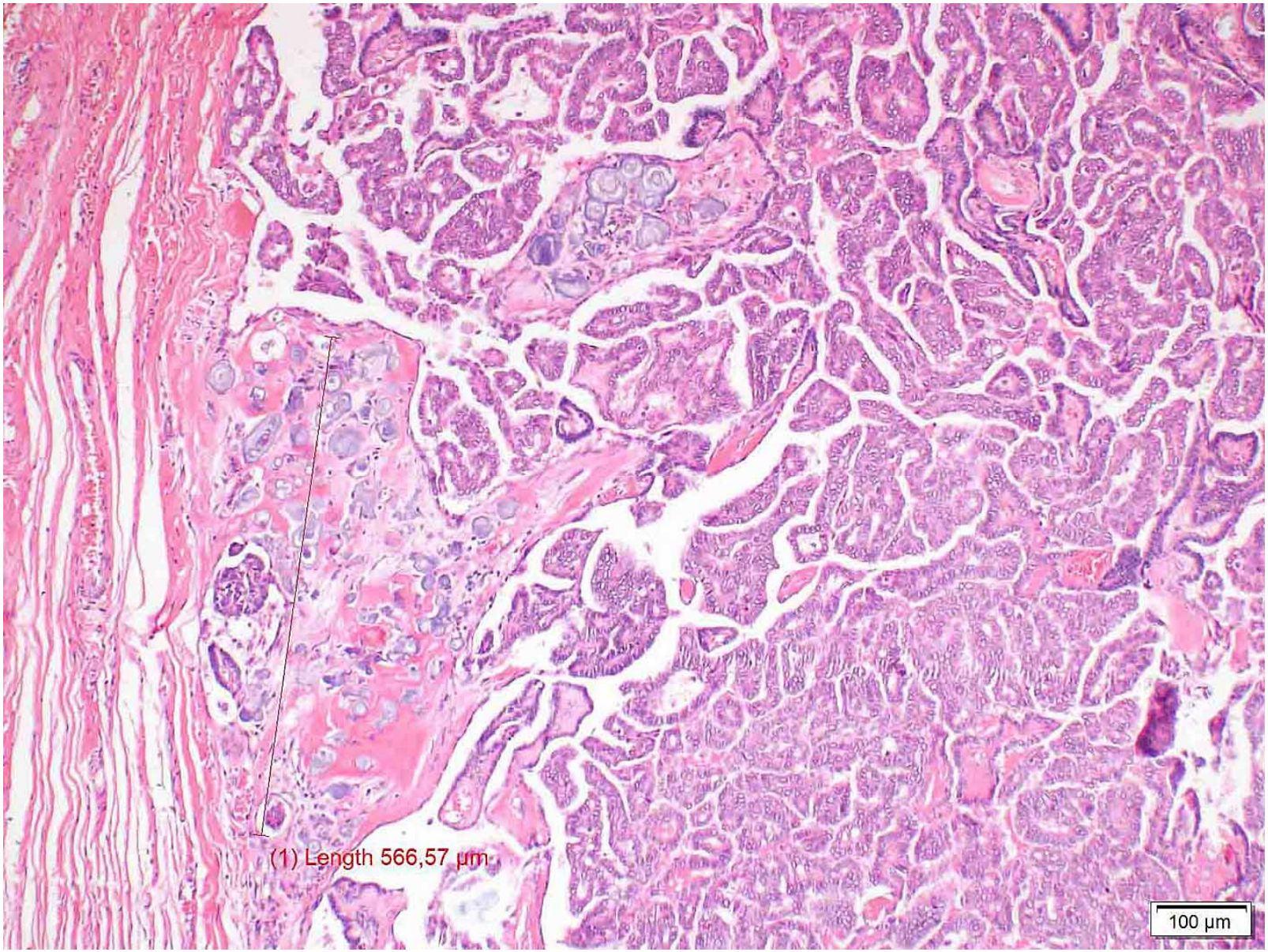
(1) Length 566,57 µm
100 µm

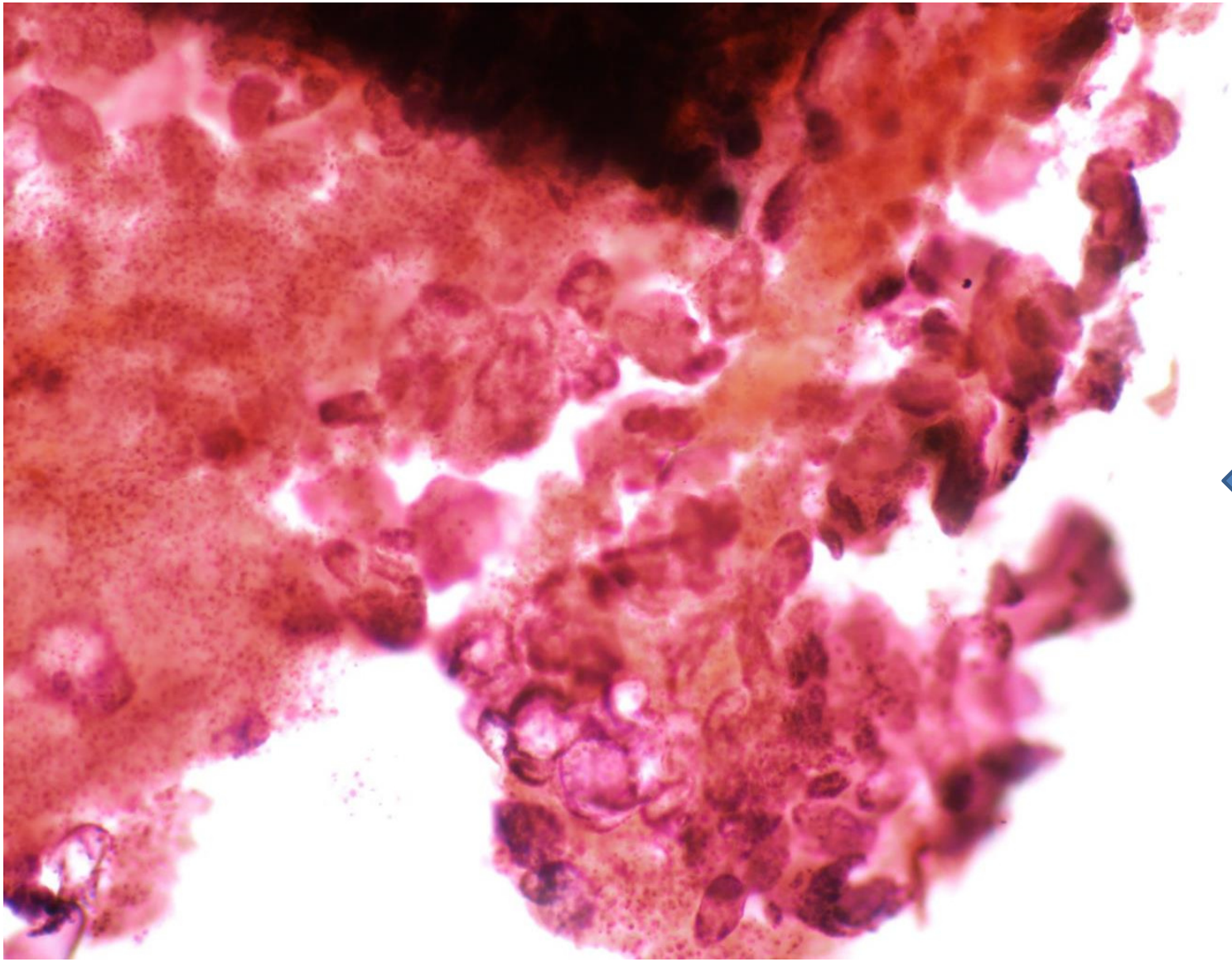

LGSC

Take home messages

- **The correct classification of ovarian tumors is crucial**
- correct treatment (surgery, chemotherapy, targeted therapy..)
- clinical trials

- **Changes in the tumor classification**
- WHO, TNM, FIGO
- primary vs. metastatic mucinous tumors

- **Ancillary diagnostic techniques**
- IHC
- molecular methods