Gynecological tumors in familial syndromes

Pavel Dundr

Department of Pathology, 1st Faculty of Medicine Charles University and General University Hospital in Prague

Syndrome	Gene	Tumor
Hereditary breast and ovarian cancer	BRCA1, BRCA2	High grade serous carcinoma
Lynch syndrome	MSH2, MSH6, MLH1, PMS2, EPCAM	Endometrioid carcinoma (endometrium, ovary)
		Clear cell carcinoma (endometrium, ovary)
Rhabdoid tumor predisposition syndrome	SMARCA4, SMARCB1	Small cell carcinoma of the ovary, hypercalcemic type
Cowden syndrome	PTEN	Endometrial cancer
Tuberous sclerosis complex	TSC1 (hamartin), TSC2 (tuberin)	PEComa
		Extrapulmonary lymphangioleiomyomatosis
DICER1 syndrome	DICER1	Sertoli-Leydig cell tumor of the ovary
		Embryonal rhabdomyosarcoma (cervix)
Nevoid basal cell carcinoma syndrome	PTCH1, SUFU2	Ovarian fibroma
Von Hippel-Lindau disease	VHL	Clear cell papillary cystadenoma of the broad ligament
Peutz-Jeghers syndrome	STK11	Gastric type mucinous adenocarcinoma (cervix)
		Sex cord tumor with annular tubules (ovary)
		Sertoli cell tumor
Hereditary leiomyomatosis and renal cell carcinoma	FH	Uterine leiomyoma

Role of the pathologist

- Knowledge of familial syndromes
- Recognition of the distinct features of tumors associated with hereditary syndromes, with comments on the potential benefit from genetic counseling
- Screening
- Examination of prophylactically removed specimens

Hereditary breast and ovarian cancer

BRCA1/BRCA2 mutations

- **Associated with a higher risk of developing various tumors, especially:**
  - Breast
  - Ovary
  - Prostate (lifetime risk up to 39%)
  - Pancreas (lifetime risk 1-7%)
  - Colorectal
  - Bile ducts
  - Malignant melanoma

Lifetime risk of cancer			
	General population	BRCA1 mutation	BRCA2 mutation
Breast	12.3%	65%	45%
Ovary	1.3%	39%	11%

SEER Stat Fact Sheets: Breast cancer. http://seer.cancer.gov/statfacts/html/breast.html
SEER Stat Fact Sheets: Ovary Cancer. http://seer.cancer.gov/statfacts/html/ovary.html
Balmaña J, et al. Ann Oncol 2011;22(Suppl. 6):vi31–vi34

Morphologic patterns in BRCA1/2 mutated HGSC

PRIMARY TUMORS

- SET features (at least in 25 %)
- Necrosis (>25% tumor volume)
- High mitotic index (>51/10 HPF)
- Dense TILs (diffuse, > 29/HPF)

- Attempts to select patients at risk eligible for genetic counseling
- Not restricted to tumors with BRCA germline mutation
- May be seen in somatic mutations, BRCA1 promoter methylation, other homologous recombination abnormalities, sporadic setting

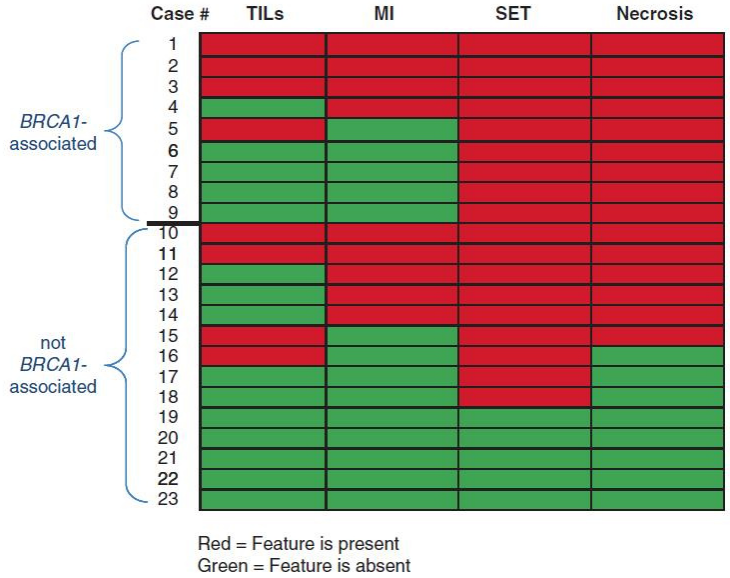

METASTASIS

- All cases with BRCA1/2 abnormalities:
  - pushing pattern of metastases
  - infiltrative metastases with pure papillary pattern
- All cases without metastases
  - infiltrative pattern (combinations of papillary, micropapillary, glandular, cribriform architecture)

IMMUNOHISTOCHEMISTRY

- several studies
- variable sensitivity, specificity, NPV
- screening?

Soslow RA, et al. Mod Pathol. 2012;25(4):625-36.
Reyes MC, et al. Mod Pathol. 2014;27(10):1405-11.
Garg K, et al. Am J Surg Pathol. 2013;37(1):138-46.

Morphologic patterns in BRCA1/2 mutated HGSC

- SET features (at least in 25 %)
- Necrosis (>25% tumor volume)
- High mitotic index (>51/10 HPF)
- Dense TILs (diffuse, > 29/HPF)

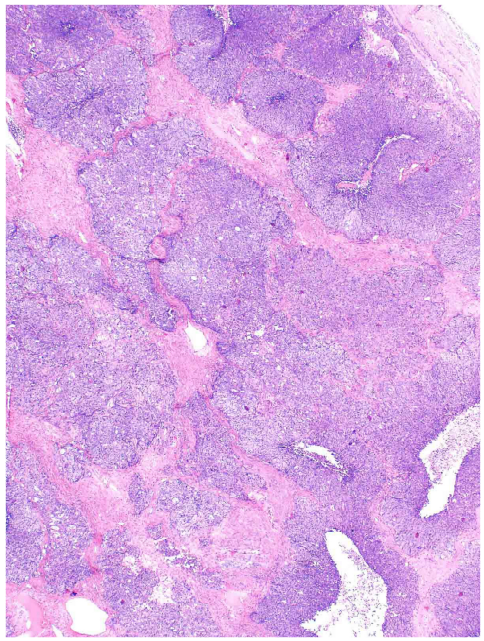
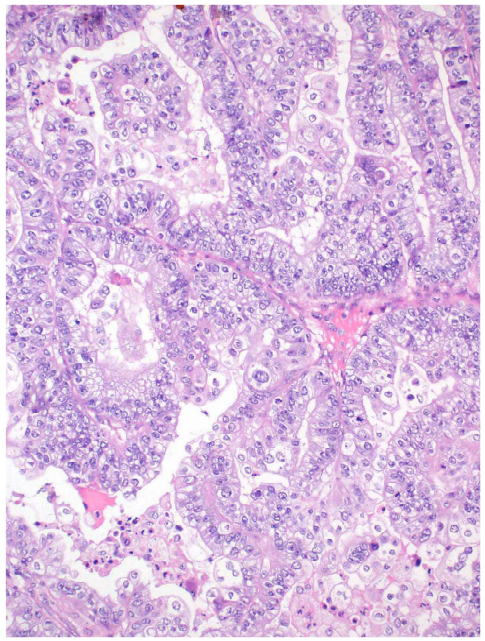
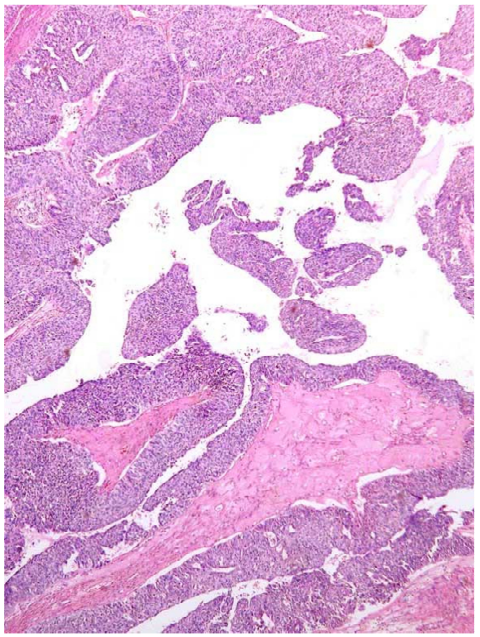

Current approach endorsed by the SGO: all women with epithelial ovarian, tubal, and peritoneal cancers should receive genetic counseling

Risk-reducing salpingo-oophorectomy

- Processing of the specimens:
  - Sectioning and extensively examining the fimbriated end - (SEE-FIM) protocol
  - Fallopian tube: in toto
  - Ovary: in toto

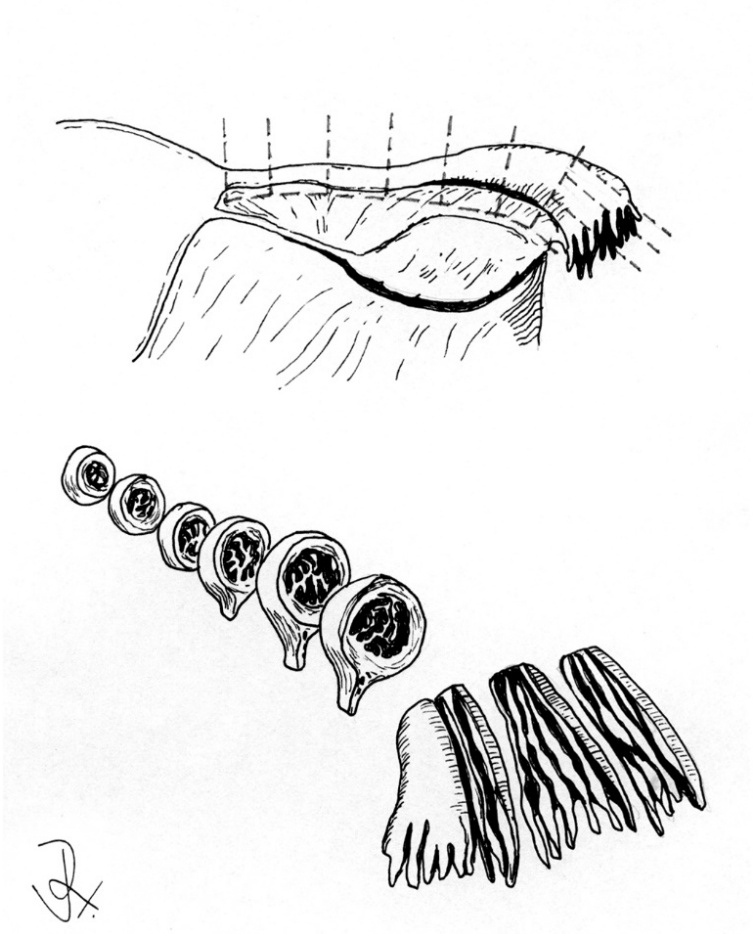

Lee Y et al. Adv Anat Pathol 2006; 13:1-7

Lynch syndrome

Screening: Indication; Algorithms; Methodology

Processing of the prophylactic specimens

Findings in the prophylactic specimens

Lynch syndrome

- 75% risk of colorectal cancer

  (mean age 41-43 years)
- 40-60% risk of endometrial cancer (mean age 47 years)
- 10-15% risk of ovarian cancer (mean age 42 years)

- In 50-60% of patients, gynecological cancer precedes colorectal cancer ("sentinel" cancer!)

- AD
- Genetically heterogeneous
- MSH2 (60%)
- MLH1 (30 %)
- - epigenetic silencing (EPCAM)
- PMS2
- MSH6
- TGFBR2
- MLH3

Lynch syndrome screening

- Amsterdam criteria, revised Amsterdam criteria, Bethesda I and Bethesda II criteria (all cancer types)

- Study on 129 families with Lynch syndrome
- Amsterdam criteria: met by 38%, 12%, 78% and 25% of the families with mutations in *MSH2*, *MSH6*, *MLH1* and *PMS2*
- Revised Amsterdam criteria: 62%, 48%, 87% and 38%
- Each of the four clinical Bethesda criteria had low sensitivity for identifying *MSH6* or *PMS2* mutations

- Clinical criteria are not sensitive enough, low sensitivity esp. for MSH2 and PMS6 mutation

- All cancers in the Lynch syndrome tumor spectrum should be subjected to IHC analysis and/or analysis for microsatellite instability

Sjursen W, et al. J Med Genet. 2010;47(9):579-85.

Lynch syndrome screening – endometrial cancer

- IsGyP:
- All women with EC should undergo systematic clinical screening for LS (review of personal and family history) and/or IHC/molecular screening
- IHC screening of EC for LS is the preferred strategy when resources are available. The most cost-effective approach involves screening by MSH-6 and PMS-2
- IHC alone, with subsequent MSH-2 or MLH1 IHC when indicated

- NCCN Guidelines:
  - Universal testing of endometrial cancers for mismatch repair (MMR) gene
  - Testing should be done on the final hysterectomy specimen (can be done on presurgical biopsy if hysterectomy not performed)
  - MLH1 loss should be further evaluated for promoter methylation to assess epigenetic process
  - Genetic counseling and testing for all other MMR abnormalities

Cho KR, et al. Int J Gynecol Pathol 2019; 38:S114-122

Features of Lynch syndrome-associated EC

	No.	Age range (years)	Subtype (no.)	Location (no.)	Mutation				
					MLH1	*MSH2*	*MSH6*	*PMS2*	NA
Endometrium [14,17–22,24,35,39,46,47]	234	30–67		Corpus 234					
Endometrioid			197		51	111	14	7	14
Serous			5		–	4	1	–	–
Clear cell			9		1	3	–	–	5
Mixed, NOS			4		2	1	1	–	–
Clear/endometrioid			1		–	1	–	–	–
Clear/serous			3		–	3	–	–	–
Undifferentiated			3		–	2	1	–	–
MMMT			4		–	4	–	–	–
Squamous			1		–	–	1	–	–
Neuroendocrine			1		–	2	–	–	–
Carcinoma, NOS			6		–	–	–	–	6
Lower Uterine Segment [23,25,26,45]	13	39–81		NA					
Endometrioid			8		1	1	–	–	6
Non-endometrioid, NOS			4		–	–	–	–	4
Mixed clear/endo			1		–	1	–	–	–

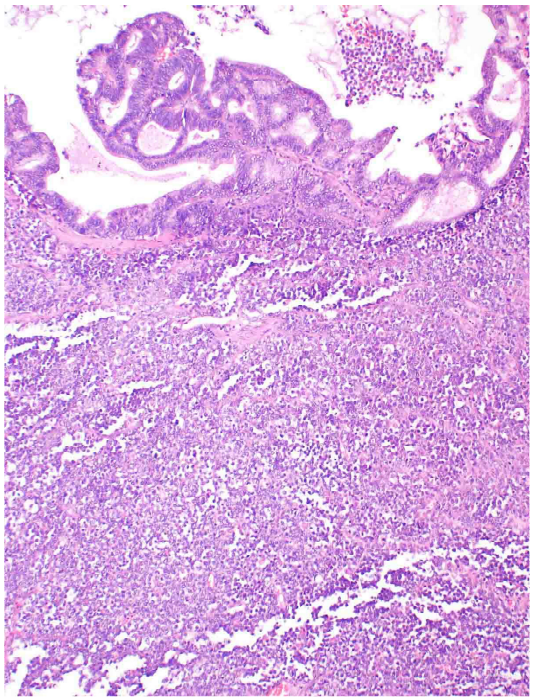

Dedifferentiated carcinoma

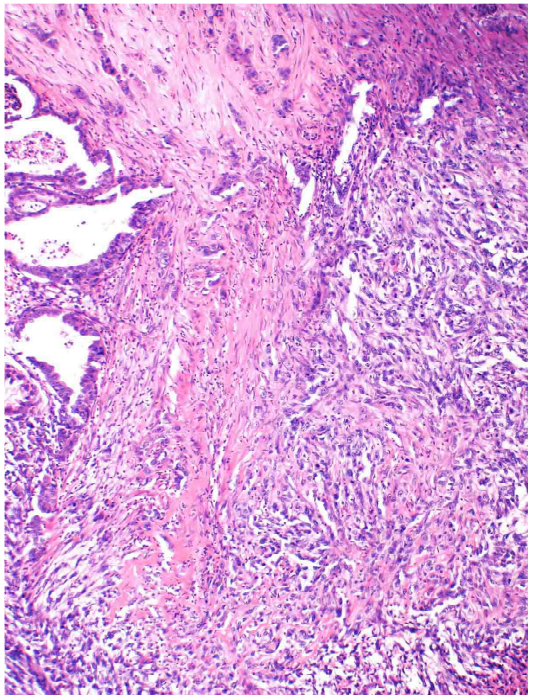

Carcinosarcoma

Morphological features suggestive of Lynch syndrome:
- presence of prominent TILs
- localization in the lower uterine segment
- mixed features; dedifferentiated carcinoma; carcinosarcoma

Downes MR, et al. Histopathology. 2014;65(2):228-39

Algorithm for Lynch syndrome screening in endometrial cancer

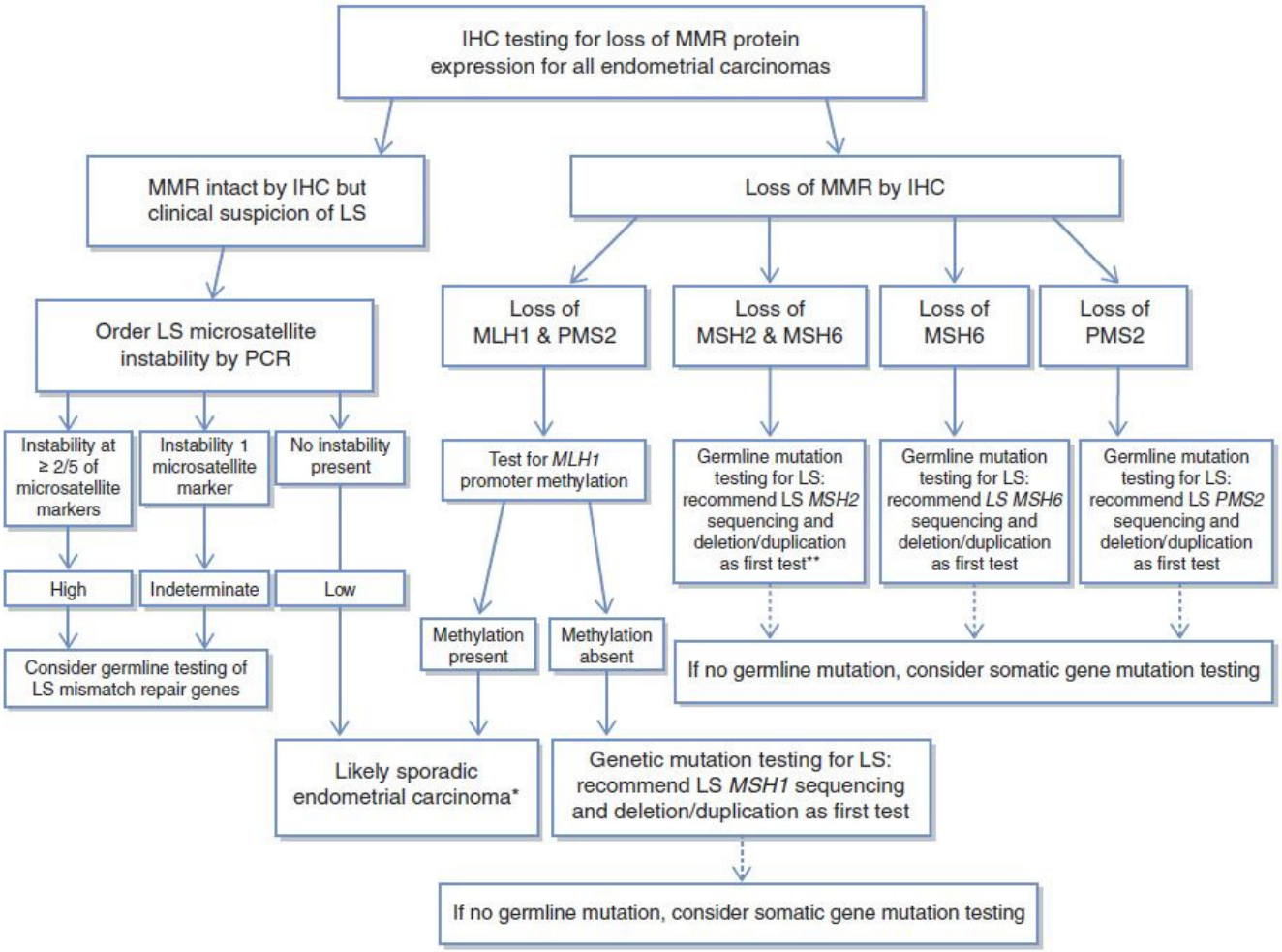

Mills AM, Longacre TA. Am J Surg Pathol 2016

Lynch syndrome screening – ovarian cancer

- No unified approach

- Unselected patients – very low detection rate
  - HGSC at about 1% MSI / dMMR (usually not related to Lynch sy
  - > 10% EC, CCC, dedifferentiated ca, MMMT are MSI / dMMR

- Age (<50 years) and histological (EC and CCC) reflex testing (?)

Features of Lynch syndrome-associated OC

Ovary[4,28–36,38,47]	186	26–79	NA				
Serous		58	5	13	1	–	39
Mucinous		16	5	2	–	–	9
Clear cell		24	1	4	6	–	13
Endometrioid		48	9	13	3	–	23
Mixed, NOS		4	–	–	–	–	4
Clear/endometrioid		3	1	2	–	–	–
Endometrioid/serous		1	–	1	–	–	–
Endo/clear/mucinous		1	1	–	–	–	–
Endo/serous/mucinous		1	1	–	–	–	–
Endo/clear/serous		1	1	–	–	–	–
Undifferentiated		1	–	–	–	–	1
Carcinoma, NOS		28	4	–	–	–	24

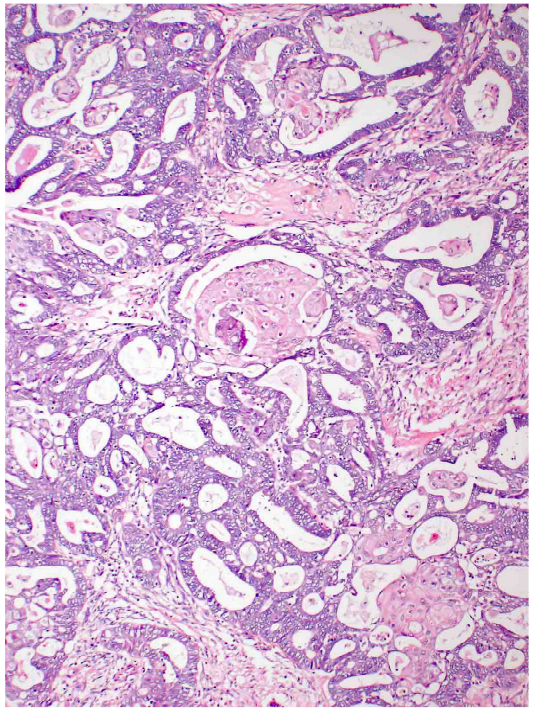

Endometrioid carcinoma G1

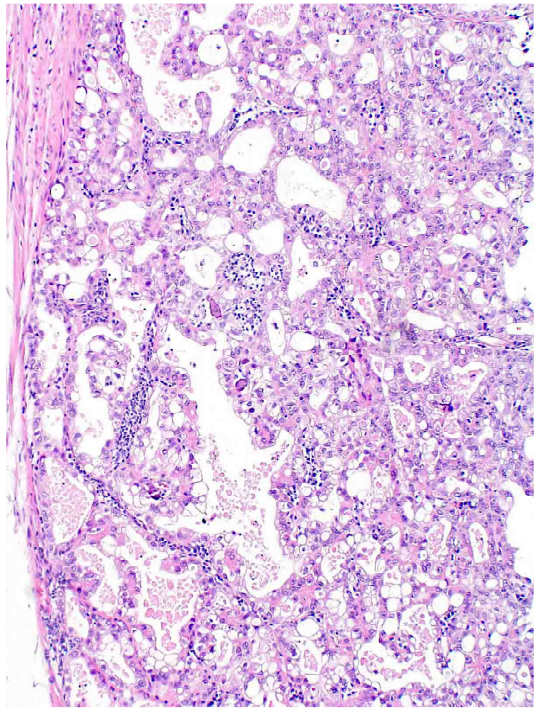

Clear cell carcinoma

Downes MR, et al. Histopathology. 2014;65(2):228-39

MMR testing

Immunohistochemistry

- 4 antibodies (MSH2, MSH6, MLH1, PMS2)
- Retained protein expression (MMR-proficient)
- Loss of (any) protein expression - dMMR (MMR-deficient)

PCR

- Bethesda panel, Promega panel...
- Our department:
  - 5 mononucleotids
    - BAT-25, BAT-25, NR-21, NR-22, NR-24
  - Equivocal cases: addition of 3 dinucleotids
    - D2S123, D5S346, D7S250

MMR-IHC

- Available in most laboratories
- Cheap, cost effective
- Easy interpretation (binary result)
- Low tissue requirements (possible even in poor samples)

- Easy interpretation (binary result):
  - any nuclear staining = intact
  - may be focal, faint
  - must be positive internal control (stromal tissue, inflammatory cells etc.)
  - exclude arteficial staining (cytoplasmic, dot-like nuclear etc.)
  - exclude precursor lesions

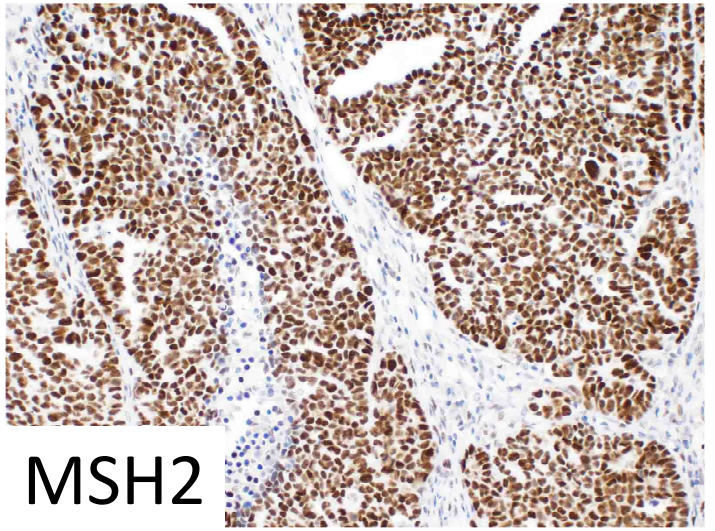

MSH2

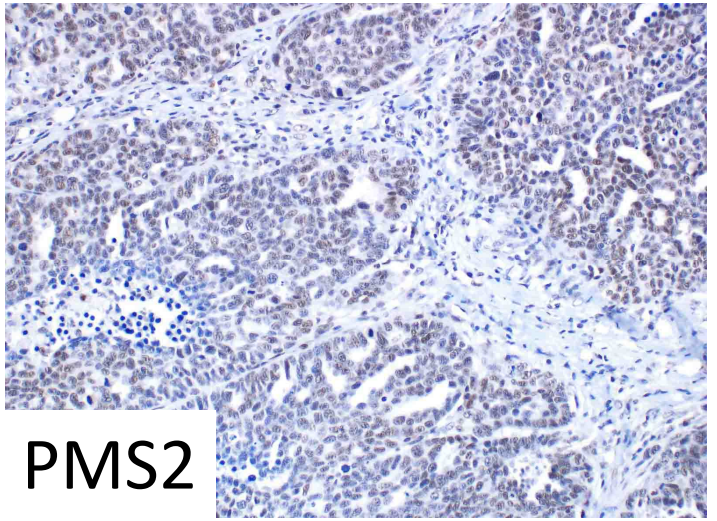

PMS2

Microsatellite instability analysis

- **Our system:**
  - 5 mononucleotide repeats and pentaplex PCR
  - BAT-25, BAT-26, NR-21, NR-22, NR-24
  - doubtful cases: addition of D2S123, D5S346, D7S250



- **Bethesda panel:**
  - BAT-25, BAT-26, D2S123, D5S346, D7S250
- **Promega MSI analysis system:**
  - BAT-25, BAT-26, NR-21, NR-24, MONO-27
- MSS - all markers stable
- MSI-L - 1 of 5 markers instable
- MSI-H - 2 or more markers instable

Suraweera N, et al. Gastroenterology. 2002;123(6):1804-11.

Methodology

- Endometrial and ovarian cancer more MSH2/MSH6 mutations and less MLH1/PMS2 mutations when compared to CRC
- Testing MSI (fragment analysis) - does not detect about 50% of MSH6 mutations
- overall IHC sensitivity is about 90% (regardless of mutation type)

- Preferred IHC testing

- Up to 50% (25-50%) of dMMR cases: negative result of germline testing
  - false positive result (rare)
  - unidentified/undetected germline mutation
  - somatic mutation/inactivation (Lynch-like tumors)
  - false negative result (missense MLH1 mutations, inactive protein detected by IHC)

Mills AM, Longacre TA. Am J Surg Pasthol 2016;40:e35-e44

Rationale for prophylactic surgery

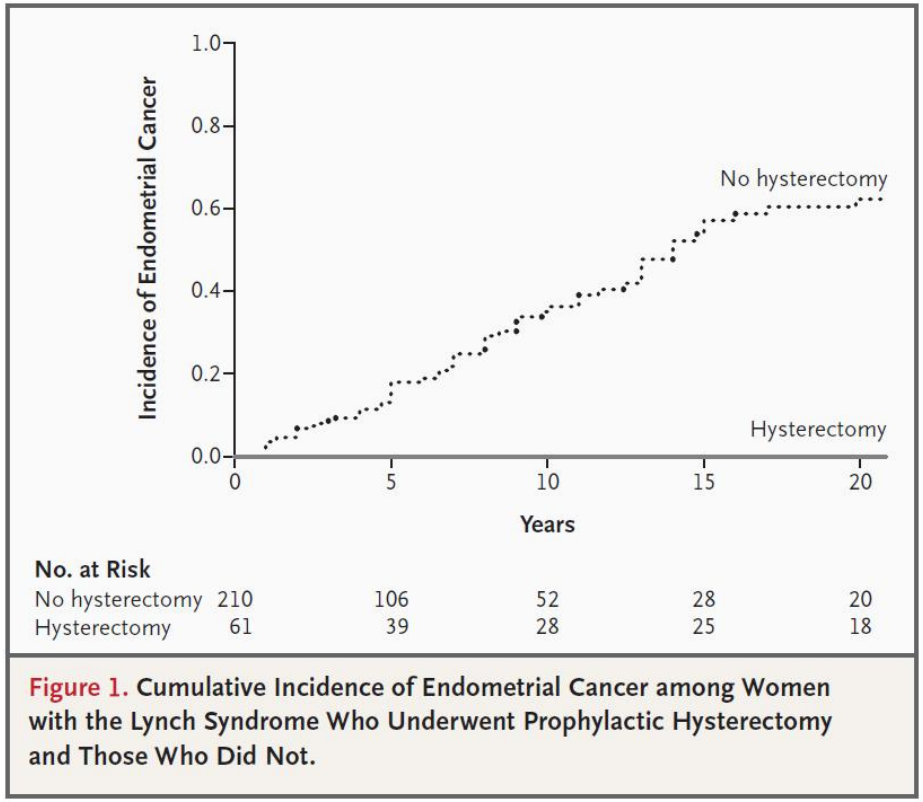

Figure 1. Cumulative Incidence of Endometrial Cancer among Women with the Lynch Syndrome Who Underwent Prophylactic Hysterectomy and Those Who Did Not.

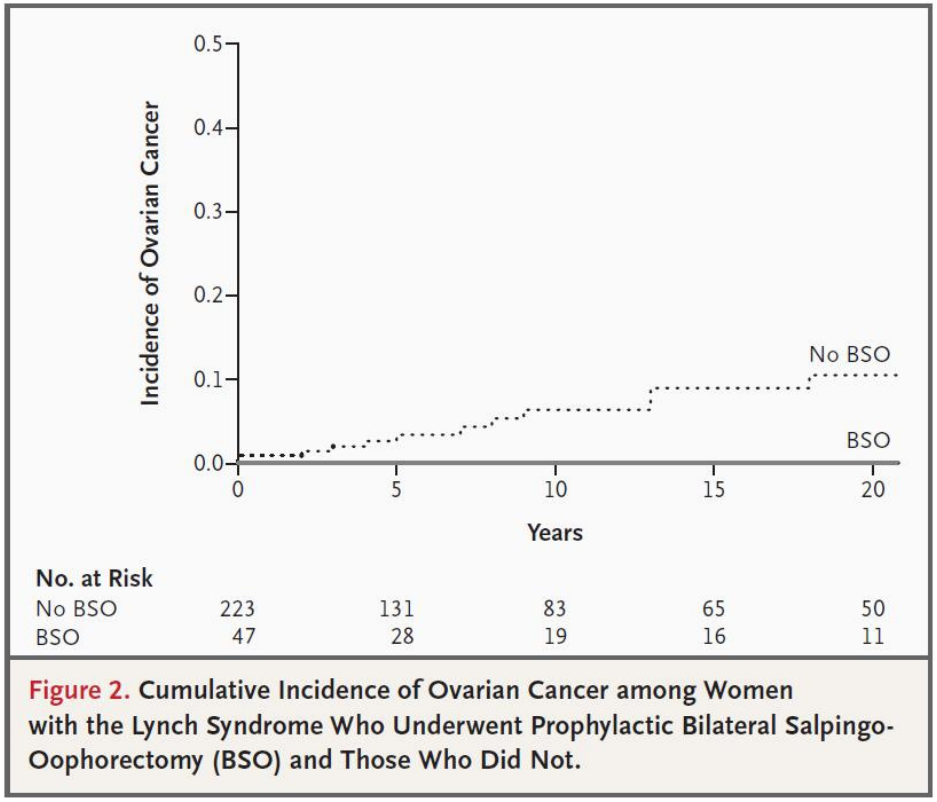

Figure 2. Cumulative Incidence of Ovarian Cancer among Women with the Lynch Syndrome Who Underwent Prophylactic Bilateral Salpingo-Oophorectomy (BSO) and Those Who Did Not.

Schmeler KM, et al. N Engl J Med. 2006;354(3):261-9

Recommendations for optimal specimen handling and grossing of prophylactic gynecological resections (hysterectomy and bilateral salpingo-oophorectomy)

Ovaries and tubes: SEE-FIM protocol
Lower uterine segment: *in toto*
Cervix: representative anterior, posterior, right and left lateral sections
Endometrium: In the absence of a gross lesion *in toto*
All gross abnormalities need to be submitted for microscopic examination

Downes MR, et al. Histopathology. 2014;65(2):228-39

Findings in prophylactic specimens

- 25 specimens
- Abnormal finding in 8 specimens (32%):
  - 6 endometrial hyperplasia
  - 2 cases of endometrioid carcinoma
- Paucity of studies describing the pathological findings in prophylactic gynecological specimens in LS patients

Downes MR, et al. Histopathology. 2014;65(2):228-39

Lynch syndrome - take home messages

1. Preferred method of screening is IHC
2. The criteria for screening are different in different countries (all patients with EC and all/selected patients with OC?)
3. Processing of the prophylactic specimens should be standardized - no official recommendation / guidelines

Cowden syndrome

Cowden syndrome

- AD
- Mutation of PTEN (phosphatase and tensin homolog)
- Predisposition to hamartomatous growths
- Predisposition to multiple organ malignancy:
  - breast, endometrial, thyroid, colon, renal cancers
- Rare (1: 200 000)

Cancer type	Estimated lifetime risk
Breast	25%–50%, possibly higher
Endometrial	5%–28%
Renal	Unclear, possibly up to 34%
Colon	9%–16%
Thyroid	3%–17%, possibly higher
Melanoma	6%

- Risk of EC starts at the age of 25 years
- 2 case reports of EC in adolescents

Gammon A, et al. Appl Clin Genet. 2016;9:83-92

PTEN aberration

- Somatic mutations common (breast, EC, melanoma...)
- PTEN inactivation – up to 93% of EC sporadic cases (genetic or epigenetic changes)
- Somatic mutations can be related to MMR deficiency in Lynch syndrome patients

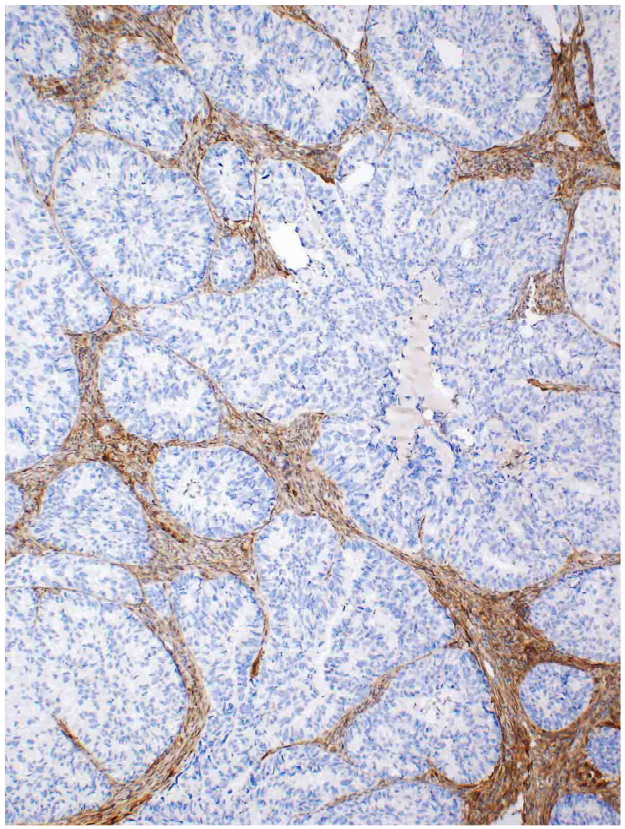

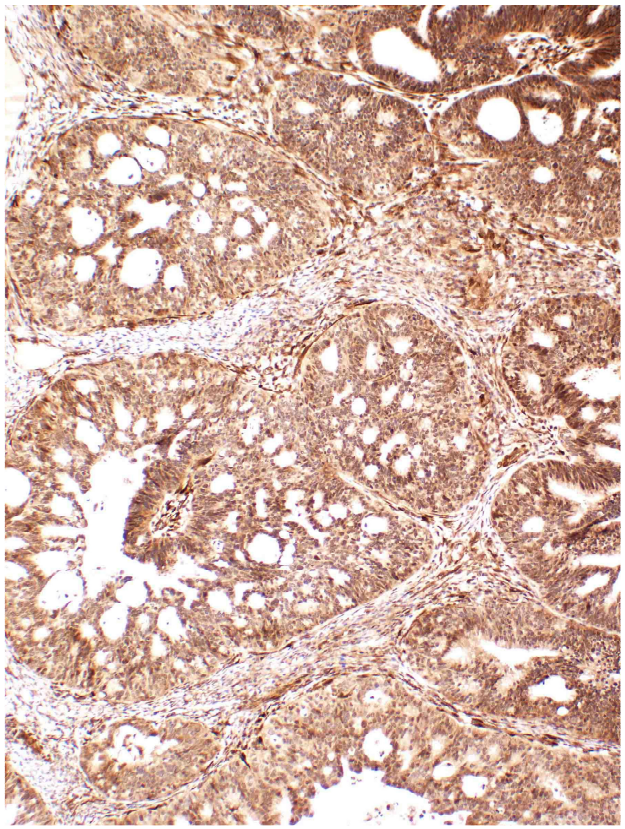

Cowden syndrome - take home messages

1. EC associated with Cowden disease has no distinct pathological features (mostly EC G1)
2. IHC examination of the loss of PTEN expression cannot be used for screening (common somatic changes of PTEN)
3. The role of pathologist is limited to suggesting Cowden syndrome testing in rare early-onset cases (especially with retained MMR protein expression)

Rhabdoid tumor predisposition syndrome (RTPS)

- AD
- **Increased risk of developing rhabdoid tumors:**
  - kidney
  - CNS (atypical teratoid/rhabdoid tumor)
  - extracranial / extrarenal malignant rhabdoid tumors
  - head and neck, paravertebral muscles
  - liver, urinary bladder, mediastinum
  - retroperitoneum, pelvis, heart
  - **small-cell carcinoma of the ovary, hypercalcemic type**

- Germinal mutation of SMARCB1 or SMARCA4 gene
- Majority of the patients with RTPS - *de novo* germline SMARCB1 pathogenic variant
- **Most patients with SMARCA4-related RTPS inherited a pathogenic variant from an unaffected parent**
- Incomplete penetrance
- Types of RTPS-related tumors may vary among different members of the same family

Small cell carcinoma of the ovary, hypercalcemic type

- Diffuse growth pattern
- Follicle-like spaces (most cases)
- May show nested, trabecular, corded pattern
- Small cells, high N/C ratio
- Frequent mitoses
- Necroses
- Large cells (in up to 40% of cases)
- Large cell variant (only large cells)

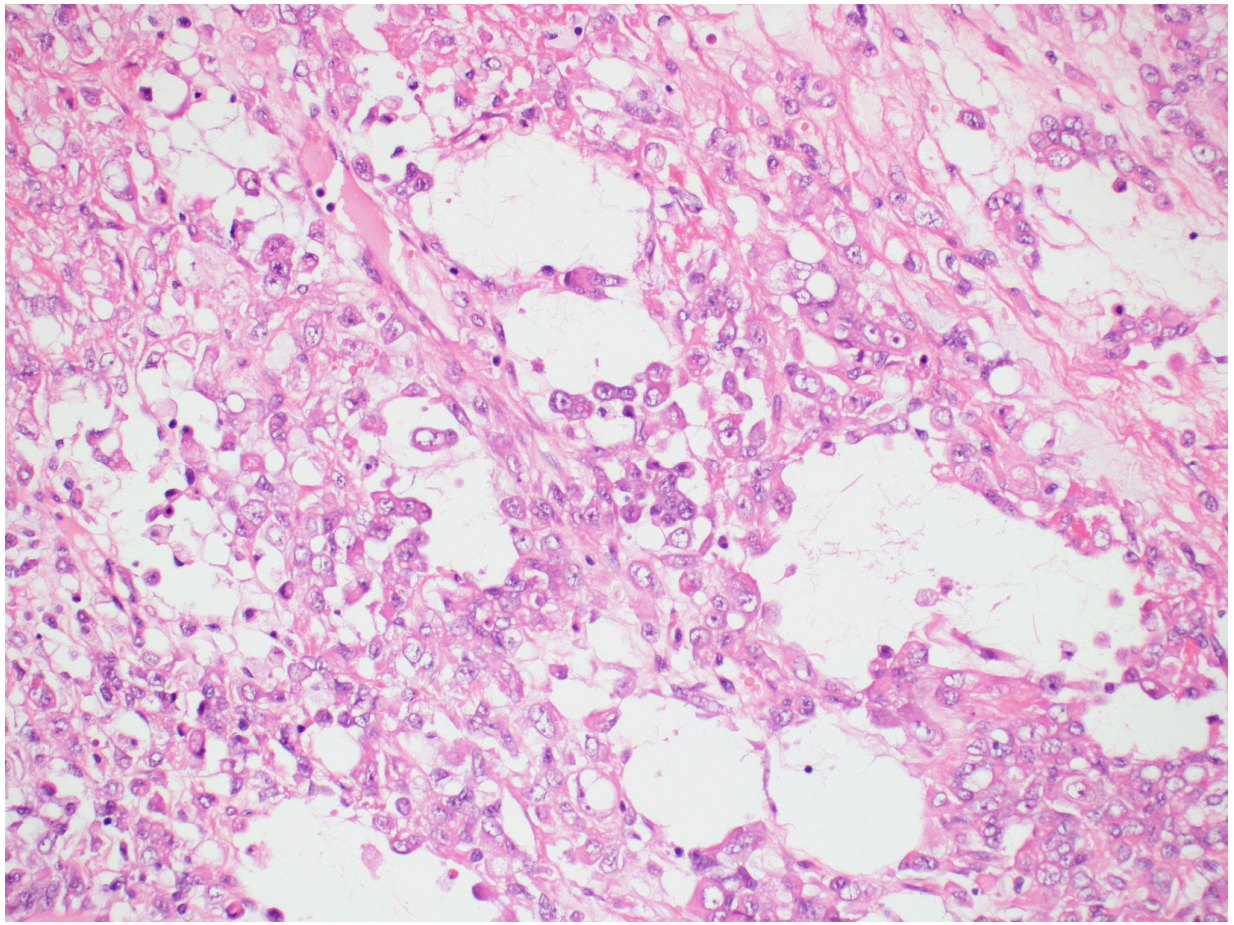

Small cell carcinoma of the ovary, hypercalcemic type

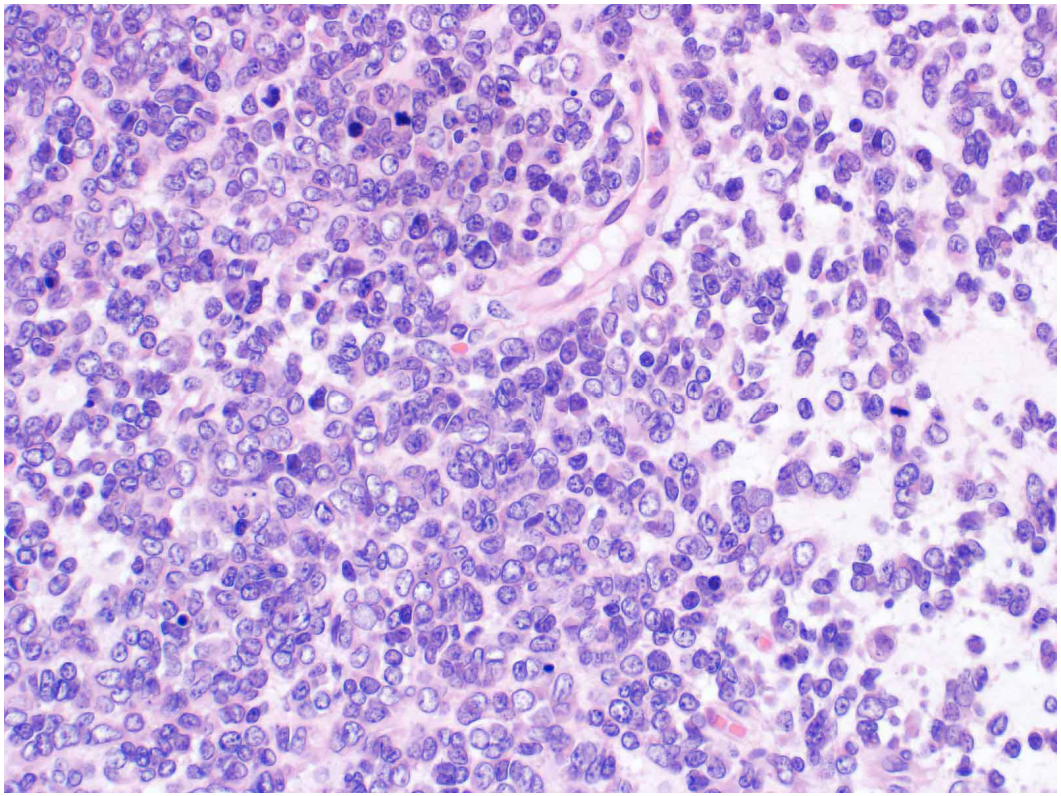

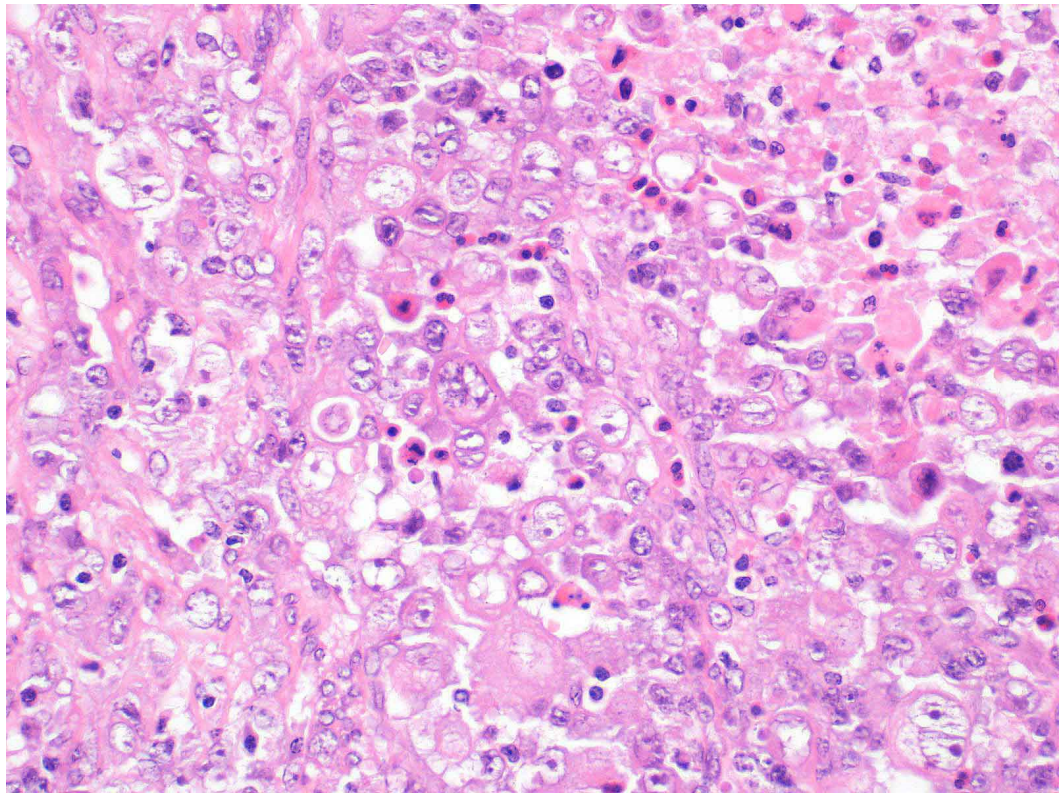

Large cell variant

Small cell carcinoma of the ovary, hypercalcemic type

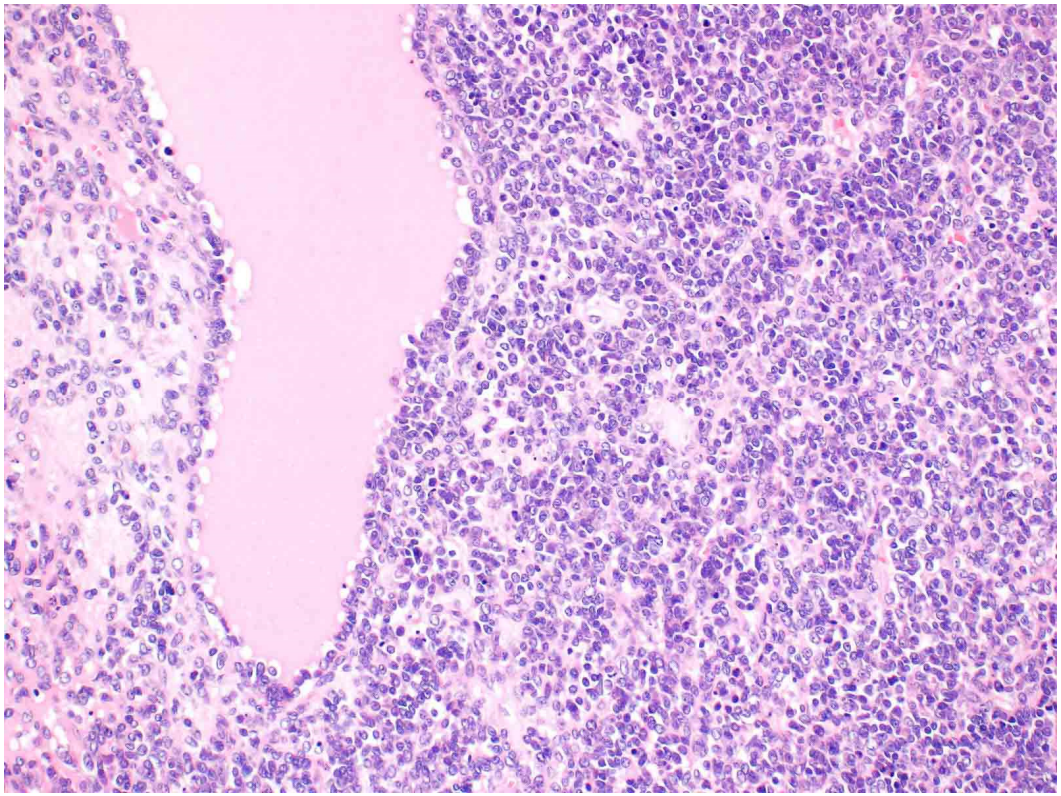

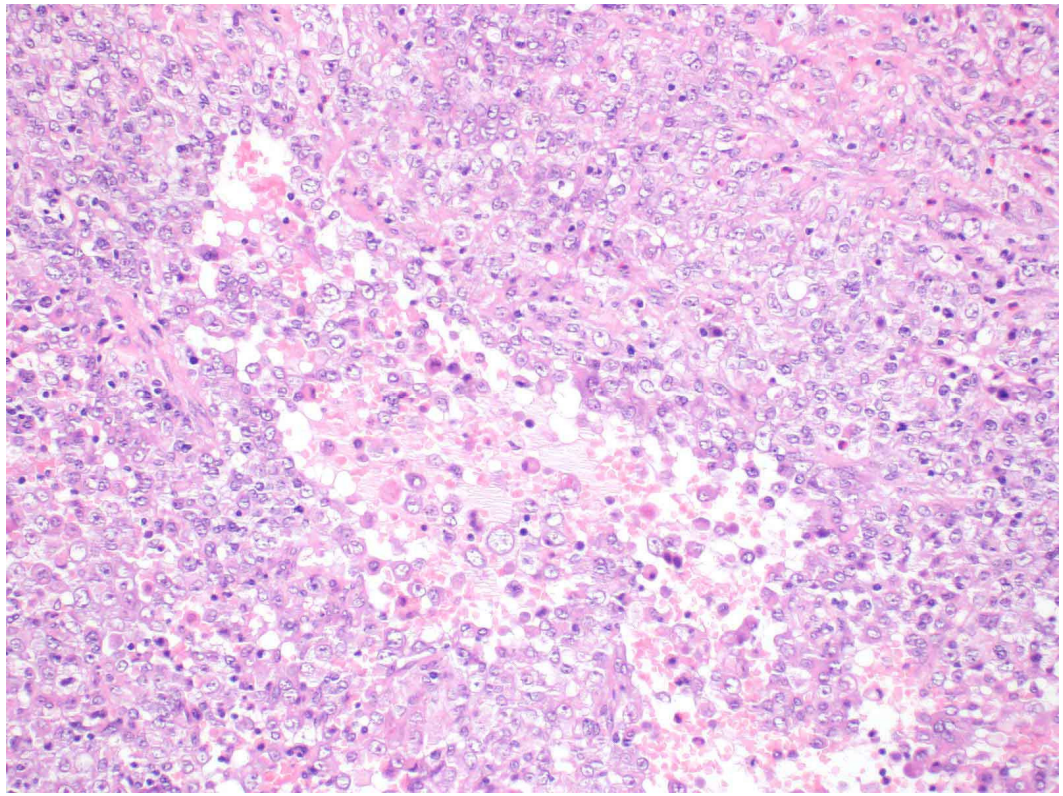

Large cell variant

Small cell carcinoma of the ovary, hypercalcemic type

- IHC:
- Loss of SMARCA4 (BRG1) expression (!)

- Other IHC findings nonspecific
- Positive:
  - EMA, cytokeratin, CD10, WT1, minority of cases also synaptophysin, chromogranin
- Negative:
  - Inhibin, TTF-1

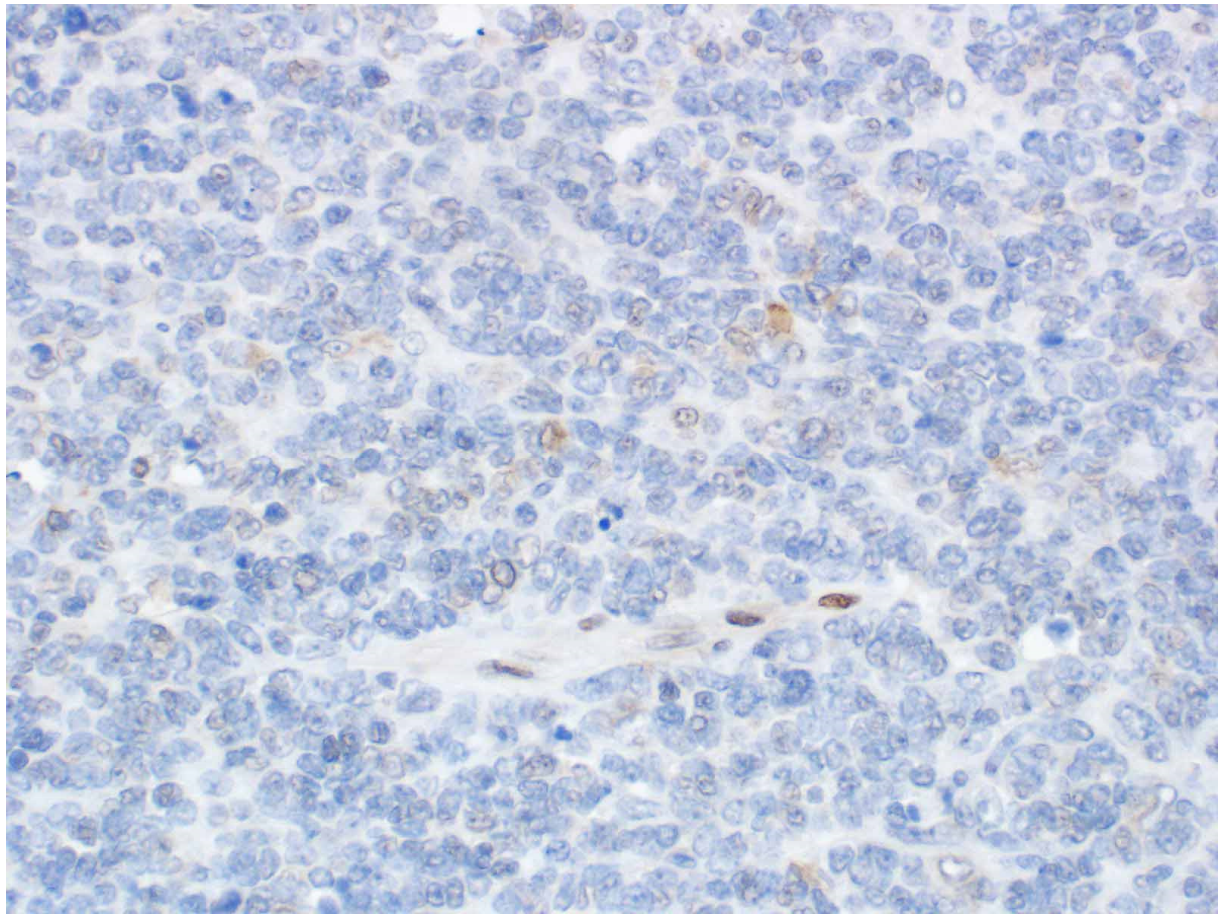

RTPS - take home messages

1. Loss of SMARCA4(BRG1) expression (!)
2. Comment on the potential benefit of genetic counseling concerning this syndrome

Hereditary leiomyomatosis and renal cell carcinoma

- **AD hereditary disease**
- Germinal mutations of the FH gene for fumarate hydratase
- Predisposition to multiple skin and uterine leiomyomas and renal carcinoma

- **AR - fumarate aciduria**
  - metabolic disease
  - psychomotoric retardation, hypotonia, encephalopathy
  - death in the first years of life

- Uterine leiomyomas:
  - often at a younger age
  - multiple, larger
  - leiomyoma with bizarre nuclei

- Kidney tumors:
  - papillary renal carcinoma "non-I. type"
  - Other types (collecting ducts, clear cell ..)

Hereditary leiomyomatosis and renal cell carcinoma

- Expression of fumarate hydratase may be detected by IHC
- Loss of expression may be related to:
  - FH mutation (IHC does not distinguish between germinal and somatic mutations)
  - epigenetic inactivation (hypermethylation)
  - FH deletion

- Study of Harrison et al. (2016)
  - IHC loss of expression:
    - 12/1152 LM
    - 0/88 LMS
    - 5 patients with HLRCC had at least 1 FH-deficient LM

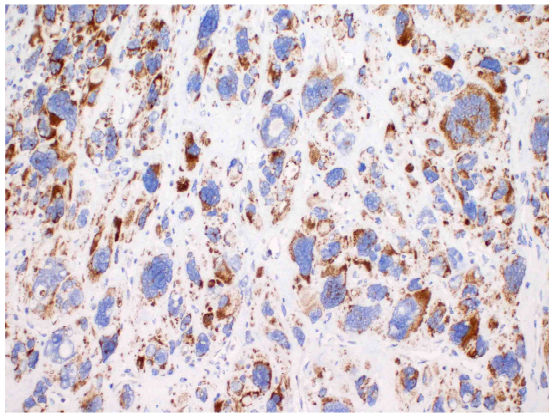

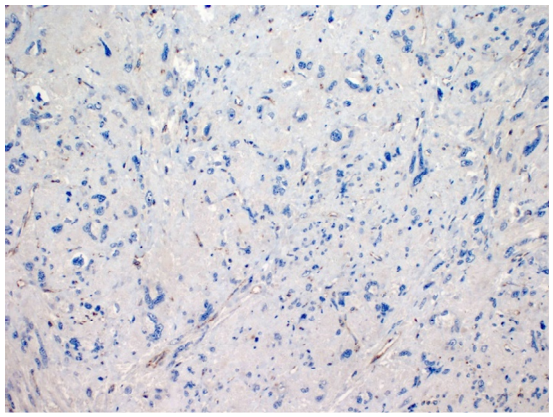

Harrison WJ et al. Am J Surg Pathol 2016; 40:599-607

Hereditary leiomyomatosis and renal cell carcinoma

- Our study (200 uterine tumors):
  IHC:
  - 108 leiomyoma with bizzare nuclei
  - 50 leiomyoma
  - 42 leiomyosarcoma

- NGS and Sanger sequencing:
  120 tumors
  - 53 LBN
  - 47 LM
  - 20 LMS

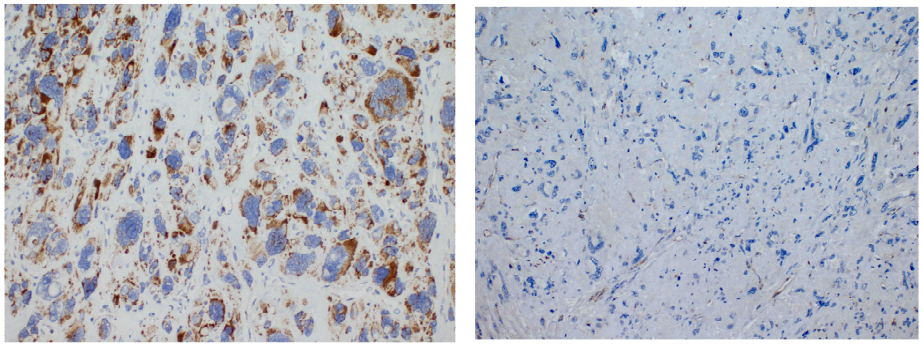

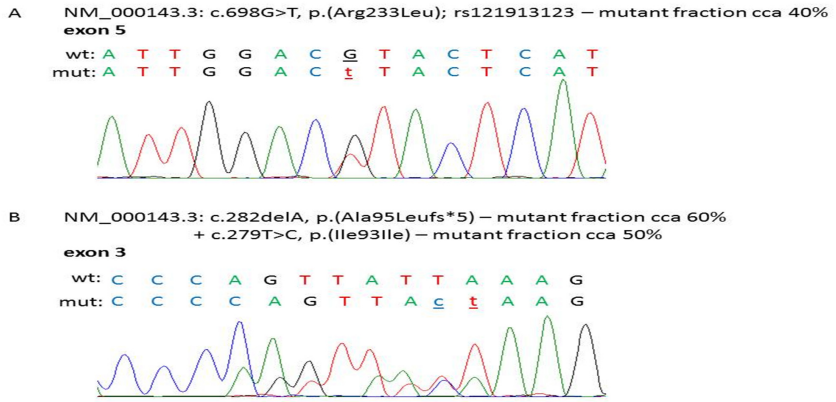

Hereditary leiomyomatosis and renal cell carcinoma

- Our study (200 uterine tumors):
  IHC:
  - 108 leiomyoma with bizzare nuclei
  - 50 leiomyoma
  - 42 leiomyosarcoma

- NGS and Sanger sequencing:
  120 tumors
  - 53 LBN
  - 47 LM
  - 20 LMS

- Loss of FH expression:
  - 67/108 (62%) LBN
  - 1/50 (2%) LM
  - 0/42 (0%) LMS

- FH mutation:
  - 15/53 (28%) LBN (13/15 loss of FH expression)
  - 0/50 (0%) LM
  - 0/42 (0%) LMS

- IHC
  - Sensitivity: 87%
  - Specificity: 58%

Hereditary leiomyomatosis and renal cell carcinoma

- Morphologic features of FH-deficient LM:
  - prominent („inclusion-like“) eosinophilic nucleoli
  - hypercellularity
  - nuclear atypias (LM with bizarre nuclei)
  - stromal edema
  - staghorn vessels
  - hyaline globules
- Inconsistent findings!
- Limited practical value

- Screening for HLRCC in unselected patients - limited benefit
- Most FH-deficient leiomyomas somatic mutations
- Morphologic features inconstant and subtle

- Genetic testing for HLRCC in these patients in the absence of other clinical risk factors is not recommended
- Clinical risk factors:
  - personal or a family history of cutaneous leiomyomas; renal carcinoma; or symptomatic leiomyomas at a very young age

Hereditary leiomyomatosis and renal cell carcinoma - take home messages

1. Comment on the potential benefit of genetic counseling concerning this syndrome in lesions with morphological features suggestive of FH-deficient leiomyomas
2. IHC for loss of FH expression can support the need for counseling
3. Intact IHC FH staining is not exclusive of the syndrome

Peutz-Jeghers syndrome

Peutz-Jeghers syndrome

- AD
- Germline mutation of STK11
- Incidence 1:50,000 to 1: 200,000
- - hamartomatous intestinal polyps
- - mucocutaneous pigmentations

- Increased incidence of several cancer types

Table 1. Reported cancers and age at diagnosis in 1,644 Peutz–Jeghers syndrome patients from 20 cohort studies (3, 23–41)

Cancer	No. cancers	Mean age in years
Gastrointestinal	198	42 (*n*=69)
Colorectum	80	43 (*n*=23)
Small intestine (including duodenum)	41	37 (*n*=18)
Stomach	35	40 (*n*=14)
Esophagus	3	33 (*n*=1)
Pancreas	32	52 (*n*=12)
Biliary tract	7	32 (*n*=1)
Extragastrointestinal		
Breast	59	44 (*n*=23)
Uterus	10	43 (*n*=1)
Ovary	16	35 (*n*=8) (including one Sertoli tumor at age 6)
Cervix	14	36 (*n*=5)
Testes	3	6 (*n*=1)
Lung	25	47 (*n*=8)
Other[a]	44	45 (*n*=9)
Unknown	15	50 (*n*=7)
Total	384	42 (*n*=131)

Van Lier et al. Am J Gastroenterol 2010; 105:1258-1264

Peutz-Jeghers syndrome

- **Gynecological lesions:**

- Distinct pathological features:
  - 1. Gastric type of mucinous endocervical carcinoma
  - 2. Ovarian sex cord tumors with annular tubules
  - 3. Synchronous mucinous metaplasia and neoplasia of the female genital tract
  - 4. Lobular endocervical glandular hyperplasia (?)

- Nonspecific pathological features:
  - 1. Sertoli / Sertoli-Leydig cell tumor of the ovary
  - 2. Ovarian carcinoma
  - 3. Endometrial carcinoma

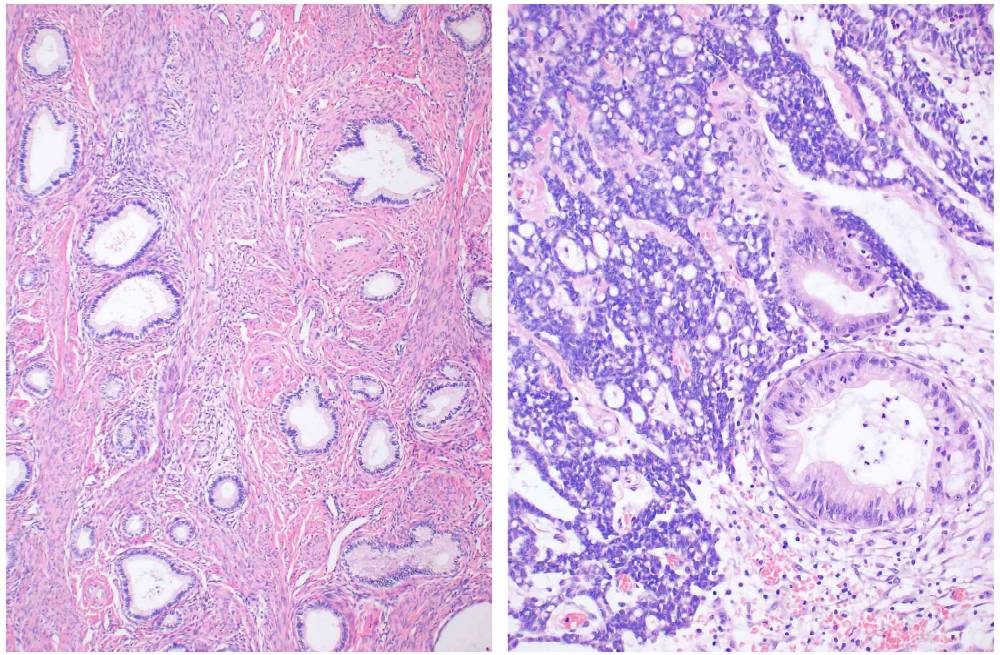

- 42-year old female with PGS
- Synchronous well differentiated gastric type of endocervical carcinoma and moderately differentiated Sertoli-Leydig cell tumor with heterologous elements (DOD 2 years after the diagnosis)
- History:
  - Father died of lung cancer
  - Sister died of cervical cancer

Van Lier et al. Am J Gastroenterol 2010; 105:1258-1264

Peutz-Jeghers syndrome - take home messages

1. Comment on the potential benefit of genetic counseling concerning this syndrome in lesions with morphological features suggestive of PJS
2. No specific IHC features suggestive of this syndrome

DICER1 syndrome

DICER1 syndrome

- AD
- Incidence of germinal DICER1 mutation:
  - ~1:10,600 in general population
  - ~1:4,600 in TCGA study

- Multinodular goiter
- Predisposition to several tumors:
  - pleuropulmonary blastoma, cystic nephroma, thyroid cancer, pinealoblastoma…
  - embryonal rhabdomyosarcoma
  - Sertoli-Leydig cell tumor
  - gynandroblastoma
  - endometrioid carcinoma (3/524 in TCGA study = 0,6%)

Stewart DR, et al. J Clin Oncol 2019; 37:668-676
Cowan M, et al. Gynecol Oncol Rep. 2018;25:94-97
Kim J, et al. Mol Genet Genomic Med 2019; e555

DICER1 somatic mutations

- Sertoli-Leydig cell tumor
  - moderately and poorly differentiated
  - retiform
  - heterologous elements
- Sex cord-stromal tumors resembling juvenile GCT or gynandroblastoma
- Ovarian fibrosarcoma (1 case, 9-year old girl)

- Frequency varies between 16-97% (!)
- More common in younger patients
- Mutually exclusive with FOXL2 mutations (about 20%)

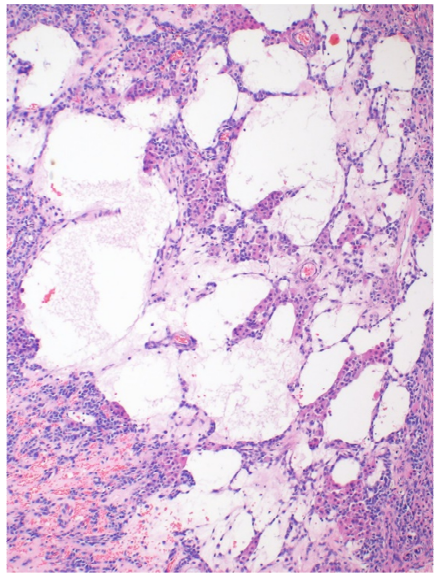

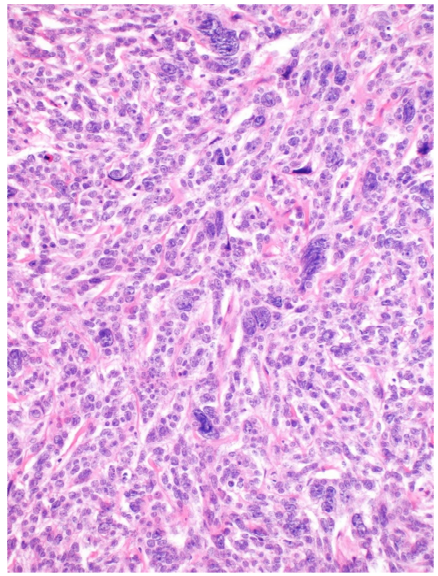

Karnezis et al. Am J Surg Pathol 2019;
de Kock L et al. Am J Surg Pathol 2017;41:1178-1187
Schultz KAP et al. Gynecol Oncol 2017;47:521-527
Melendes-Zajgla J et al. Sci Rep 2018;8:3252

DICER1 syndrome - take home messages

1. Comment on the potential benefit of genetic counseling concerning this syndrome when reporting:

- cervical embryonal rhabdomyosarcoma
- every or at least moderately or poorly differentiated SLCT

Tuberous sclerosis complex

Tuberous sclerosis complex

- AD
- incidence 1:6,000 – 1:10,000
- Up to 2/3 patients *de novo* mutation (mostly TSC2)
- Affected genes: TSC1 (hamartin) or TSC2 (tuberin)
- clinical symptomes highly variable

- **Diagnostic signs:**
  - multiple renal angiomyolipomas
  - sclerotic foci in the brain cortex
  - subependymal glial nodes
  - retinal hamartomas
  - facial angiofibromas
  - ungual fibromas
  - fibrous plaques in the scalp or forehead

- **Suspected signs:**
  - multiple renal cysts or tumors
  - lymphangioleiomyomatosis
  - rhabdomyoma of the heart
  - family history of TSC
  - CNS: calcification, hypomyelination
  - hypomelanotic maculae of the skin

Tuberous sclerosis complex

- **Gynecological lesions:**
- 1. Extrapulmonary lymphangioleyomyomatosis
- 2. Perivascular epitheloid cell tumors
  - mostly uterus
  - cervix, vagina, adnexa
  - estimated risk for TSC in patients with PEComa is about 10 %

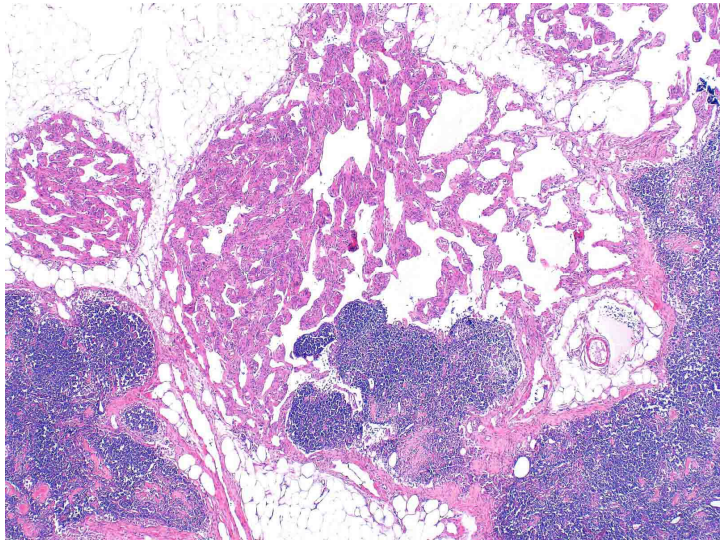

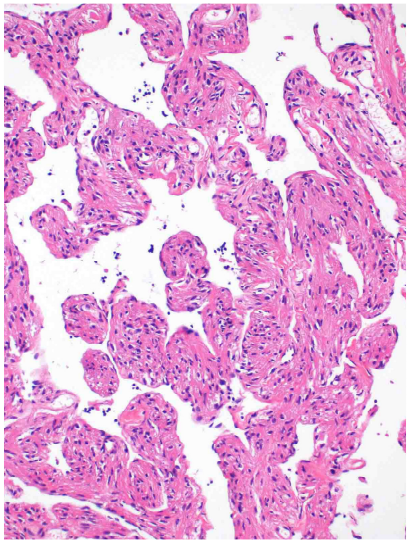

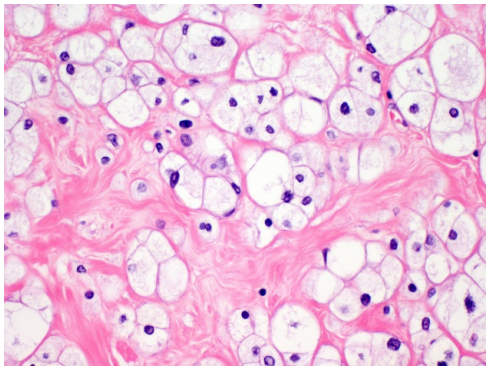

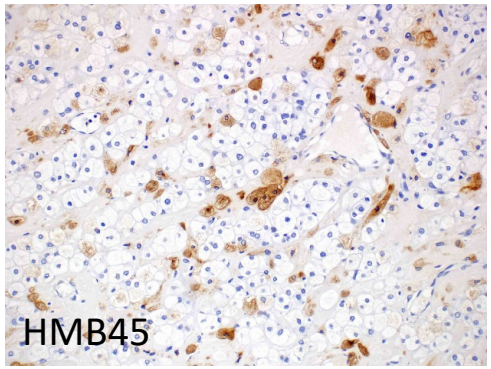

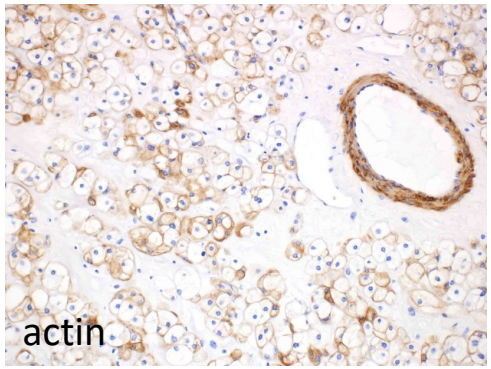

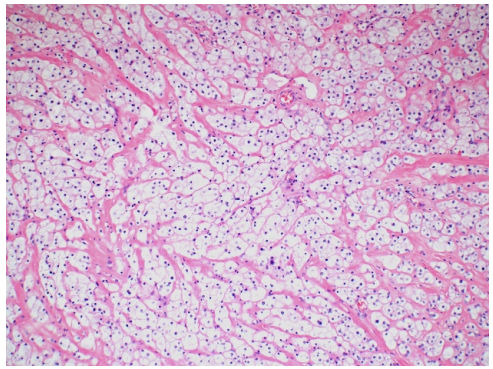

Tuberous sclerosis complex - take home messages

1. In patients with extrapulmonary LAM or PEComa: comment on the potential benefit of genetic counseling concerning this syndrome in lesions with morphological features suggestive of FH-deficient leiomyomas
2. No specific morphological or IHC features suggestive of this syndrome

Nevoid basal cell carcinoma syndrome

Nevoid basal cell carcinoma syndrome

- AD
- 1: 30,000
- Germline mutation of PTCH1 or SUFU2
- 20-30 % *de novo* mutations

- Early-onset multifocal BCC
- Multiple jaw keratocysts
- 60% patients: macrocephaly, frontal bossing, coarse facial features and facial milia
- Skeletal anomalies (bifid ribs, wedge-shaped vertebrae)
- Ectopic calcifications (falx cerebri)
- Cardiac fibromas (2%)
- Ovarian fibromas (20%)
- medulloblastoma in 5% of children

Nevoid basal cell carcinoma syndrome

- Ovarian fibromas:
  - Multifocal
  - Multinodular
  - Bilateral
  - Heavily calcified
  - No microscopic differences when compared to sporadic fibromas



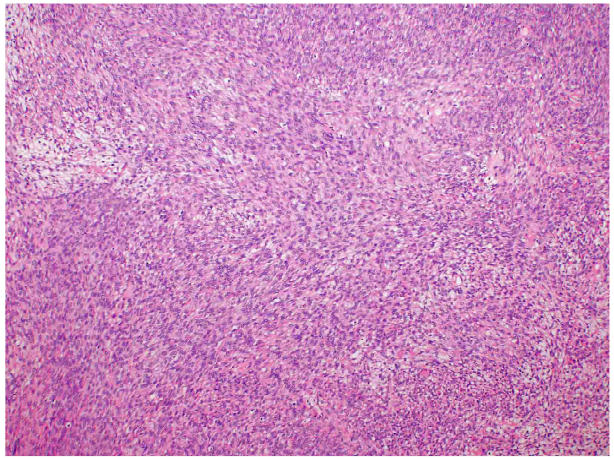

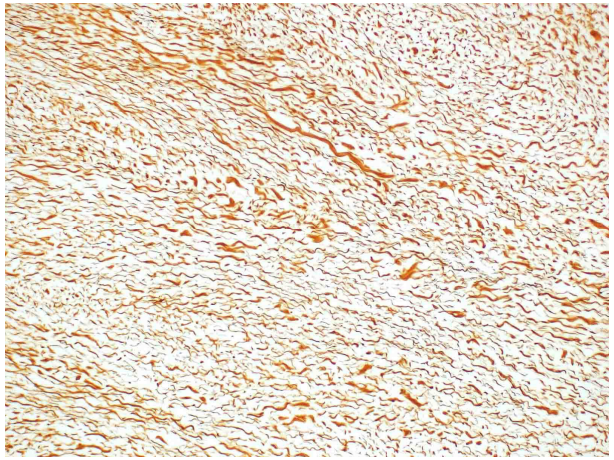

Nevoid basal cell carcinoma syndrome - take home messages

1. In young patients with bilateral, multinodular and/or heavily calcified ovarian fibromas: comment on the potential benefit of genetic counseling concerning this syndrome
2. No specific IHC features suggestive of this syndrome

Conclusion

- Recognition of the distinct features of tumors associated with hereditary syndromes with comments on potential benefit from genetic counseling - sentinel cancer!
- Screening (problems with indication and reimbursement)
- Examination of prophylactically removed specimens (adhere to the guidelines for processing, if available)

- Knowledge of familial syndromes and related tumors is essential