Epithelial neoplasia
Case 8

Pavel Dundr

Department of Pathology, 1st Faculty of Medicine Charles University and General University Hospital in Prague



History

- 28-year-old female
- Unilateral ovarian tumor ("Cyst of the right ovary")
- Referee pathologist's diagnosis: mucinous ovarian carcinoma
- Second opinion requested

- No other pathological or clinical data



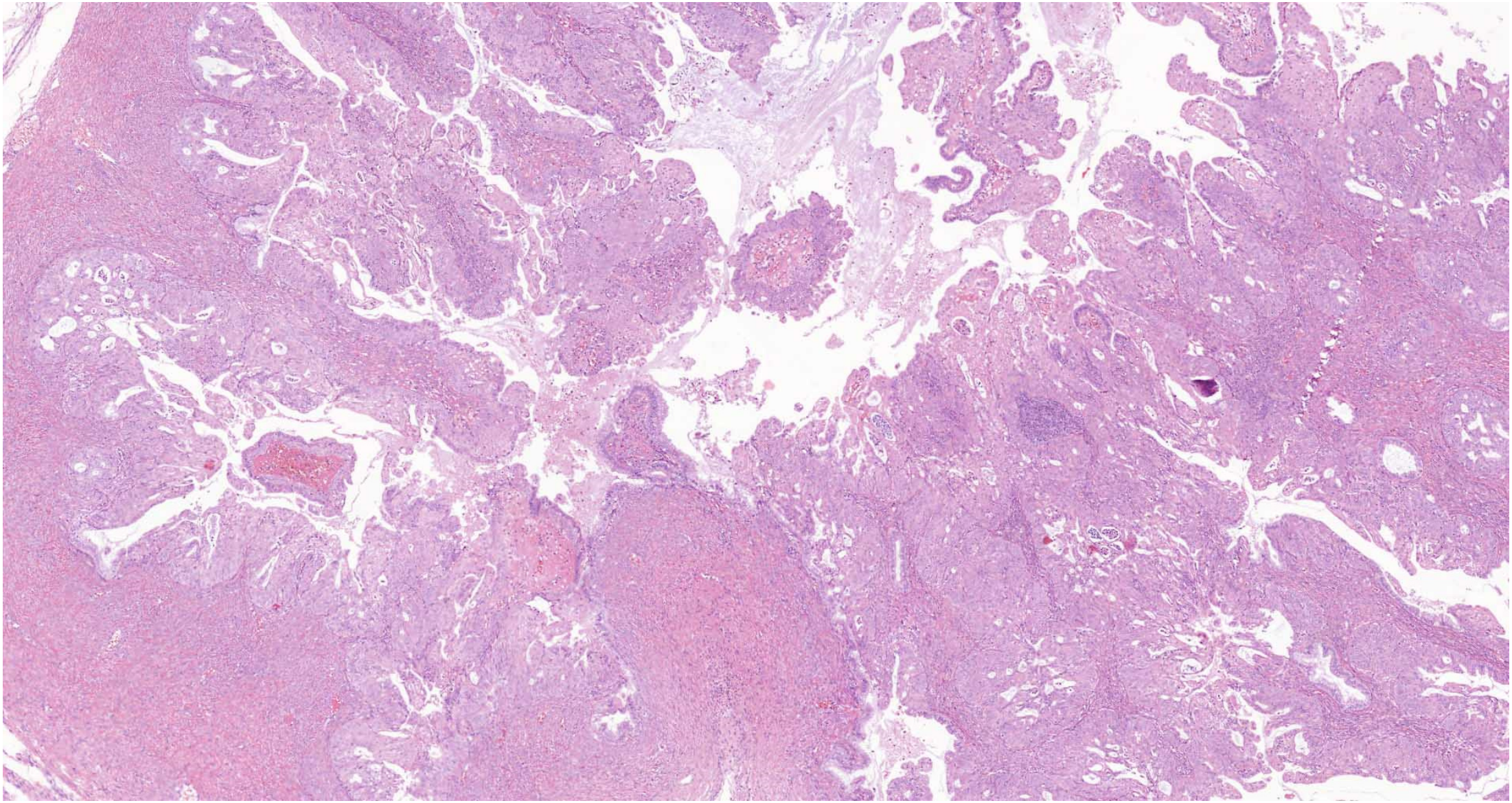

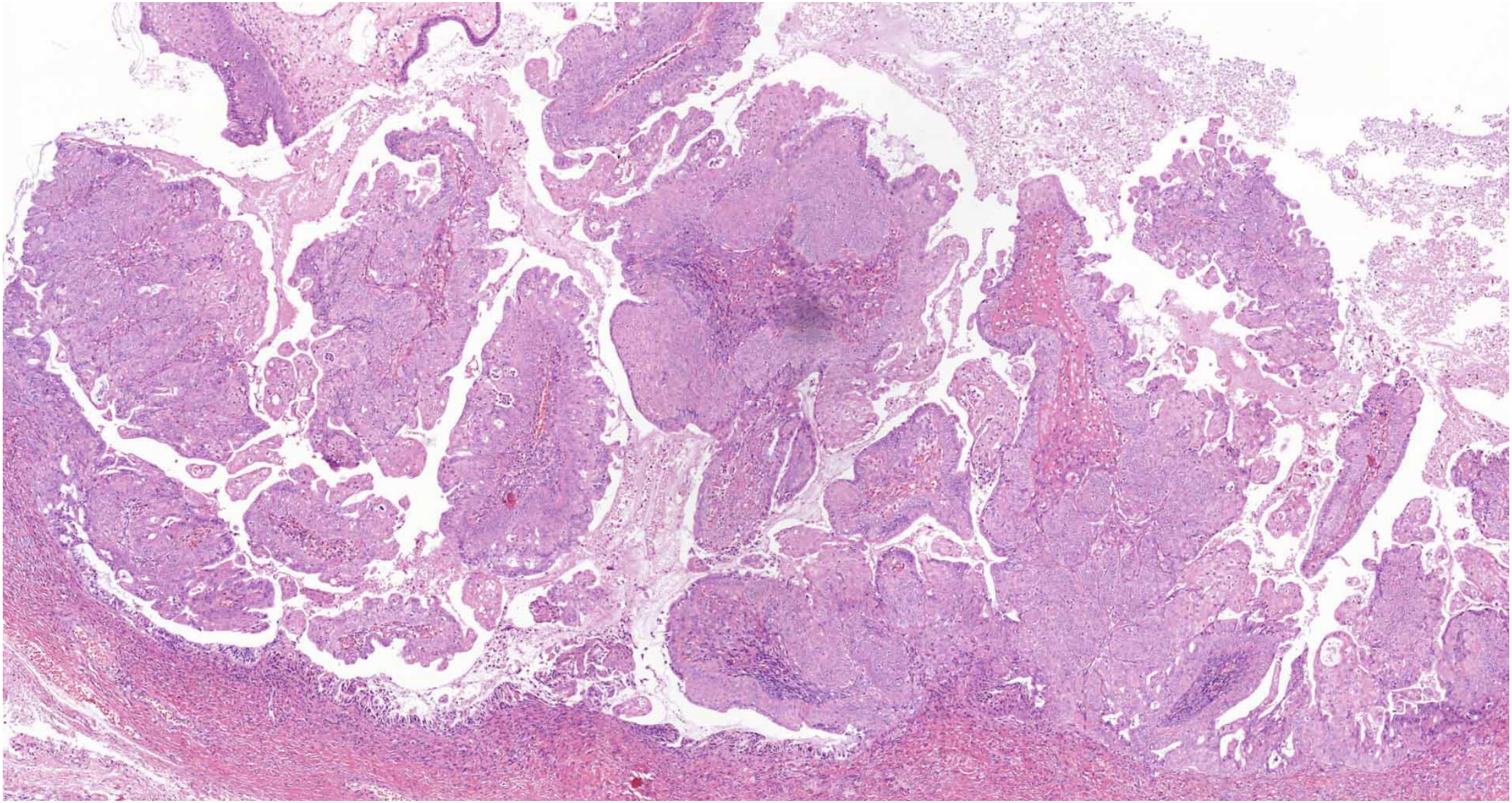

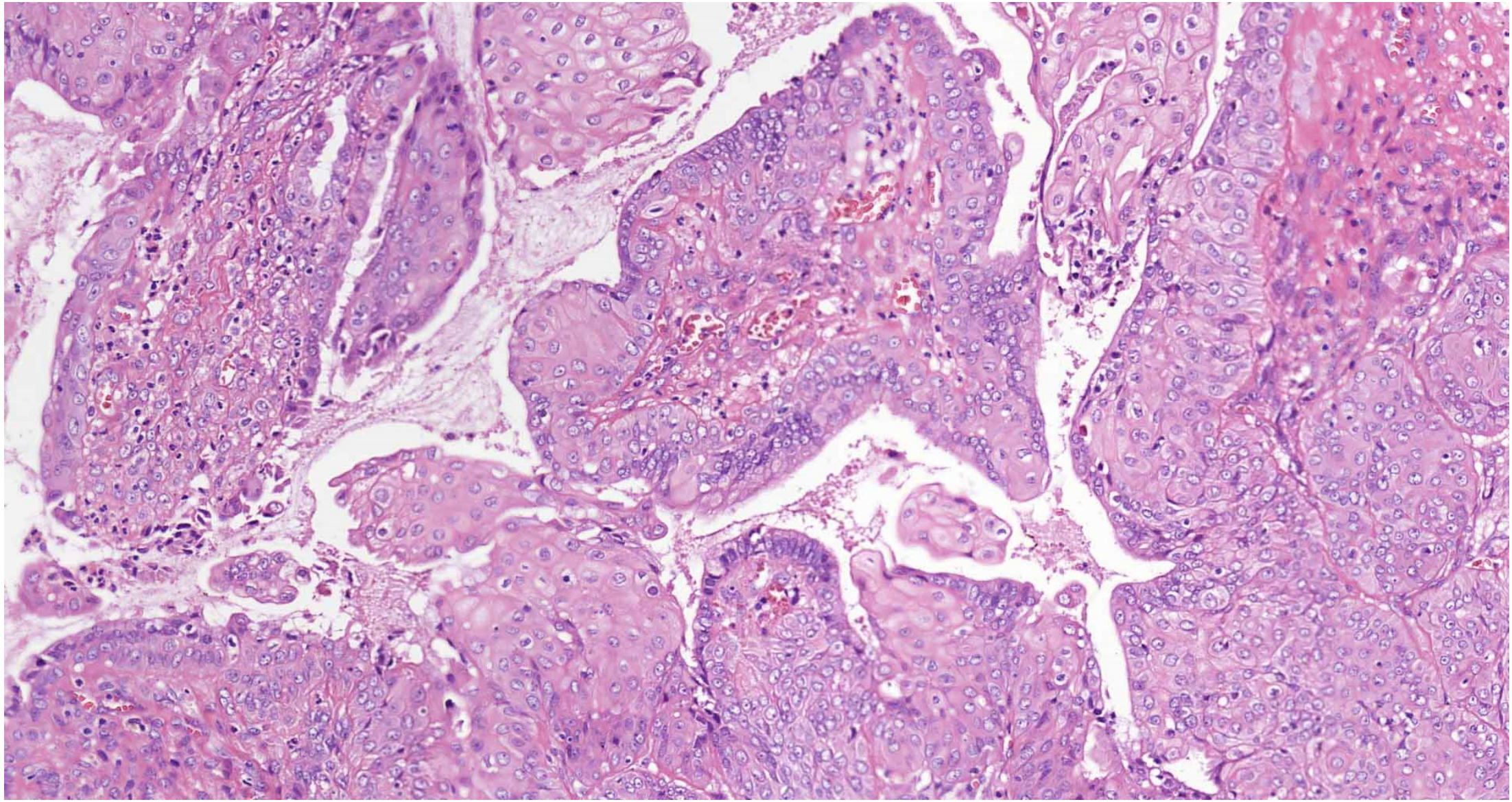

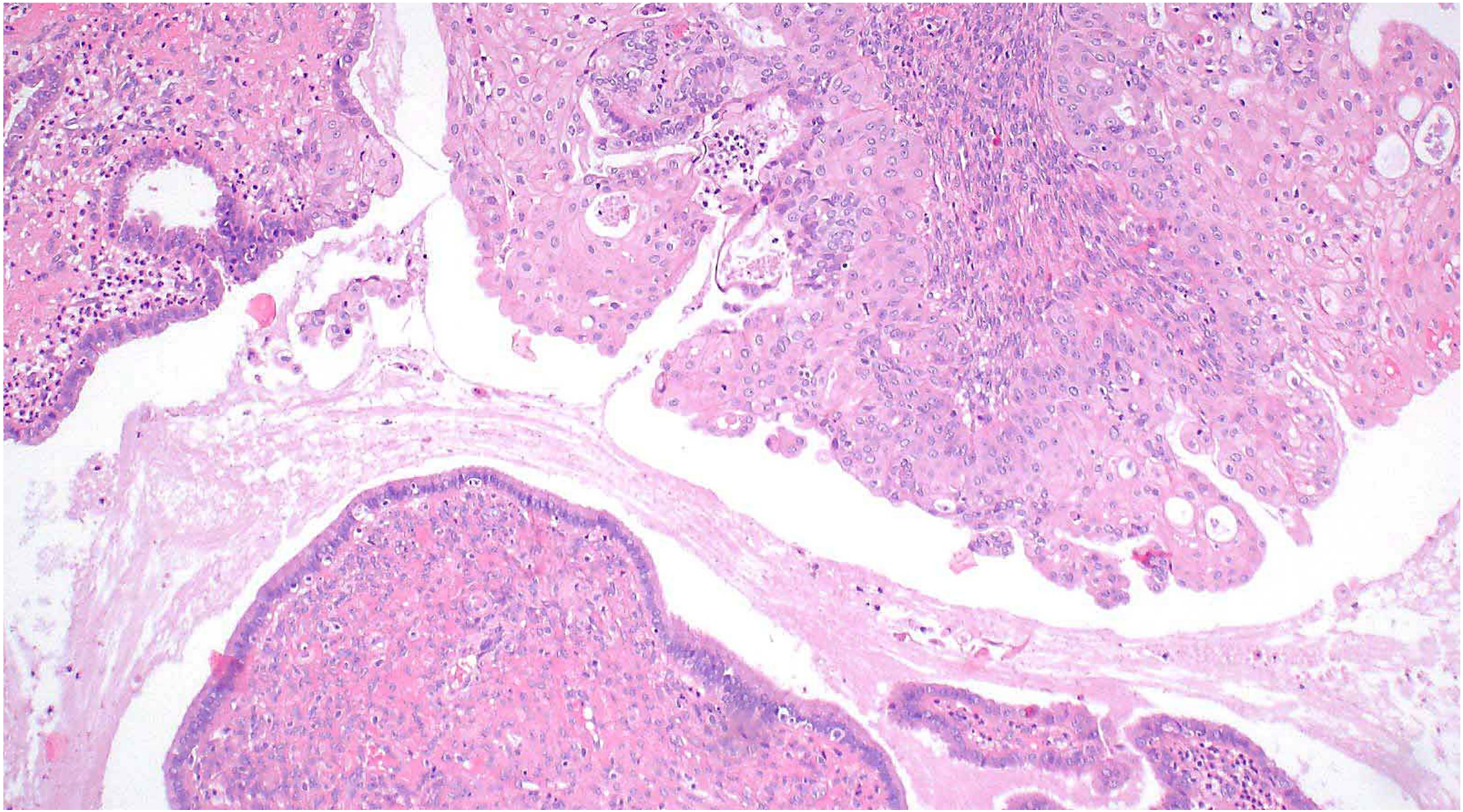

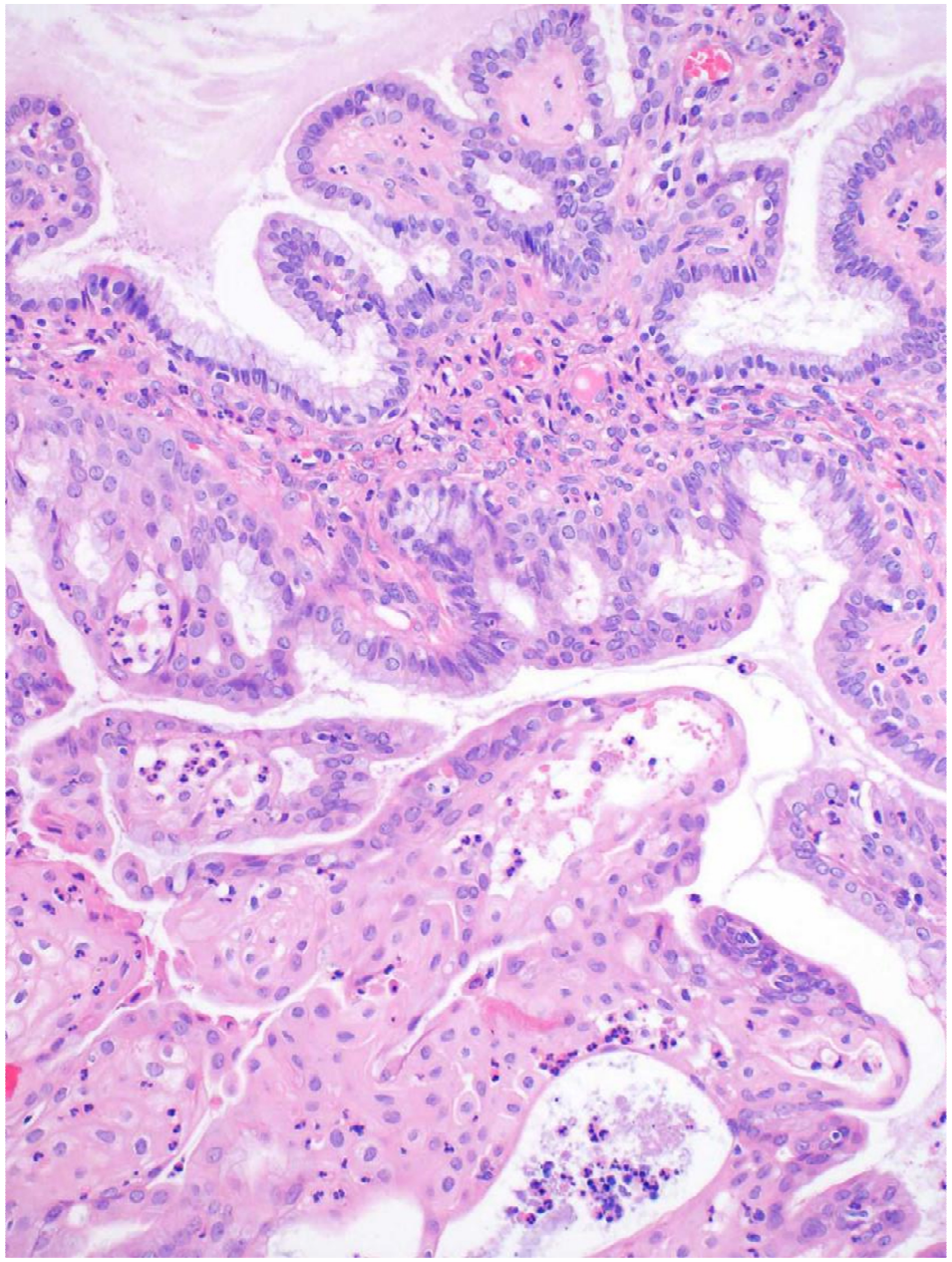

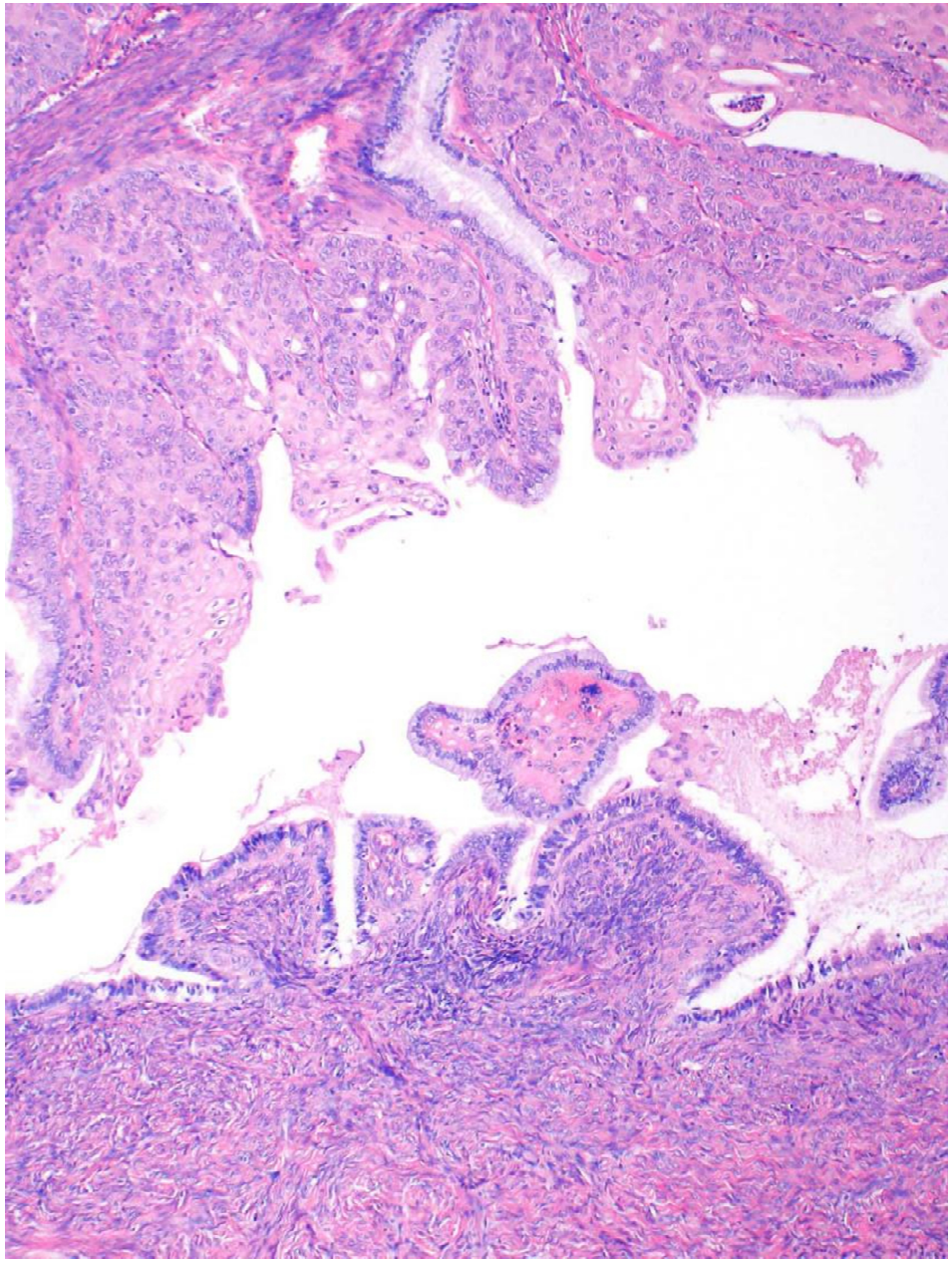

Diagnosis?

Immunohistochemical findings

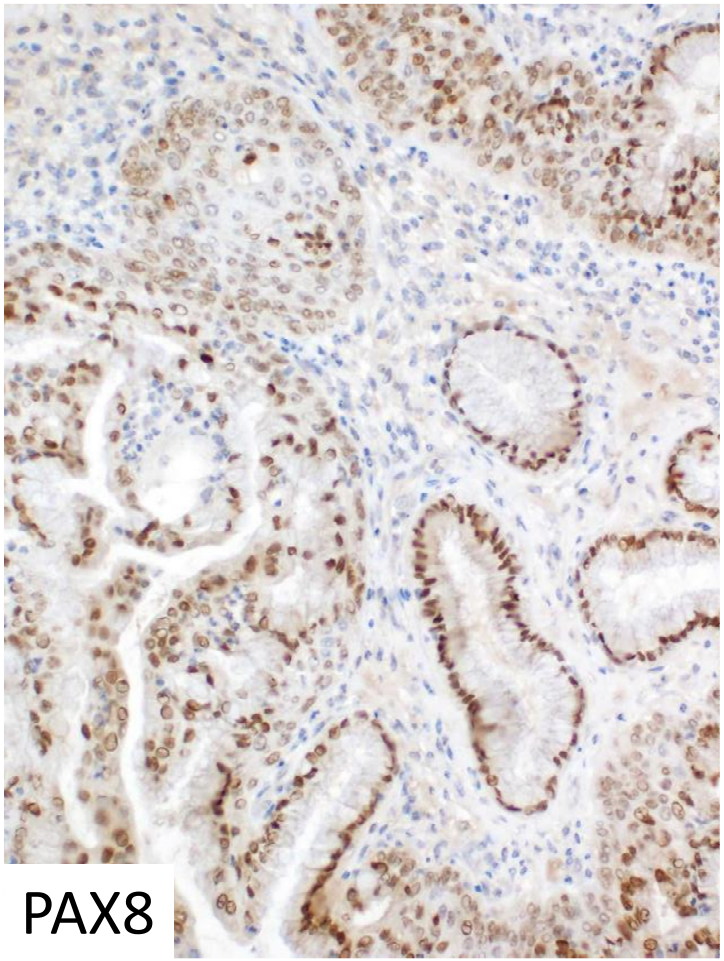

PAX8

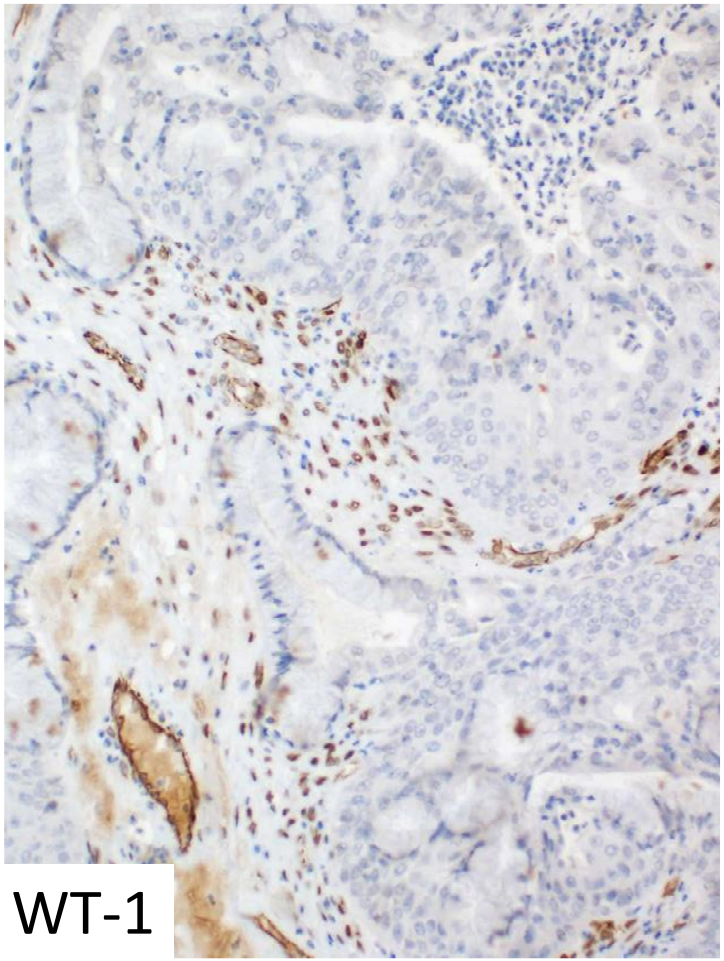

WT-1

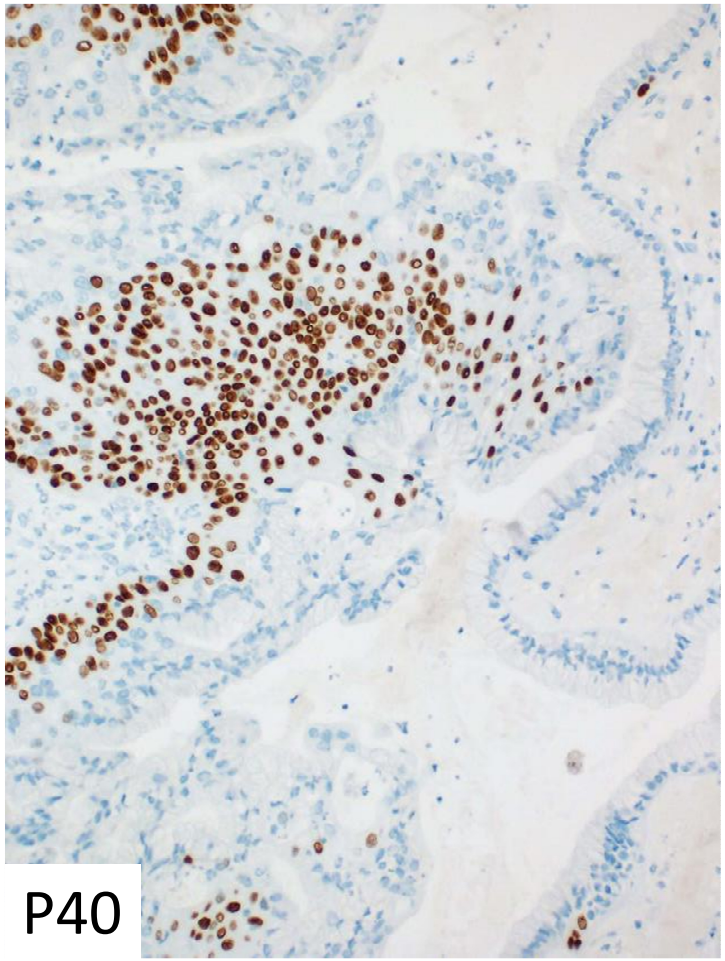

P40

Immunohistochemical findings

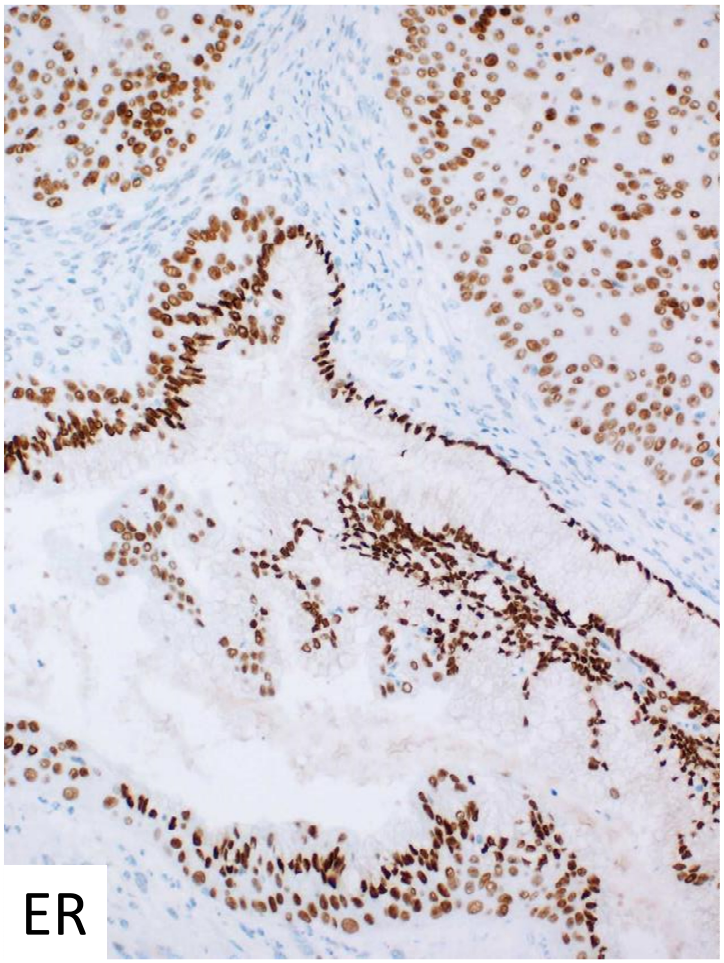

ER

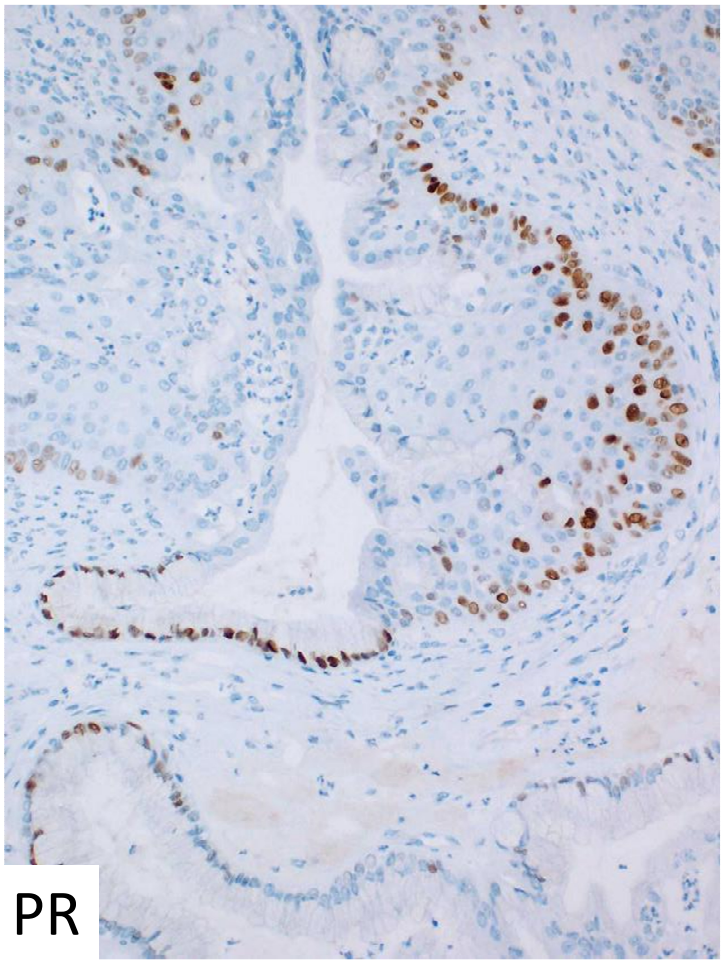

PR

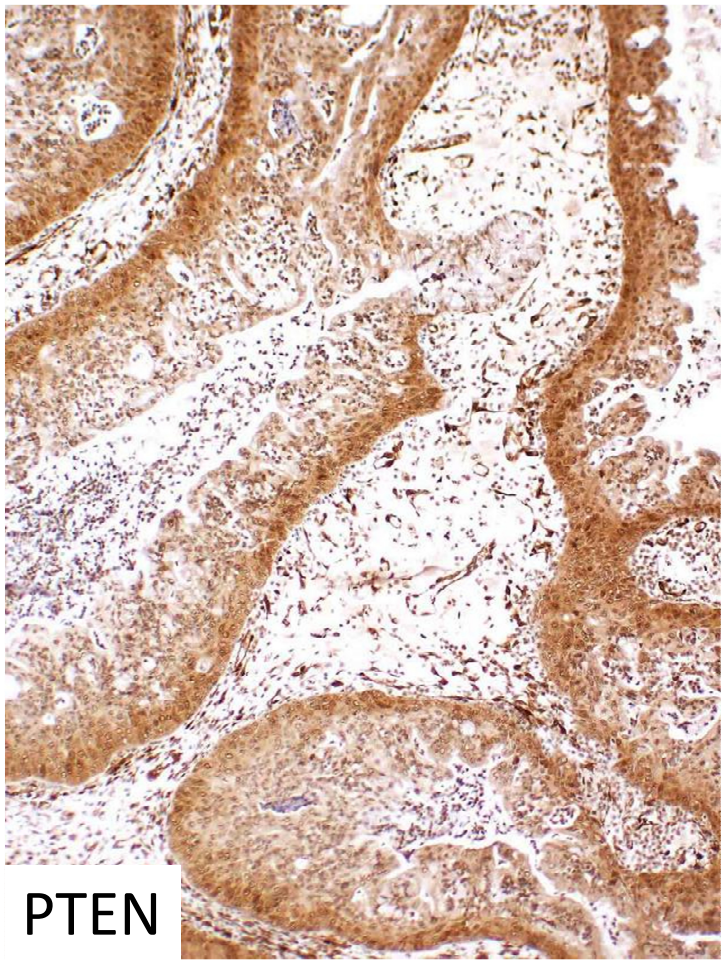

PTEN

Immunohistochemical findings - summary

	Glandular	Squamous
PAX8	+++	++
WT-1	-	-
ER	+++	+++
PR	+	+
P60	-	++
P40	-	++
PTEN	+++	+++
ARID1A	+++	+++
Ki-67	< 3 %	25%

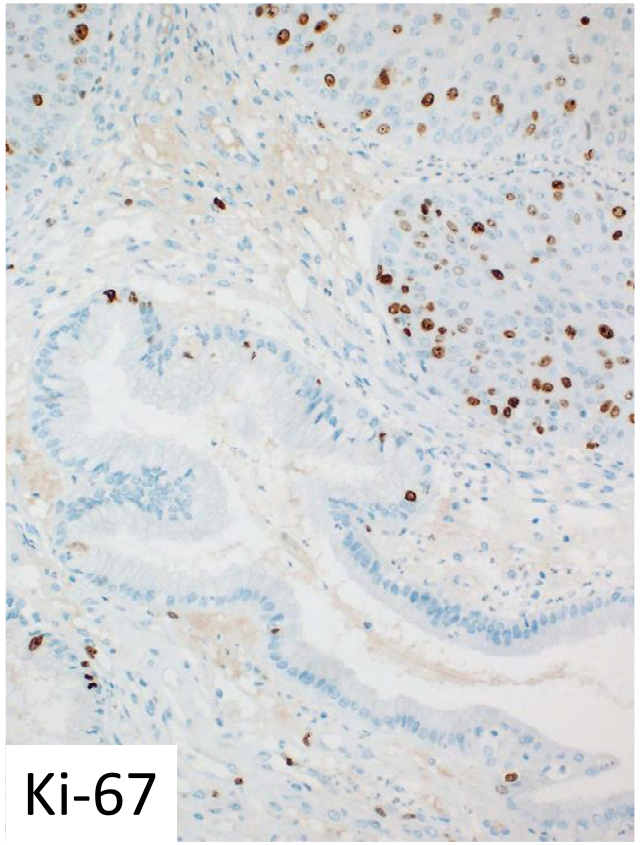

Ki-67

Diagnosis?

Müllerian mucinous borderline tumor with extensive squamous differentiation

Seromucinous borderline tumor

Endocervical-type mucinous borderline tumor

Mixed cell type borderline tumor

Müllerian mucinous borderline tumor with extensive squamous differentiation

- 2003 – "MEBMMSO (mixed-epithelial papillary cystadenoma of borderline malignancy with squamous overgrowth)"; 4 cases
- 2018 – "Ovarian borderline mucinous tumor with squamous overgrowth"; 1 case

Nagai Y, et al. Am J Surg Pathol. 2003;27(2):242-7.
Vasudevan G, et al. Indian J Pathol Microbiol. 2018;61(2):261-263.

Differential diagnosis

- Squamous cell carcinoma arising in a BTO (1 case reported in the literature) or a cystic mucinous teratoma (1 case reported in the literature)
- Ovarian carcinoma of another type (?)
- Prominent squamous diffrentiation described in a one case of seromucinous carcinoma
- Brenner borderline tumor / malignant Brenner tumor

Baughn MR et al. Ann Diagn Pathol. 2011;15(6):446-9.
D'Angelo E, et al. Int J Gynecol Pathol. 2010;29(6):529-32.
Taylor J, McCluggage WG. Am J Surg Pathol. 2015;39(7):983-92.

Conclusions

- Squamous cell differentiation may be present in several tumor cell types, especially endometrioid and mixed (seromucinous)
- This component may rarely predominate ("squamous cells overgrowth")
- May be present in benign, borderline and malignant tumors
- Should be distinguished from pure squamous tumors or tumors with a different differentiation (Brenner tumors)

Epithelial neoplasia
Case 9

Pavel Dundr

Department of Pathology, 1st Faculty of Medicine Charles University and General University Hospital, Prague



History

- 55-year-old female
- Unilateral ovarian tumor
- **Referee pathologist's diagnosis**: ovarian tumor, looks like Sertoli-Leydig cell tumor, but the immunophenotype is not supportive of this possibility
- **Second opinion**: Tumor of uncertain histogenesis, Müllerian origin possible but the IHC profile is not typical, metastasis cannot be excluded
- Request for a „third opinion" („Ovarian tumor of uncertain histogenesis")

- No other pathological or clinical data

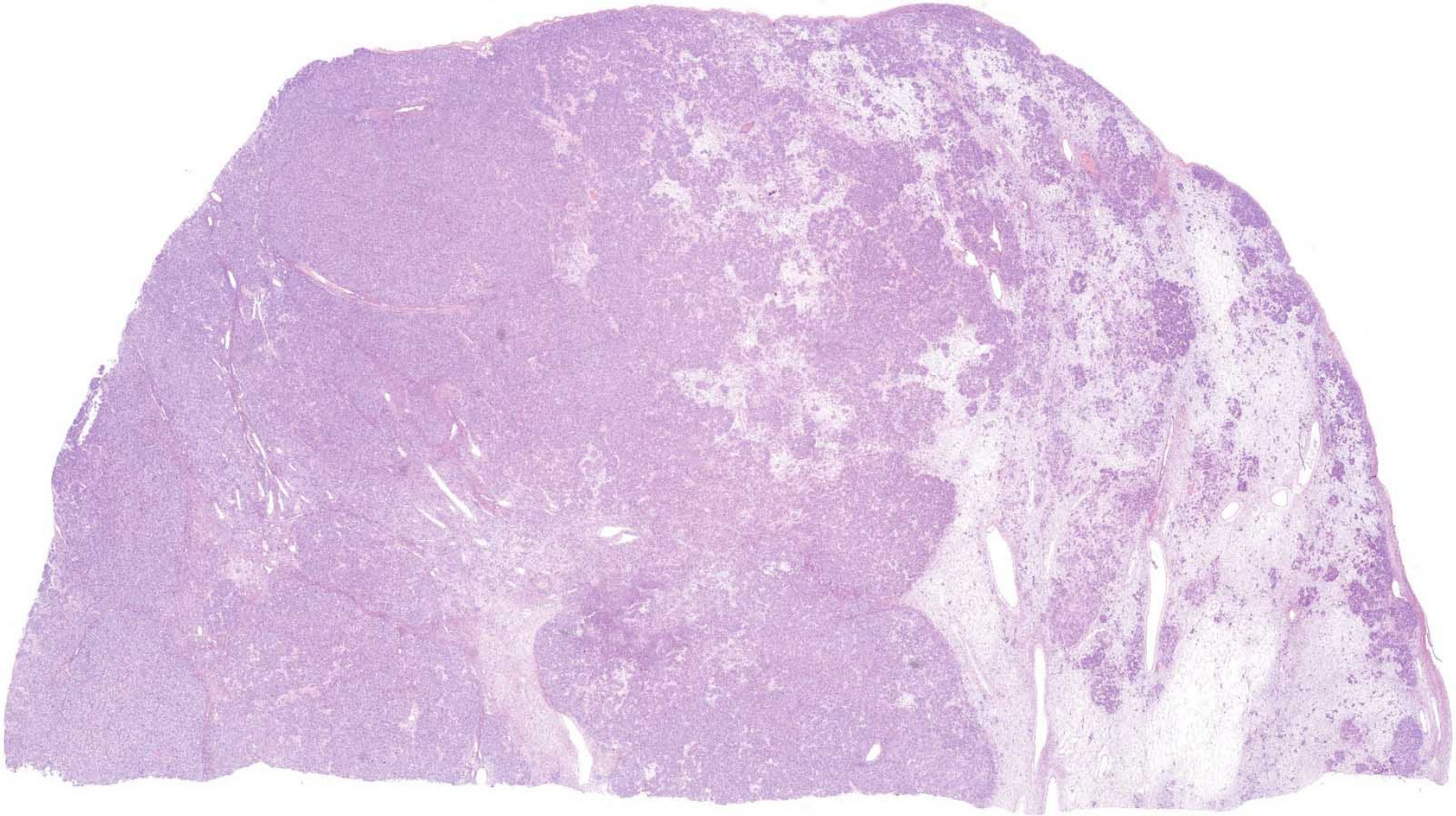

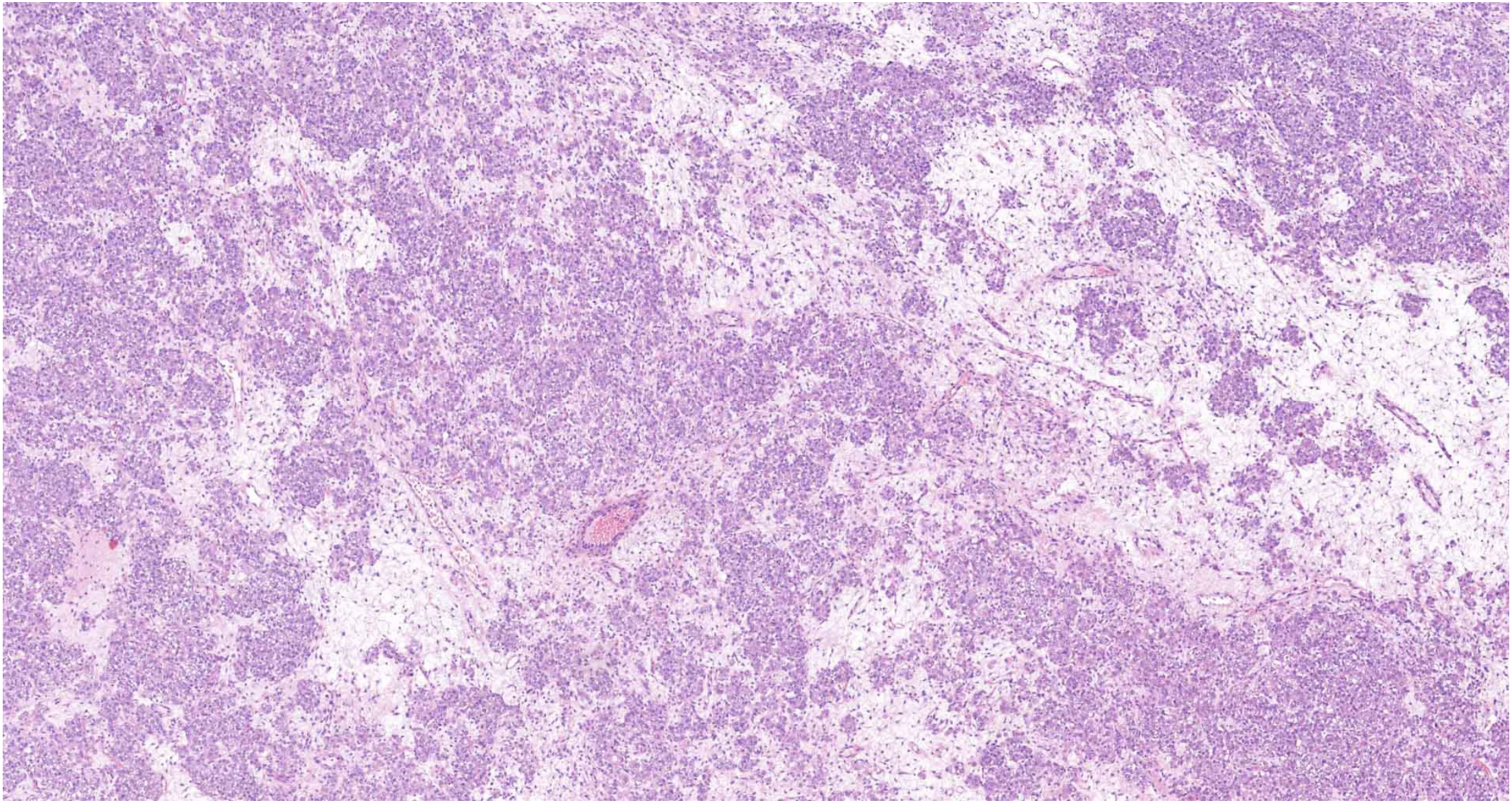

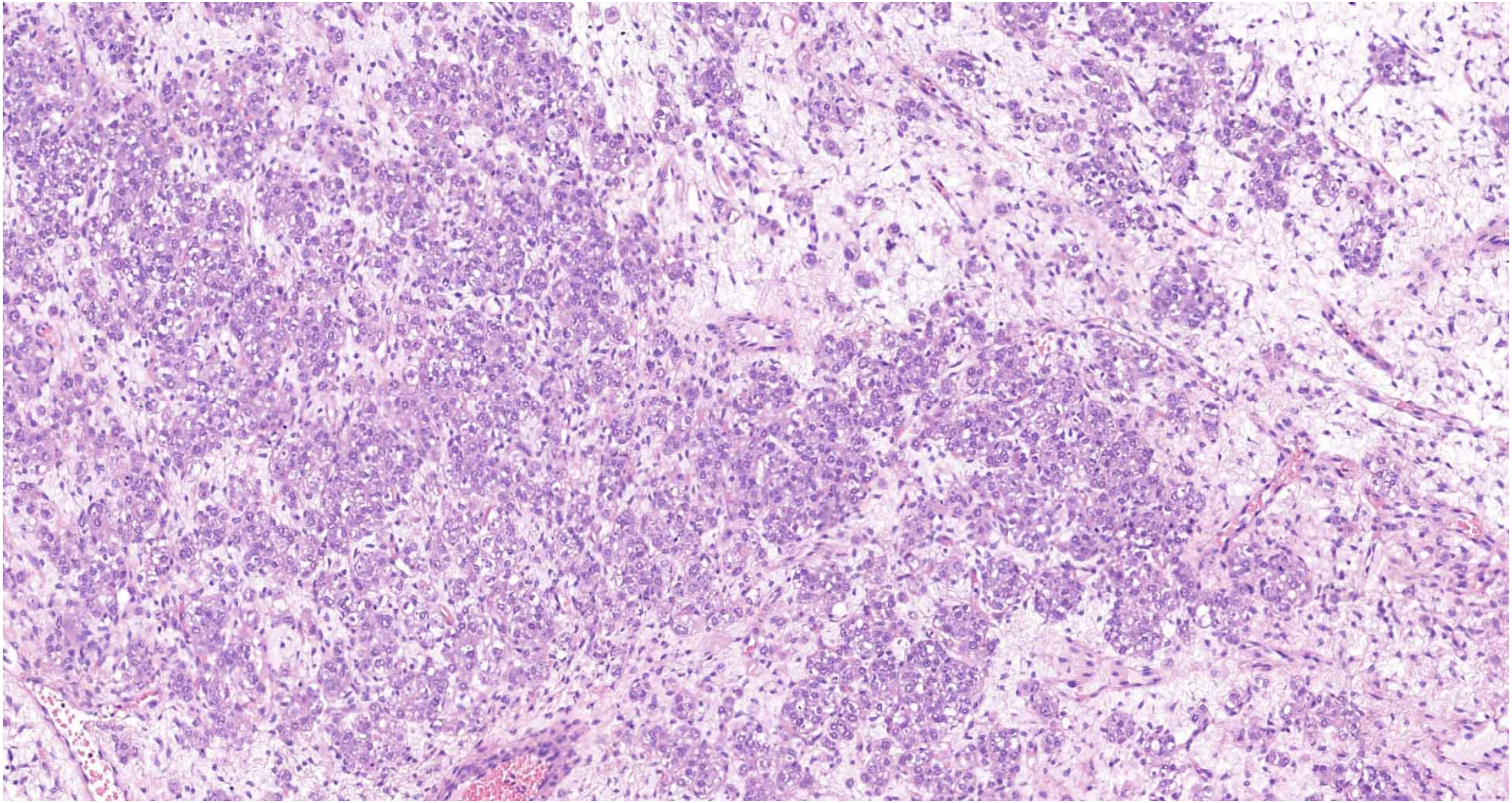

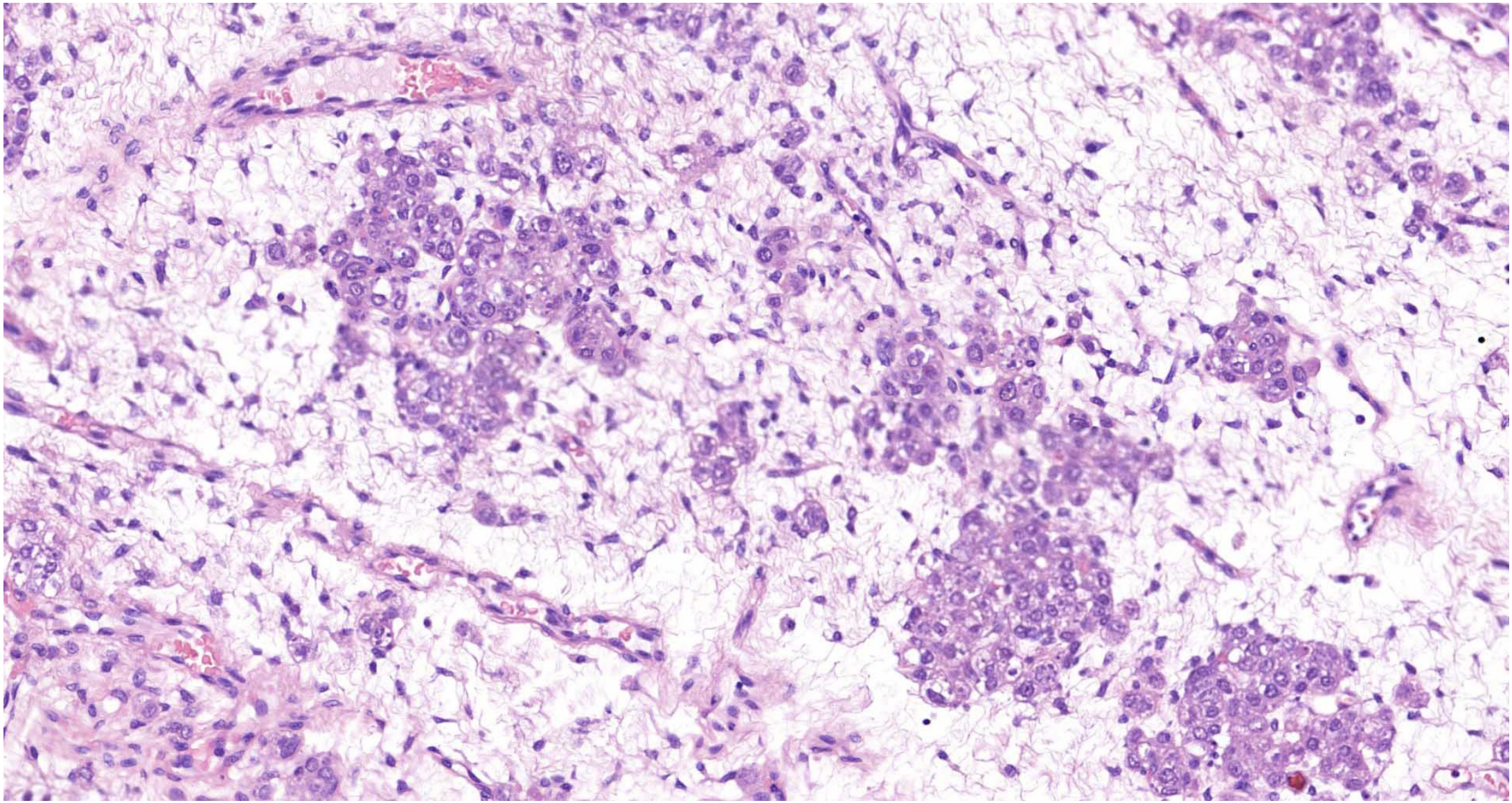

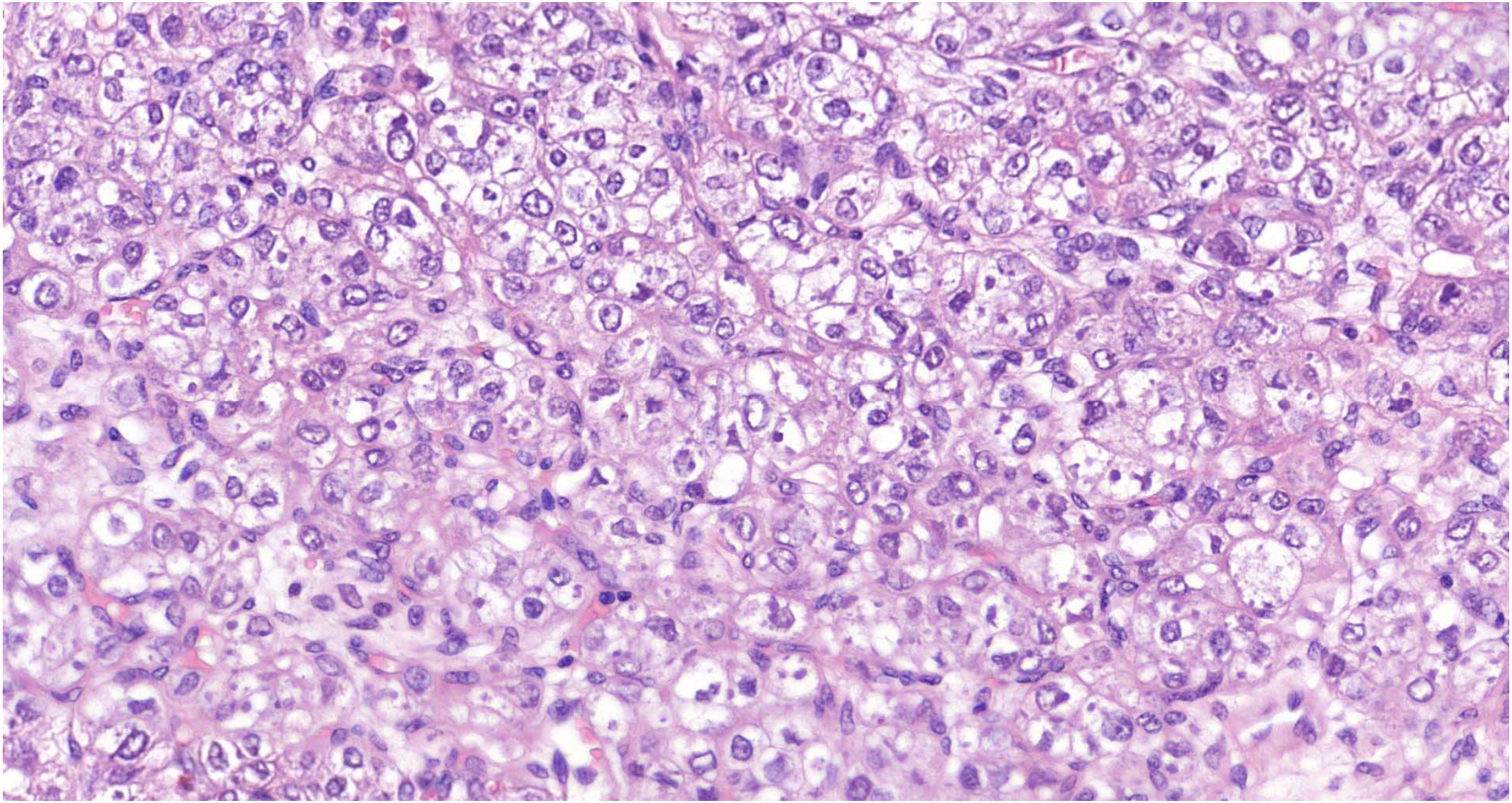

Diagnosis?

Immunohistochemical findings

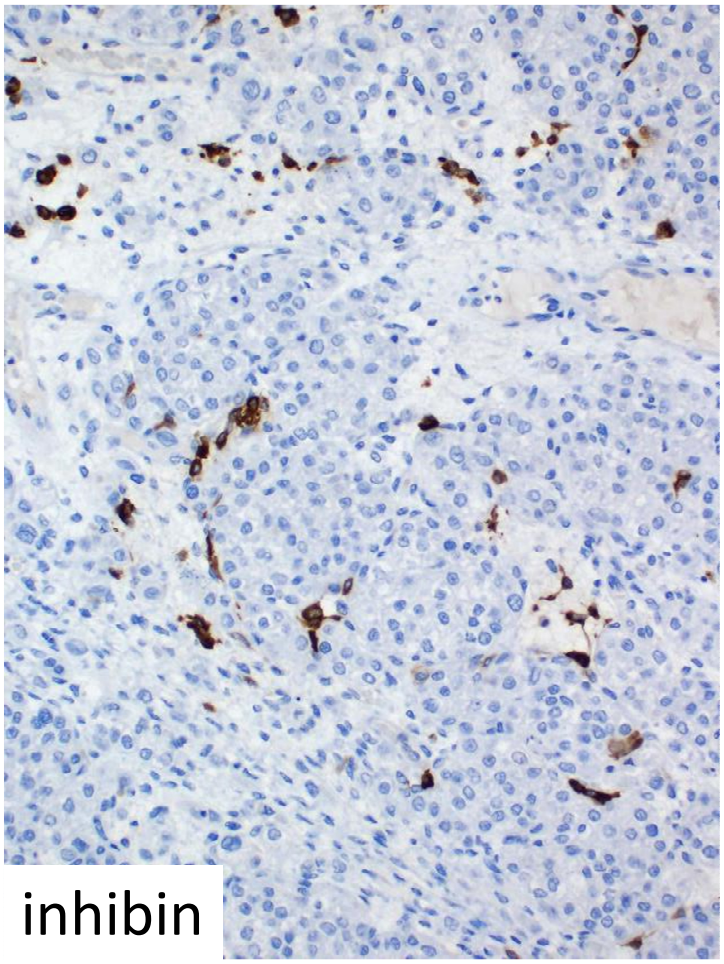

inhibin

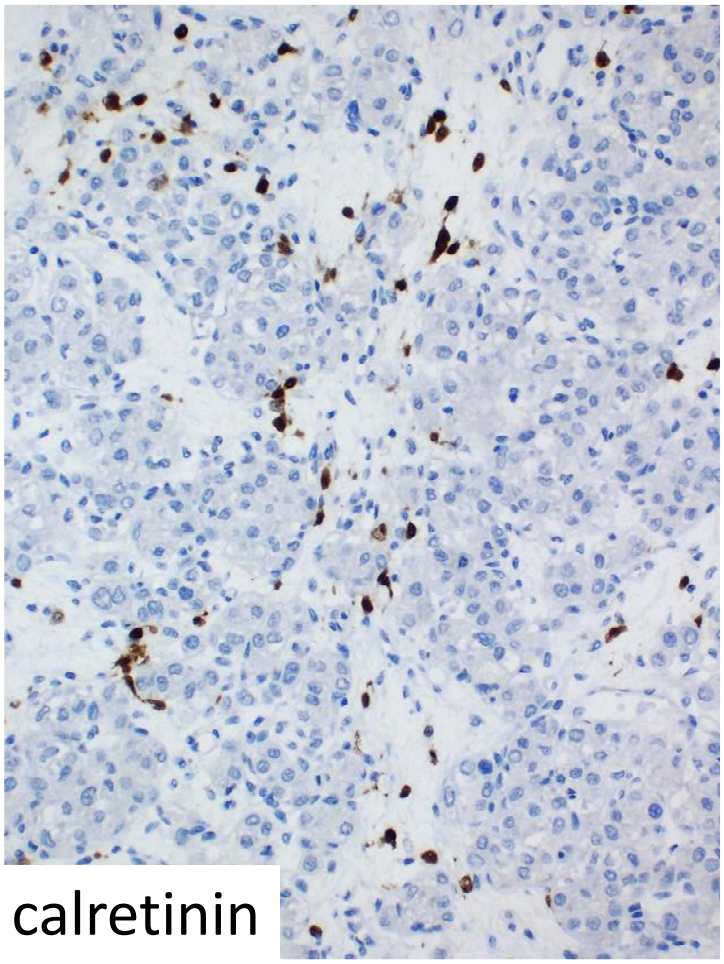

calretinin

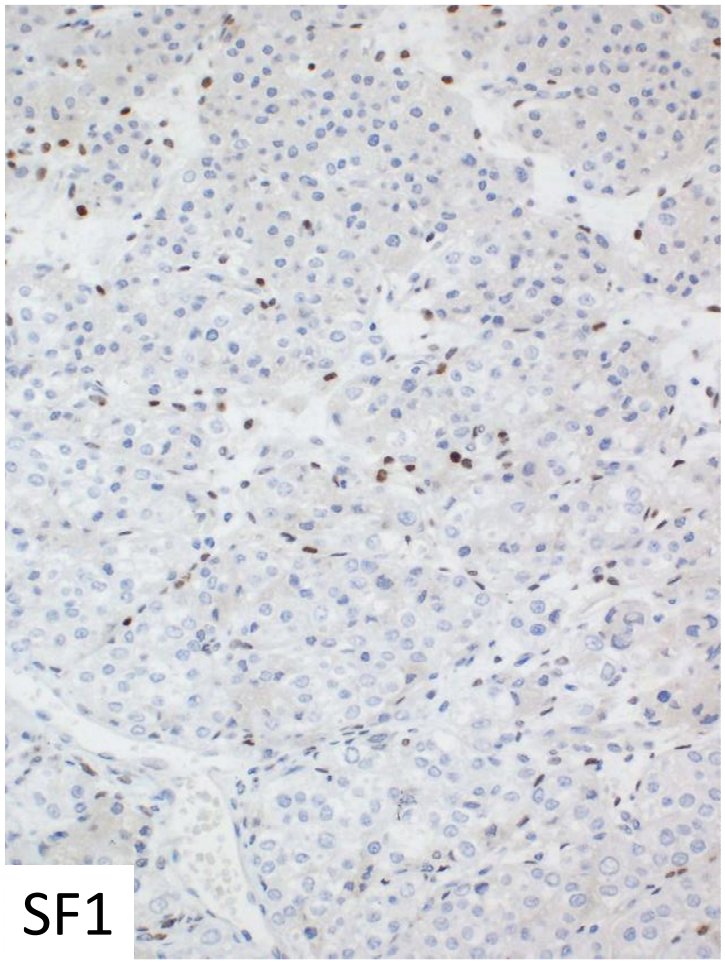

SF1

Immunohistochemical findings

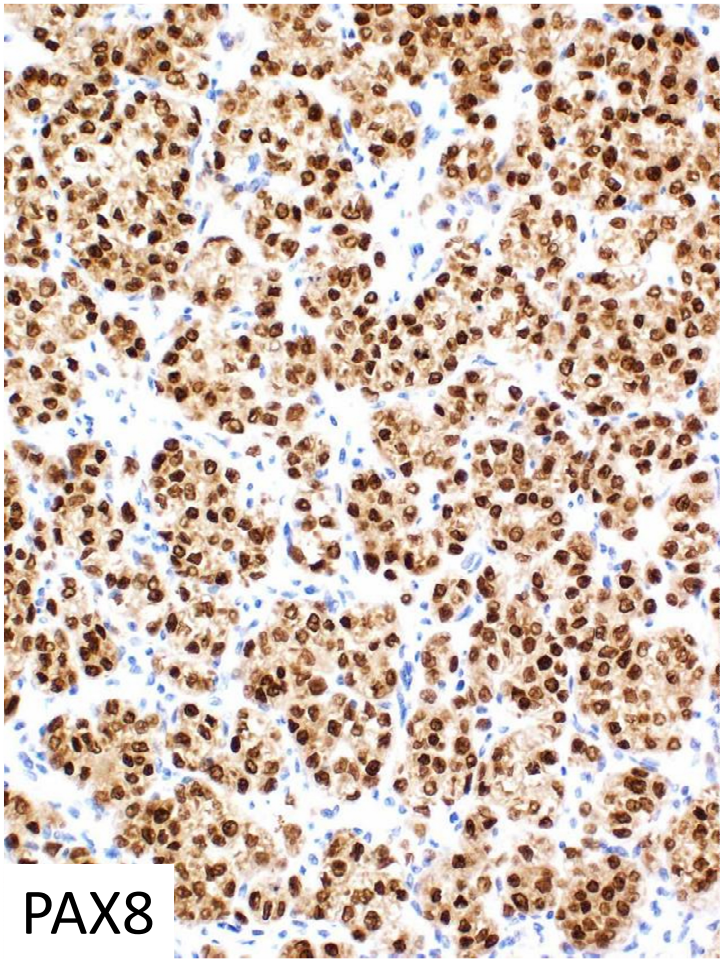

PAX8

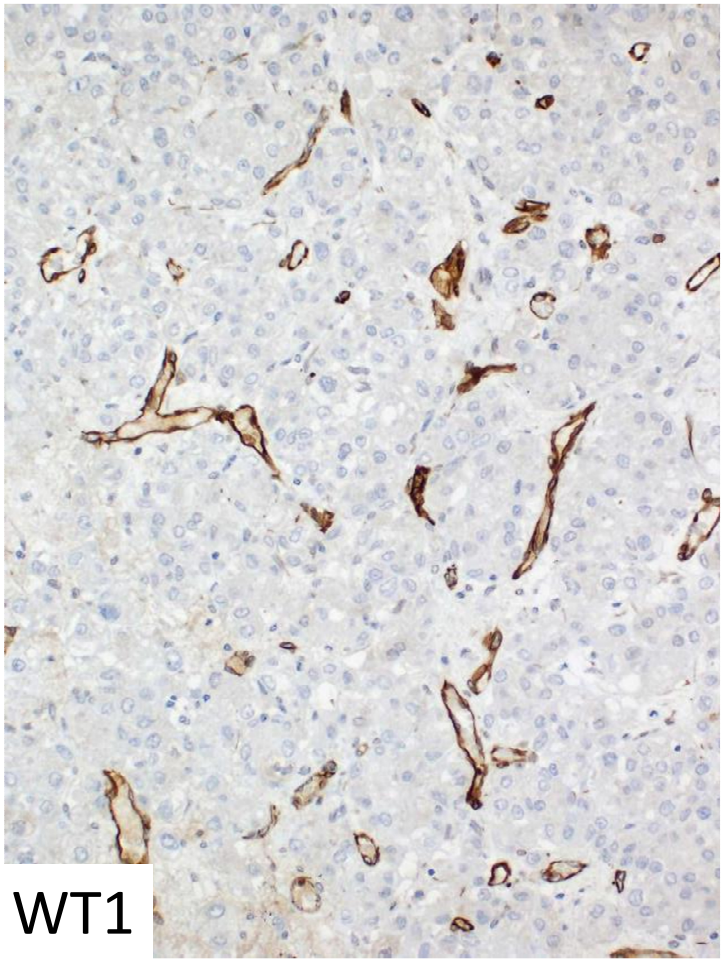

WT1

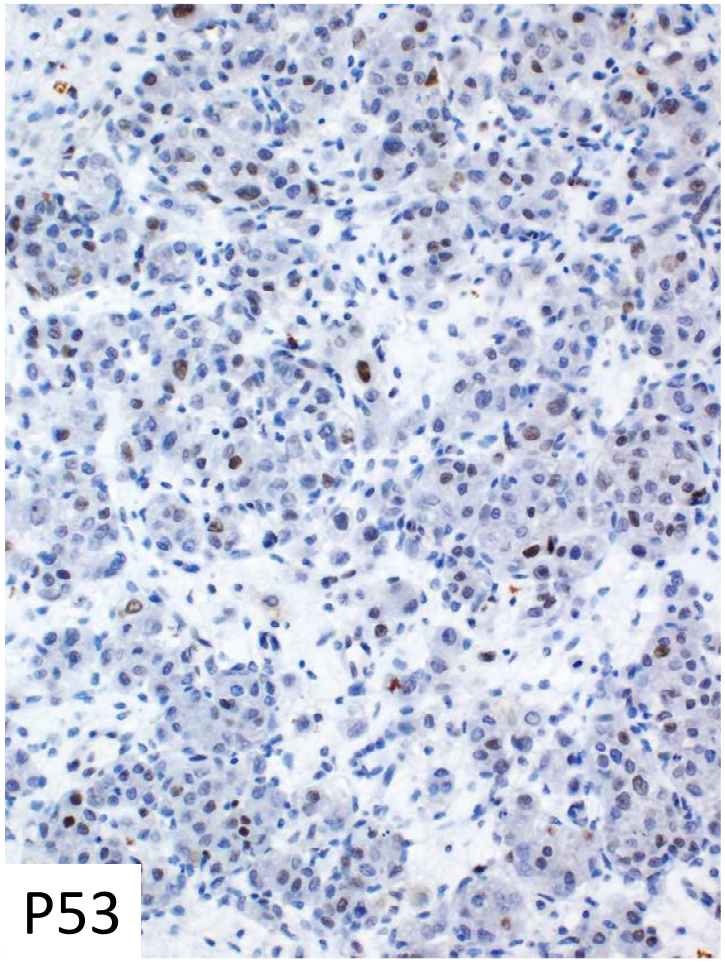

P53

Immunohistochemical findings

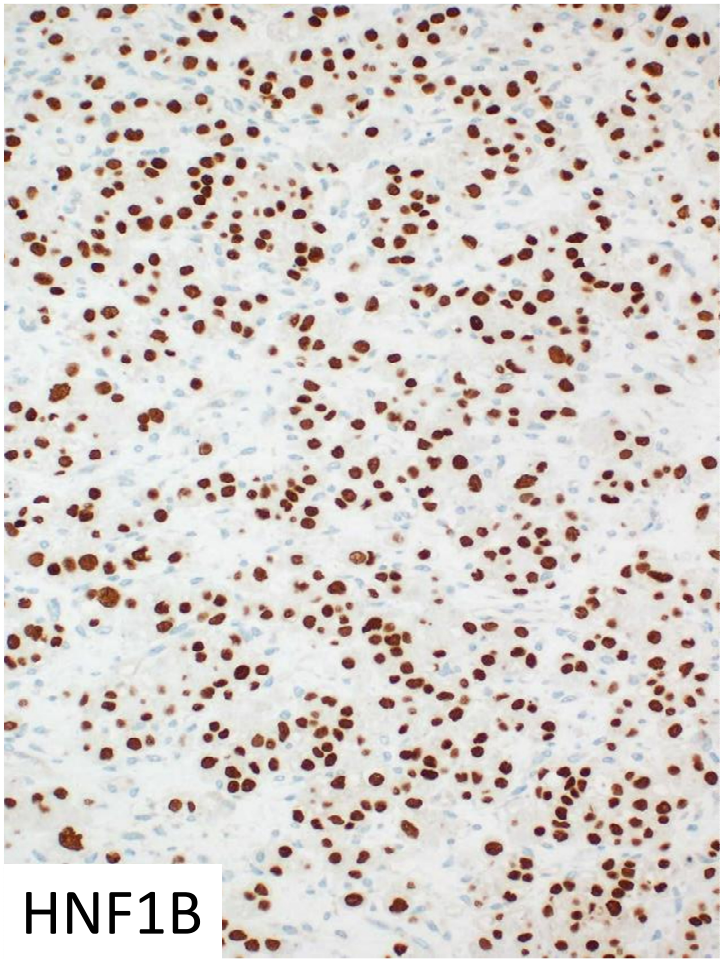

HNF1B

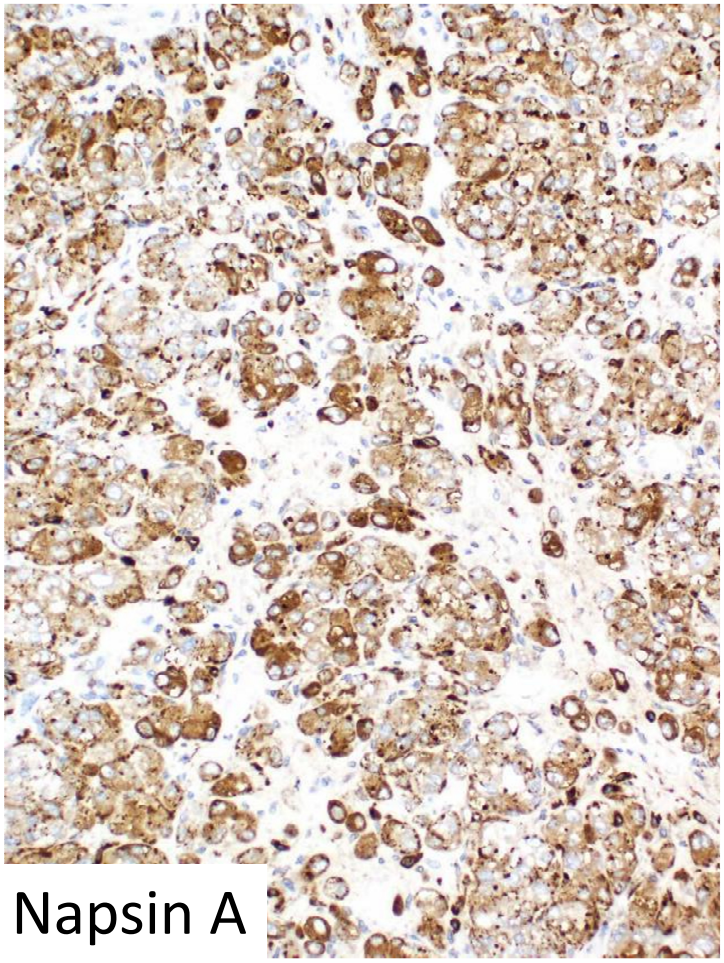

Napsin A

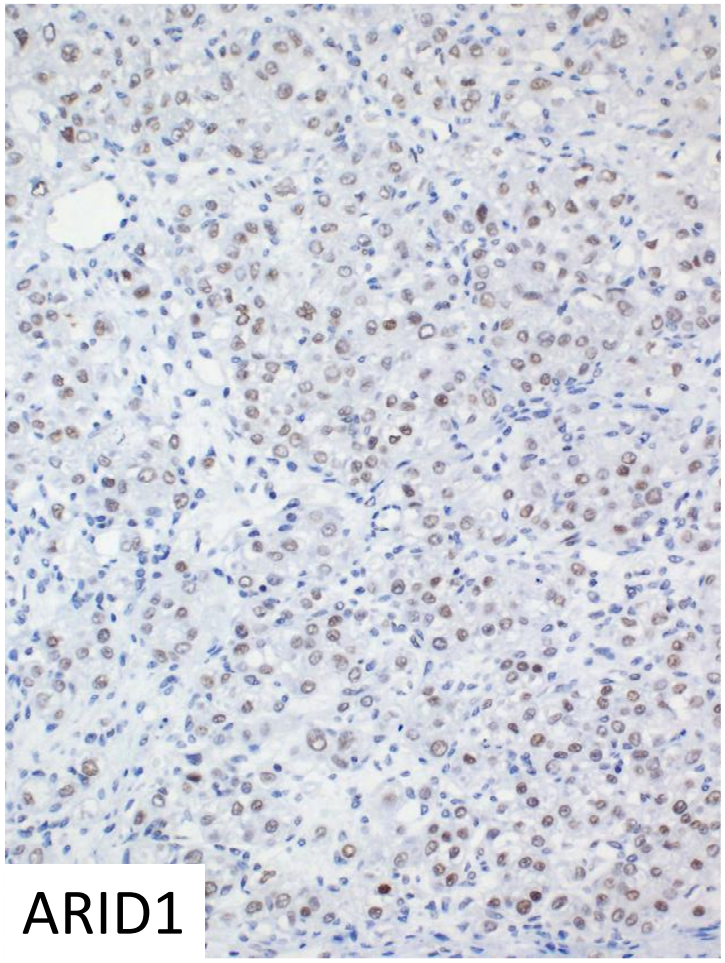

ARID1

Immunohistochemical findings - summary

Positive	Negative	Other	
PAX8	SF1	P16	"mosaic"
HNF1B	WT1	P53	wt
Napsin A	inhibin	Ki-67	20% (60% hot spots)
ARID1A	calretinin		
cytokeratin 7	ER		
CK AE1/3	PR		
	RCC		
	chromogranin		
	synaptophysin		
	S100		
	melan A		
	CD56		

Diagnosis?

Clear cell carcinoma of the ovary

Clear cell carcinoma of the ovary

- **Gross features**
  - usually unilateral, mean size of 15 cm (up to 30 cm)
  - solid – solid/cystic – cystic

- **Microscopy**
  - tubulocystic, papillary, adenofibromatous, solid (usually mixed patterns)
  - cells polygonal, cuboidal, flattened
  - nuclei hyperchromatic, vesicular, prominent nucleoli, most tumors show „hobnail cells“
  - cytoplasm clear to eosinophilic (may be purely eosinophilic)

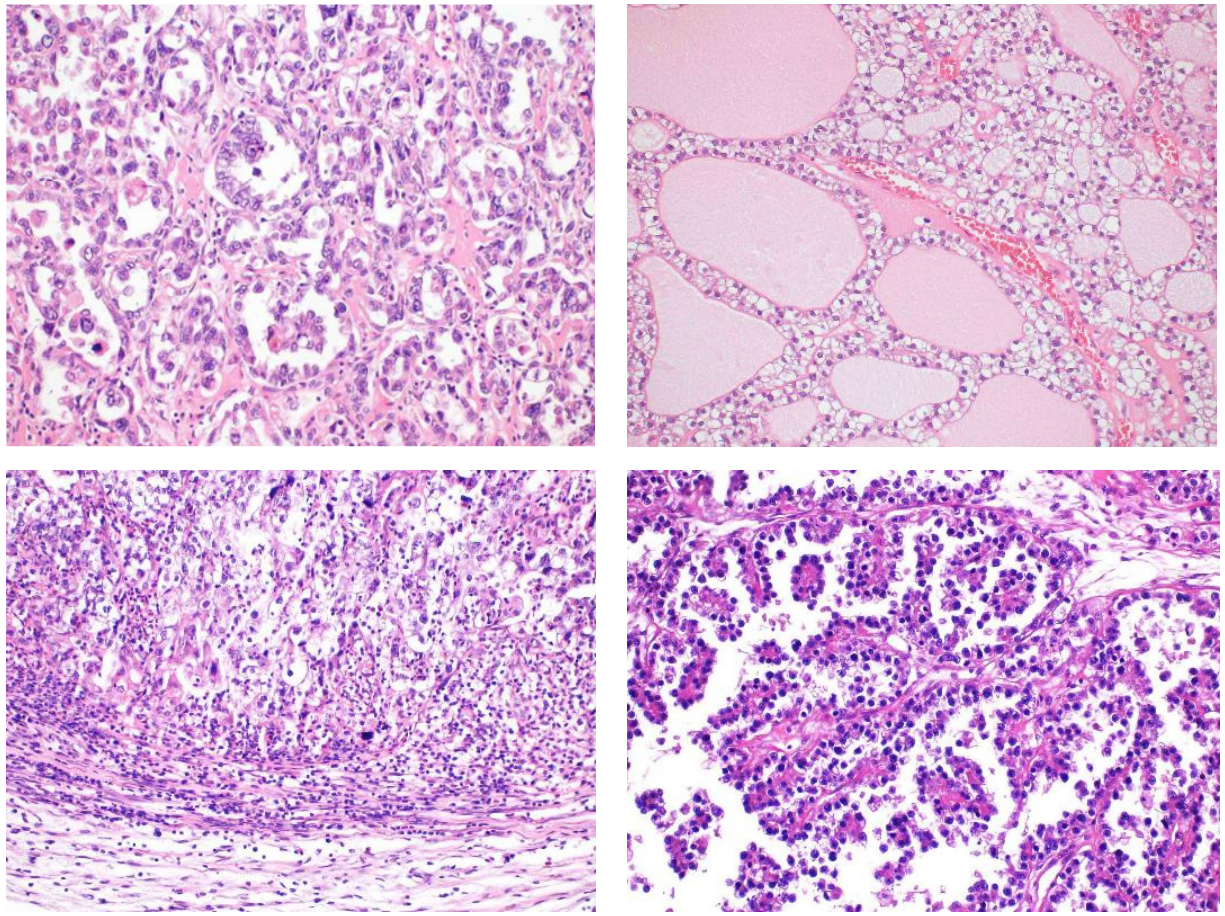

Differential diagnosis

- Germ cell tumors
  - Yolk sac tumor
  - Dysgerminoma
- Serous tumors
- Other tumors with clear cell change
  - endometrioid carcinoma with secretory changes
- Struma ovarii (rarely)
  - cystic follicles
- Sertoli-Leydig cell tumor (solid variant of CCC)

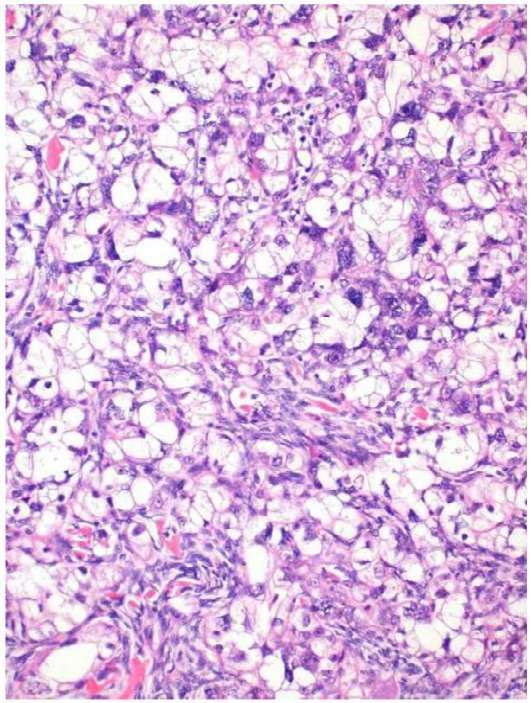

HGSC with clear cell change

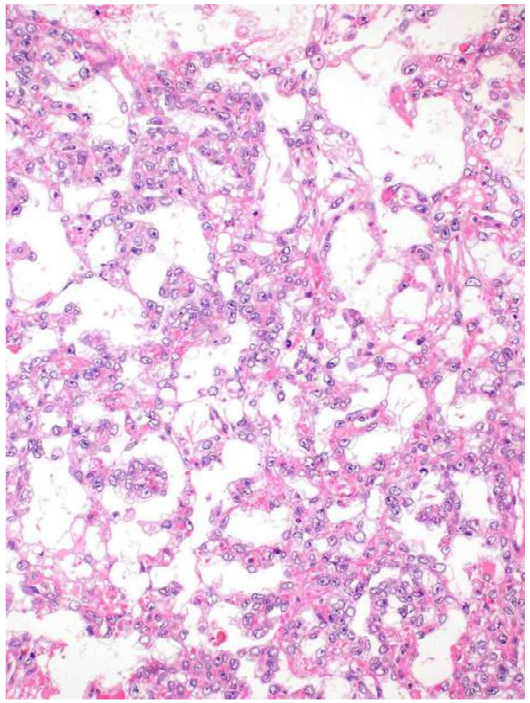

Yolk sac tumor

Conclusion

- Solid arrangement in a clear cell carcinoma may be the only architectural pattern
- Differential diagnosis in these cases may be difficult
- Immunohistochemical examination is necessary