Precursor Lesions Case Presentation

Naveena Singh, Case 1

June 27, 2019

N Singh Case 1: History

- 45F
- Suspicious right ovarian mass.
- CA125 increased – 44; Ca 19-9 increased - 103.
- RSO and biopsies.
- Ruptured before surgery but probably on pelvic examination. ?Malignant, if so re-operate later.

N Singh Case 1: Macro

- Collapsed and ruptured cystic ovarian mass measuring 90 x 60 x 40 mm.
- Normal fallopian tube present externally which measures 60 x 8 mm.
- External surface is otherwise smooth.
- Internal surface shows multiple, delicate, cauliflower-like projections and solid areas altogether measuring 50 x 40 mm with a maximum thickness of 20 mm.

N Singh Case 1: Histology

- High grade adenocarcinoma
- ER and WT1 positive; mutant (null) pattern of p53 expression
- **Fallopian tube examined entirely, and at multiple levels from the fimbrial end, and shows no intraepithelial or invasive carcinoma.**

N Singh Case 1: Completion surgery

- Completion surgery 2 months later
- TAHLSO, omentectomy and peritoneal biopsies

N Singh Case 1: Section from second surgery: TAH LSO

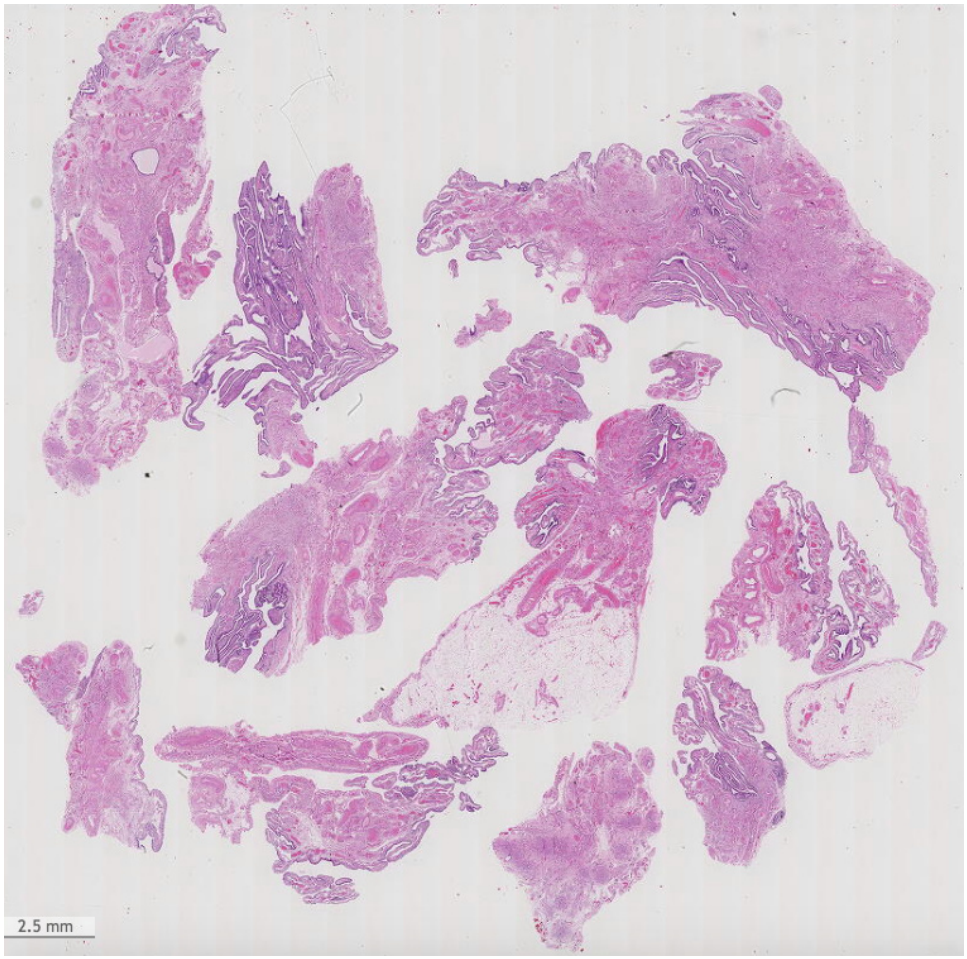

- What is this structure?
- How has it been sectioned?



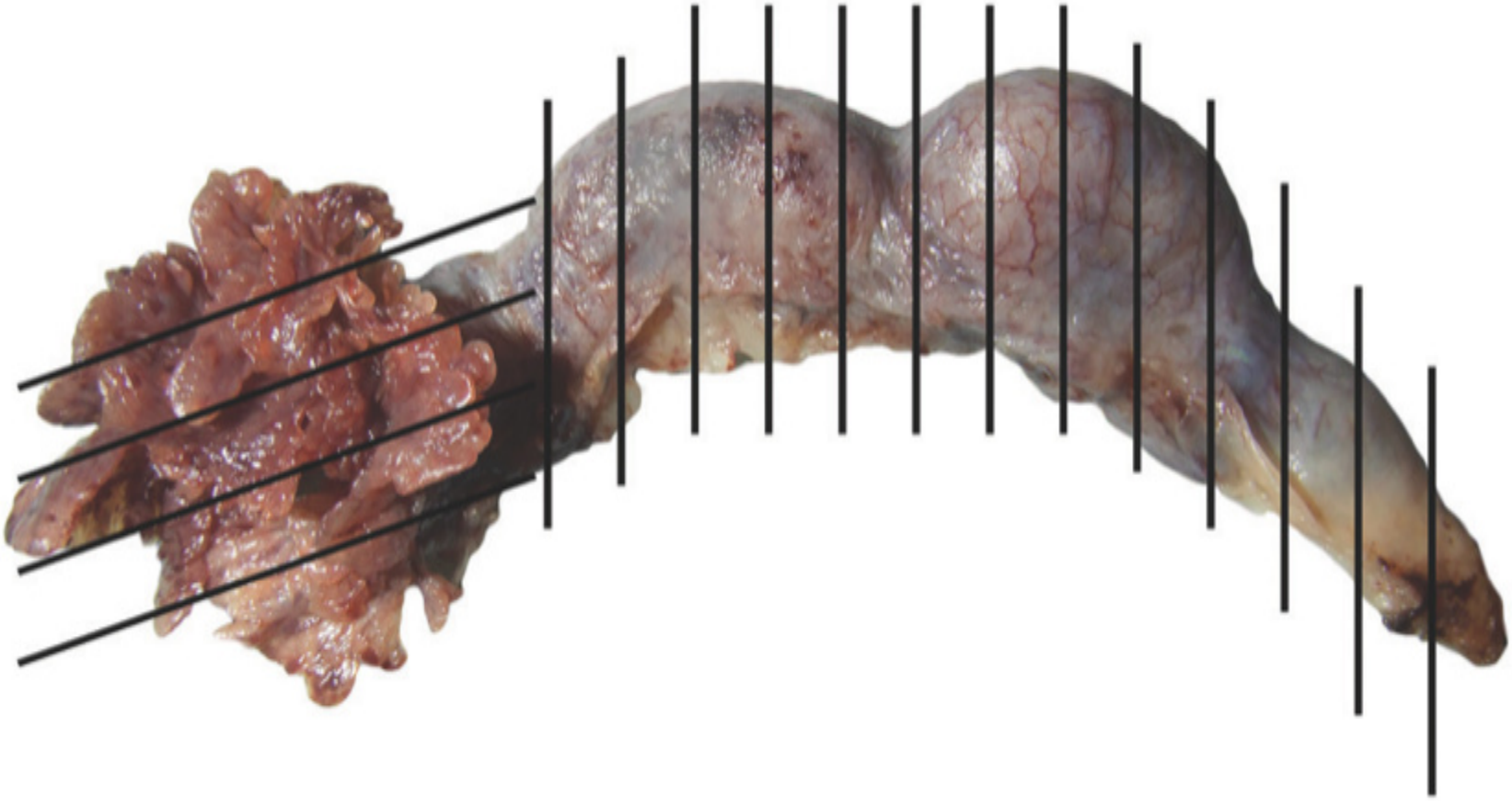

Sectioning and Extensively Examining the FIMbriated end of the FT: SEE-FIM

N Singh Case 1: Section from second surgery: TAH LSO

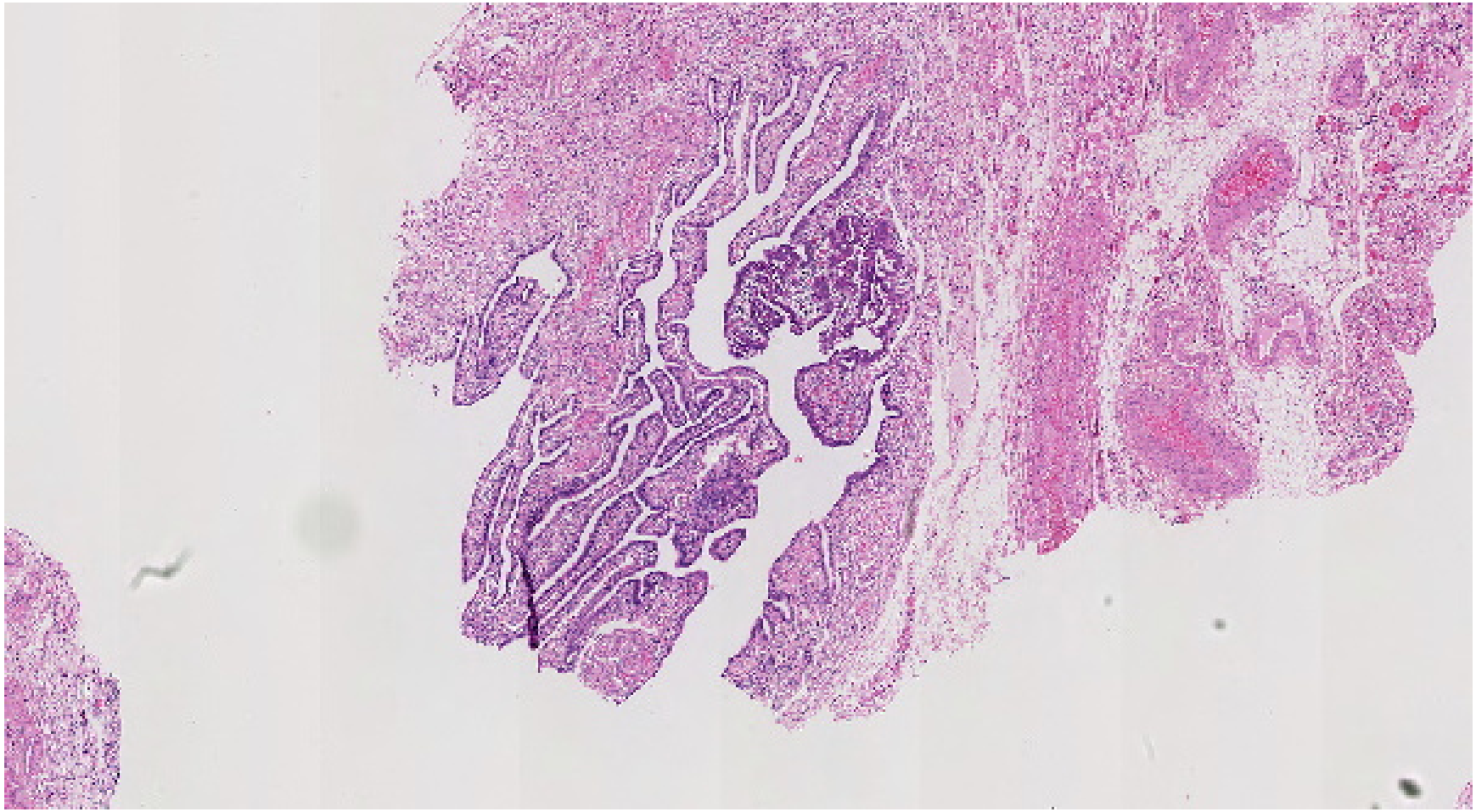

N Singh Case 1: Section from second surgery: TAH LSO

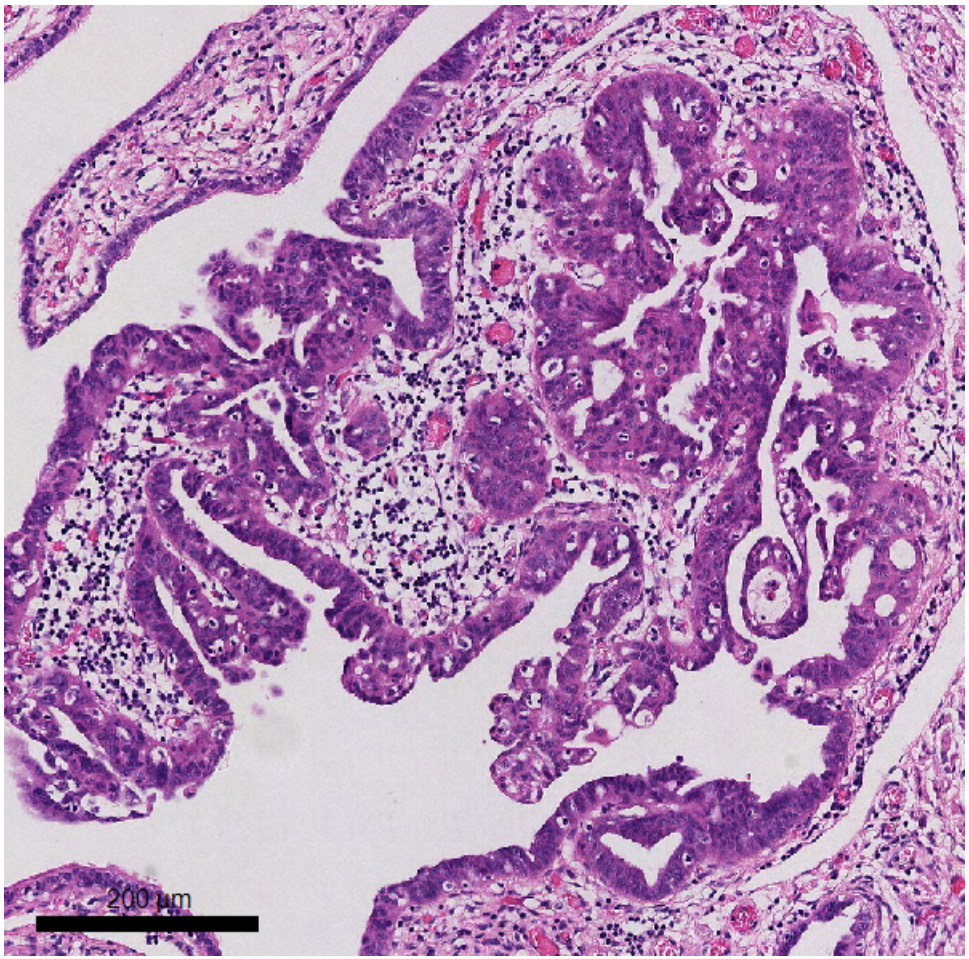

N Singh Case 1: Section from second surgery: TAH LSO

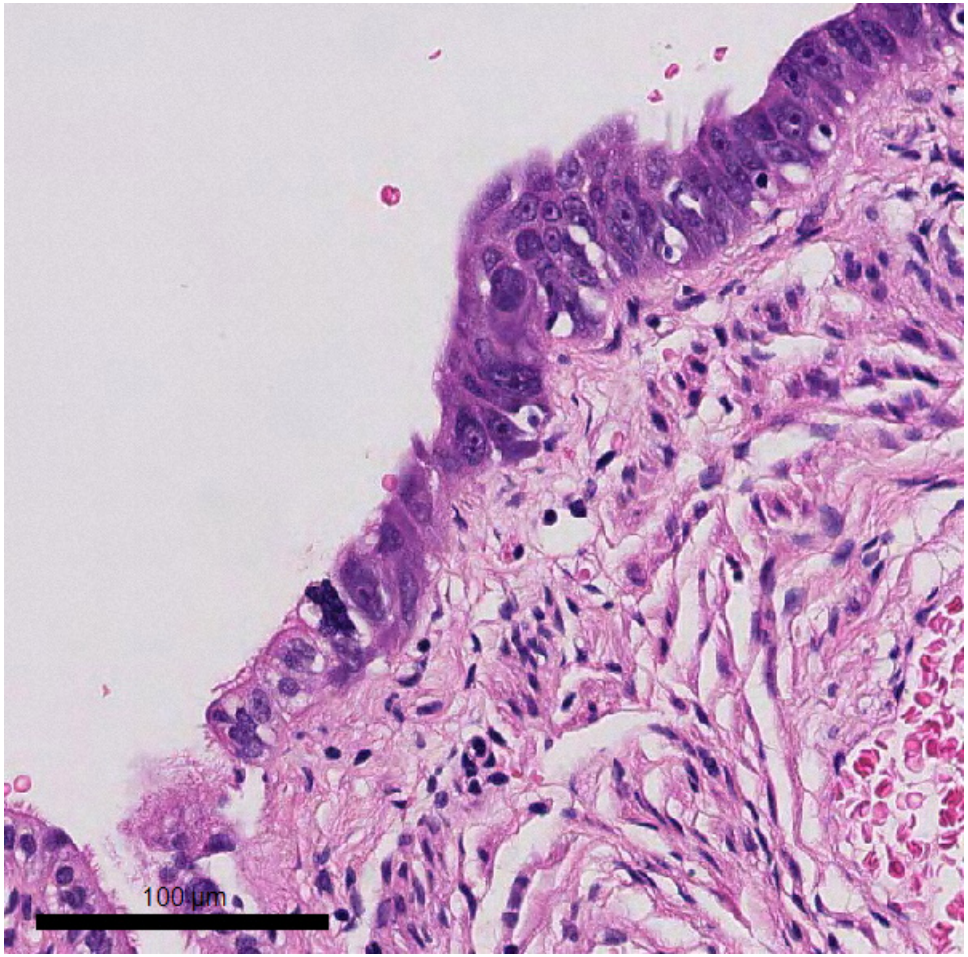

N Singh Case 1

- **This was the only site of disease other than the right ovary.**
- **There was no stromal invasion.**

- What is the diagnosis at second surgery?
- What is the stage of this carcinoma?

N Singh Case 1

- **This was the only site of disease other than the right ovary.**
- **There was no stromal invasion.**

- What is the diagnosis at second surgery? **STIC**
- What is the stage of this carcinoma?

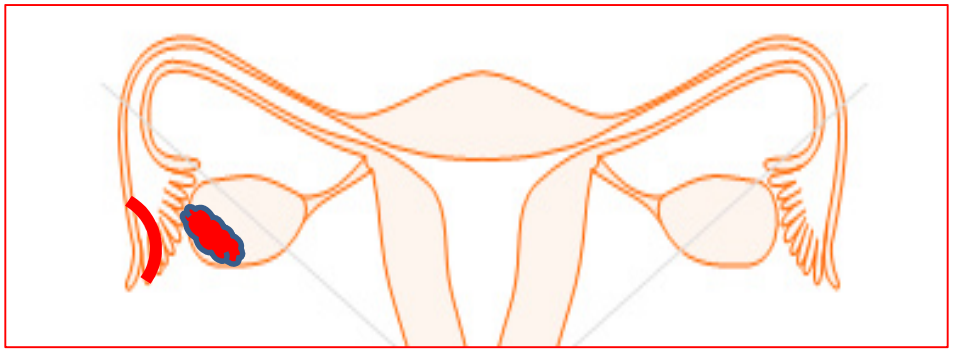

2016 BAGP and ISGyP Survey (173 pathologists from different countries):

What FIGO stage would you assign in a case showing STIC with invasive HGSC in one ovary and no other disease site?

Primary ovarian stage I: 27%

Primary ovarian stage II: 13%

Primary tubal stage I: 15%

Primary tubal stage II: 45%

McCluggage et al. Int J Gynecol Pathol 2017;36:230.

No	Site 1, nature and size	Site 2, nature and size	Common TP53 alteration			COSMIC
			CDS	AA	Genomic Start	
1	RO, 130mm HGSC	LO, 100mm HGSC	c.613_614A>CC	p.Y205fs	Chr17:7578234	No*
2	LFT, 40mm, HGSC	RFT, 22mm HGSC	c.746G>T	p.R249M	Chr17:7577535	COSM43871
3	LO, 130mm HGSC	RO, 3mm HGSC	c.451C>T	p.P151S	Chr17:7578479	COSM10905
4	RO, 150mm HGSC	LFT, STIC and 12mm HGSC	c.701A>G	p.Y234C	Chr17:7577580	COSM10725
5	RFT, 7mm HGSC	LO, 4mm HGSC	c.524G>A	p.R175H	Chr17:7578406	COSM10648
6	RO, 90mm HGSC	LFT, STIC	c.672+1G>A	(intronic/splice)	Chr17:7578176	COSM6906
7	LO, 220mm HGCS	LFT, 0.5mm HGSC	c.742C>T	p.W248R	Chr17:767422 1	COSM10656

Singh et al, Mod Pathol, 2018; **31**(4): 652.

No	Site 1, nature and size	Site 2, nature and size	Common TP53 alteration			COSMIC
			CDS	AA	Genomic Start	
1	RO, 130mm HGSC	LO, 100mm HGSC	c.613_614A>CC	p.Y205fs	Chr17:7578234	No*
2						M43871
3						M10905
4	RO, 150mm HGSC	LFT, STIC and 12mm HGSC	c.701A>G	p.Y234C	Chr17:7577580	COSM10725
5	RFT, 7mm HGSC	LO, 4mm HGSC	c.524G>A	p.R175H	Chr17:7578406	COSM10648
6	RO, 90mm HGSC	LFT, STIC	c.672+1G>A	(intronic/splice)	Chr17:7578176	COSM6906
7	LO, 220mm HGCS	LFT, 0.5mm HGSC	c.742C>T	p.W248R	Chr17:767422 1	COSM10656

***Identical** TP53* mutations in cases showing only 2 disease foci on opposite adnexa (one on left and other on right)

Singh et al, Mod Pathol, 2018; **31**(4): 652.

Learning Points from Case 1: SEE-FIM

- SEE-FIM should be done in all of the following:
  - **Risk-reducing** salpingo-oophorectomy/salpingectomy
  - BSO in high-risk cases
  - All extra-uterine HGSC with ***normal*** FT, including post-chemo

- No need to examine FT fully in the following:
  - Obvious tubal involvement
  - Opportunistic salpingectomy - single fimbrial block (very low likelihood of significant lesion in non-high-risk cases - Meserve et al. Gynecol Oncol 2017; 146:69.)

Learning Points from Case 1: Stage

- Ambiguity in staging low-volume disease

- STIC should count as a disease site for staging purposes
- Bilateral ovarian and bilateral tubal disease (without pelvic/abdominal spread) should be staged similarly as other categories of pelvic spread, ie stage IIA, not IB

Learning Points from Case 1: Multifocal/peritoneal origin

- Low volume disease, even if on opposite sides of the pelvis arise from the same clone
- There is very little evidence of multifocal origin in HGSC
- PPC is not a true biological entity

Learning Points from Case 1: Other HGSC precursor lesions

- Systematic examination +/- IHC has led to recognition of lesions lesser than STIC
- Diagnosis of STIC should be according to strict protocol (Carlson et al, 2010; Int J Gyn Path 29:310.):

morphology + p53 mutant expression + Ki67 >10%

STIC detection – Diagnostic criteria

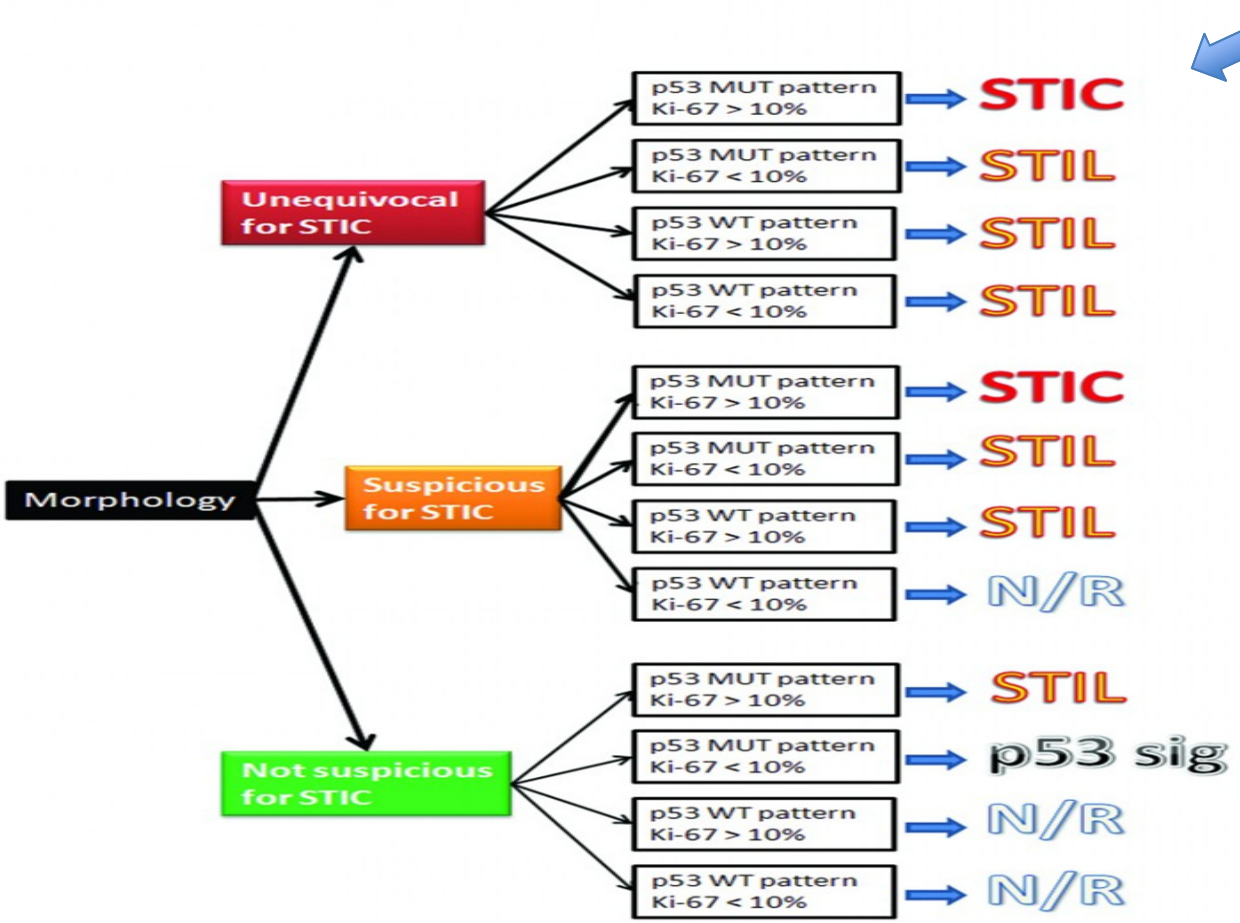

(IHC probably not necessary in morphologically clearcut lesion)

SCOUT: Secretory cell outgrowths

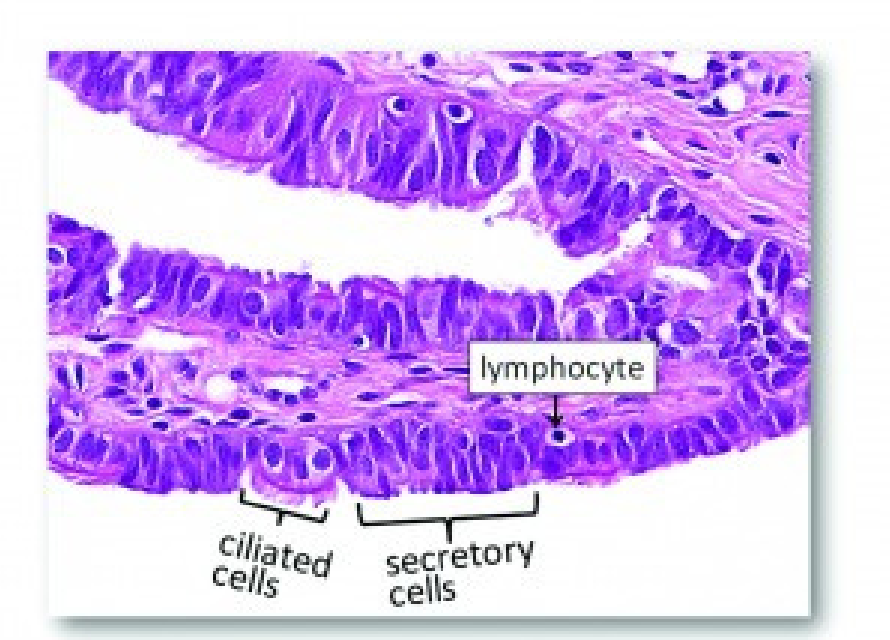

- Normal tubal epithelium: Ciliated, secretory and intercalated cells
- Alternate in small groups, variable
- Secretory cells capable of differentiating into ciliated under hormonal influences
- SCOUT = linear expansion of 30 or more secretory cells not interrupted by ciliated cells
- Bcl2 ++

Normal, bcl-2+ in secretory cells

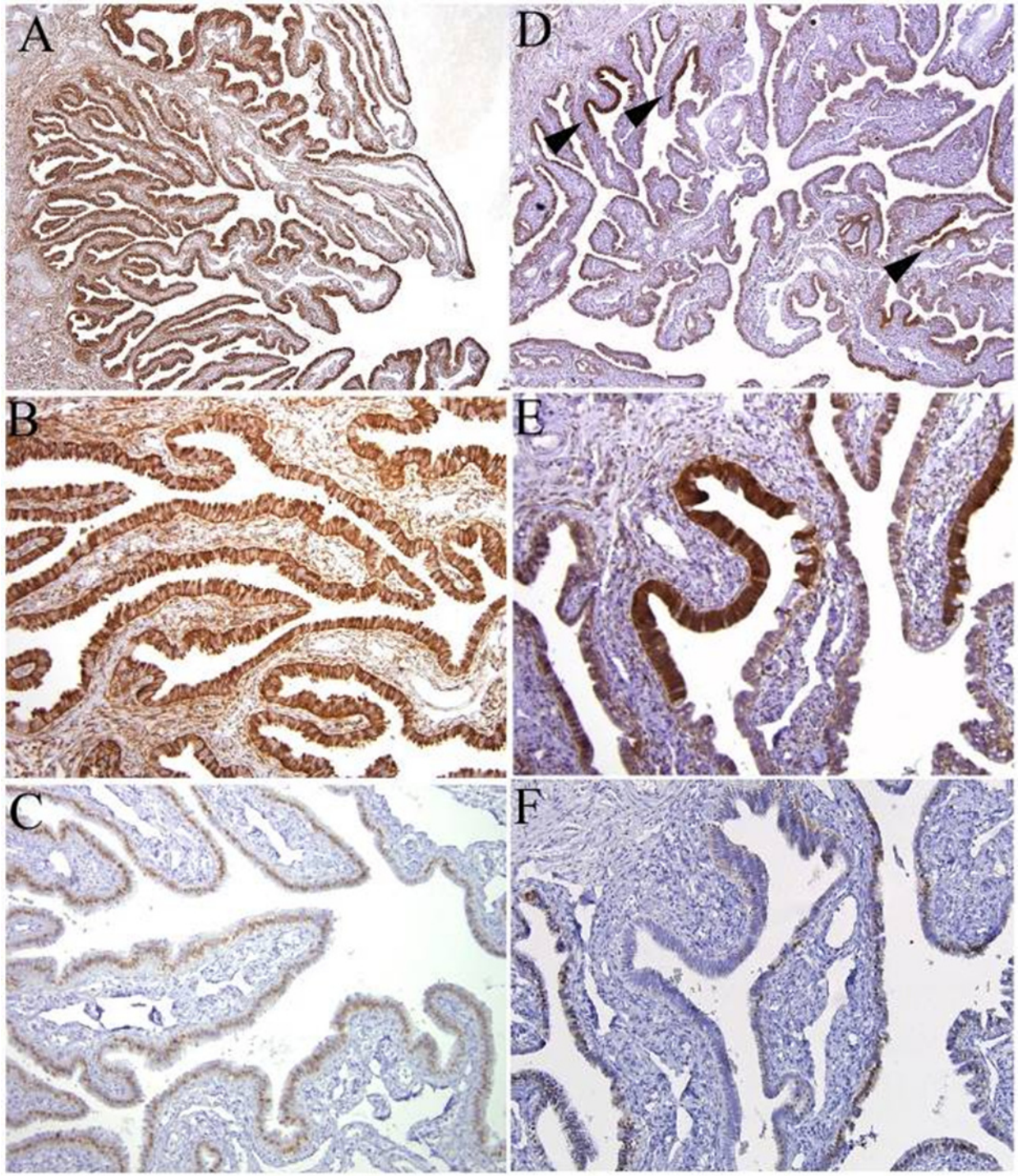

SCOUT, bcl-2+ in continuous stretch of secretory cells

Normal, bcl-2+ in secretory cells

SCOUT, bcl-2+ in continuous stretch of secretory cells

Normal, p73+ in ciliated cell nuclei

SCOUT, p73- in SCOUT cells

SCOUT: Secretory cell outgrowths

- Higher frequency in association with pelvic serous ca
- Located anywhere along FT
- Loss of PAX2 in most instances
- P53 wt, ie normal, in most cases
- P53 signatures = a subset of SCOUTS showing p53 mutation, located at fimbrial end of FT
- Currently unclear whether this represents a precursor or a marker for genetic perturbations associated with serous carcinogenesis

p53 Signature

- Subset of SCOUTS
- Identified by intense p53 staining
- Located in fimbrial end
- P53 mutation and accumulation of p53 protein
- Exhibits evidence of DNA damage
- ↑ in pelvic serous ca and in low parity, ie epidemiologically similar
- Morphologically normal, ie no atypia
- Indistinguishable from normal epithelium on H&E
- Transition lesions ‘proliferative p53 signatures’ identified
- **Considered to be true precursor lesion**
- **Currently NO management implications – looking for these routinely is NOT recommended**

p53 signature

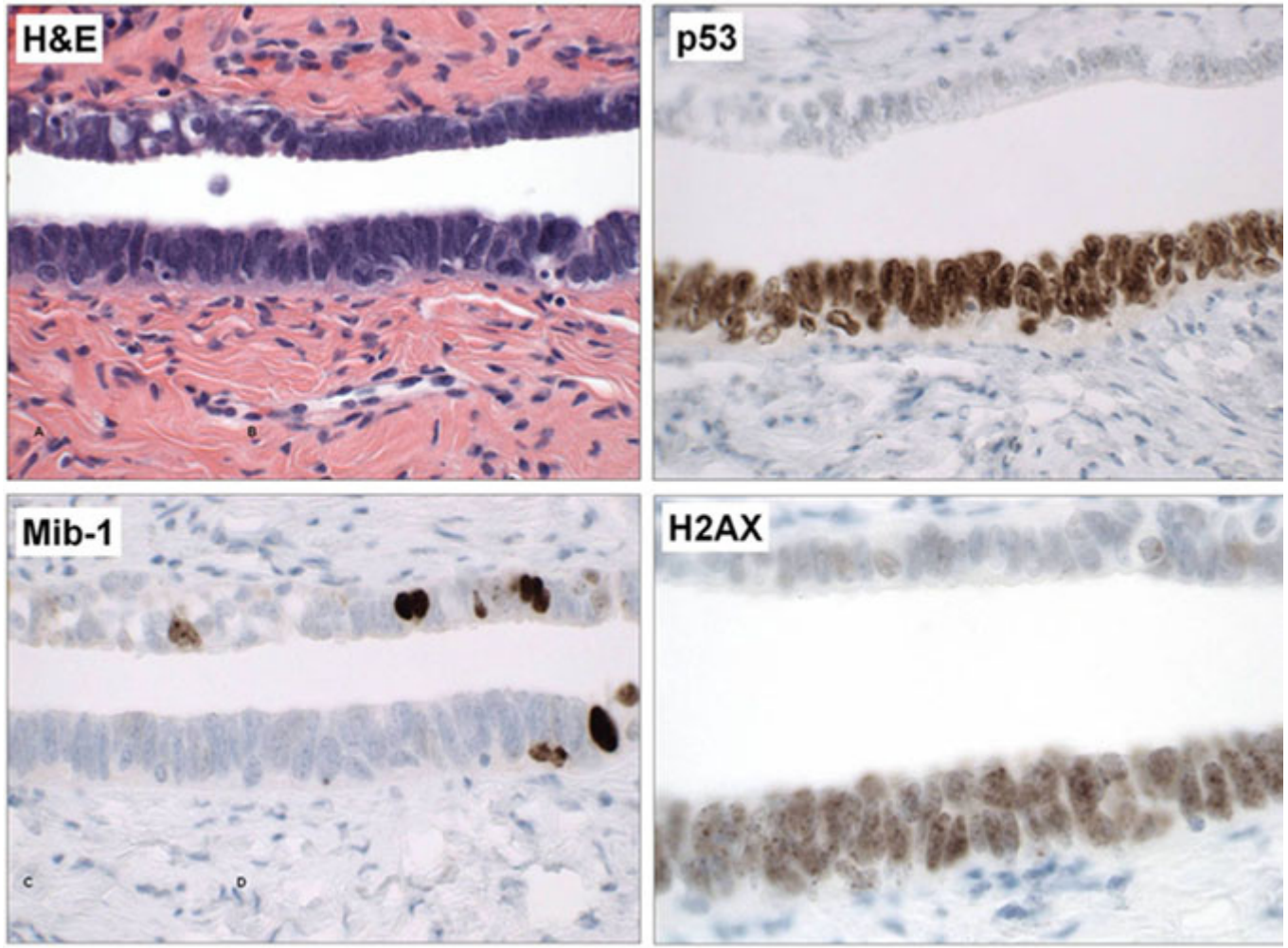

Frontiers in Bioscience E3, 625-634, January 1, 2011

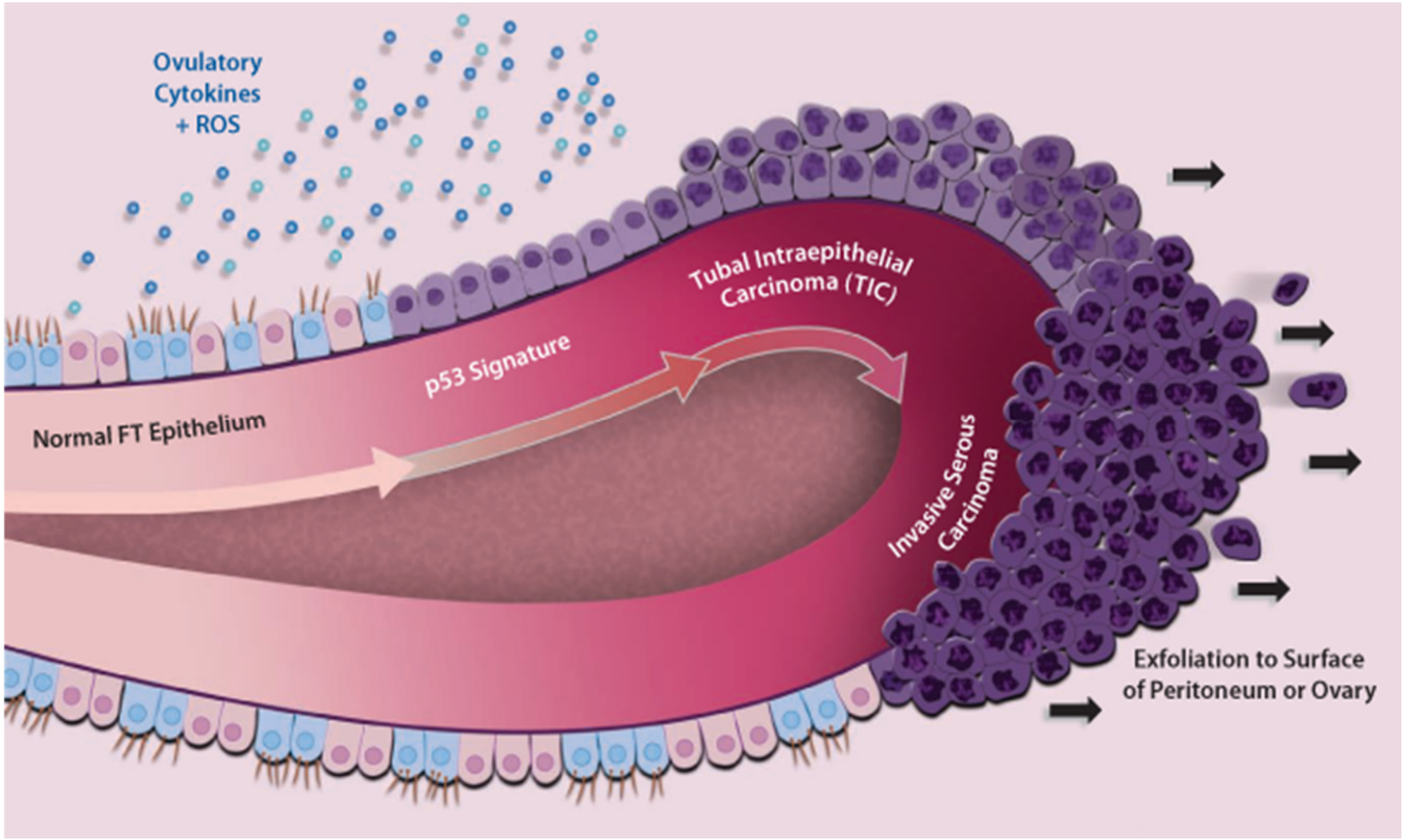

Serous cancer, or the p53 signature identified. Credit: Ronny Drapkin, M.D
National Cancer Institute. US NIH. www.cancer.gov

Pathologic features of the fallopian tube (FT) carcinogenesis spectrum.

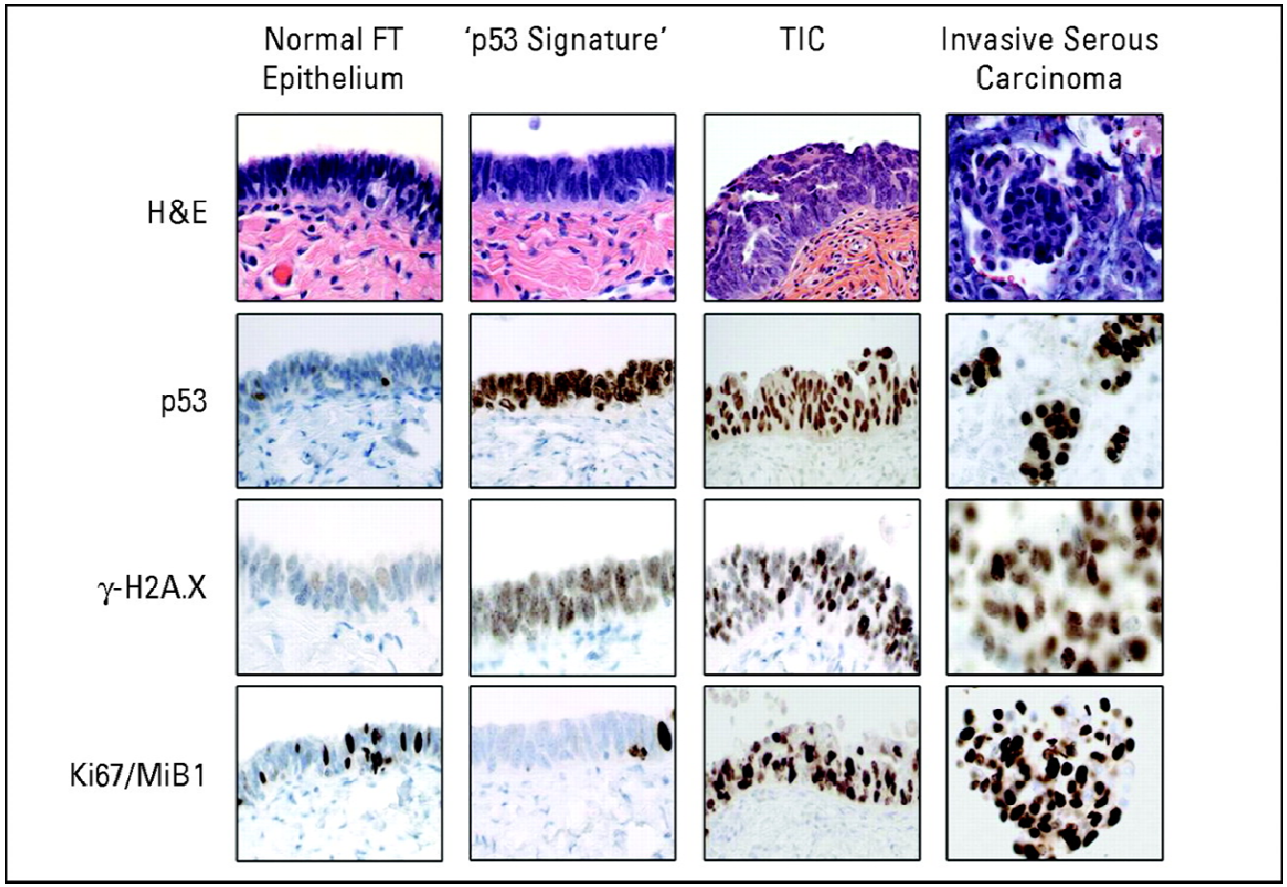

Levanon K et al. JCO 2008;26:5284-5293

JOURNAL OF CLINICAL ONCOLOGY

©2008 by American Society of Clinical Oncology

Premalignant epithelial atypias

- Many terms: proliferative p53 signatures, TILT, STIL
- Uncommon
- Expansion or proliferation of p53 positive epithelium, larger stretches than p53 signatures
- Less atypia; preserved polarity; admixture of ciliated cells
- Low proliferation on Ki67
- Less consistent expression of other serous ca markers
- ie lacks all features for diagnosis of STIC
- **Currently NO management implications – looking for these routinely is NOT recommended**

Learning Points from Case 1: Summary

- Primary site of extra-uterine HGSC should follow a uniform protocol
- SEE-FIM protocol on ***both*** tubes is essential for correct primary site assignment
- STIC should count as a disease site for staging purposes
- Bilateral ovarian and bilateral tubal disease (without pelvic/abdominal spread) should be staged similarly as other categories of pelvic spread, ie stage IIA, not IB
- Lesser lesions (p53 signatures/ STIL) should not be reported as these have no management implications

Case 1

Final diagnosis after completion surgery:

HGSC of left tubal origin, FIGO stage IIA

THANK YOU!