Barts Health NHS
NHS Trust

Precursors of and Site of Origin Assessment in High-Grade Serous Carcinoma

Naveena Singh, Consultant Pathologist

Technology Transfer in Diagnostic Pathology 10th CE
Regional Meeting – Gynecological Pathology
Visegrád, Hungary

Outline

- Introduction
- What is STIC and how commonly is it found in HGSC
- Evidence that HGSC originates as STIC
  - Molecular
  - Other
- Clinical implications of this evidence
- Current approach to site assignment
- Conclusions

Outline

- Introduction
- What is STIC and how commonly is it found in HGSC
- Evidence that HGSC originates as STIC
  - Molecular
  - Other
- Clinical implications of this evidence
- Current approach to site assignment
- Conclusions

Ovarian Cancer - Facts

WHO classification (2003)

- Cancer subtypes (surface epithelial)
  - Serous
  - Mucinous
  - Endometrioid
  - Clear Cell
  - Transitional
  - Squamous
  - Mixed
  - Undifferentiated
- Origin: Mesothelial, CIC
- Outcomes
  - 70% present at high stage
  - 5YS around 30%

WHO classification (2014)

- Cancer subtypes (epithelial)
  - **High grade serous**
  - Low grade serous
  - Endometrioid
  - Clear Cell
  - Mucinous
  - Undifferentiated
- Origin: Extraovarian: FT (+/- CIC), endometriosis
- Outcomes
  - 70% present at high stage
  - 5YS around 40%

Ovarian Cancer - Prevention

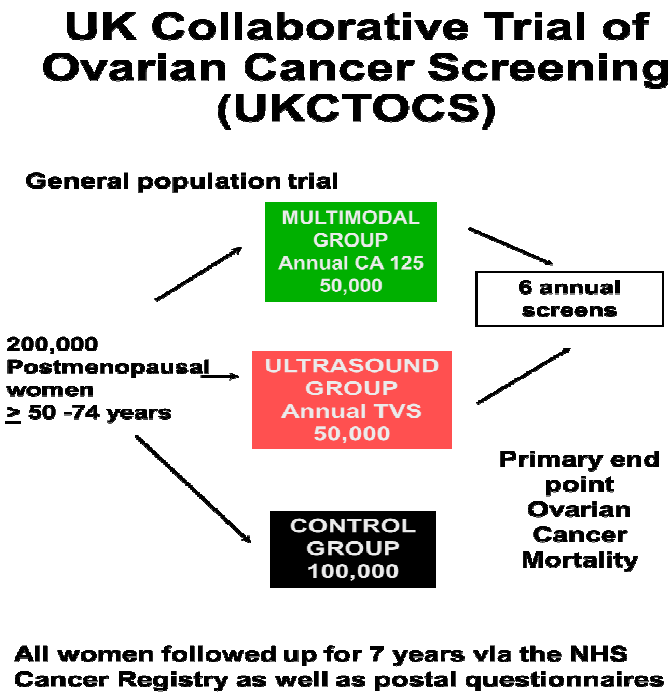

- Rate of rise of CA-125 – ROC curve
- Narrow margin between onset and dissemination
- Short precursor period
- Contrast to cervix cancer
- Screening with known biomarkers not sufficiently sensitive

Ovarian Cancer Origins, previous concepts

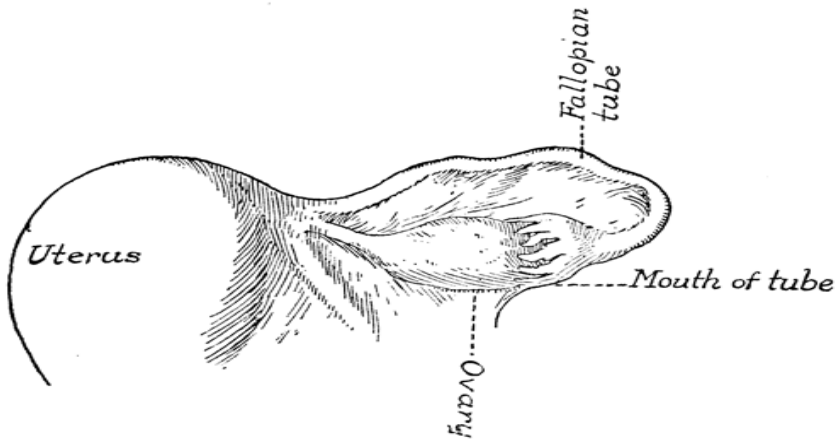

- ↑ ovulation = ↑Ov Ca risk
- ↑ ovulation = ↑ CIC
- Follicular fluid rich in free radicals
- Inflammation and repair
- Ov Ca believed to arise from
  - Mesothelium (pluripotential for Mullerian tissues)
  - Cortical inclusion cysts

Ovarian Cancer - Origins

- ***Earlier studies of sporadic and familial ovarian cancer did not systematically examine the FT***

- **Current view is that virtually all (extra-uterine) HGSC arises from FT**

Ovarian Cancer - Origins

- Precursor lesions – growing list!
  - STIC
  - SCOUT
  - TILT
  - STIL
  - p53 signatures
  - Tubal dysplasia
  - Proliferative p53 signatures
  - Premalignant epithelial atypia
  - Others …..

Ovarian Cancer - Origins

- ***Precursor = One that precedes or indicates something to come***

- Serous Tubal Intraepithelial Carcinoma (STIC): Precursor or Early stage?

- Metastatic potential even when non-invasive

Outline

- Introduction
- What is STIC and how commonly is it found in HGSC
- Evidence that HGSC originates as STIC
  - Molecular
  - Other
- Clinical implications of this evidence
- Current approach to site assignment
- Conclusions

Original Paper

Dysplastic changes in prophylactically removed Fallopian tubes of women predisposed to developing ovarian cancer

Jurgen M. J. Piek[1], Paul J. van Diest[2]*, Ronald P. Zweemer[1], Jan W. Jansen[3], Ria J. J. Poort-Keesom[1], Fred H. Menko[4], Johan J. P. Gille[4], Ans P. M. Jongsma[1], Gerard Pals[4], Peter Kenemans[1] and René H. M. Verheijen[1]

[1]*Department of Obstetrics and Gynaecology, University Hospital Vrije Universiteit, Amsterdam, The Netherlands*
[2]*Department of Pathology, University Hospital Vrije Universiteit, Amsterdam, The Netherlands*
[3]*Department of Pathology, De Heel Hospital, Zaandam, The Netherlands*
[4]*Department of Clinical and Human Genetics, University Hospital Vrije Universiteit, Amsterdam, The Netherlands*

J Pathol 2001; 195:451.

Serous Tubal Intraepithelial Carcinoma, STIC

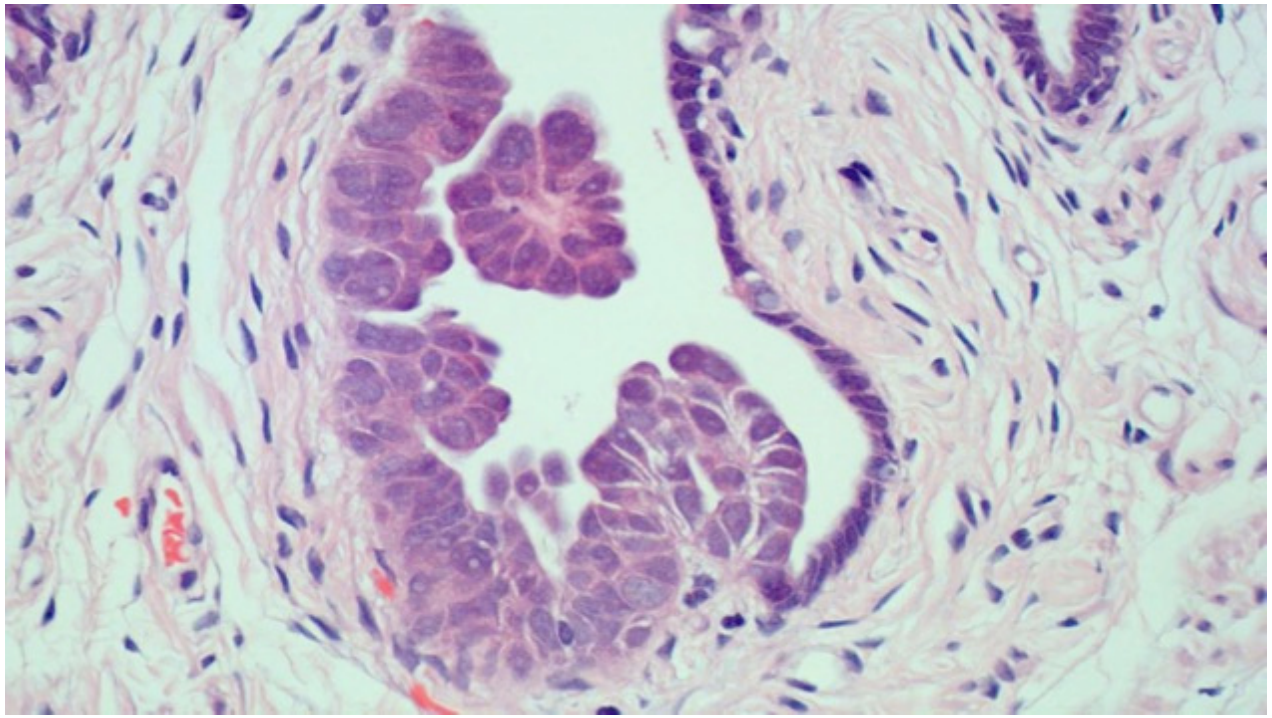

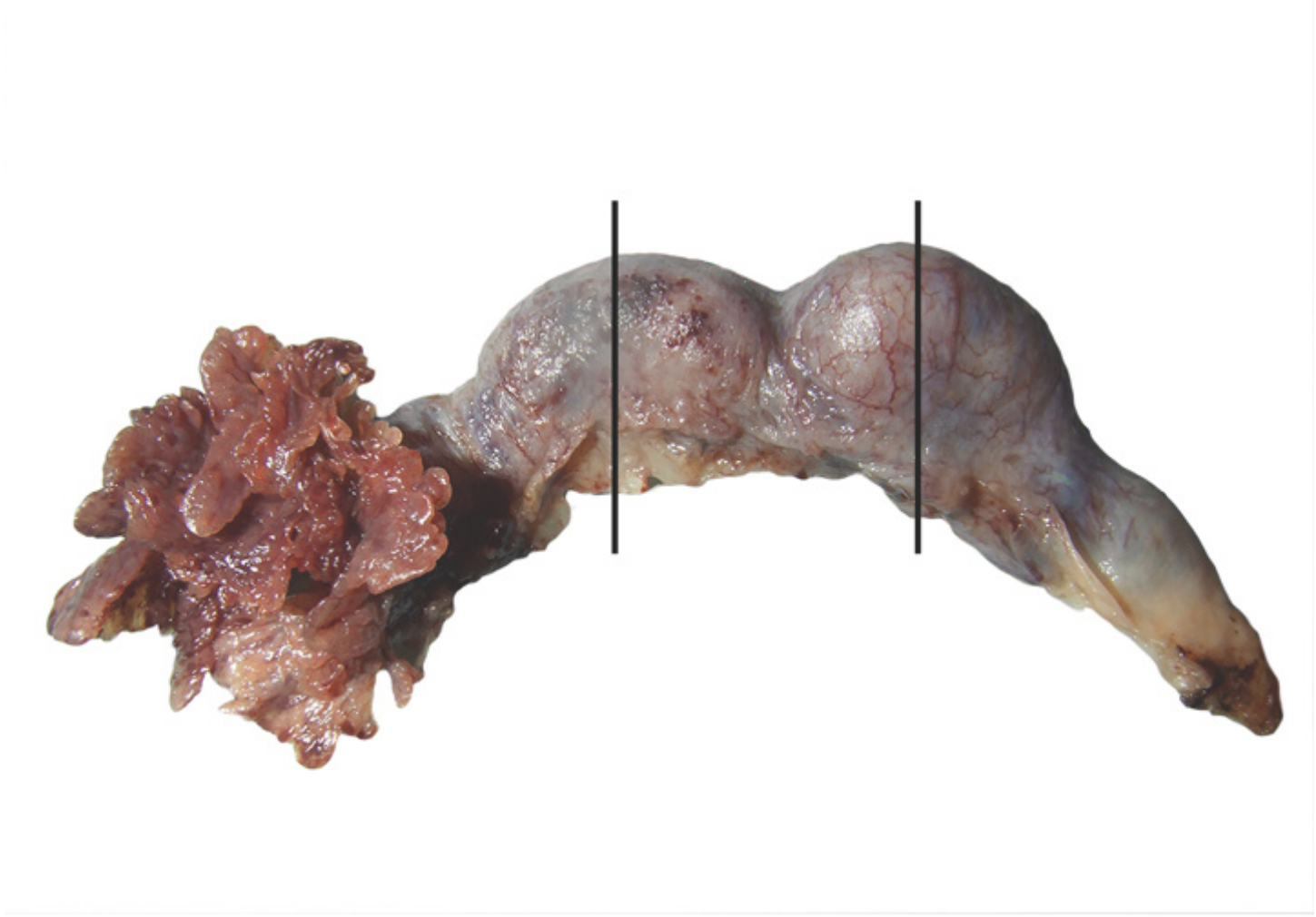



Sectioning and Extensively Examining the FIMbriated end of the FT: SEE-FIM

The Tubal Fimbria Is a Preferred Site for Early Adenocarcinoma in Women With Familial Ovarian Cancer Syndrome

Fabiola Medeiros, MD, Michael G. Muto, MD,† Yonghee Lee, MD,* Julia A. Elvin, MD, PhD,* Michael J. Callahan, MD,† Colleen Feltmate, MD,† Judy E. Garber, MD,‡ Daniel W. Cramer, MD,† and Christopher P. Crum, MD**



Am J Surg Pathol 2006; 30:130.

Frequency of STIC in HGSC



Serous tubal intraepithelial carcinomas associated with high-grade serous ovarian carcinomas: a systematic review

- 10 studies met selection criteria
- Sporadic cases show STIC in 11-61%
- Accurate estimate remains to be determined.
- Lack of accurate estimate makes it difficult to evaluate the potential impact of prophylactic salpingectomy.

Chen et al, BJOG 2017; 124:872.

Frequency of STIC in HGSC is determined by lack of opportunity to study at low stages

Incidental Nonuterine High-grade Serous Carcinomas Arise in the Fallopian Tube in Most Cases

Further Evidence for the Tubal Origin of High-grade Serous Carcinomas

C. Blake Gilks, MD, Julie Irving, MD,† Martin Köbel, MD,‡ Chenghan Lee, MD, PhD,§ Naveena Singh, FRCPath,‖ Nafisa Wilkinson, FRCPath,¶ and W. Glenn McCluggage, FRCPath#*

Incidental Serous Tubal Intraepithelial Carcinoma and Early Invasive Serous Carcinoma in the Nonprophylactic Setting

Analysis of a Case Series

Jane C. Morrison, MD, Luis Z. Blanco, Jr, MD,* Russell Vang, MD,*† and Brigitte M. Ronnett, MD*†*

Am J Surg Pathol, 2015. 39:357.
Am J Surg Pathol, 2015. 39:442.

Study	Total cases	Cases with STIC	FT HGSC	Ov HGSC
Semmel, 2009	1	1	1	
Rabban, 2014	4	4	3	1
Morrison, 2014	22	22	6	1
Gilks, 2014	21	20	12	2
Total	48	47	22	4

- **47/48 (98%) sporadic* incidental cases contained STIC**

*NOT prophylactic specimens

Singh et al. Pathology. 2015 Aug;47(5):423-31.

Frequency of STIC in HGSC is determined by lack of opportunity to study at low stages

Disease Distribution in Low-stage Tubo-ovarian High-grade Serous Carcinoma (HGSC): Implications for Assigning Primary Site and FIGO Stage.

- 152 stage I and stage II cases from 6 teaching hospitals
- 95% (19/20) of ***optimally examined*** cases show STIC
- Many factors influence detection

Singh et al. Int J Gynecol Pathol 2018; **37**(4): 324.

Factors determining STIC detection – rapid growth

Nature of Tubal Involvement in HGSC			
	Incidental HGSC/STIC[1,2]	Stage I/II[3]	All Stages[4]
STIC alone	26 (60%)	9 (13%)	5 (9%)
Invasive tubal mucosal HGSC +/- STIC	17 (40%)	36 (54%)	26 (49%)
Tube and ovary inseparable	0	10 (15%)	13 (25%)
No tubal involvement	0	12 (18%)	9 (17%)
Total	43	67	53

[1]Gilks et al. Am J Surg Pathol. 2015. 39:357.
[2]Morrison et al. Am J Surg Pathol, 2015. 39:442.
[3]Singh et al. Int J Gynecol Pathol 2018; **37**(4): 324.
[4]Singh et al. Histopathology. 2015; 67:331.

Outline

- Introduction: what is STIC and how commonly is it found in HGSC

  - **In low-stage disease, STIC is found in virtually every case of HGSC**

Outline

- Introduction
- What is STIC and how commonly is it found in HGSC
- Evidence that HGSC originates as STIC
  - Molecular
  - Other
- Clinical implications of this evidence
- Current approach to site assignment
- Conclusions

Demonstrating clonal identity in HGSC

- Marked genomic heterogeneity
- STIC lesions microscopic – only detected in FFPE
- *TP53* early and founder abnormality (98%)
- Demonstration of identical *TP53* mutation is powerful evidence of clonal origin

Brief Report

Next-Generation Sequencing of Tubal Intraepithelial Carcinomas

Andrew S. McDaniel, MD, PhD; Jennifer N. Stall, MD; Daniel H. Hovelson, MS; Andi K. Cani, MS; Chia-Jen Liu, MS; Scott A. Tomlins, MD, PhD; Kathleen R. Cho, MD

TP53 mutations in serous tubal intraepithelial carcinoma and concurrent pelvic high-grade serous carcinoma—evidence supporting the clonal relationship of the two lesions

Elisabetta Kuhn,[1] Robert J Kurman,[1–3] Russell Vang,[1,2] Ann Smith Sehdev,[4] Guangming Han,[5] Robert Soslow,[5] Tian-Li Wang[2,3] and Ie-Ming Shih[1–3]*

Intraepithelial Carcinoma of the Fimbria and Pelvic Serous Carcinoma: Evidence for a Causal Relationship

David W. Kindelberger, MD, Yonghee Lee, MD,* Alexander Miron, PhD,† Michelle S. Hirsch, MD, PhD,* Colleen Feltmate, MD,‡ Fabiola Medeiros, MD,* Michael J. Callahan, MD,‡ Elizabeth O. Garner, MD, MPH,‡ Robert W. Gordon,† Chandler Birch,* Ross S. Berkowitz, MD,‡ Michael G. Muto, MD,‡ and Christopher P. Crum, MD**

STIC lesions in disseminated HGSC are clonally related to tumour at other sites

Clonal identity of STIC and HGSC

- HGSC and STIC arise from a single clone
- No evidence to suggest multifocal origin (except very rarely usually in familial cases)

But what is the direction of spread?



Could STIC represent secondary/metastatic spread?

Nongynecologic Metastases to Fallopian Tube Mucosa

A Potential Mimic of Tubal High-grade Serous Carcinoma and Benign Tubal Mucinous Metaplasia or Nonmucinous Hyperplasia

Joseph T. Rabban, MD, MPH, Poonam Vohra, MD, and Charles J. Zaloudek, MD

- 100 non-gyn tumours with FT metastasis
- 91% accompanied by ovarian mets
- 57% fimbrial location
- Resembled STIC
- **'… current proposals for basing primary site on STIC may not reflect true biology of cancer development and progression'**

(*Am J Surg Pathol* 2015;39:35–51)

RESEARCH BRIEF

Genomics of Ovarian Cancer Progression Reveals Diverse Metastatic Trajectories Including Intraepithelial Metastasis to the Fallopian Tube AC

Mark A. Eckert[1], Shawn Pan[1], Kyle M. Hernandez[2], Rachel M. Loth[1], Jorge Andrade[2], Samuel L. Volchenboum[2,3], Pieter Faber[4], Anthony Montag[5], Ricardo Lastra[5], Marcus E. Peter[6], S. Diane Yamada[1], and Ernst Lengyel[1]

Cancer Discov 2016; 6(12); 1342.

Evidence that STIC Represents the Primary Lesion

- Telomeric length: Kuhn et al, 2010
- Clonal evolution: Bashashati et al, 2013
- Bilateral involvement in tube (16%) vs ovary (62%): Singh et al 2015
- CCNE amplification and centrosome number: Kuhn et al 2016
- Whole exome seq, CNA and evolutionary analysis: Labidi-Galy et al, 2017

Evidence that STIC Represents the Primary Lesion

- Telomeric length: Kuhn et al, 2010
- **Clonal evolution: Bashashati et al, 2013**
- Bilateral involvement in tube (16%) vs ovary (62%): Singh et al 2015
- CCNE amplification and centrosome number: Kuhn et al 2016
- **Whole exome seq, CNA and evolutionary analysis: Labidi-Galy et al, 2017**

Shortened Telomeres in Serous Tubal Intraepithelial Carcinoma: An Early Event in Ovarian High-grade Serous Carcinogenesis

Elisabetta Kuhn, MD, Alan Meeker, PhD,*† Tian-Li Wang, PhD,†‡ Ann Smith Sehdev, MD,§ Robert J. Kurman, MD,*†‡ and Ie-Ming Shih, MD, PhD*†‡*

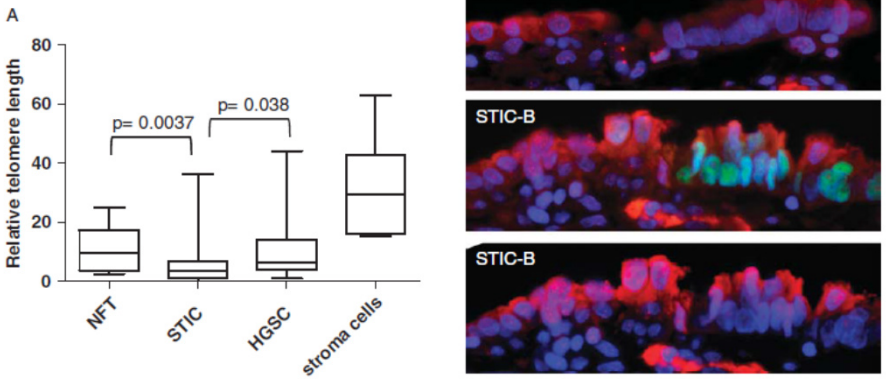

- Majority of STIC showed shortened telomeres
- Majority of corresponding HGSC showed longer telomeres
- Supports hypothesis of STIC being precursor rather than metastatic lesions

CCNE1 amplification and centrosome number abnormality in serous tubal intraepithelial carcinoma: further evidence supporting its role as a precursor of ovarian high-grade serous carcinoma

Elisabetta Kuhn[1], Tian-Li Wang[1], Kai Doberstein[2], Asli Bahadirli-Talbott[1], Ayse Ayhan[1,3], Ann Smith Sehdev[4], Ronny Drapkin[2], Robert J Kurman[1,5] and Ie-Ming Shih[1,5]

[1]Department of Pathology, Johns Hopkins Medical Institutions, Baltimore, MD, USA; [2]Department of Obstetrics and Gynecology, Penn Ovarian Cancer Research Center, University of Pennsylvania, Philadelphia, PA, USA; [3]Department of Pathology, Seirei Mikatahara Hospital, Hamamatsu, Japan; [4]Legacy Health Systems, Portland, OR, USA and [5]Department of Gynecology and Obstetrics, Johns Hopkins Medical Institutions, Baltimore, MD, USA

Kuhn et al, Mod Pathol 2016; 29:1254.

Journal of Pathology
J Pathol 2013; **231**: 21–34
Published online in Wiley Online Library
(wileyonlinelibrary.com) DOI: 10.1002/path.4230

ORIGINAL PAPER

Distinct evolutionary trajectories of primary high-grade serous ovarian cancers revealed through spatial mutational profiling

Ali Bashashati,[1,†] Gavin Ha,[1,†] Alicia Tone,[2,†] Jiarui Ding,[1,3] Leah M Prentice,[2] Andrew Roth,[1] Jamie Rosner,[1] Karey Shumansky,[1] Steve Kalloger,[2] Janine Senz,[2] Winnie Yang,[2] Melissa McConechy,[2] Nataliya Melnyk,[2] Michael Anglesio,[2] Margaret TY Luk,[4] Kane Tse,[5] Thomas Zeng,[5] Richard Moore,[5] Yongjun Zhao,[5] Marco A Marra,[5] Blake Gilks,[6] Stephen Yip,[7] David G Huntsman,[2,7] Jessica N McAlpine[8] and Sohrab P Shah[1,7,*]

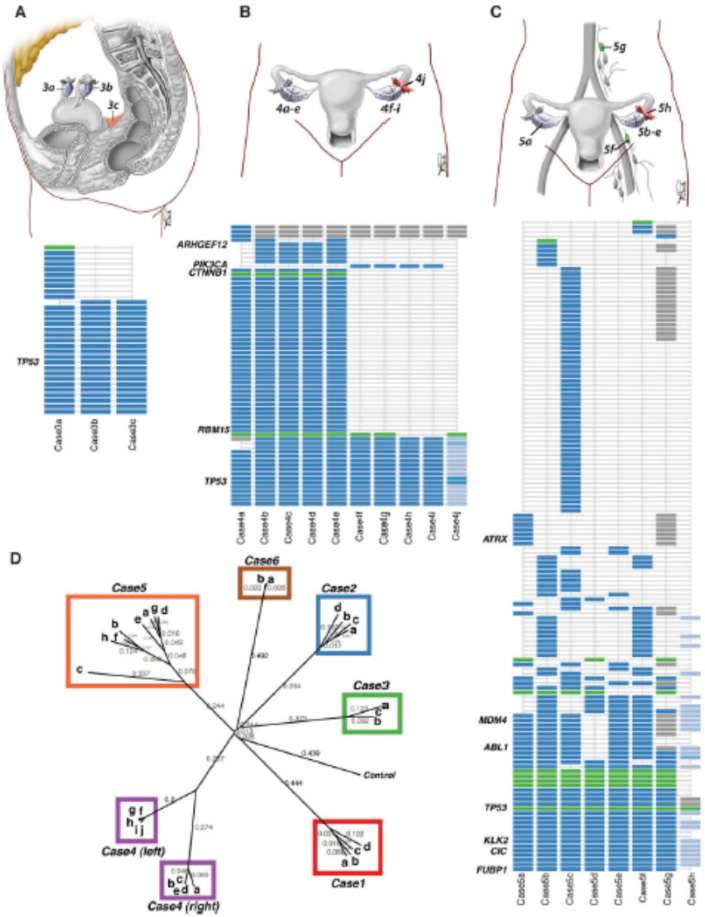

- Wide range of genomic diversity in HGSC
- FT mucosal lesion was ancestral based on phylogenetic mapping

nature COMMUNICATIONS

ARTICLE

DOI: 10.1038/s41467-017-00962-1 OPEN

High grade serous ovarian carcinomas originate in the fallopian tube

S. Intidhar Labidi-Galy[1,13], Eniko Papp[2,14], Dorothy Hallberg[2], Noushin Niknafs[2,3], Vilmos Adleff[2], Michael Noe[2], Rohit Bhattacharya[2,4], Marian Novak[1,14], Siân Jones[5], Jillian Phallen[2], Carolyn A. Hruban[2], Michelle S. Hirsch[6], Douglas I. Lin[6,15], Lauren Schwartz[7], Cecile L. Maire[1], Jean-Christophe Tille[8], Michaela Bowden[6], Ayse Ayhan[9,10,11,12], Laura D. Wood[2], Robert B. Scharpf[2], Robert Kurman[2,12], Tian-Li Wang[2,12], Ie-Ming Shih[2,12], Rachel Karchin[2,3], Ronny Drapkin[1,6,16] & Victor E. Velculescu[2]

Nature Comm 2017; 8:1093.

- 5 patients
- Whole-exome sequence and copy number analyses of laser capture microdissected lesions (p53 signatures, STIC, FT HGSC, Ov HGSC and metastases)
- Majority of tumor-specific alterations present in STICs
- Evolutionary analyses reveal that p53 signatures and STICs are precursors of ovarian carcinoma
- 7-year window between STIC and initiation of ovarian carcinoma, with further metastases following rapidly

Unilateral vs bilateral tubal and ovarian involvement in HGSC

	Unilateral	Bilateral	Total
Ovary	18 (38%)	**29 (62%)**	47
Fallopian tube	**37 (84%)**	7 (16%)	44

- Bilaterality = strong indicator of secondary spread
- In 53 chemo-naïve cases, ovarian involvement in HGSC was significantly more frequently bilateral
- Tubal involvement unilateral in 84% supporting primary rather than metastatic involvement

Singh et al, 2015

Study	Total cases	Cases with STIC	FT HGSC	Ov HGSC	Organ-confined	Organ-confined: FT	Organ-confined: Ov
Semmel, 2009	1	1	1		1	1	0
Rabban, 2014	4	4	3	1	3	3	0
Morrison, 2014	22	22	6	1	21	21	0
Gilks, 2014	21	20	12	2	18	18	0
Total	48	47	22	4	**43**	**43**	**0**

43/43 organ-confined early sporadic* HGSC are located in FT

*not RRSO specimens

Evidence of ovarian origin of HGSC

- Cortical inclusion cysts (CIC) and ovarian surface epithelium:
  - Undergo serous metaplasia
  - Transformation to HGSC and LGSC in culture
  - Premalignant morphological and genomic changes
  - Accompanied by immune/inflammatory cells as in tubal mucosa
  - Aneuploidy demonstrated

Kurman, RJ. Ann Oncol 2013. 24(s10):x16-x21.
Auersperg, N. Gynecol Oncol. 2013; 130: 246.

Evidence of ovarian origin of HGSC - summary

- Very little evidence (despite searching for decades!)
- Most ‘ovarian’ cases can be explained by lack of ability to identify tubal origin for a variety of reasons

Ovaries are preferential metastatic site

- Growth in ovary out of proportion to that in FT
- A variety of tumours, not just HGSC (e.g. endometrium, cervix, gastric, colorectal, appendiceal etc)
- Enzymatically active stromal cells that promote growth of a variety of epithelial tumours

Song et al. Med Hypotheses 2011. 77:356.

Outline

- Evidence that HGSC originates as STIC
  - Molecular
  - Other

  - **Strong evidence that HGSC originates in STIC**

Outline

- Introduction
- What is STIC and how commonly is it found in HGSC
- Evidence that HGSC originates as STIC
  - Molecular
  - Other
- Clinical implications of this evidence
- Current approach to site assignment
- Conclusions

FIGO 2013 ovarian cancer staging: Additional requirements

International Journal of Gynecology and Obstetrics 124 (2014) 1–5

Contents lists available at ScienceDirect

International Journal of Gynecology and Obstetrics

journal homepage: www.elsevier.com/locate/ijgo



FIGO GUIDELINES

Staging classification for cancer of the ovary, fallopian tube, and peritoneum☆

Jaime Prat *; for the FIGO Committee on Gynecologic Oncology [1]

- Designate histotype
- Designate primary site (O, T, P, U)

FIGO GUIDELINES

Staging classification for cancer of the ovary, fallopian tube, and peritoneum ☆

Jaime Prat * for the FIGO Committee on Gynecologic Oncology [1]

- No guidelines provided in either document
- **“The decision as to primary site should be pragmatic, based on experience and professional judgement.”**



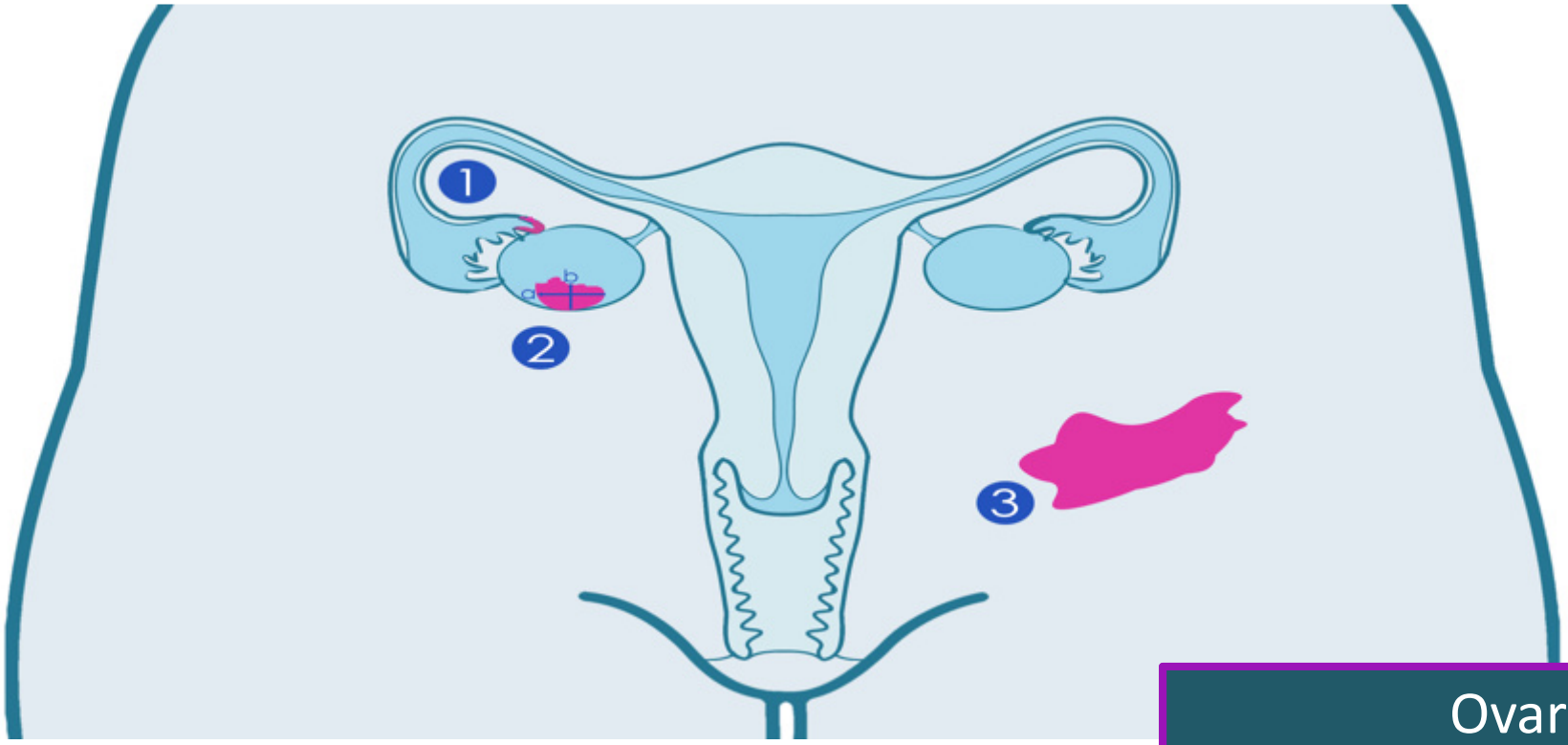

STIC + small volume ovarian HGSC + large volume peritoneal HGSC

Ovarian?
Peritoneal?
Tubal?
Undesignated?

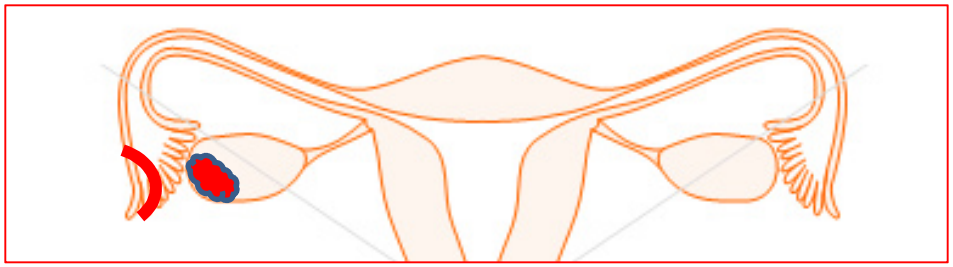

2016 BAGP and ISGyP Survey (173 pathologists from different countries):

What FIGO stage would you assign in a case showing STIC with invasive HGSC in one ovary and no other disease site?

Primary ovarian: 40%

Primary tubal: 60%

McCluggage et al. Int J Gynecol Pathol 2017;36:230.

- Absence of a uniform approach to assigning primary site:
  - Non-uniform categorisation of primary
  - What about clinical management?

Does primary site affect management in HGSC?

- Significantly lower rate of surgery in “PPC” (UKCTOCS, ongoing sub analysis)
- Variable uptake of opportunistic salpingectomy
- Variable enthusiasm to explore risk-reducing salpingectomy (and delayed oophorectomy) in high risk women: ***PROTECTOR*** – R Manchanda)

Outline

- Introduction
- What is STIC and how commonly is it found in HGSC
- Evidence that HGSC originates as STIC
  - Molecular
  - Other
- Clinical implications of this evidence
- Current approach to site assignment
- Conclusions

Contents lists available at ScienceDirect

Gynecologic Oncology

journal homepage: www.elsevier.com/locate/ygyno



Clinical Commentary

Primary site assignment in tubo-ovarian high-grade serous carcinoma: Consensus statement on unifying practice worldwide

Naveena Singh, C Blake Gilks, Lynn Hirschowitz, Sean Kehoe, Iain A McNeish, Dianne Miller, Raj Naik, Nafisa Wilkinson, W Glenn McCluggage

Gynec Oncol. 2016; 353:230.

UKCTOCS

United Kingdom Collaborative Trial of Ovarian Cancer Screening

Site Assignment in HGSC

- **TUBAL**, in the presence of:
  - STIC
  - Invasive *mucosal* carcinoma
  - Part or all of tube is incorporated into tubo-ovarian mass
- **OVARIAN**, in the absence of tubal involvement as above
- **PERITONEAL**, in the absence of gross or microscopic involvement of tubes (mucosal) and ovaries (WHO 2014)
- **TUBO-OVARIAN** if diagnosis based on small samples/post chemo/post-BSO when tubes were not fully examined
- **UNDESIGNATED:** USE SPARINGLY! (genuine uncertainty between uterine vs tubo-ovarian)

ICCR 2015, CAP checklist 2016

Reasons to adopt uniform protocol

1. UNIFORM TERMINOLOGY: **Tubo-ovarian HGSC**
2. Uniformity in primary site assignment
3. Uniformity in staging FIGO I and II
4. Mandates uniform specimen handling (HGSC and high risk cases)
5. Underscores difference between HGSC and other histotypes
6. Science not dogma should form basis of protocols
7. Paves way for acceptance of preventative strategies

Current approach to site assignment

- Adopted in international ovarian cancer pathology reporting guidelines: ICCR, CAP, RCPath

- Adopted in upcoming ESGO-ESMO OC management guidelines

Outline

- Introduction
- What is STIC and how commonly is it found in HGSC
- Evidence that HGSC originates as STIC
  - Molecular
  - Other
- Clinical implications of this evidence
- Current approach to site assignment
- Conclusions

Conclusions

- HGSC originates in the Fallopian tube in the vast majority of cases

- This should be reflected in our classification, terminology, approach to management and research priorities

Table: Site Assignment in HGSC

- **TUBAL**, in the presence of:
  - STIC
  - Invasive *mucosal* carcinoma
  - Part or all of tube is incorporated into tubo-ovarian mass
- **OVARIAN**, in the absence of tubal involvement as above
- **PERITONEAL**, in the absence of gross or microscopic involvement of tubes (mucosal) and ovaries (WHO 2014)
- **TUBO-OVARIAN** if diagnosis based on small samples/post chemo/post-BSO when tubes were not fully examined
- **UNDESIGNATED:** USE SPARINGLY! (genuine uncertainty between uterine vs tubo-ovarian)

Thank You