Barts Health NHS
NHS Trust

Ovarian Serous Borderline Tumours and Prognosis

Naveena Singh, Consultant Pathologist

Technology Transfer in Diagnostic Pathology 10th CE Regional Meeting – Gynecological Pathology
Visegrád, Hungary
June 28, 2019

Ovarian Borderline Tumours

“There are no borderline tumours, only borderline pathologists.”

This comment only illustrates the lack of understanding about this disease

Ovarian Borderline Tumours

- Lower limit: proliferation >10% of epithelium
- Upper limit: Invasion <5mm in max diameter (microinvasion)
- Microinvasive Ca: small focus of LGSC in an otherwise typical SBT – rare, extensive sampling, careful management

SBT survival

- Stage I: >95%
- Stage II-IV: approximately 65%
- Indolent, protracted clinical course

SBT: Prognostic factors

- Bilaterality
- Surface involvement
- Micropapillary pattern
- Microinvasion
- Implant morphology
- Nodal involvement
- Stage

SBT: Prognostic factors

- Bilaterality
- Surface involvement
- Micropapillary pattern
- Microinvasion
- **Implant morphology**
- Nodal involvement
- **Stage**

WHO 2014: Changes to SBT

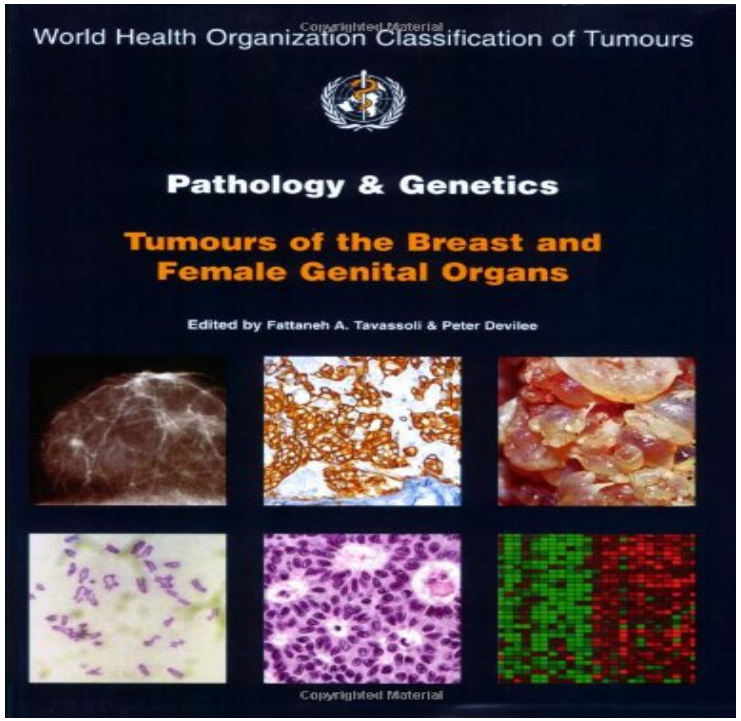

1.

Invasive implant = LGSC

Outcome of implants

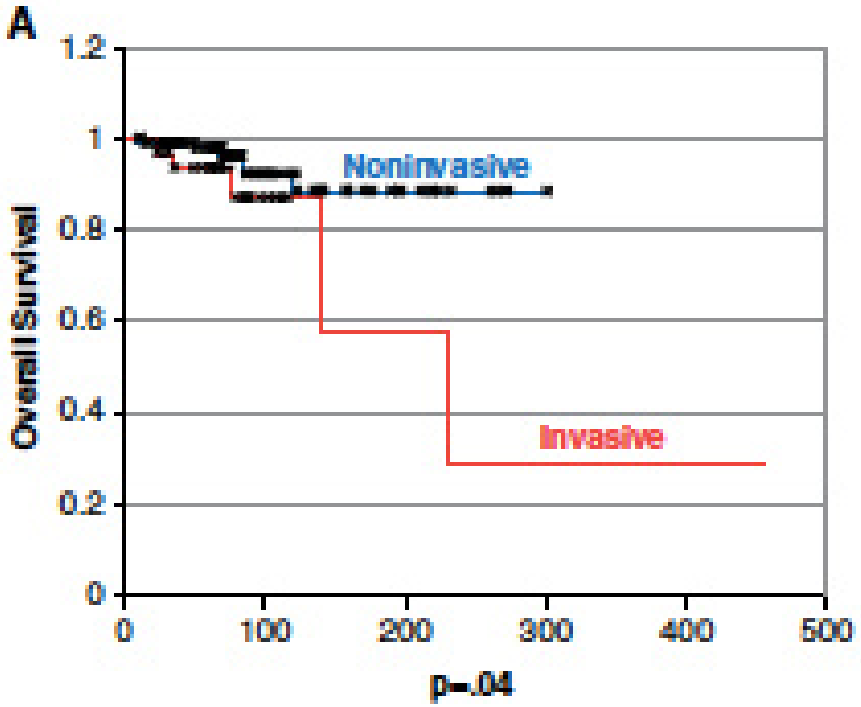

McKenney et al. Am J Surg Pathol 2016; 40:1155

WHO 2014: Changes to SBT

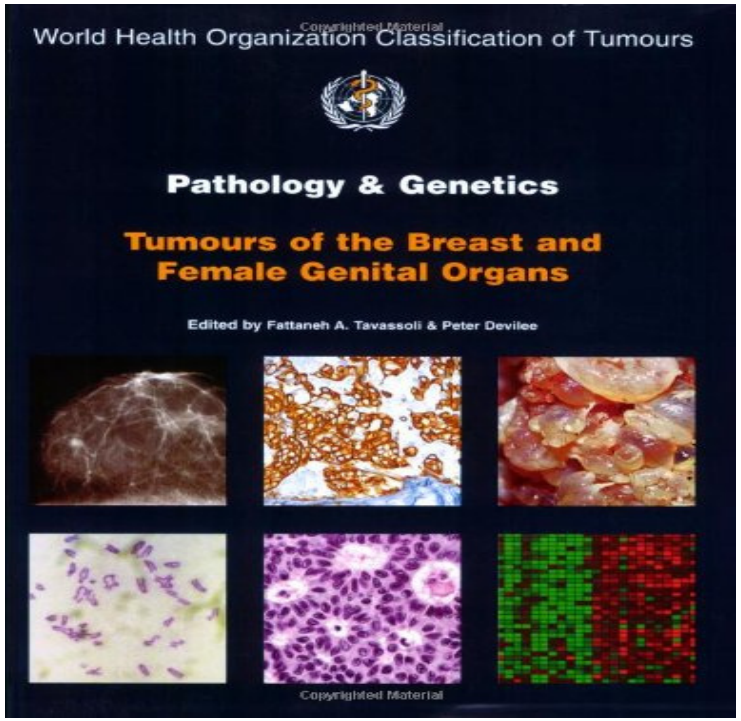

2. SBT with micropapillary pattern = non-invasive LGSC

Confusing; most pathologists do not use this terminology

ORIGINAL ARTICLE

Long-term Behavior of Serous Borderline Tumors Subdivided Into Atypical Proliferative Tumors and Noninvasive Low-grade Carcinomas

A Population-based Clinicopathologic Study of 942 Cases

Russell Vang, MD,† Charlotte G. Hannibal, PhD,‡ Jette Junge, MD,§ Kirsten Frederiksen, PhD,‡ Susanne K. Kjaer, MD,‡‖ and Robert J. Kurman, MD*†¶*

- Population-based
- No patients lost to follow-up (up to 36 yrs)
- 942 cases

Vang et al. AJSP 2017; 41:725

SBT, what matters

- **Stage** and, for patients with advanced stage tumors, **invasiveness of implants**/presence of LGSC are associated with significantly worse prognosis (HR compared to stage I: non-invasive implants – 1.8, invasive implant 6.6)
- Micropapillary SBT more likely to be associated with bilaterality, surface involvement, advanced stage, and invasive implants/LGSC
- For stage I SBT, both conventional and micropapillary variant are associated with a very favorable prognosis
- Micropapillary variant of SBT is not of clinical significance, independent of stage/implants

Ovarian Serous Borderline Tumours

- Extent of surgery
  - Fertility sparing an option but strong consideration to completion surgery after childbearing done, if > stage Ia
  - Node dissection not indicated (unless clinically involved, then “plucked”)
- INVASIVE IMPLANTS in SBT ARE NOW TERMED EXTRA-OVARIAN LGSC

Serous Tumors

(Pathogenesis - Dualistic model)

Benign → SBT → SBT-MP → Low-grade Serous Ca

KRAS and *BRAF* mutations (70%)

Tubal Intraepithelial Ca → High-grade Serous Ca

p53 mutations

BRCA1/2 loss of function

Chromosomal instability

Serous Borderline Tumour (SBT)

ORIGINAL ARTICLE

Long-term Behavior of Serous Borderline Tumors Subdivided Into Atypical Proliferative Tumors and Noninvasive Low-grade Carcinomas

A Population-based Clinicopathologic Study of 942 Cases

Russell Vang, MD,† Charlotte G. Hannibal, PhD,‡ Jette Junge, MD,§ Kirsten Frederiksen, PhD,‡ Susanne K. Kjaer, MD,‡‖ and Robert J. Kurman, MD*†¶*

Vang et al. AJSP 2017; 41:725

Serous Borderline Tumour

➔ 3-10% risk of recurrence; higher in incompletely staged

➔ 4% risk of malignant transformation

➔ Higher all-cause mortality

- ALL above occur irrespective of tumour morphology/stage
- All above can occur after long intervals
- At diagnosis there are few morphological or molecular parameters to predict poor outcome

Serous Borderline Tumour (SBT)

- Diagnosis
  - Usual
  - Micropapillary pattern
  - Microinvasion
- Implant morphology
- Nodal involvement: upstage but do not imply adverse outcome
- Stage

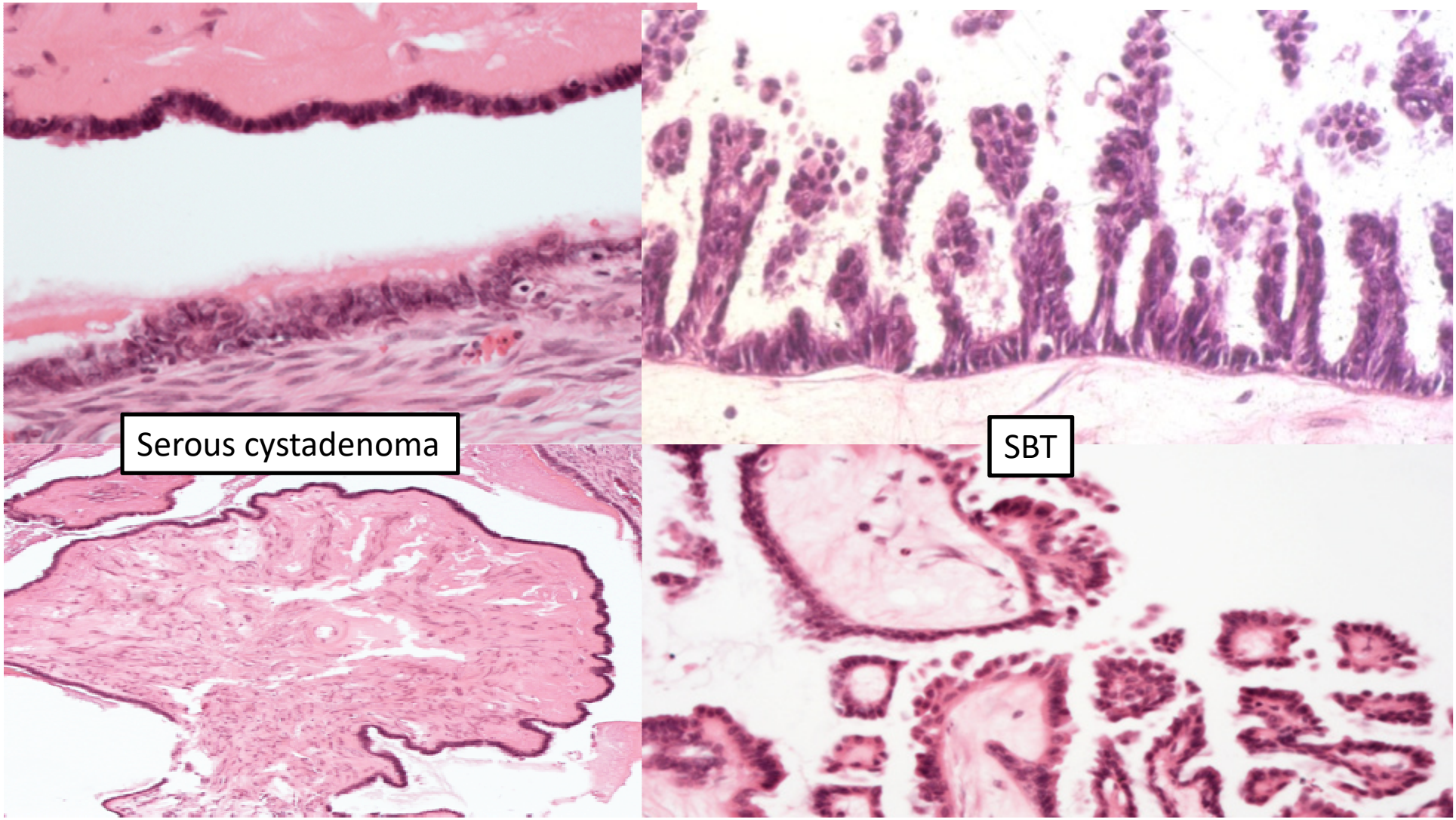
Serous cystadenoma
SBT

SBT diagnosis

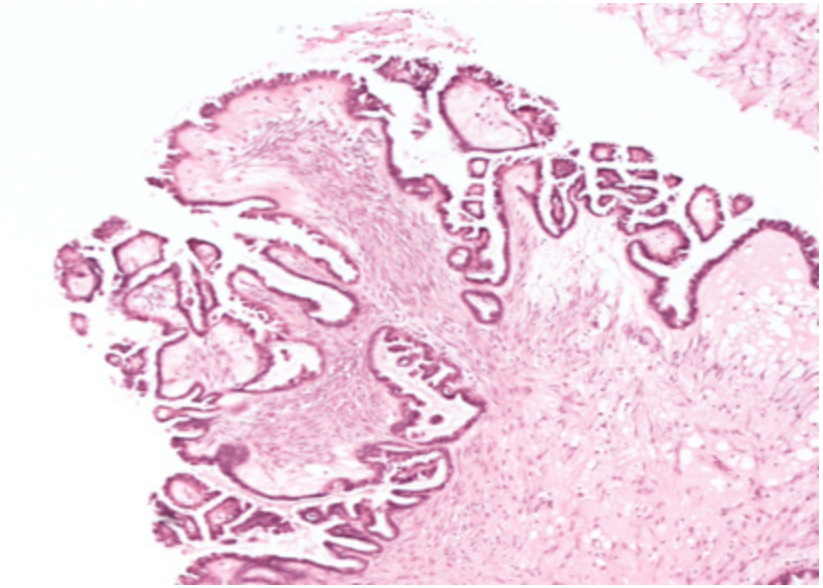

- ARCHITECTURAL features: tufts, detachment of cell groups
- >10% of epithelium

CAREFUL in presence of

- Surface involvement
- Necrosis/infarction

Microinvasion

Eosinophilic cell pattern (most reported cases)

- Single cells or cell clusters with eosinophilic cytoplasm
- Surrounding stroma usually normal, but may have clefts

Other patterns (infrequently reported)

- Solid or cribriform masses, branching papillae, filiform papillae, macropapillae, stromal response, alone or in combination

SBT: Microinvasion, typical

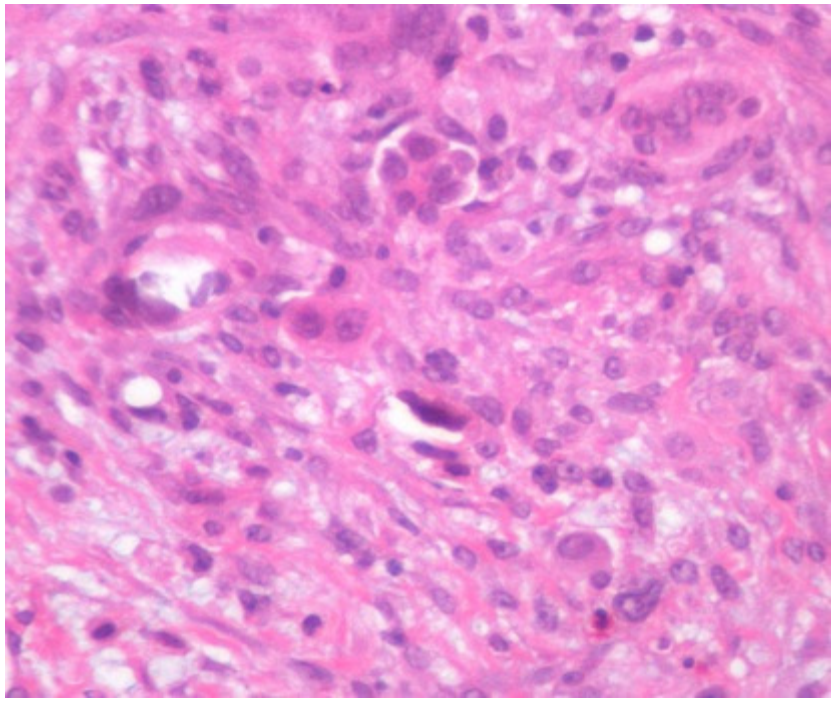

- Single cells or small papillae surrounded by cleft
- <5mm in longest dimension
- <10mm^2 in area
- No adverse impact on prognosis
- Terminally diff, senescent, low Ki67

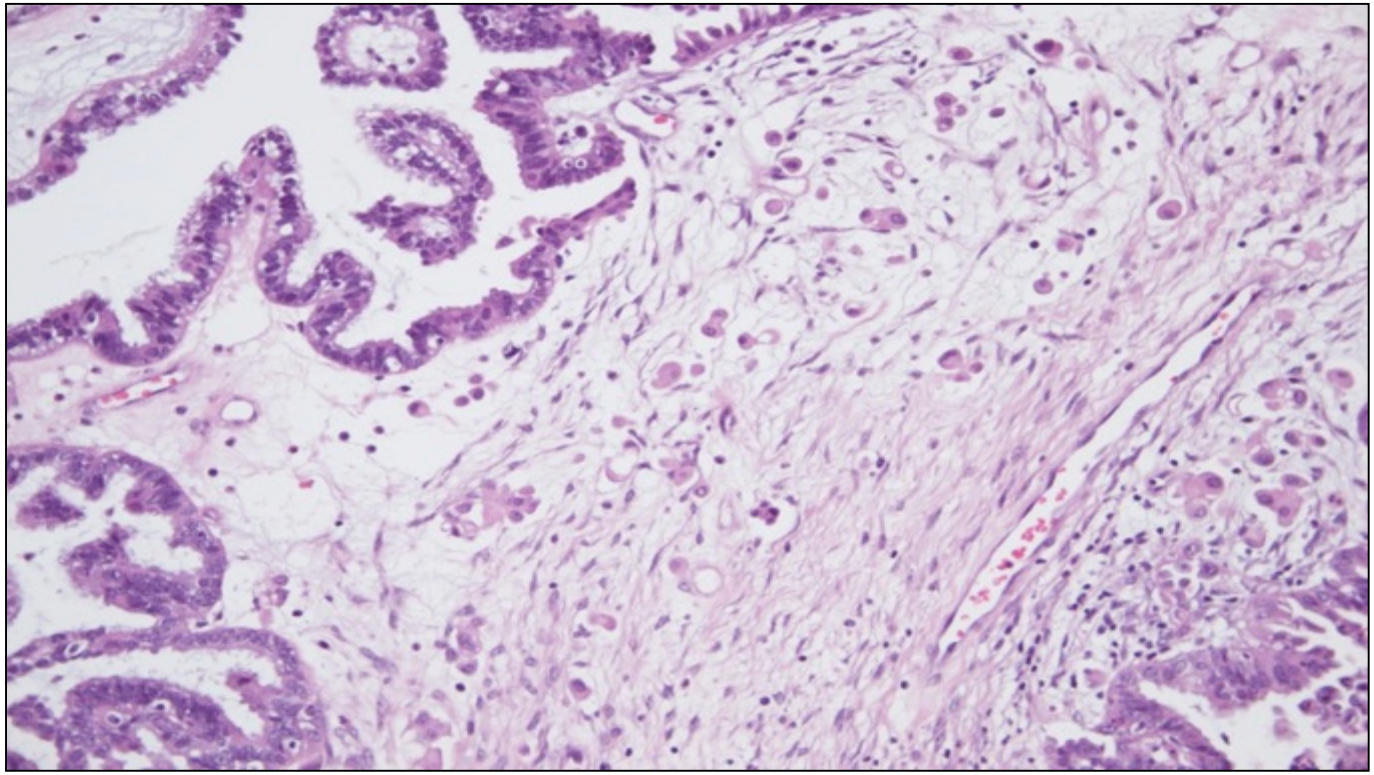

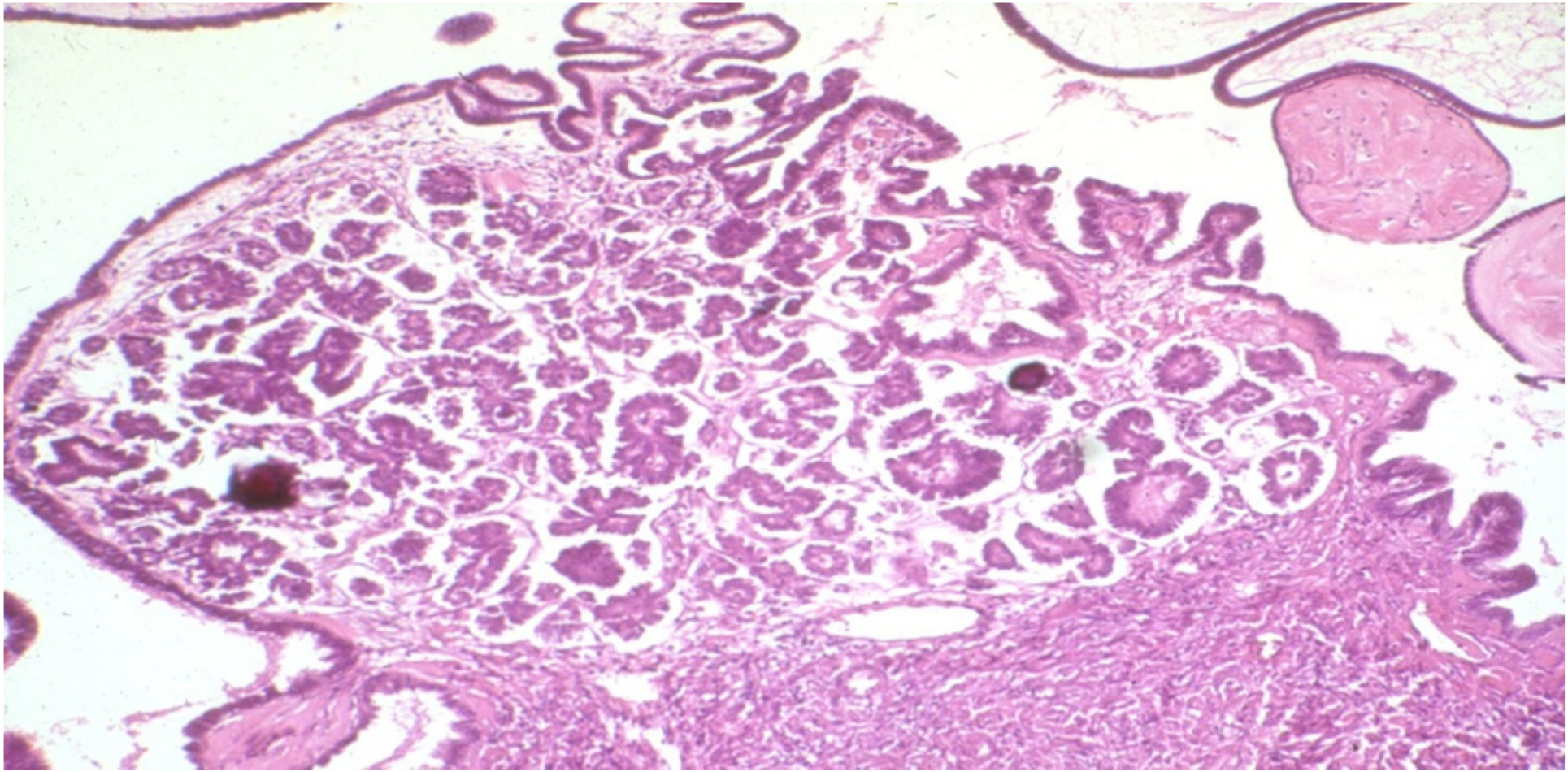

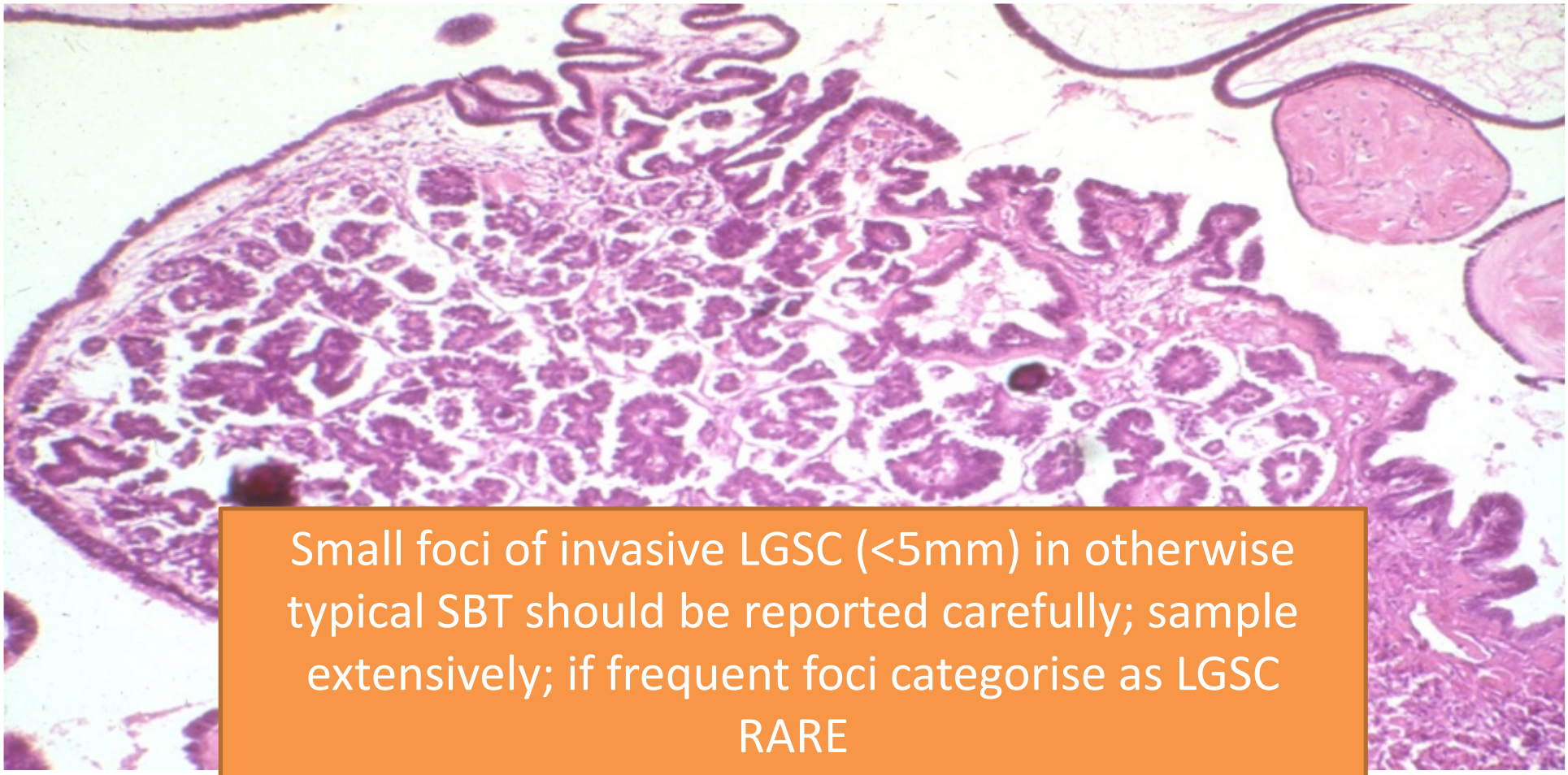

Small foci of invasive LGSC (<5mm) in otherwise typical SBT should be reported carefully; sample extensively; if frequent foci categorise as LGSC

RARE

Some categorise as ‘microinvasive’

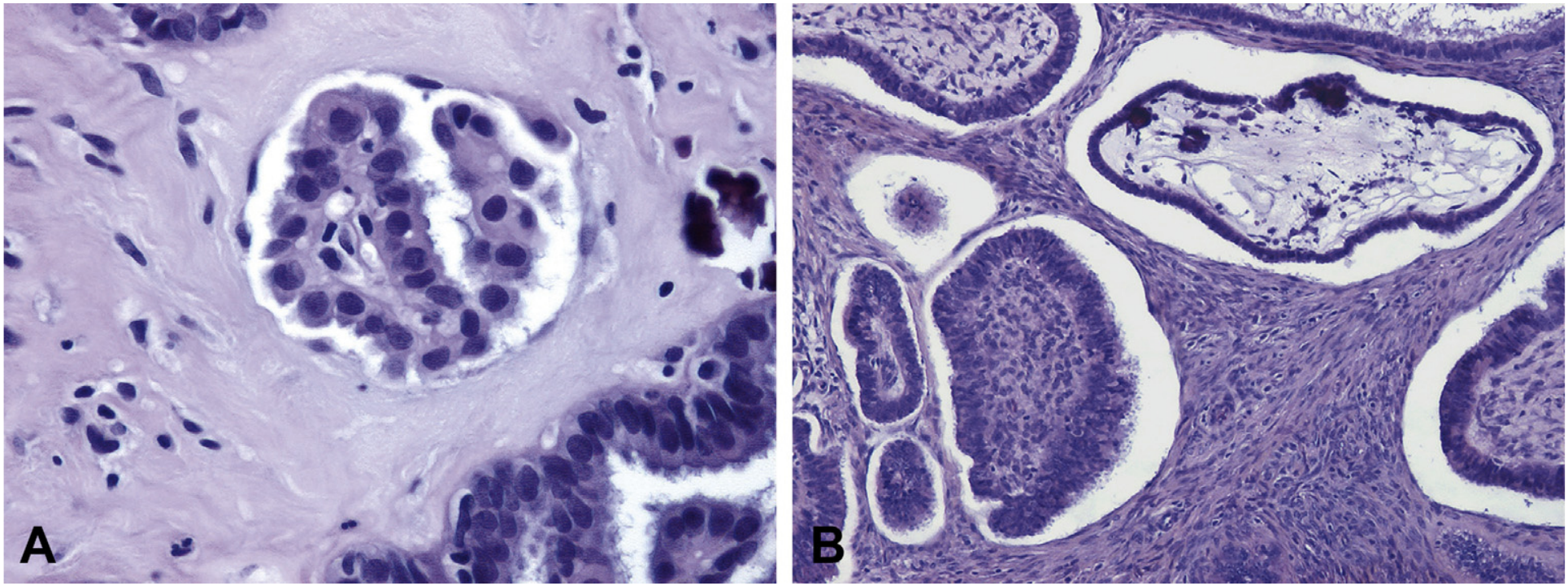
A
B

SBT micropapillary pattern (8% of SBT)

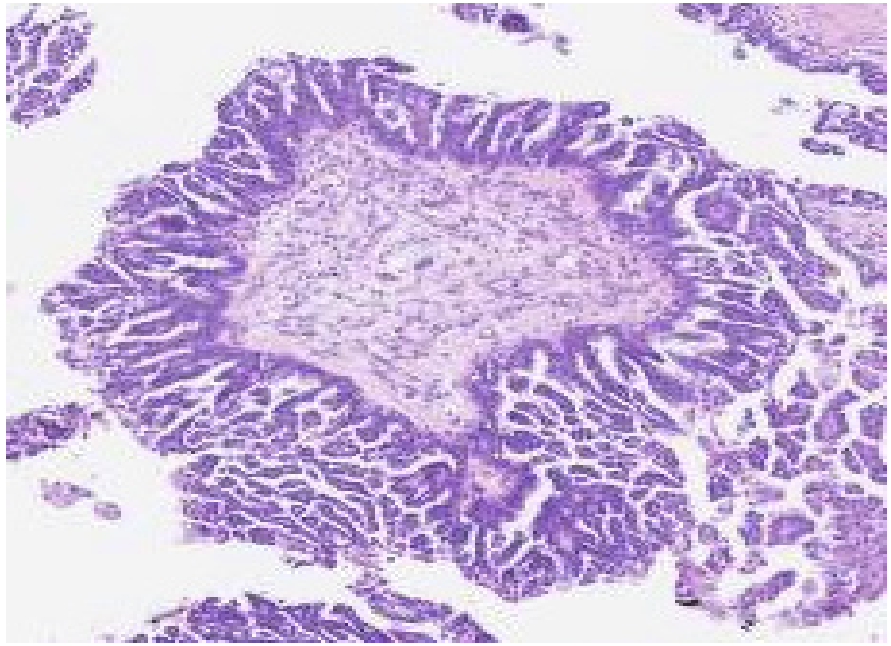

- Micropapillae 5x as tall as wide; >5mm in any one section
- May be cribriform
- ↑ Invasive implants (LGSC)
- Also ↑ LGSC with stage I disease
- → important to distinguish apart from association with invasive implants
- (v few outcomes)

Am J Surg Pathol. 2017 Jun;41(6):725-737

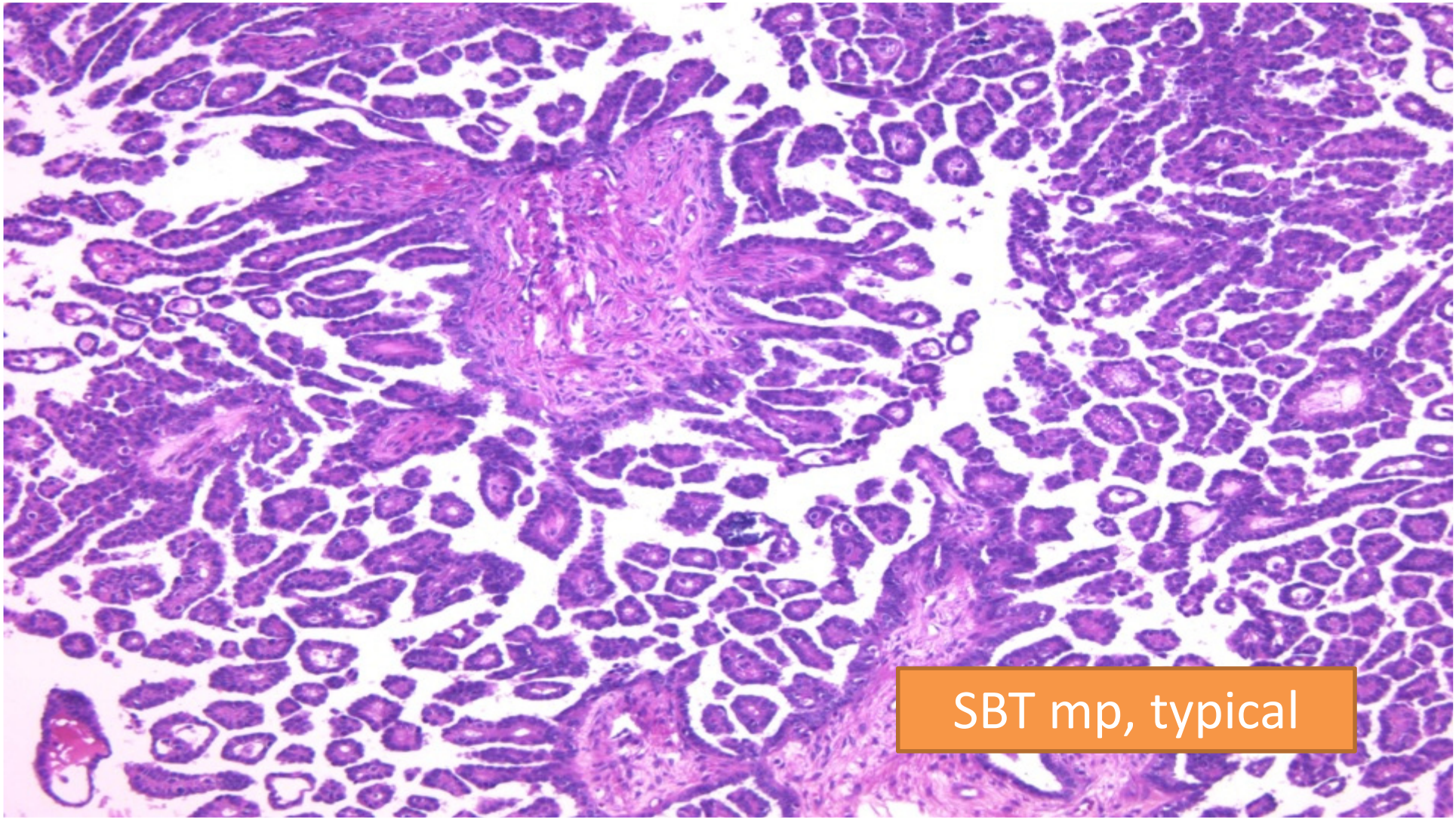
SBT mp, typical

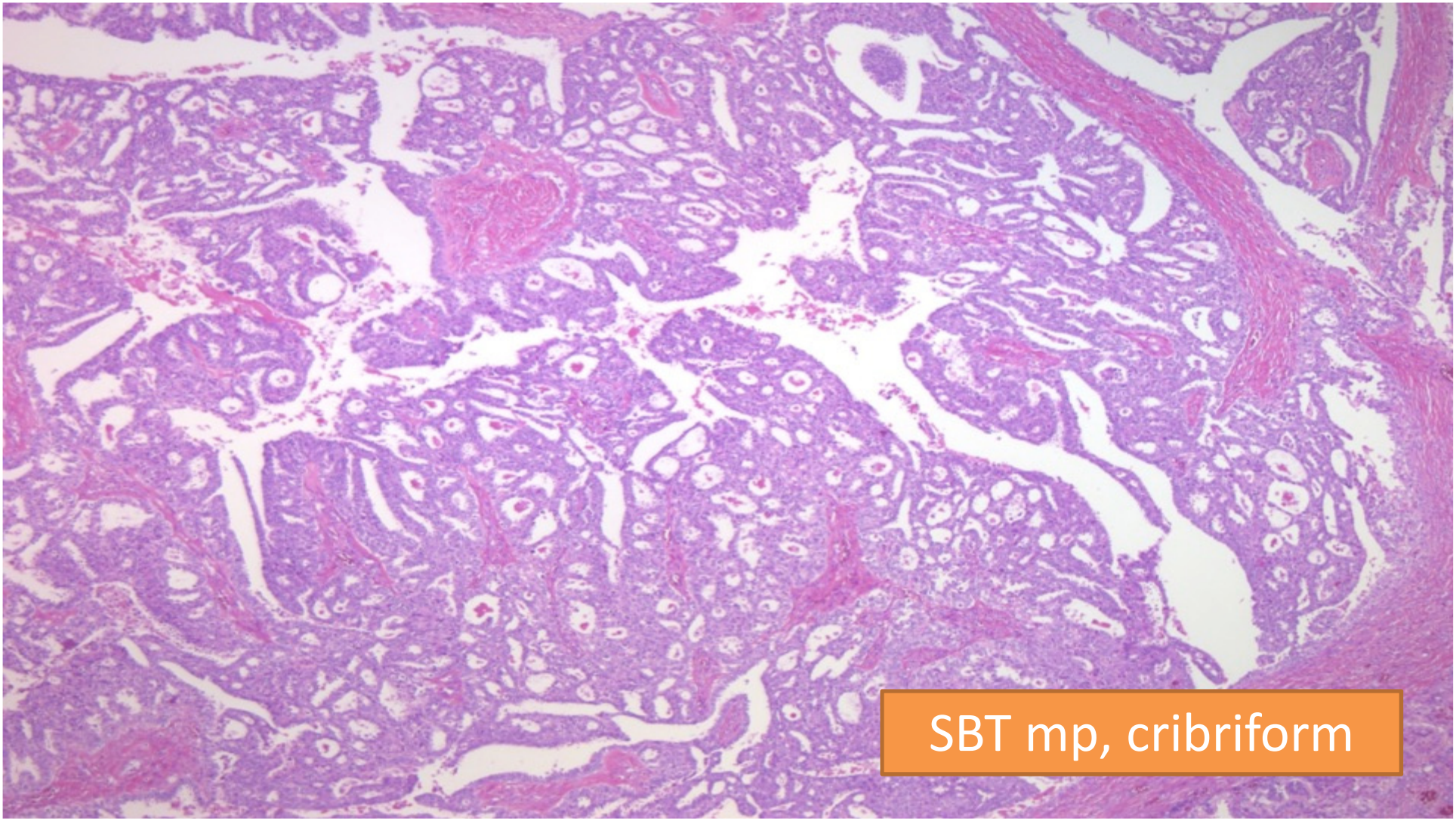
SBT mp, cribriform


SBT mp cytology: uniform nuclei, slightly more pleomorphic than usual SBT

SBT Micropapillary

Significantly higher rate of :

- Bilaterality
- Microinvasion
- Residual gross disease at end of surgery
- Stage >I
- Invasive implants (in advanced stage cases)
- For Stage 1 tumours, progression to LGSC is uncommon:
  - 13/754 (1.7%) with conventional SBT
  - 4/55 (7.3%) with micropapillary SBT
  - (no difference in OS; HR 1.0 vs 1.1)

Micropapillary architecture summary

- Sample primary tumor extensively
- Designate borderline, micropapillary type (non-invasive LGSC is used as a synonym in WHO 2014 but NOT advocated)
- ***Examine extraovarian disease for invasion***
- Stage I cases have an excellent prognosis
- Stage II and III cases without invasive implants have an excellent prognosis after surgery alone
- Poorer outcomes related to high stage and greater frequency of invasive extra-ovarian disease

SBT: Extra-ovarian manifestations

- **'INVASIVE IMPLANTS' ARE NOW TERMED EXTRA-OVARIAN LGSC**
  - **RARE (8% of all stage II+ SBT; 50% of all stage II+ mpSBT)**

- ie 'IMPLANTS' are NON-INVASIVE, may be
  - Epithelial
  - Desmoplastic

SBT: Extra-ovarian LGSC (previously ‘invasive implant’)

- Destructive invasion: irregular, aggressive-appearing infiltration into underlying tissue with tumor replacing or destroying it.
- To recognize invasion in omental biopsies there must be obliteration of omental tissue
- Presence of small papillae or single tumor cells within abundant desmoplastic stroma is not interpreted as stromal invasion
- Small superficial biopsy specimens of desmoplastic implants in which underlying tissue is absent are classified as noninvasive on the assumption that they have been easily stripped away from underlying tissue.

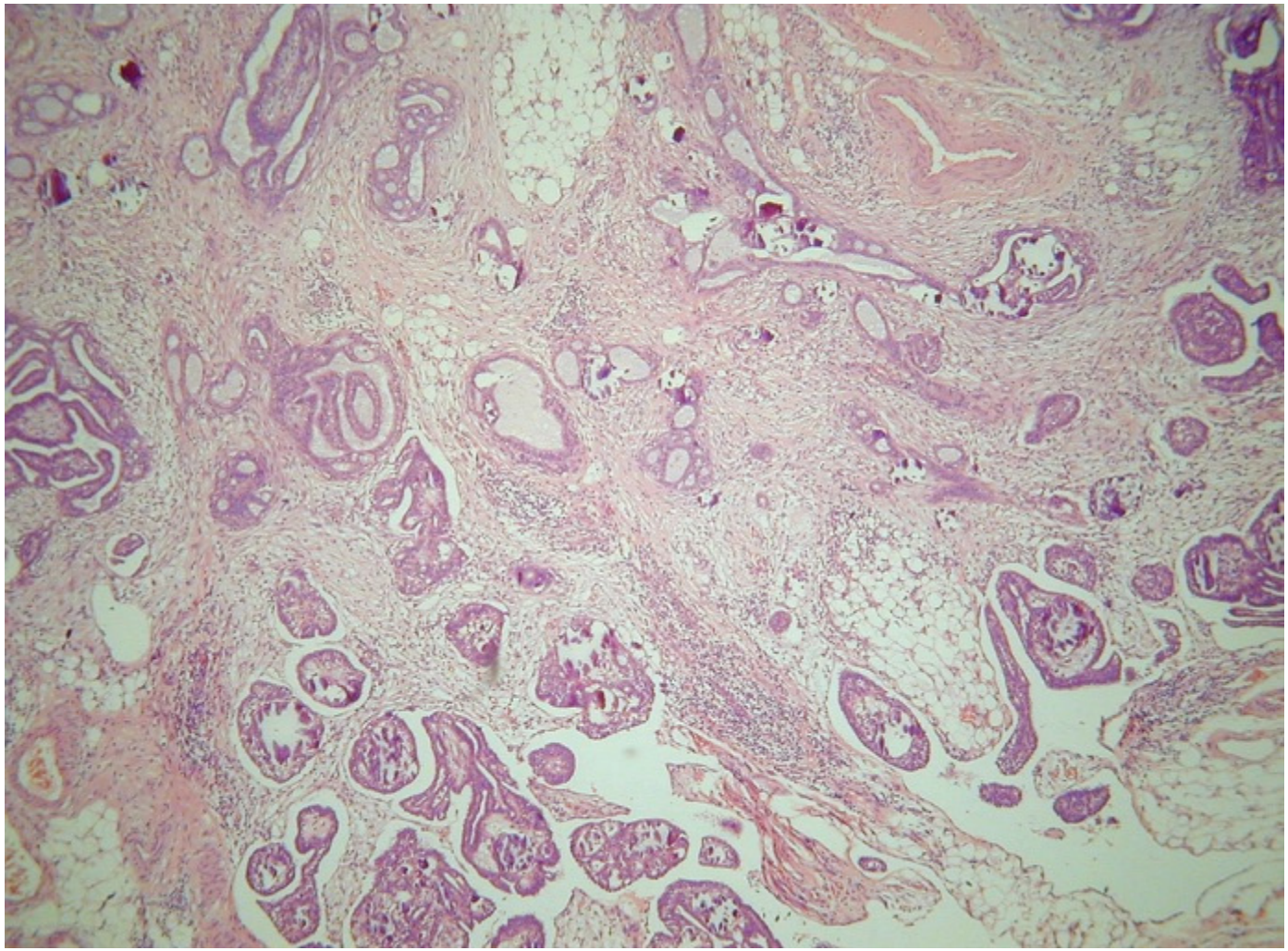

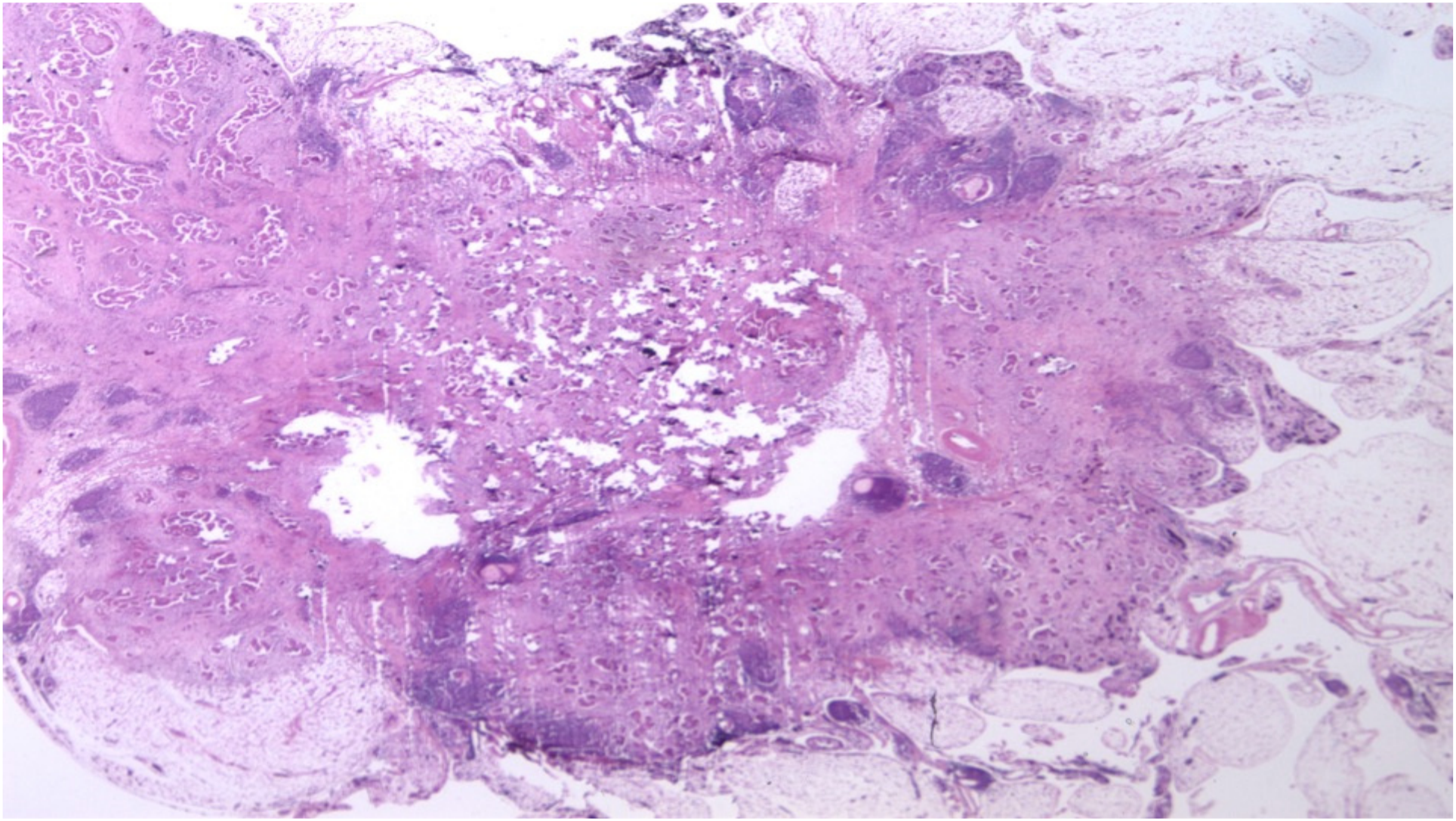

A

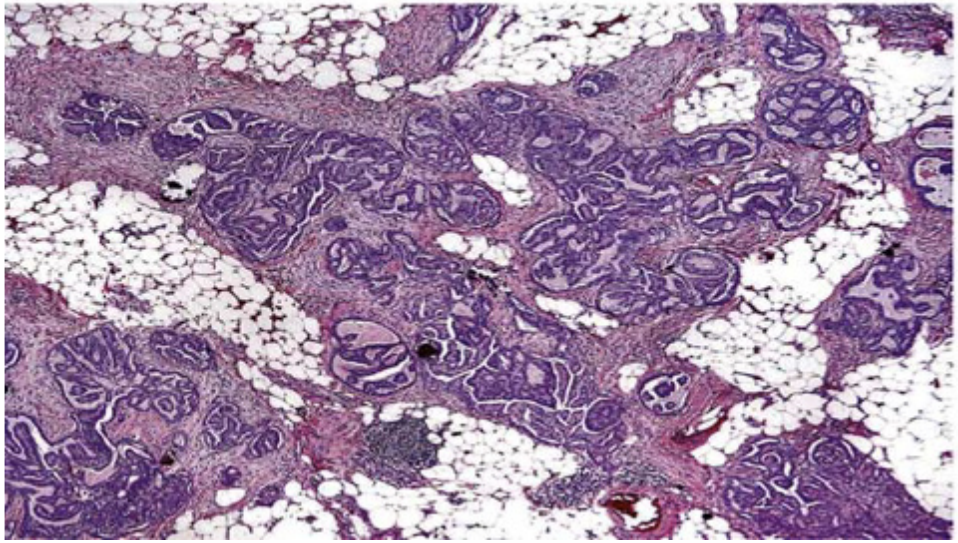

B

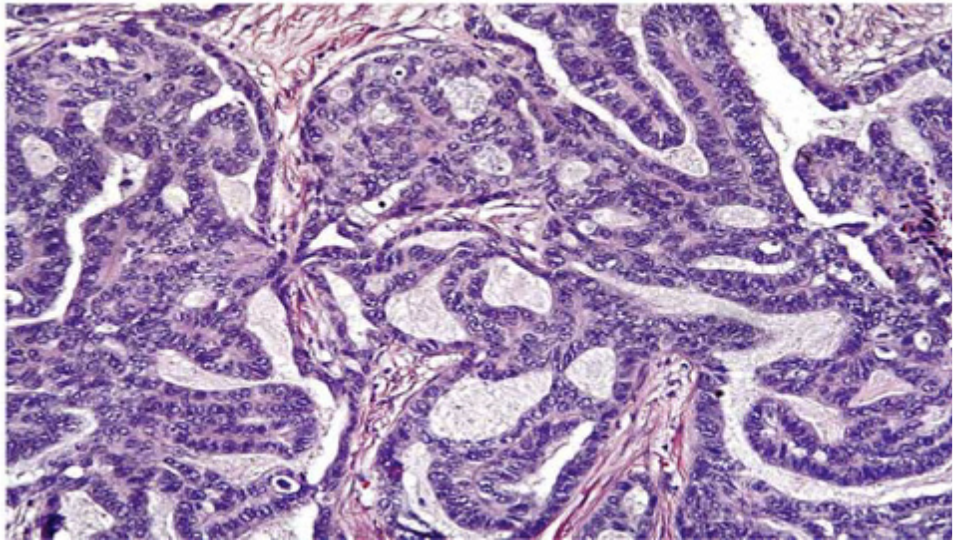

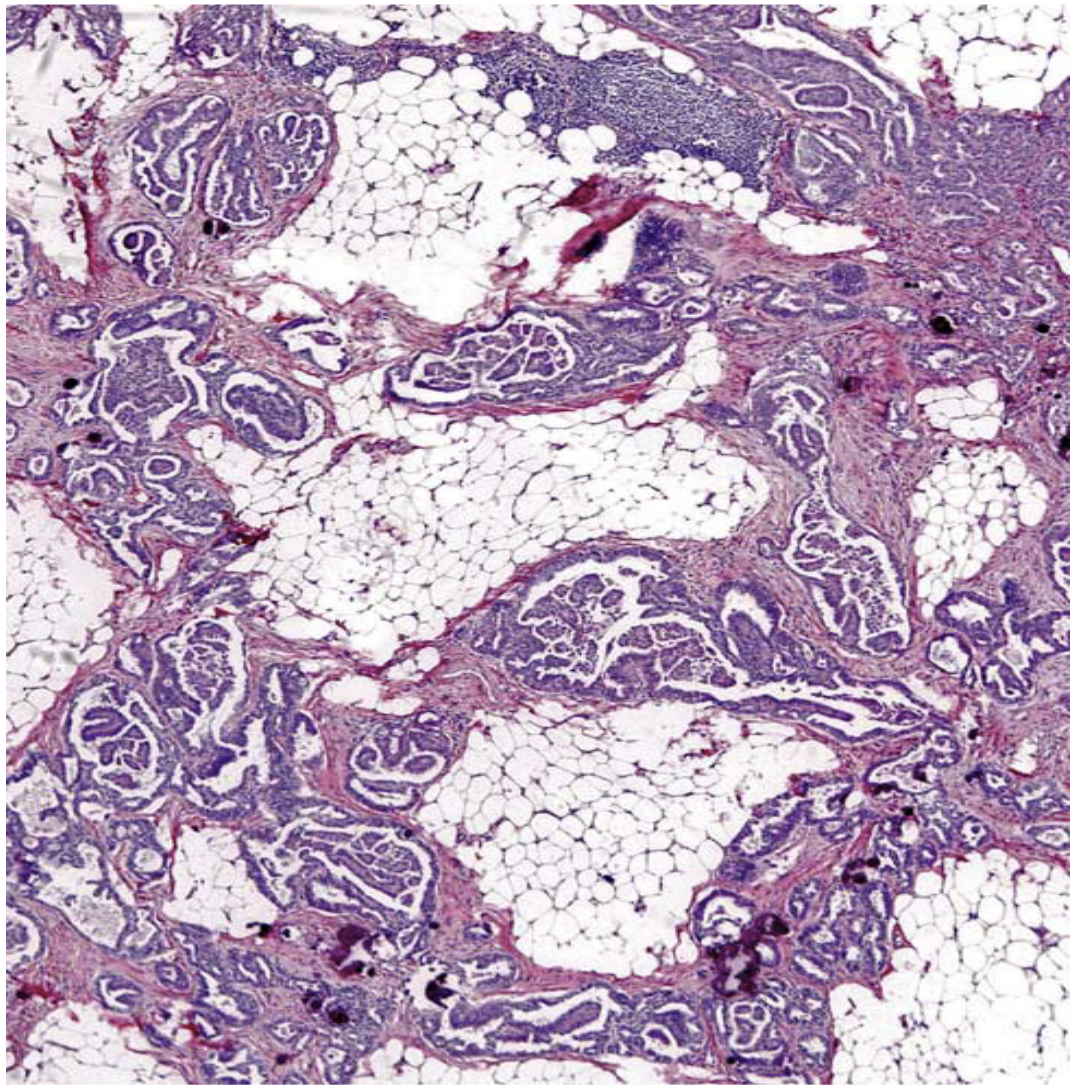

SBT: (Non-invasive) Implants

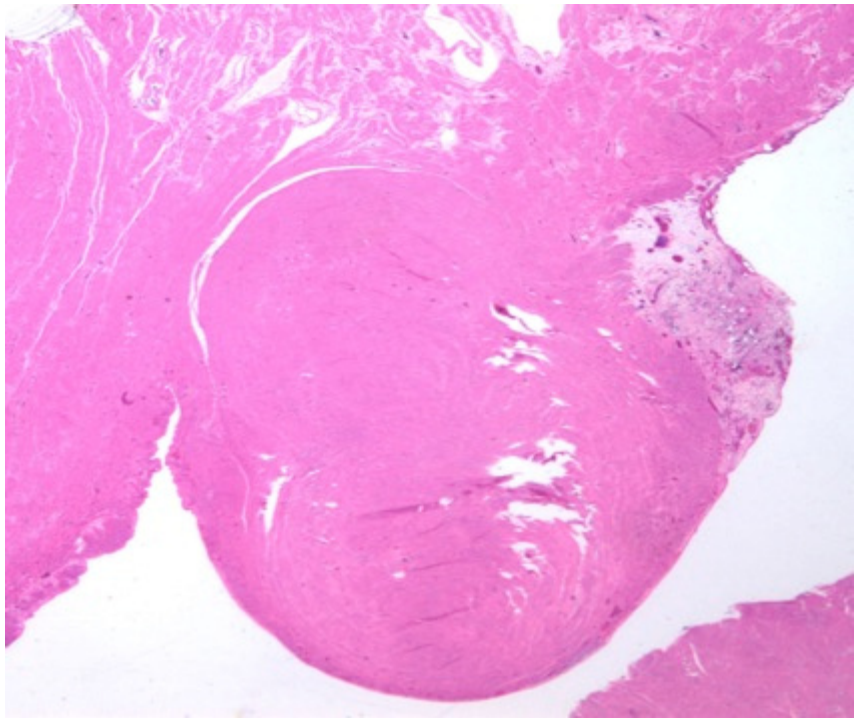

- 86% extra-ovarian disease in advanced stage SBT are non-invasive implants
- 92% in usual SBT
- 50% in mpSBT
- Non-invasive implants also have risk of subsequent Ca
- Include in staging

NON-INVASIVE EPITHELIAL

- papillary formations of epithelial cells without invasion of underlying tissues
- looks like borderline tumour in ovary ("dropped off")

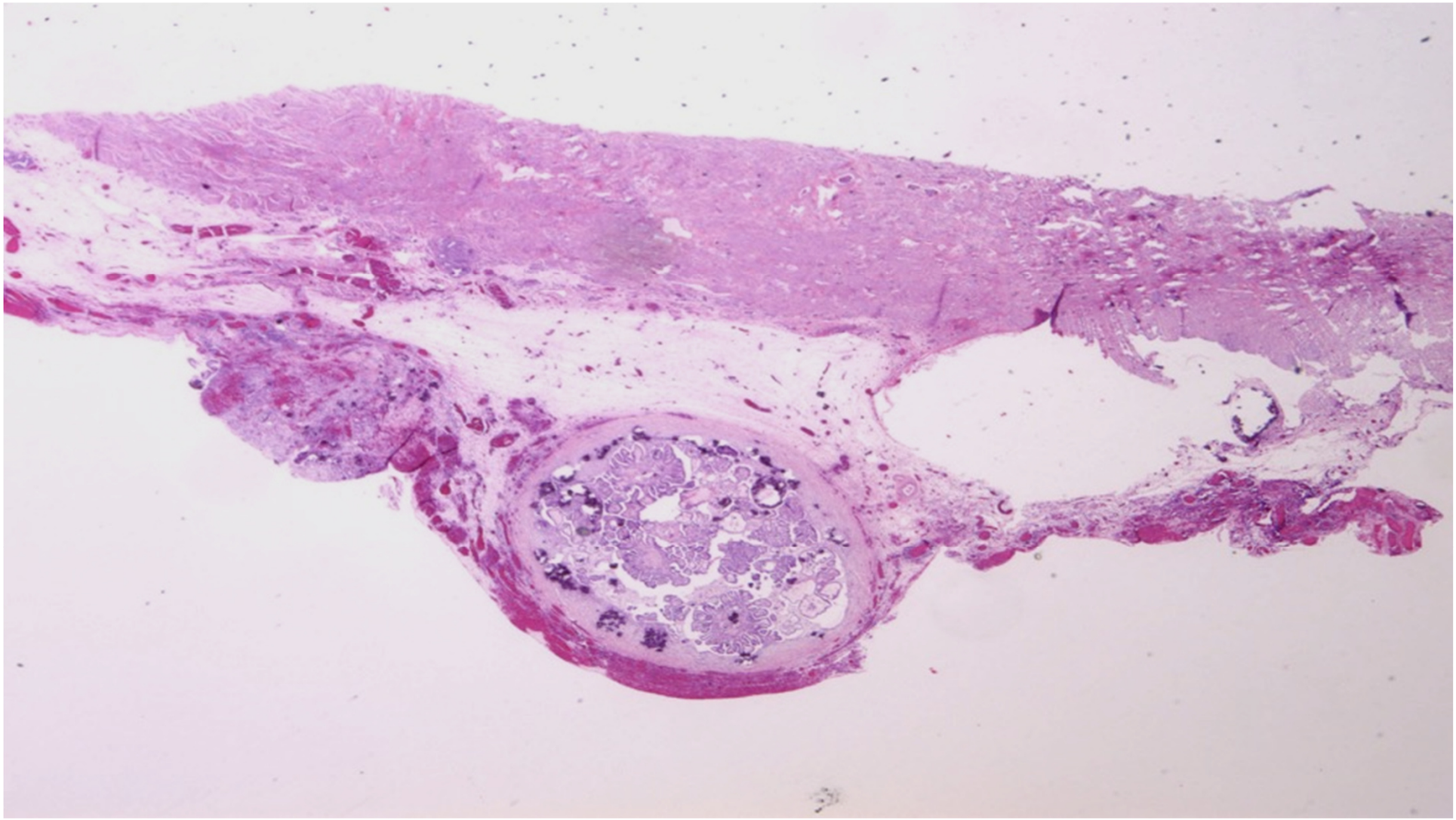

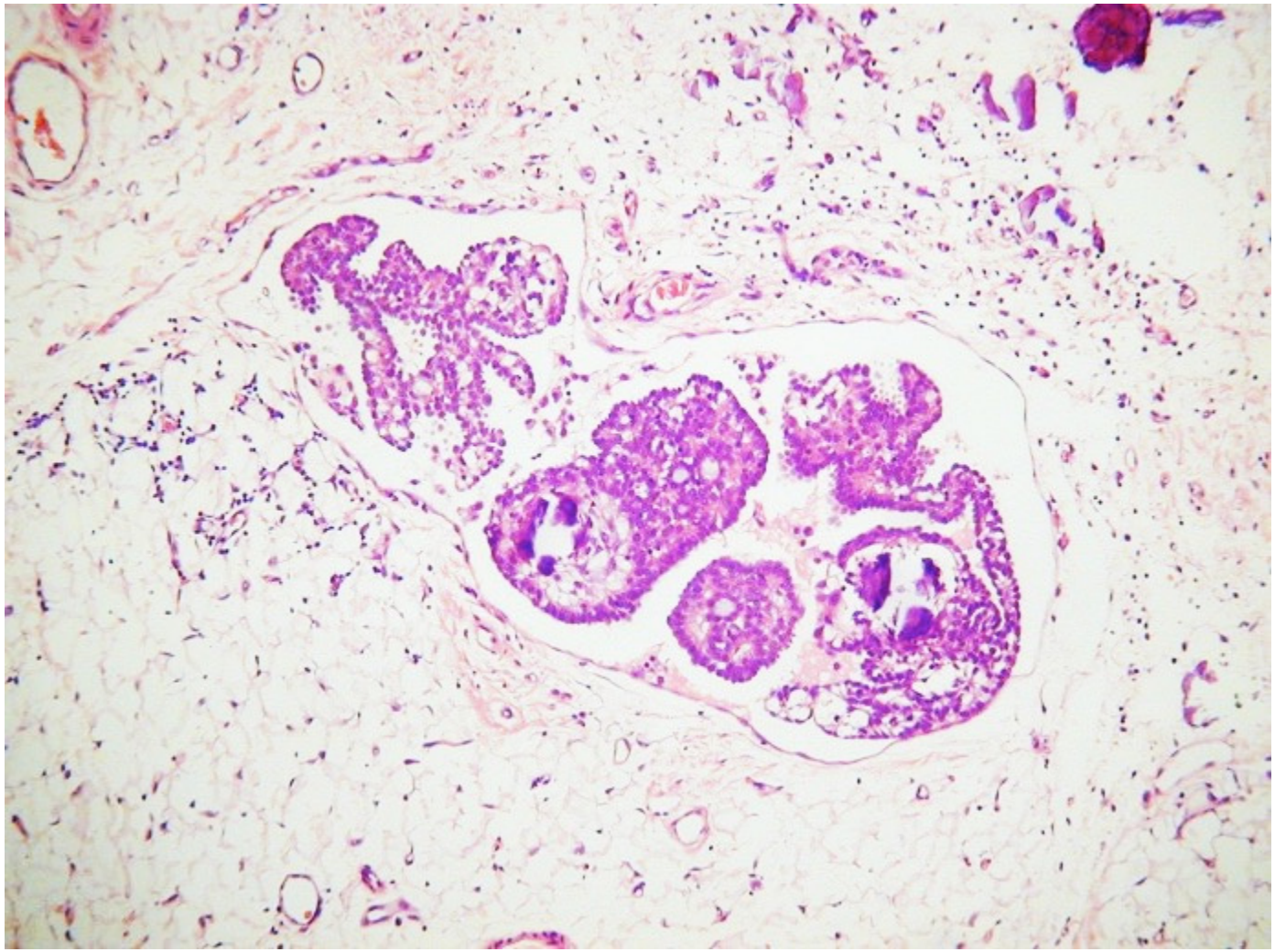

NON-INVASIVE DESMOPLASTIC

- located on surface without invasion of underlying tissues (often don’t see underlying tissue-stripped off)
- may extend into septa of omentum
- glands lined by mildly atypical cells
- embedded in abundant fibrous tissue (often “granulation tissue-like”)
- may have lot of necrosis in “early” lesions

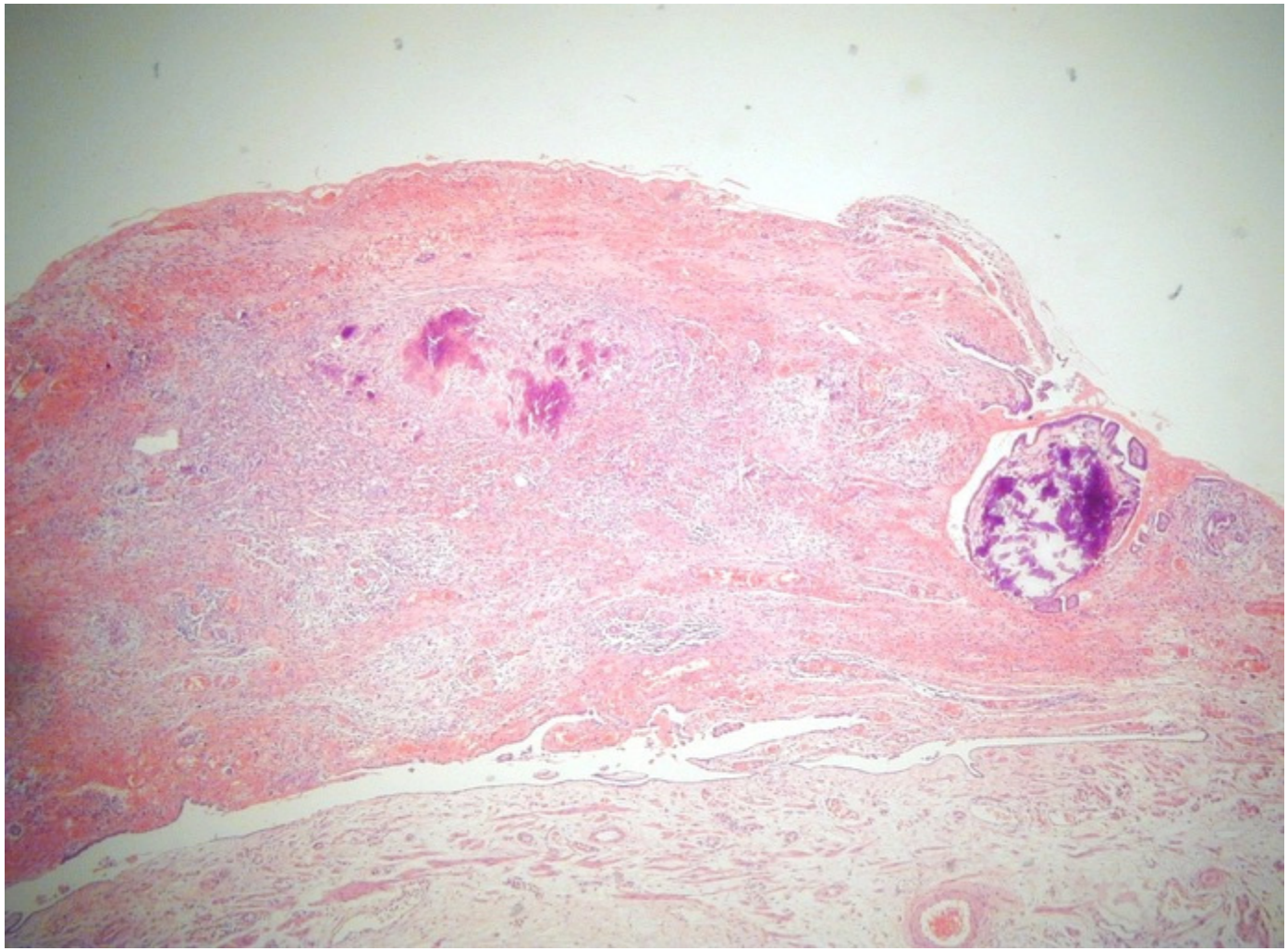

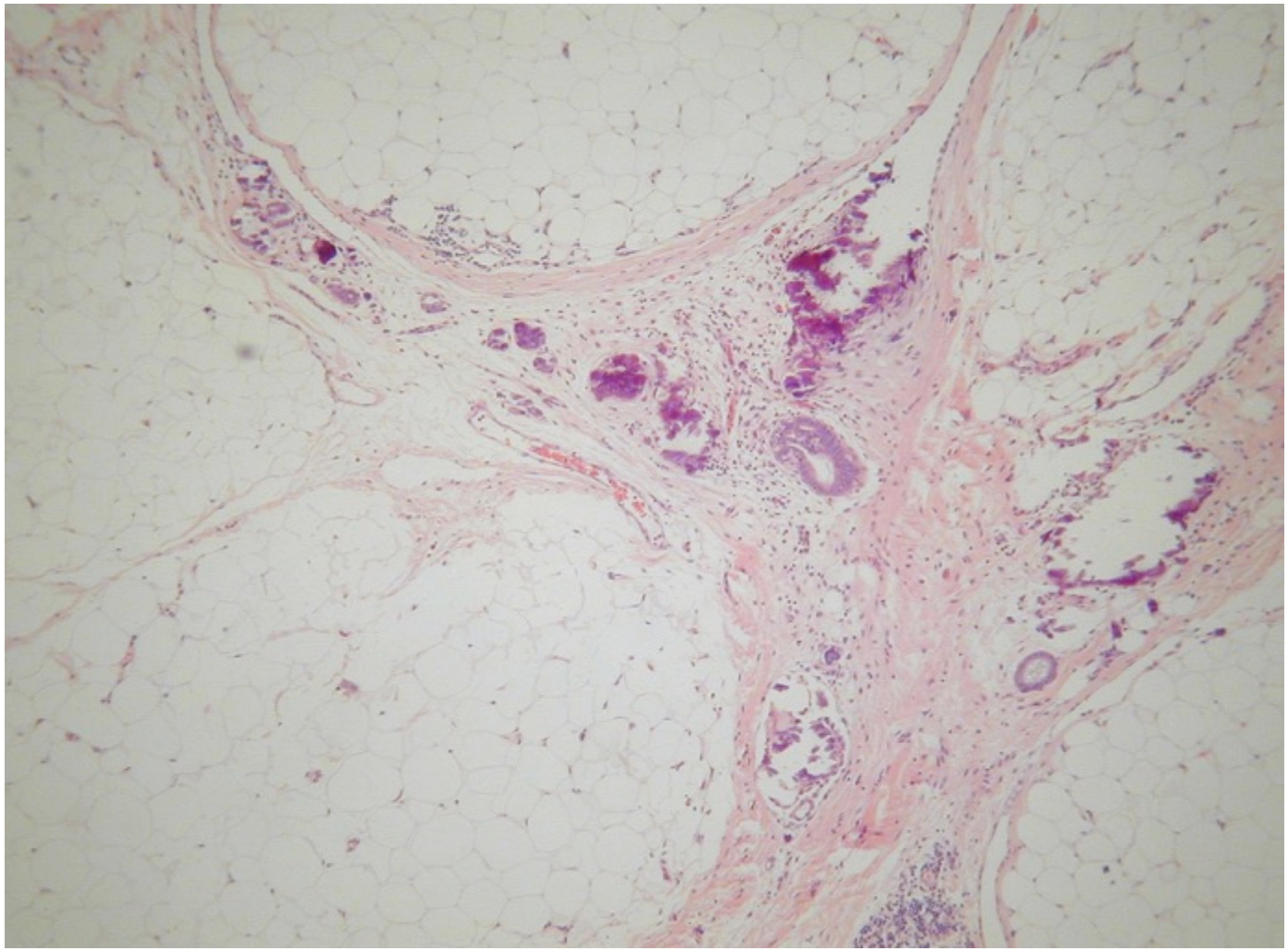

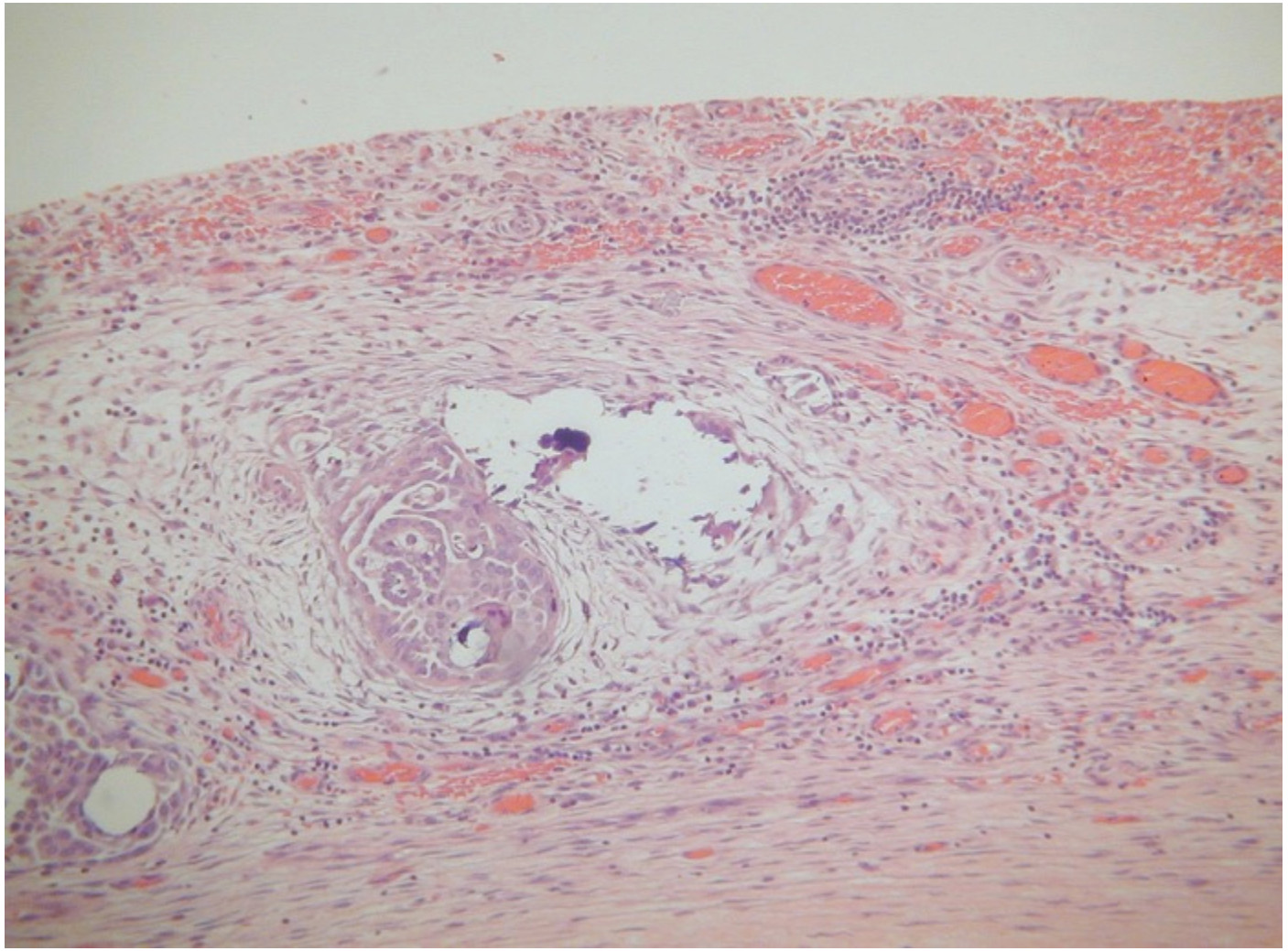

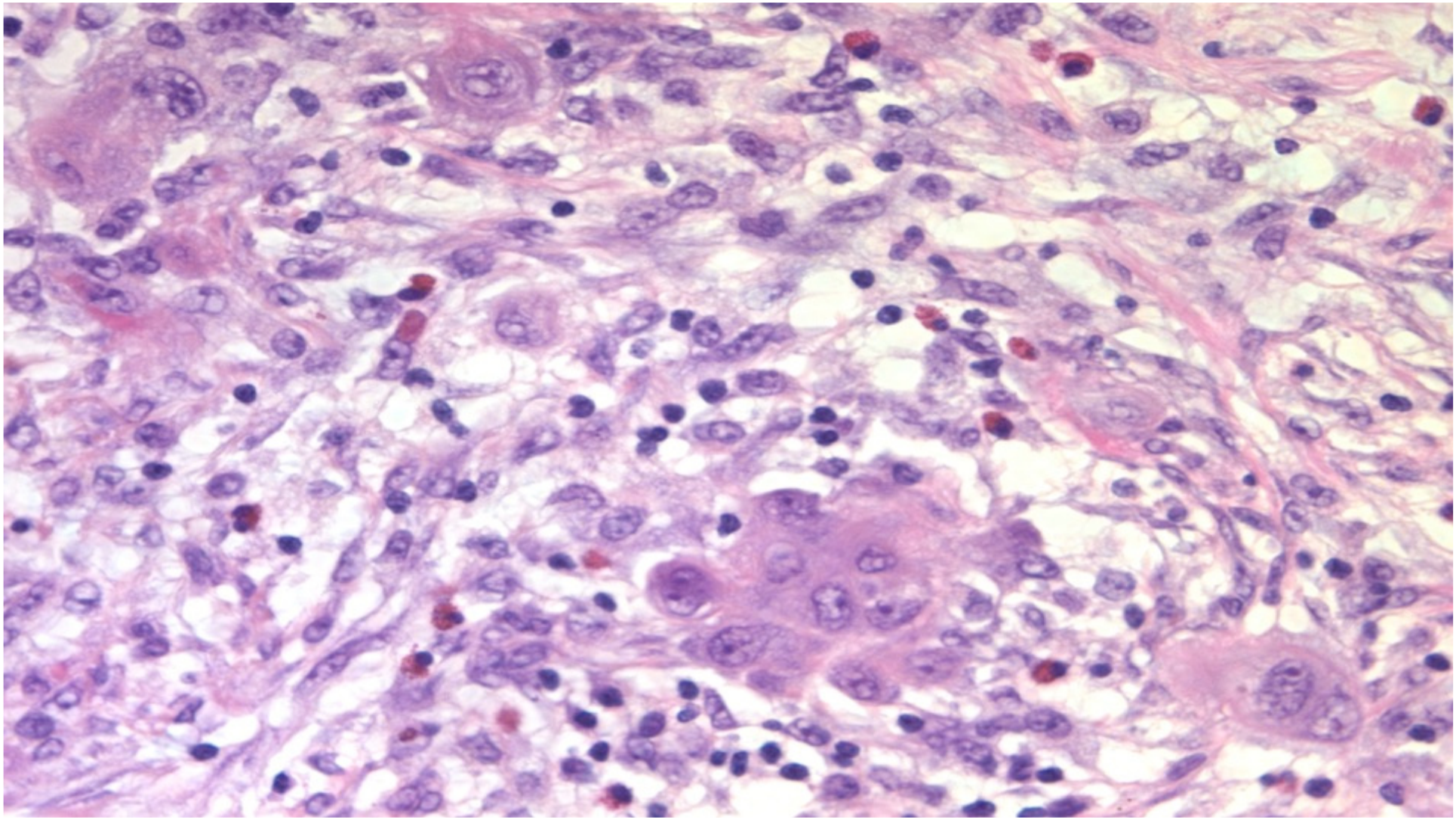

ORIGINAL ARTICLE

Classification of Extraovarian Implants in Patients With Ovarian Serous Borderline Tumors (Tumors of Low Malignant Potential) Based on Clinical Outcome

Jesse K. McKenney, MD, C. Blake Gilks, MD,† Steve Kalloger, MSc,† and Teri A. Longacre, MD**

A minority of cases:

- demonstrate interfaces indeterminate for omental invasion and
- fail to demonstrate unequivocal proliferative/cytologic features of LGSC
- Classification as “indeterminate” is warranted
- Associated with an intermediate prognosis between noninvasive and invasive implants

AJSP 2016; 40:1155

Indeterminate implants

- Focal encroachment into underlying or adjacent parenchymal tissue, imparting a subtle irregular interface at low power magnification or
- Focal micropapillary architecture but no evidence of infiltration into underlying parenchyma (i.e., exhibit a smooth interface) or
- No evidence of infiltration into underlying parenchyma, but with cytological atypia that exceeds that of the usual implant (i.e., moderate atypia, insufficient to warrant a diagnosis of carcinoma)

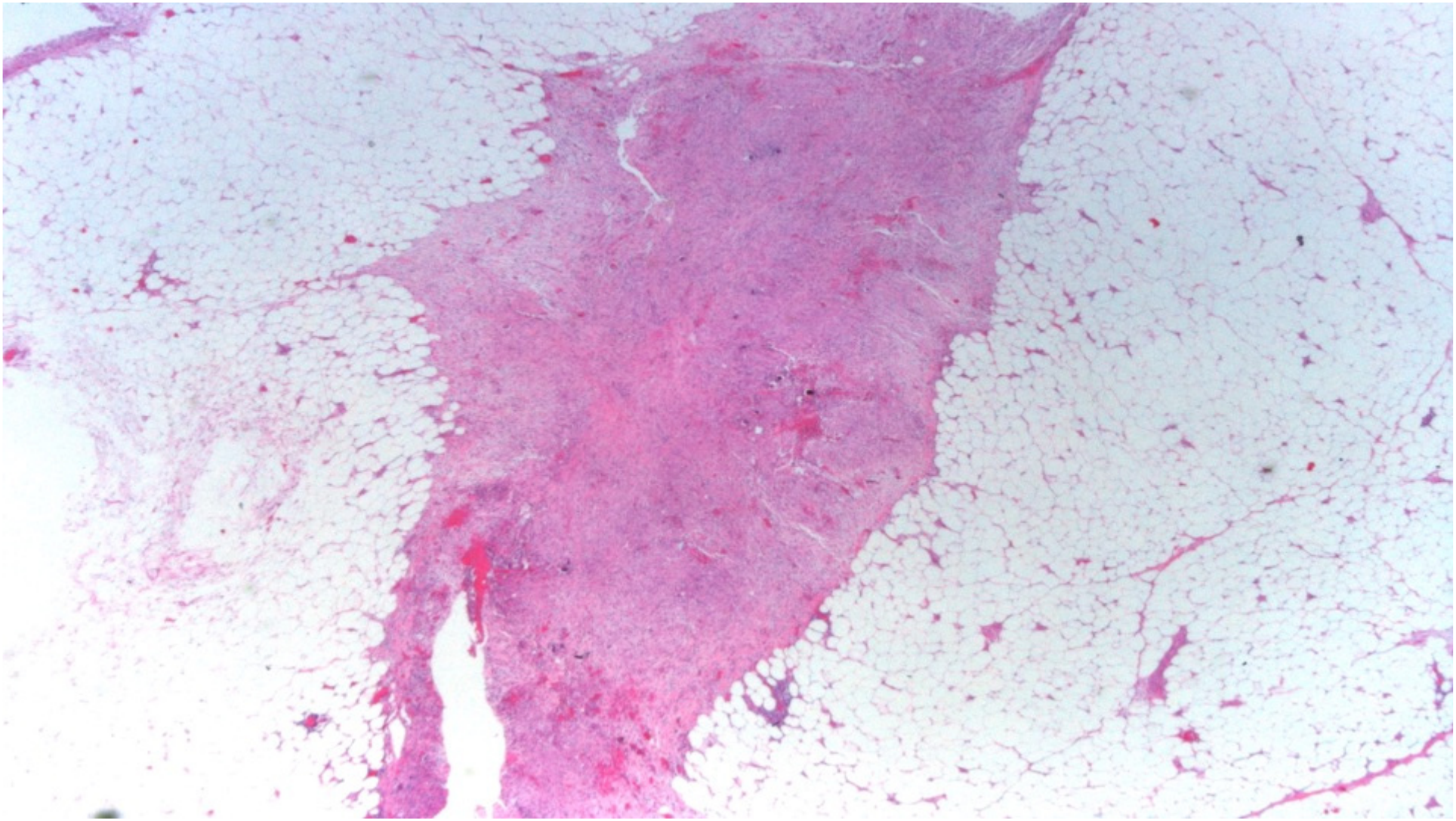

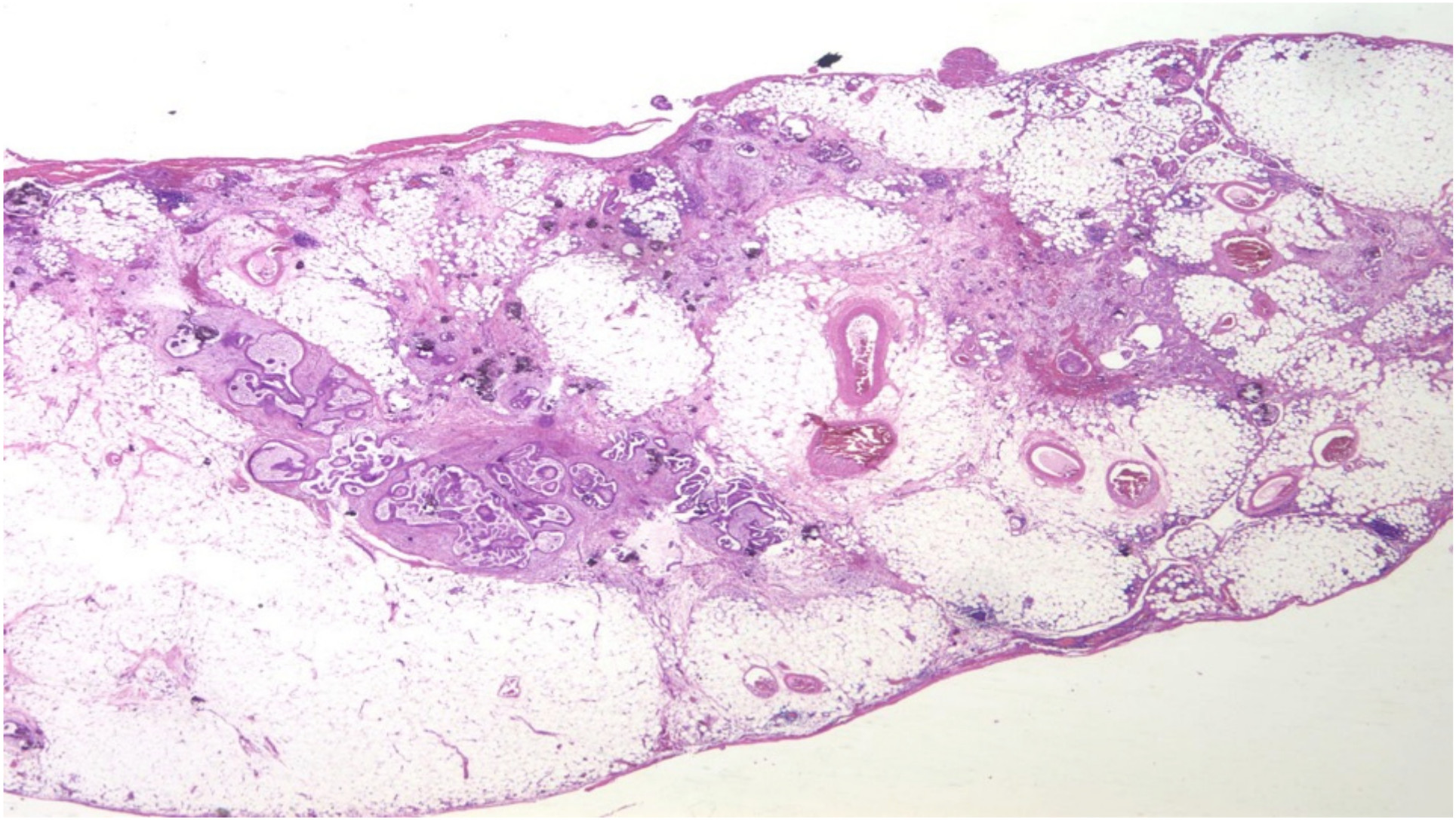

ORIGINAL ARTICLE

Classification of Extraovarian Implants in Patients With Ovarian Serous Borderline Tumors (Tumors of Low Malignant Potential) Based on Clinical Outcome

Jesse K. McKenney, MD, C. Blake Gilks, MD,† Steve Kalloger, MSc,† and Teri A. Longacre, MD**

- Presence of invasive implant should be confirmed by at least 2 pathologists, one of whom is an experienced gynae pathologist

AJSP 2016; 40:1155

SBT: Nodal involvement

- 15% SBT upstaged due to LNI
- Variety of patterns:
  - individual cells/clusters of cells/simple, nonbranching papillae
  - intraglandular
  - cells with prominent cytoplasmic eosinophilia ("eosinophilic cell" pattern)
  - micropapillary pattern
- Diffuse or focal with discrete nodular aggregates
- Associated with nodal endosalpingiosis
- No difference in survival LNI vs no LNI
- Discrete nodular aggregates >1mm associated with worse survival

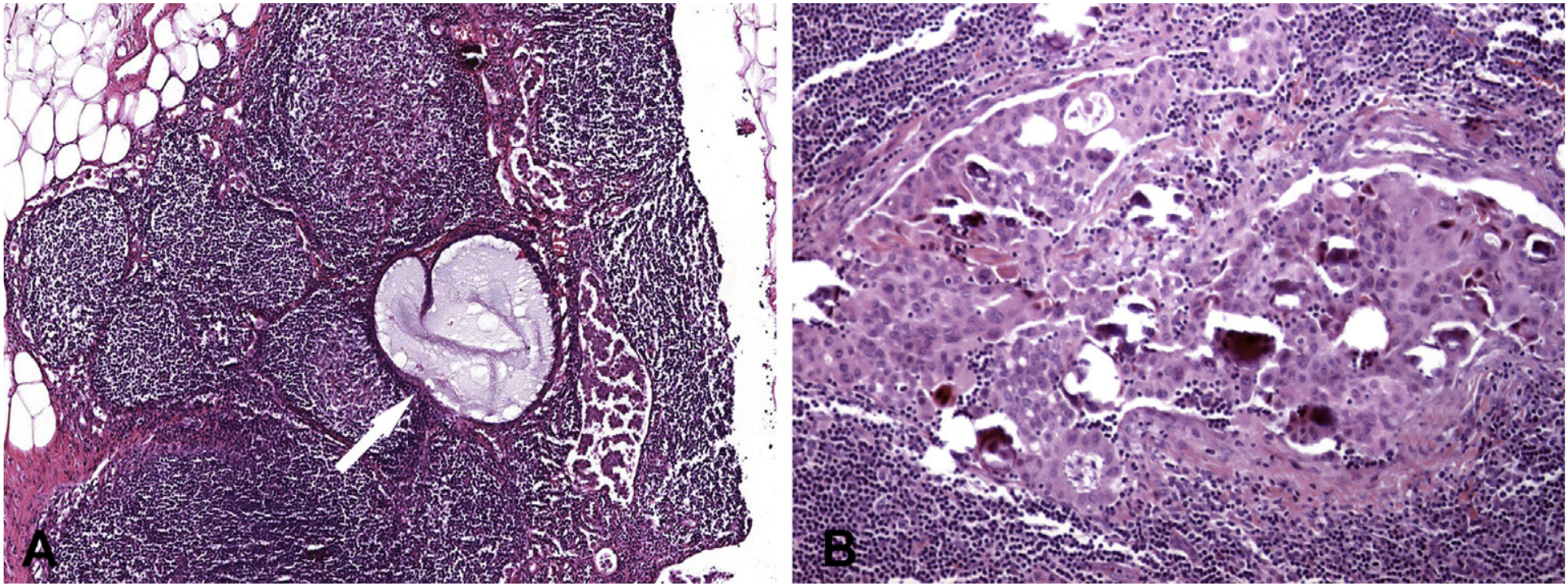
A
B

Staging of SBT

- Staged as carcinoma
- Non-invasive implants and nodal involvement are included in staging of SBT and LGSC (include comment if all extra-ovarian disease is non-invasive)
- If LGSC based on extra-ovarian disease, list the sites and nature of disease; indicate volume of invasive component and site(s)

Endosalpingiosis is common in SBT-LGSC spectrum; not included in stage; ?associated with higher chance of recurrence

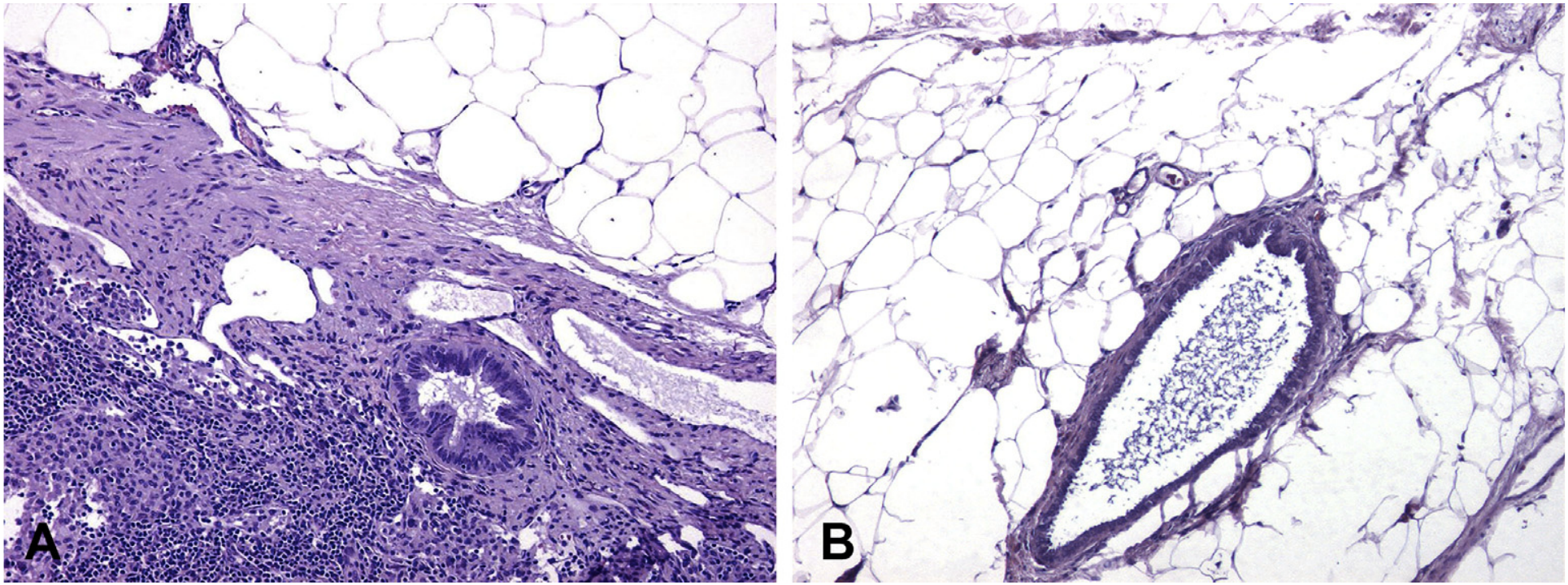

SBT summary

- **Stage and assessment of invasiveness of extraovarian disease are the most important prognostic indicators in SBT**
- INVASIVE IMPLANTS ARE NOW TERMED EXTRA-OVARIAN LGSC
- ie ‘IMPLANTS’ are NON-INVASIVE, may be epithelial/desmoplastic
- Micropapillary pattern is associated with a higher likelihood of extra-ovarian disease and LGSC
- Criteria for diagnosis of invasive implants are reproducible
  - Based on low power destructive tissue invasion
  - Be conservative (i.e. most patients will not have invasive implants)
  - Second opinion in difficult cases; consider classifying as ‘indeterminate’

Thank you