Case Presentation: Epithelial Neoplasia

Naveena Singh, Case 6

June 28, 2019

N Singh Case 6: History

- 48F
- Ovarian mass
- Raised inflammatory markers
- Emergency laparotomy

N Singh Case 6: Ovarian mass

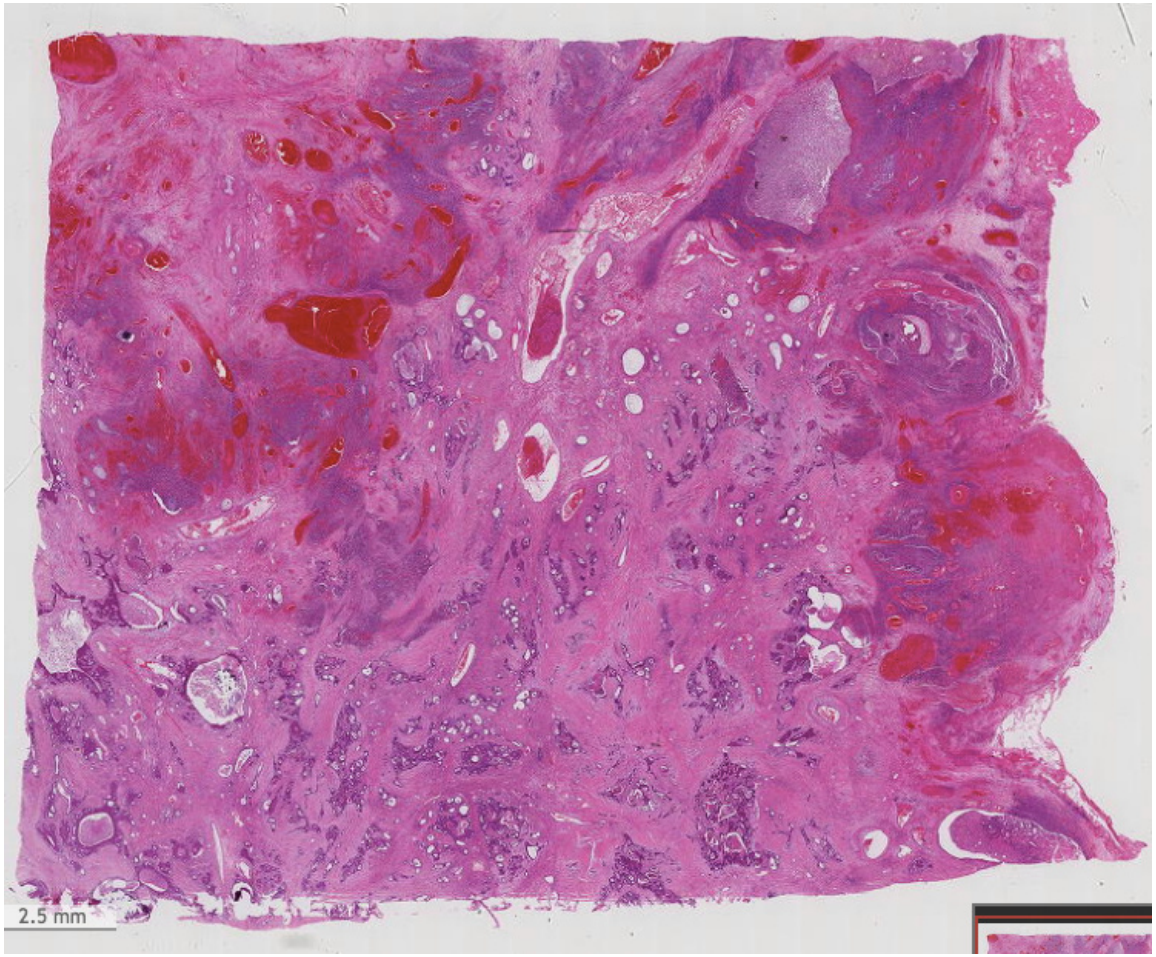

N Singh Case 6: Ovarian mass

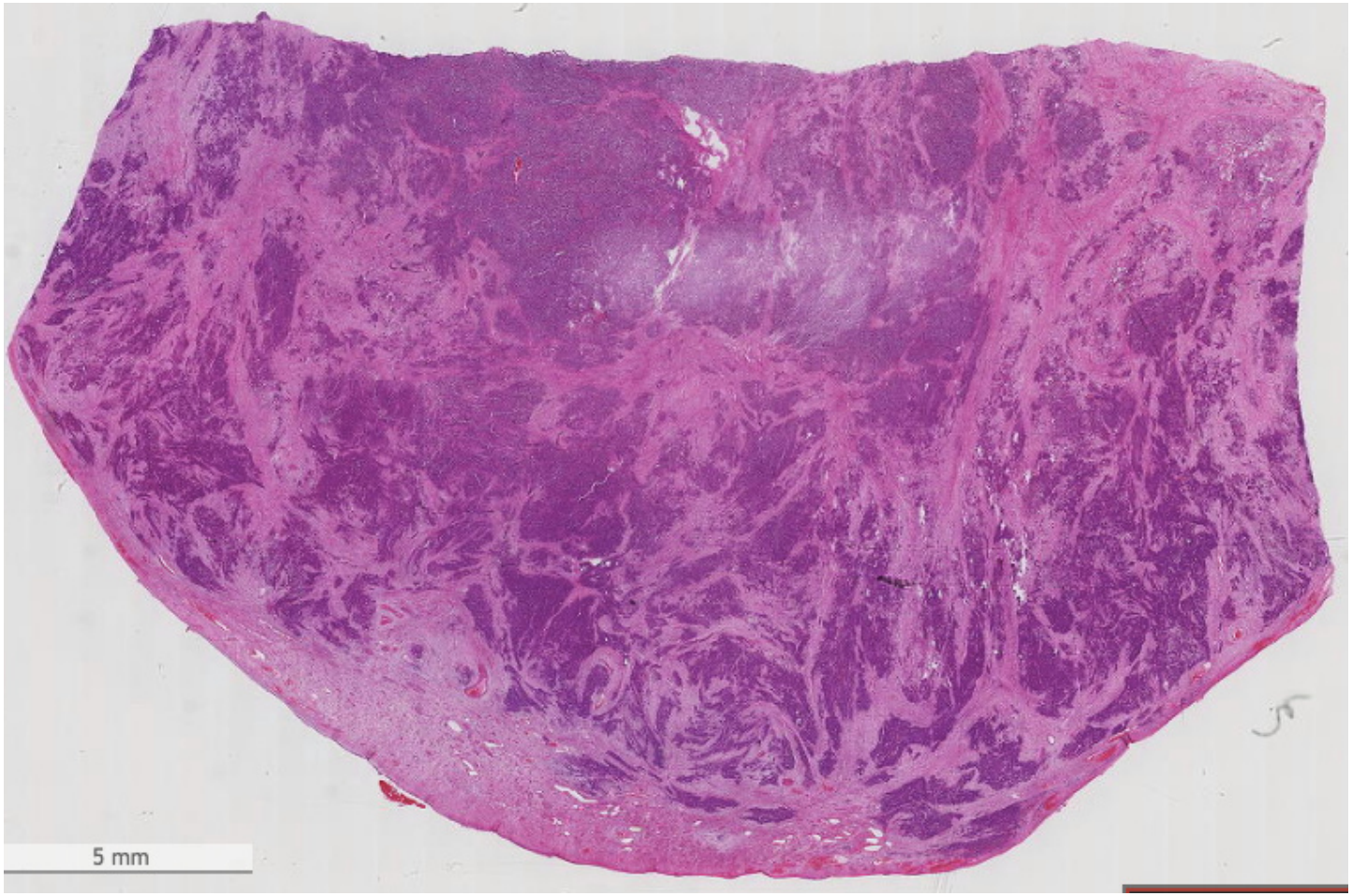

N Singh Case 6: Ovarian mass, area 1

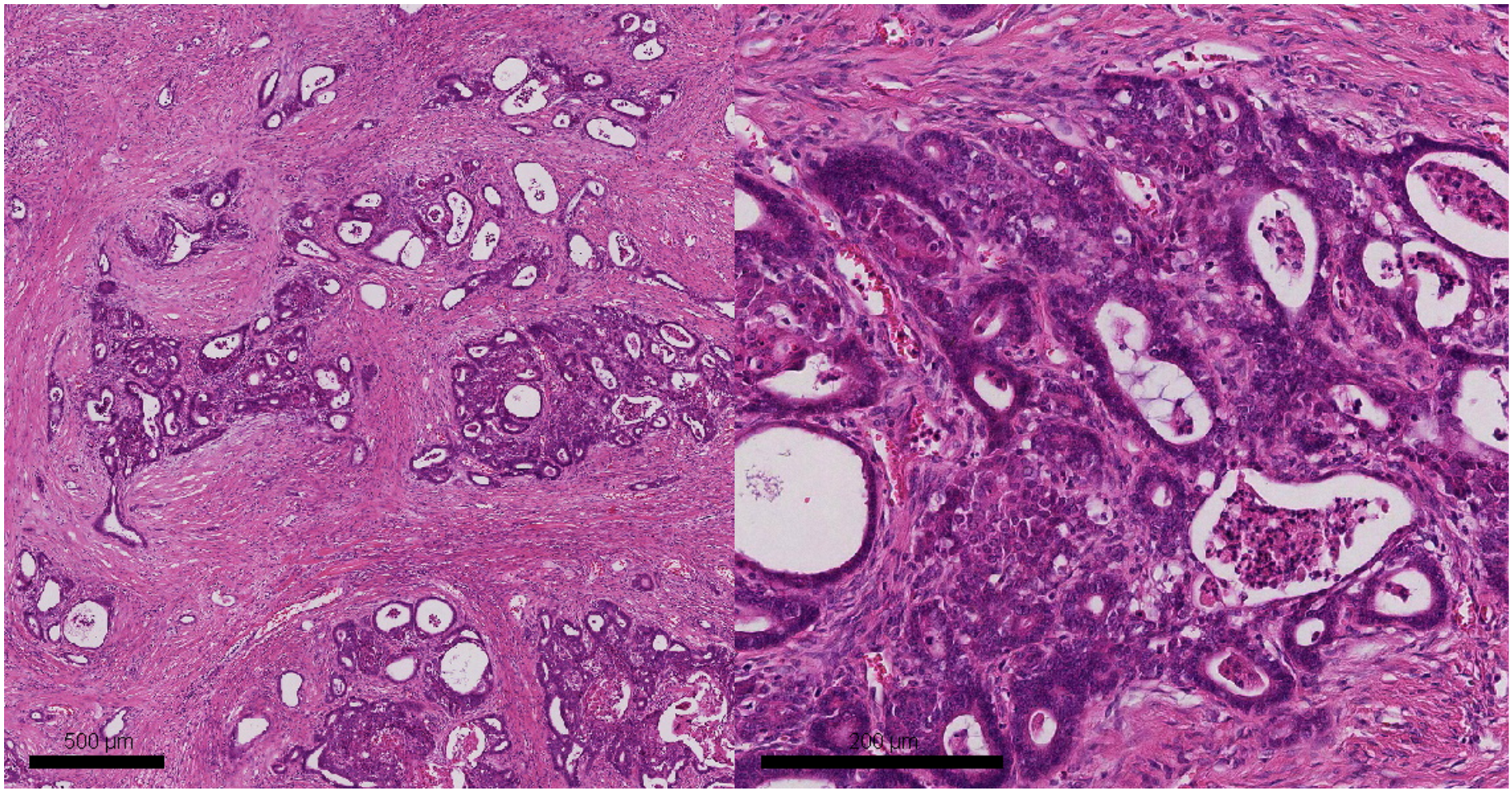

N Singh Case 6: Ovarian mass, area 2

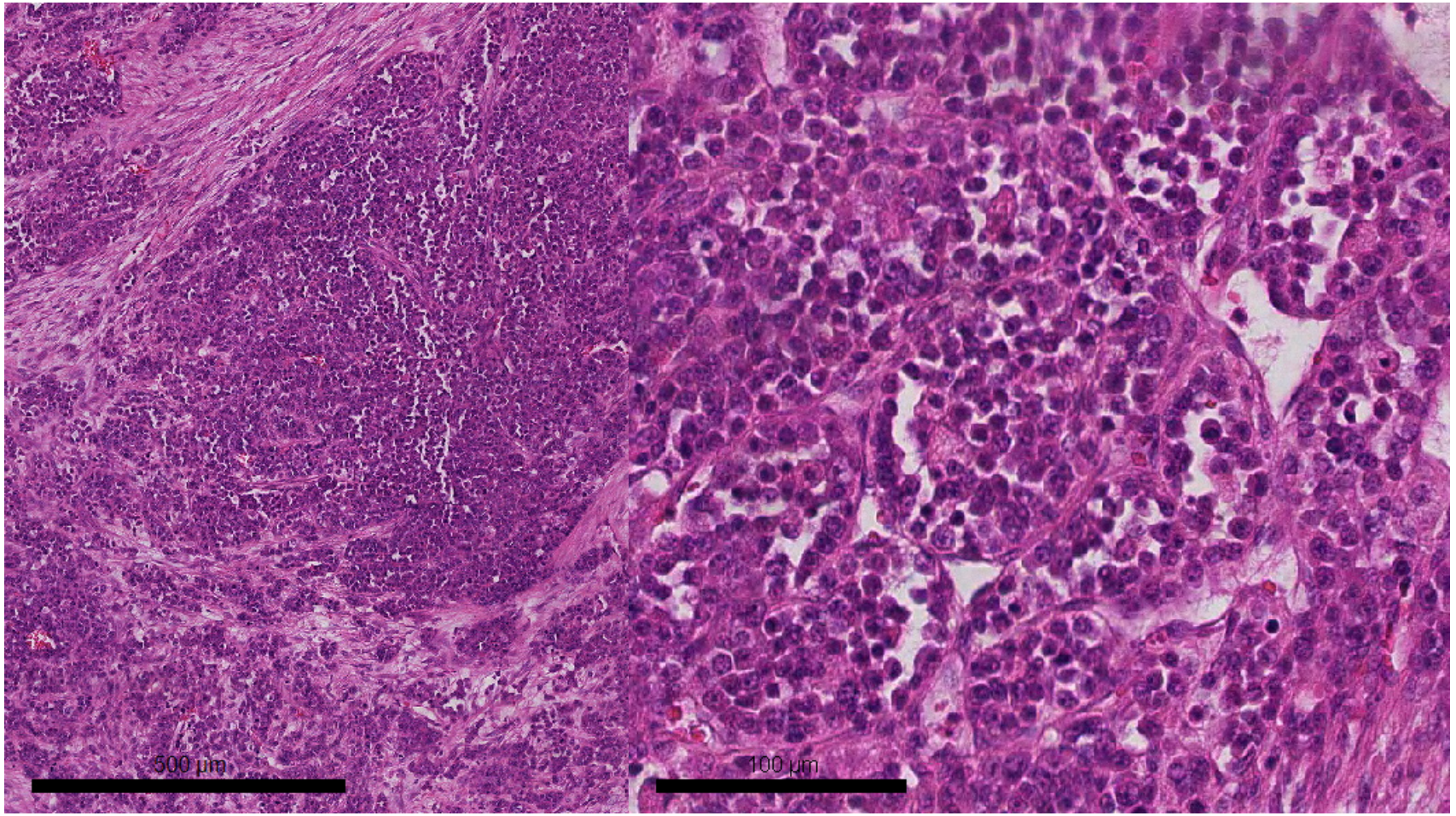

N Singh Case 6: Ovarian mass, area 2

- What is the diagnosis?

Differential diagnosis of undifferentiated ovarian carcinoma

- Solid pattern of HGSC
- G3 endometrioid Ca
- Undifferentiated/dedifferentiated Ca
- Carcinosarcoma
- Small cell Ca of hypercalcemic type
- Neuroendocrine Ca
- Sex cord-stromal/germ cell
- Undifferentiated sarcoma
- Metastatic: Melanoma/Lymphoma/leukaemia

Differential diagnosis of undifferentiated ovarian carcinoma

- Solid pattern of HGSC
- G3 endometrioid Ca
- Undifferentiated/dedifferentiated Ca
- Carcinosarcoma
- Small cell Ca of hypercalcemic type
- Neuroendocrine Ca
- Sex cord-stromal/germ cell
- Undifferentiated sarcoma
- Metastatic: Melanoma/Lymphoma/Leukaemia

Differential diagnosis of undifferentiated ovarian carcinoma

- Solid pattern of HGSC
- G3 endometrioid Ca
- Undifferentiated/dedifferentiated Ca
- Carcinosarcoma
- Small cell Ca of hypercalcemic type
- Neuroendocrine Ca

Differential diagnosis of undifferentiated ovarian carcinoma

- Solid pattern of HGSC
- G3 end
- Undiffe
- Carcino
- Small c
- Neuroendocrine Ca

ALL HAVE POOR OUTCOMES
BUT
DISTINCTION HAS IMPORTANT MANAGEMENT IMPLICATIONS IN CURRENT PRACTICE

Differential diagnosis of undifferentiated ovarian carcinoma

- Solid pattern of HGSC/Carcinosarcoma: Genetics referral (BRCA)/PARPi
- G3 endometrioid Ca/Undifferentiated/dedifferentiated Ca: Genetics referral (Lynch)/Immune checkpoint inhibitor Rx
- Small cell Ca of hypercalcemic type: Genetics referral (SMARCA4/SMARCB1 mut)
- Neuroendocrine Ca: therapeutic implications

Case 6: IHC results

	EEC component	UC component
ER/PR	+++	-
p53	wt	wt
PAX8	+	+
EMA	+	+ (focal)
CK (AE1/3)	+	+ (focal)
Synaptophysin	-	+ (focal)

Case 6: Ovarian mass diagnosis

- Dedifferentiated carcinoma

Undifferentiated/dedifferentiated carcinoma (endometrium/ovary)

- Uncommon (1-9%)
- Poorly defined; inconsistently recognised
- Clinically aggressive with poor outcomes

Undifferentiated carcinoma (Silva et al)

Architecture

- patternless, solid sheet-like growth
- extensive necrosis with perivascular viable tumour cells
- lack convincing histological evidence of epithelial differentiation, such as glands, nests, trabeculae, or papillae
- myxoid background

Undifferentiated carcinoma

Tumour cells

- monotonous, discohesive, medium-sized ovoid to round
- moderate-to-large vesicular nuclei, prominent nucleoli
- high mitotic and apoptotic activity; atypical mitoses may be seen
- cytoplasm may be scanty or abundant and clear or vacuolated
- rhabdoid morphology common

Undifferentiated carcinoma

Some uncommon findings:

- focal abrupt keratinisation may be seen
- may show focal neuroendocrine differentiation (<10% of cells)
- may show focal significant nuclear pleomorphism

De-differentiated carcinoma

- Areas of endometrioid carcinoma juxtaposed with undifferentiated carcinoma without evident transition

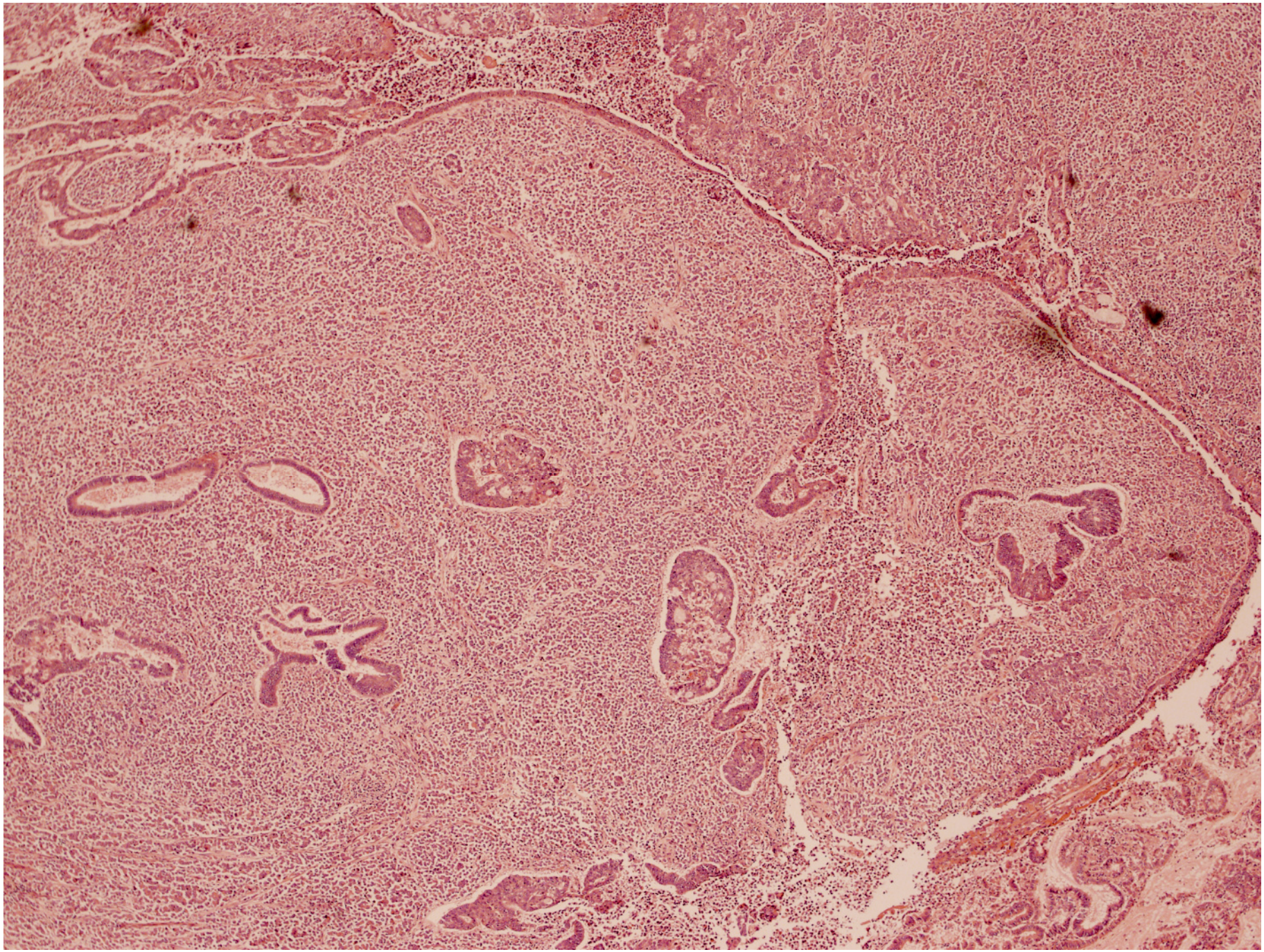

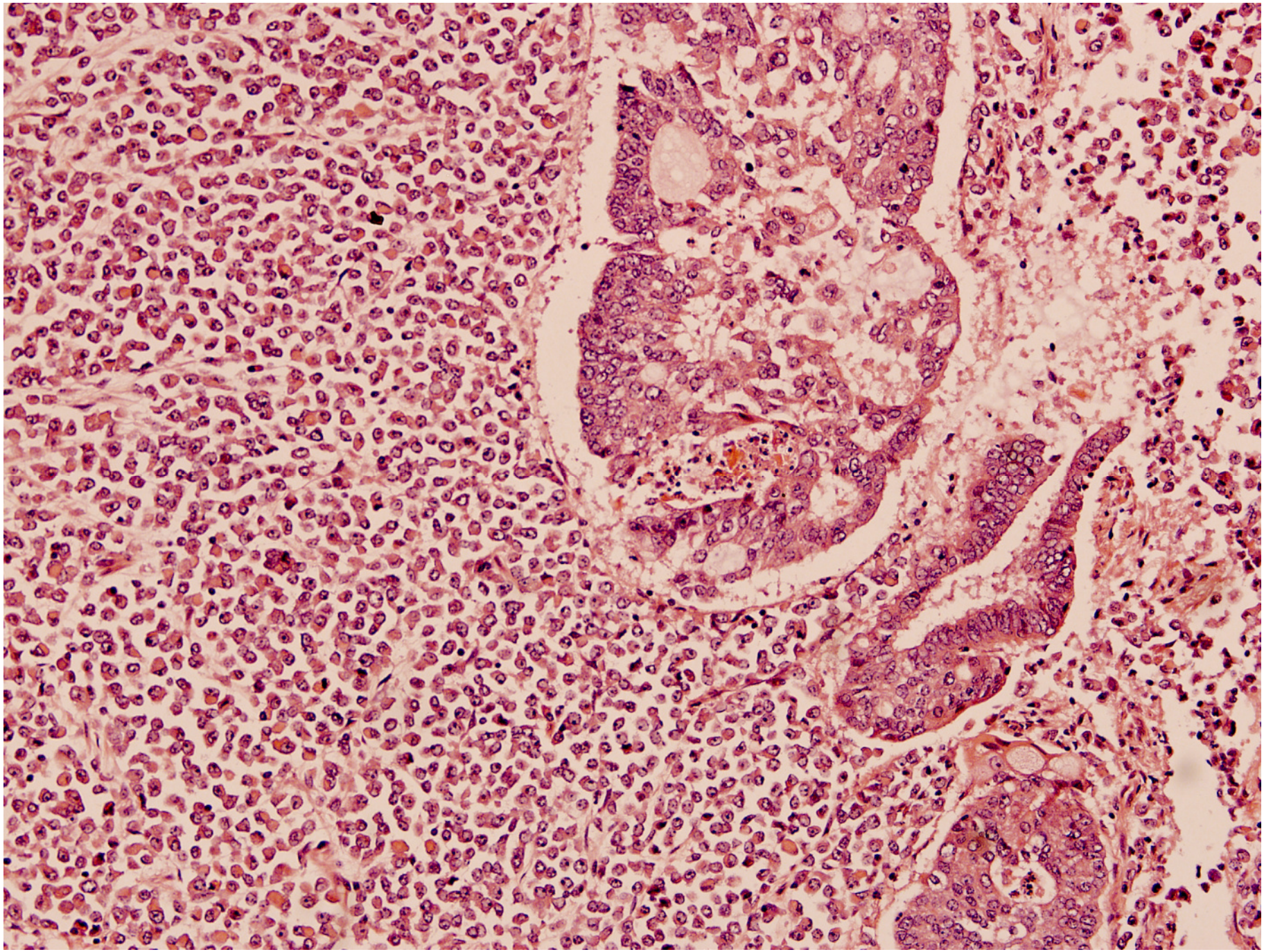

Undiff and Dediff Ca – Molecular heterogeneity

IHC results

- 18 cases: 7 Undiff; 11 Dediff
- Loss of ARID1A in 10/18 (56%)
- Loss of MMR expression in 8/18 (45%)
- p53 overexpression in 3/18 (11%)
- SMARCB1 (INI1) normal in all cases

TCGA category	All cases
MMRd (hypermutated)	8 (45%)
POLE mut (ultramutated)	2 (11%)
TP53 mut (copy no. high)	2 (11%)
NSMP (copy no. low)	5 (28%)

Rosa-Rosa et al. Mod Pathol 2016;29:1390.

Dediff Ca – molecular pathogenesis

- SMARCA4 mutation in 4/8 cases
- Loss of switch/sucrose non-fermenting (SWI-SNF) complex protein expression in 15/30 (50%) of undiff component in dediff ca
  - SMARCA4 (BRG1) and SMARCA2 (BRM) loss (37%)
  - SMARCBB1 (INI1) and SMARCA2 (BRM) (13%)
- 31 G3 endometrioid ca showed normal expression
- Spatial association between undiff component and SWI-SNF loss
- 10/15 in cases with MMR defect

Karnezis et al; Mod Pathol 2016; 29:302.

SWI-SNF complex and cancer

- DNA is tightly packaged into chromatin
- At any time 1000s of genes need to be activated/repressed in a coordinated manner
- Chromatin must be remodeled to permit this:
  - Histone modifying enzymes recognize and mark specific residues
  - ATP-dependent chromatin remodeling complexes specifically recognize these histones marks
- Chromatin structure = packaging solution + sophisticated apparatus for regulating gene expression.

Tang et al. Prog Biophys Mol Biol . 2010 ; 102: 122. Lu and Allis. Nat Genet. 2017; 49(2): 178.

SWI-SNF complex and cancer

- Through ATP hydrolysis unwrap, mobilize, exchange or eject the nucleosome, and subsequently recruiting a transcriptional apparatus to nucleosomal DNA
- Defects in various subunits of SWI/SNF complex found in ~20% of human tumors (ARID1A, SMARCB1, SMARCA4, SMARCA2)
- One of the most commonly affected targets in cancer
- Potential for targeted therapies

Tang et al. Prog Biophys Mol Biol . 2010 ; 102: 122. Lu and Allis. Nat Genet. 2017; 49(2): 178.

SWI-SNF complex and cancer

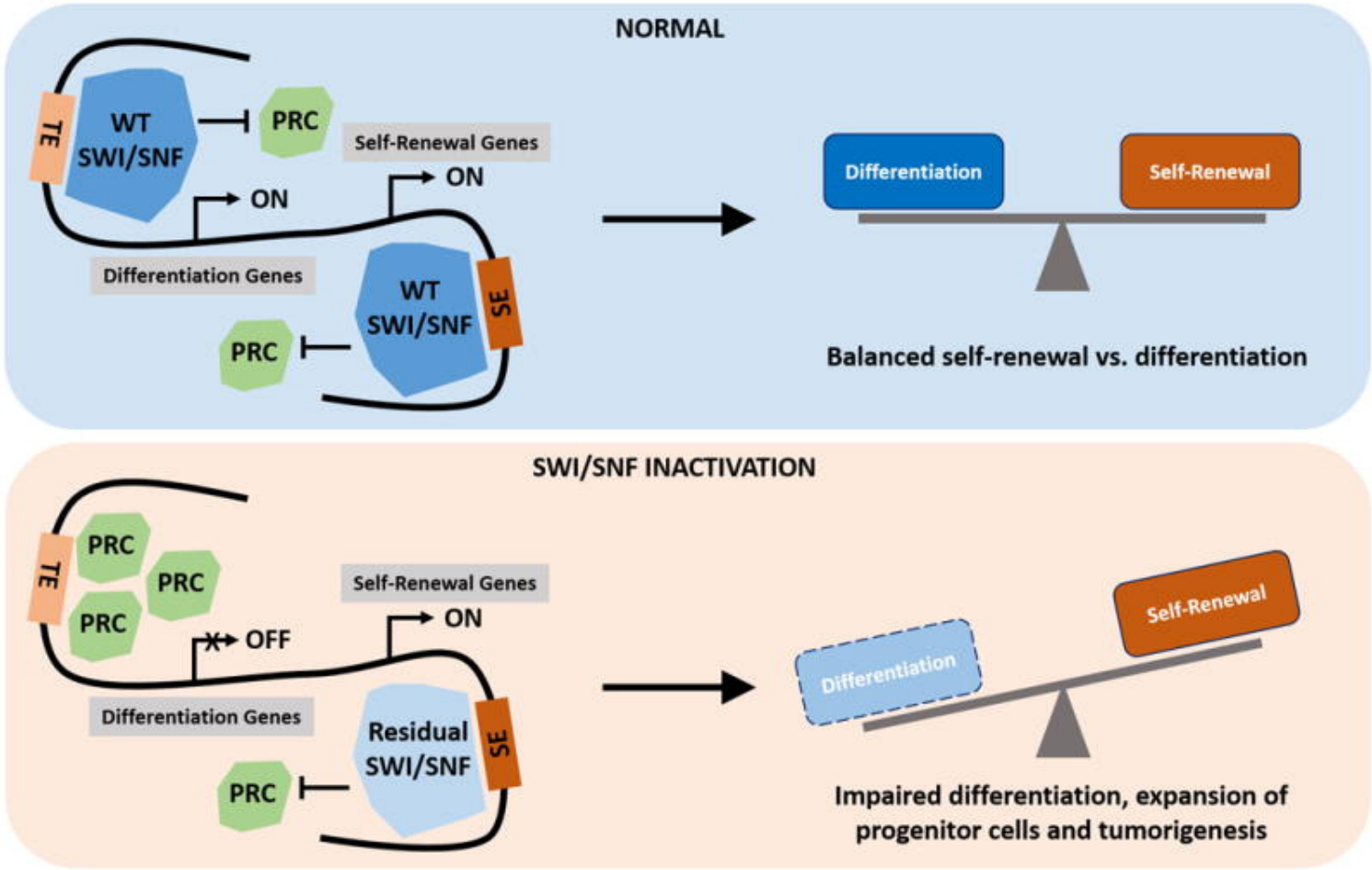

Lu and Allis. Nat Genet. 2017; 49(2): 178

Dediff Ca survival

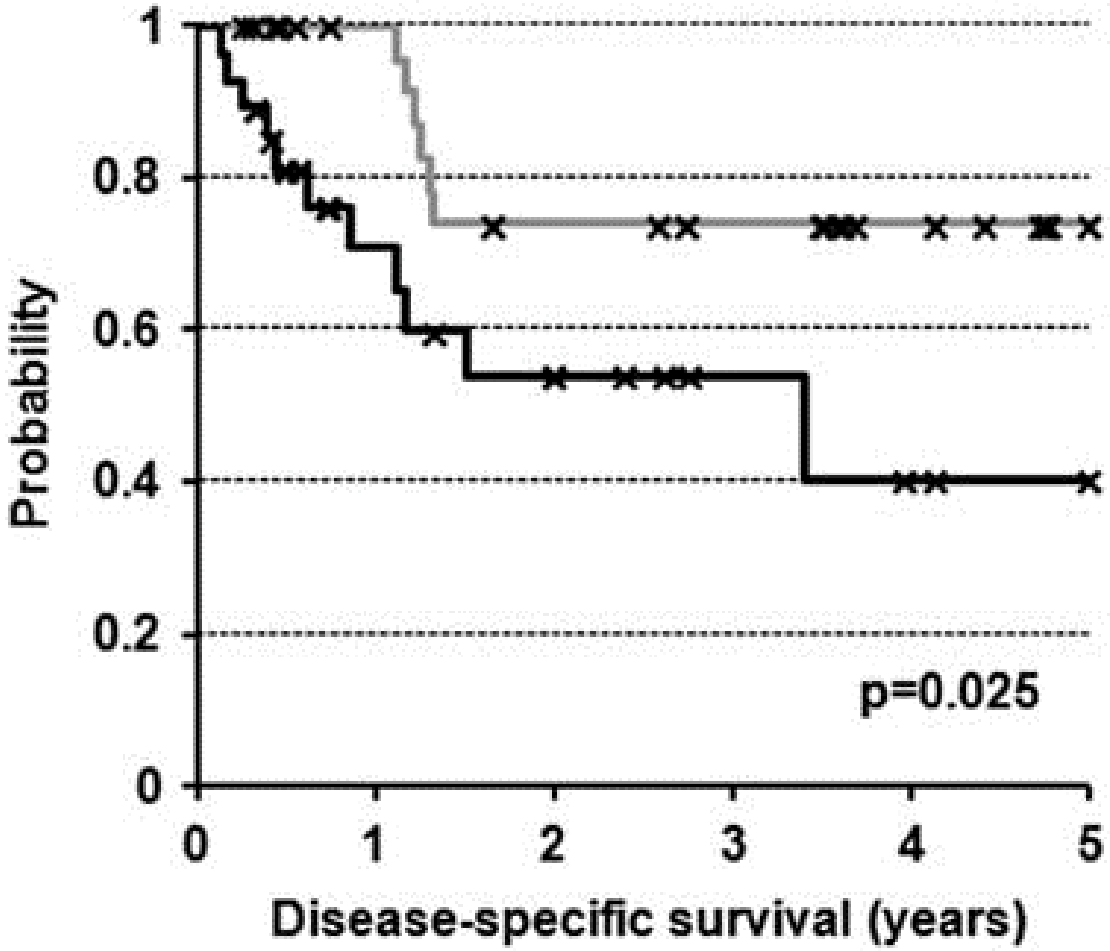

Significantly decreased survival of Dediff (solid black) vs G3 EEC (grey line)

Karnezis et al; Mod Pathol 2016; 29:302.

Undiff and Dediff CA - IHC

Marker	Undiff	Dediff
PAX8	Negative in 80%	Negative in 85%
ER	Negative in 87%	Negative in 85%
Keratin cocktail	Negative/focal/patchy in 80%	Negative/focal/patchy in 65%
E-cadherin	Negative/focal/patchy in 82%	Negative/focal/patchy in 70%
p53	Diffuse* in 38%	Diffuse* in 26%
Synaptophysin	30%**	
Chromogranin	28%**	
CD56	26%**	

*Diffuse = strong nuclear staining in >75% cells

**staining for neuroendocrine markers is seen in 10% or less cells in most cases; only 9% cases exhibit diffuse expression

Ramalingam et al. Int J Gynecol Pathol 2015; 35:410.
Taraif et al. Int J Gynecol Pathol 2009; 28:142.

Undiff and Dediff CA - MMR

Study	MMR IHC		Further info on MMRd
Karnezis et al 2016 (n=30; MMRd in 21/30, 70%)	MLH1/PMS2 loss	13	
	MSH2/MSH6 loss	2	
	PMS2 loss	5	
	MSH6 loss	1	
Ramalingam et al 2016 (n=34; MMRd in 18/34, 53%)	MLH1/PMS2 loss	17	5 cases tested showed MLH1 promoter methylation
	MSH6 loss	1	
Garg and Soslow 2011 (case report, n=1)	MLH1 and PMS2 loss	1	MLH1 mutation, Lynch syndrome

Undifferentiated and Dedifferentiated Carcinoma: Learning points

- Recognition of undifferentiated carcinoma is important:
  - very aggressive tumour
  - Targeted Rx (immune checkpoint inhib; future SWI-SNF-related)
- Exact definition is still work in progress; potential for missing AND overcalling
- As dediff ca can be seen:
  - At time of diagnosis
  - Only at metastatic sites
  - Only at recurrence

Undifferentiated and Dedifferentiated Carcinoma: Learning points

Morphological + IHC:

- **PAX8 loss, ER loss, low expression of epithelial markers**
- **Loss of SMARCA4/ARID1A/SMARCB4**
- Can be focal (rarely diffuse) NE marker positive
- Frequent MMR loss
- p53 wt

N Singh Case 6: Incidental finding, uterus

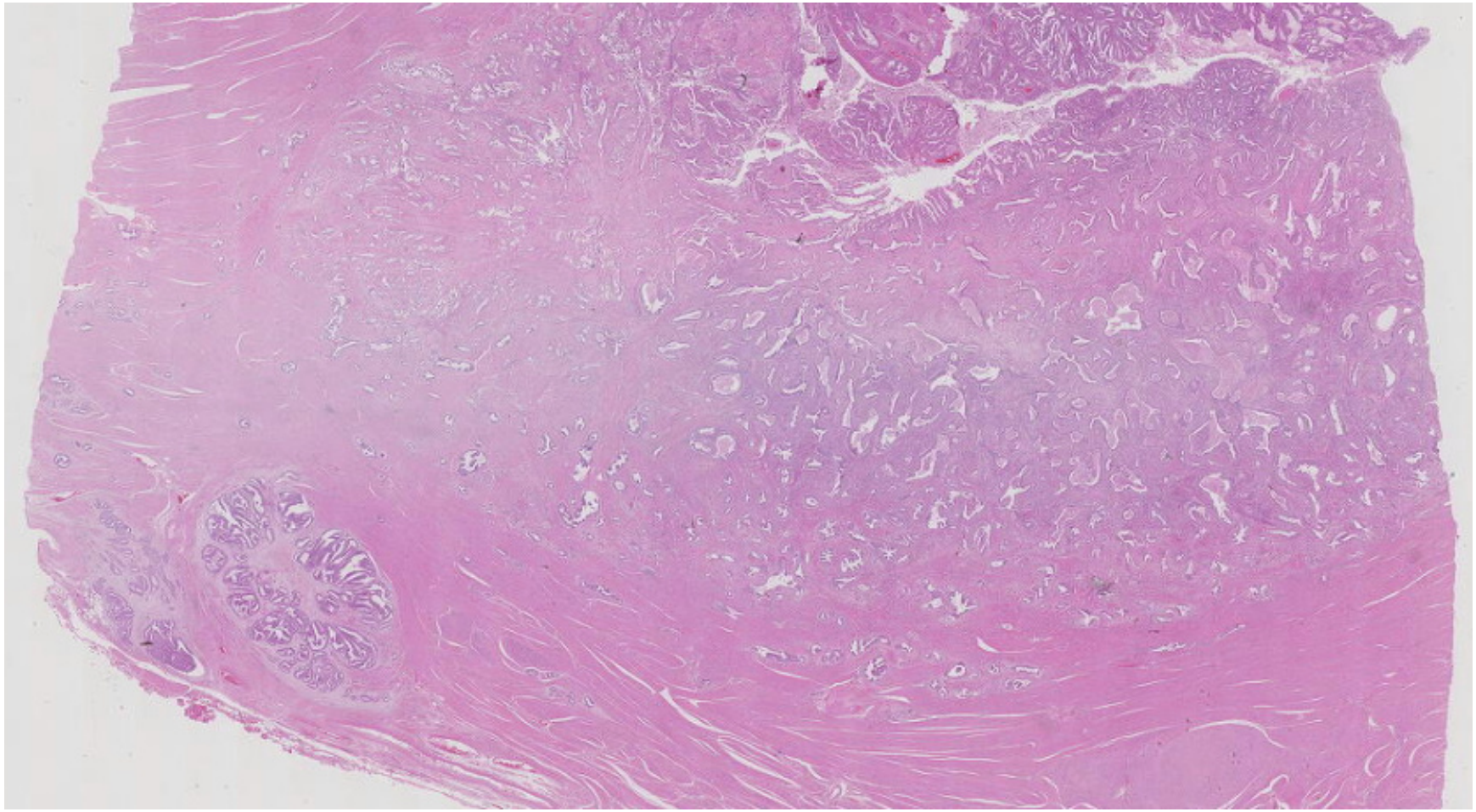

N Singh Case 6: Incidental finding, uterus

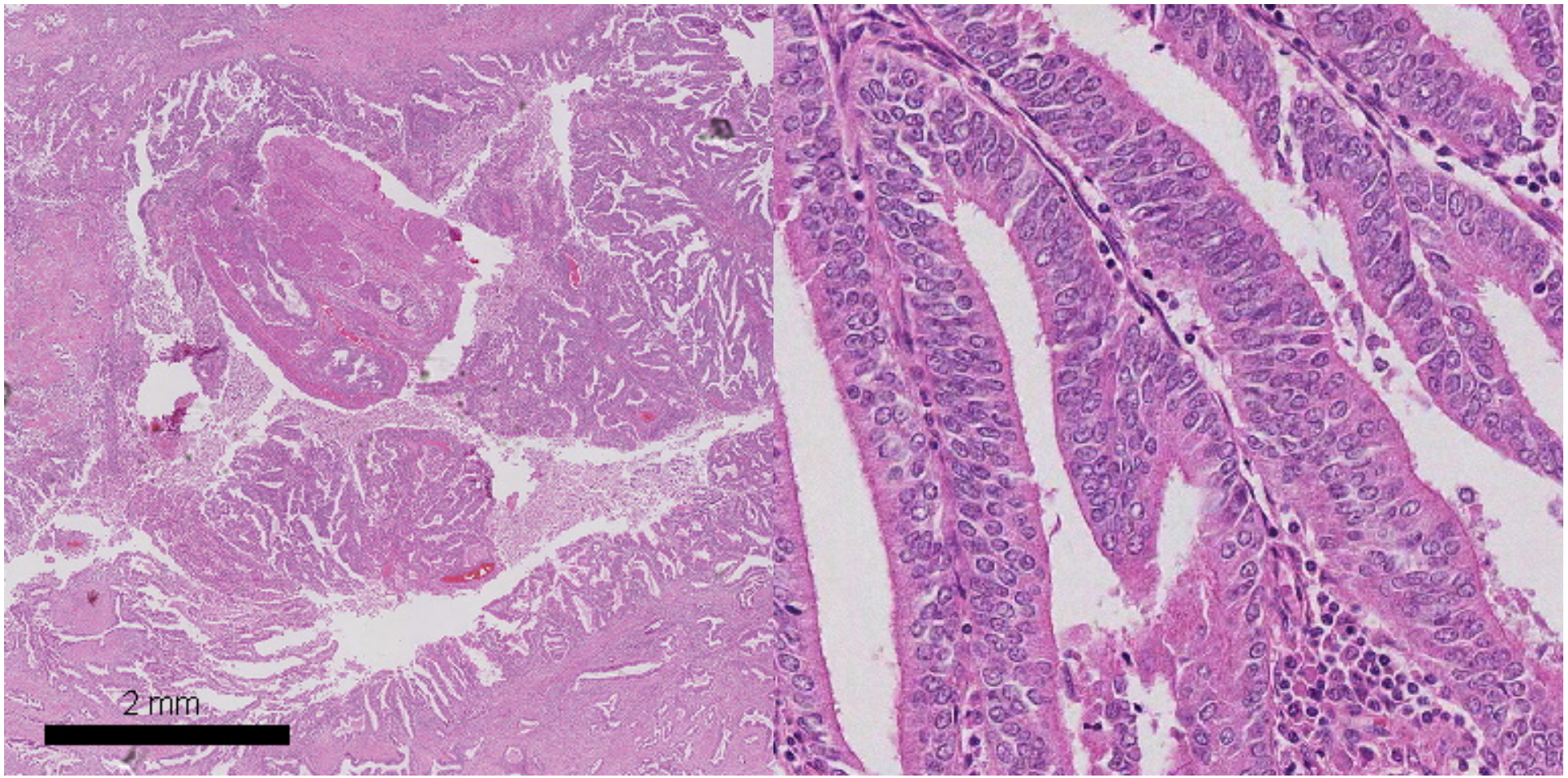

Primary endometrioid ovarian Ca

Three morphological features are emphasised:

- Squamous metaplasia
- Background endometriosis
- Adenofibromatous pattern

- Synchronous endometrial carcinoma or atypical hyperplasia (15-20%)

Synchronous vs metastatic carcinoma of ovary and endometrium

- Features favouring metastasis from endometrial
  - Histologically similar
  - Large endometrial – small ovarian
  - Atypical hyperplasia
  - Deep myoinvasion
  - LVSI in myometrium
  - Other extrauterine spread
  - Metastatic features of ovarian tumour

Synchronous vs metastatic carcinoma of ovary and endometrium

- Features favouring synchronous tumours
  - Histologically dissimilar
  - Superficial endometrial tumour without deep myoinvasion
  - No LVSI in myometrium
  - Atypical hyperplasia
  - No other extrauterine spread
  - Primary features of ovarian tumour – unilateral, parenchymal, no surface/hilar involvement, no LVSI
  - Background endometriosis

BRIEF COMMUNICATION

Massively Parallel Sequencing-Based Clonality Analysis of Synchronous Endometrioid Endometrial and Ovarian Carcinomas

Anne M. Schultheis*, Charlotte K. Y. Ng*, Maria R. De Filippo, Salvatore Piscuoglio, Gabriel S. Macedo, Sonia Gatius, Belen Perez Mies, Robert A. Soslow, Raymond S. Lim, Agnes Viale, Kety H. Huberman, Jose C. Palacios, Jorge S. Reis-Filho, Xavier Matias-Guiu, Britta Weigelt

JNCI J Natl Cancer Inst (2016) 108(6): djv427

BRIEF COMMUNICATION

Synchronous Endometrial and Ovarian Carcinomas: Evidence of Clonality

Michael S. Anglesio, Yi Kan Wang, Madlen Maassen, Hugo M. Horlings, Ali Bashashati, Janine Senz, Robertson Mackenzie, Diljot S. Grewal, Hector Li-Chang, Anthony N. Karnezis, Brandon S. Sheffield, Melissa K. McConechy, Friedrich Kommoss, Florin A. Taran, Annette Staebler, Sohrab P. Shah, Diethelm Wallwiener, Sara Brucker, C. Blake Gilks, Stefan Kommoss, David G. Huntsman

JNCI J Natl Cancer Inst (2016) 108(6): djv428

BRIEF COMMUNICATION

Massively Parallel Sequencing-Based Clonality Analysis of Synchronous Endometrioid Endometrial and Ovarian Carcinomas

Anne M. Schultheis*, Charlotte K. Y. Ng*, Maria R. De Filippo,
Salvatore Piscuoglio, Gabriel S. Macedo, Sonia Gatius, Belen Perez Mies,
Robert A. Sos
Jose C. Palaci

Cases traditionally classified as 'synchronous' independent rprimary carcinomas are ***clonally identical***, i.e. they represent indolent metastases

108(6): djv427

BRIEF COMMU

Synchron
Evidence of Clonality

Michael S. Anglesio, Yi Kan Wang, Madlen Maassen, Hugo M. Horlings,
Ali Bashashati, Janine Senz, Robertson Mackenzie, Diljot S. Grewal,
Hector Li-Chang, Anthony N. Karnezis, Brandon S. Sheffield,
Melissa K. McConechy, Friedrich Kommoss, Florin A. Taran, Annette Staebler,
Sohrab P. Shah, Diethelm Wallwiener, Sara Brucker, C. Blake Gilks,
Stefan Kommoss, David G. Huntsman

JNCI J Natl Cancer Inst (2016) 108(6): djv428

N Singh Case 6

- What is the diagnosis?
- What is the stage? (in addition to ovarian tumour there was nodal and ometnal metastasis)
- What else should be done?

N Singh Case 6 Diagnosis

- De-differentiated carcinoma (grade 1 endometrioid endometrial carcinoma in combination with undifferentiated carcinoma) of endometrial origin, FIGO stage IVB.

- (MMR normal)

Thank you

Case Presentation: Epithelial Neoplasia

Naveena Singh, Case 7

June 28, 2019

N Singh Case 7: History

- 48F
- Bilateral ovarian masses

N Singh, case 7: Ovary

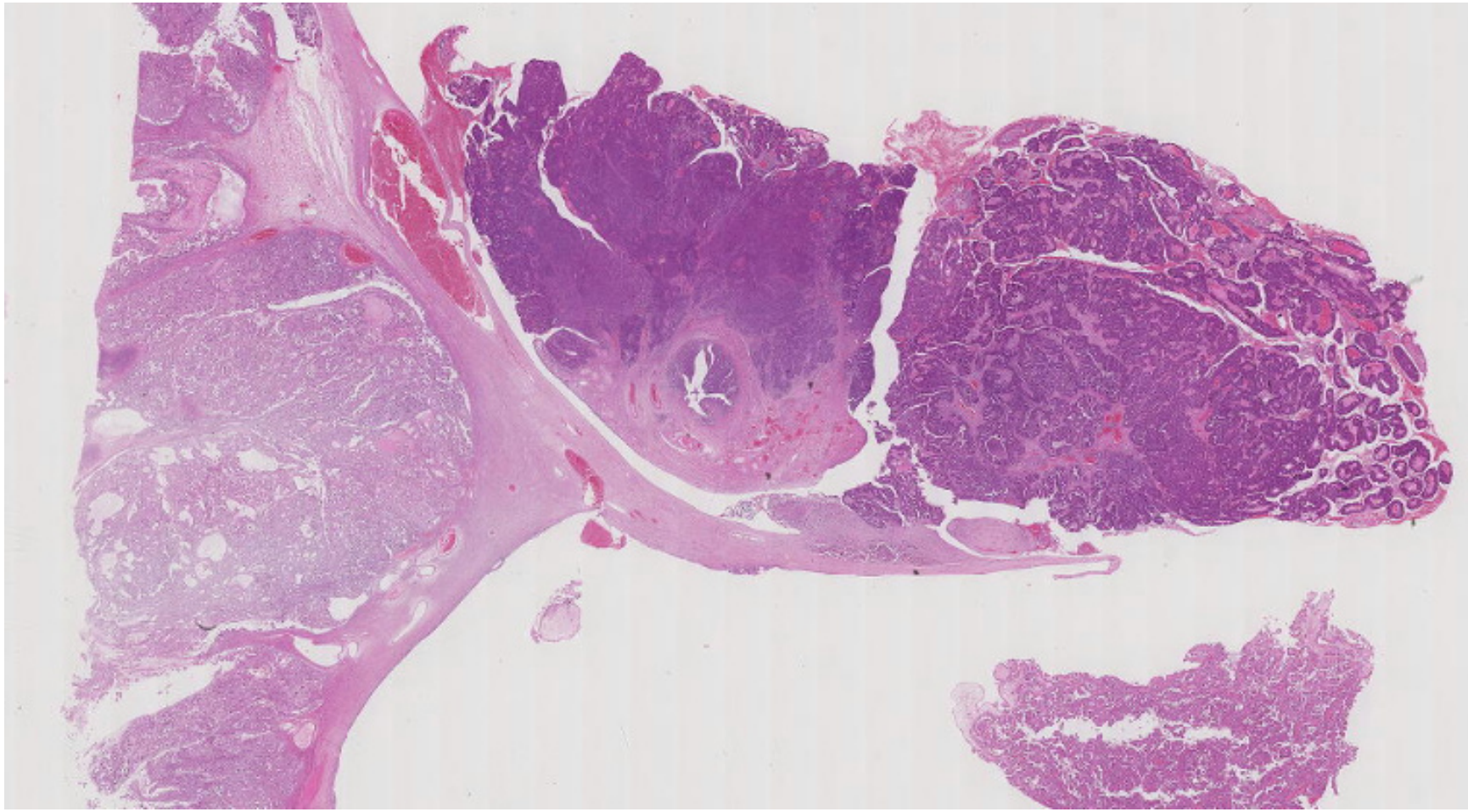

N Singh, case 7: Ovary, area 1

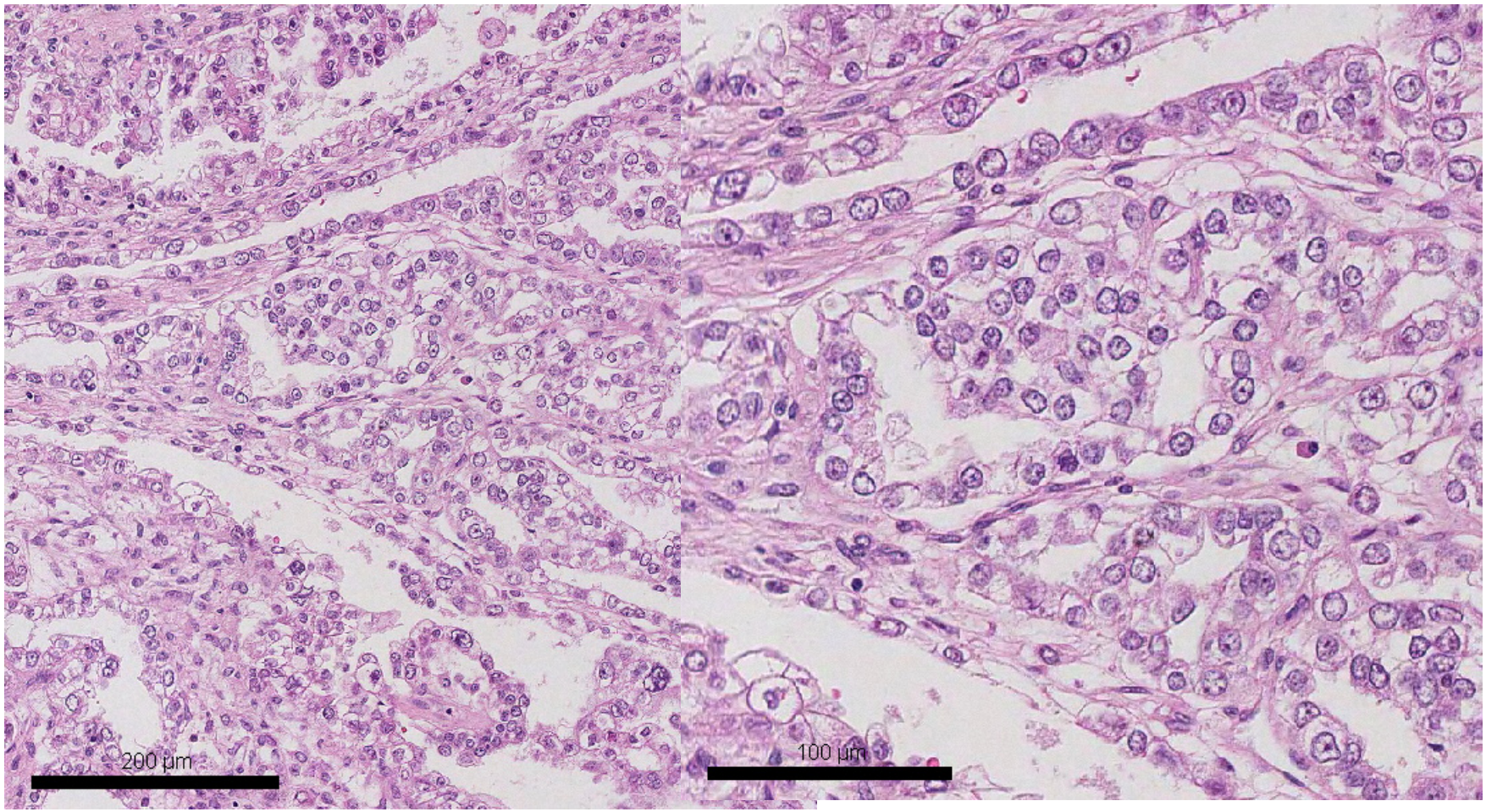

N Singh, case 7: Ovary, area 2

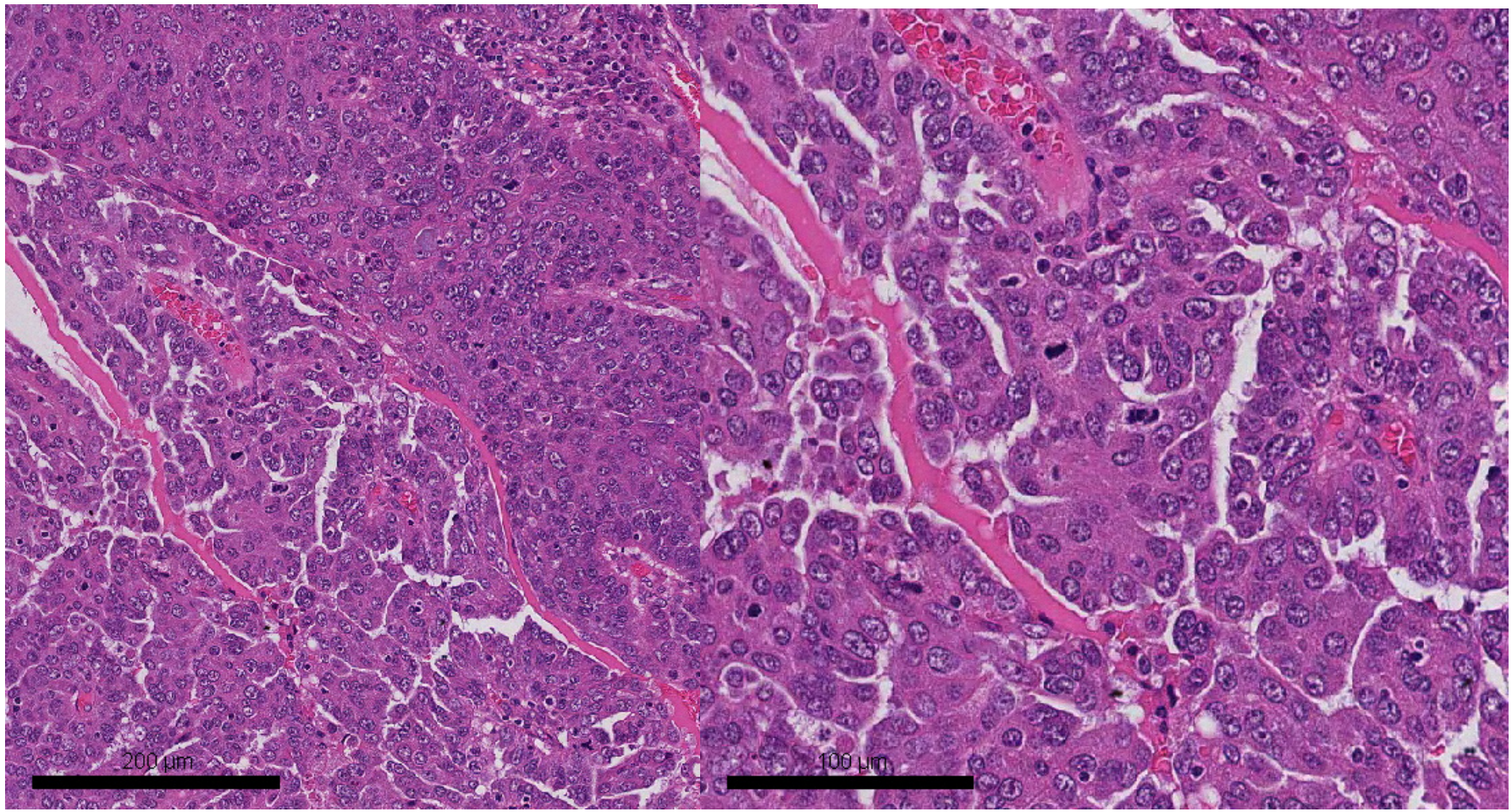

Diagnosis

- ?high-grade serous carcinoma
- ?clear cell carcinoma
- ?mixed carcinoma

Ovarian Carcinoma in previous years

- Histological typing irreproducible
- Frequent diagnosis of ‘mixed’ carcinoma
- Most ‘mixed’ related to marked variation in patterns of HGSC (“SET” pattern is typically solid, pseudo-endometrioid and transitional-like)

HISTOTYPE DID NOT AFFECT CLINICAL MANAGEMENT

WHO 2014: Changes to EOC

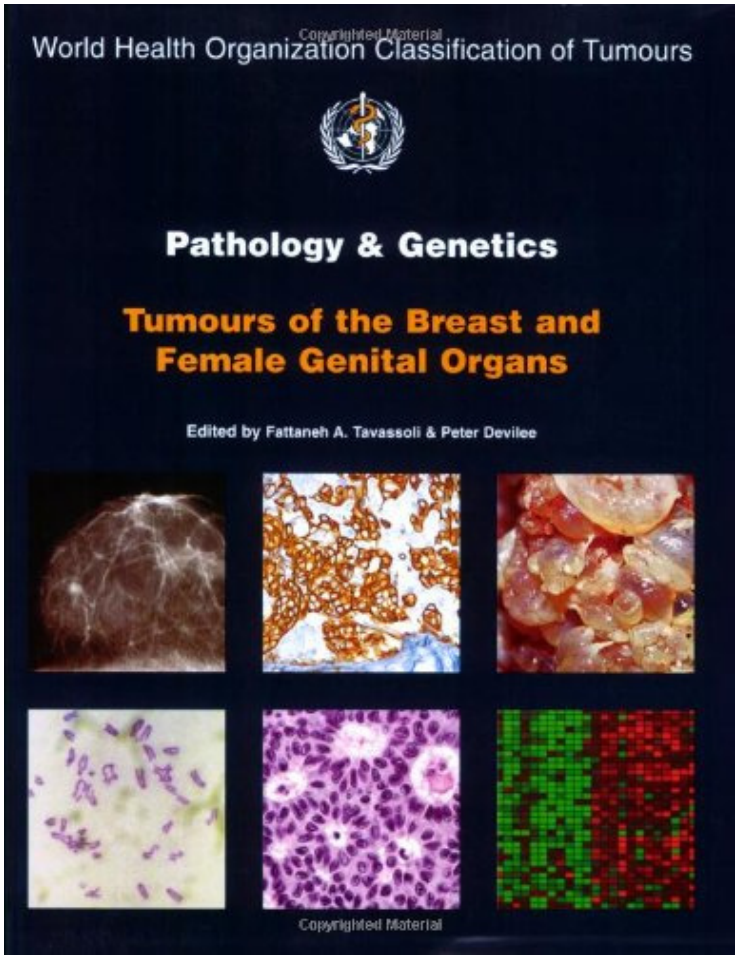

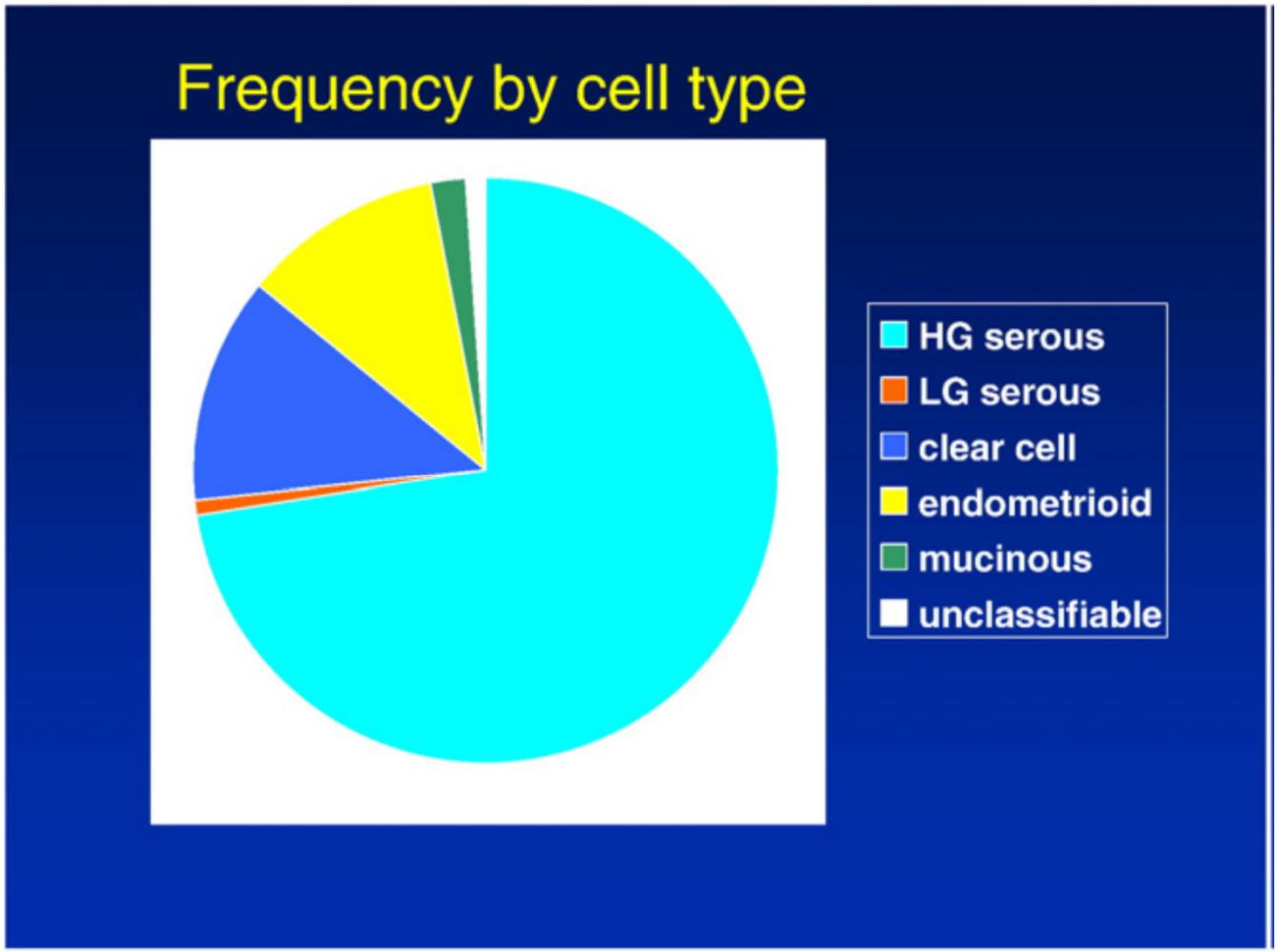

Gilks and Prat. Human Pathology (2009) 40, 1213–1223

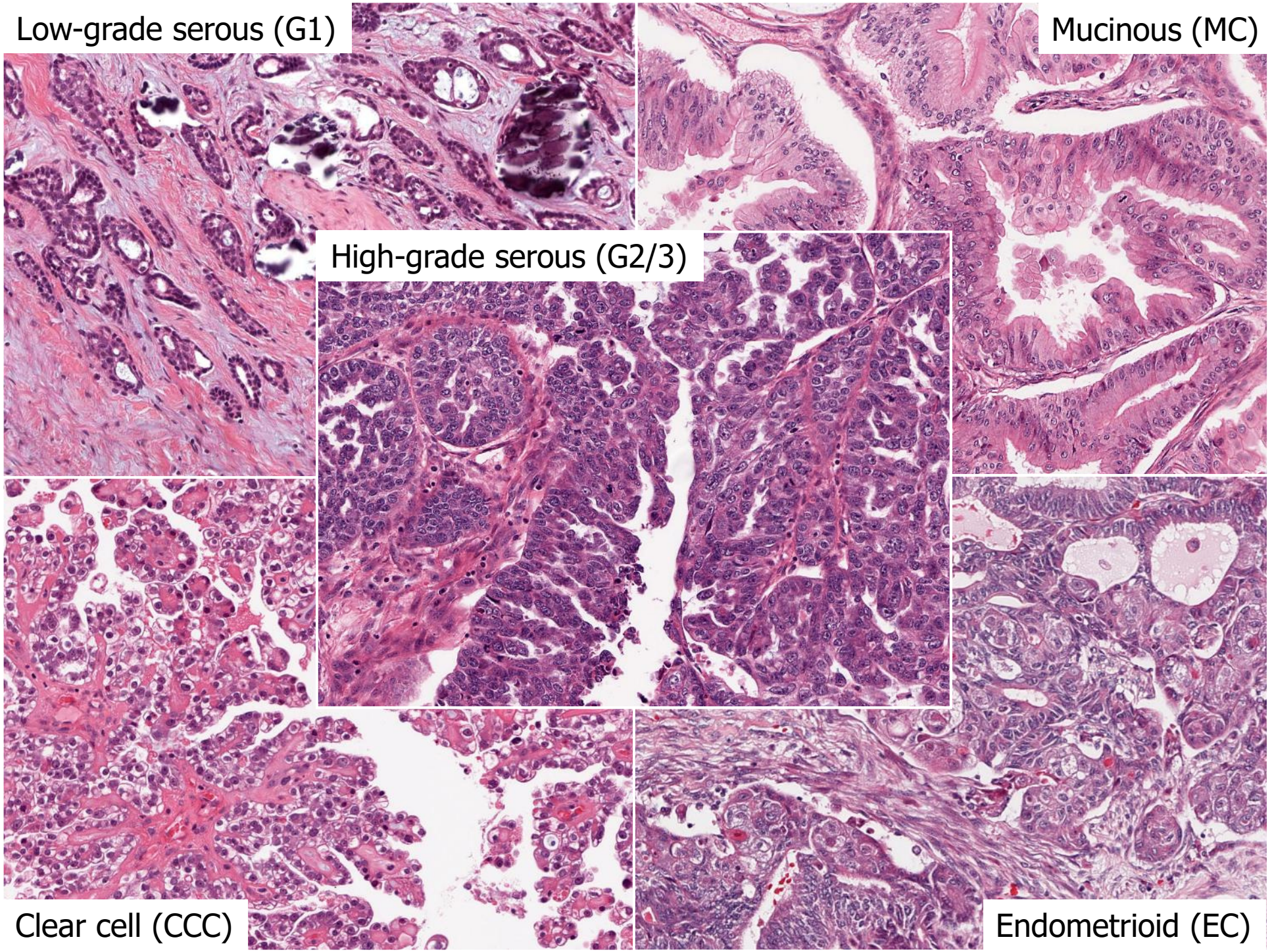
Low-grade serous (G1)
Mucinous (MC)
High-grade serous (G2/3)
Clear cell (CCC)
Endometrioid (EC)

Epithelial ovarian carcinoma subtypes

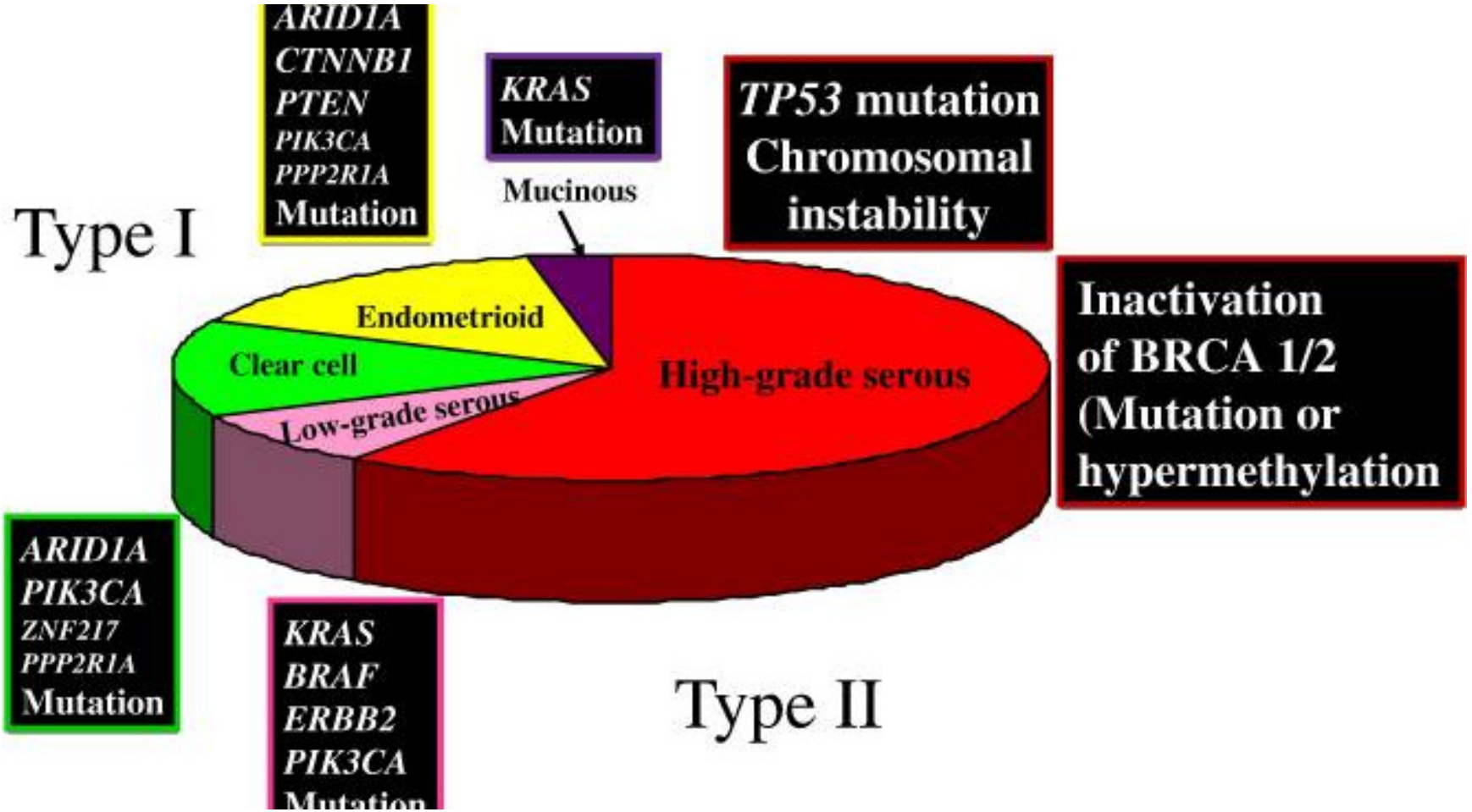

Kurman and Shih. Hum Pathol. 2011 Jul;
42(7): 918–931.

Mean age

Type	Mean age
High-grade serous	61y
Low-grade serous	54 y
Endometrioid	55 y
Mucinous	55 y
Clear cell	56 y

Gynecol Oncol 2010, 116: 50-6

Five major types - stage

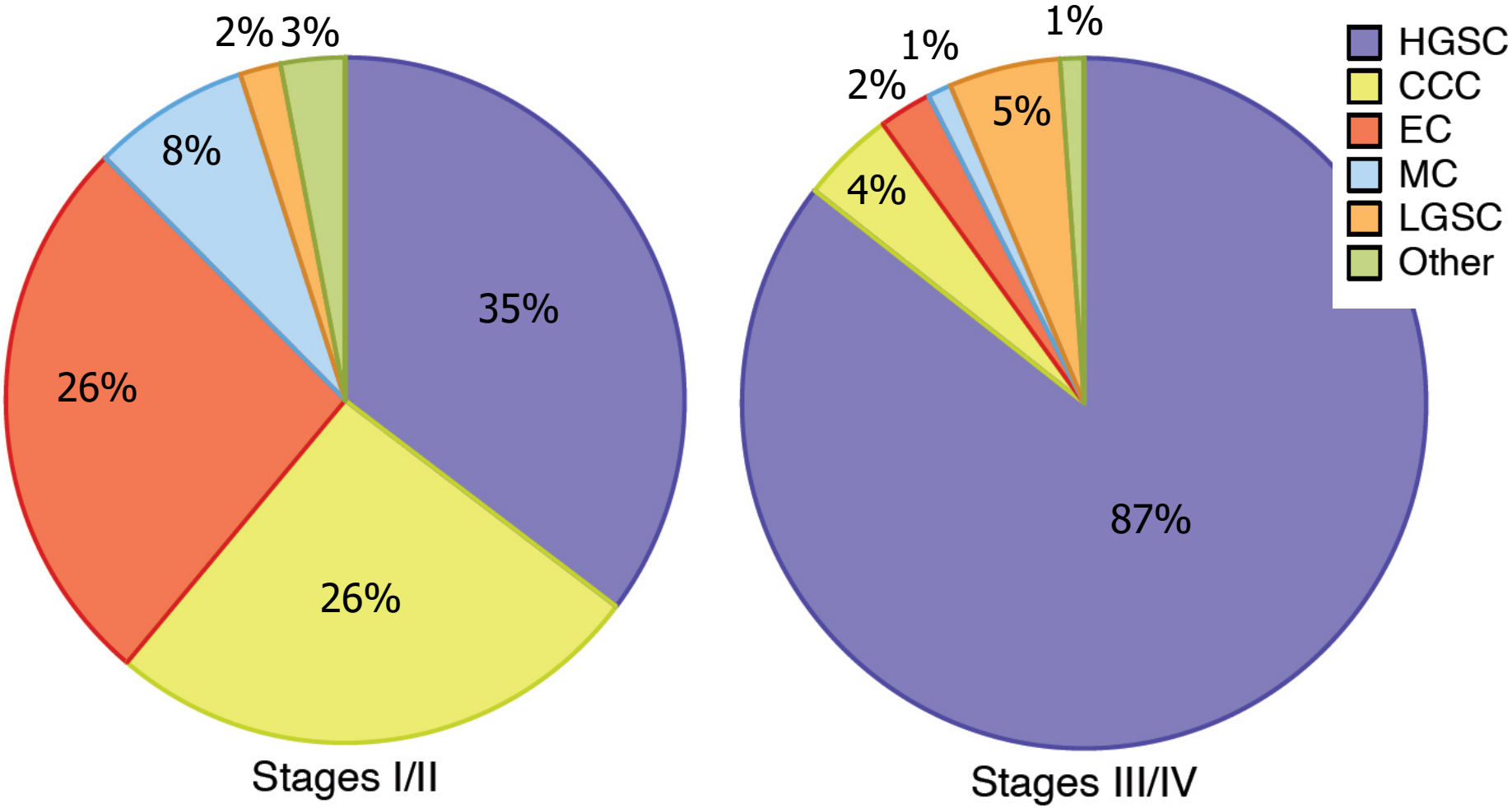

Int J Gyn Pathol, 2010, 29: 203-11

Reasons for Accurate Subtyping



- Platinum sensitivity
- Other forms of treatment: personalised medicine

Reasons for Accurate Subtyping

Genetic Testing and Cancer Prevention

- HGSC: BRCA1, BRCA2, hereditary breast-ovarian cancer syndromes
- Non-Serous (CCC and EC): Lynch Syndrome

WHO 2014

- HGSC and LGSC separate entities
- LGSC diagnosed by presence of invasion at any site (not on basis of ovarian neoplasm; ~~SBT with invasive implant~~)
- SBT with micropapillary proliferation = non-invasive LGSC
- TCC removed (most are HGSC)
- ‘Mixed’ carcinomas removed

HGSC

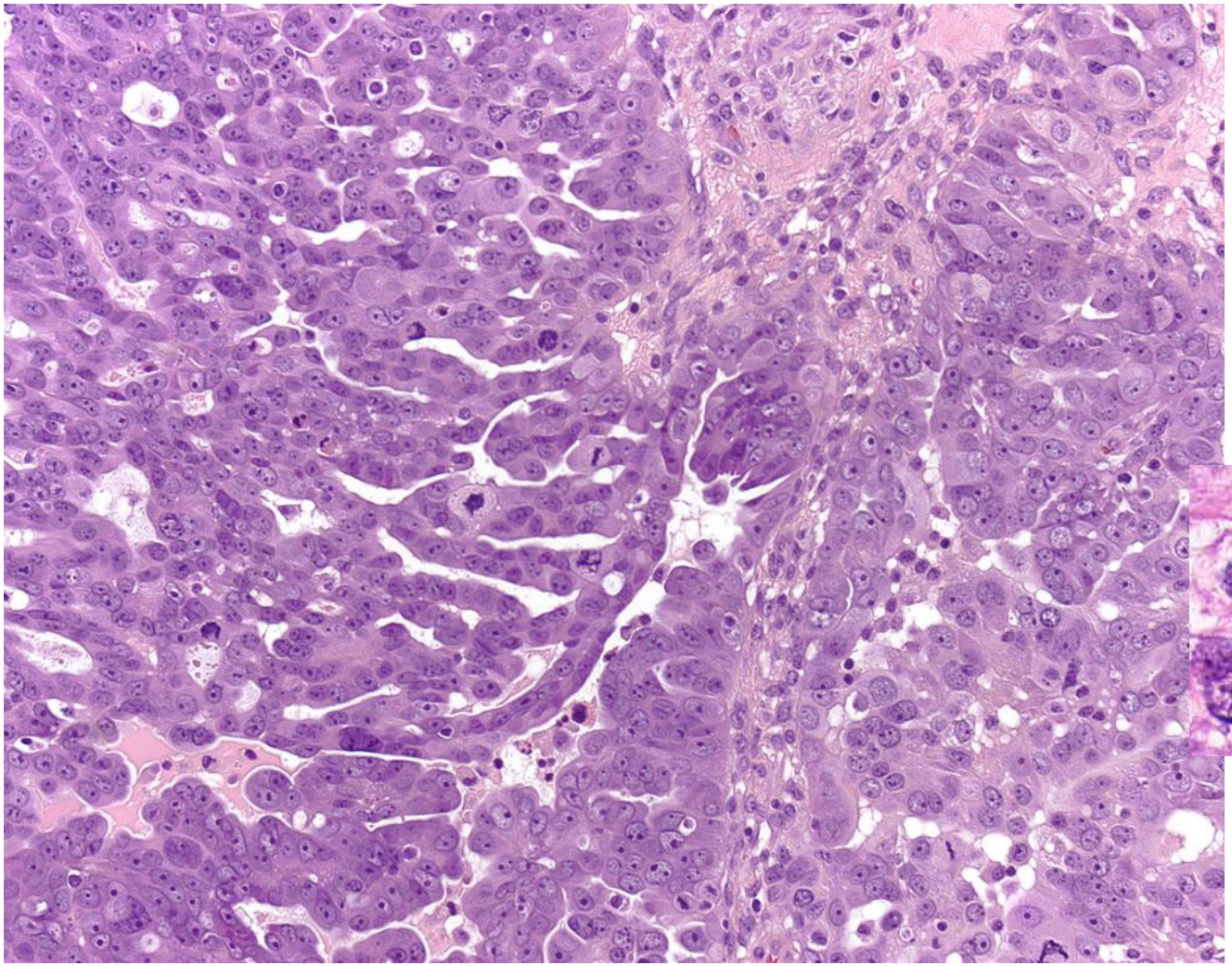

Architecture:
Heterogeneous

Nuclei:
At least grade 2 nuclei
Variation in size ≥ 3:1
Mitotic count ≥13/10HPF
Apoptosis
Tumor giant cells

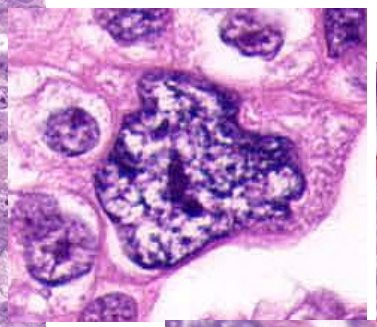

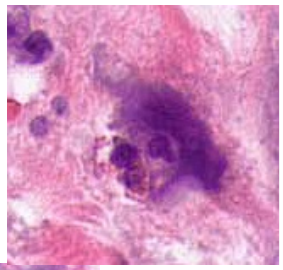

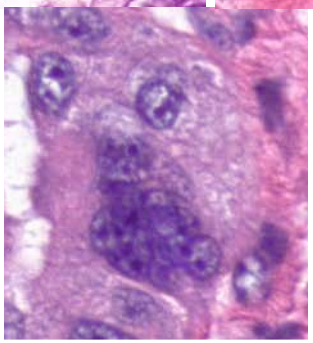

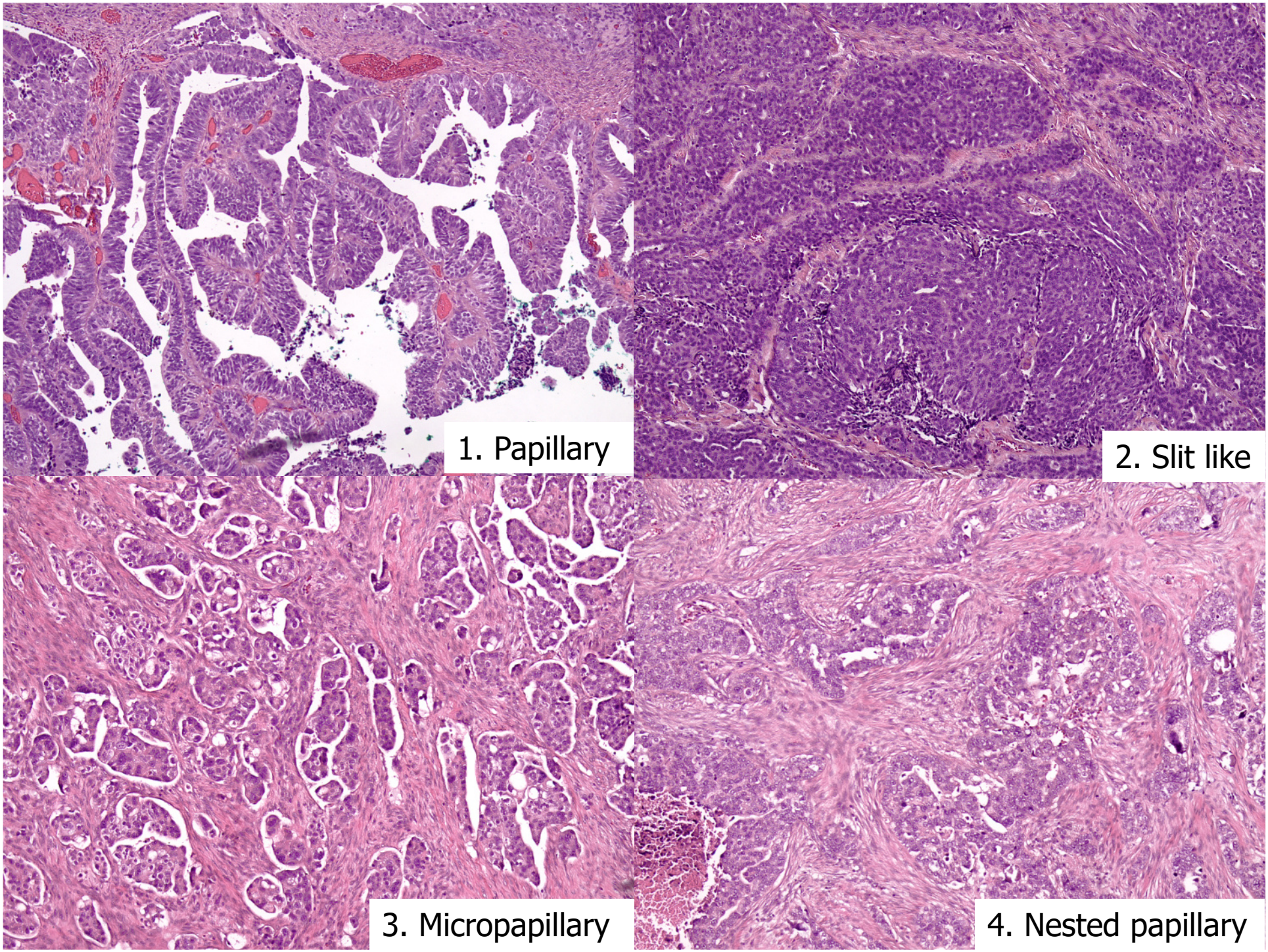
1. Papillary
2. Slit like
3. Micropapillary
4. Nested papillary

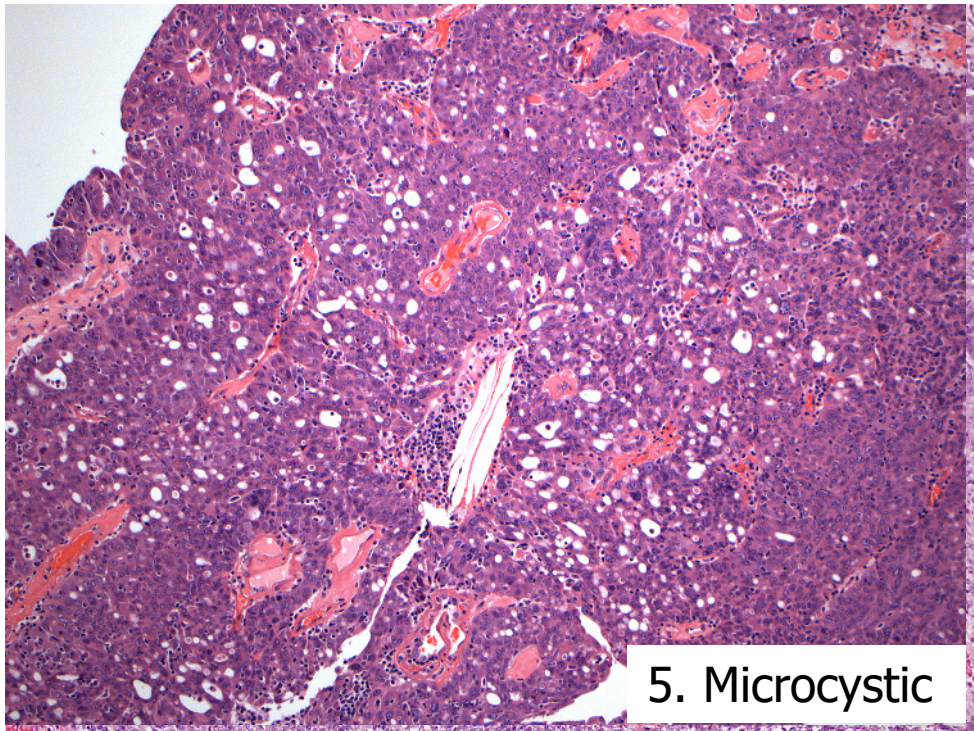

5. Microcystic

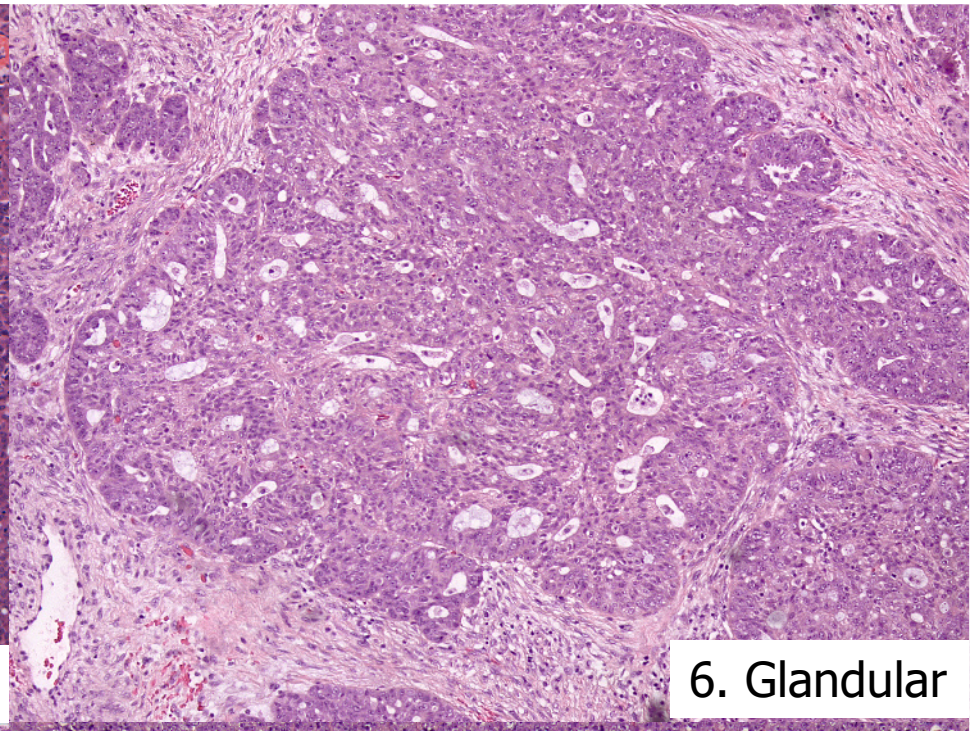

6. Glandular

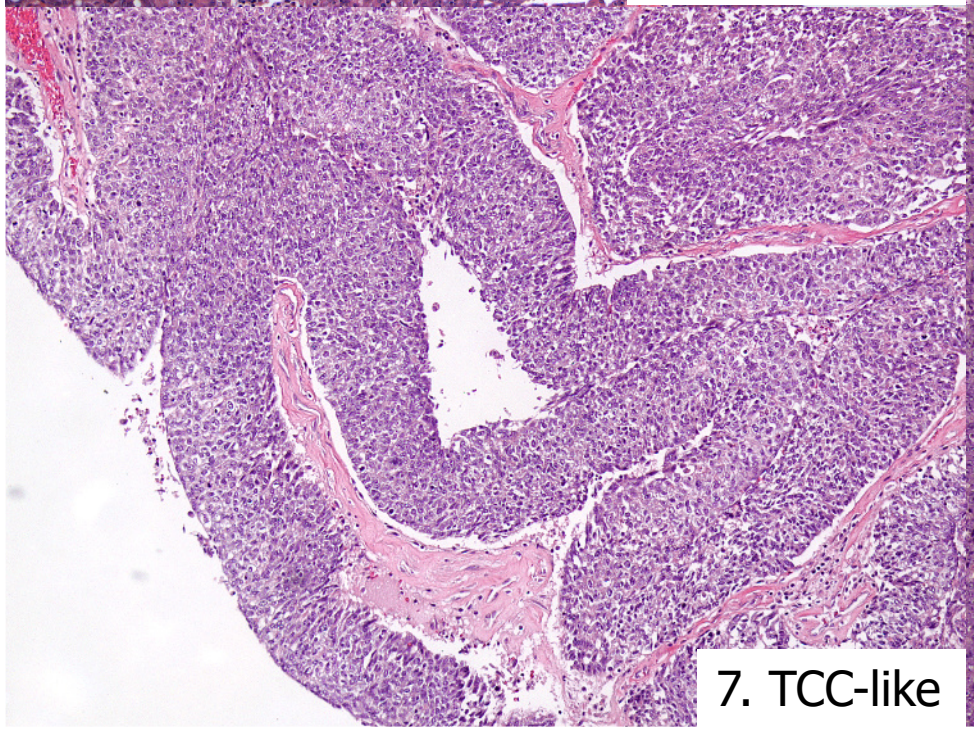

7. TCC-like

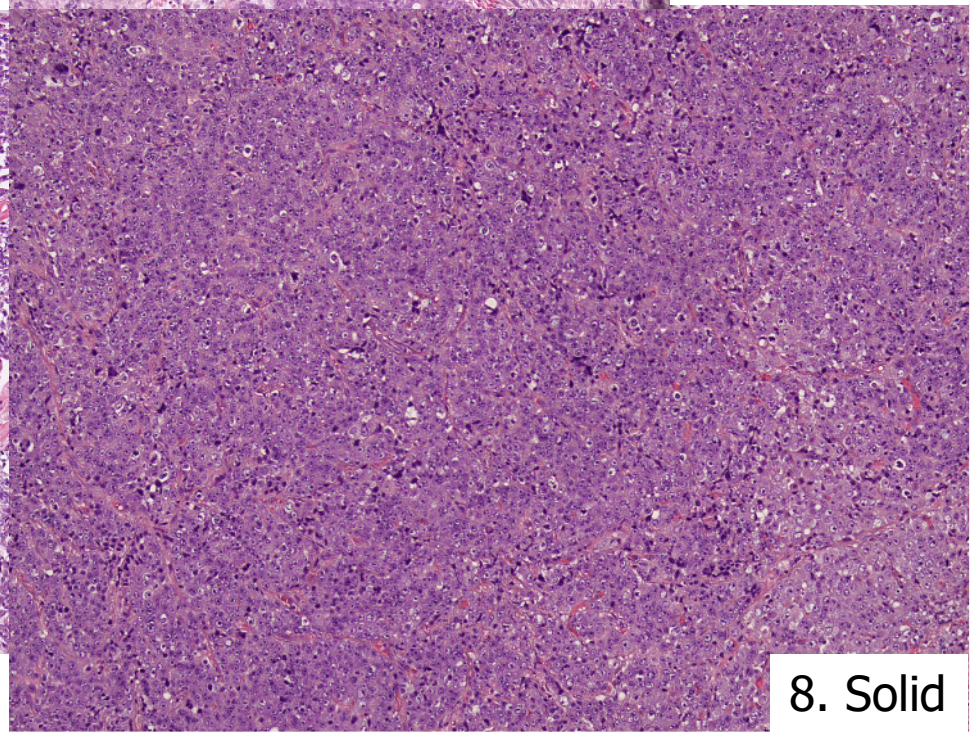

8. Solid

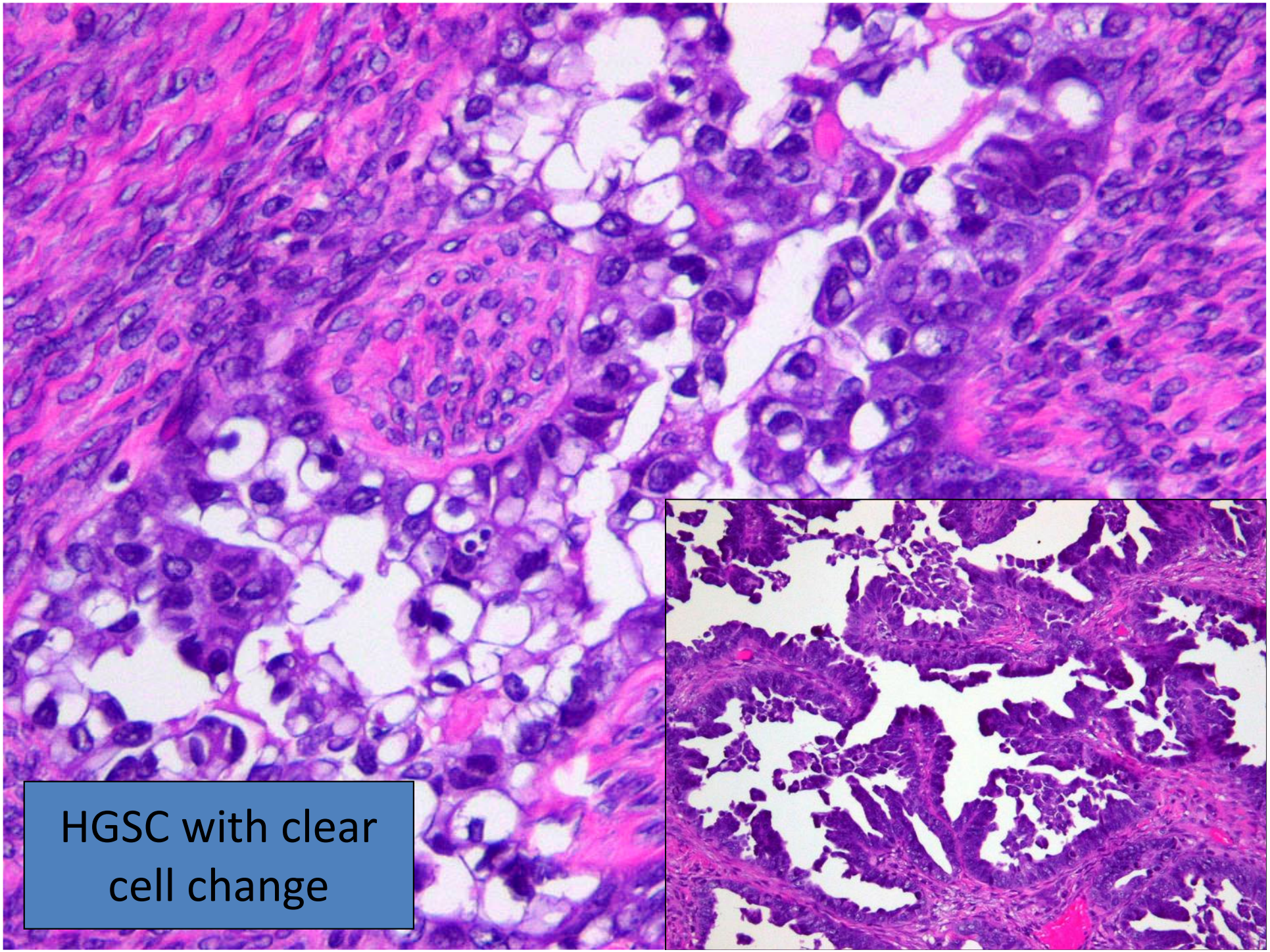
HGSC with clear cell change

Diagnostically challenging areas

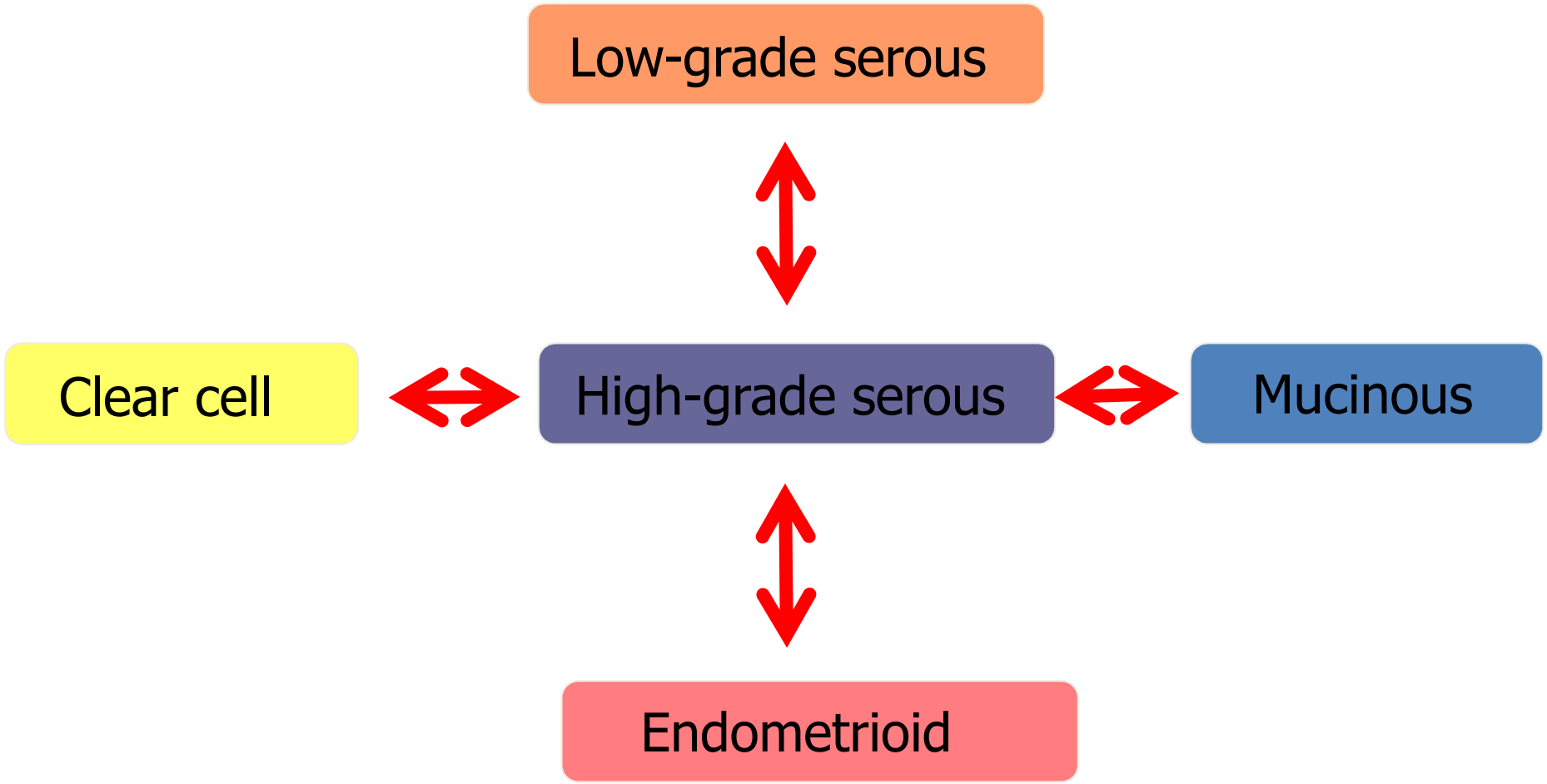

IHC marker expression

	HGSC	LGSC	EC	CCC	MC
PAX8 present	98%	100%	85%	98%	35-60%
WT1 present	97%	98%	10%	1%	0.5%
TP53 abnormal	94%	0	14%	12%	61%
P16 block	65%	3%	8%	17%	10%
Napsin A present	2%	0	8%	92%	3%
PR present	37%	58%	85%	7%	4%
ER present	93%	96%	90%	15%	9%

Int J Gynecol Pathol 2016; 35:430-441

Immunostains for histotype differential diagnosis:

1. HGSC vs LGSC: p53
2. Serous vs Endometrioid: WT1, p53
3. Clear Cell vs Serous: WT1, ER, Napsin A
4. Mucinous vs Endometrioid: ER

HGSC IHC panel

- PAX8 (ER or PR, or CA125 – fair specificity for breast vs ovary)

- WT1:
  - fairly but not entirely specific for serous tumours
  - ⬇ intensity after chemoRx (Casey et al, 2017)
  - ?prognostic value; needs further study
  - ALSO POSITIVE: mesothelial cells, AGCT, SCCHT

- p53

- p16

p53 IHC in HGSC (and USC)

- (p53 IHC interpretation is tumour-specific)

- Optimised p53 IHC is good surrogate for *TP53* mutation

- **Optimisation of protocol is essential**
- **Correct interpretation is essential**

- Classically “all or none”
- Recent identification of further patterns

Interpretation of p53 immunohistochemistry

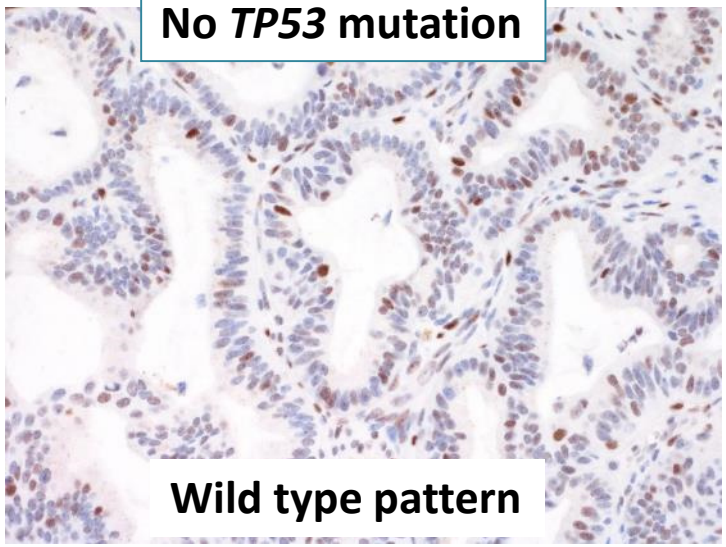

Normal

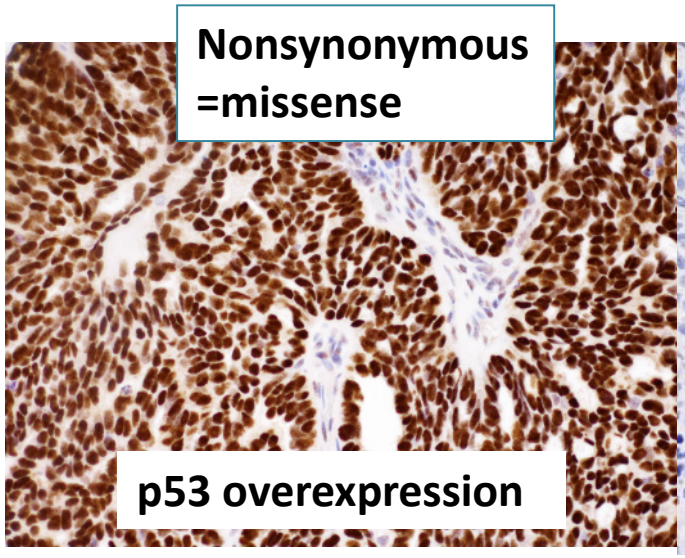

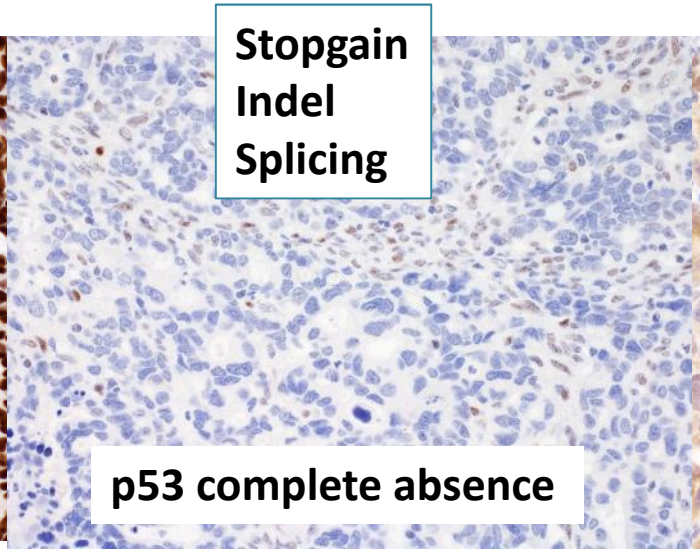

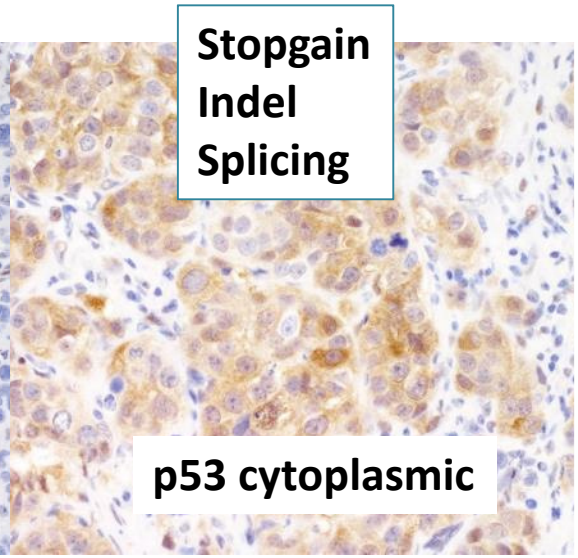

Abnormal

J Pathol Clin Res 2016;2:247

p53 IHC Interpretation

(www.thebagp/resources)

Pattern	p53 IHC interpretation	*TP53* mutation type	Frequency in HGSC
		***TP53* MUTATION ABSENT**	
Wild type	Normal	No mutation	<1%
		***TP53* MUTATION PRESENT**	
Overexpression	Abnormal	Non-synonymous (missense); also in-frame deletion, splicing	66%
Complete absence/ null	Abnormal	Indels, stopgains, splicing mutations	25%
Cytoplasmic	Abnormal	Indels and stopgains with disruption of the nuclear localization domain	2%
Wild type	Normal	Truncating mutation	4%

Optimal On-slide Control for p53: TONSIL

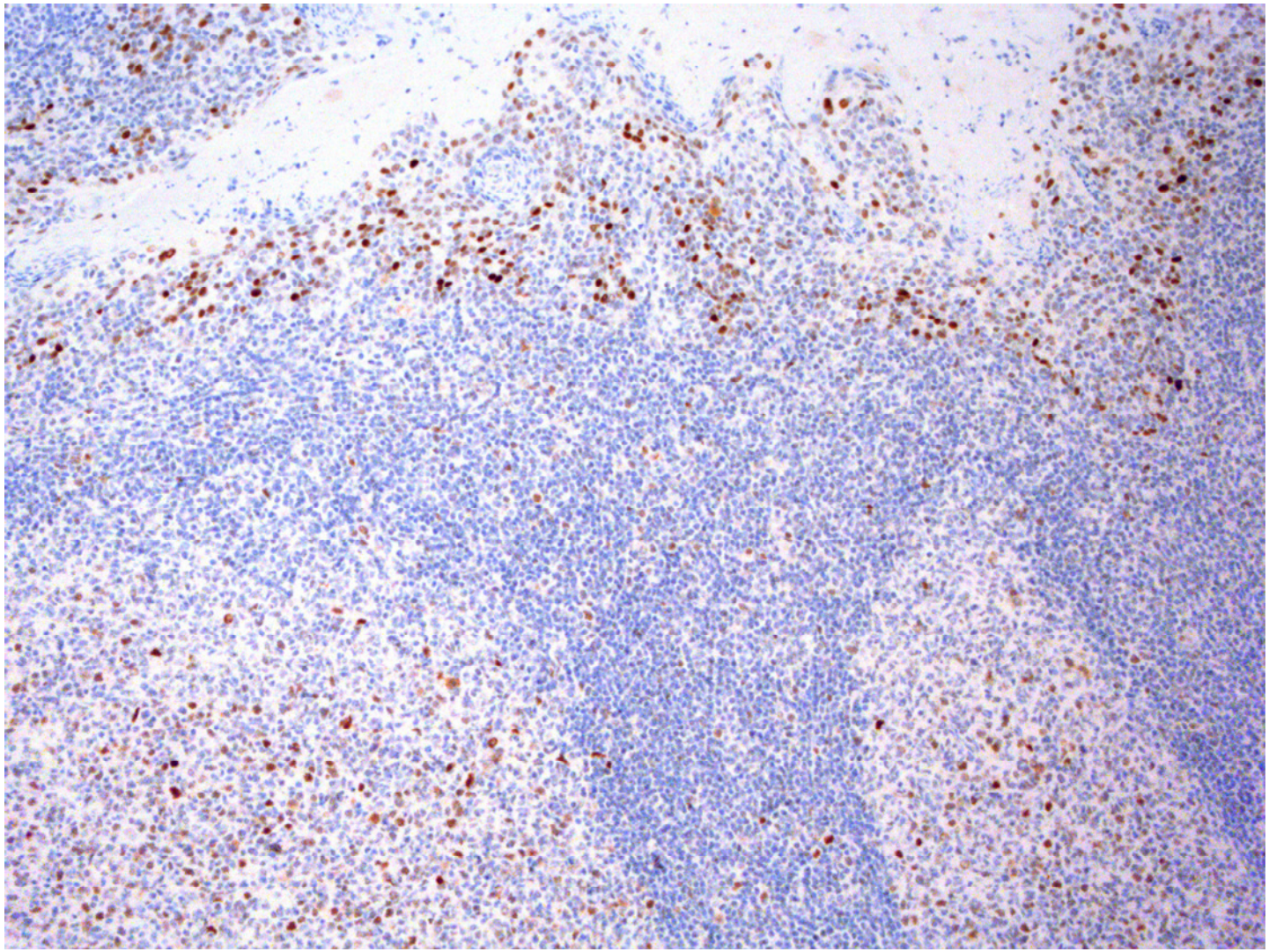

ORIGINAL ARTICLE

Morphologic and Molecular Characteristics of Mixed Epithelial Ovarian Cancers

Robertson Mackenzie, BSc, Aline Talhouk, PhD,† Sima Eshragh, MD,‡ Sherman Lau, BSc,‡ Daphne Cheung, BMLSc,‡ Christine Chow, BMLSc,‡ Nhu Le, PhD,§ Linda S. Cook, PhD,‖ Nafisa Wilkinson, MD,¶ Jacqueline McDermott, MD,# Naveena Singh, MD,# Friedrich Kommoss, MD,** Jacobus Pfisterer, MD,†† David G. Huntsman, MD,*†‡‡ Martin Köbel, MD,§§ Stefan Kommoss, MD,‖‖ C. Blake Gilks, MD,†‡ and Michael S. Anglesio, PhD†‡‡*

Am J Surg Pathol 2015

- Historically up to 11% OC classified as ‘mixed
- Review of 871 cases of ovarian carcinoma with classification by current criteria
- <1% (population-based data) truly mixed
- Usually endometriosis-related histotypes
- Mixed [ECa + CCC] and [ECa + LGSC] accounted for most cases

Morphologic and Molecular Characteristics of Mixed Epithelial Ovarian Cancers

Robertson Mackenzie, BSc, Aline Talhouk, PhD,† Sima Eshragh, MD,‡ Sherman Lau, BSc,‡ Daphne Cheung, BMLSc,‡ Christine Chow, BMLSc,‡ Nhu Le, PhD,§ Linda S. Cook, PhD,‖ Nafisa Wilkinson, MD,¶ Jacqueline McDermott, MD,# Naveena Singh, MD,# Friedrich Kommoss, MD,** Jacobus Pfisterer, MD,†† David G. Huntsman, MD,*†‡‡ Martin Köbel, MD,§§ Stefan Kommoss, MD,‖‖ C. Blake Gilks, MD,†‡ and Michael S. Anglesio, PhD†‡‡*

- 22 cases of 'mixed Ca:
  - 9 EC-CCC
  - 4 EC-LGSC
  - 3 HGSC-CCC
  - 2 MC-CCC
  - 4 other
- 41% (9/22) of "mixed" carcinomas showed uniform molecular/immunophenotype throughout; 59% (12/22) mixed morphologically and otherwise)

Am J Surg Pathol 2015

This case HGSC-CCC truly ‘mixed’ (?collision) tumour

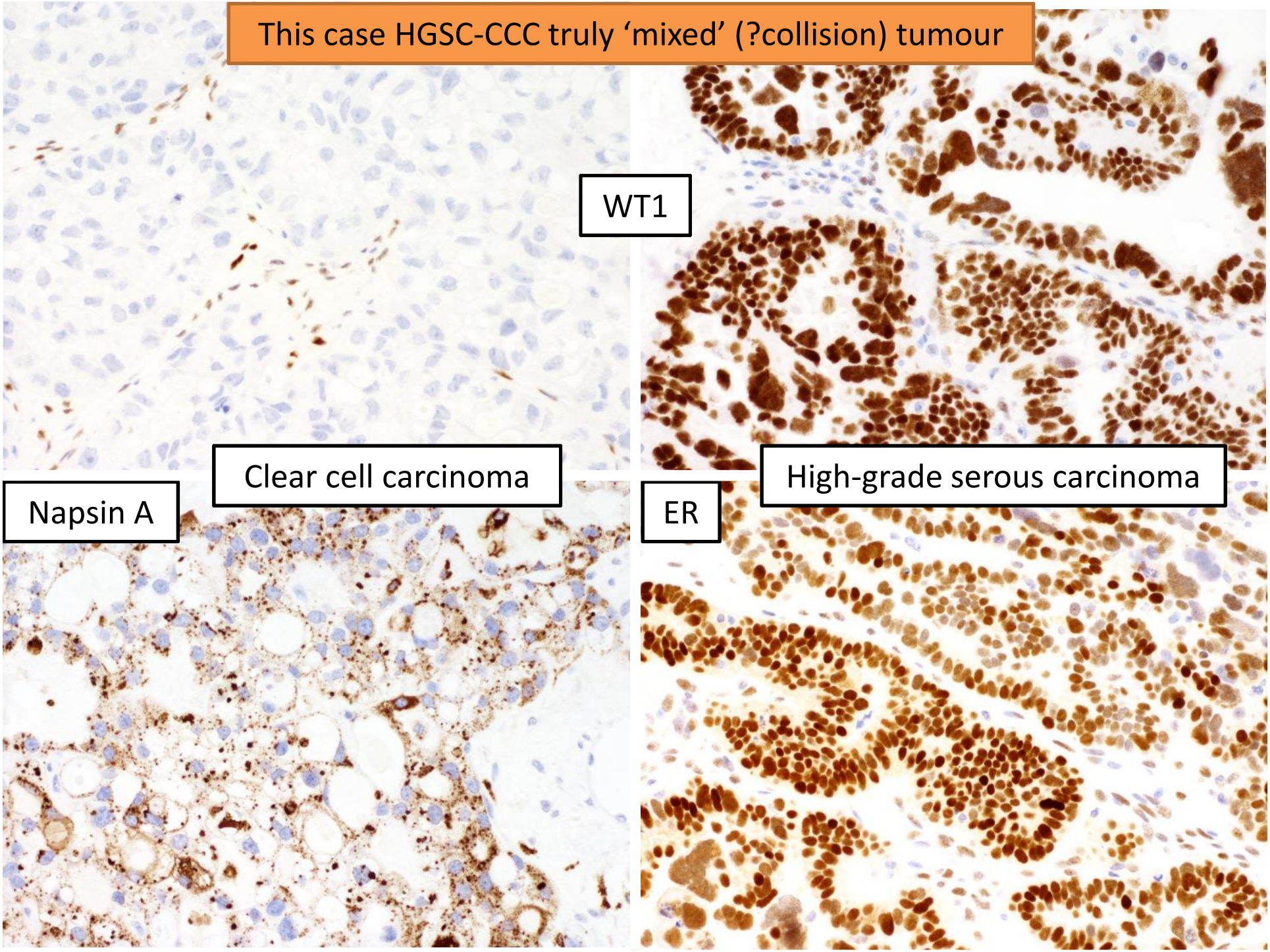

Case 7 Diagnosis

- Mixed HGSC-CCC

Case 7 learning points

- Ovarian carcinomas belong to 5 major histotypes
- Easily and reproducibly classifiable using morphology and limited panel of IHC
- Important management implications
- ‘Mixed’ carcinoma is rare (<1% of OC) (but not non-existent)
- Most cases are mixtures of endometriosis-associated OC
- (Likely to return in WHO 2020!)