Barts Health NHS
NHS Trust

Problems in Staging of Gynaecological Cancers

Naveena Singh, Consultant Pathologist

Technology Transfer in Diagnostic Pathology 10th CE
Regional Meeting – Gynecological Pathology
Visegrád, Hungary
June 28, 2019

Acknowledgements

- Professor W Glenn McCluggage, Belfast, UK

- Dr Varsha Shah, Newport, UK

For their generous help with slides and photographs

Outline

- Introduction
- Ovarian carcinoma
- Cervical carcinoma
- Endometrial carcinoma
- Vulval carcinoma
- Conclusions

Introduction

- Purpose of staging:
  - To enable comparisons between centres
  - To assign disease to a specific prognostic category
    - For patient and family
    - For optimal treatment
- Gyn cancers broadly staged according to FIGO; TNM system is mostly aligned to FIGO
- International Collaboration on Cancer Reporting (ICCR): datasets for standardised reporting of all pathology, including stage:http://www.rcpa.edu.au/Library/Practising-Pathology/ICCR/Cancer-Datasets

Ovarian cancer

FIGO 2013: Unified staging for O, T, P

- Need to assign primary site
- Need to assign histotype

FIGO 2013 ovarian cancer staging: New features

STAGE I: Tumor confined to ovaries			
FIGO 2013		FIGO 1988	
IA	Tumor limited to 1 ovary, capsule intact, no tumor on surface, negative washings.	IA	Tumor limited to 1 ovary, capsule intact, no tumor on surface, negative washings/ascites.
IB	Tumor involves both ovaries otherwise like IA.	IB	Tumor involves both ovaries otherwise like IA.
IC	Tumor limited to 1/both ovaries	IC	Tumor involves 1 or both ovaries with any of the following: capsule rupture, tumor on surface, positive washings/ascites.
IC1	Surgical spill		
IC2	Capsule rupture before surgery or tumor on ovarian surface.		
IC3	Malignant cells in the ascites or peritoneal washings.		

FIGO 2013 ovarian cancer staging: New features

STAGE II: Tumor involves 1 or both ovaries with pelvic extension (below the pelvic brim) or primary peritoneal cancer			
FIGO 2013		FIGO 1988	
IIA	Extension and/or implant on uterus and/or Fallopian tubes	IIA	Extension and/or implant on uterus and/or Fallopian tubes
IIB	Extension to other pelvic intraperitoneal tissues	IIB	Extension to other pelvic intraperitoneal tissues
		IIC	IIA or IIB with positive washings/ascites.

FIGO 2013 ovarian cancer staging: New features

STAGE III: Tumor involves 1 or both ovaries with cytologically or histologically confirmed spread to the peritoneum outside the pelvis and/or metastasis to the retroperitoneal lymph nodes			
FIGO 2013		FIGO 1988	
IIIA (Positive retroperitoneal lymph nodes and /or microscopic metastasis beyond the pelvis)		IIIA	Microscopic metastasis beyond the pelvis.
IIIA1	Positive retroperitoneal lymph nodes only IIIA1i: Metastasis ≤ 10 mm IIIA1ii: Metastasis > 10 mm		
IIIA2	Microscopic, extrapelvic (above the brim) peritoneal involvement ± positive retroperitoneal lymph nodes		

FIGO 2013 ovarian cancer staging: New features

STAGE III: Tumor involves 1 or both ovaries with cytologically or histologically confirmed spread to the peritoneum outside the pelvis and/or metastasis to the retroperitoneal lymph nodes			
FIGO 2013		FIGO 1988	
IIIB	Macroscopic, extrapelvic, peritoneal metastasis ≤ 2 cm ± positive retroperitoneal lymph nodes. Includes extension to capsule of liver/spleen.	IIIB	Macroscopic, extrapelvic, peritoneal metastasis ≤ 2 cm in greatest dimension.
IIIC	Macroscopic, extrapelvic, peritoneal metastasis > 2 cm ± positive retroperitoneal lymph nodes. Includes extension to capsule of liver/spleen.	IIIC	Macroscopic, extrapelvic, peritoneal metastasis > 2 cm in greatest dimension and/or regional lymph node metastasis.

FIGO 2013 ovarian cancer staging: New features

Stage 1: Tumour confined to ovaries			
FIGO 2013		FIGO 1988	
IVA	Pleural effusion with positive cytology	IV	Distant metastasis excluding peritoneal metastasis. Includes hepatic parenchymal metastasis.
IVB	Hepatic and/or splenic parenchymal metastasis, metastasis to extra- abdominal organs (including inguinal lymph nodes and lymph nodes outside of the abdominal cavity)		

Ovarian cancer staging: Specific issues highlighted by FIGO

- what is the appropriate stage designation for a case showing tumor limited to one ovary (or a peritoneal site) and STIC?, and

- bilateral involvement (stage IB), i.e. whether these constitute independent contralateral primary tumours or metastases

Ovarian cancer staging: Other issues

- Dense pelvic adhesions requiring sharp dissection: Stage I or stage II?
  - Usually endometriosis-related
  - FIGO recommends upstaging only if microscopically proven tumour in tissues outside the adnexa
- Many others, principally questioning whether staging should be based on volume or locations affected; needs prospective study

Cervical cancer

FIGO 2018

Received: 24 July 2018 | Revised: 5 November 2018 | Accepted: 20 December 2018

DOI: 10.1002/ijgo.12749

FIGO COMMITTEE REPORT

WILEY GYNECOLOGY OBSTETRICS FIGO

Revised FIGO staging for carcinoma of the cervix uteri ☆

Neerja Bhatla[1,*] | Jonathan S. Berek[2] | Mauricio Cuello Fredes[3] | Lynette A. Denny[4] | Seija Grenman[5] | Kanishka Karunaratne[6] | Sean T. Kehoe[7] | Ikuo Konishi[8] | Alexander B. Olawaiye[9] | Jaime Prat[10] | Rengaswamy Sankaranarayanan[11,12]

[1]Division of Gynaecologic Oncology, Department of Obstetrics and Gynaecology, All India Institute of Medical Sciences, New Delhi, India

[2]Stanford Women's Cancer Center, Stanford Cancer Institute, Stanford University School of Medicine, Stanford, CA, USA

[3]Division Obstetrics and Gynecology, School of Medicine, Pontificia Universidad Católica de Chile, Santiago, Chile

[4]Department of Obstetrics and Gynaecology, Groote Schuur Hospital and SAMRC Gynaecology Cancer Research Centre, University of Cape Town, Cape Town, South Africa

[5]University of Turku and Department of Obstetrics and Gynecology, Turku University Hospital, Turku, Finland

[6]Department of Obstetrics and Gynaecology, Faculty of Medicine, University of Colombo, Colombo, Sri Lanka

[7]University of Birmingham and St. Peters College, Oxford, UK

[8]National Hospital Organization Kyoto Medical Center, Kyoto, Japan

[9]Division of Gynecologic Oncology, Department of Obstetrics, Gynecology and Reproductive Sciences, University of Pittsburgh School of Medicine, Pittsburgh, PA, USA

[10]Autonomous University of Barcelona, Barcelona, Spain

[11]International Agency for Research on Cancer (WHO-IARC), Lyon, France

[12]RTI International India, New Delhi, India

FIGO 2018 Cervix Cancer Staging: Salient changes

- ***Horizontal dimension no longer considered in defining the upper boundary of a Stage IA carcinoma.***
- ***Diagnosis of Stage IA1 and IA2 carcinomas is made on microscopic examination of a surgical specimen, which includes the entire lesion.***
  - ***Margins of an excision specimen should be reported to be negative***
  - ***If margins of the cone biopsy are positive for invasive cancer, the stage is assigned as IB1***
- ***Stage IB sub-divided into IB1, IB2 and IB3 based on maximum tumour size.***
- ***Revised 2018 system includes nodal status; the presence of nodal involvement in a tumour of any size upstages the case to Stage IIIC, with IIIC1 indicating pelvic and IIIC2 indicating para-aortic nodal involvement. (Revised FIGO classification thereby now more closely aligned with TNM).***

Stage I (2018): Carcinoma strictly confined to the cervix (extension to the uterine corpus should be disregarded)		
2009 FIGO stage: Description	**2018 FIGO stage: Description**	**Comment**
IA: Invasive carcinoma diagnosed only by microscopy, with maximum depth of invasion </= 5mm and largest extension </= 7 mm	***IA: Invasive carcinoma diagnosed only by microscopy, with maximum depth of invasion <5mm***	**-Lateral extent of the carcinoma is no longer considered in distinguishing between FIGO Stage IA and IB carcinomas** **- If margins of loop are involved patient is allocated to Stage IB1.**
IA1: Measured stromal invasion <3 mm in depth and extension </= 7 mm	IA1: Measured stromal invasion <3 mm in depth	
IA2: Measured stromal invasion >/=3 mm and <5 mm in depth and extension </= 7 mm	IA2: Measured stromal invasion >/=3 mm and <5 mm in depth	
IB: Clinically visible lesions limited to the cervix or pre-clinical cancers greater than stage IA	***IB: Invasive carcinoma with measured deepest invasion >/= 5 mm (greater than Stage IA), lesion limited to the cervix uteri***	**-See above** **-LVSI must be commented upon, although does not affect FIGO stage.**
IB1: Clinically visible lesion </= 4.0cm in greatest dimension	IB1: Invasive carcinoma >/= 5 mm depth of stromal invasion, and <2 cm in greatest dimension	**-New stage category**
	IB2: Invasive carcinoma >/= 2 cm and < 4 cm in greatest dimension	**-New stage category**
IB2: Invasive carcinoma > 4 cm in greatest dimension	IB3: Invasive carcinoma >/= 4 cm in greatest dimension	**-New stage category**

Stage II (2018): Carcinoma invades beyond the uterus, but has not extended onto the lower third of the vagina or to the pelvic wall		
2009 FIGO stage: Description	**2018 FIGO stage: Description**	**Comment**
IIA: Without parametrial invasion	*IIA: Involvement limited to the upper two-thirds of the vagina without parametrial involvement*	- No major change
IIA1: Clinically visible lesion </= 4 cm in greatest dimension	IIA1: Invasive carcinoma < 4cm in greatest dimension	
IIA2: Clinically visible lesion > 4 cm in greatest dimension	IIA2: Invasive carcinoma >/= 4 cm in greatest dimension	
IIB: With obvious parametrial invasion	*IIB: With parametrial involvement but not up to the pelvic wall*	-No change

Stage III (2018): Carcinoma involves the lower third of the vagina and/or extends to the pelvic wall and/or causes hydronephrosis or non-functioning kidney and/or involves pelvic and/or para-aortic lymph nodes		
2009 FIGO stage: Description	**2018 FIGO stage: Description**	**Comment**
IIIA: Tumour involves lower third of the vagina, with no extension to the pelvic wall	*IIIA: Carcinoma involves the lower third of the vagina with no extension to the pelvic wall*	-No change
IIIB: Extension to the pelvic wall and/or hydronephrosis or non-functioning kidney	*IIIB: Extension to the pelvic wall and and/or causes hydronephrosis or non-functioning kidney*	-No change
	*IIIC: Involvement of pelvic and/or para-aortic lymph nodes, irrespective of tumour size and extent (with r and p notations)**	-New stage category
	IIIC1: Pelvic lymph node metastasis only	
	IIIC2: Para-aortic lymph node metastasis	

*Adding notation of r (imaging) and p (pathology) to indicate the findings that are used to allocate the case to Stage IIIC.
Example: If imaging indicates pelvic lymph node metastasis, the stage allocation would be IIIC1r, and if confirmed by pathology, it would be IIIC1p.
The type of imaging modality or pathology technique should always be documented.

Confusing statement about micrometastasis

Stage IV (2018): Carcinoma has extended beyond the true pelvis or has involved (biopsy-proven) the mucosa of the bladder or rectum. (A bullous oedema, as such, does not permit a case to be allotted to Stage IV.)		
2009 FIGO stage: Description	2018 FIGO stage: Description	Comment
IVA: Spread of the growth to adjacent organs	*IVA: Spread to adjacent pelvic organs*	-No change
IVB: Spread to distant organs	*IVB: Spread to distant organs*	

TUMOUR DIMENSIONS

- Important for staging, management and prognostication
- Small carcinomas (IA1, IA2, IB1)- accurate staging, critical for patient management
- Radical hysterectomy versus trachelectomy - cut-off of 2cm sometimes used
- 4cm cut-off (IB1/IB2 and IIA1/ IIA2)
- 2cm size may be of prognostic value in IB1 tumours

TUMOUR MEASUREMENT

- **CAN BE EXTREMELY DIFFICULT**
- ICCR: Measure in 3 dimensions in mm (2 of horizontal extent, 1 depth of invasion) (allows assessment of tumour volume)
- **Combinations of gross and microscopic** in different cases (do not give 2 separate measurements)
- Measurements in any prior specimens (loops/cones should be taken into account)
- Multifocal tumours (ICCR): stage according to largest
- Diameter vs circumference issue: clincial and imaging assessments are of diameter; “opening-up” circumferential tumours overestimates tumour size

MEASUREMENT OF DEPTH OF INVASION

- Measure from base of epithelium from which tumour arises (surface or crypt) to deepest point of invasion
- If no obvious epithelial origin despite multiple levels, measure from tumour base to base of nearest surface epithelium

Measurement of depth and lateral extent

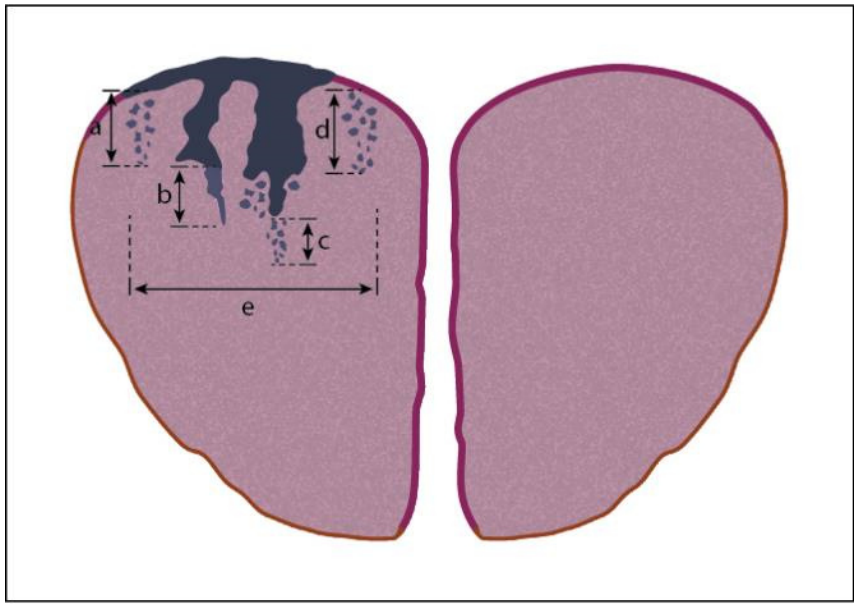

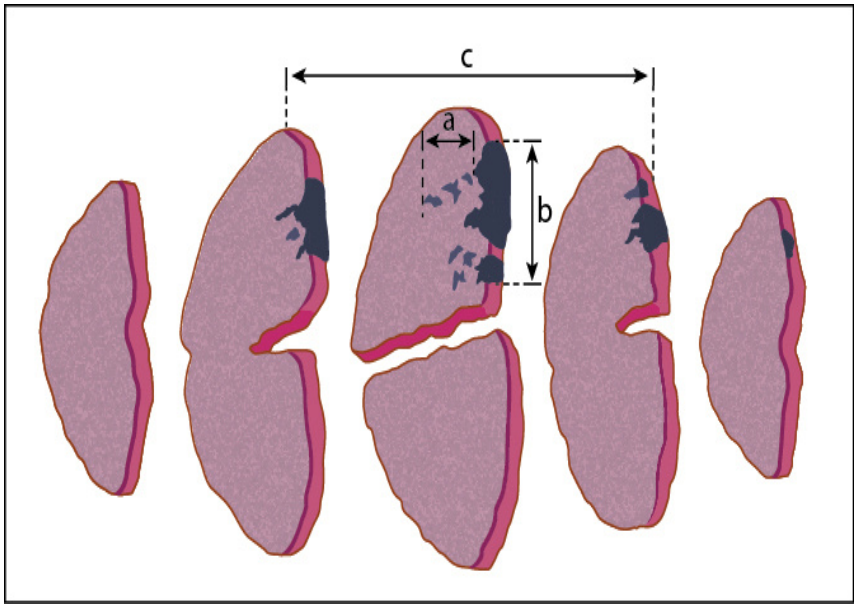

FIGO 2018 no longer requires horizontal measurement for FIGO stage I vs II distinction

MEASUREMENT OF TUMOUR THICKNESS RATHER THAN DEPTH OF INVASION

IN SOME SITUATIONS, THICKNESS IS TAKEN AS A SURROGATE OF DEPTH OF INVASION AND MAY GIVE INCORRECT ESTIMATE OF INVASIVE DEPTH

- AIS/CGIN with invasion – cannot distinguish invasive from in-site component clearly (may overestimate)
- Ulcerated tumours (may underestimate depth of invasion)
- Polypoid exophytic tumours (adenocarcinomas and squamous carcinomas)

ADENOCARCINOMA- GLANDULAR ARCHITECTURAL COMPLEXITY AND EXTENSION BEYOND THE NORMAL GLAND FIELD



EXOPHYTIC TUMOURS

- Exophytic tumours with little/ no stromal invasion (do not misdiagnose as in-situ carcinomas)
- Especially with adenocarcinomas; rarely with squamous carcinomas
- Measure thickness (equates with depth of stromal invasion)
- Probably no real evidence that can be safely treated conservatively

EXOPHYTIC TUMOURS

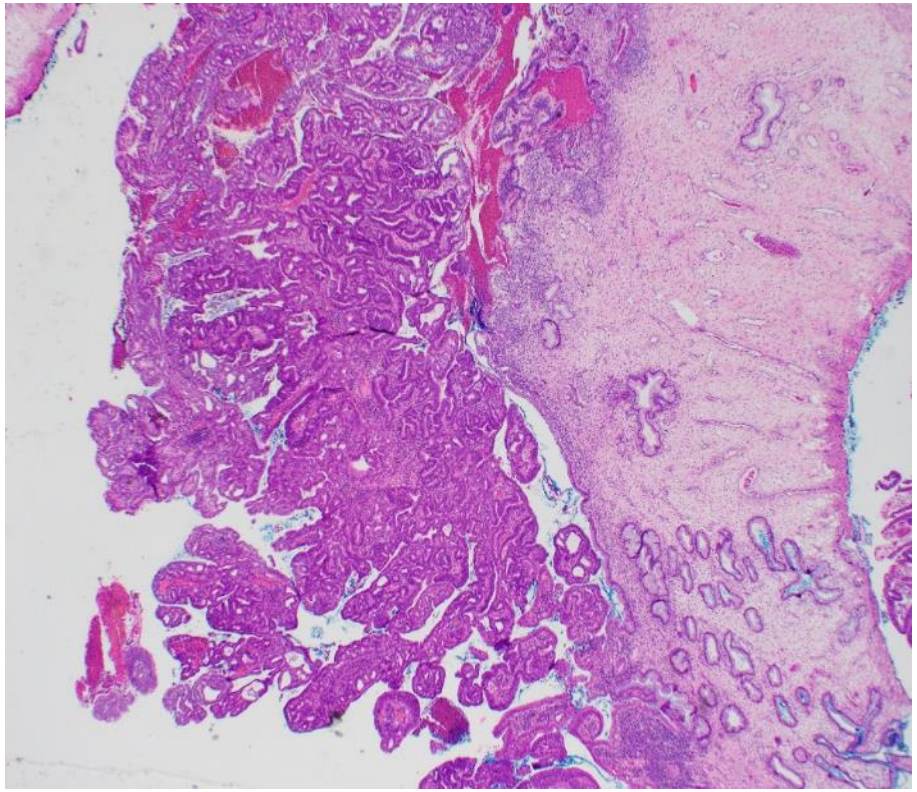

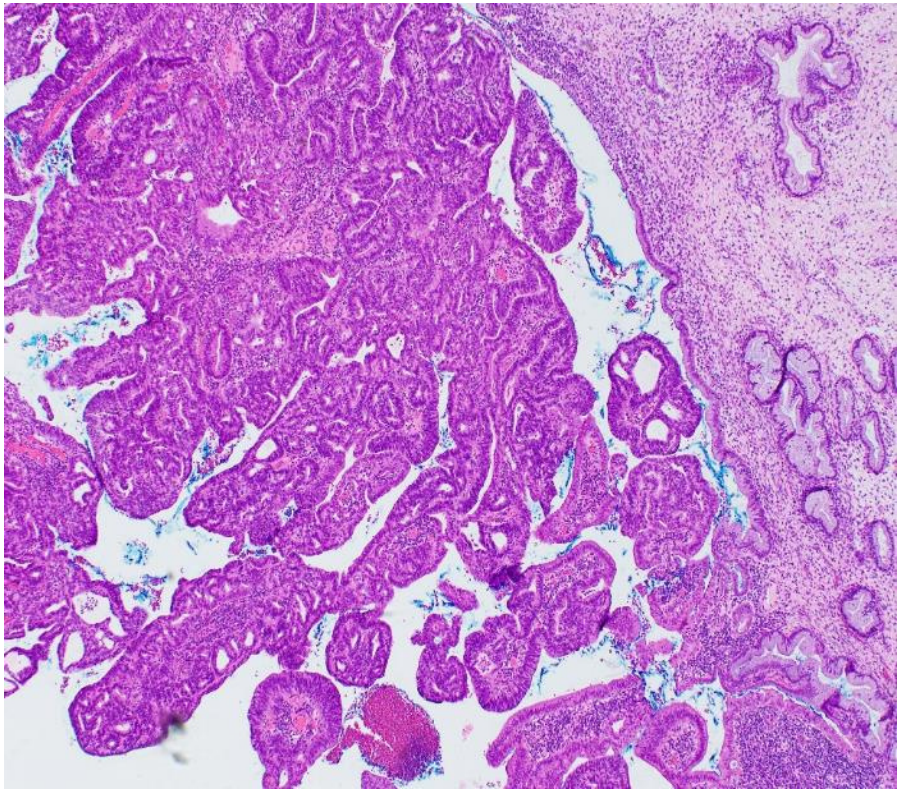

PRIOR CONE/ LOOP

- Add maximum horizontal dimension of tumour in initial cone/ loop and maximum horizontal dimension of tumour in final cone/ loop/ hysterectomy/ trachelectomy together; WILL LIKELY OVERESTIMATE MAXIMUM HORIZONTAL DIMENSION
- Maximum depth of invasion in cone/ loop or hysterectomy/ trachelectomy is taken as maximum depth of invasion; do not add together

MULTIFOCAL STAGE IA1 SQUAMOUS CARCINOMAS

International Journal of Gynecological Pathology
33:213–217, Lippincott Williams & Wilkins, Baltimore
© 2014 International Society of Gynecological Pathologists

Original Article

Multifocal FIGO Stage 1A1 Cervical Squamous Carcinomas have an Extremely Good Prognosis Equivalent to Unifocal Lesions

Patrick McIlwaine, M.D., Hans Nagar, F.R.C.O.G., and W. Glenn McCluggage, F.R.C.Path.

International Journal of Gynecological Pathology
00:1–8, Lippincott Williams & Wilkins, Baltimore
© 2016 International Society of Gynecological Pathologists

Original Article

Multifocal FIGO Stage IA1 Squamous Carcinoma of the Cervix: Criteria for Identification, Staging, and its Good Clinical Outcome

Elizabeth Day, M.B., B.Chir., Ph.D., Siobhan Duffy, B.Sc., M.B.Ch.B., Gareth Bryson, B.Sc., M.B.Ch.B., F.R.C.Path., Sheeba Syed, M.B.B.S., M.D., M.R.C.Path., Smruta Shanbhag, M.B.B.S., M.R.C.O.G., Kevin Burton, M.B.C.H.B., M.D., M.R.C.O.G., Rhona Lindsay, B.Sc., M.B.Ch.B., M.R.C.O.G., Nadeem Siddiqui, F.R.C.O.G., Ph.D., and David Millan, B.Sc., M.B., Ch.B., F.R.C.Path.

MULTIFOCAL STAGE IA1 SQUAMOUS CARCINOMAS

- FIGO- no guidelines (measure from one edge to the other)
- 46 cases of “multifocal” cervical squamous carcinoma treated by local excision with clear margins; no recurrences (median follow up of 45 months and 7 years in 2 studies)
- Includes many cases which would have been FIGO IB1 if measured from one edge to other as suggested by FIGO
- **PAPERS USED ARBITRARY DISTANCE OF 2mm APART; level blocks to make sure foci do not “join-up”**
- Criteria noted by ICCR and suggest can use pending more evidence
- Cases should be discussed at tumour board meeting
- Potential to avoid unnecessary radical surgery in young women
- Measure each invasive focus individually and stage on largest
- New FIGO 2018 staging system may solve some of these problems

LYMPHOVASCULAR SPACE INVASION (LVSI)

- LVSI does not affect tumour stage (tumour confined to vessels outside cervix- stage I) but document on report
- General agreement that LVSI is an adverse prognostic feature in early stage cervical cancer (IB)
- May be seen even in small cancers
- May influence management in certain cases (IA2, large IB1)
- Vascular markers not routinely performed but may assist in problematic cases
- Occasional studies have found blood vessel invasion to have a worse prognosis than lymph vessel invasion and to be a predictor of ovarian involvement; however, markers not routinely recommended

LVSI in FIGO IA1 SCC

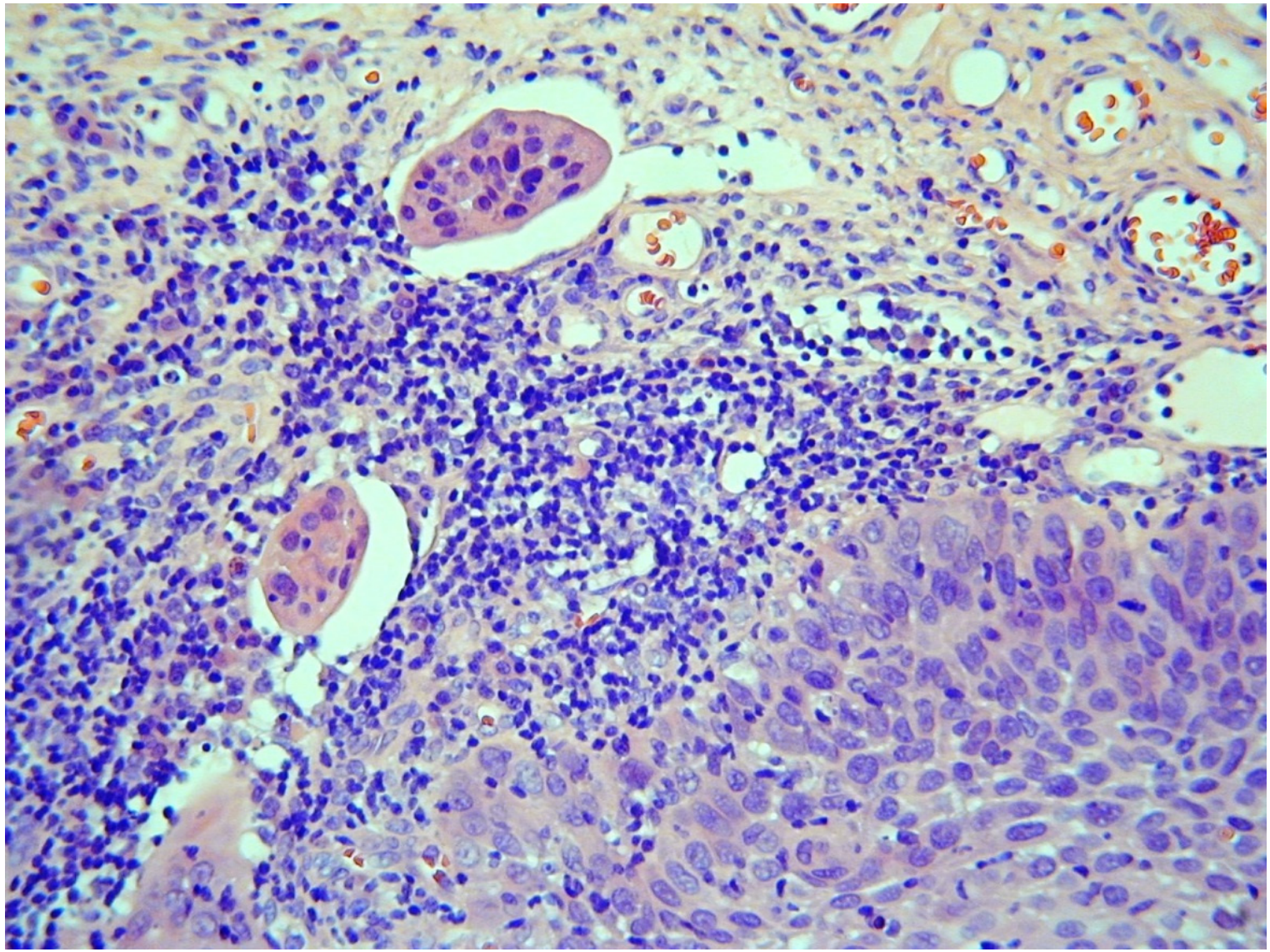

LVSI OUTSIDE ORGAN OF ORIGIN- DOESN'T UPSTAGE IN ABSENCE OF TISSUE INVOLVEMENT

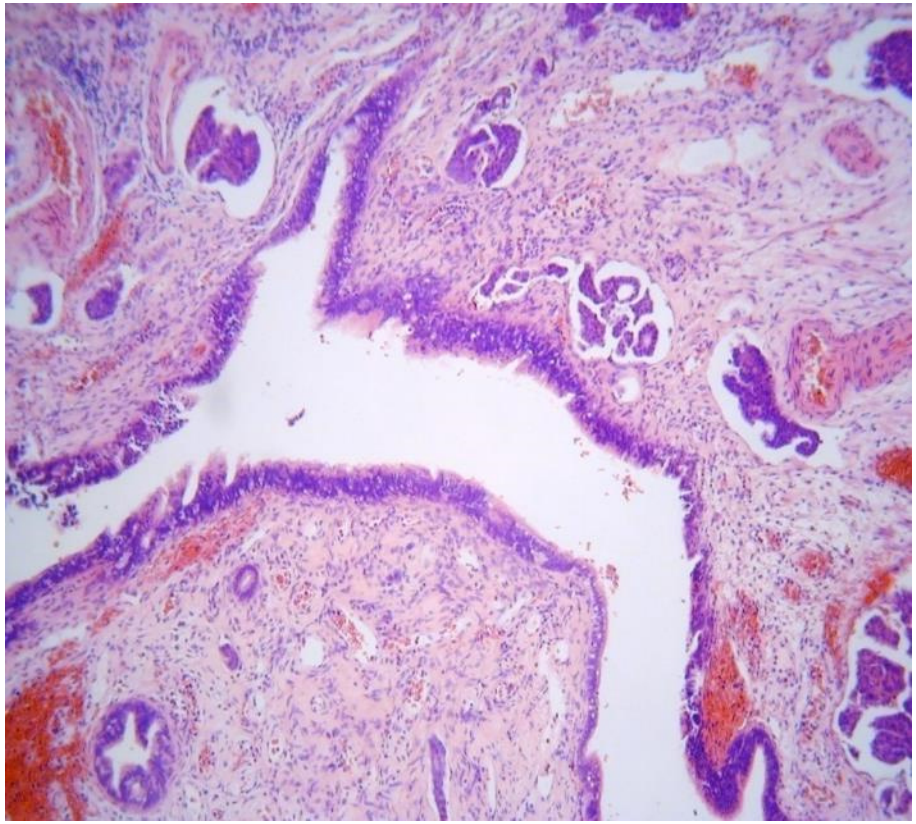

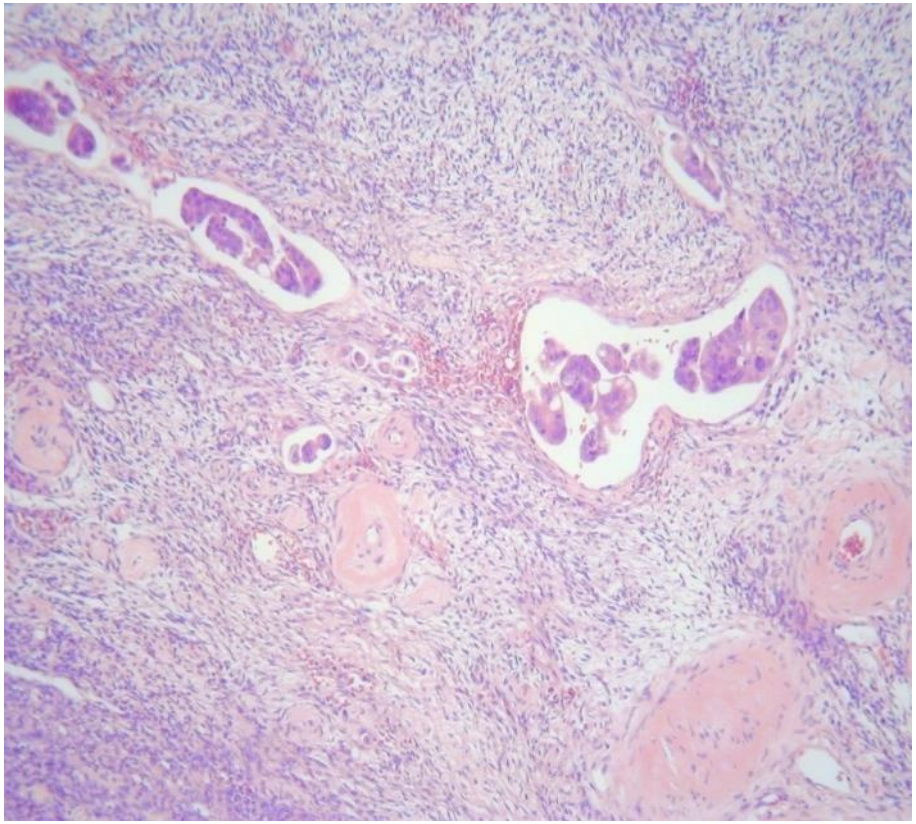

EXTENT OF INVASION

- Record macroscopic or microscopic involvement of lower uterine segment/ uterine corpus- possible increased risk of ovarian and para-aortic nodal involvement (not included in staging)
- Vaginal involvement
- Parametrial involvement
- Adnexal involvement (different patterns)
- Nodal involvement
- Other tissues

MARGIN STATUS

- FIGO 2018: Margin invovlement by invasive disease in loop/cone constitutes Stage Ib

- Status of all surgical resection margins should be provided (endocervical, ectocervical, radial/ deep stromal, vaginal)

LYMPH NODE STATUS

- One of most important prognostic parameters in cervical cancer
- Included in FIGO 2018; upstagges case of any dimension to Stage IIIC
- ESGO guidelines also include EXTRANODAL EXTENSION
- ICCR- other parameters may be recorded if locally agreed and for future research- size of nodal metastasis, extranodal extension

LYMPH NODES IN CERVICAL CANCER

- REGIONAL- paracervical/ parametrial/ pelvic/ para-aortic*
- NON-REGIONAL- inguinal/ other
- TNM Classification- REGIONAL nodal involvement categorised in N status; NON-REGIONAL nodal involvement categorised as distant metastasis

PROGNOSTIC SIGNIFICANCE OF LYMPH NODE MICROMETASTASES AND ITCs

- Little information regarding gynaecological tumours in general
- TNM8/ ICCR – macrometastasis (MAC)(>2mm); micrometastasis (MIC)(>0.2-2mm); isolated tumour cells (ITCs) (up to 0.2mm)
- MAC- pN1; MIC- pN1(mi); ITCs (pN0)
- Same definitions as in most other organs

FIGO 2018 and low volume mets

- **7.2 Controversial issues:** Presence of isolated tumor cells or micrometastases: Metastases in lymph nodes have been graded as isolated tumor cells (<0.2 mm), micrometastases (0.2–2.0 mm), or macrometastases (>2.0 mm). **Presence of isolated tumor cells or micrometastases signifies low volume metastasis and their implication is not clear. The presence of micrometastases or isolated tumor cells may be recorded but their presence does not change the stage.**

Endometrial carcinoma

Pathologic Prognostic Factors in Endometrial Carcinoma (Other Than Tumor Type and Grade)

Singh et al. Int J Gynecol Pathol 2019;38:S93-113.



2019: Open Access issue of ISGyP Project:
W Glenn McCluggage

Endometrial cancer: FIGO stage (2009)

- **Stage I: Tumour confined to the corpus uteri**
  - IA No or less than half myometrial invasion
  - IB Invasion of half or more of the myometrium
- **Stage II: Cervical stromal invasion**
- **Stage III: Local and/or regional spread of the tumour**
  - IIIA Uterine serosal and/or adnexal involvement
  - IIIB Vaginal and/or parametrial involvement
  - IIIC1 pelvic node involvement
  - IIIC2 para-aortic lymph node involvement
- **Stage IV:**
  - IVA Tumour invades bladder and/or bowel mucosa
  - IVB distant metastasis including omentum and inguinal nodes

ESMO Risk groups (2016)

- **Low risk:** Endometrioid, G1-2, **1A, LVSI-**
- **Intermediate risk:** Endometrioid, G1-2, **1B, LVSI-**
- **High-intermediate risk**
  - Endometrioid, G1-2, **1A/1B, LVSI+**
  - Endometrioid, G3, **1A, LVSI +/-**
- **High risk**
  - Endometrioid, G3, **1B, LVSI +/-**
  - Endometrioid **stage II-III**
  - Non-endometrioid

Outer myometrial invasion or not: Expansile growth pattern

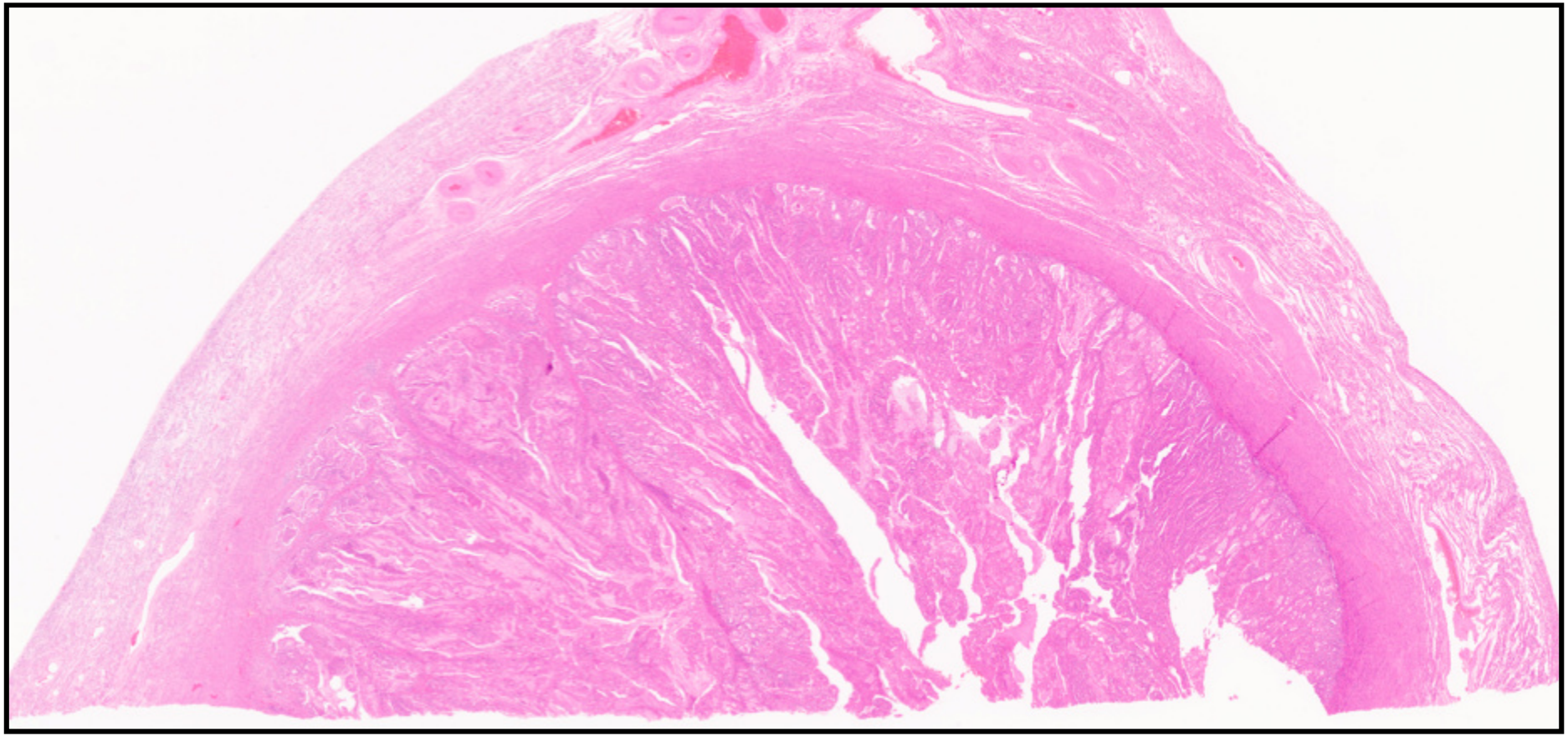

May rarely mimic 1B even when non-invasive or vice versa

Desmoplasia = myoinvasion

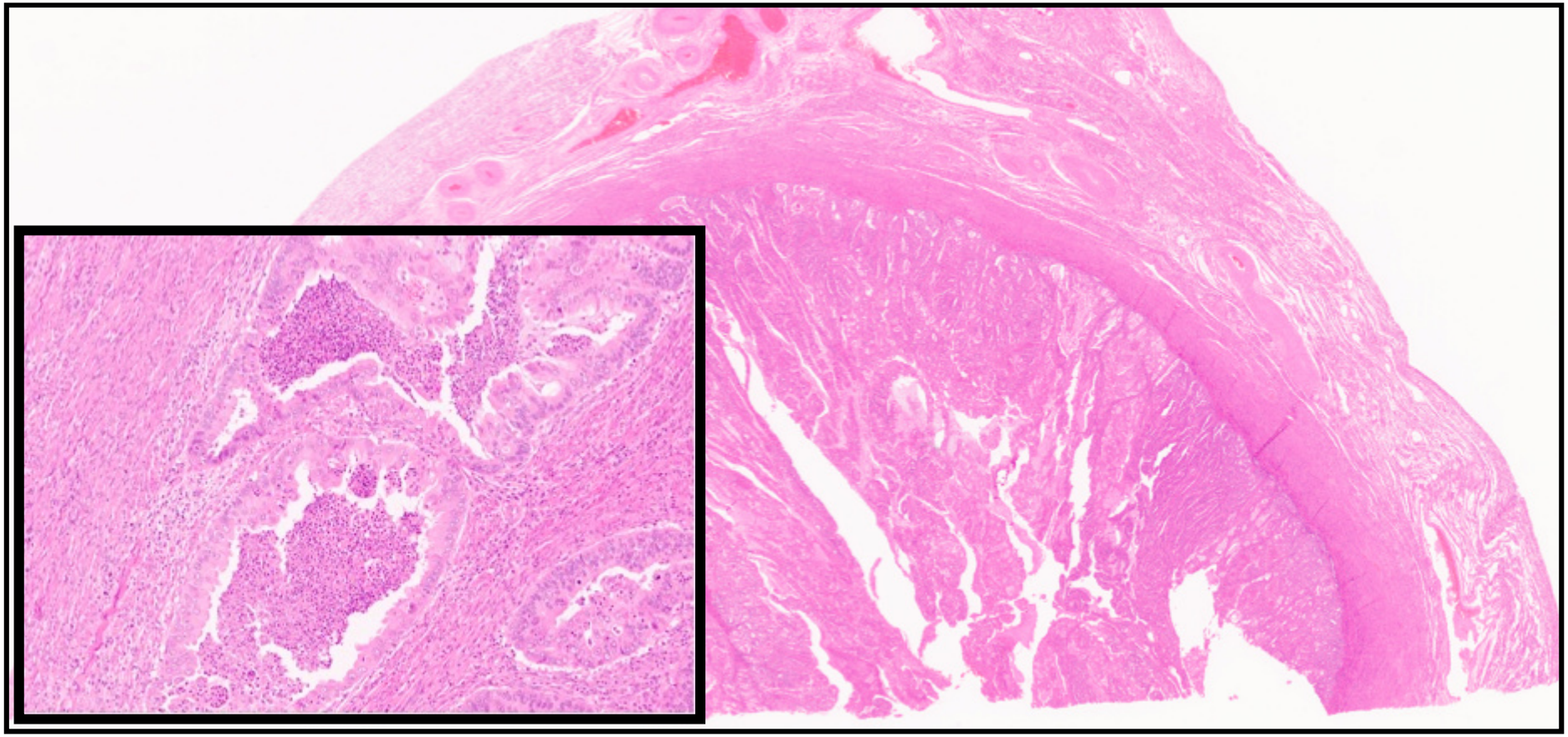

Benign glands at base = no invasion

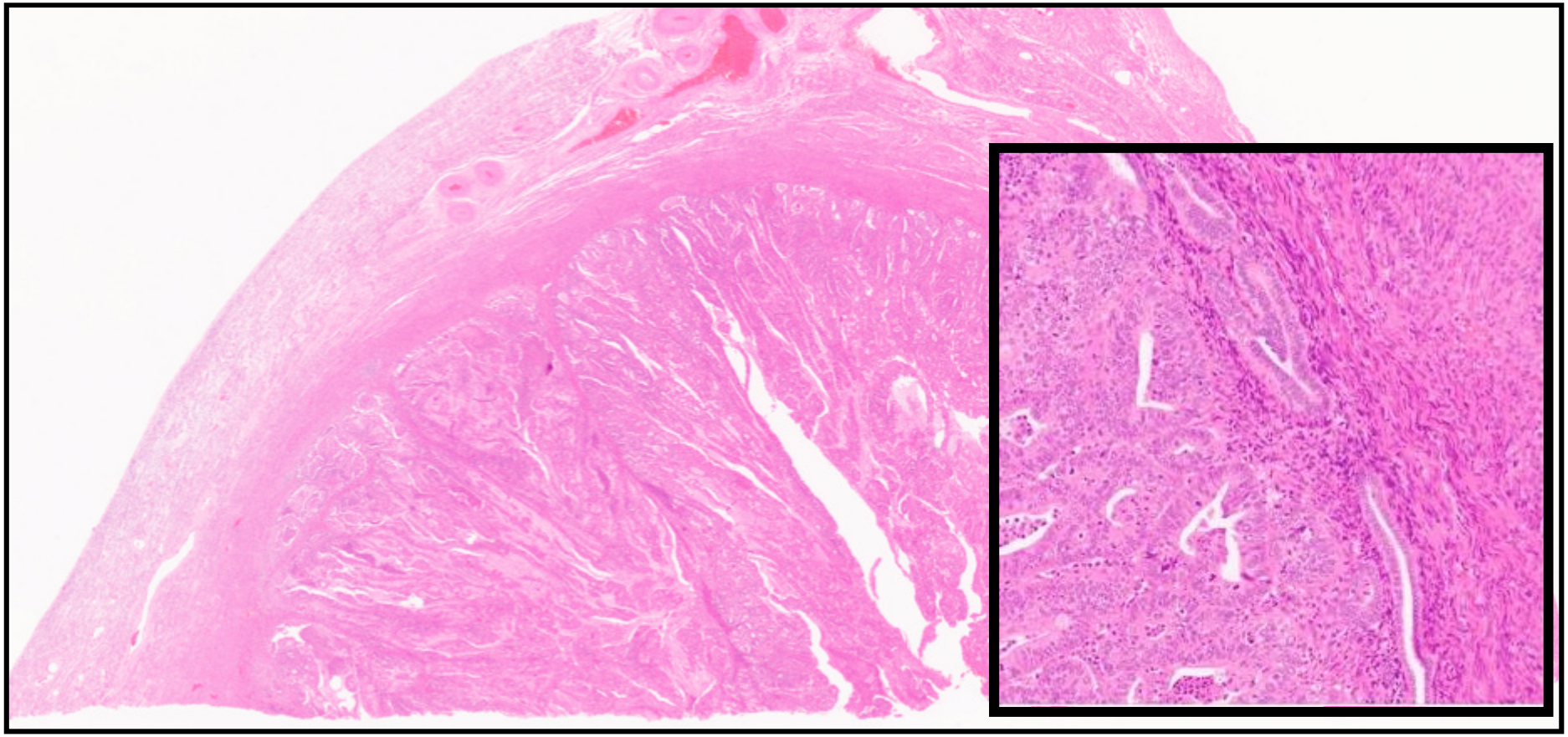

Tumour expanding irregular endomyometrial junction

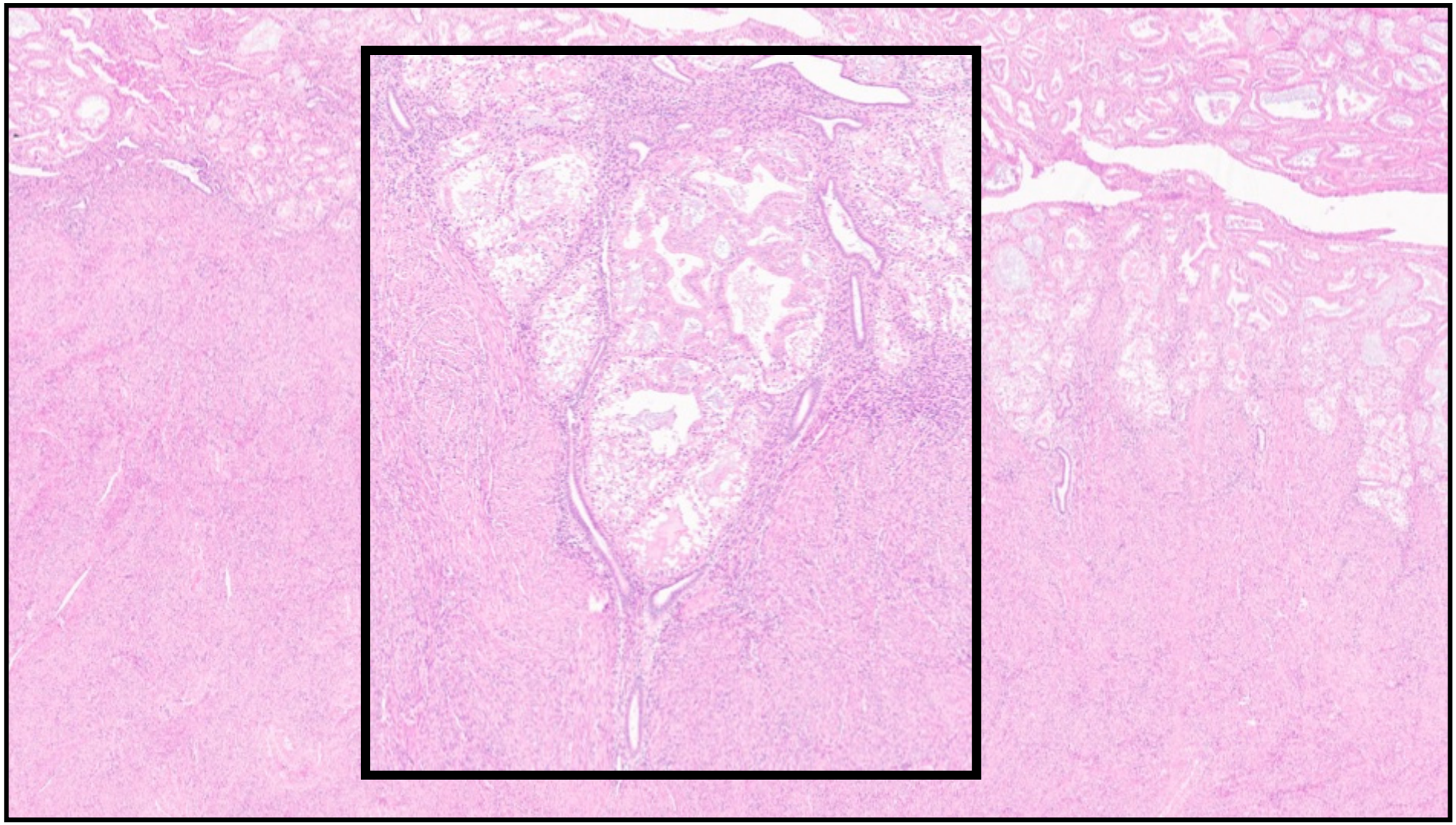

Outer myometrial invasion or not: Tumour involving adenomyosis

- Presence of benign glands/stroma
- Absence of desmoplasia

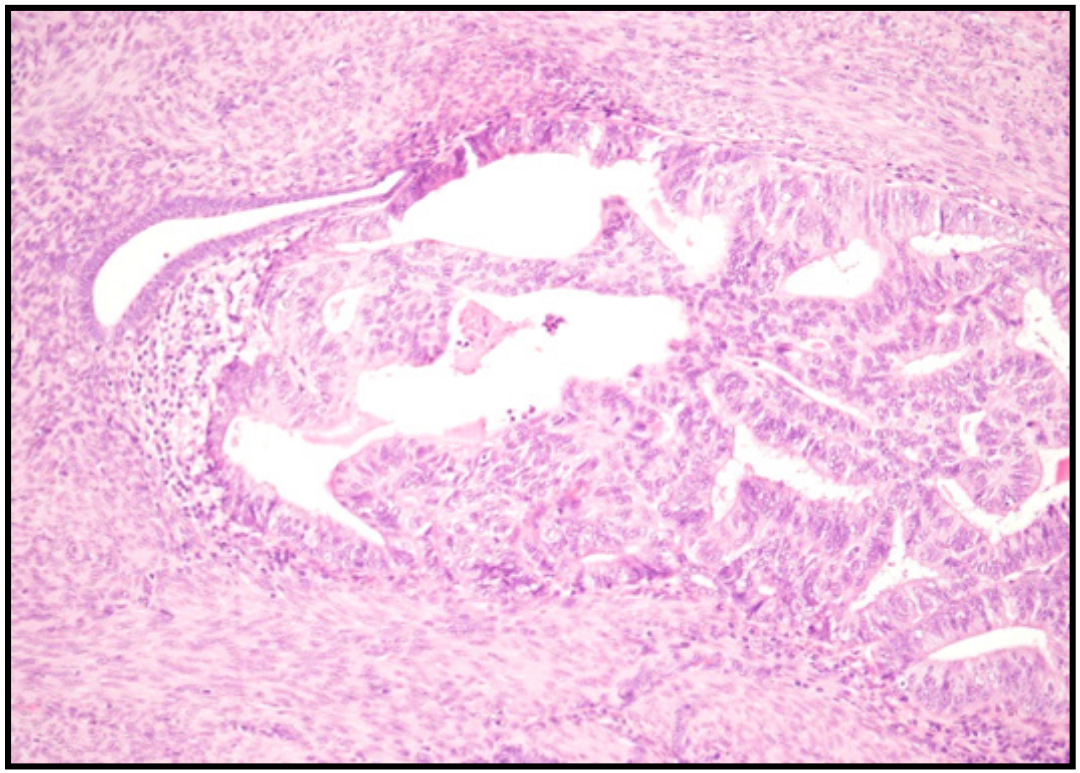

Outer myometrial invasion or not: Tumour involving adenomyosis

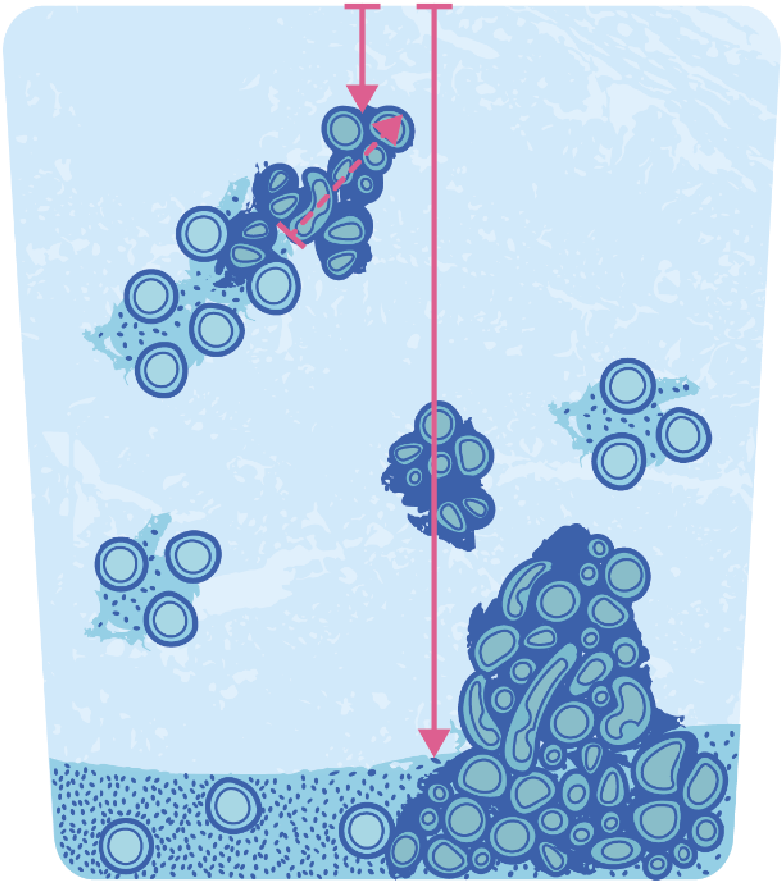

- Two views on measurement
- Associated with better prognosis
- Risk of understaging
- **Deepest myoinvasive point should be reported according to location in myometrium, regardless of whether or not it arises from adenomyosis.**
- **Accompanied by comment that the clinical significance is unknown, and that this may be an overestimate of true depth of invasion.**

Microcystic elongated and fragmented gland (MELF) invasion pattern

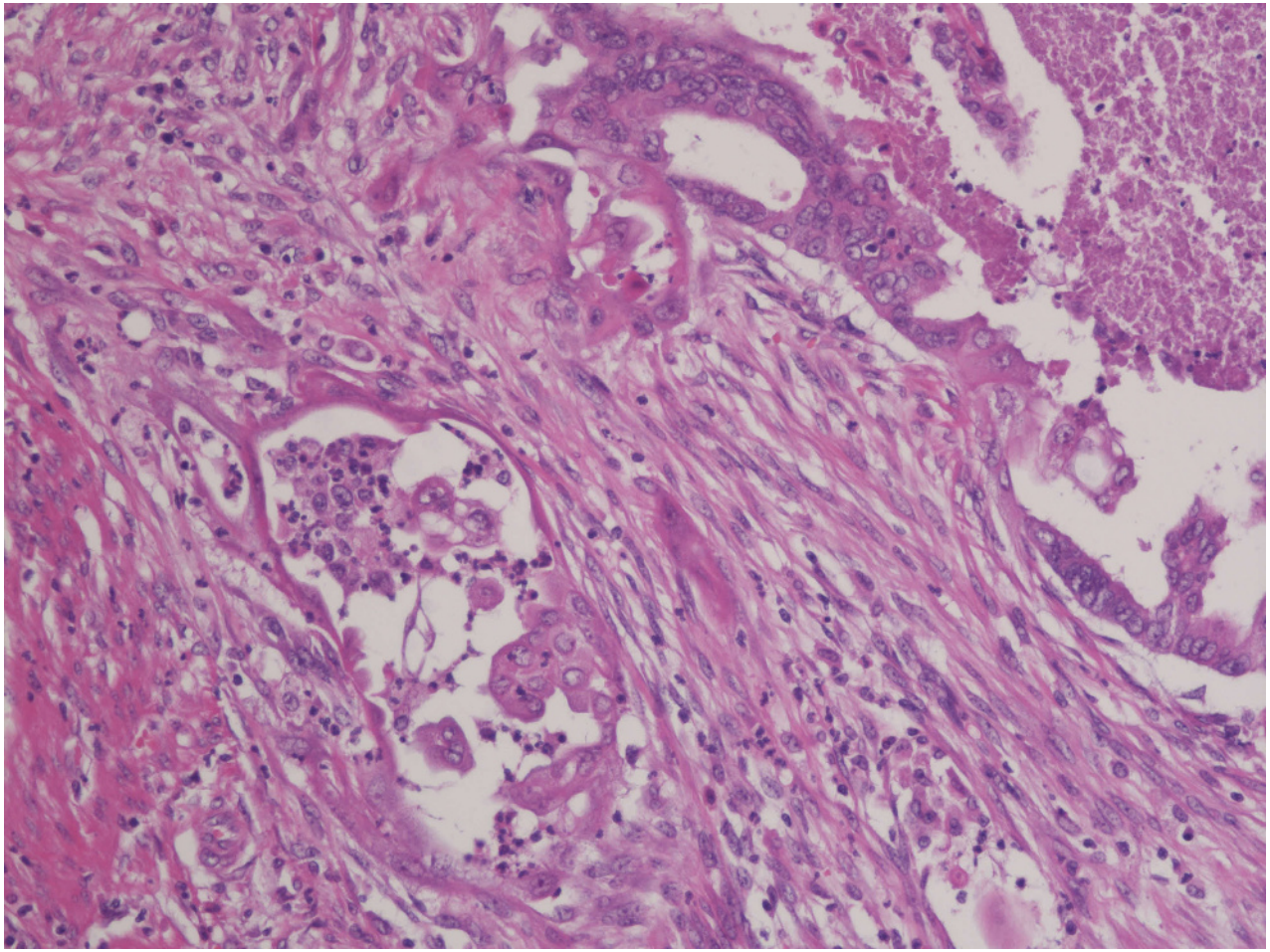

Microcystic elongated and fragmented gland (MELF) invasion pattern

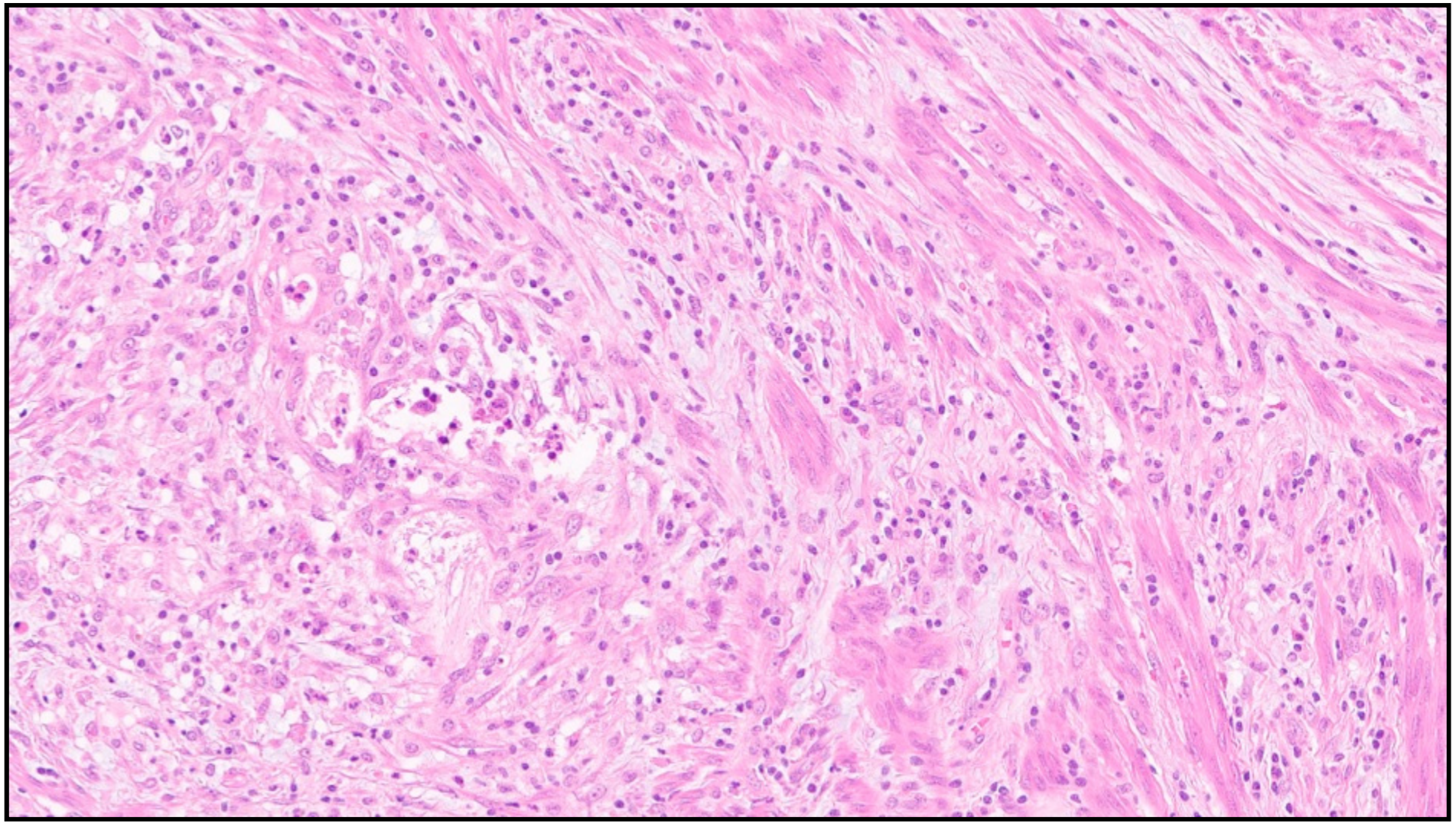

MELF: Small clusters or single cells in fibromyxoid stroma

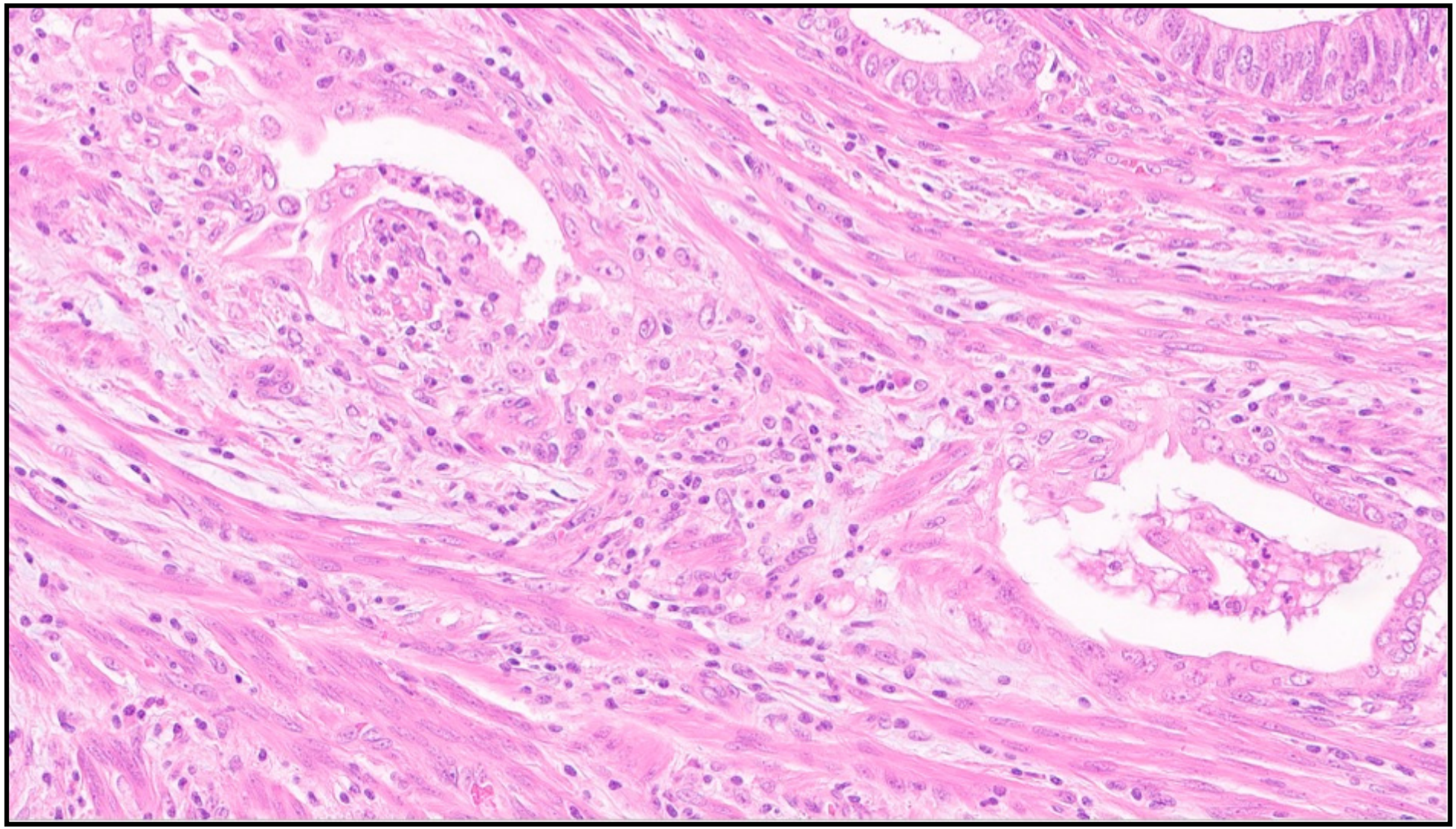

MELF: Acute inflammation in lumina, clusters of lymphoid cells

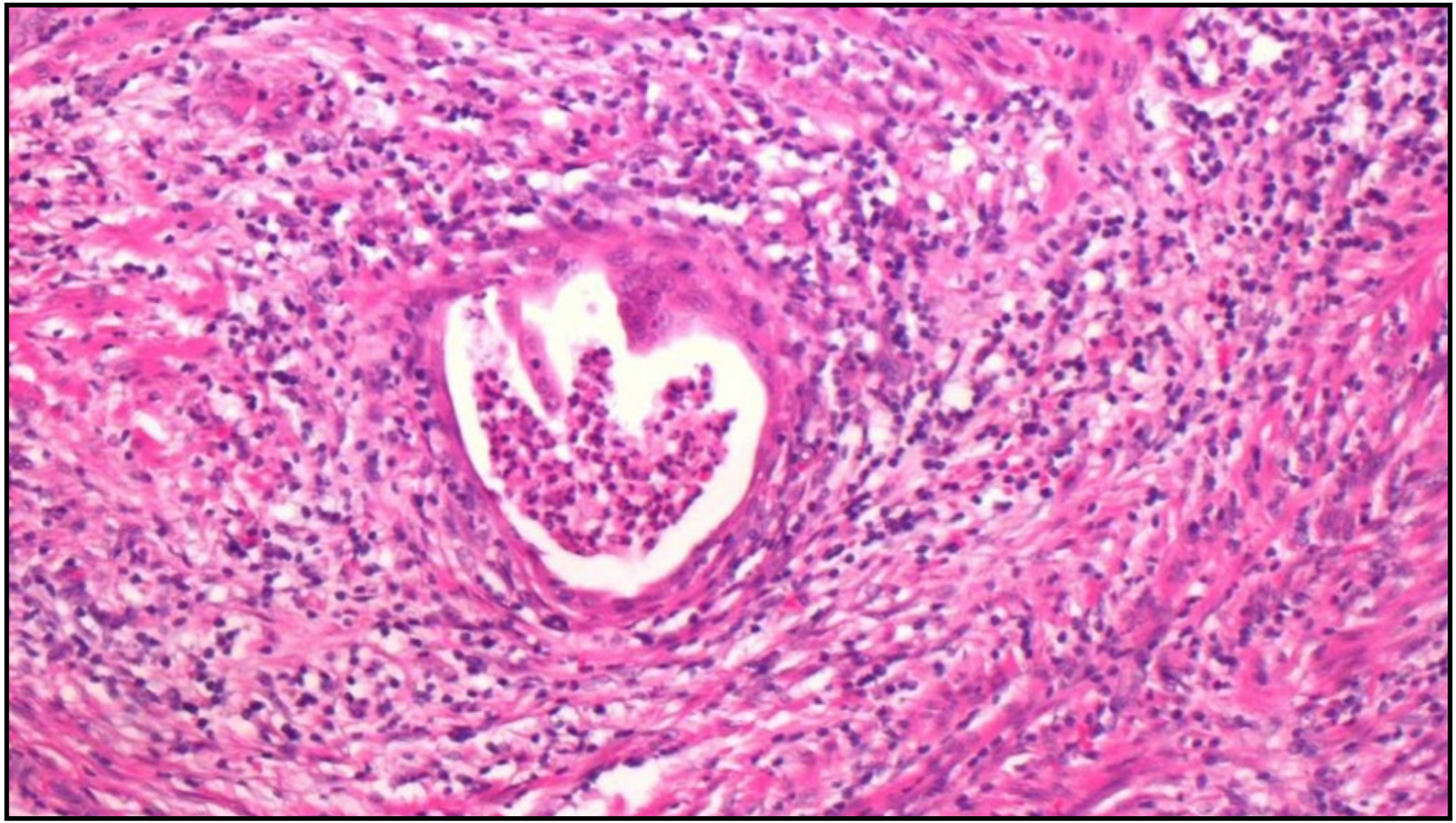

MELF: discontinuous and deep

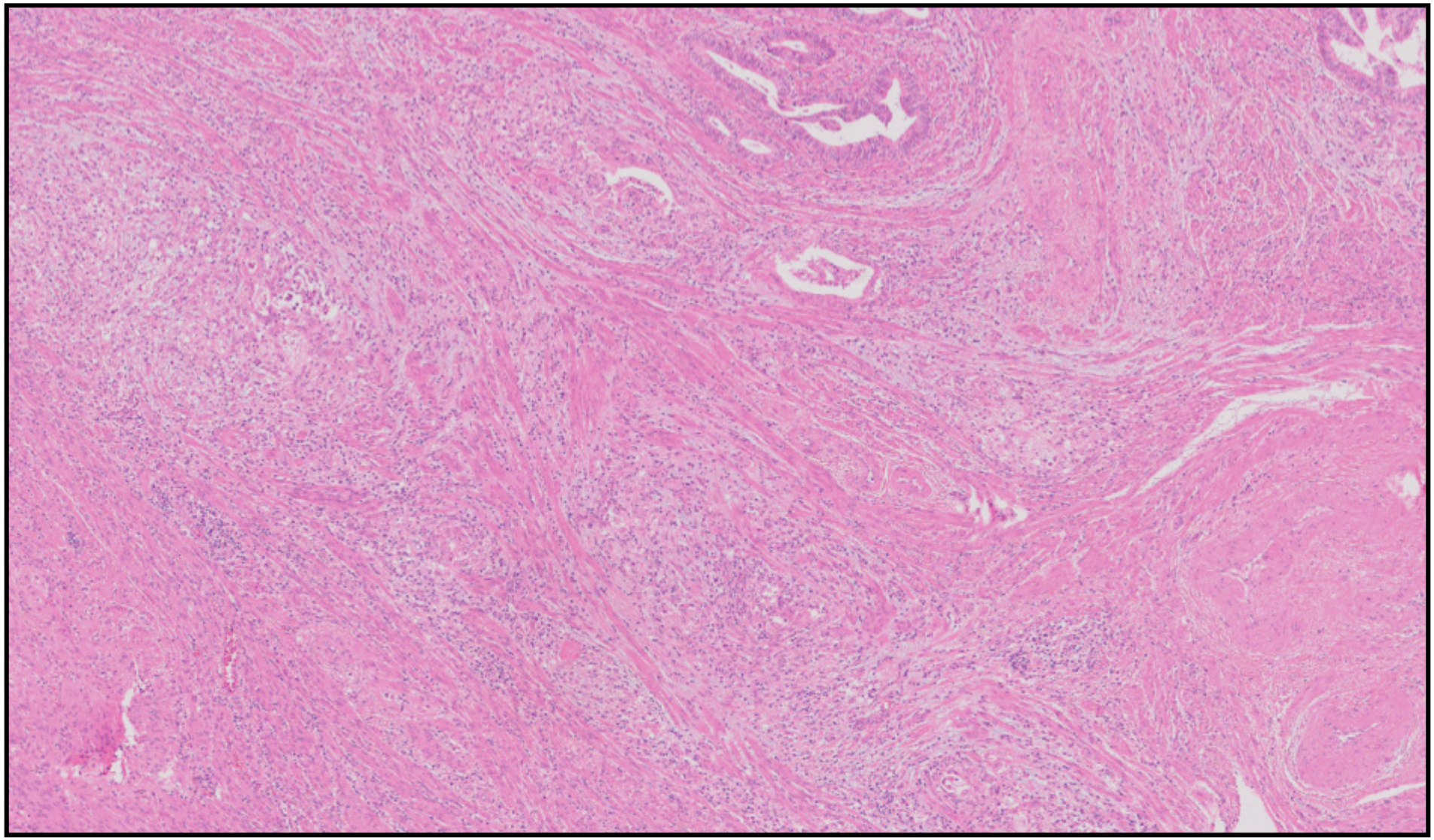

MELF: LVSI

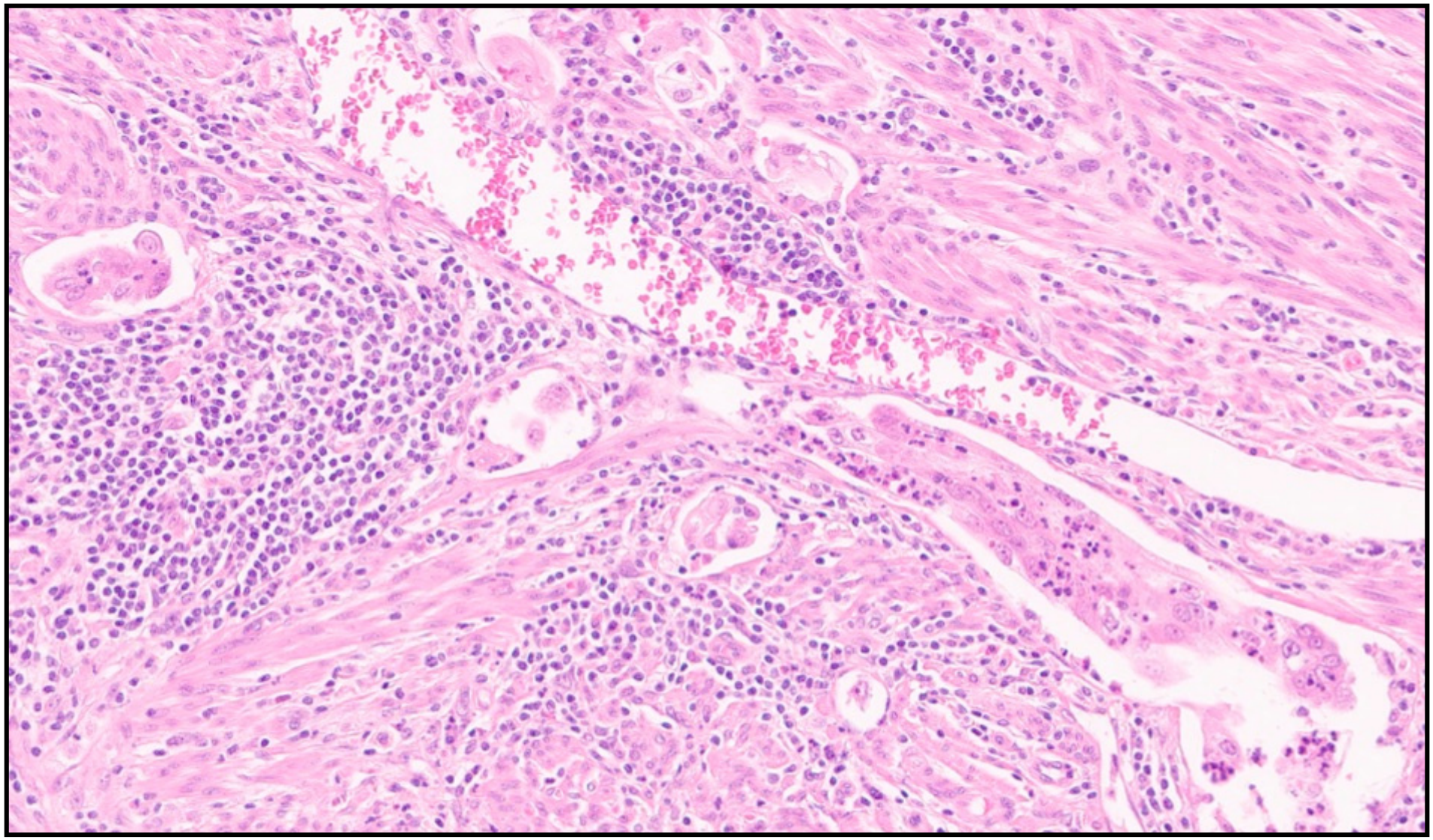

MELF: Lymph node involvement

- **Single histiocyte like cells**
  - Deceptive pattern

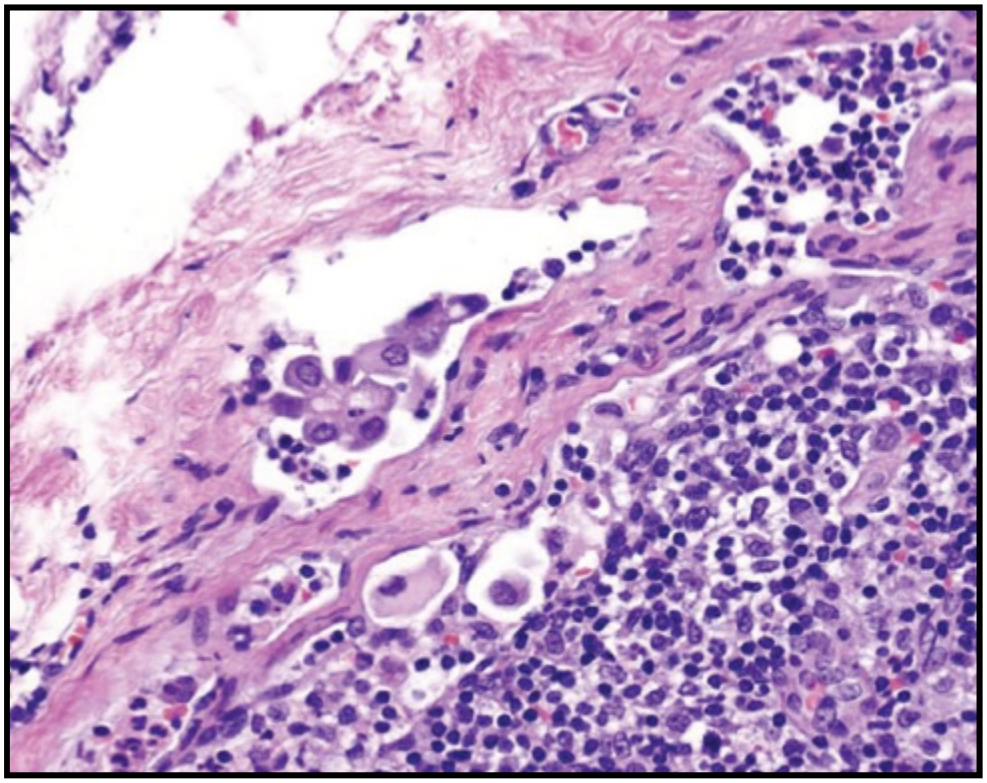

MELF significance

- **Not an independent prognostic factor**
- **Usually with low-grade endometrioid**

MELF significance

- Subtle pattern often seen focally at the invasive front in low-grade EC
- MAY BE MISSED: due to the relative pallor and different appearance of the tumor at these sites, resulting in underestimation of depth of invasion

- This pattern is significantly associated with LVSI, and when present a careful search should be performed to exclude as well as correctly identify LVSI, which is otherwise an uncommon finding in low-grade endometrioid EC.
- Typically glands with a markedly attenuated lining showing detached tumor cells within the lumen, findings that may be wrongly interpreted as LVSI
- May prompt histopathologic ultrastaging of resected lymph nodes for occult metastatic involvement within some institutions.

MELF invasion pattern issues

Fibromyxoid stroma alone ≠ invasion

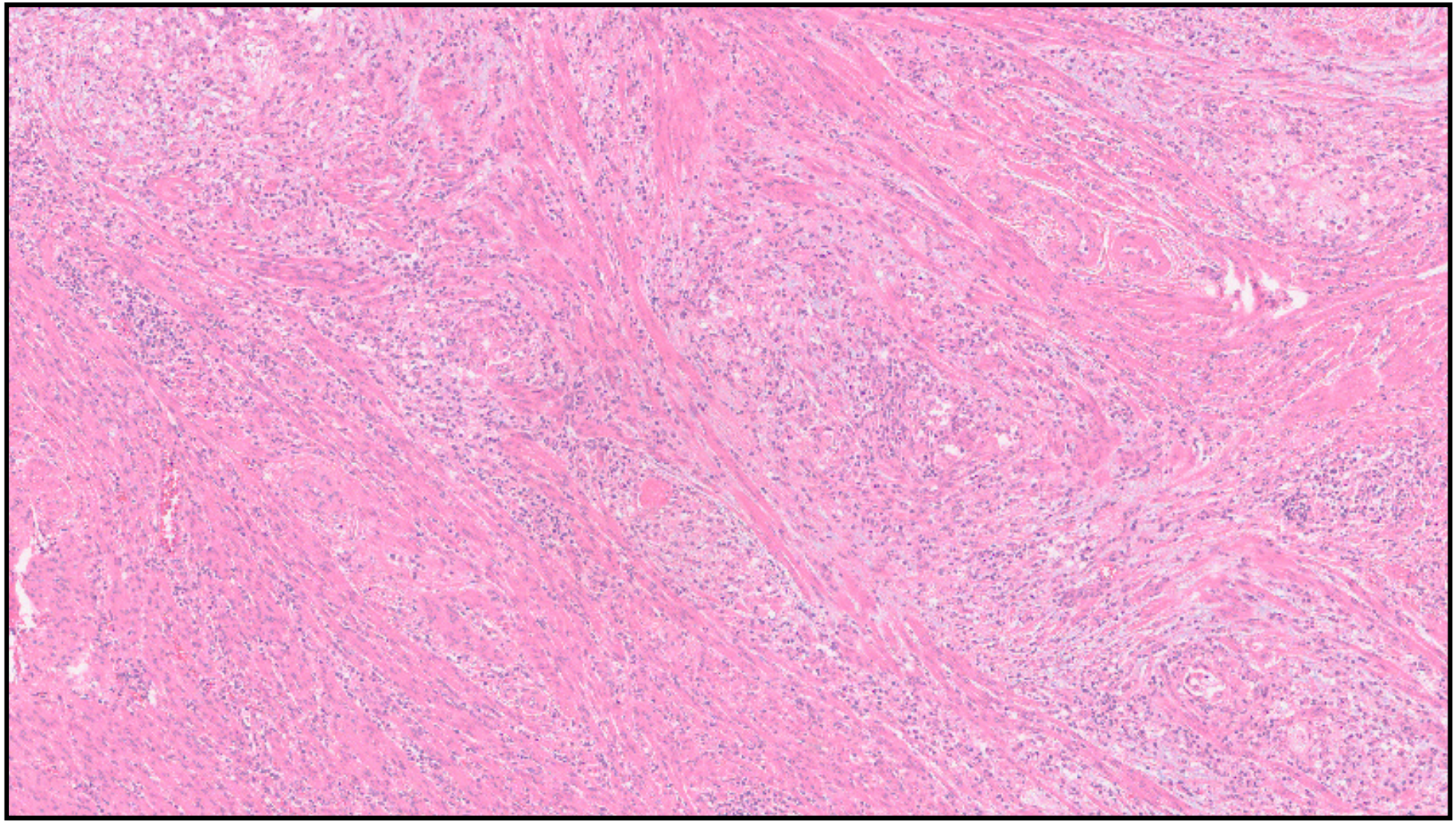

MELF invasion pattern issues

Fibromyxoid stroma alone ≠ invasion

- Need to identify tumour cells

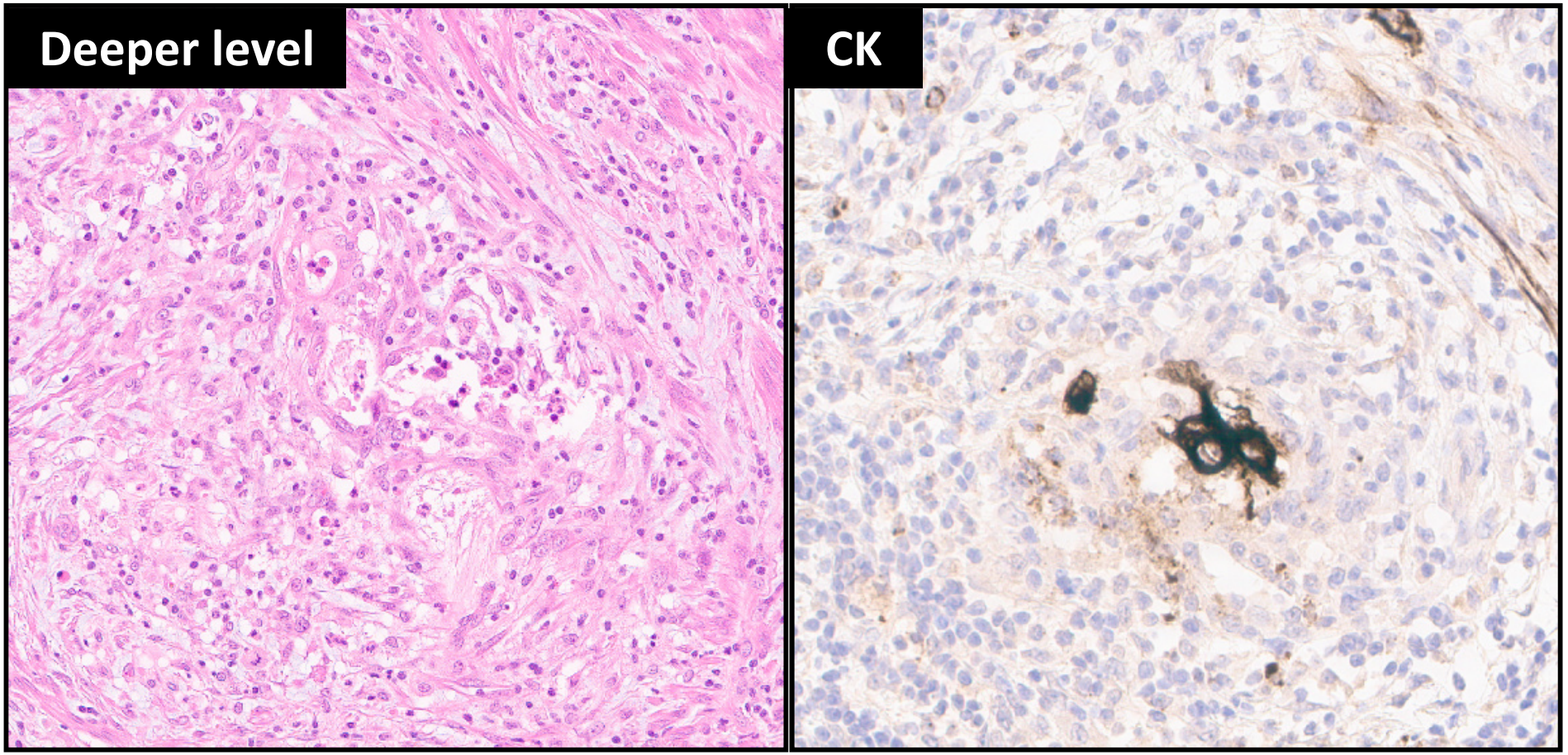

MELF invasion pattern issues

Mimics vascular invasion

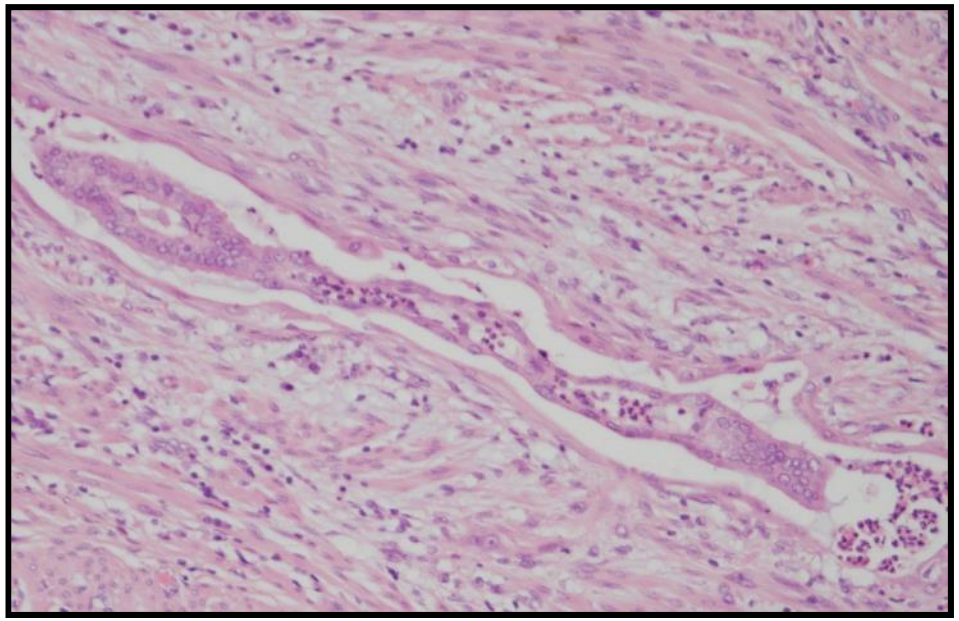

MELF invasion pattern issues

Mimics vascular invasion

- MELF spaces lined by cytokeratin positive atrophic epithelial cells

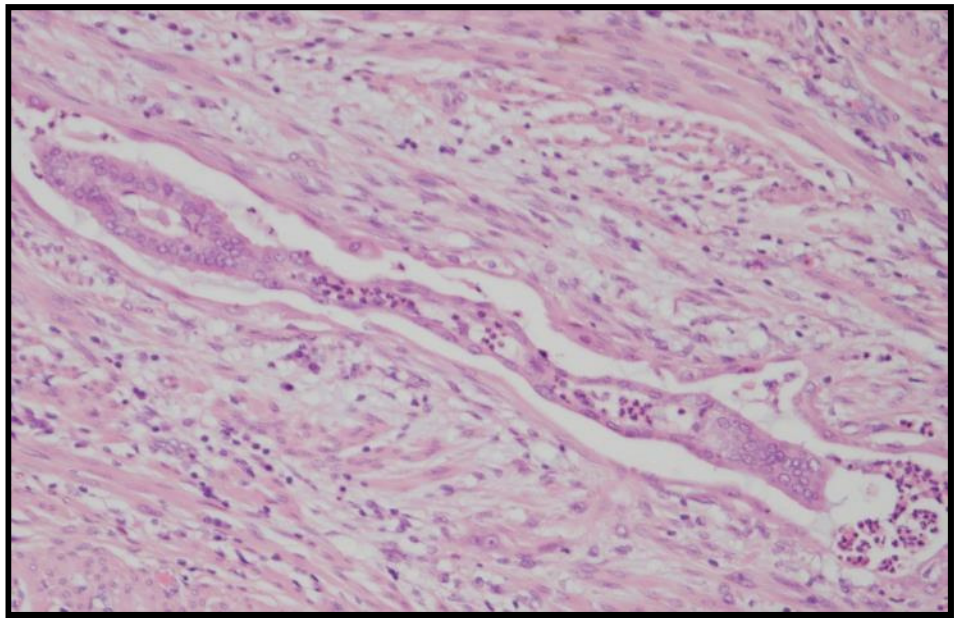

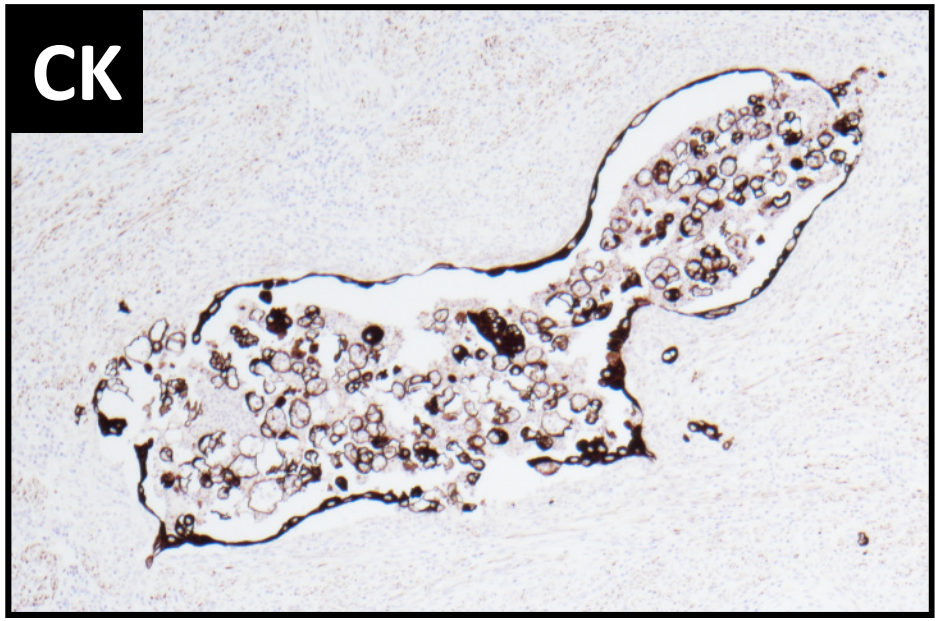

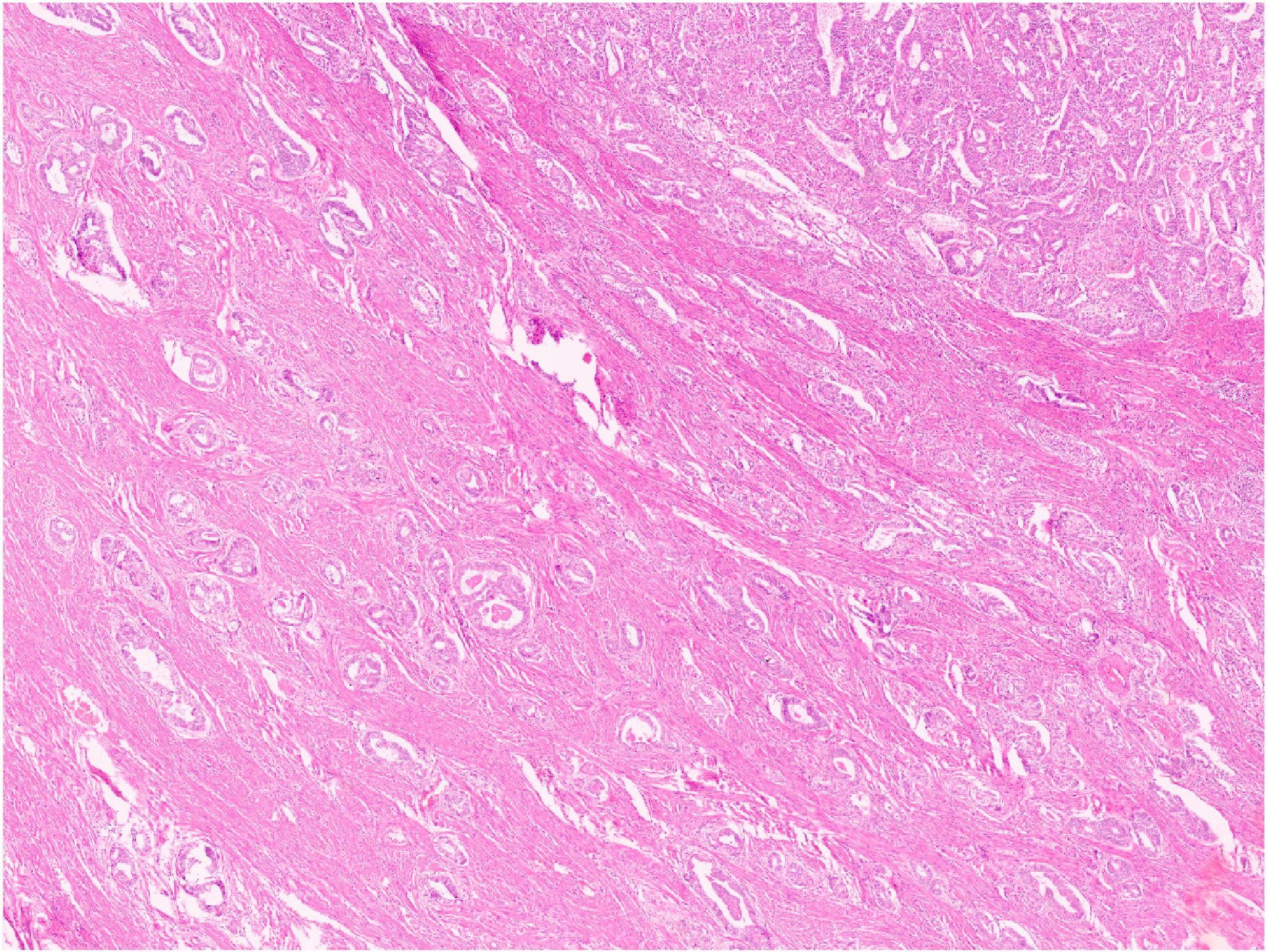

Myometrial invasion

Adenoma malignum like pattern

- Scattered single naked glands without desmoplasia
- Haphazard chaotic distribution of glands

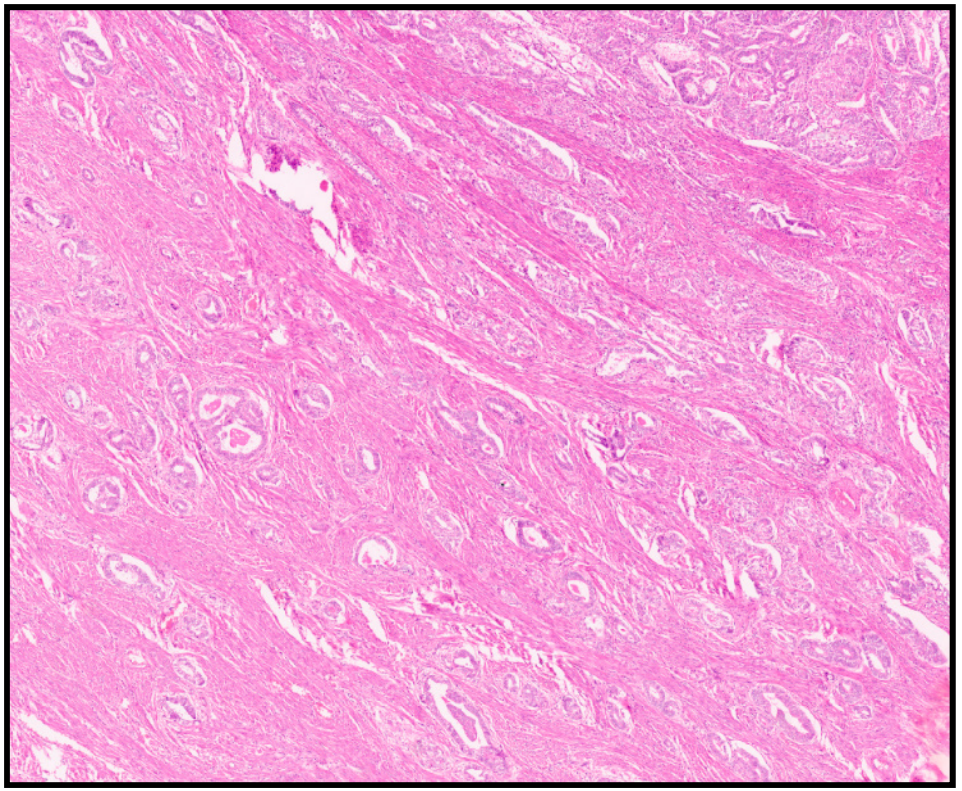

Myoinvasion: Other issues

- **In exophytic tumors, measure depth of myometrial invasion, not tumor thickness, should be measured by identifying the adjacent endomyometrial junction and by correlating with the macroscopic appearance.**
- **Tumors involving polyps:**
  - **Measurement of invasion is performed only if the tumor invades the underlying myometrium and measurement should be performed from the adjacent endometrial-myometrial interface.**
  - **Invasion into polyp stroma can be described, but depth should not be measured.**
- **CARE when measuring tumour depth in cornua/isthmus; i.e. as "none or less than half" OR "half or more" of myometrial thickness *at that location.***
- **When EC invades a leiomyoma, the thickness of the myometrial wall at this site should be measured to include the leiomyoma and this distance should be used in calculating the depth of invasion.**

Extent of myometrial invasion

Less common scenarios

- **Tumour invading leiomyoma**
  - Include leiomyoma in wall thickness

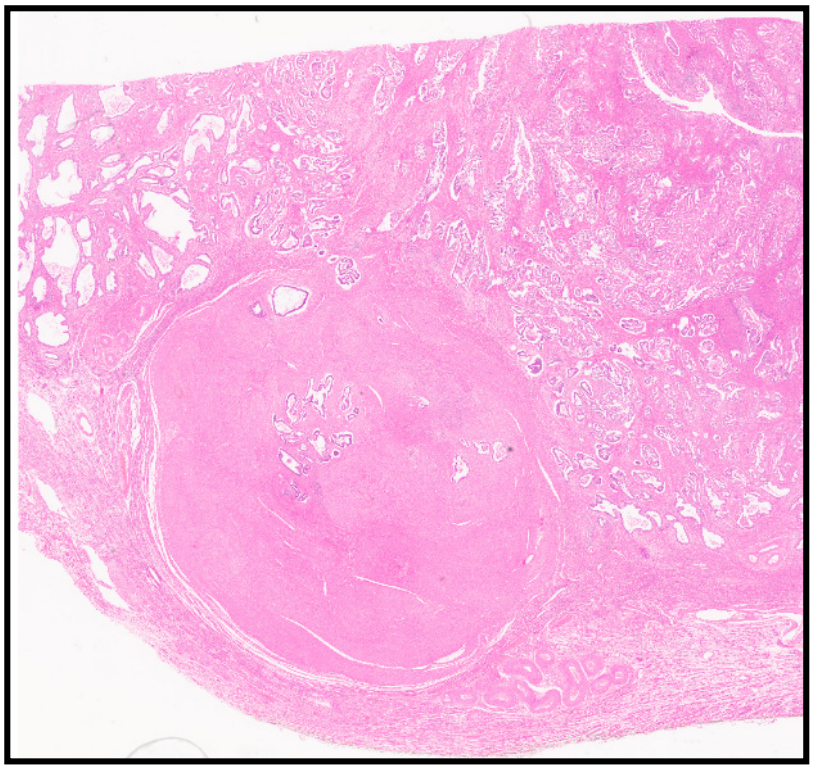

Extent of myometrial invasion

Less common scenarios

- **Polypoid tumour**
  - Do not include thickness of intraluminal component

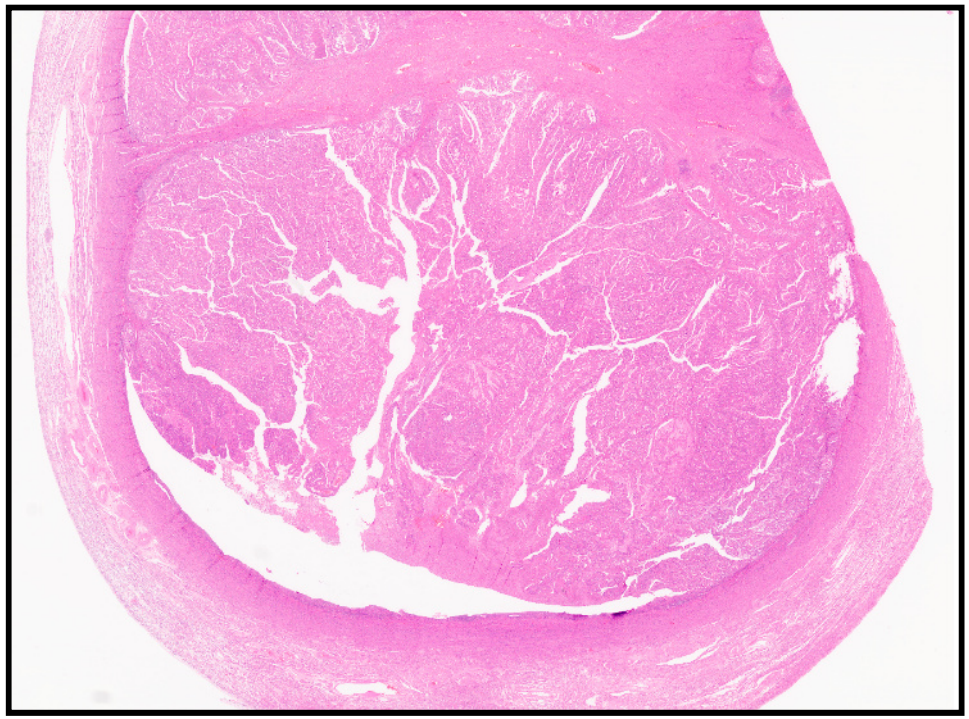

Assessing % myometrium involvement

Using distance from serosa

- Easier to determine
- More reproducible
- Recommended (RCPath 2017)

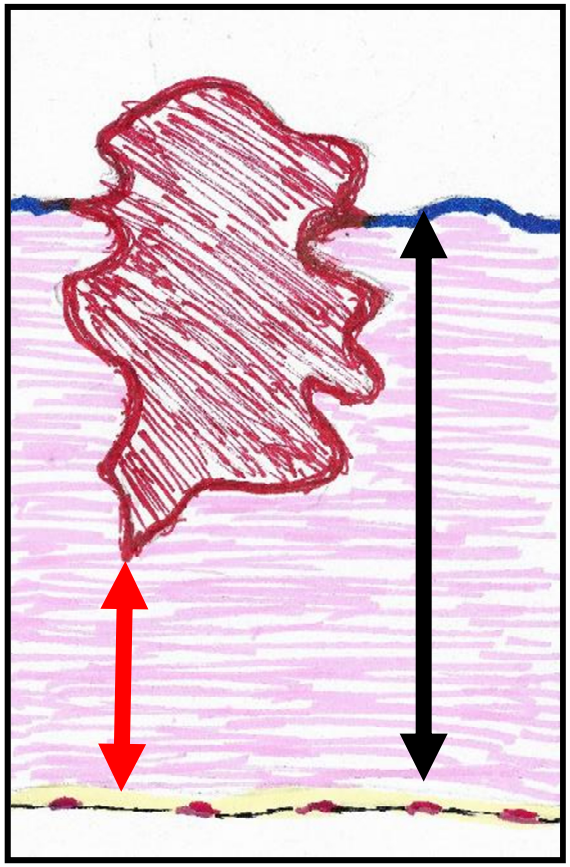

Assessing depth of invasion
An alternative approach

- Arcuate venous plexus (AVP) usually in outer half/third of myometrium

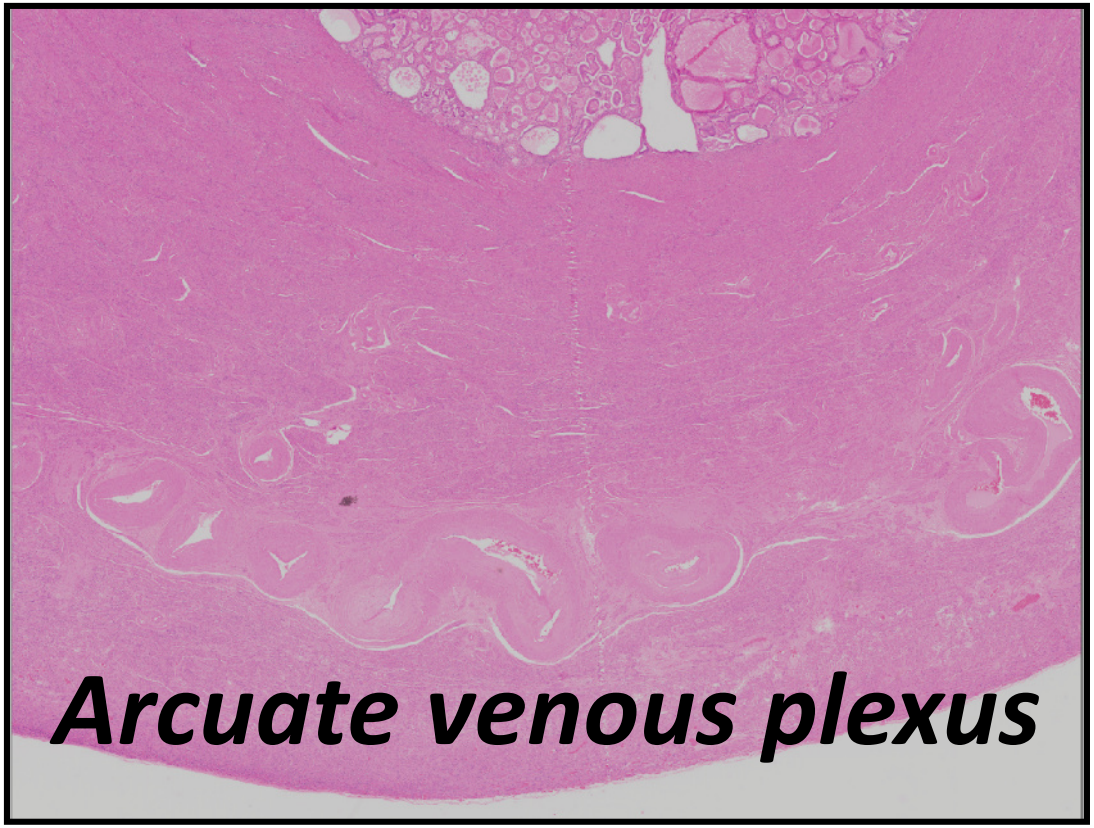

Tumour well into AVP

Outer half invasion (FIGO 1B)

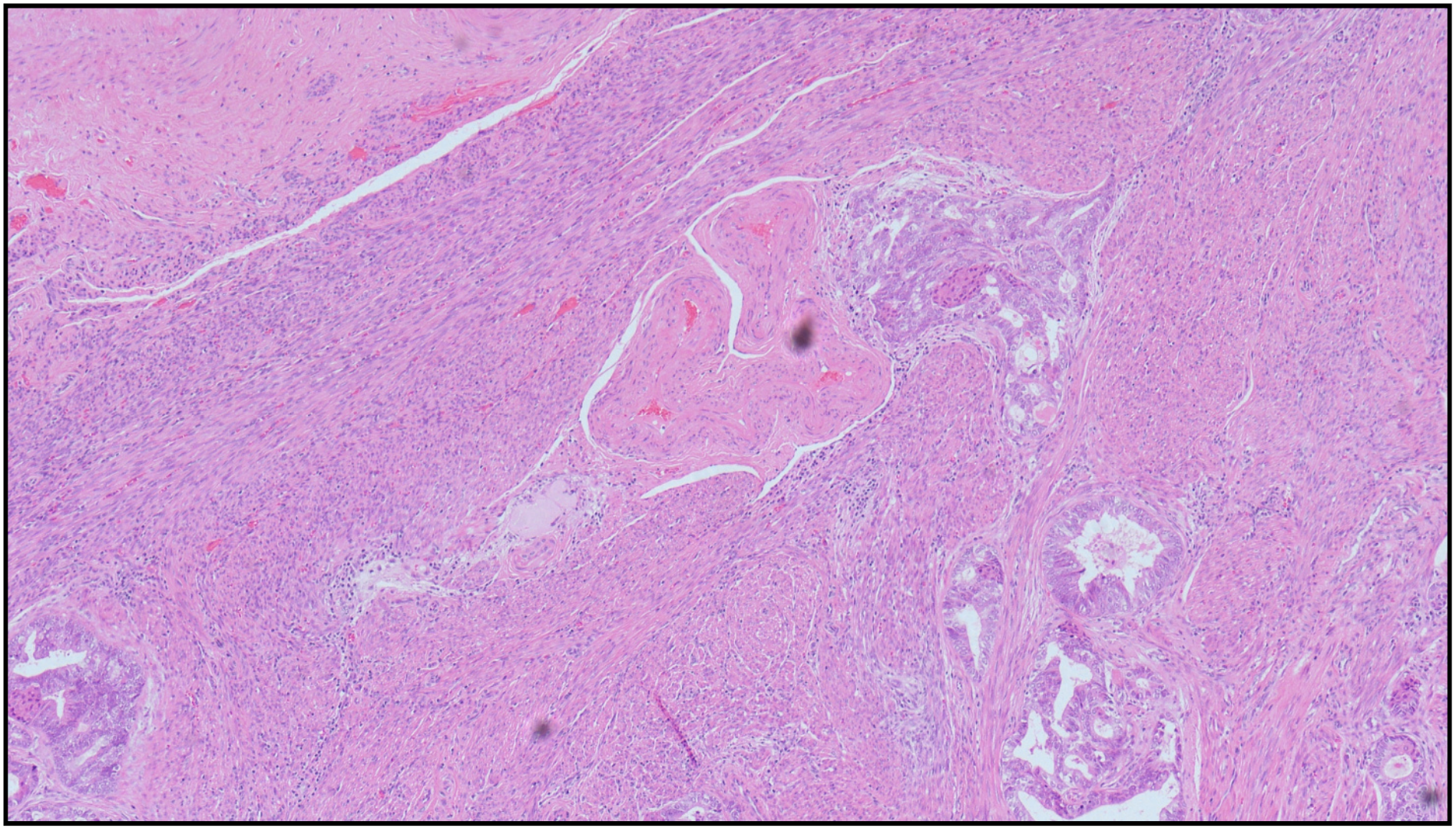

Distance of tumour free myometrium from serosa

Mandatory data item in FIGO 2018

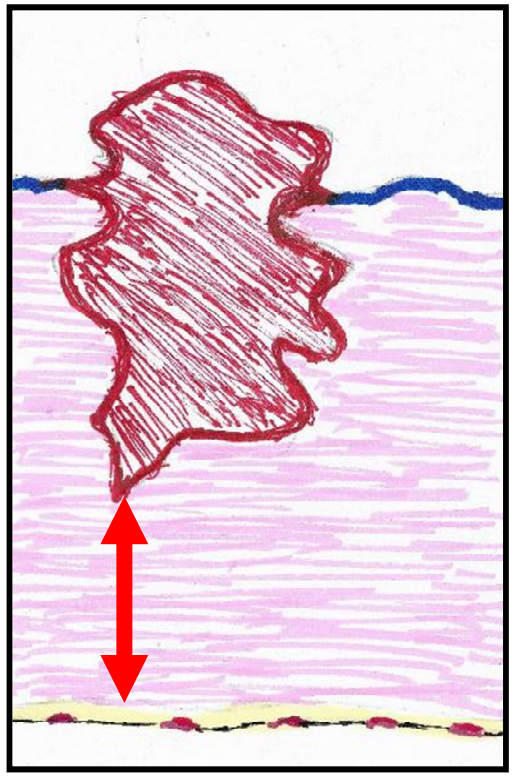

Cervical stromal invasion

FIGO stage II

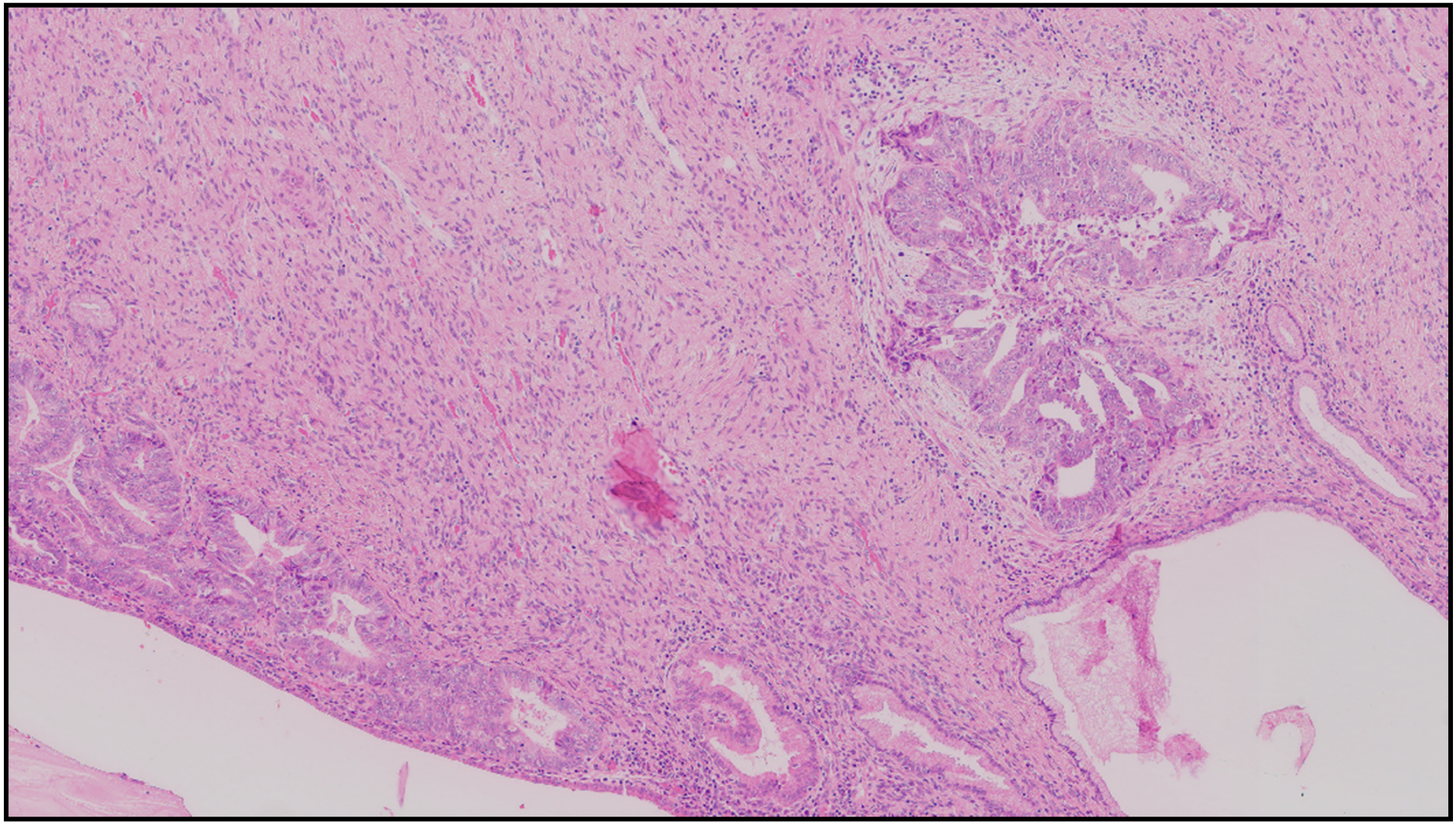

LUS vs upper endocx

- No anatomical demarcation

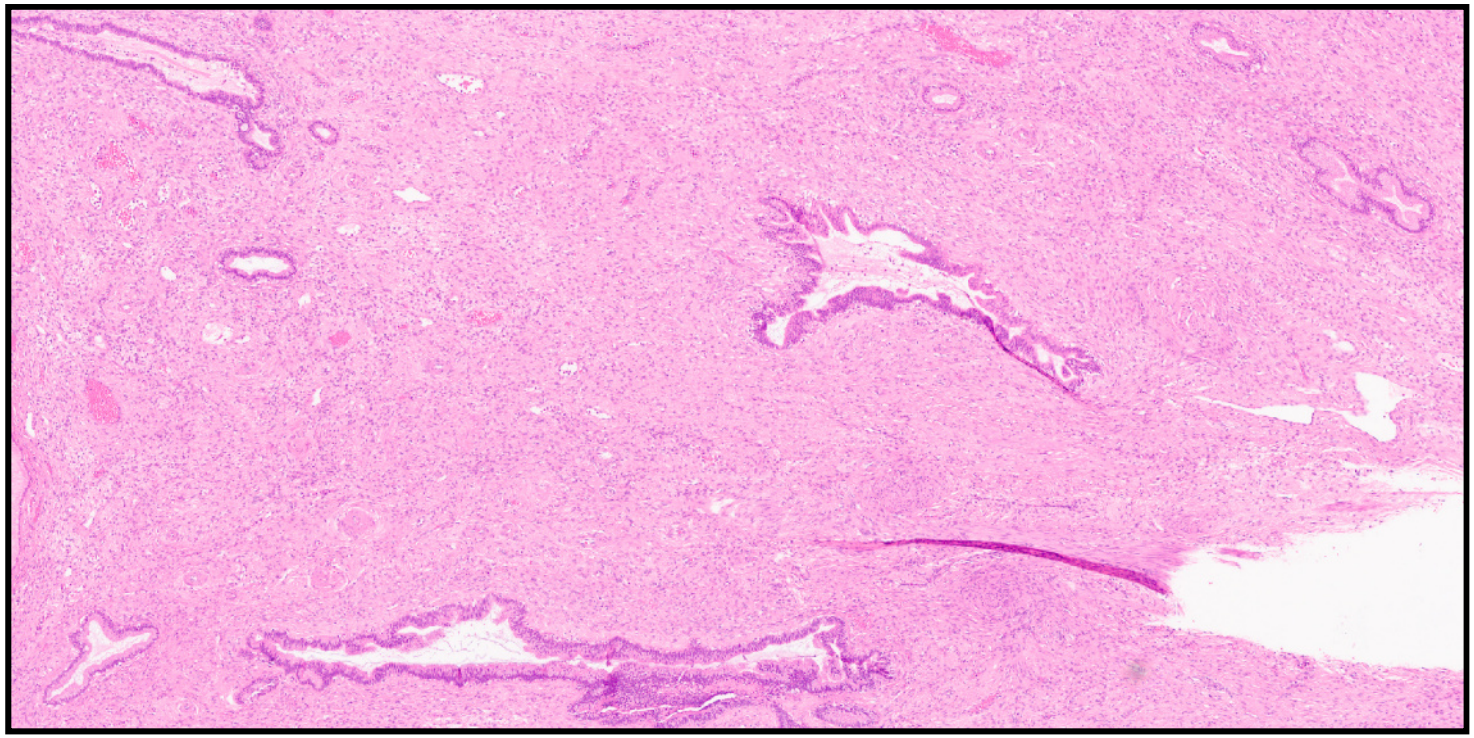

LUS vs upper endocx

- No anatomical demarcation
- LUS and endocervical glands and stroma co-mingle at the junction

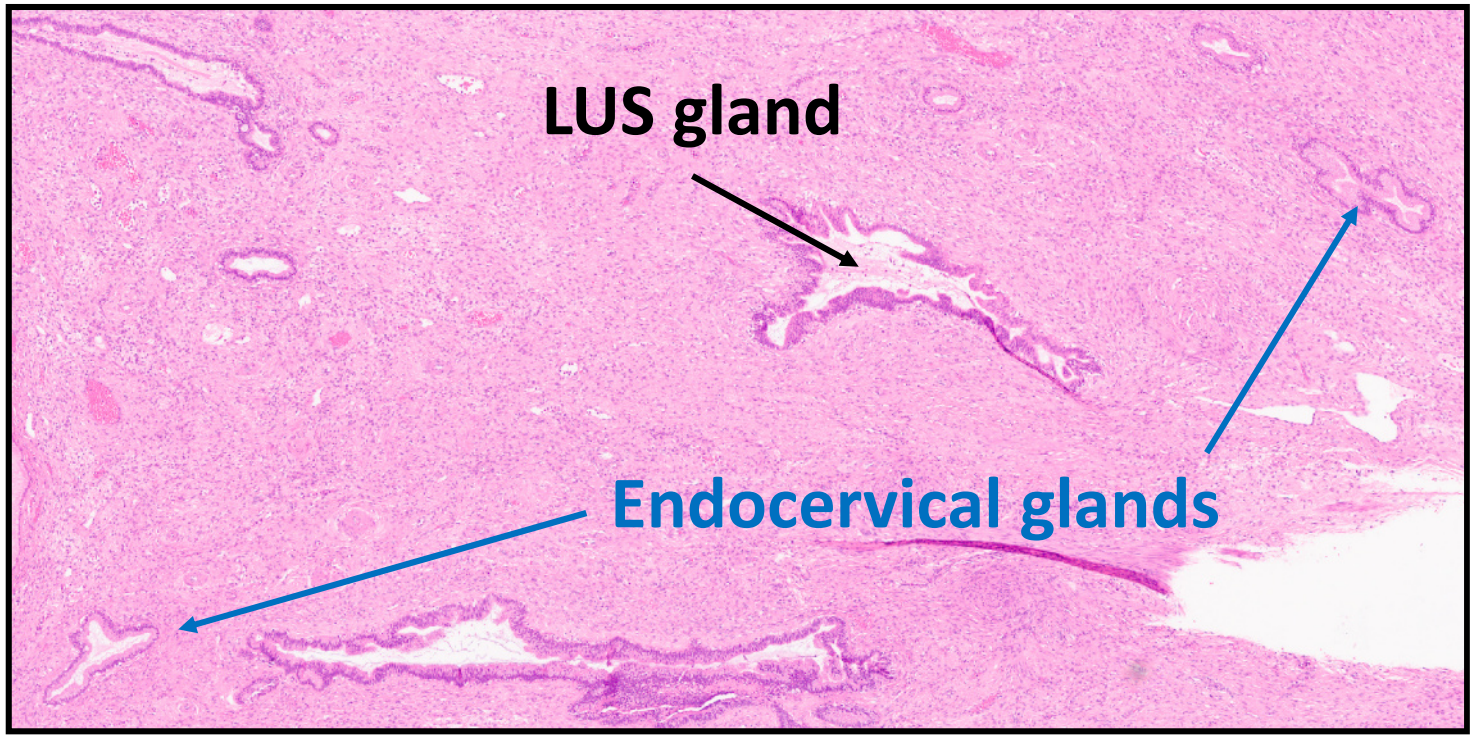

LUS vs upper endocx

- **ISGyP definition of cervical involvement**
  - Invasive tumour at level of uppermost mucinous gland = FIGO stage II

Cervical stromal invasion: Issues

- **Occasionally difficult to assess stromal invasion**

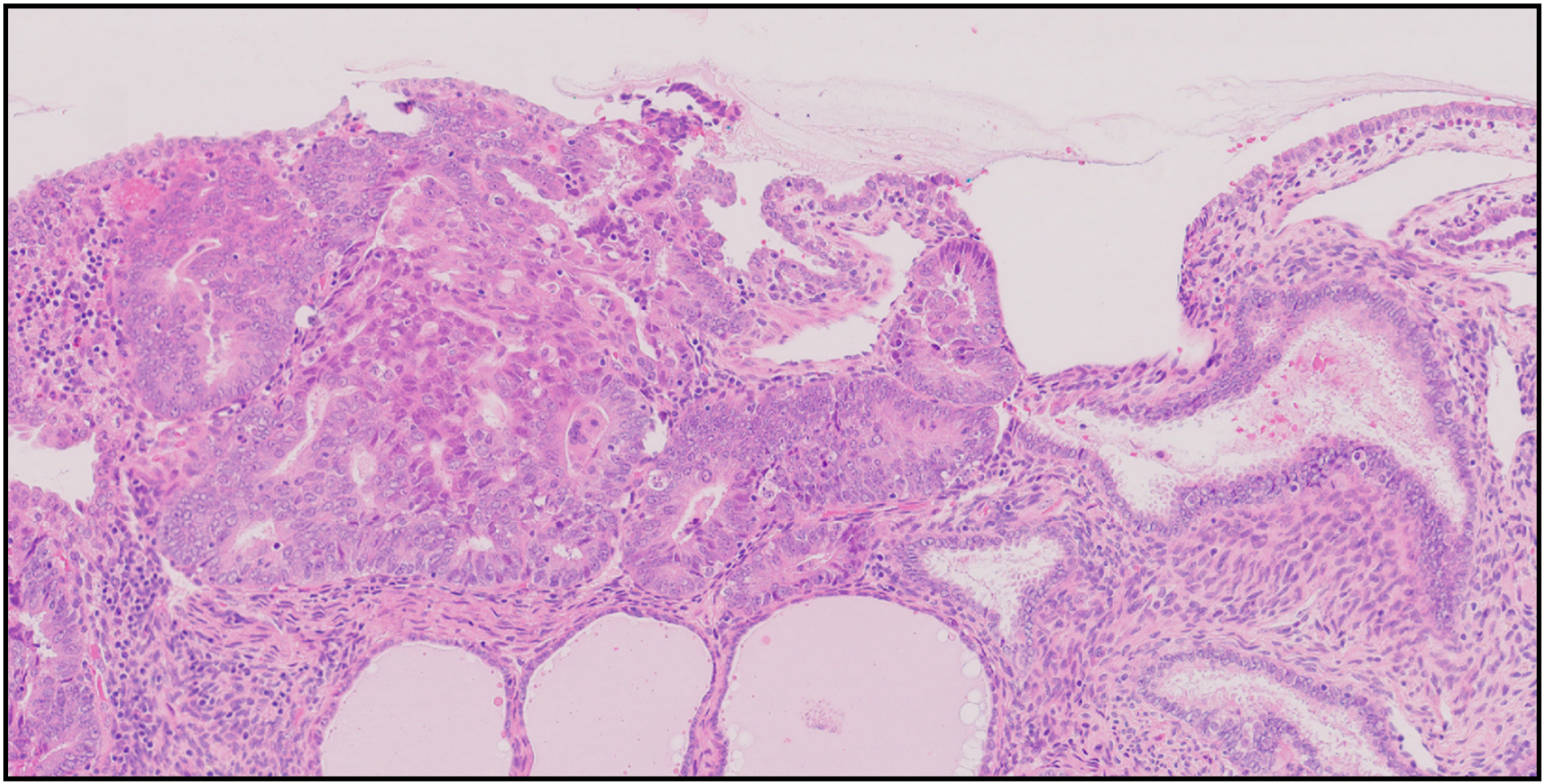

Cervical stromal invasion: Issues

- **Occasionally difficult to assess stromal invasion**
  - Confluent growth pattern = stromal invasion
  - Low power examination comparing with normal architecture of adjacent glands

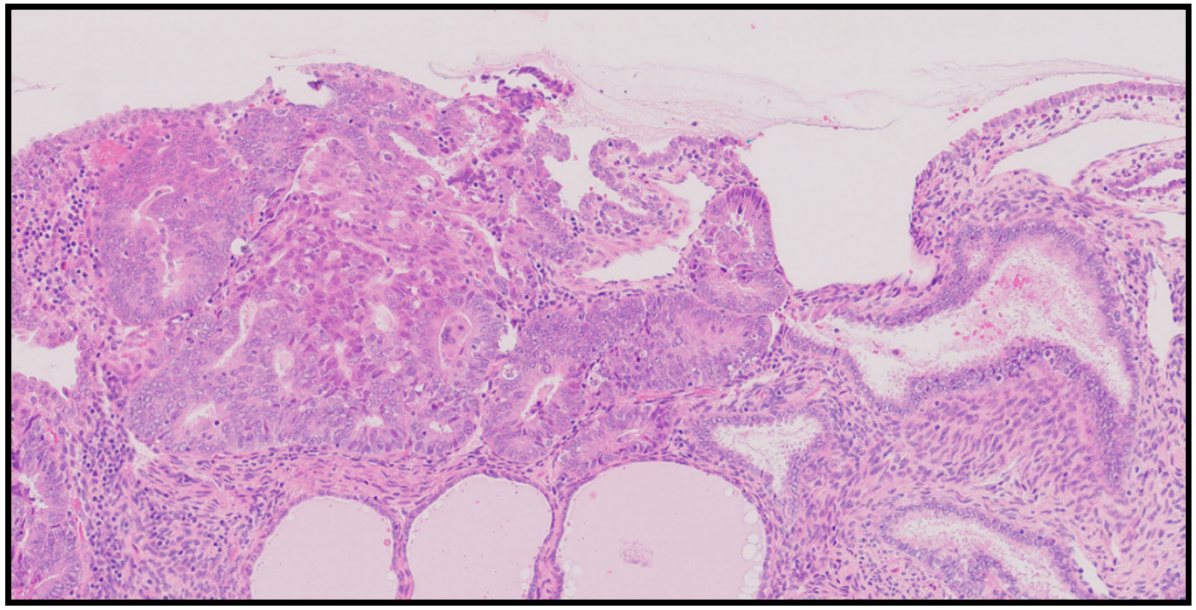

Cervical stromal invasion: Issues

- **Burrowing pattern of stromal invasion**
  - Mimics mesonephric remnants/hyperplasia
    - IHC (ER) may be of help



Cervical involvement

Benign mimics

Reactive atypical endocervical papillary proliferation

- **Usually secondary to prior biopsy/curettage**
  - Granulation tissue, micropapillation
  - Hobnail/squamoid cells
  - Mild cytologic atypia

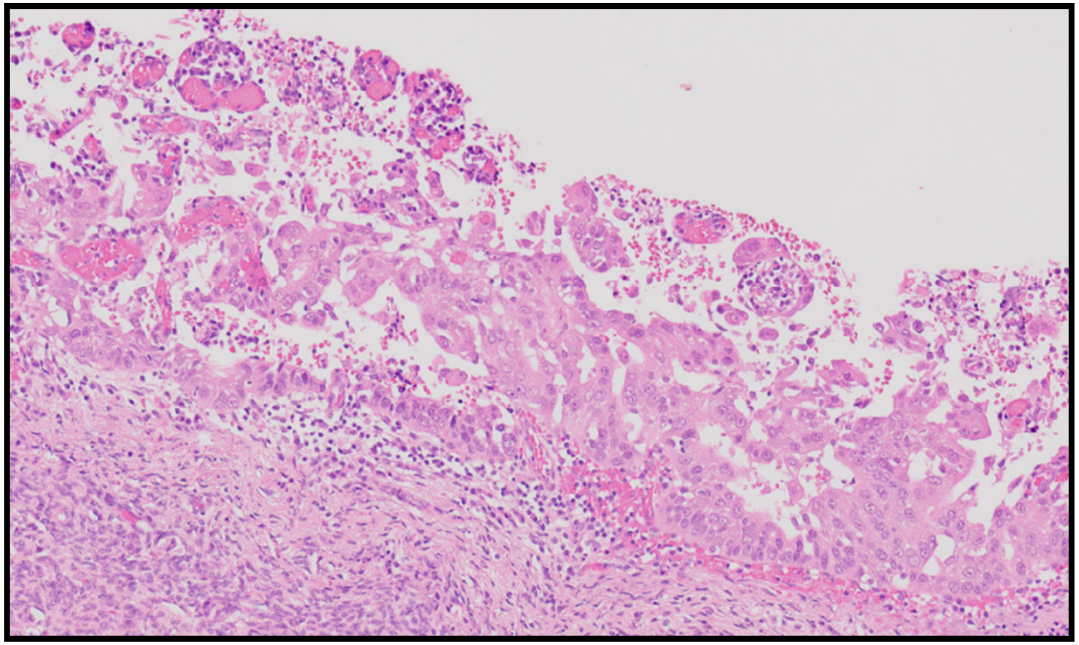

Contamination by endometrial CA

- May be due to prior curettage
- Tumour loosely attached to surface or embedded in granulation tissue

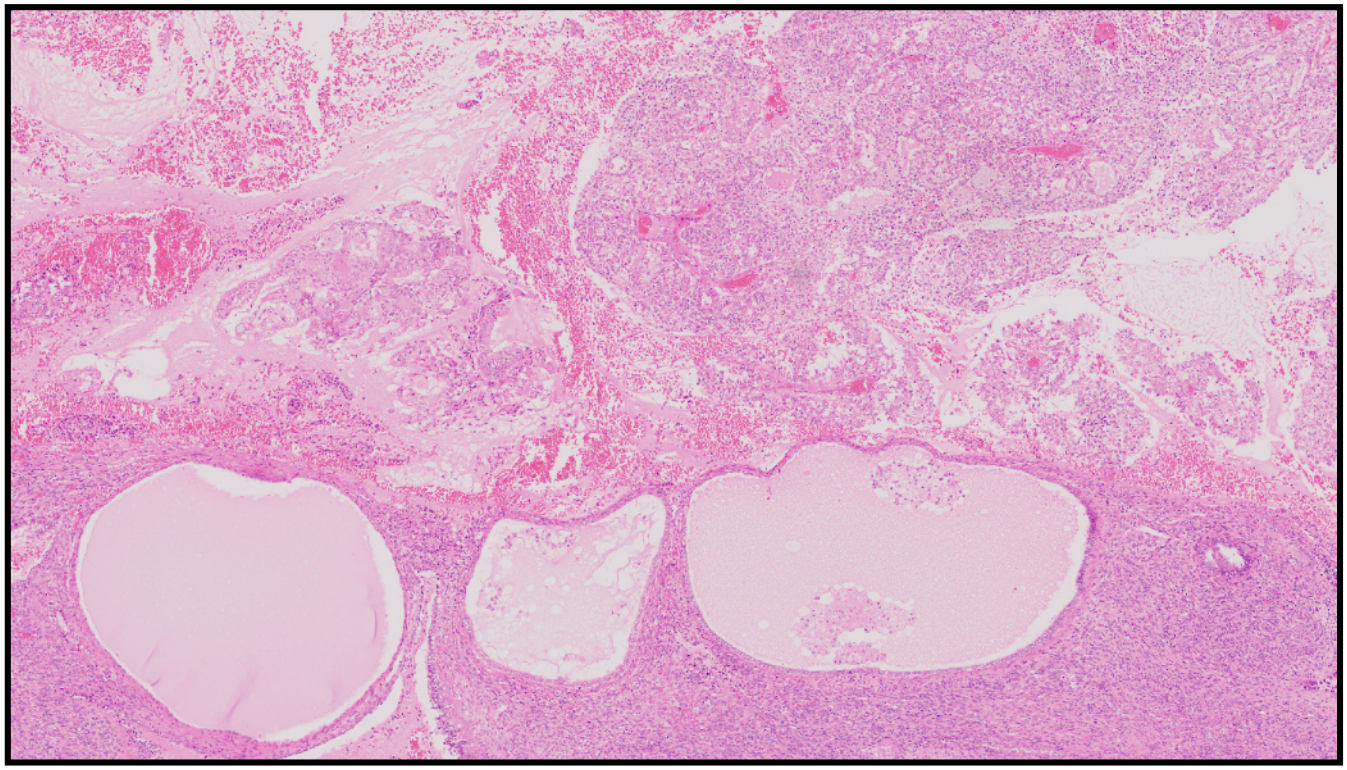

Deep endocervical tunnel clusters

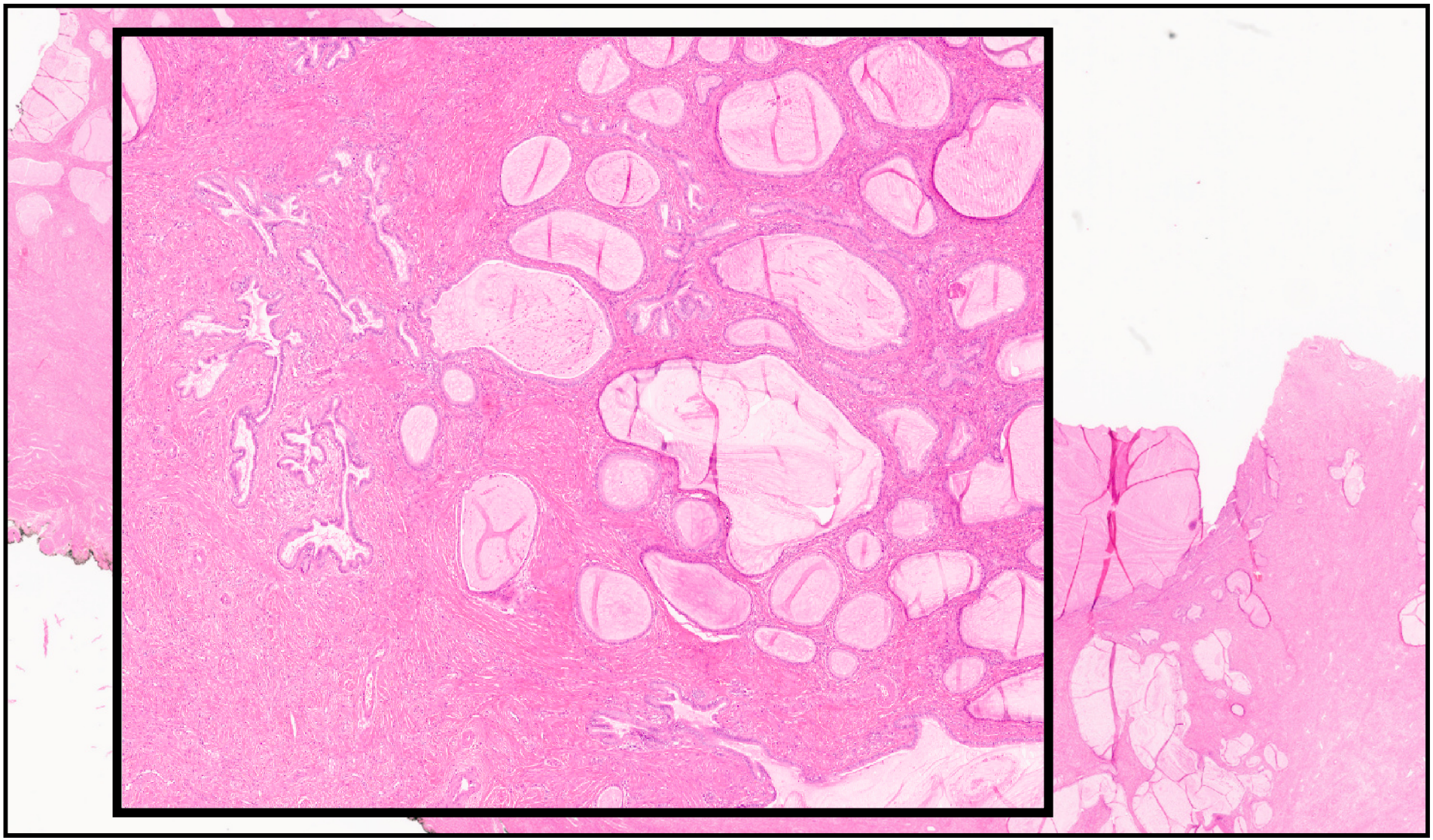

Tubo-endometrioid metaplasia

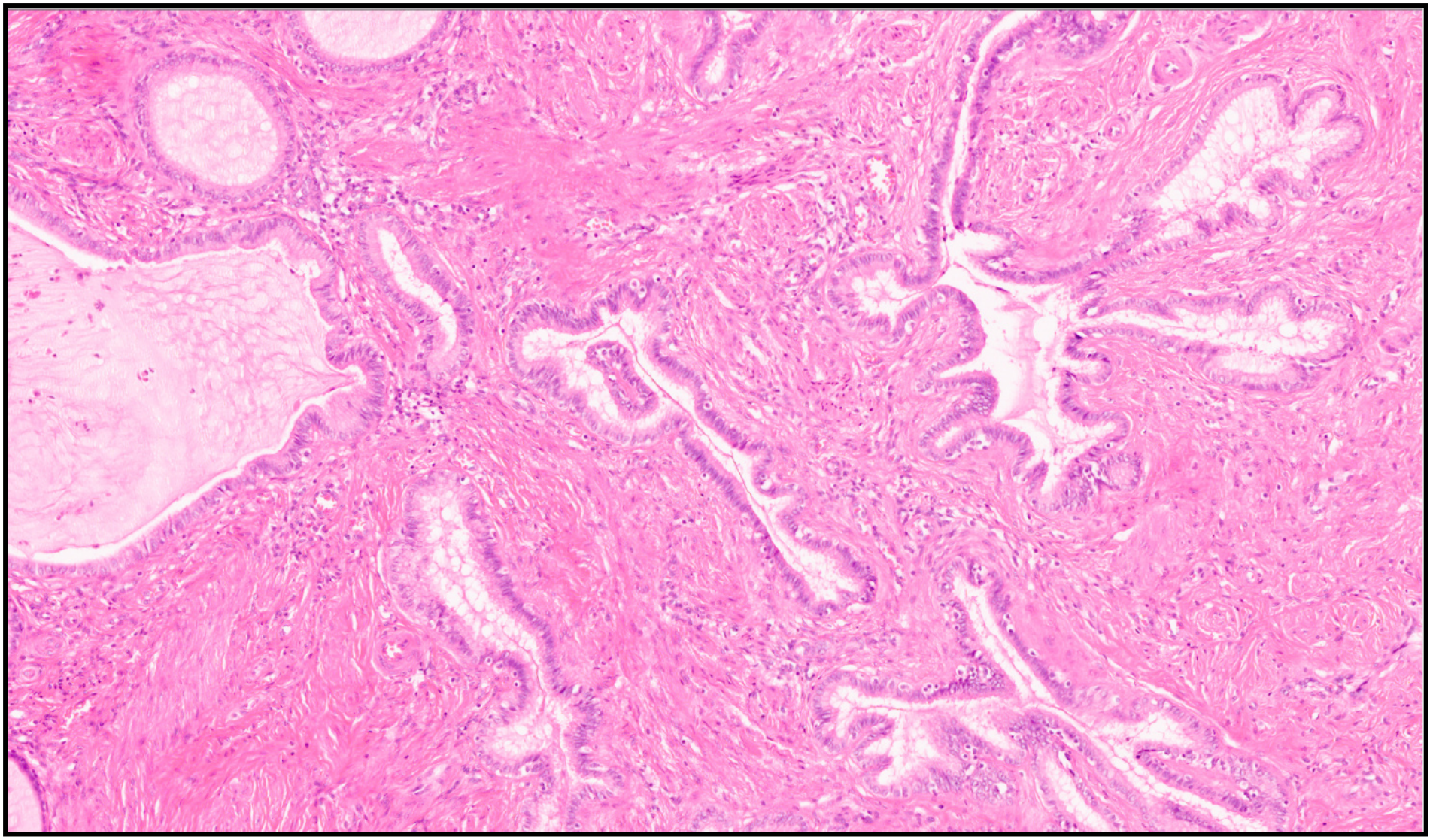

Cervical involvement

Benign mimics

- Mesonephric hyperplasia
- Cervical endometriosis

Cervical involvement
Malignant mimics

- **Primary cervical adenocarcinoma**
  - Rarely cervical adenocarcinoma may be invasive predominantly in uterine corpus/LUS
  - Rare otherwise stage 1A endometrioid carcinomas may invade cervical stroma
- **Adenoid basal carcinoma**

Cervical sampling

- 2 blocks generally sufficient
- Careful macroscopic examination is the key

Uterine serosal involvement: FIGO IIIA

Definition issue

- **RCPath (2017)**
  - Tumour must penetrate the serosal mesothelium.
- **ISGyP (2019)**
  - Submesothelial fibroconnective tissue involvement also included
  - Even if not on serosal surface

Normal uterine serosa: Scant submesothelial tissue (unlike colon)

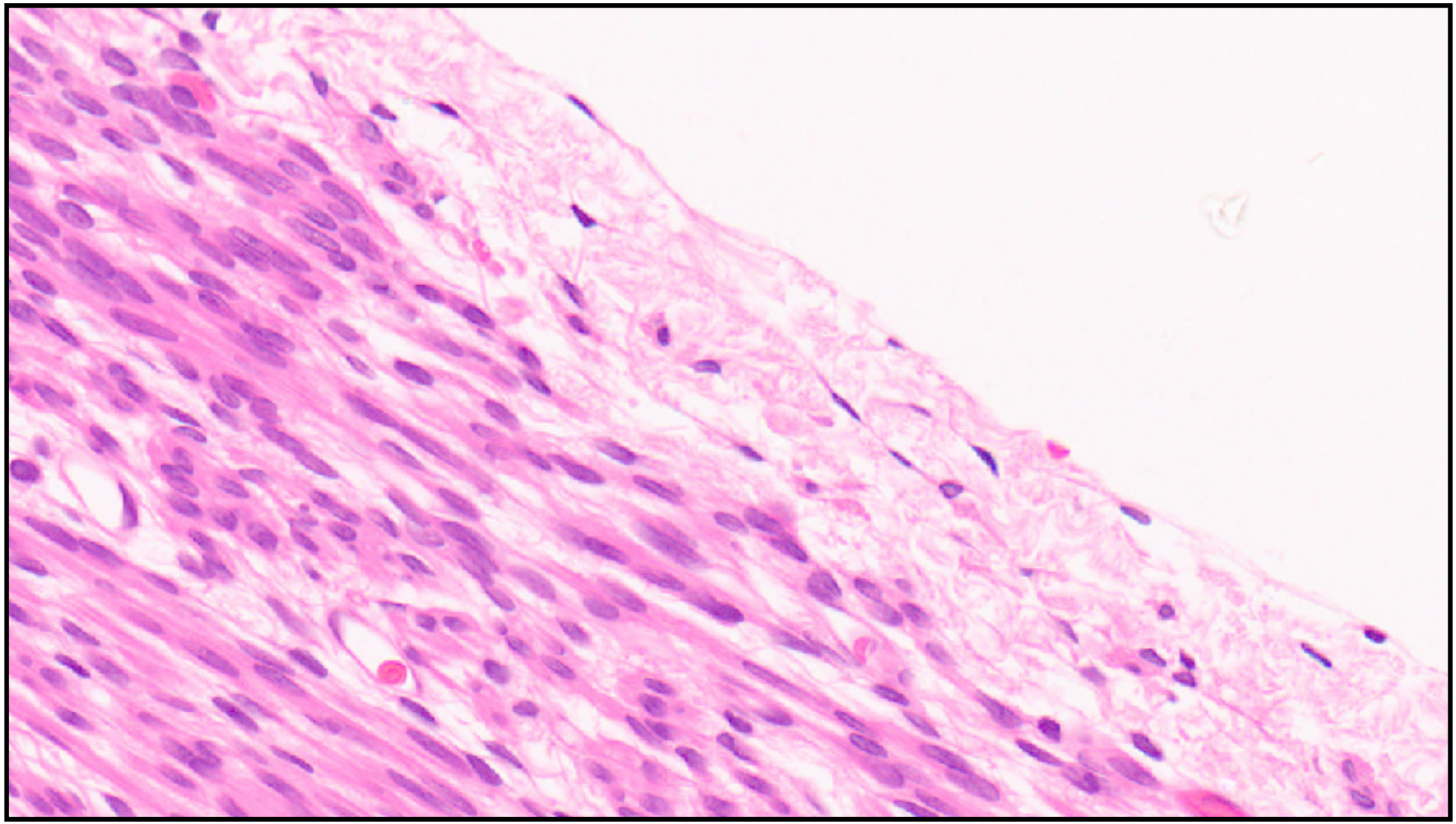

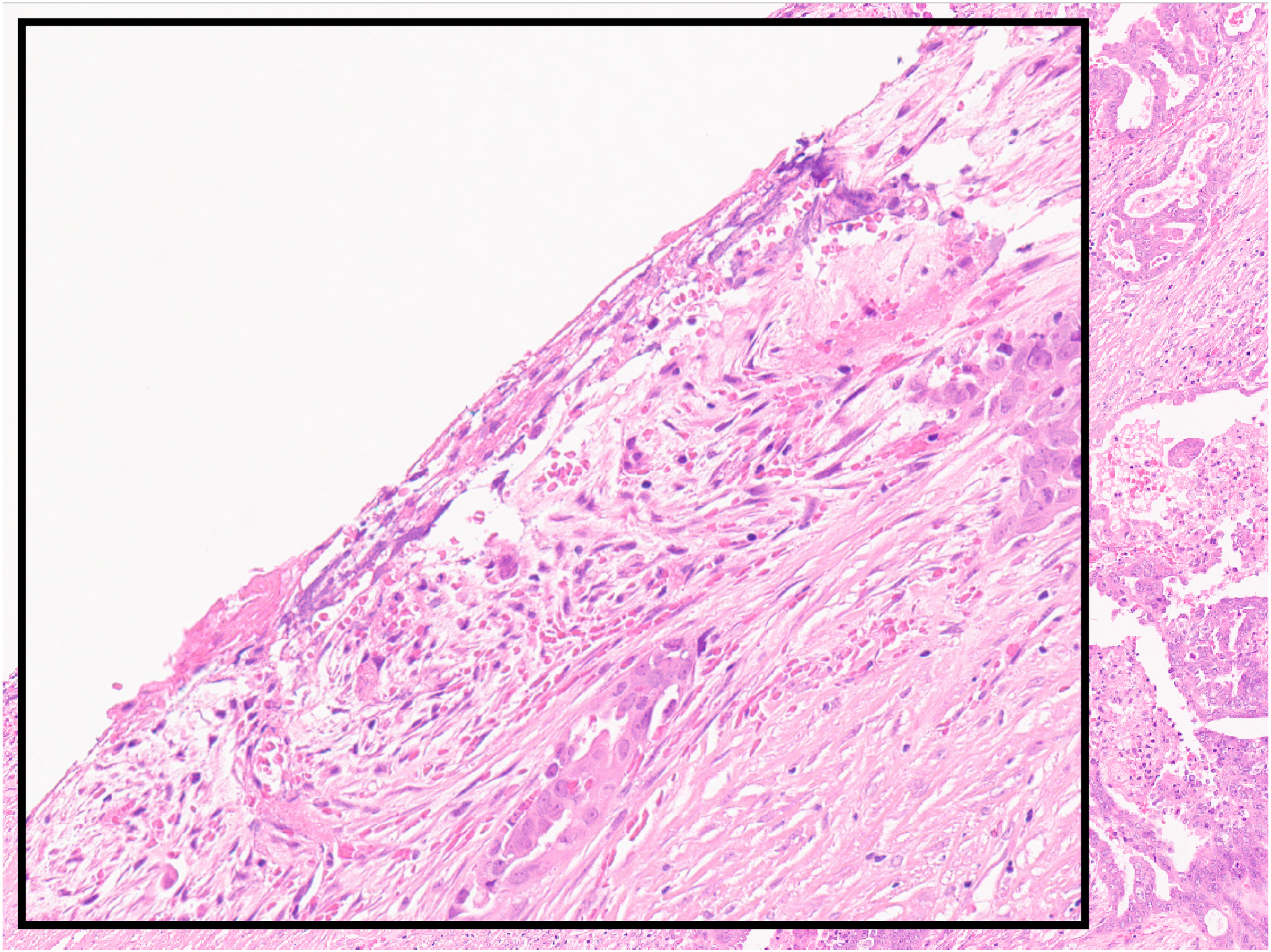

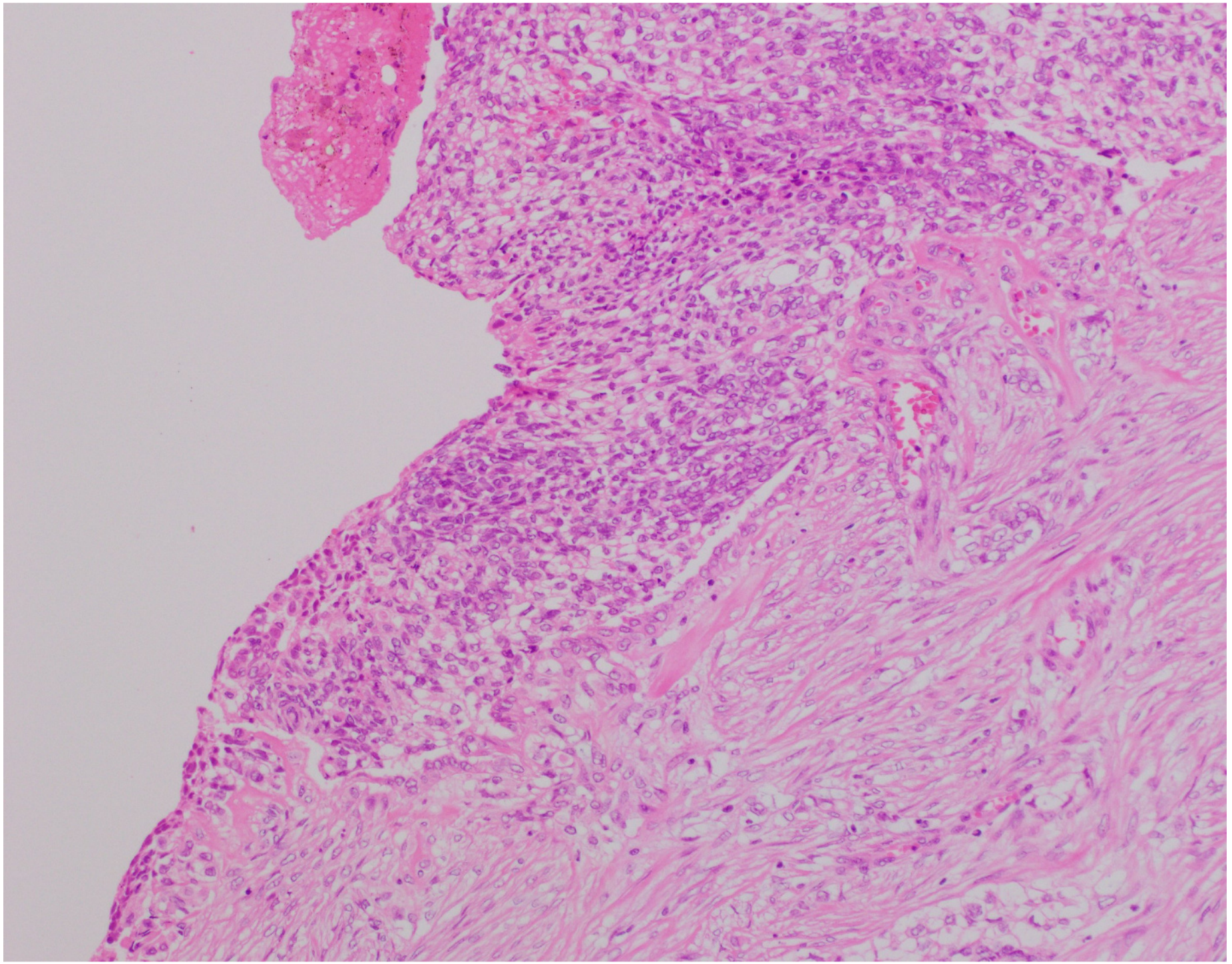

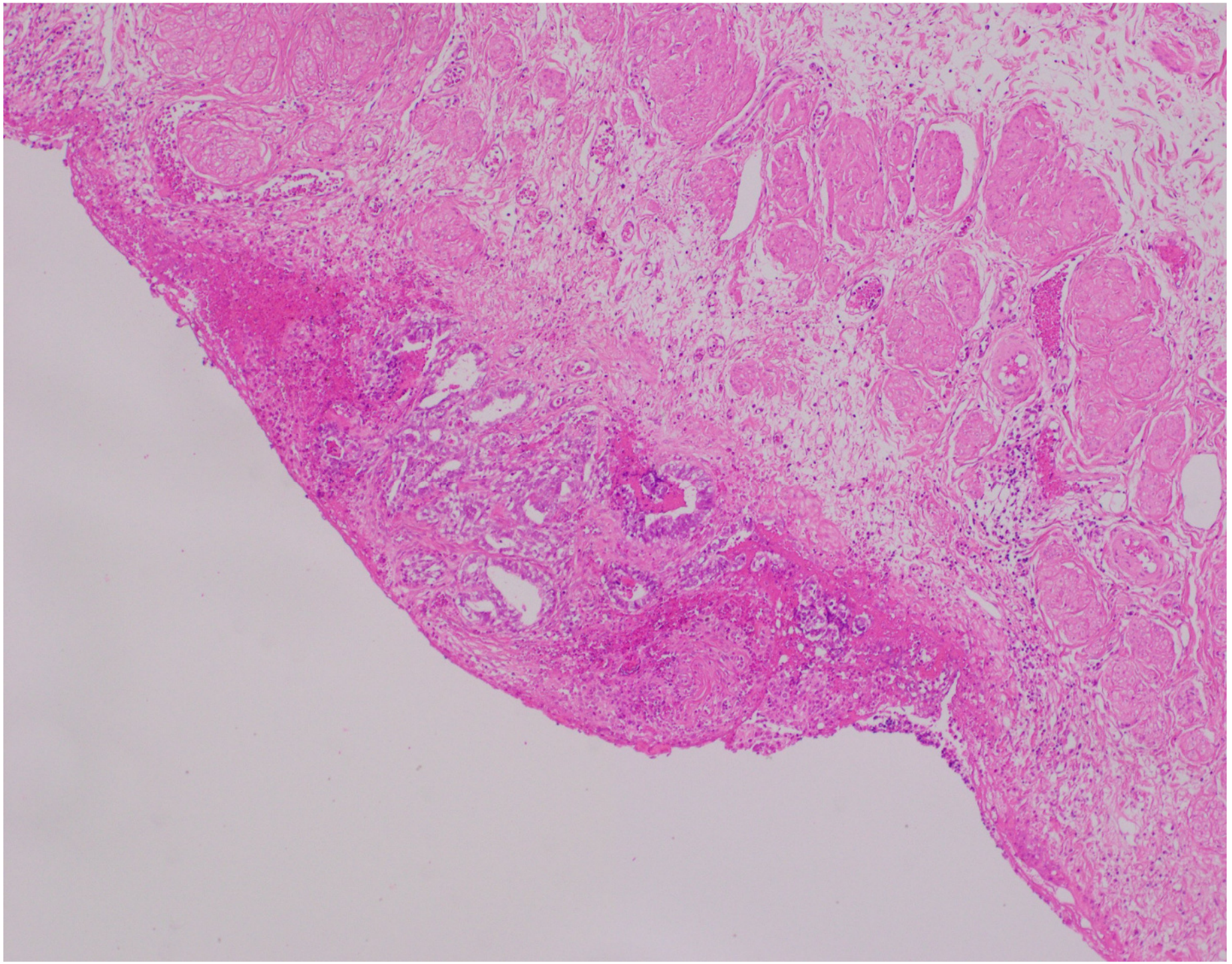

Parametrial involvement (FIGO IIIB)

- **Usually continuous, rarely discontinuous**
- **Parametrectomy only performed as part of radical hysterectomy**
- **Sample scant parametrium present in simple hysterectomy specimen**
  - Do not shave the myometrium
- **Positive lymph node in parametrium = IIIC1**

LVSI

- **Not part of FIGO/TNM staging**
  - Do not upstage the tumour based on location of LVSI
- **Independent adverse prognostic factor**
  - Particularly if extensive
- **Most important in stage 1, G1-2, endometrioid**
  - Probably more relevant than 1A/1B distinction
  - EBRT recommended if LVSI+

LVSI : Issues

- **Significant interobserver variation**
  - **LVSI mimics**
    - Retraction artefacts
    - MELF invasion
  - **Artefactual LVSI induced by**
    - Autolysis
    - Laparoscopic surgery
  - **Focal vs /extensive LVSI**

LVSI vs. retraction artefacts

- **Features of LVSI**
  - Generally not widespread
  - Usually associated with deep myometrial invasion
  - At advancing edge of tumour

LVSI vs. retraction artefacts

- **Features of LVSI**
  - Conforms to vascular contours
  - Within angulated and slit-like spaces
  - Associated lymphoid aggregates

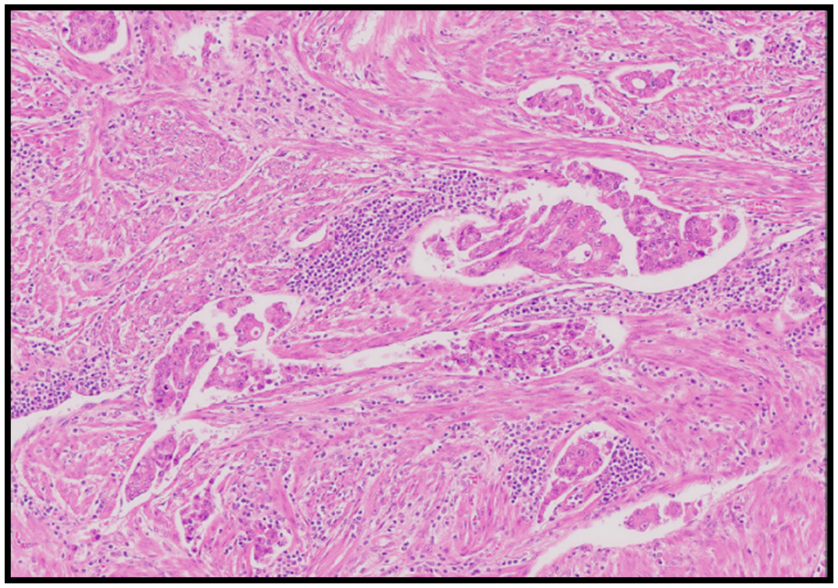

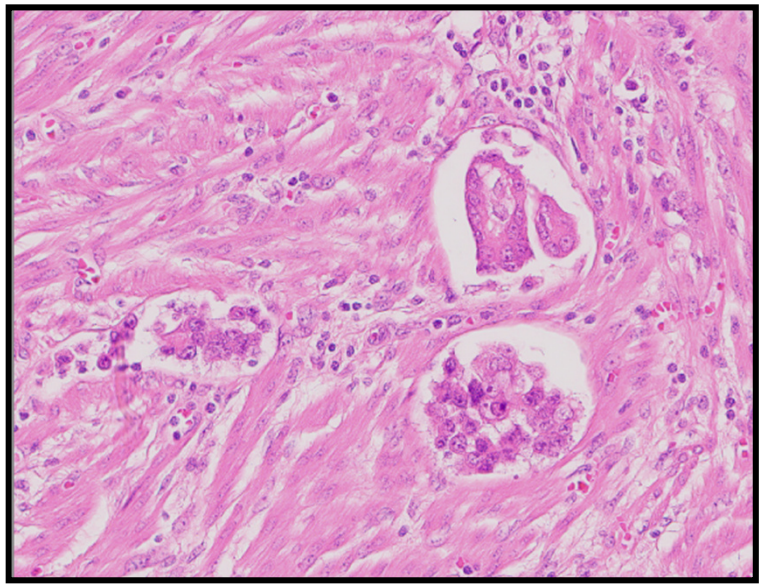

LVSI mimic: MELF invasion

- MELF spaces lined by cytokeratin positive atrophic epithelial cells

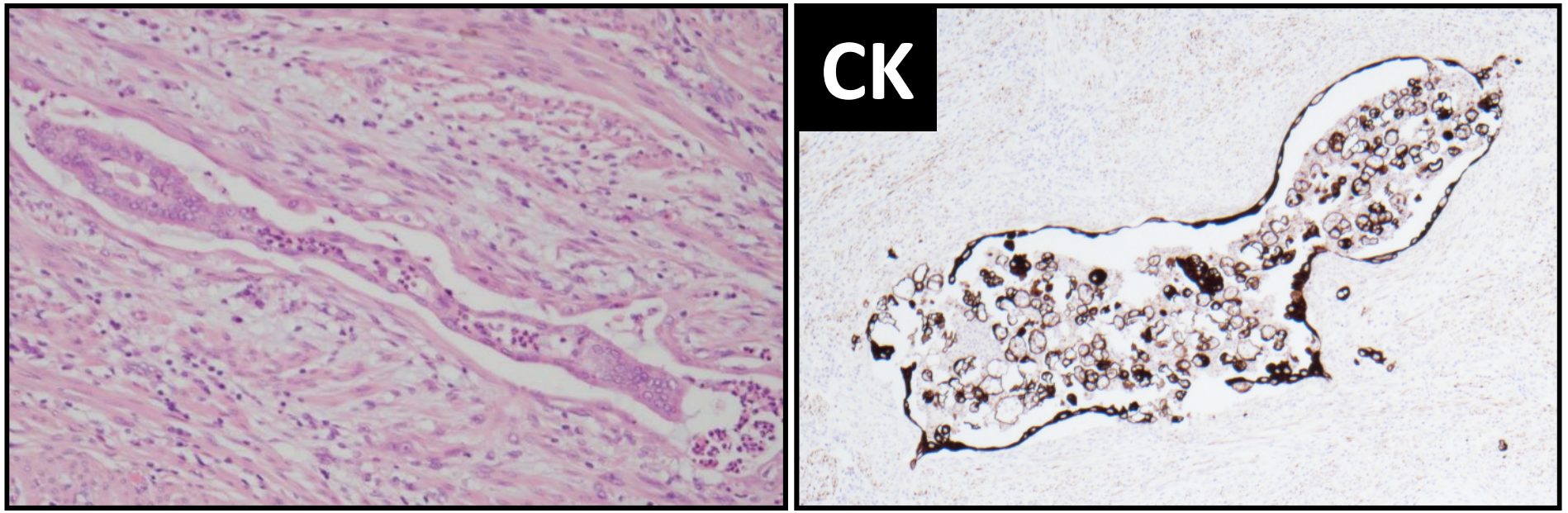

Artefactual LVSI

Autolysis

- Smearing artefact (toothpaste effect)
- In thick vessels in outer myometrium.
- Disproportionate to grade and stage
- May be present on serosa

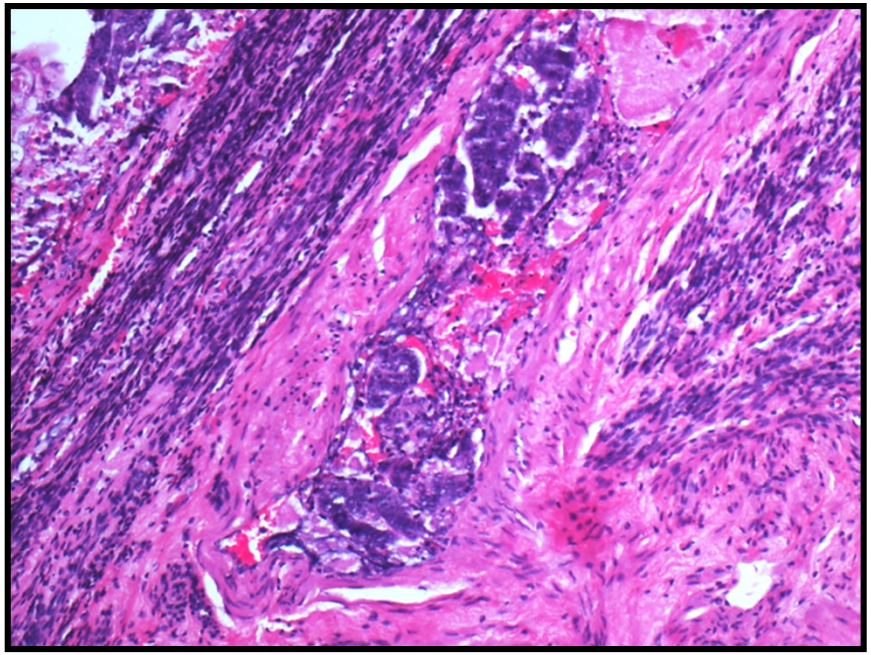

Artefactual LVSI

Laparoscopic surgery

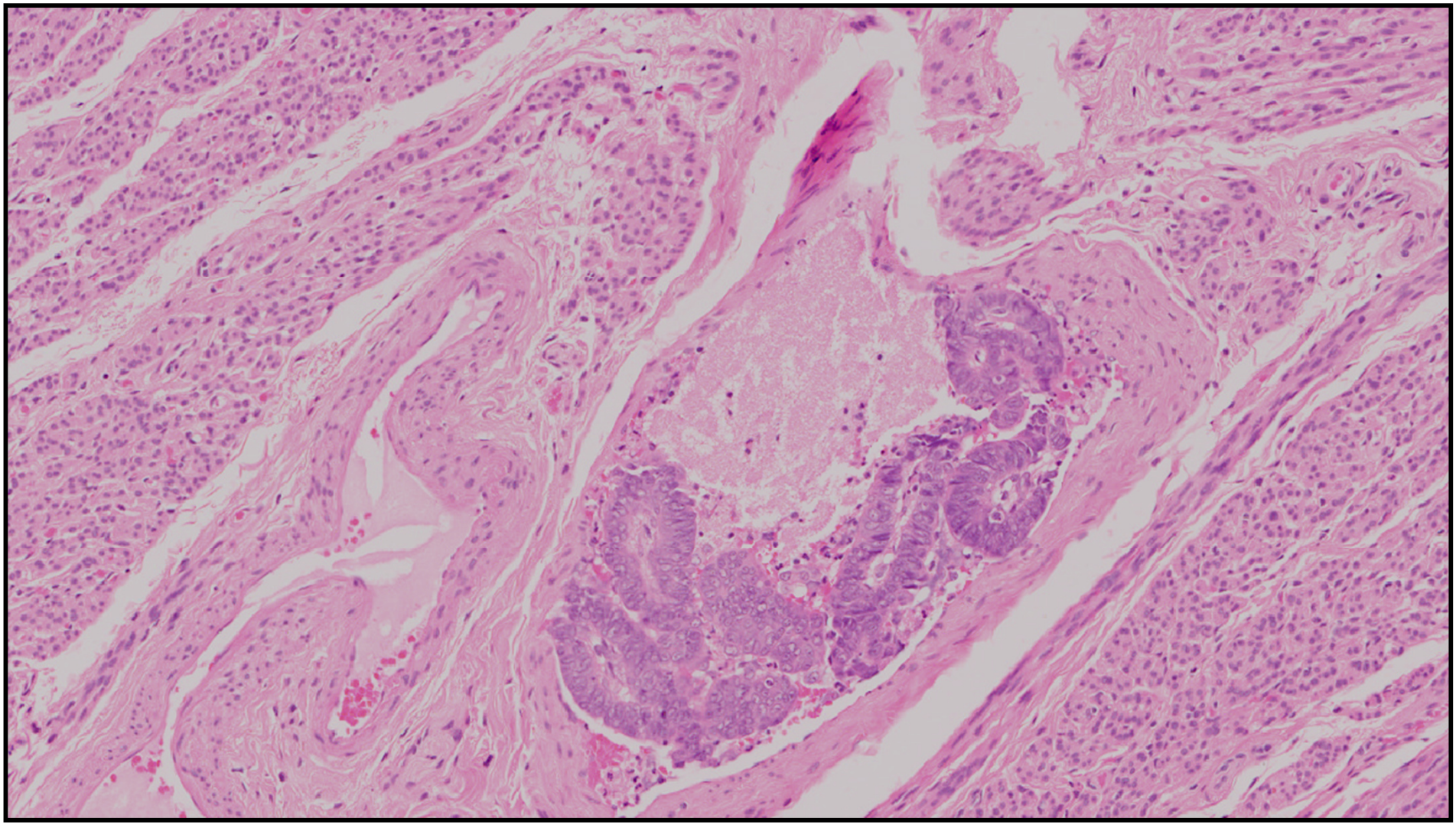

Laparoscopy induced clefts

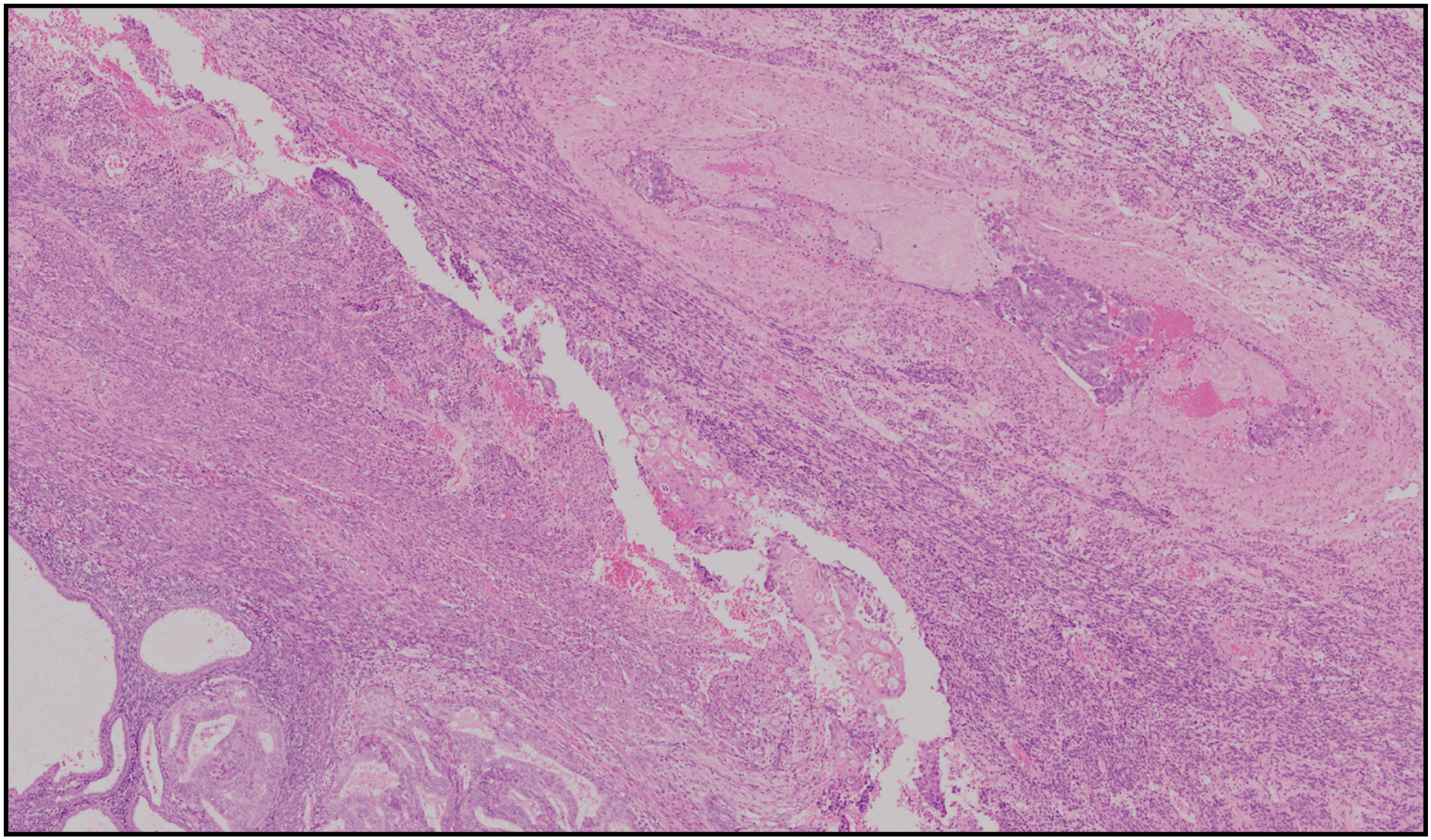

Artefactual LVSI

Laparoscopic surgery

- **Significance uncertain**
  - One study suggested increased incidence of recurrence*
- **Currently does not affect management**

*Dewdney SB et al. The prognostic significance of lymphovascular space invasion in laparoscopic versus abdominal hysterectomy for endometrioid endometrial cancer. Eur J Gynaecol Oncol. 2014;35:7–10.

Substantial LVSI

- **≥5 distinct widely separated vascular spaces involved by tumour outside the immediate invasive foci**
- **Strongest independent prognostic factor**
  - Significance of focal LVSI uncertain

Vaginal involvement (FIGO IIIB)

- **Direct continuous involvement**
  - Poor prognosis

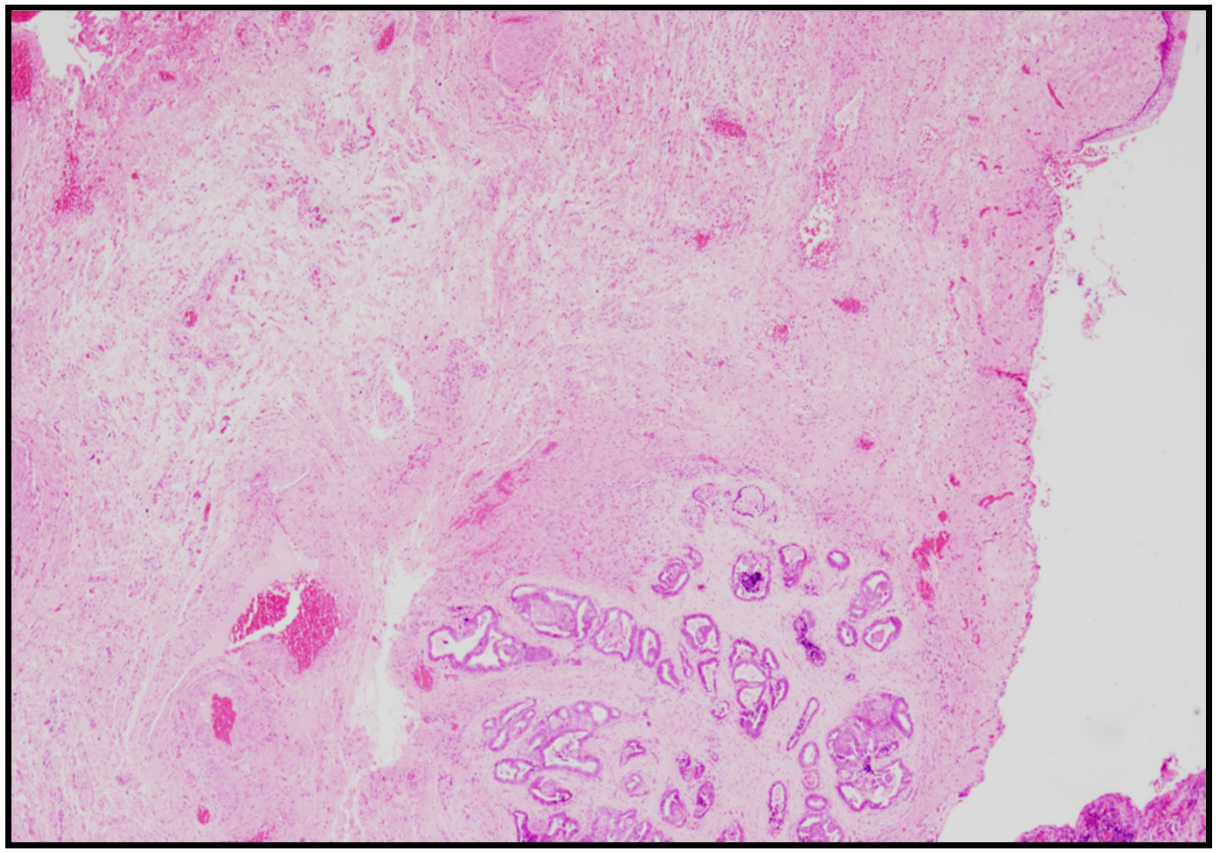

Vaginal involvement (FIGO IIIB)

- **Discontinuous “drop metastasis”**
  - Implantation secondary to prior bx/surgery?
  - Very rare at presentation
  - More common with recurrence
    - Usually curable particularly if low-grade EC
      - WLE , radiation +/- hormone therapy

Fallopian tube involvement

Fallopian tube involvement

Free floating luminal tumour cells

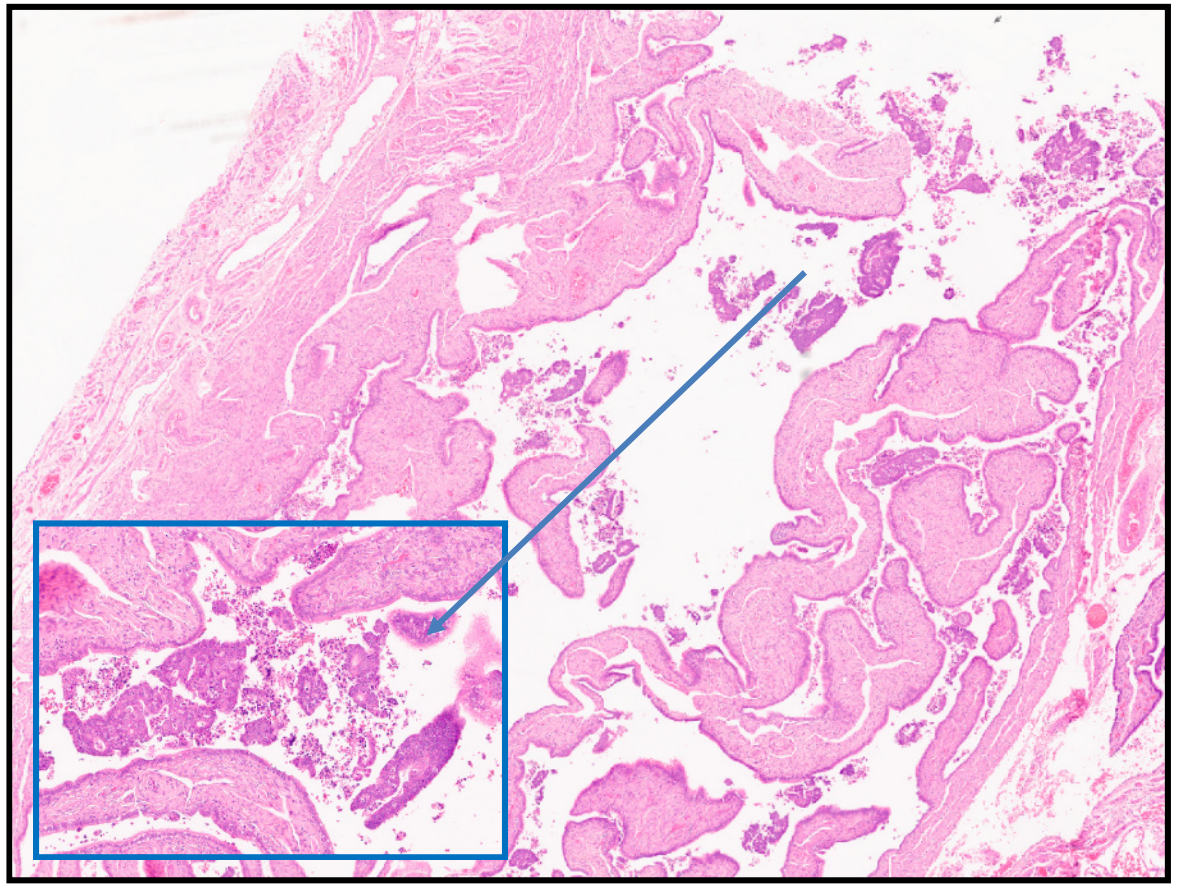

Fallopian tube involvement

Free floating lumenal tumour cells

- **Do not upstage**

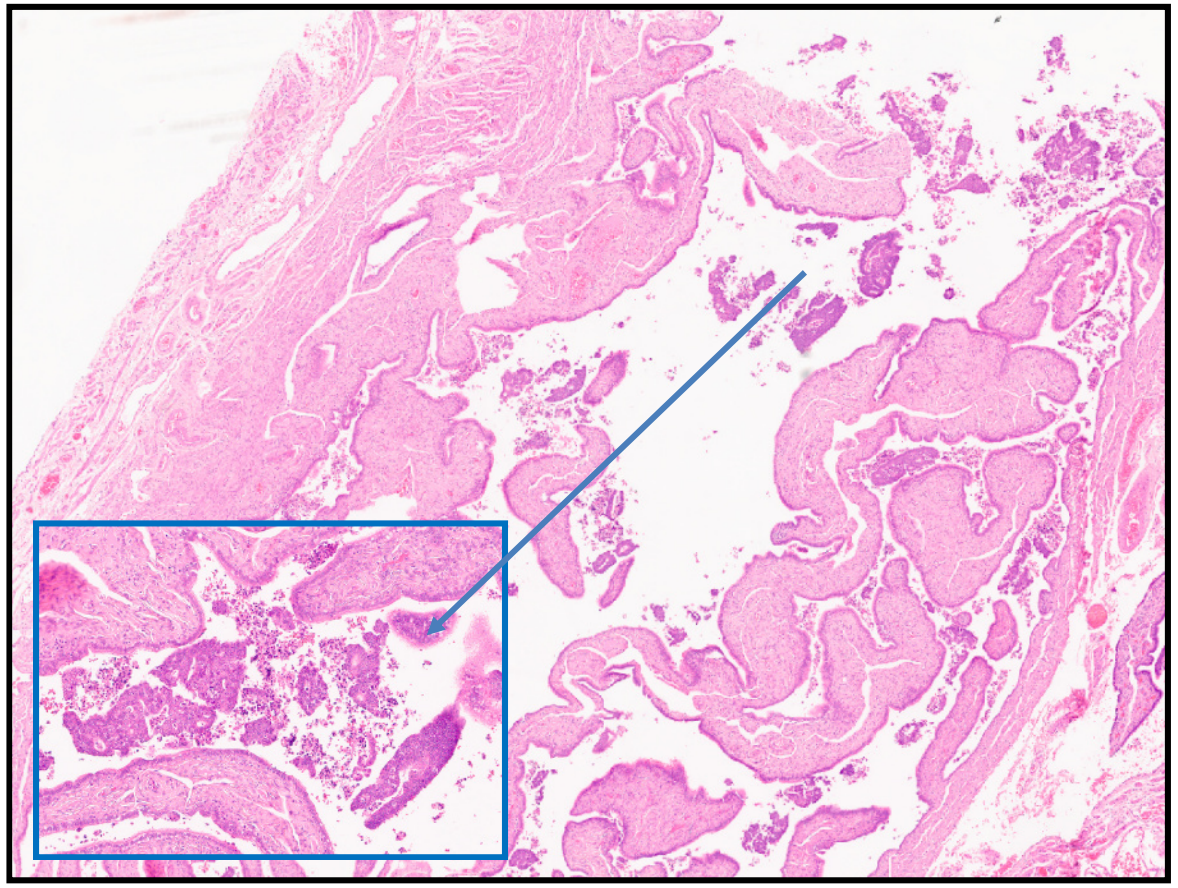

Fallopian tube involvement: FIGO IIIA

Patterns

- Intramucosal
- Mucosal and deep
- Deep layers only

- Likely to be metastasis in the setting of an endometrial cancer

Fallopian tube involvement

Pure intramucosal endometrioid CA

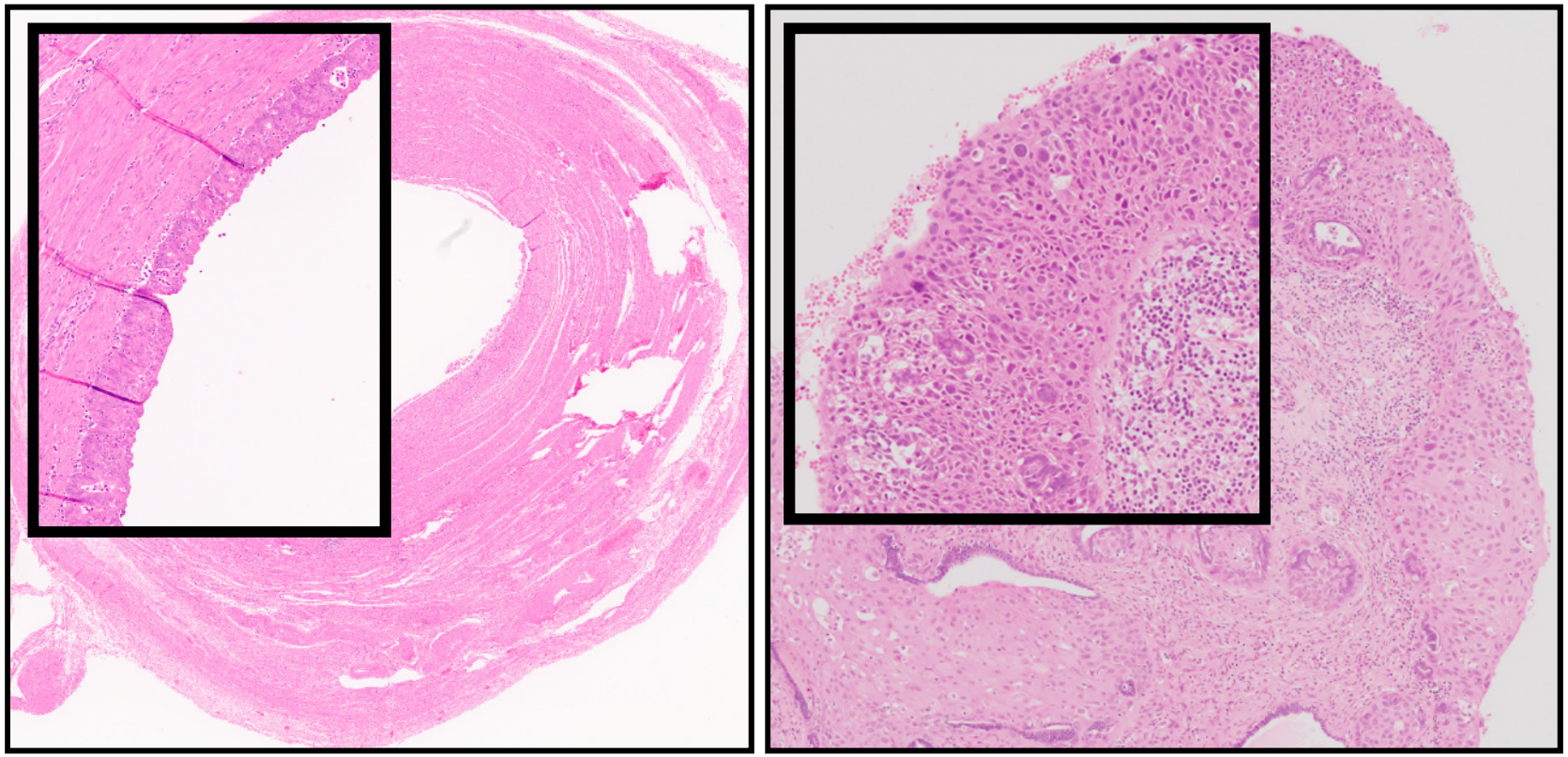

Fallopian tube involvement

Pure intramucosal endometrioid CA

- Occasionally seen
- Prognostic significance uncertain

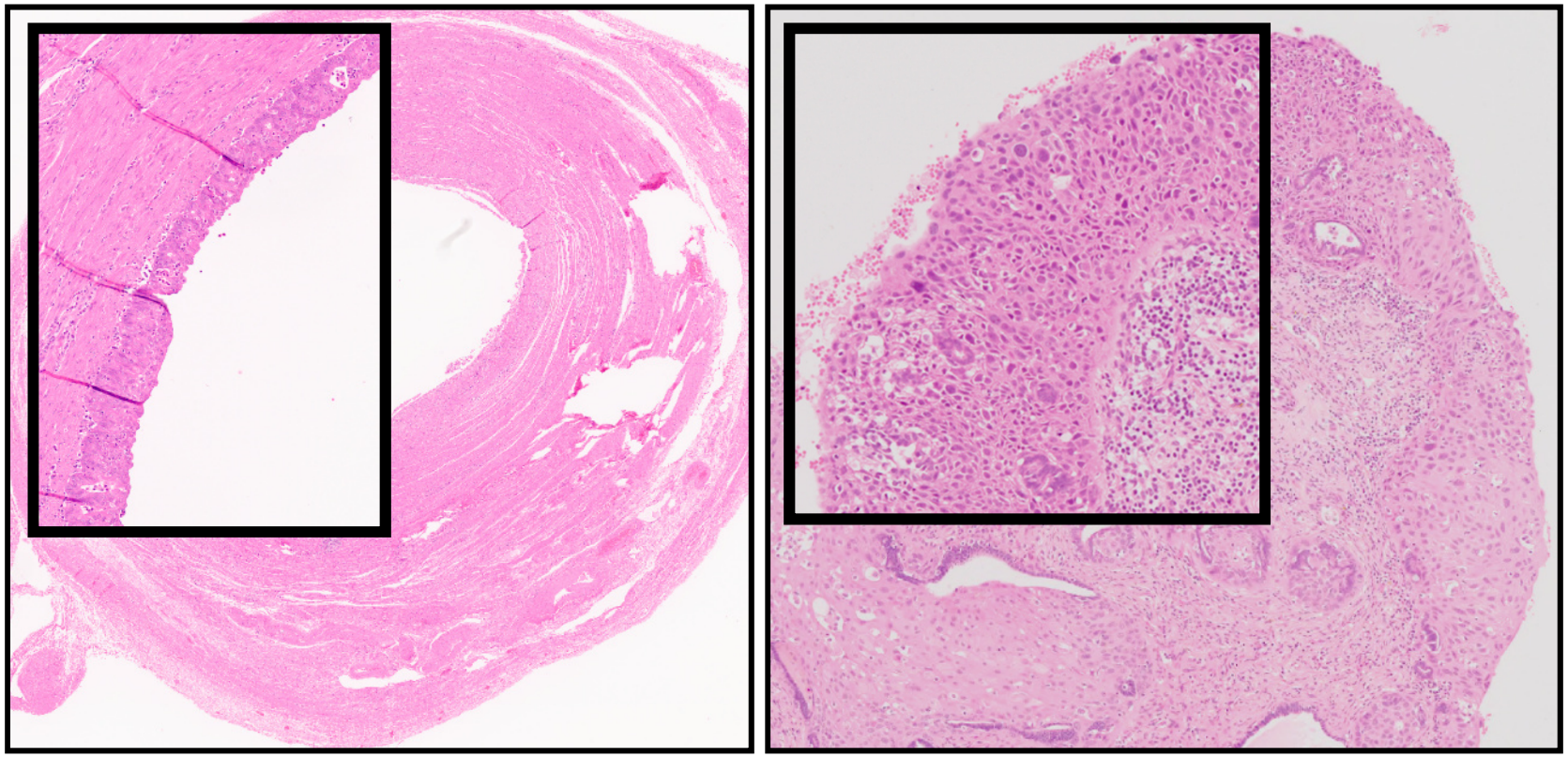

Fallopian tube involvement

Pure intramucosal *serous* carcinoma

Consider possibility of STIC (WT1 positive)

Fallopian tube involvement

Only deep layers

Indicative of metastatic endometrial carcinoma

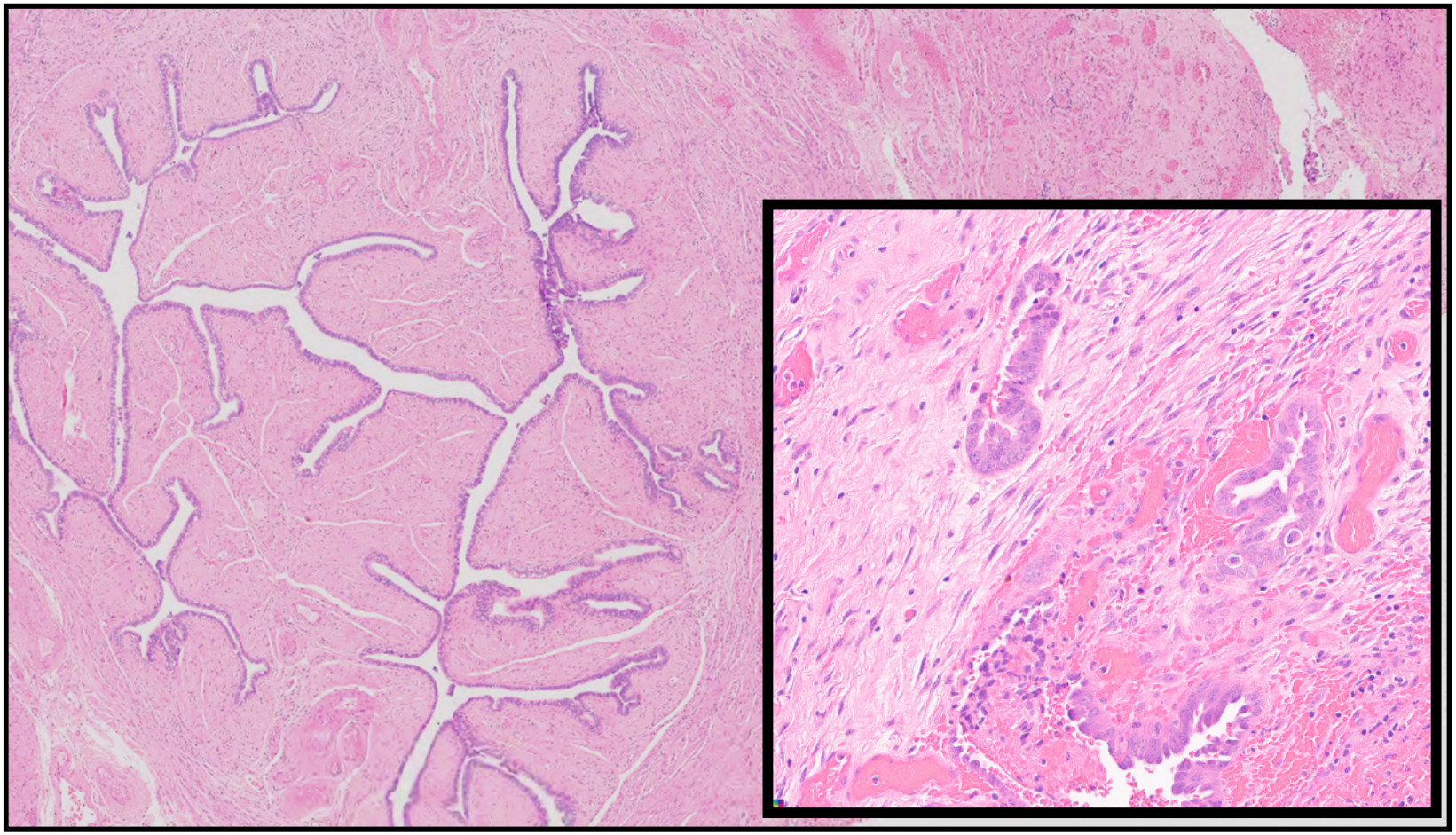

Fallopian tube involvement

Mucosal + deep

- **Endometrioid carcinoma in tube**
  - Consider possibility of synchronous tubal primary if endometrial tumour is of different grade, low-stage and lacks LVSI
- **Serous carcinoma in tube**
  - WT1 negativity would favour metastasis over synchronous tubal primary

Ovarian involvement

?metastasis ?synchronous primary

Serous carcinoma in ovary

- Likely to be metastasis in the setting of endometrial serous carcinoma
- WT1 useful (ovarian serous WT1 positive)

Endometrioid carcinoma in ovary

- **Molecular studies: most are metastasis**
  - Clonally related
- **However, use AFIP criteria**

Endometrioid carcinoma in uterus and ovary

Features favoring synchronous primaries

- **Endometrial tumour**
  - Low-grade, no/superficial invasion, No LVSI
- **Ovarian tumour**
  - Low-grade
  - Large, unilateral tumour
  - Expansile invasion
  - Associated endometriosis/Mullerian borderline tumour

Modified from: Soslow RA. Practical issues related to uterine pathology: staging, frozen section, artifacts, and Lynch syndrome. *Mod Pathol* 2016;29(suppl 1):S59–577.

Endometrioid carcinoma in ovary

Synchronous primary

- **Good prognosis if AFIP criteria suggest synchronous primaries**
  - Transtubal spread rather than true metastasis

Endometrioid carcinoma in uterus and ovary

Features favoring metastasis from uterus

- Small ovaries (<10cm)
- Bilateral involvement
- No associated endometriosis or Mullerian borderline tumour

Microscopic features favoring metastasis from uterus

- Surface involvement
- Multinodular configuration
- Destructive invasion
- LVSI

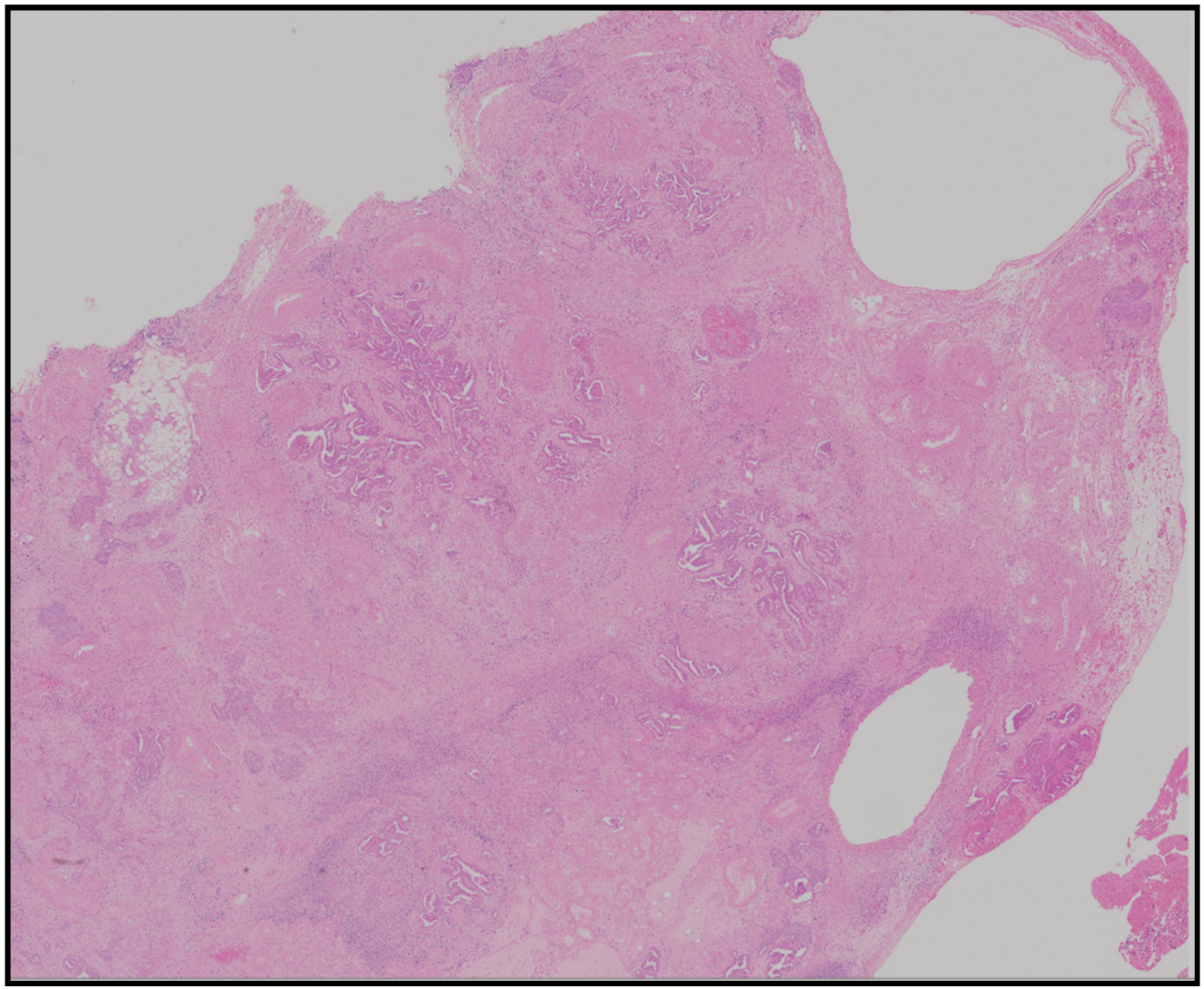

Adnexal involvement

Benign mimics

- Keratin granulomas
- Atypical endometriosis

Keratin granulomas

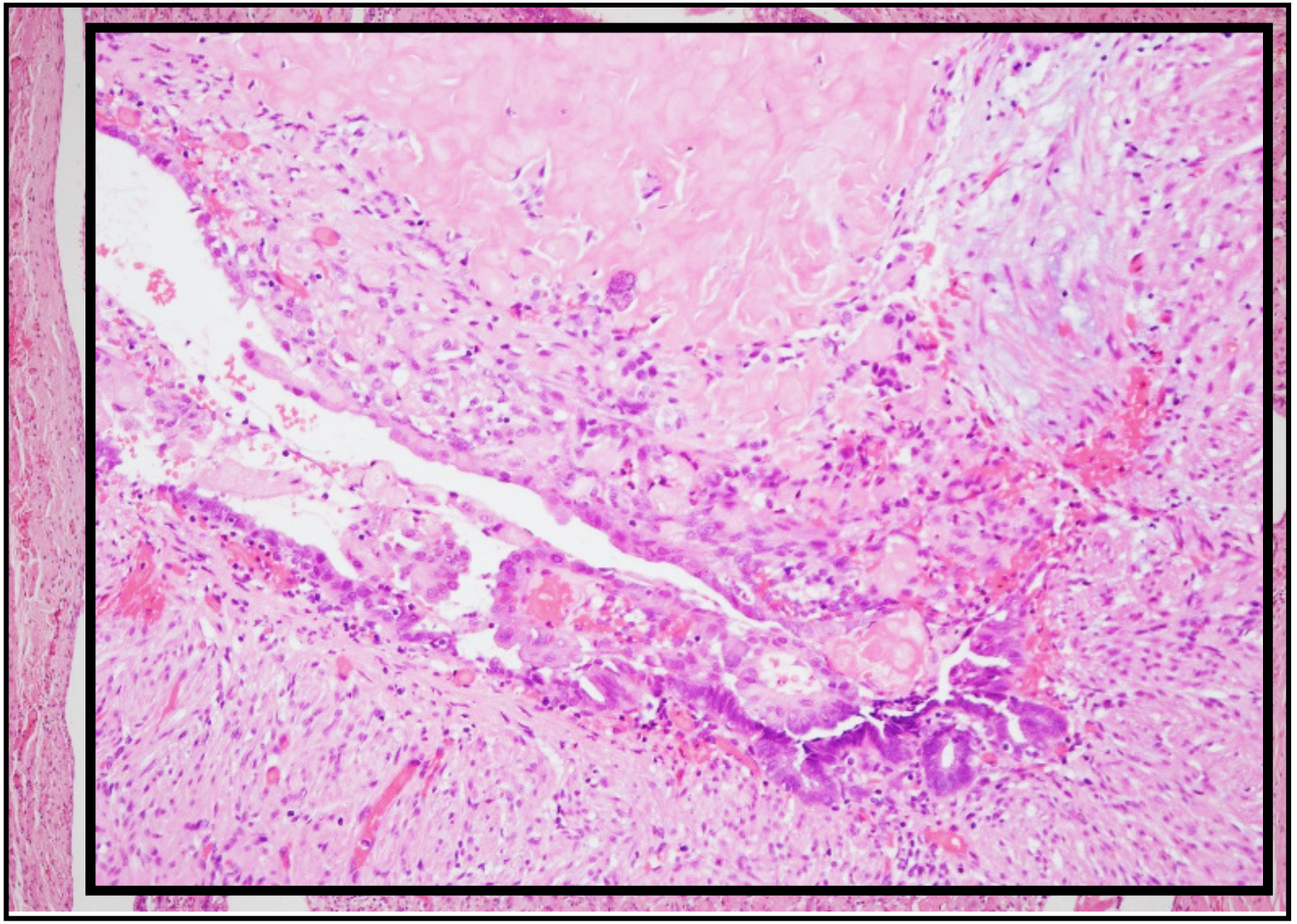

Keratin granulomas

- **Location:** serosa of uterus, ovary, fallopian tube or lumen of fallopian tube, rarely omentum
- Seen with endometrioid adenocarcinoma with squamous differentiation

Keratin granulomas

- **No prognostic significance**
- **Do not upstage**
- **Examine deeper levels**
  - Presence of malignant epithelium = metastasis

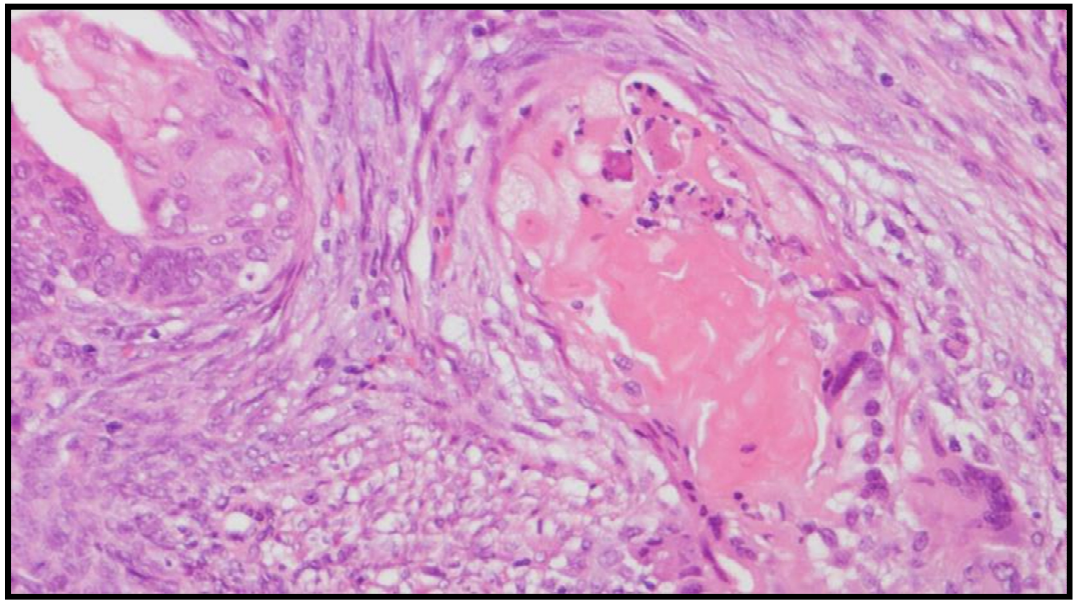

Lymph node staging

- **Isolated tumour cells**
  - **TNM:** pN0 (i+)
  - **FIGO:** Unclear ?IIIC

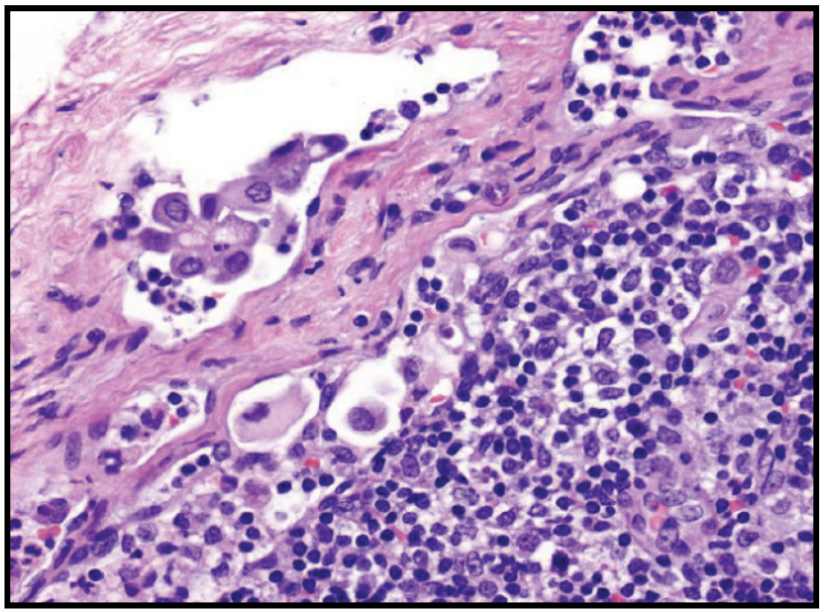

Staging pelvic/abdominal peritoneal involvement

- **Not specifically dealt with in FIGO**
- **ISGyP*:**
  - *Pelvic - FIGO IIIA*
  - *Abdominal - FIGO IVB*

*Based on advice from TNM help desk

Vulval carcinoma

- Invasion vs no invasion
- Measuring depth of invasion
- MOST IMPORTANT PROGNOSTIC DETERMINANT: **HPV STATUS**
- **HPV-independent tumours have significantly poorer prognosis:**
  - **Higher stage**
  - **LNI**
  - **Recurrence after surgery; need wider margins/radical procedure**
  - **Poorer response to adjuvant Rx**

Thank You