CASE 6

Lilla Madaras
Semmelweis University
2nd Department of Pathology

Technology Transfer in Diagnostic Pathology
10th Central European Regional Meeting
27th June 2019, Visegrád, Hungary

Case history

- Female aged 66, smoker
- Weight: 110kg, Hight: 165 cm BMI: 40,4
- Pregnancies: 8, live births 4, Missed AB: 1, inter: 3
- History of postmenopausal bleeding
- Preoperative diagnosis of EIN
- Total hysterectomy+BSO performed
- Both fallopian tubes and ovaries unremarkable
- Section from the tip of an endometrial polyp (3x4,5 cm)

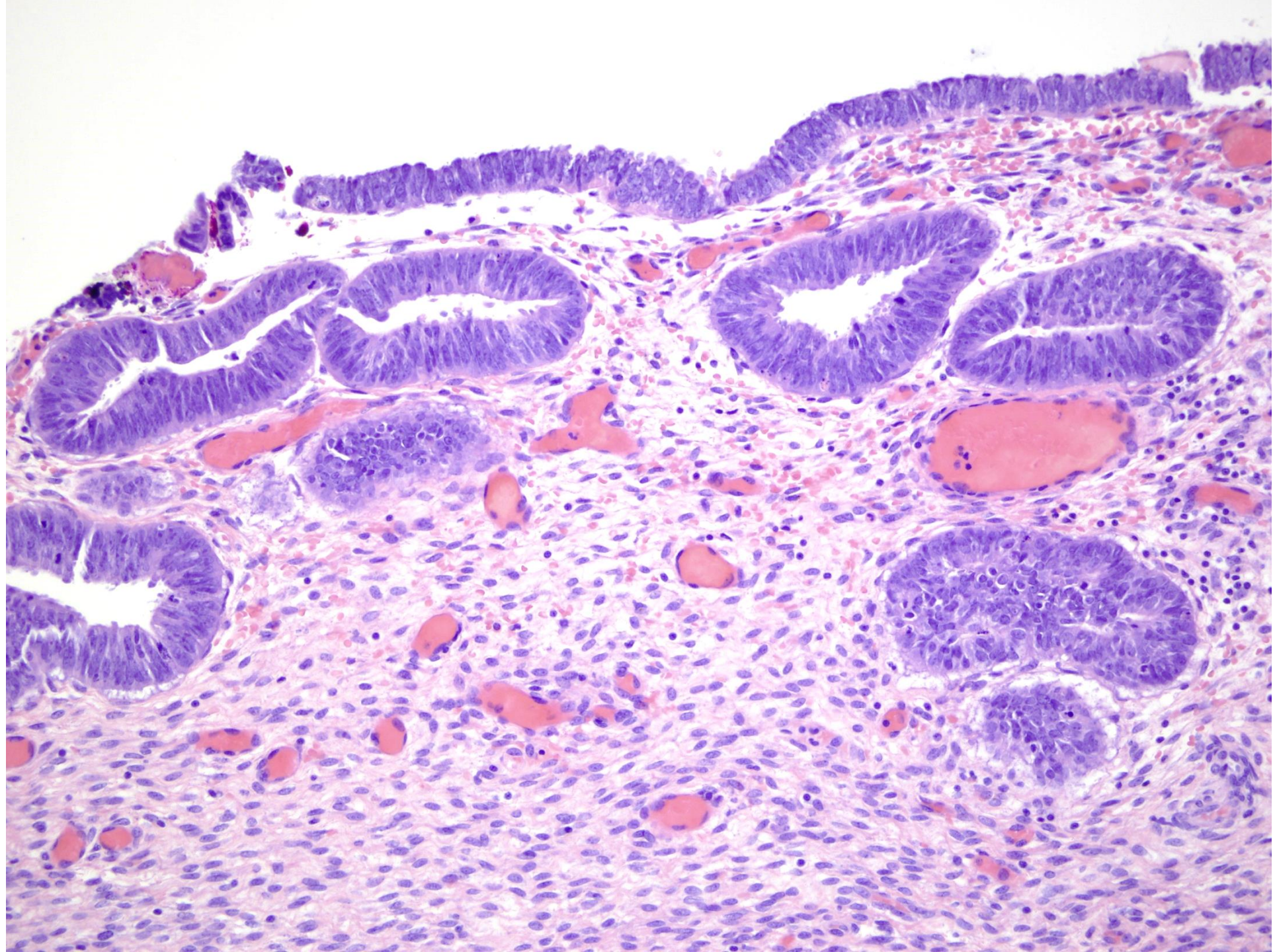

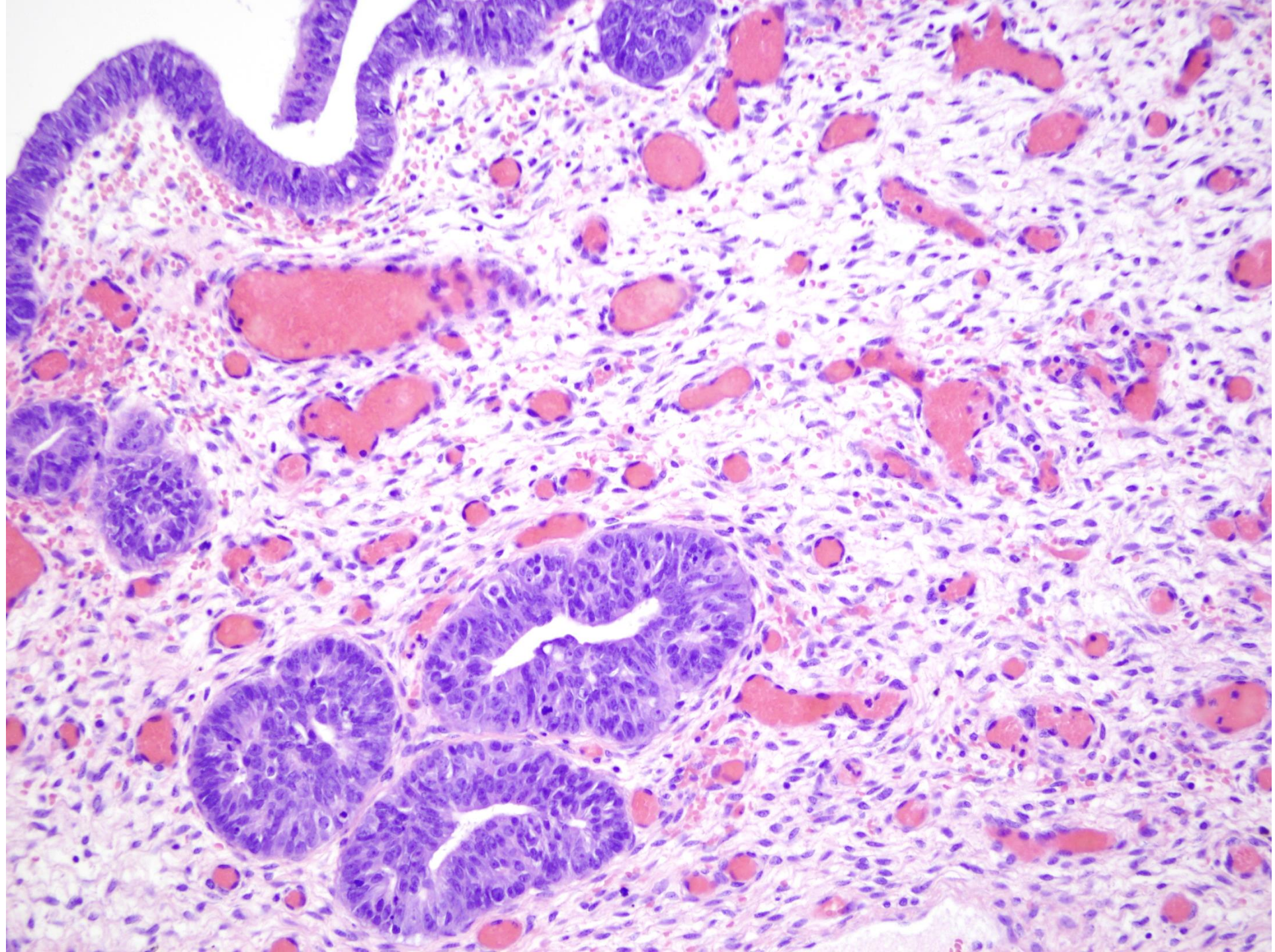

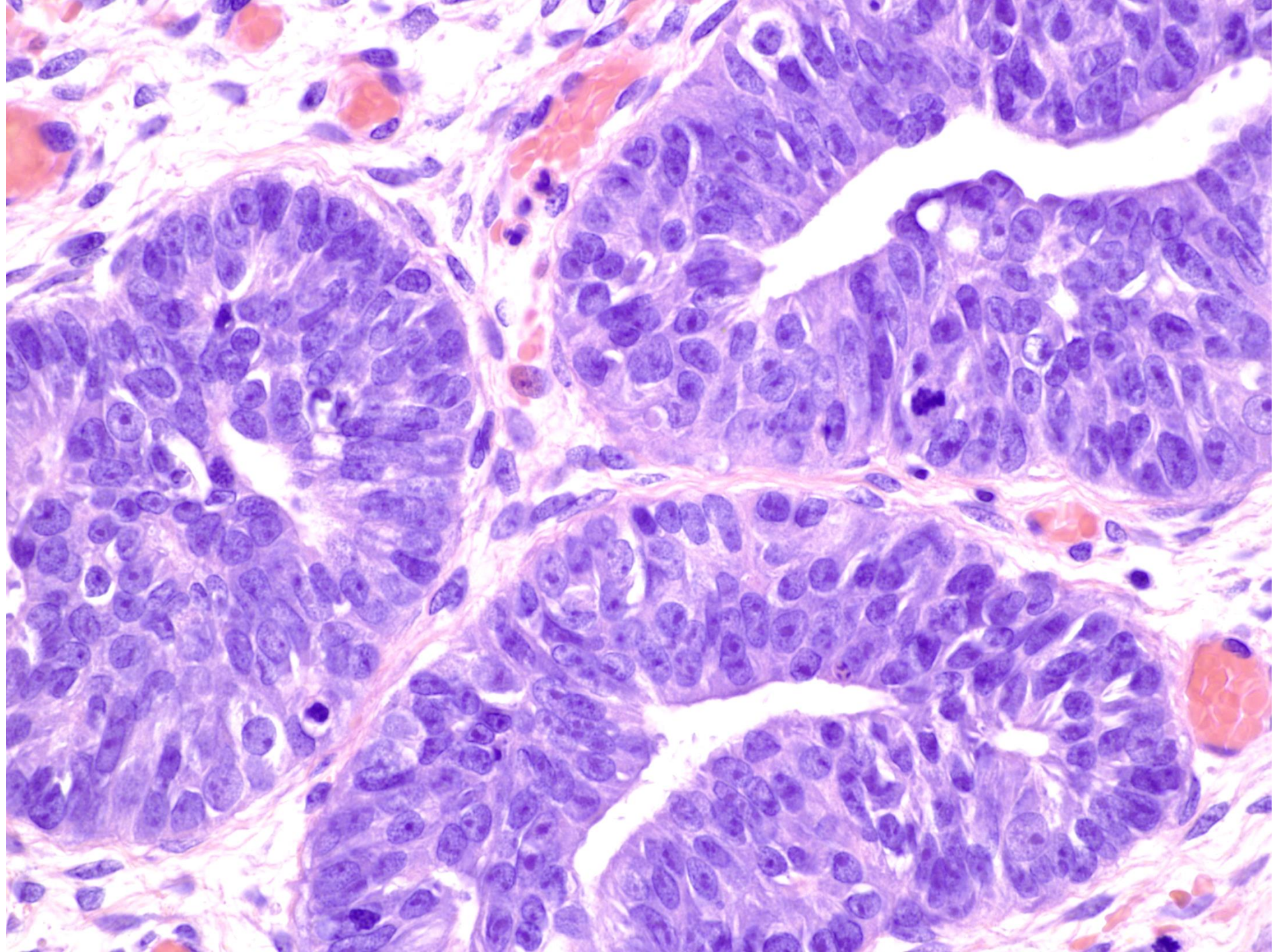

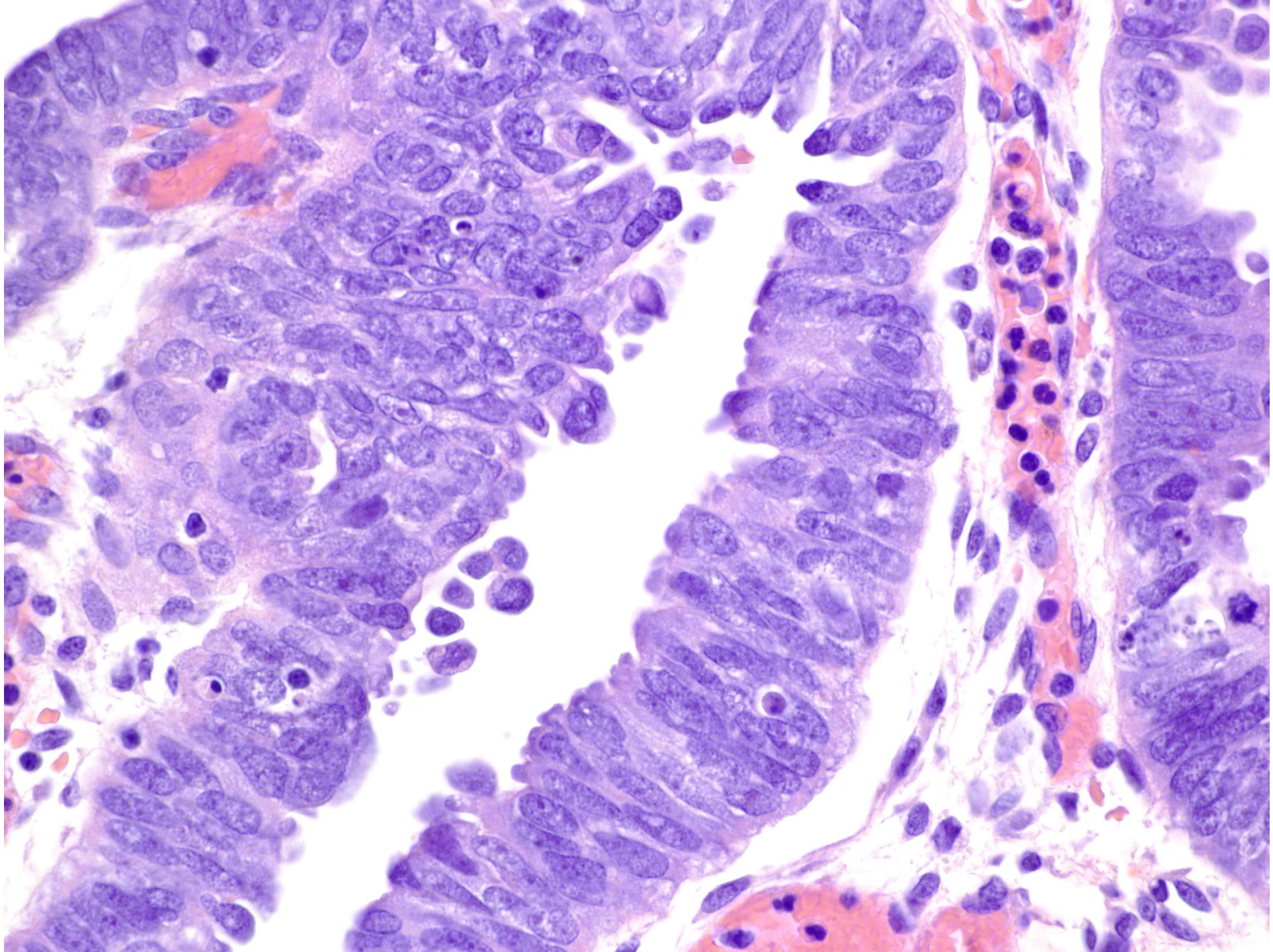

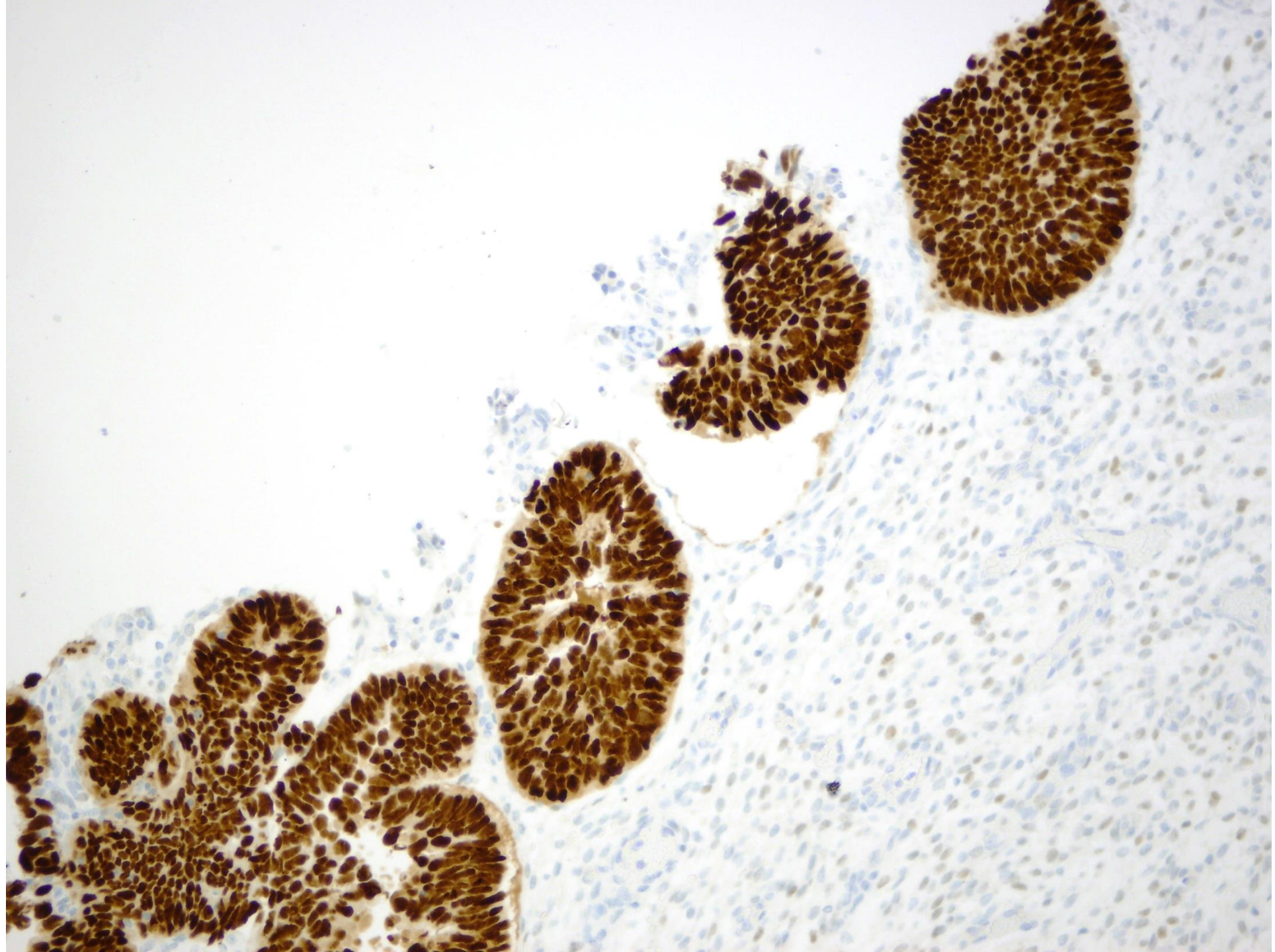

p53

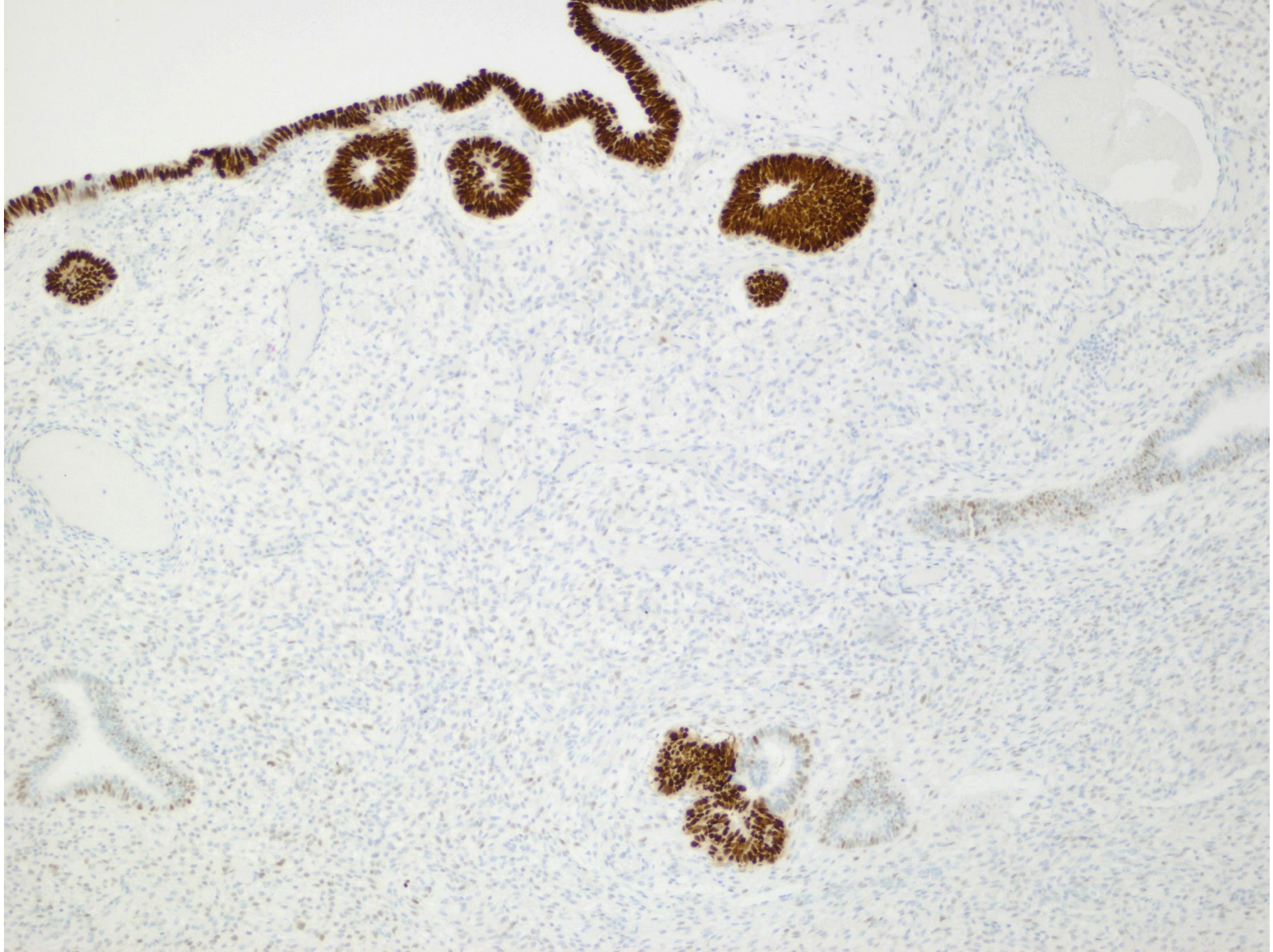

p53

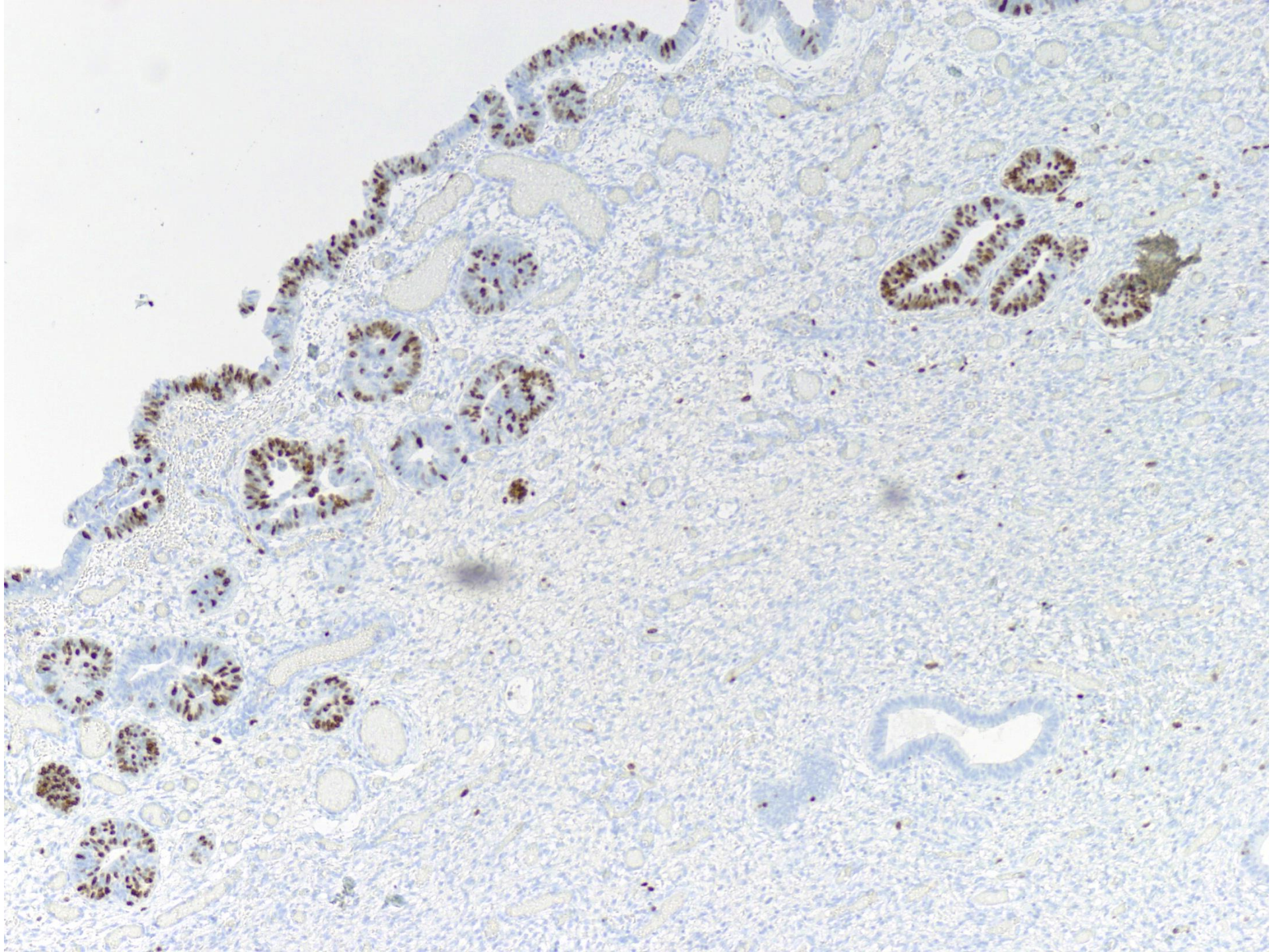

Ki67

Serous Endometrial Intraepithelial Carcinoma (SEIC)

Serous Endometrial Intraepithelial Carcinoma (SEIC)

- WHO 4th edition: non-invasive, immediate precursor of invasive uterine serous carcinoma
- This is a CARCINOMA
- Metastatic potential
- Polyp or atrophic endometrium
- Luminal surface -scalloped or frayed (apical border is often lacking)
- Marked nuclear atypia
- Numerous mitotic figures, abnormal mitoses
- p53 mutation-type staining
- High Ki67 labeling
- *Genetic profile:TP53* (80–90%), *PIK3CA* (24–40%), *FBXW7* (20–30%), and *PPP2R1A* (18–28%)-like in serous carcinoma
- Genetic susceptibility: BRCA1/2

Differential diagnosis

- Papillary syncitial metaplasia with degenerative atypia
  - (p16+, increased p53 expression-but wild type, lacks mitoses, low Ki67)
- Radiation-induced atypia
  - (More diffuse, lacks mitoses, low Ki67, p53 wild type, p16 -)
- Metastases/secondary involvement
  - AIS-cervix
  - Adnexal serous carcinomas

CASE 7

Lilla Madaras
Semmelweis University
2nd Department of Pathology

Technology Transfer in Diagnostic Pathology
10th Central European Regional Meeting
27th June 2019, Visegrád, Hungary

Clinical data

- Woman aged 50
- Abnormal uterine bleeding

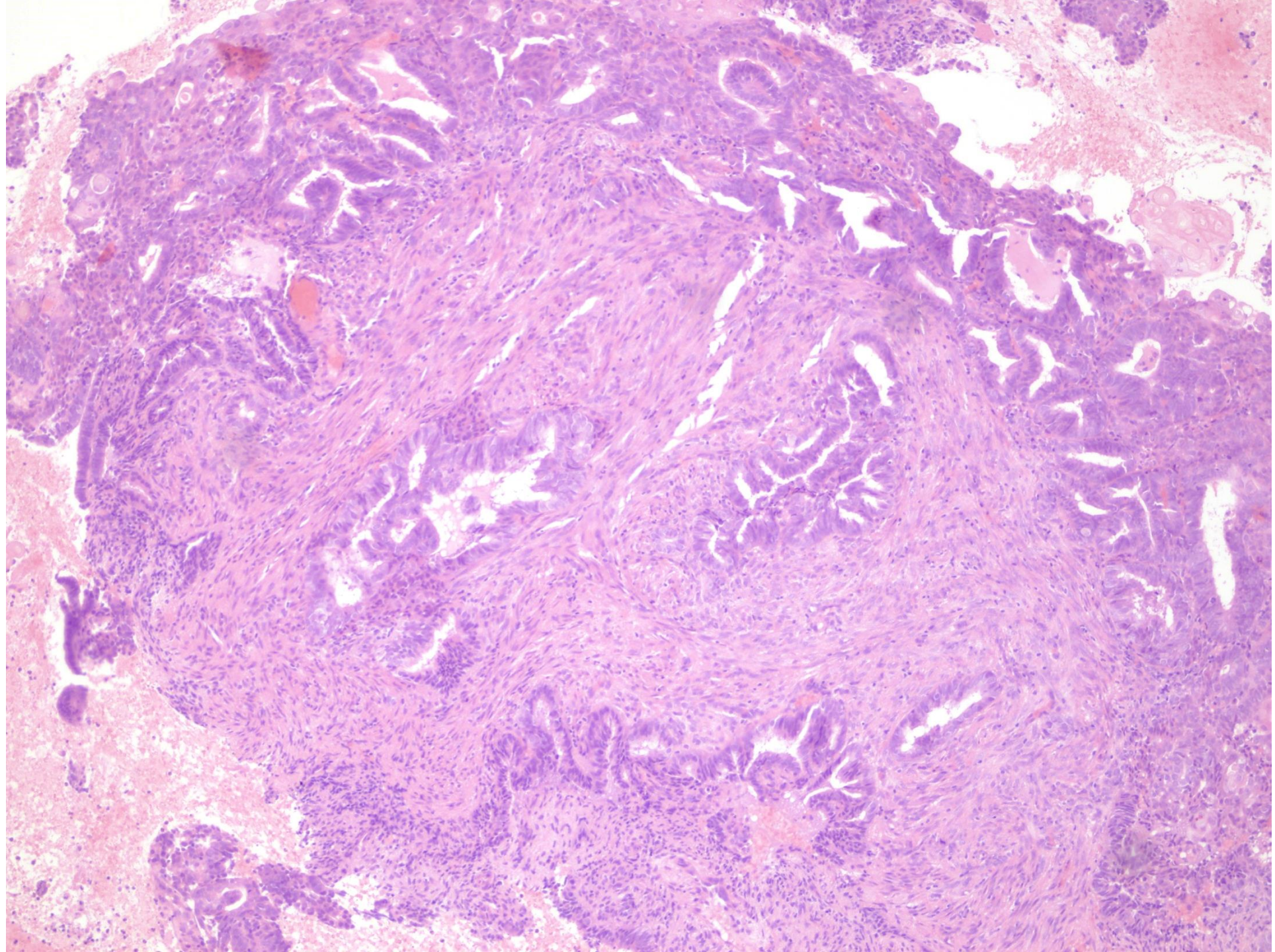

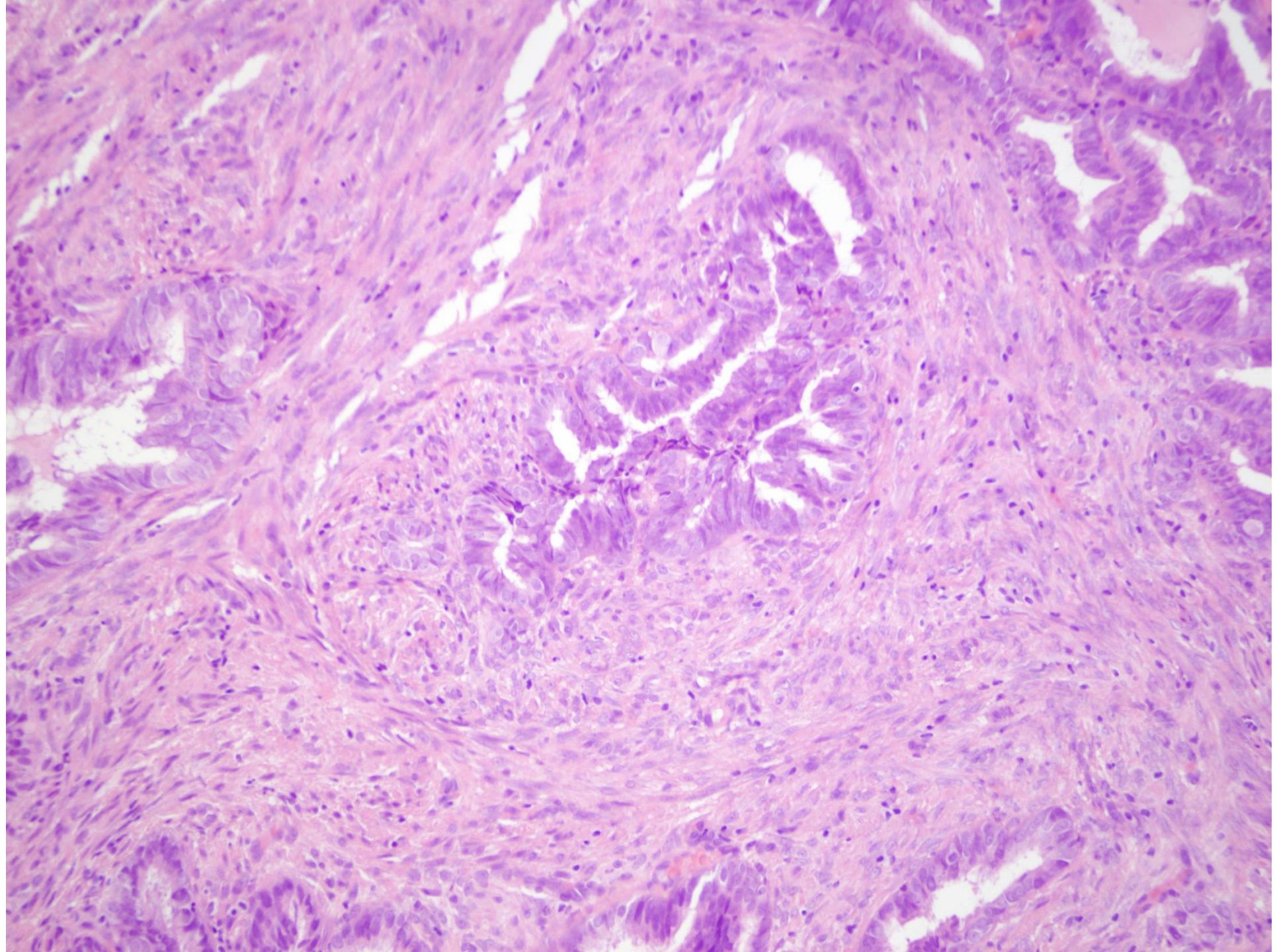

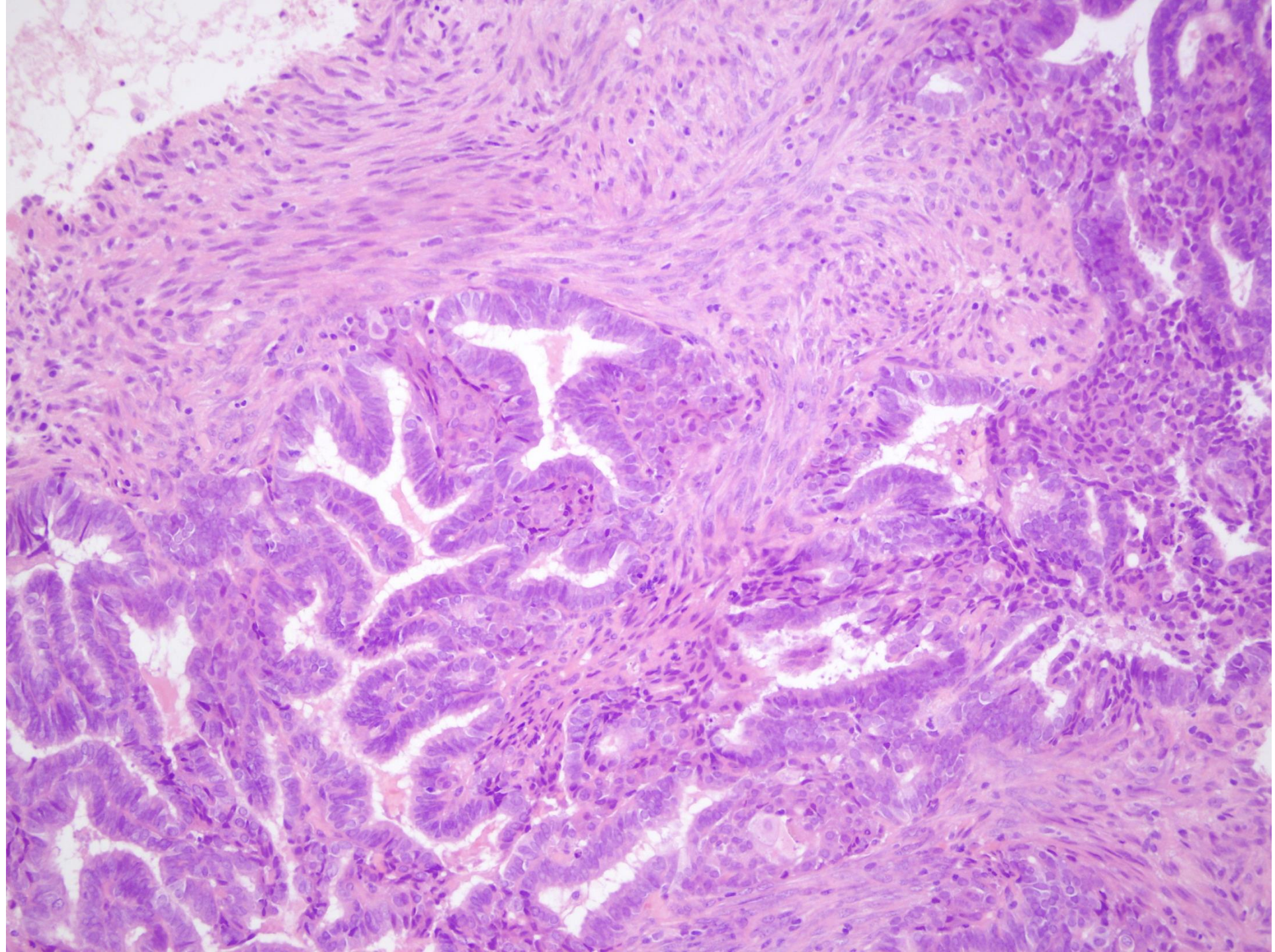

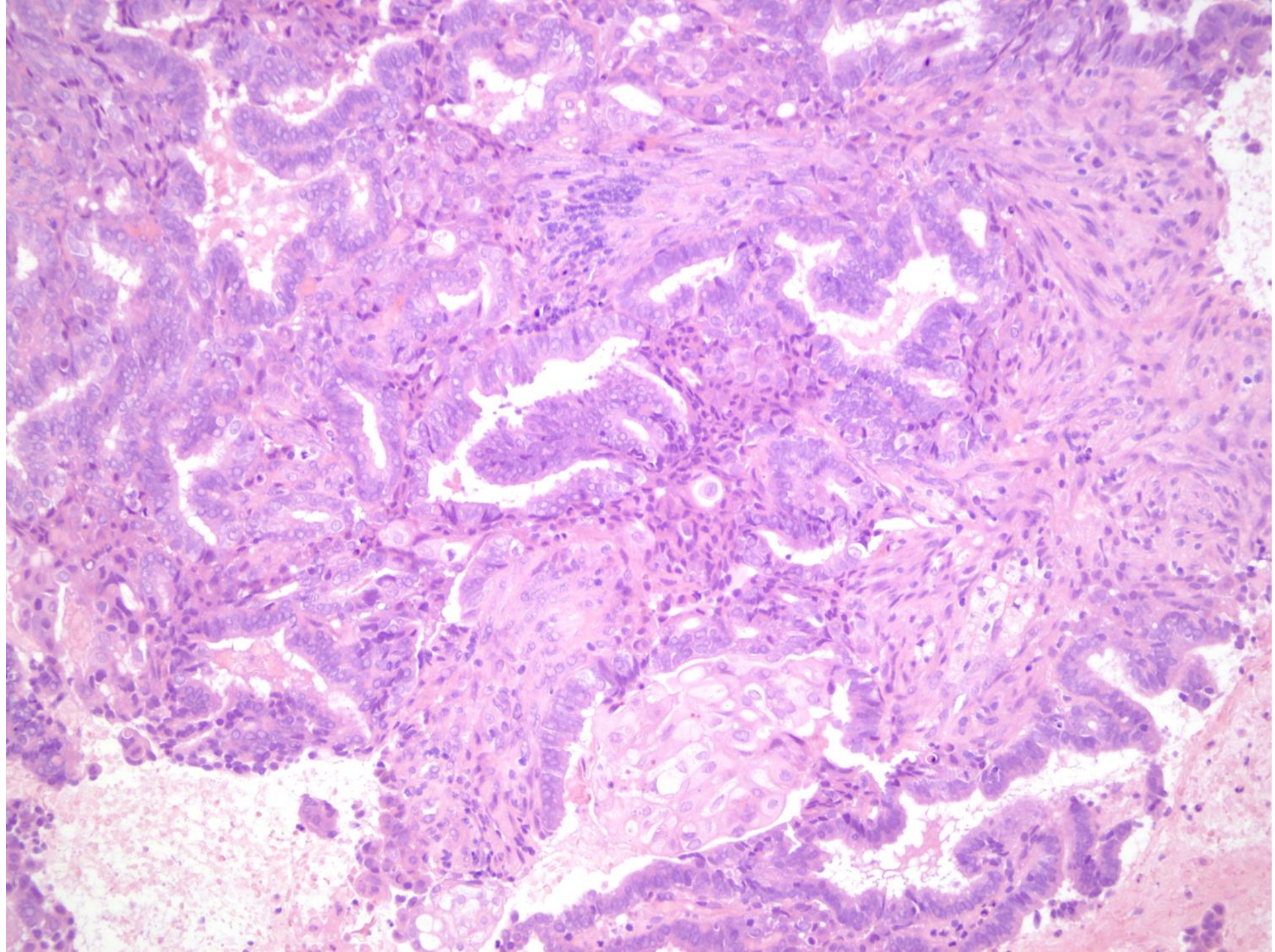

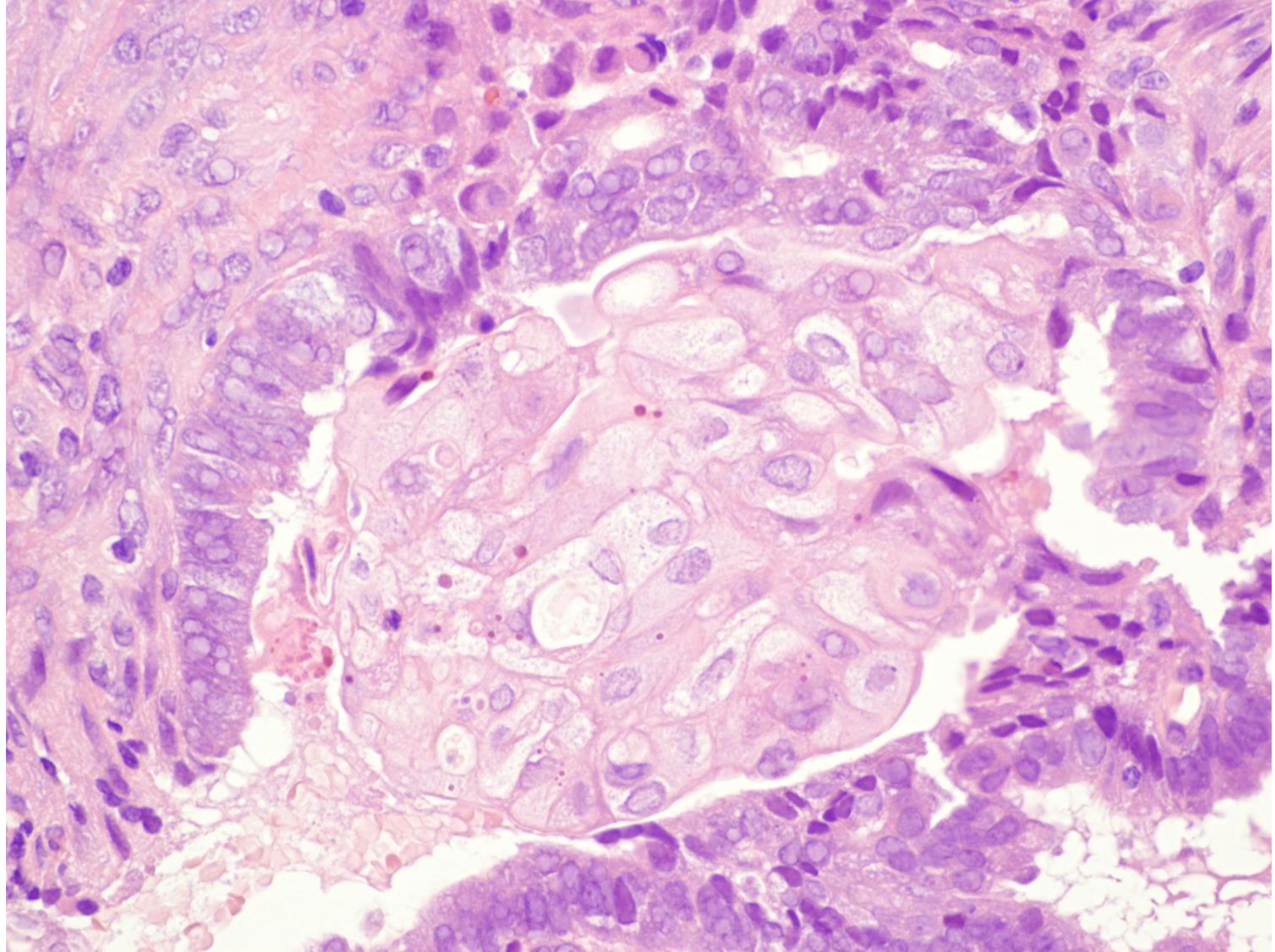

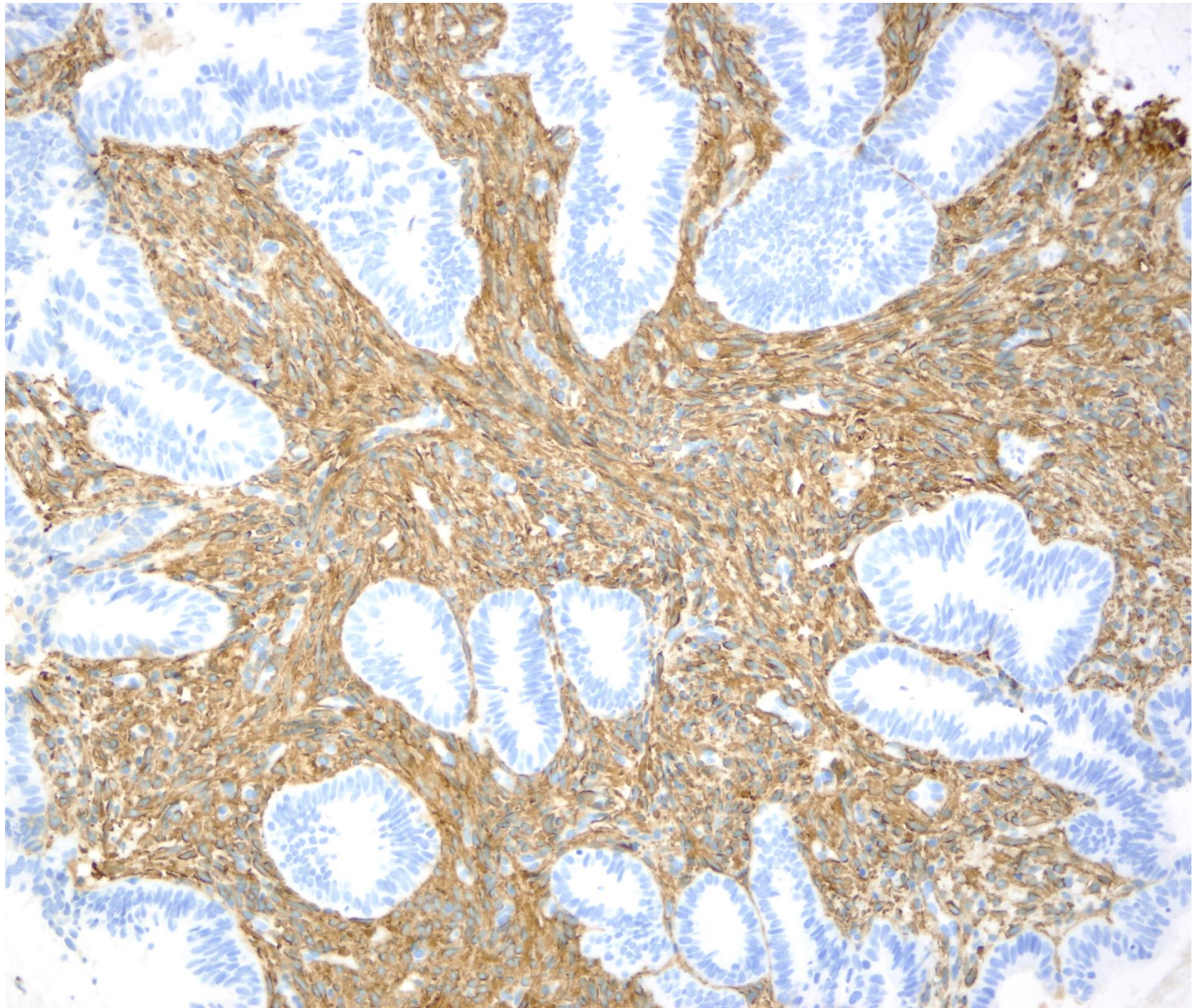

SMA

H-Caldesmon

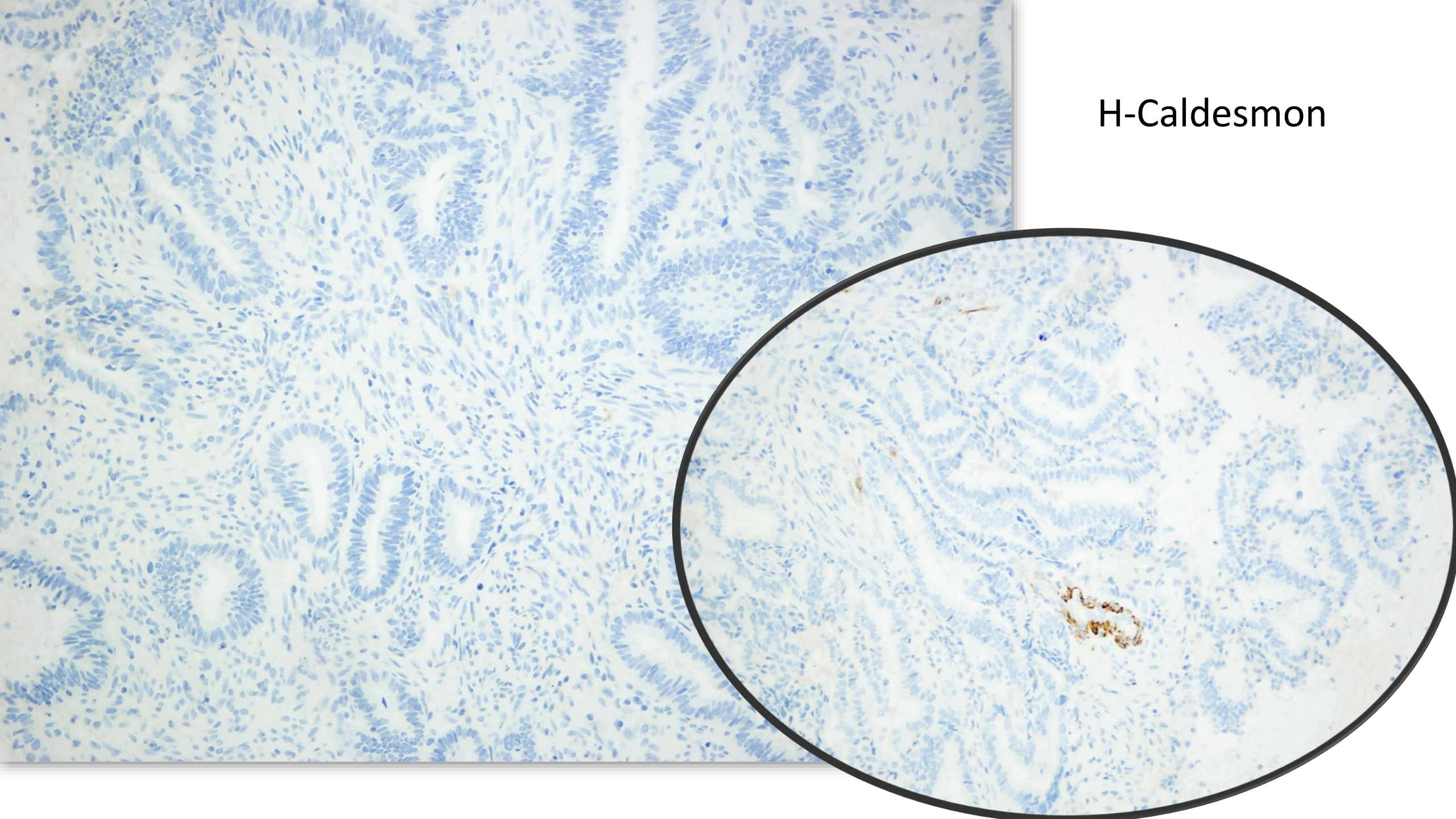

Histopathology report- Conclusions

- Most probable diagnosis: **Atypical polypoid adenomyoma**
- Increased risk of associated endometrial cancer
- Imaging studies advised

Clinical follow up

- Pregnancies: 3- 2 live births, 1 atificial abortion
- Hight: 162 cm Weight: 107 kg BMI: 40.8
- Other diseases: HT, DM T2, Hypothyreoidism, DVT and PE, IHD, depression and anxiety, anemia, coxarthrosis, gonarthrosis
- Menstrual cycles : irregular
- Surgeries: umbilical hernioplasty
- **CT scan** : widespread malignancy of the uterus with peritoneal involvement (pelvis and umbilical hernial sac), local spread to pelvic organs, cyst within the right ovary

Surgery

- Explorative laparotomy
- Widespread pelvic endometriosis
- Total hysterectomy and BSO
- Urinary bladder wall and umbilical hernial sac: endometriotic nodule removal


8775

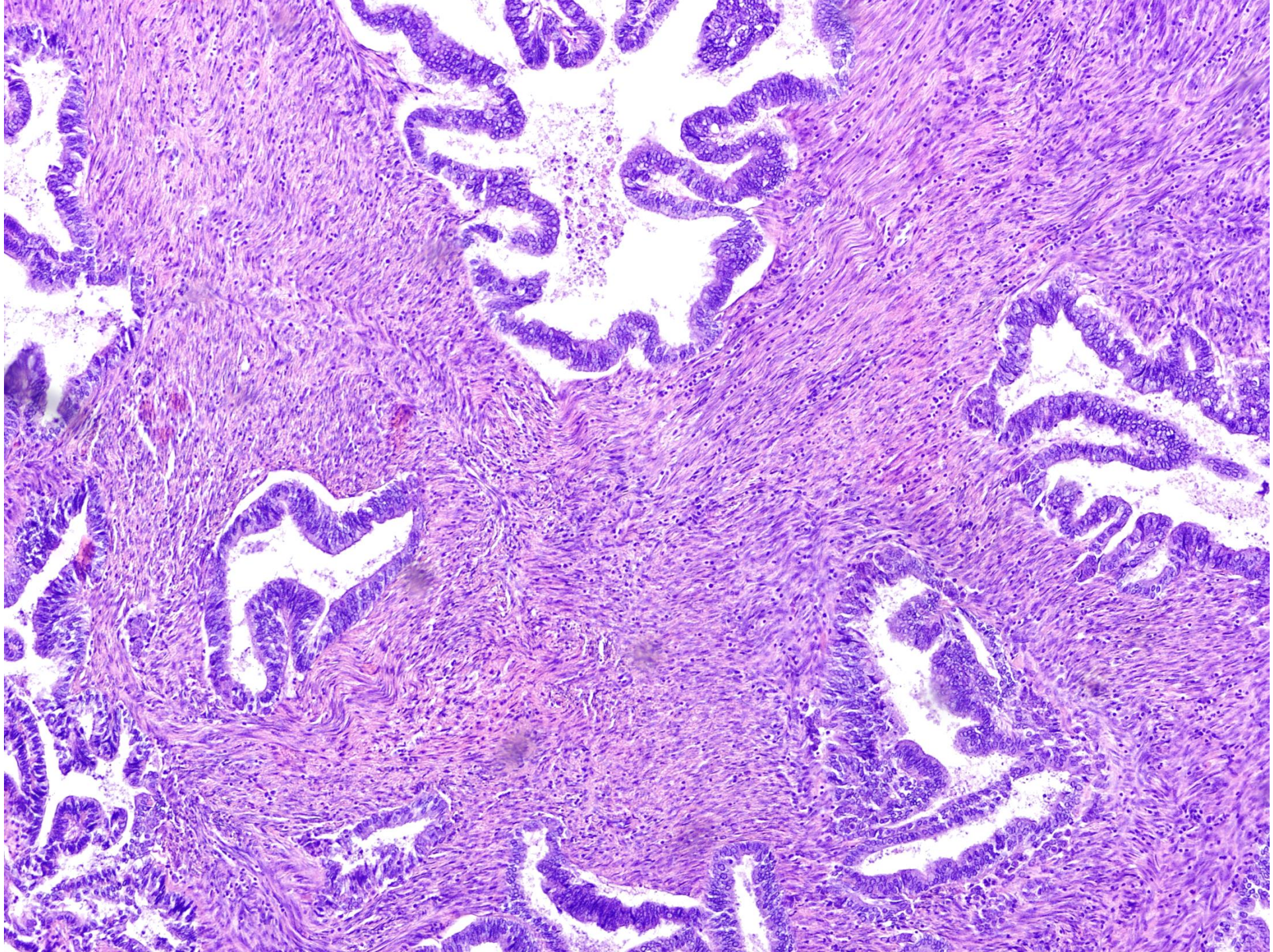

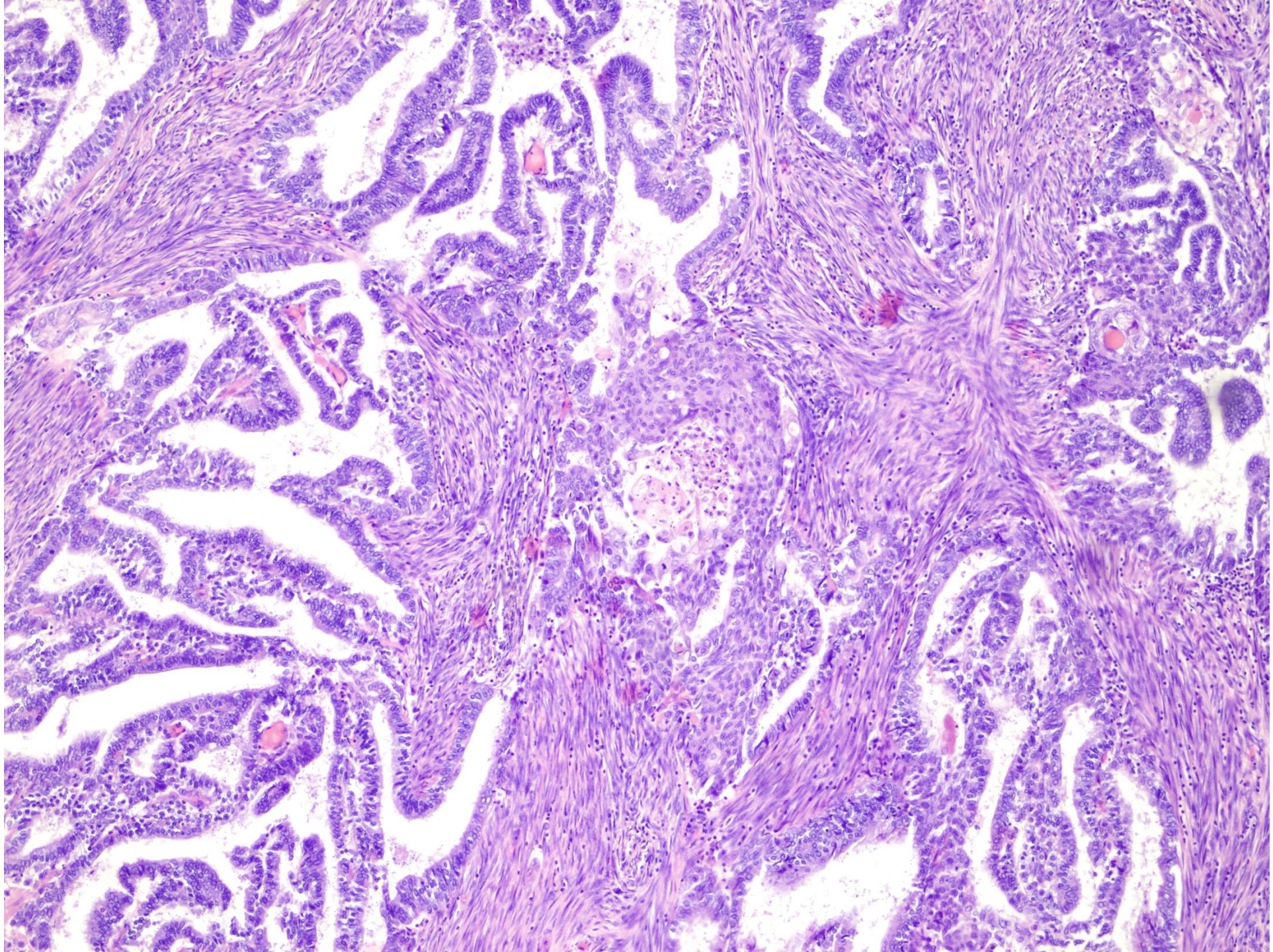

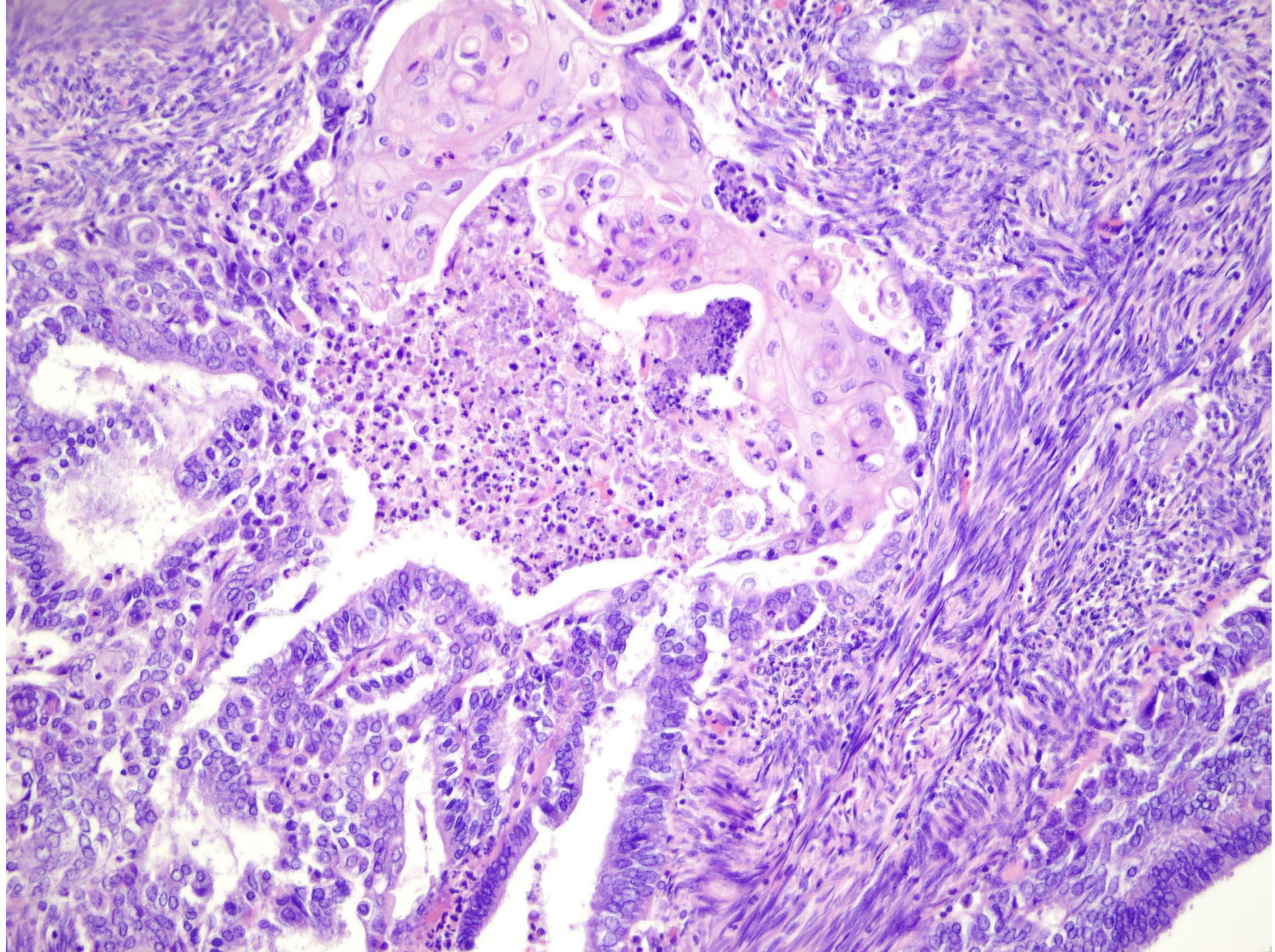

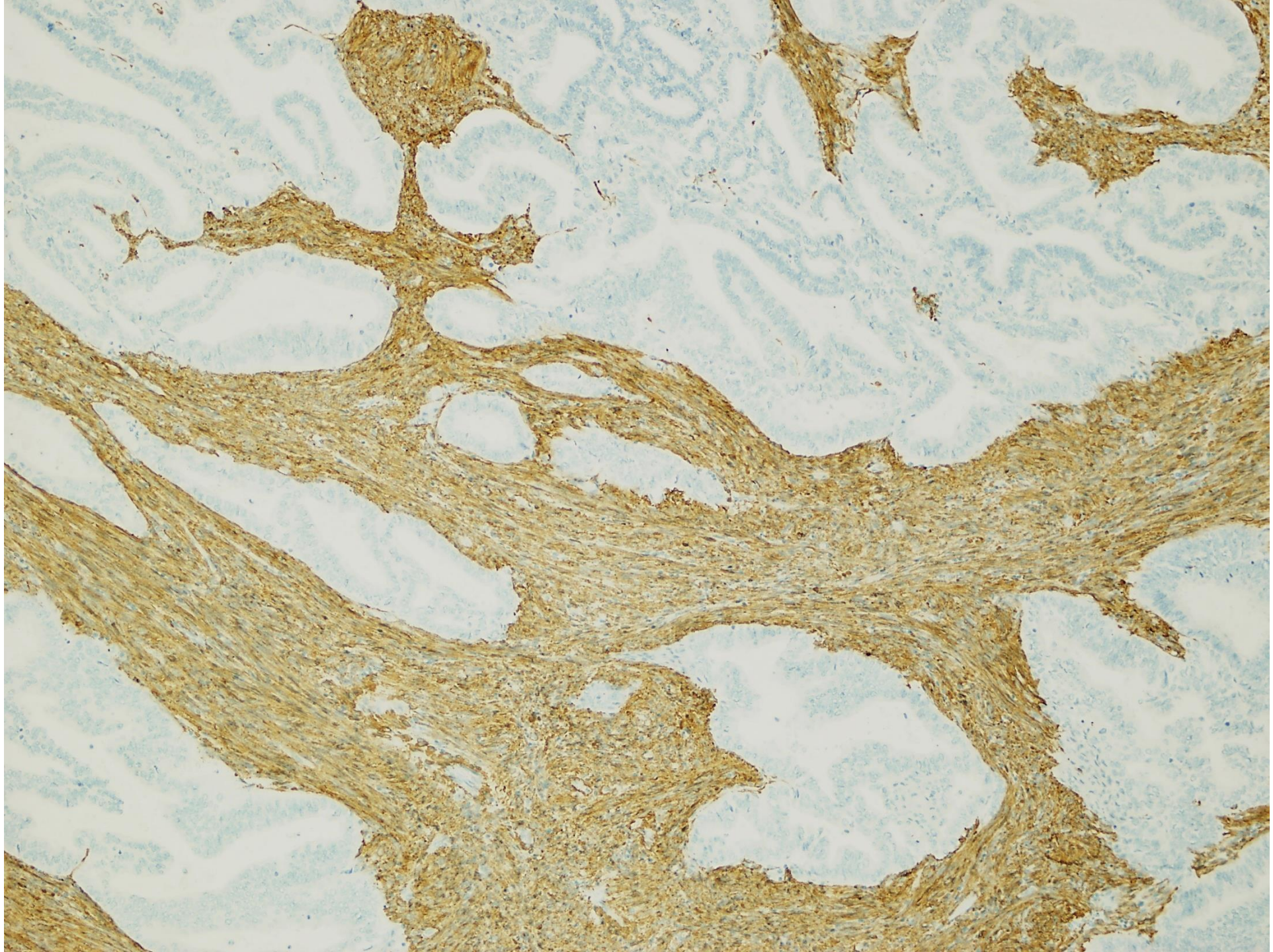

SMA

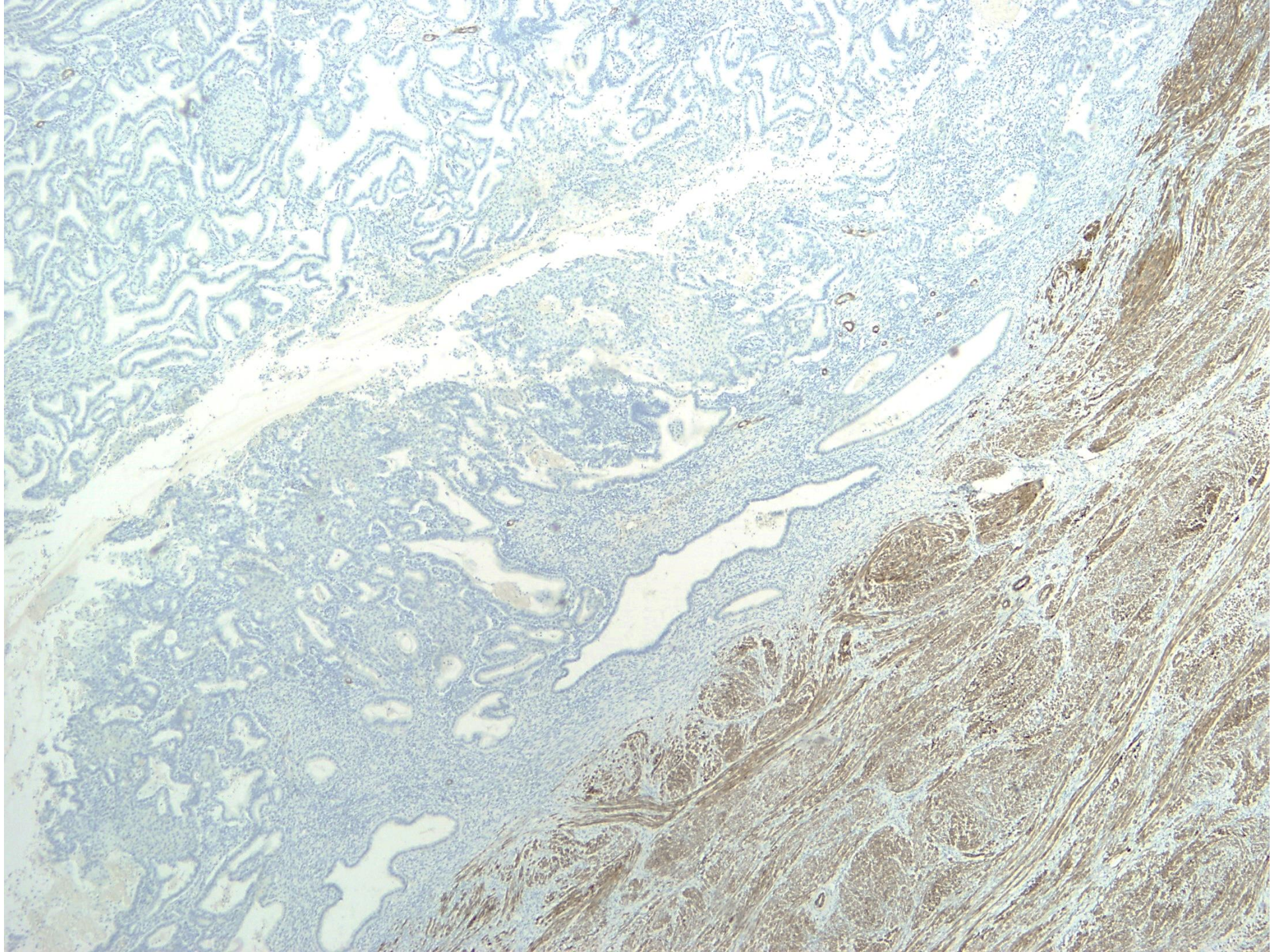

HCALD

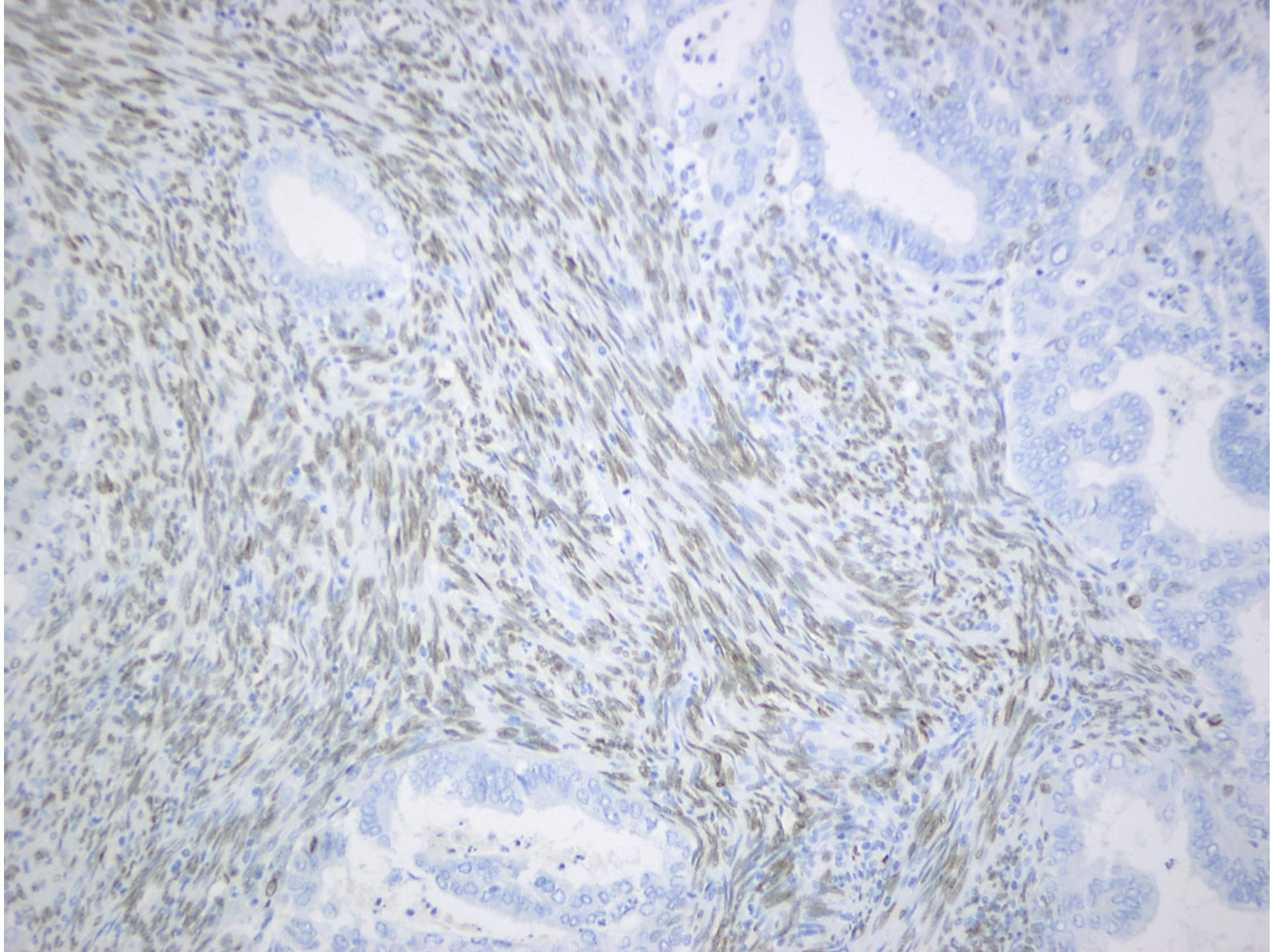

satb2

Atypical polypoid adenomyoma

Atypical polypoid adenomyoma

- 1981. Mazur
- WHO 4th Edition- Uterine mixed epithelial and mesenchymal tumors
- Pre-or perimenopausal women
- Lower uterine segment (or the fundus)
- Nulliparity, infertility, obesity-risk factors
- Usually solitary, multi-polypoid occasionally
- Biphasic polyp
- Glands-like in atypical hyperplasia
- Stroma: myofibroblasts (SMA+, H-Caldesmon-) Adenomyofibroma
- Squamous morules- Central non-keratinizing nests with necrosis occasionally
- Risk of recurrence
- Estimated risk of endometrial cancer: 10 %
- Reported coexistence with endometrioid carcinoma: 17-28%

Molecular background

- Atypical Polypoid Adenomyoma of the Uterus An Immunohistochemical and Molecular Study of 21 Cases

Němejcová K, Kenny SL, Laco J, Škapa P, Staněk L, Zikán M, Kleiblová P, McCluggage WG, Dundr P. Am J Surg Pathol. 2015 Aug;39(8):1148-55.

- MLH-1 promoter hypermethylation
- PTEN and KRAS mutations
- microsatellite instability
- findings like in endometrial atypical hyperplasia and endometrioid carcinoma
- APA may be a localized form of atypical hyperplasia

SATB2

International Journal of Gynecological Pathology
00:1–7, Lippincott Williams & Wilkins, Baltimore
Copyright © 2018 by the International Society of Gynecological Pathologists

Original Article

SATB2 is Consistently Expressed in Squamous Morules Associated With Endometrioid Proliferative Lesions and in the Stroma of Atypical Polypoid Adenomyoma

W. Glenn McCluggage, F.R.C.Path and Koen Van de Vijver, Ph.D.

- SATB2 (special AT-rich sequence-binding protein 2)- transcription factor and epigenetic regulator
- NON-neoplastic positive: glandular cells of the lower GI
- Neoplastic positive:
  - CRC (78-85%)
  - upper GI adenocarcinomas (11,5%),
  - primary ovarian mucinous neoplasms (1,7%),
  - hindgut well-differentiated neuroendocrine tumor
  - Female genital tract
    - metastatic CRC within ovaries (75%)
    - metastatic low-grade appendiceal mucinous neoplasms (80%) within ovaries
    - metastatic high grade appendiceal adenocarcinomas (100%) within ovaries
- Neoplastic negative:
  - ovarian metastases of pancreatic, gastric, gallbladder and endocervical origin
- Squamous morules- at least focal nuclear SATB2 positivity (B-catenin, p16, CD10, CDX2 +, p63-)
- APA stromal cells nuclear SATB2 positivity
- Endometrioid polyps, adenomyomas/ adenomyomatous polyps, adenosarcomas- SATB2 negative stroma

Differential diagnosis

- Atypical hyperplasia
- Endometrial endometrioid carcinoma
- Adenosarcoma
- Endometrial polyp
- Polypoid adenomyoma/ adenomyomatous polyp

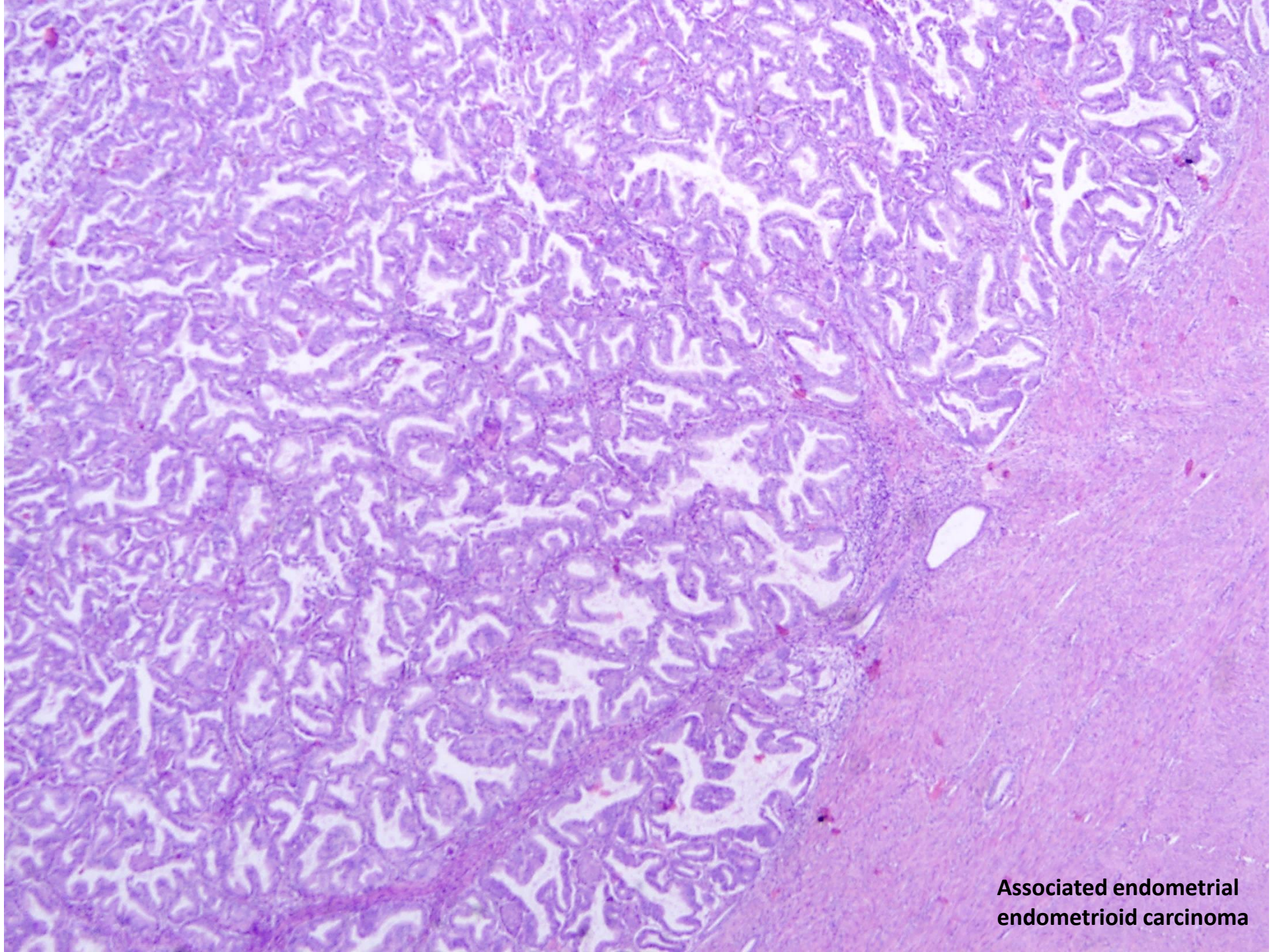
Associated endometrial
endometrioid carcinoma

Diagnosis

- Atypical polypoid adenomyoma with associated atypical hyperplasia and Grade 1 endometrial endometrioid carcinoma, pT1a
- Endometriotic cyst within the ovaries
- Endometriosis of urinary bladder
- Endometriosis within umbilical hernial sac

Highlights

- APA is most probably a localized form of atypical hyperplasia
- SATB2 + in APA stromal cells and focally + in squamous morules



István Szőnyi (1894-1960)
Dunakanyar Zebegénynél
(Danube bend at Zebegény)
1927

(Oil, canvas, 120x 100 cm)
Private collection