Robust expression of EZH2 in endocervical neoplastic lesions

[1]Evelin Makk, [1]Levente Bálint, [2]János Cifra, [1]Tamás Tornóczky, [1]Angéla Oszter, [3]Arnold Tóth, [1]Endre Kálmán, [1]Krisztina Kovács

[1]Department of Pathology, University of Pécs Medical School, Hungary
[2]Department of Pathology, County Hospital Tolna, János Balassa Hospital, Szekszárd, Hungary
[3]Department of Radiology, University of Pécs Medical School, Hungary

TECHNOLOGY TRANSFER IN DIAGNOSTIC PATHOLOGY
10TH CENTRAL EUROPEAN REGIONAL MEETING
Gynecological Pathology
ORGANIZED BY THE HUNGARIAN DIVISION OF THE INTERNATIONAL ACADEMY OF PATHOLOGY
CO-SPONSORED BY ISGyP



Visegrád, June 27-29, 2019

PÉCSI TUDOMÁNYEGYETEM
UNIVERSITY OF PÉCS

Introduction

- Enhancer of zeste homolog 2 (**EZH2**) plays a critical role in epigenetic gene silencing and chromatin remodeling, inhibits cell differentiation and targets gene expression [1].

- Recent studies focused on the role of EZH2 in the pathogenesis of various malignancies.

- High expression of EZH2 was shown to be associated with tumor aggressiveness and was suggested as a potential differential diagnostic marker in various malignancies**.**

- In the cervix, one study reported overexpression and the possible prognostic significance of EZH2 in **squamous cell carcinoma** [2].

- The aim of this study was to evaluate the nuclear expression of EZH2 in invasive endocervical adenocarcinoma (ECA) and cervical *in situ* adenocarcinoma (AIS) in comparison with normal endocervix and non-neoplastic counterparts.

1. Zhang HM, Chen SQ, Yao SZ (2016) Expression and clinical implications of enhancer of Zeste homolog 2 and p53 protein in squamous cell carcinoma and precancerous lesions in the cervix. Genet Mol Res 15(2).
2. Jin M, Yang Z, Ye W, Yu X, Hua X (2015) Prognostic significance of histone methyltransferase enhancer of zeste homolog 2 in patients with cervical squamous cell carcinoma. Oncol Lett 10(2):857–862.

Methods

- A total of **54** consecutive **neoplastic cases** (37 ECA, 17 AIS) and **32 non-neoplastic endocervical lesions** (15 reactive atypia, 9 microglandular hyperplasia, 3 tuboendometrioid metaplasia, 3 tunnel cluster, 2 endometriosis) were included in the study with adjacent normal endocervix if present.

- EZH2 immunoreactivity was evaluated semiquantitatively by three independent experts in lesions and adjacent normal glandular epithelium as well.

- Cases were regarded positive if they were obviously positive by 40X magnification and further classified according to the percentage of cells with **nuclear staining: <10% as focally positive "+", 10-50% as partly positive "++" and >50% as diffusely positive "+++".**

- EZH2 expression was defined robust if at least two of the three experts rated partial or diffuse positivity.

Robust EZH2 expression was statistically compared using **Fisher's exact test (MedCalc)** [3] among the neoplastic, non-neoplastic and normal glandular epithelium samples. A p value below 0.05 was regarded significant. Diagnostic test capability (sensitivity and specificity) of robust EZH2 expression was calculated.

Results 1 – neoplastic cases

53 out of the 54 neoplastic cases (98%) showed robust EZH2 expression. Figure 1. shows representative cases of diffuse (robust) EZH2 immunoreactivity of the neoplastic endocervical lesions (ECA and AIS) and negative immunoreactivity of the adjacent normal glandular epithelium.

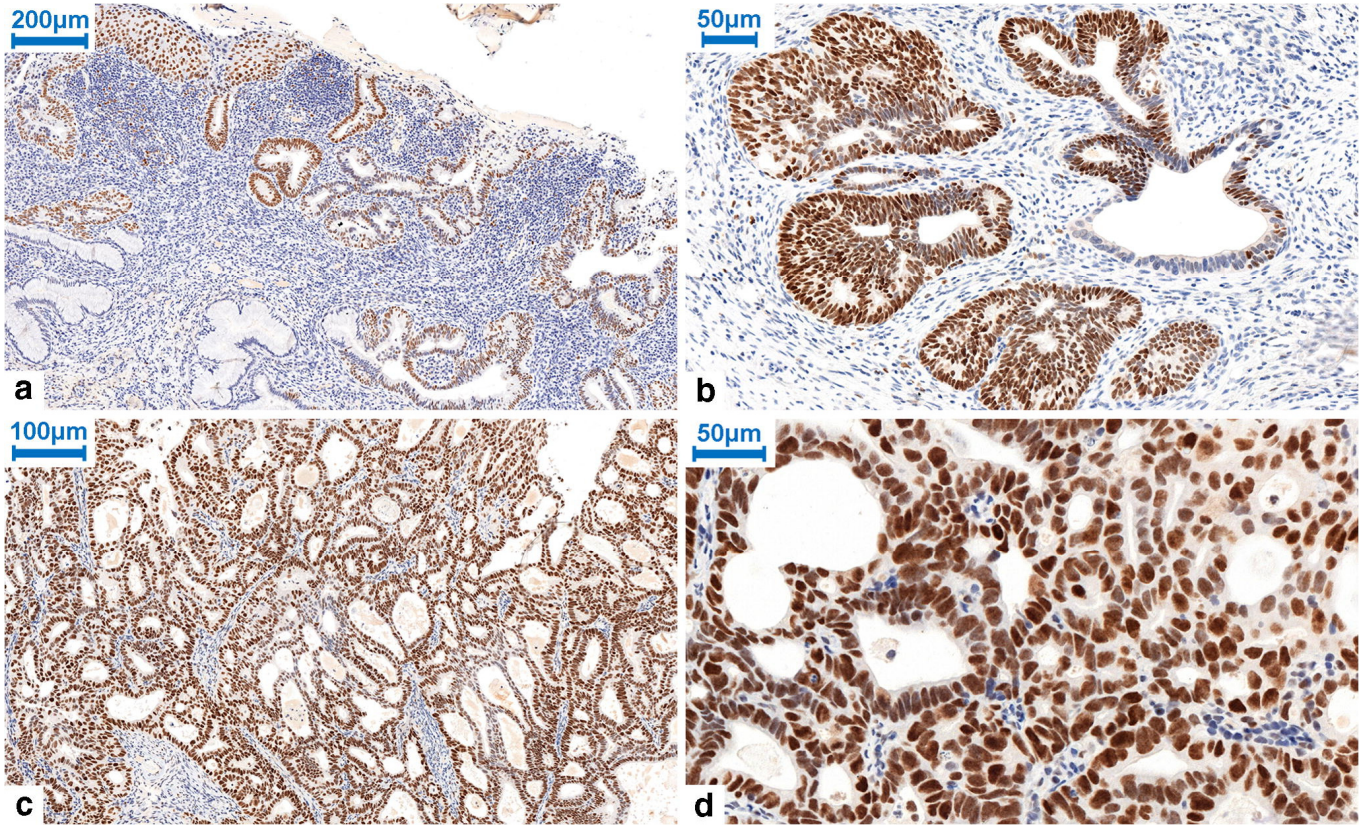

Fig. 1 EZH2 nuclear expression in CIN, AIS, and ECA a. Diffuse positive (robust) expression of EZH2 in CIN3 and AIS, negative staining of EZH2 in normal endocervical glandules (100X). b. Diffuse positive (robust) expression of EZH2 in AIS (300X). c-d. Diffuse positive (robust) nuclear expression of EZH2 in ECA (200X and 400X).

Results 2 – non - neoplastic cases

Robust EZH2 expression was significantly less often (4 out of 32 cases, 12.5%) found in the non-neoplastic endocervical lesions (p<0.0001) and never (0 out of 66 samples) in the adjacent normal glandular epithelium. **Fig. 2-3** shows representative cases of negative or focally positive (+) EZH2 immunoreactivity of the non-neoplastic lesions.

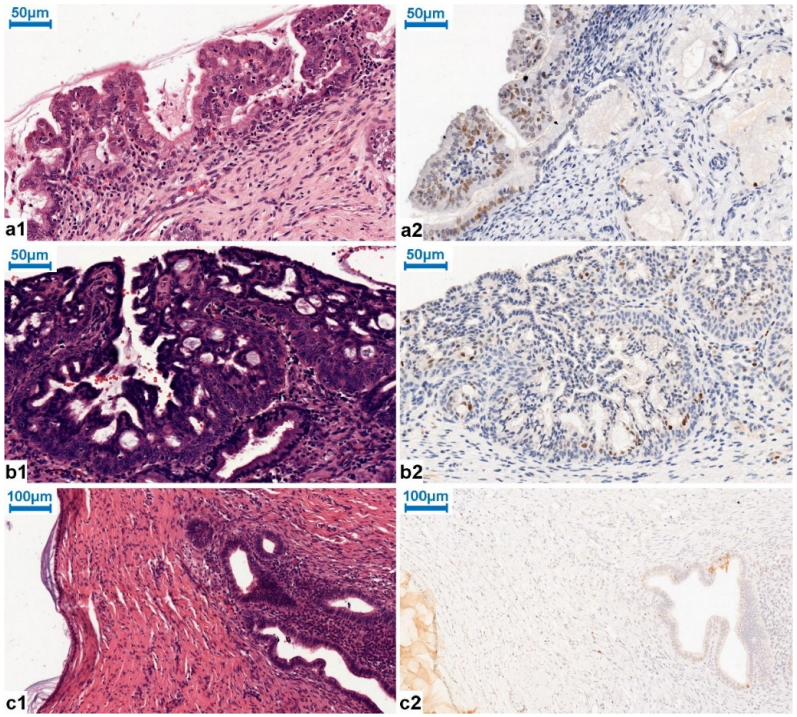

Fig. 2 Reactive atypia, microglandular hyperplasia, and endometriosis with HE a1, b1 (400X), c1 (200X). a2. EZH2 focal positivity in reactive atypia (400X). b2. No expression of EZH2 in microglandular hyperplasia, EZH2 focal positivity in squamous metaplasia (400X). c2. Negative staining of EZH2 in endometriosis (200X).

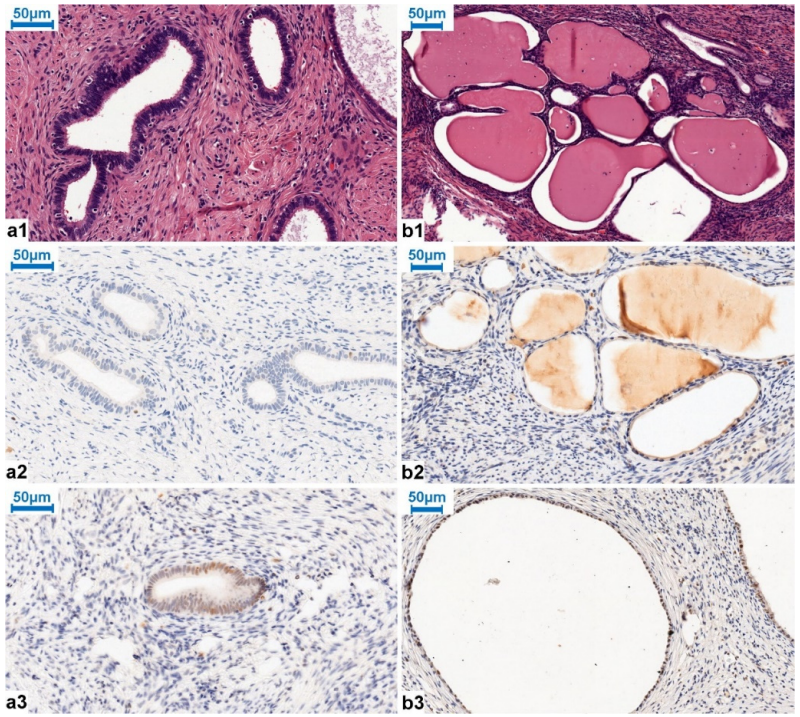

Fig. 3 Tuboendometrioid metaplasia (TEM) and tunnel cluster with HE a1, b1. (a1, 400X; b1, 300X). a2. EZH2 negative staining in TEM (400X). a3. Partly positive (robust) expression (++) of EZH2 in another sample with TEM (400X). b2. EZH2 negativity in tunnel cluster (300X). b3. Partly positive (robust) expression (++) of EZH2 in another case of tunnel cluster (300X).

Results 3 – diagnostic capability

Robust EZH2 expression had a sensitivity and specificity of over 95% in detecting neoplastic lesions versus non-neoplastic lesions or normal glandular epithelium.

Conclusion

EZH2 may play a role in the pathogenesis of endocervical neoplasia, and the **detection of robust expression of EZH2 might be a useful differential diagnostic tool** in problematic endocervical lesions in histology and cytology as well.

Acknowledgements

The authors gratefully acknowledge the Immunopathology Laboratory, Department of Pathology, University of Pécs and for their technical assistance. The present scientific certification is dedicated to the 650th anniversary of the foundation of the University of Pécs, Hungary.

Please find more details in:
Virchows Arch. 2019 Mar 22. doi: 10.1007/s00428-019-02550-8