Giant condyloma of the uterus – case report

Dóra Hargitai[1], Eszter Szabó[2], Róbert Koiss[2], Edit Babarczi[2], Áron Somorácz[1,2]

[1]SE 2nd Department of Pathology, Budapest, Hungary
[2]South-Pest Hospital Centre – National Institute for Infectology and Haematology

Clinical history

- 54-year-old woman
- exophytic lesion on the cervix of the uterus
- histological examination of the biopsy suggested verrucous carcinoma
- PET-CT showed pathological FDG accumulation in the uterus
- oncoteam proposed radical Wertheim hysterectomy due to IB2 stage squamous cell carcinoma

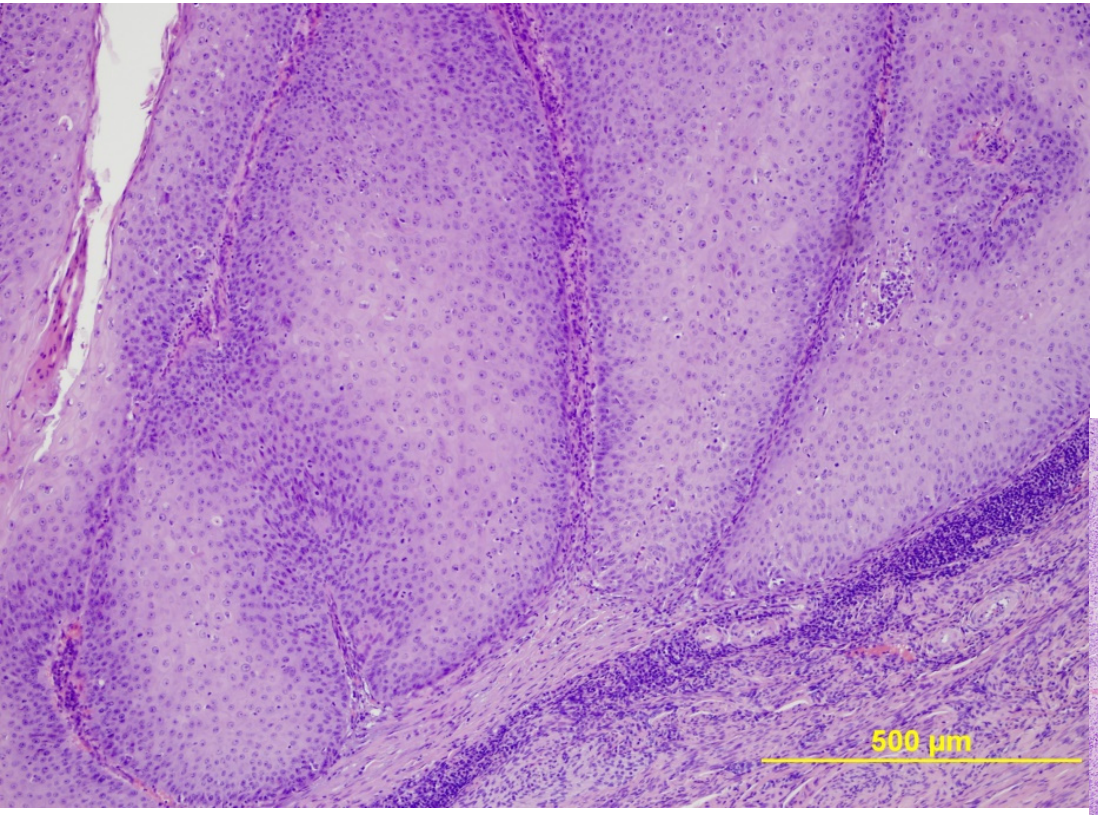

Exocervix

Uterine cavity

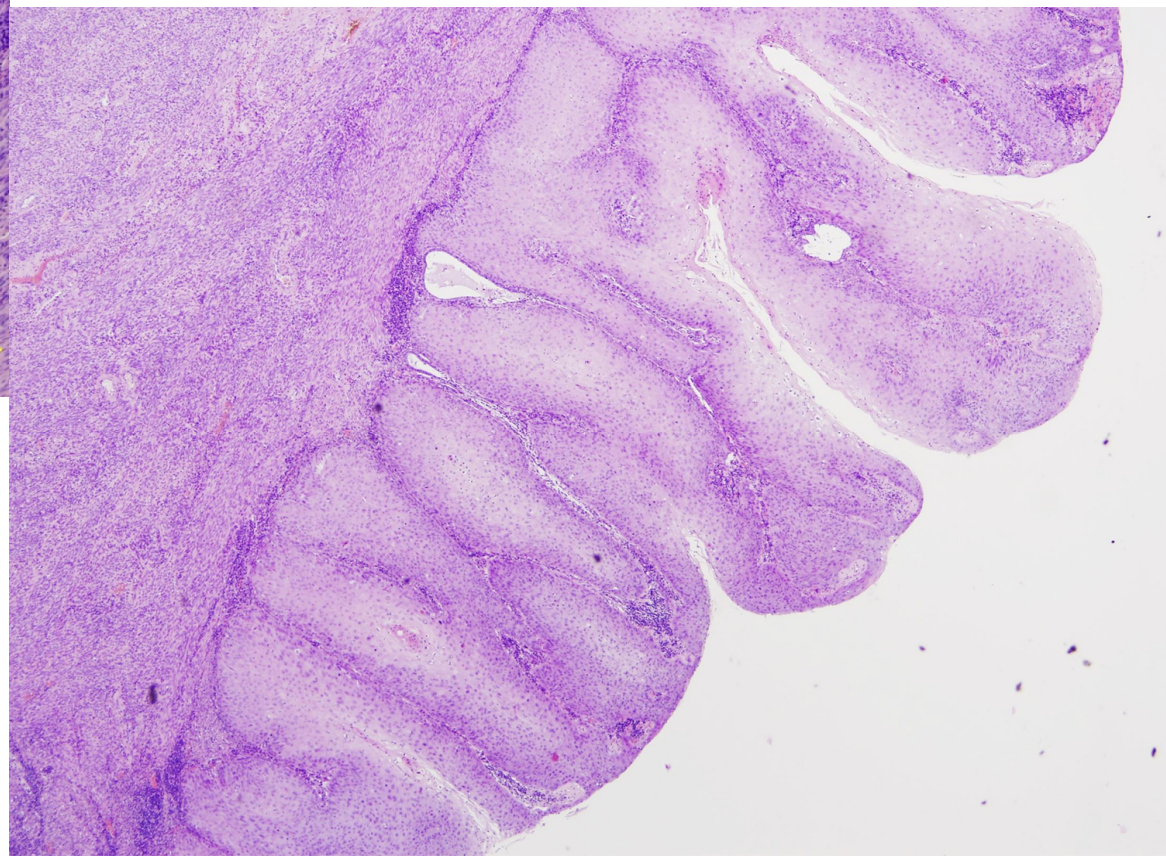

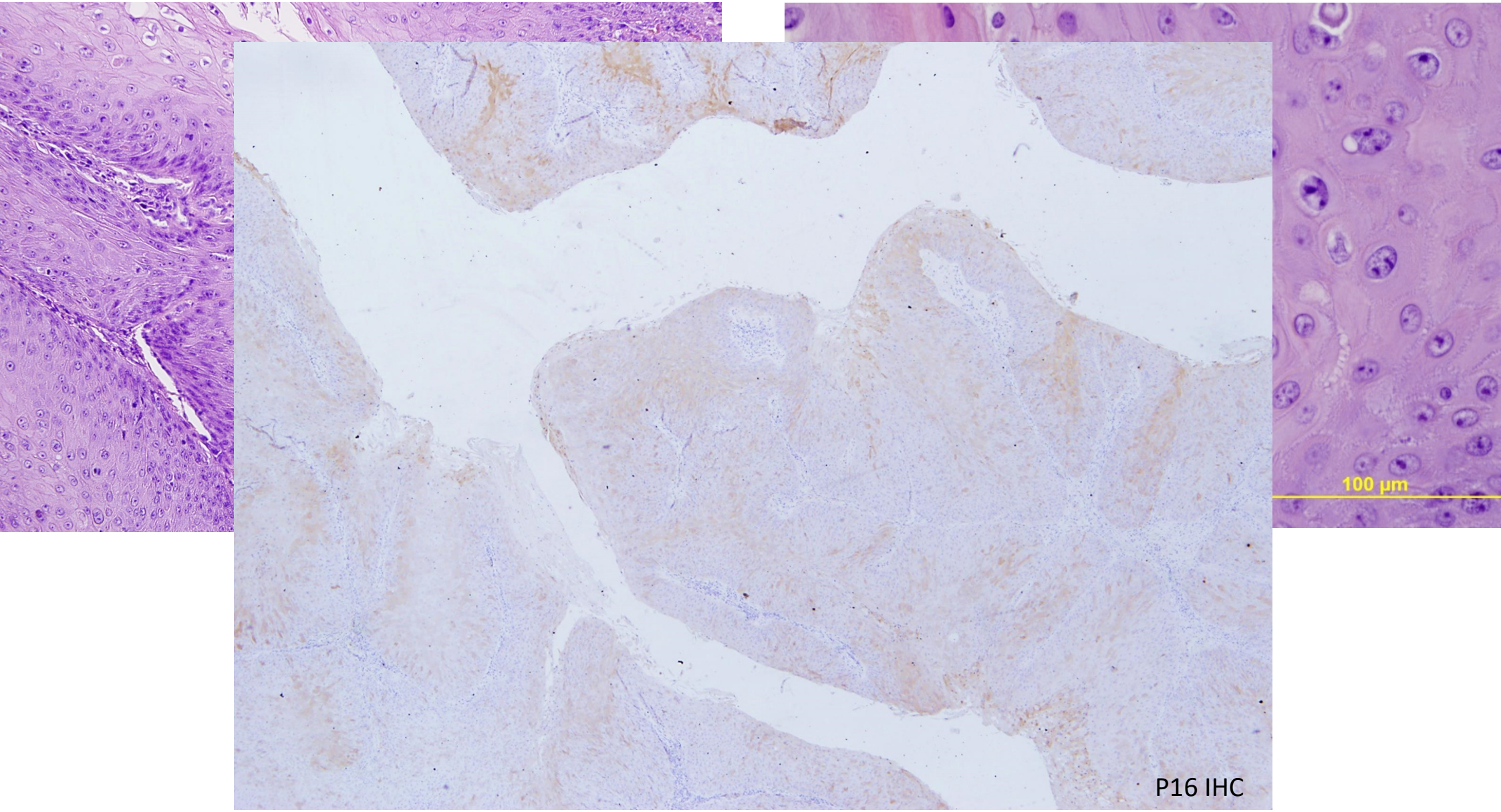
100 µm
P16 IHC

Diagnosis

- **Giant condyloma of the uterus**
- Differential diagnosis:
  - verrucosus carcinoma
  - papillary immature metaplasia