Morphological features of uterine leiomyomas with bizarre nuclei

András Rókusz, Katalin Dezső, Zoltán Sápi

Ist Department of Pathology and Experimental Cancer Research, Semmelweis University, Budapest, Hungary

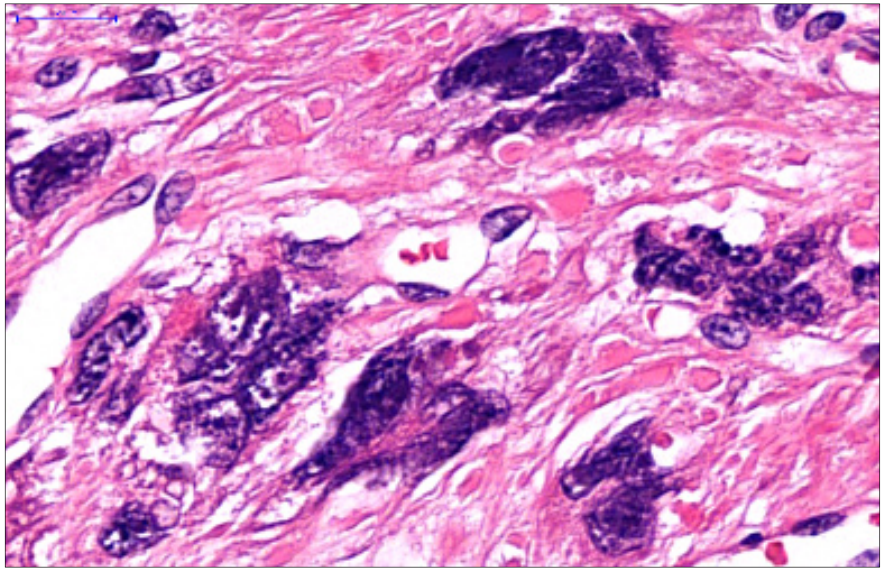

- 37-52% of leiomyomas with bizarre nuclei show loss of fumarate-hydratase (FH) activity when examined with IHC
- A subset of these tumors harbour FH mutations
- Heterozygous germline FH mutation cause HLRCC (hereditary leiomyomatosis and renal cell carcinoma syndrome)
- In women affected by HLRCC symptomatic uterine leiomyomas develop in a young age, a decade earlier than renal cell carcinoma
- Different morphological signs have been described that are suggestive for FH loss

Low-

-increa

-stagh

-alveol

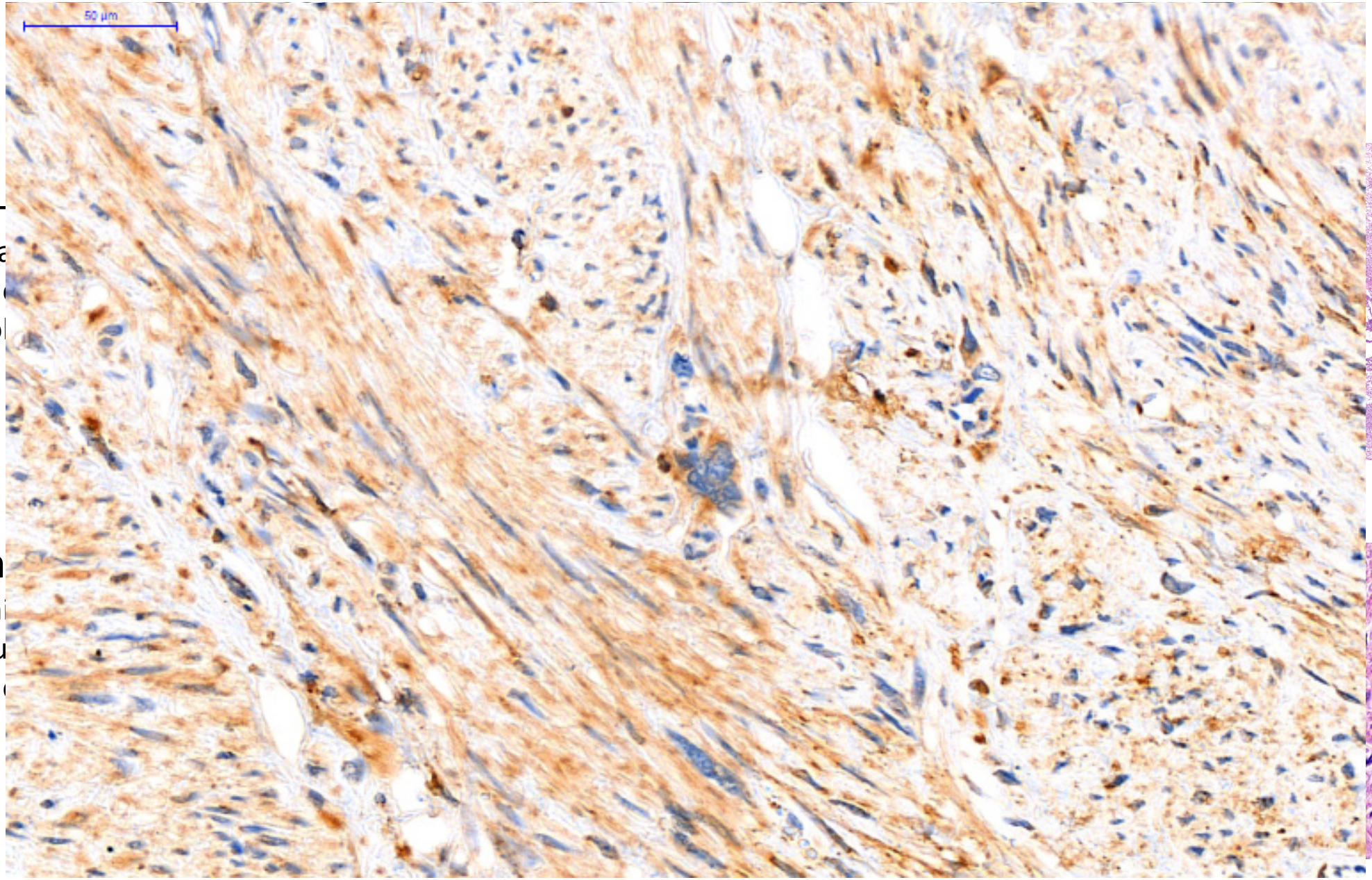

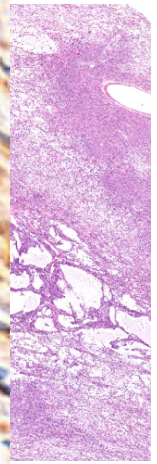

High

-promi

perinu

-eosin

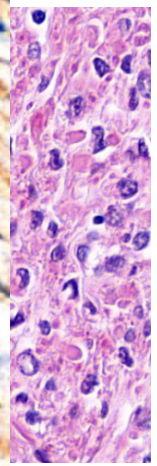

No.	Age	Distribution of bizarre nuclei	Mitoses/ 10 HPF	FH IHC	Increased cellularity	Staghorn vessels	Alveolar edema	Macronucleoli with perinucleolar halo	Eosinophilic cytoplasmic inclusions
1	61	diffuse	1	-	+	+	-	+	+
2	29	scattered	1-2	-	+	+	+	+	+
3	49	diffuse	1	-	+	+	-	+	+
4	31	scattered	0	-	+	+	+	+	+
5	37	scattered	0-1	-	+	+	+	+	+
6	35	scattered	1-2	-	+	+	+	+	-
7	46	scattered	0	+	+	+	+	-	-
8	23	scattered	2-3	-	+	+	+	+	+
9	50	nodular	0-1	n/a	+	+	+	+	+
					9/9	9/9	7/9	8/9	7/9

- Complete loss of FH in the tumor cells on IHC is a strong indicator of FH mutation in the tumor, but the majority of FH-mutant leiomyomas are sporadic and harbour somatic mutations.

- It's important to recognise morphological features of FH-deficiency in leiomyomas with bizarre nuclei to identify patients who will benefit from FH genetic testing to identify possible HLRCC (hereditary leiomyomatosis and renal cell carcinoma syndrome).

- Genetic testing is recommended if the tumor cells show complete loss of FH in a young patient (under 30 years of age), especially if a family history of cutaneous leiomyomas or renal cell carcinoma exist

- FH IHC can be helpful to differentiate leiomyoma with bizarre nuclei from leiomyosarcoma, since as far as we know uterine leiomyosarcomas are not associated with FH mutations.

Thank you for your attention!