



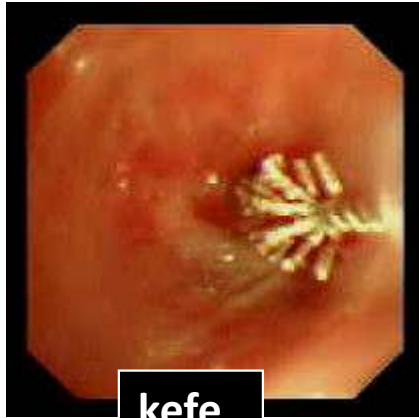A légzőrendszer citológiája

Pápay Judit
SE, I. sz. Patológiai és Kísérleti Rákkutató Intézet
Budapest

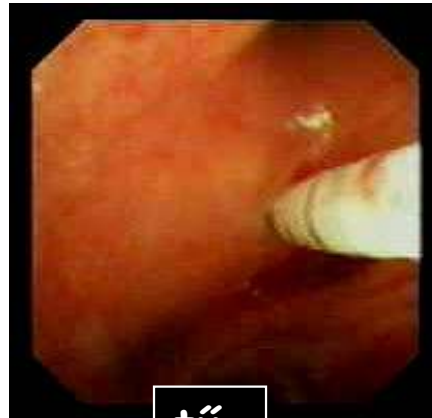XII. Cytologus Kongresszus
Balatonalmádi, 2013. június 7-9.

A mintavétel

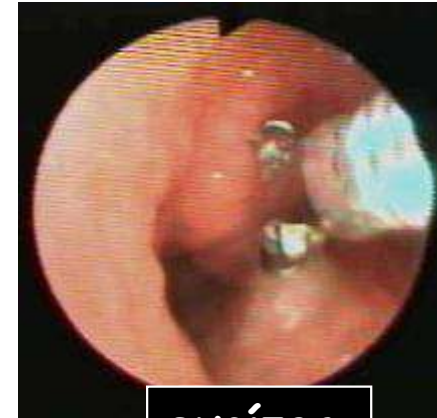
bronchoszkópos



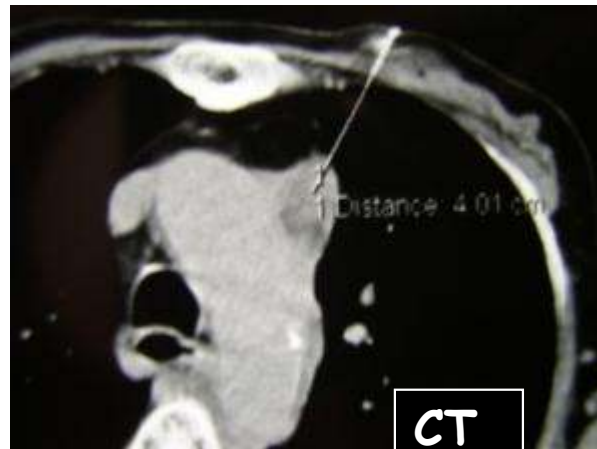
kefe



tű

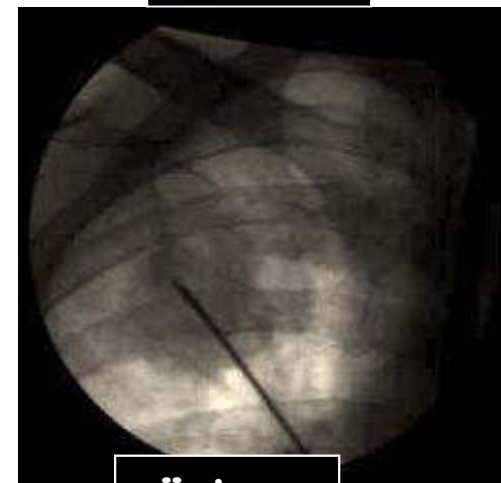


excízor



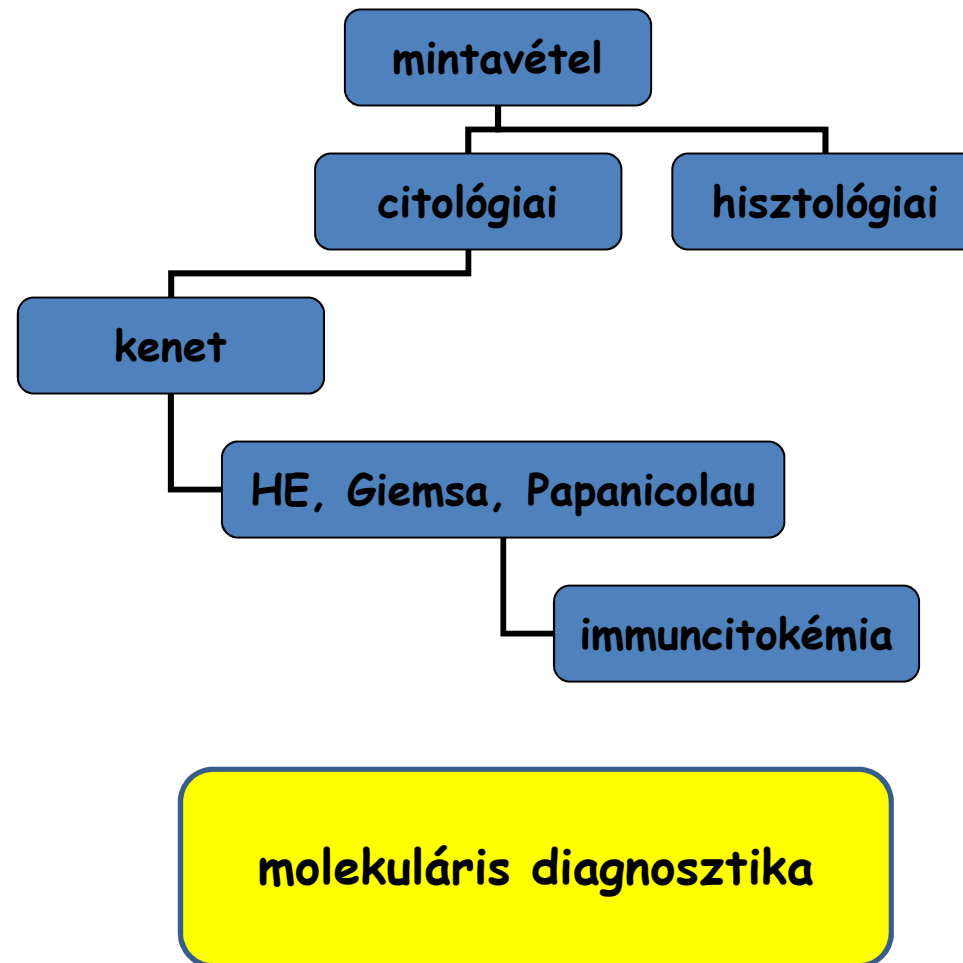
CT

kontroll



röntgen

A feldolgozás



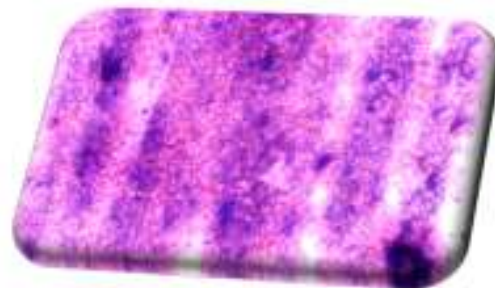
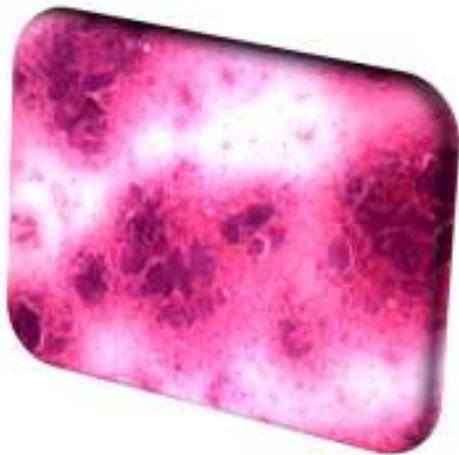
Buktatók és utánzó/hasonló elváltozások

Adenocarcinoma

Laphámrák

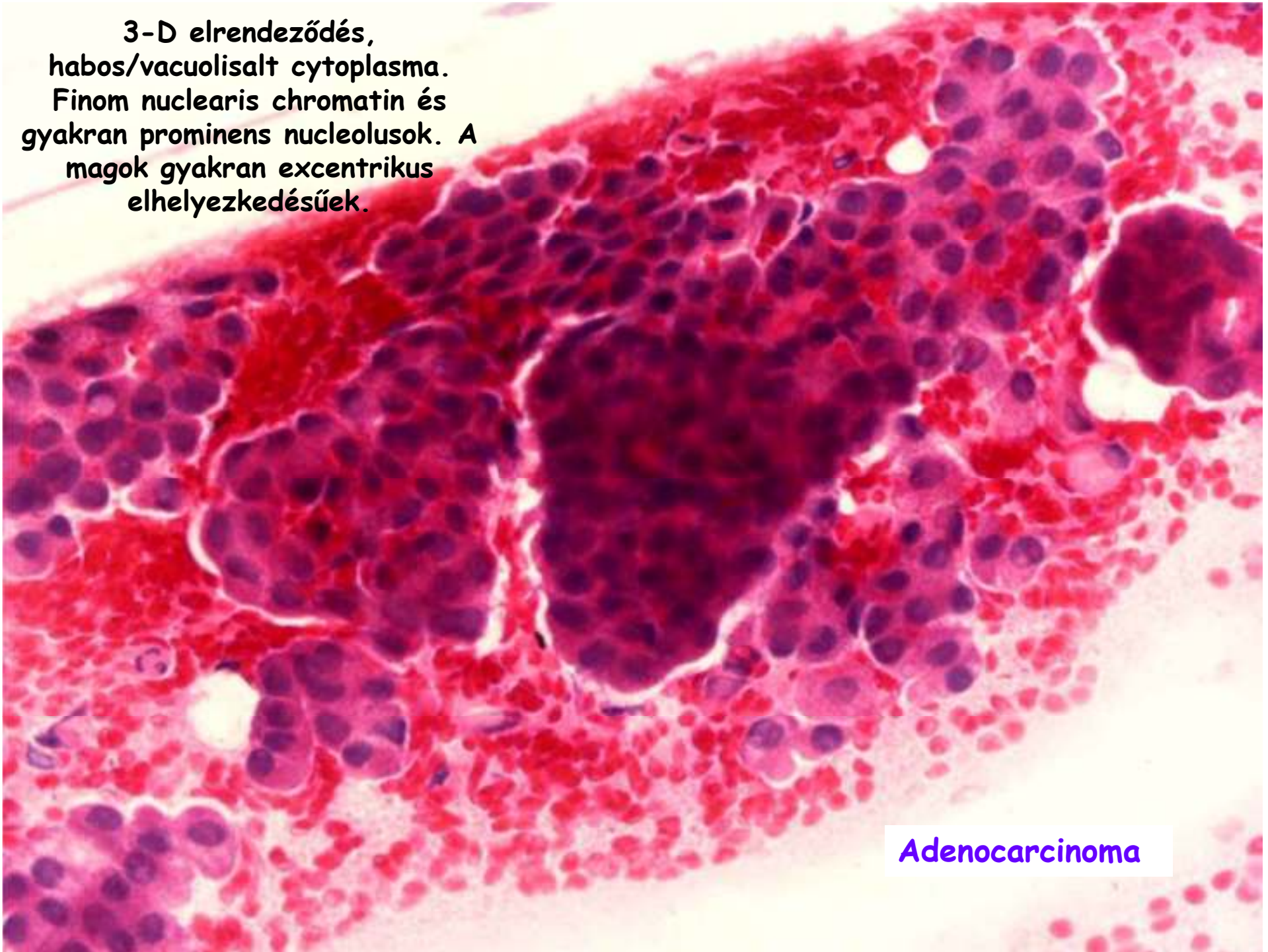
Kissejtes carcinoma

HE



3-D elrendeződés,
habos/vacuolisált cytoplasma.
Finom nuclearis chromatin és
gyakran prominens nucleolusok. A
magok gyakran excentrikus
elhelyezkedésűek.

Adenocarcinoma



Adenocarcinoma (ADC)

1. Reaktív II típusú pneumocyták

(BAL, TTP, bronchusmosás)

A II típusú pneumocyták viszonylag kisméretűek, elszórtan vagy laza kötelékekben láthatók.

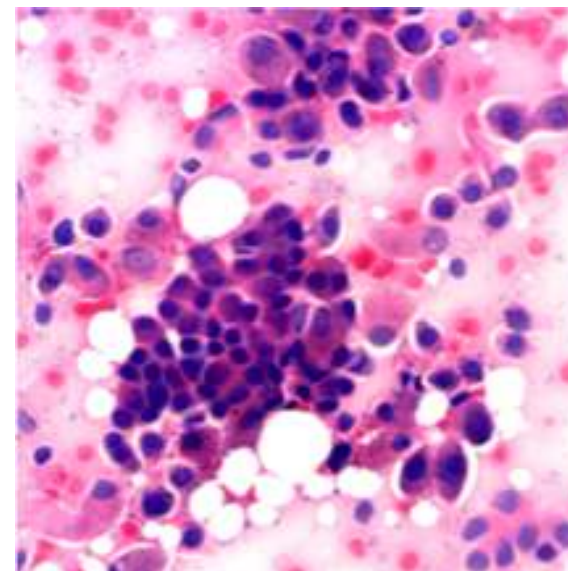
A cytoplasma finoman vacuolisált, a N/C arány alacsony, a mag lehet centrális vagy periférikus.

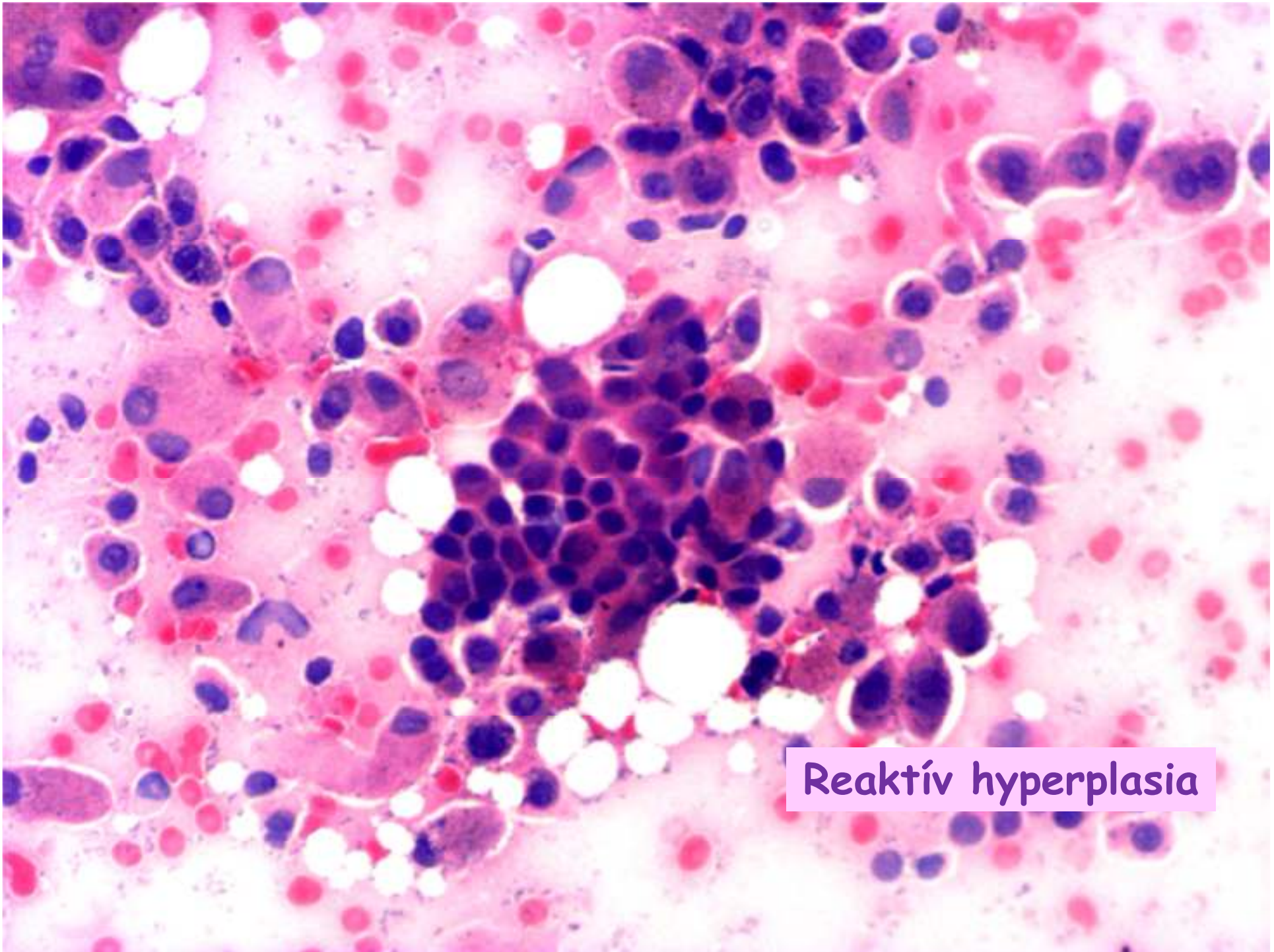
A nucleolus általában nem látható vagy bizonytalan.

Elkülönítésük a macrophagoktól gyakran nehéz.

Atípusos pneumocyták alveolaris károsodást követően jelenhetnek meg - ARDS, organizáló pneumonia, infarctus....

A klinikai adatok jelentősége!!!!
Radiomorfológiai információk!





Reaktív hyperplasia

Adenocarcinoma



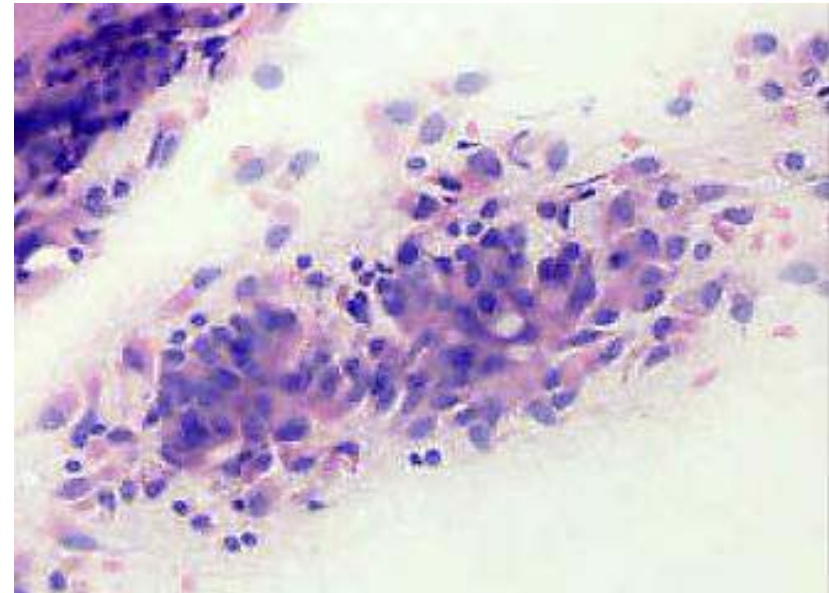
2. Bronchialis hyperplasia

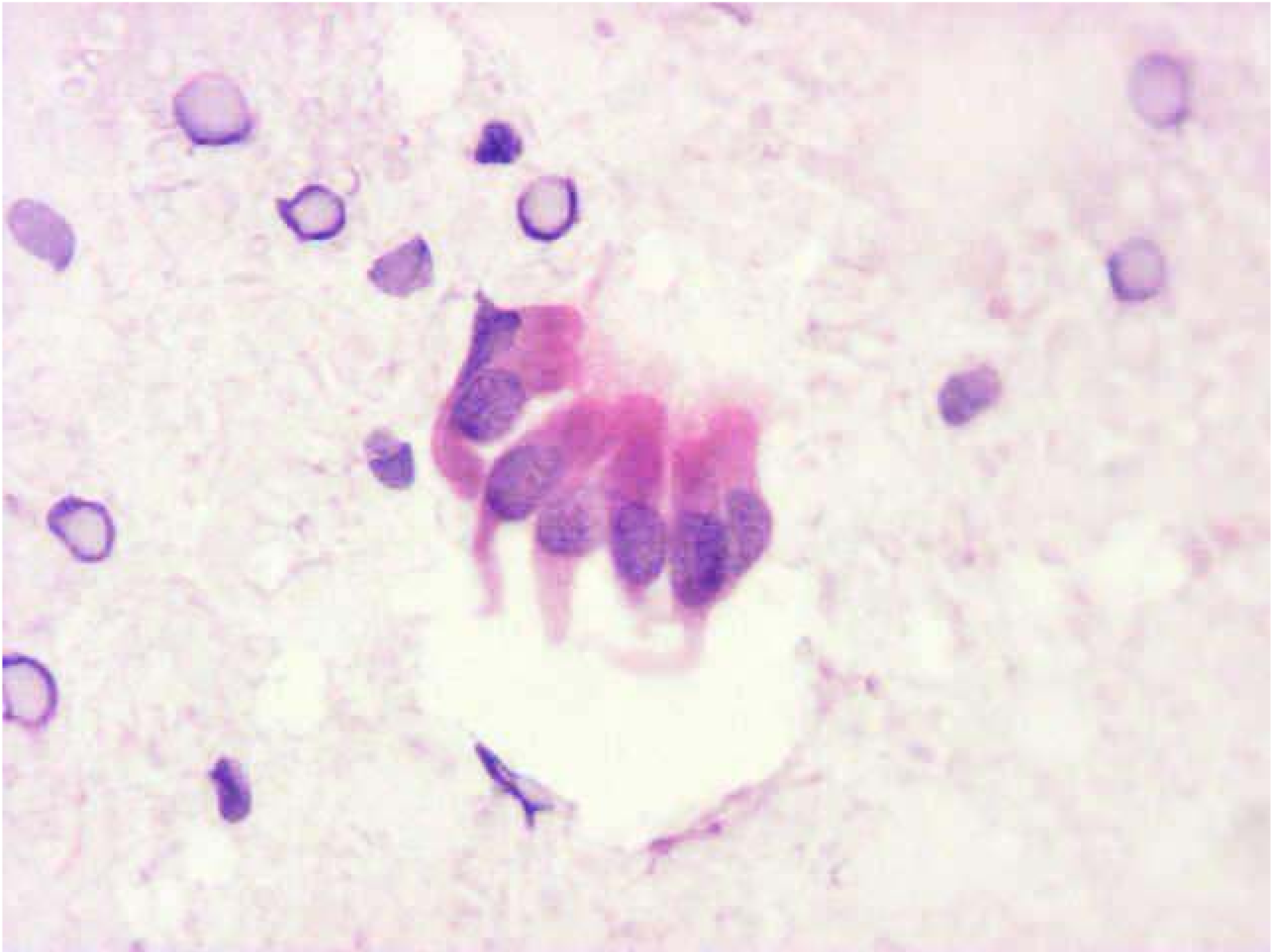Asthma, tuberculosis, vírus infekció vagy eszközös beavatkozás.

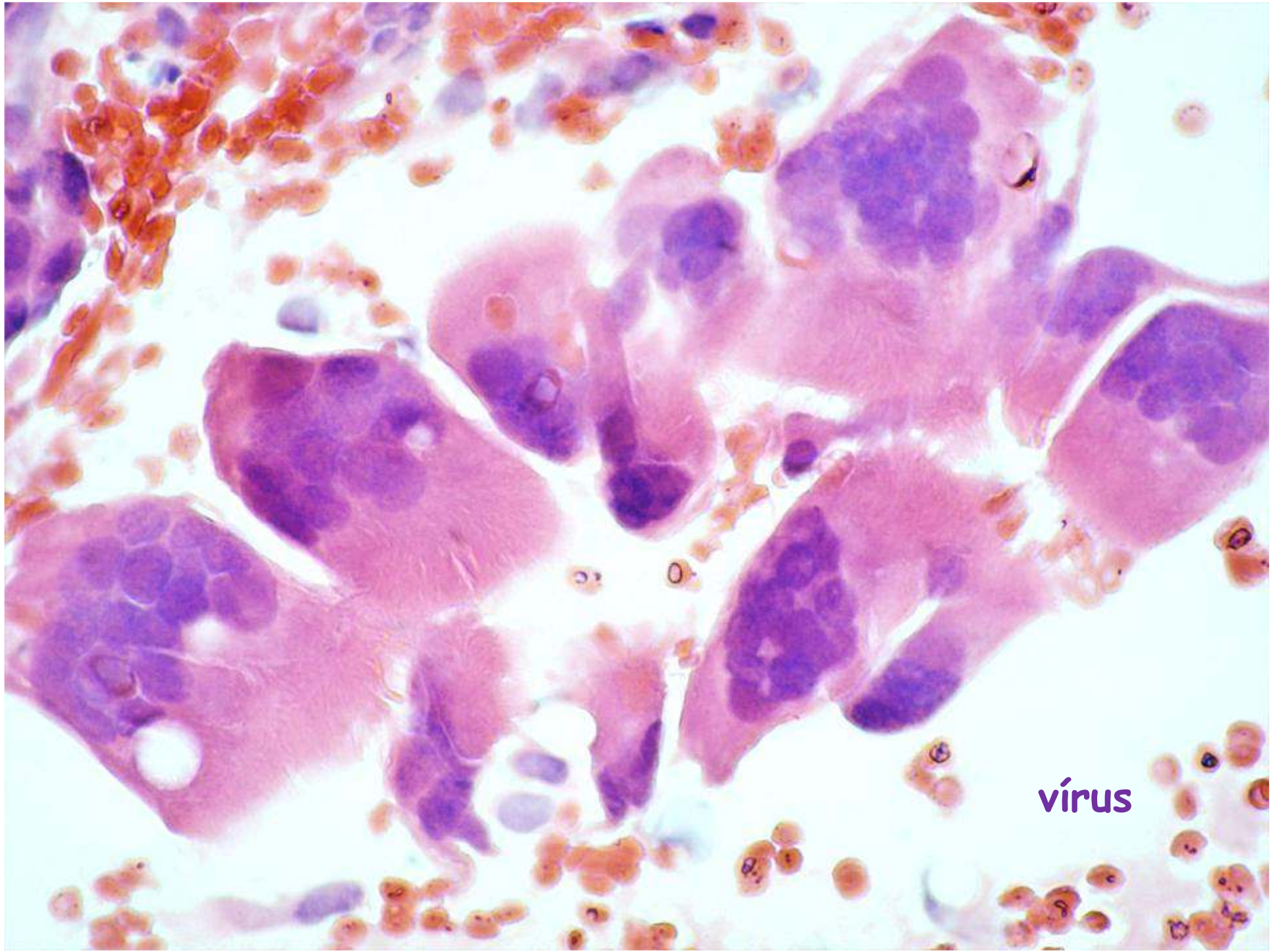Sejtdús kenet, lemezekbe rendeződött sejtek, melyek között lehetnek adenocarcinomát utánzó atípusos alakok.

! DE!!!!

a tumorsejtnek nincs csillója!!!!







virus

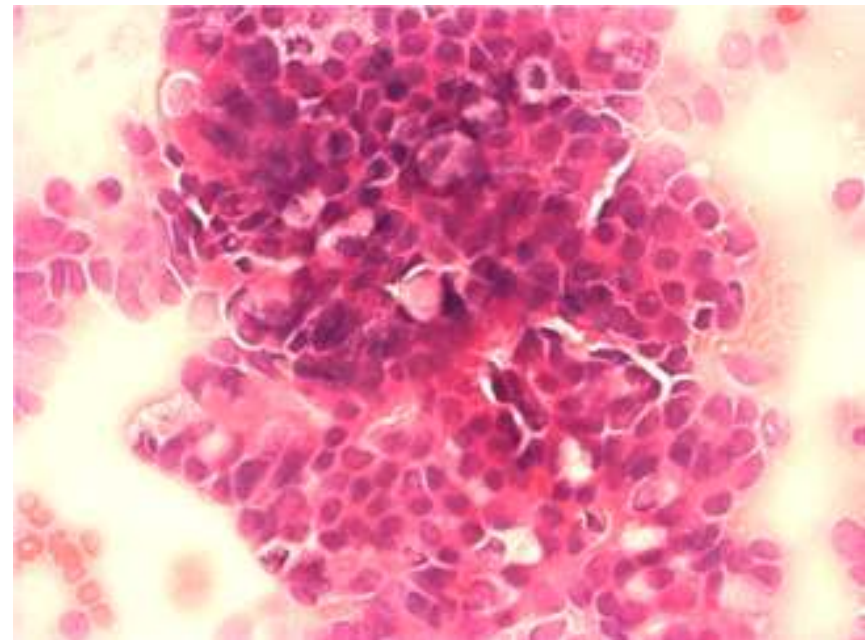
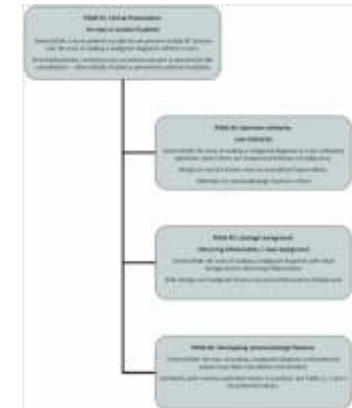Adenocarcinoma

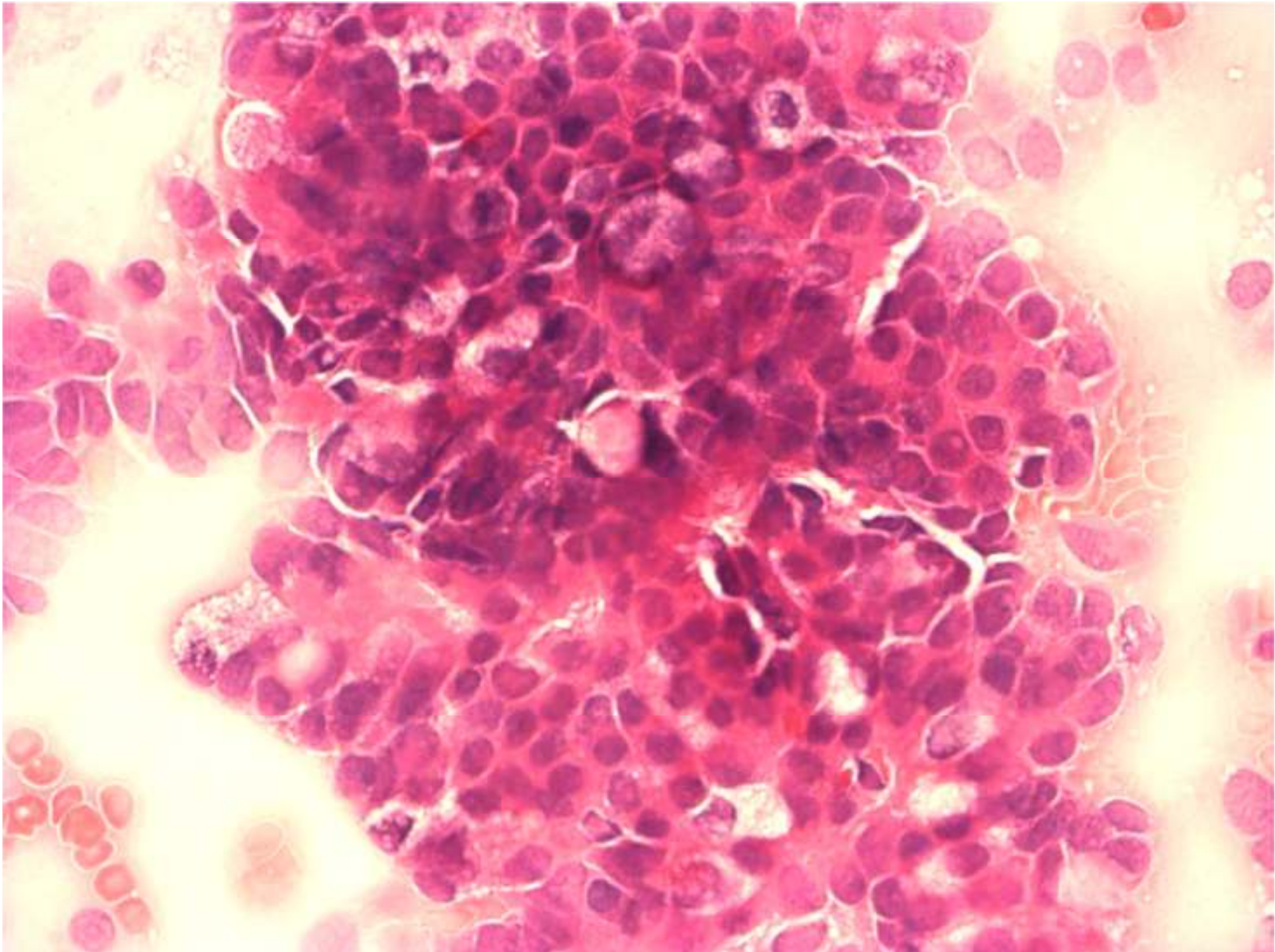
3. *Reaktív/atípusos bronchialis sejtek*

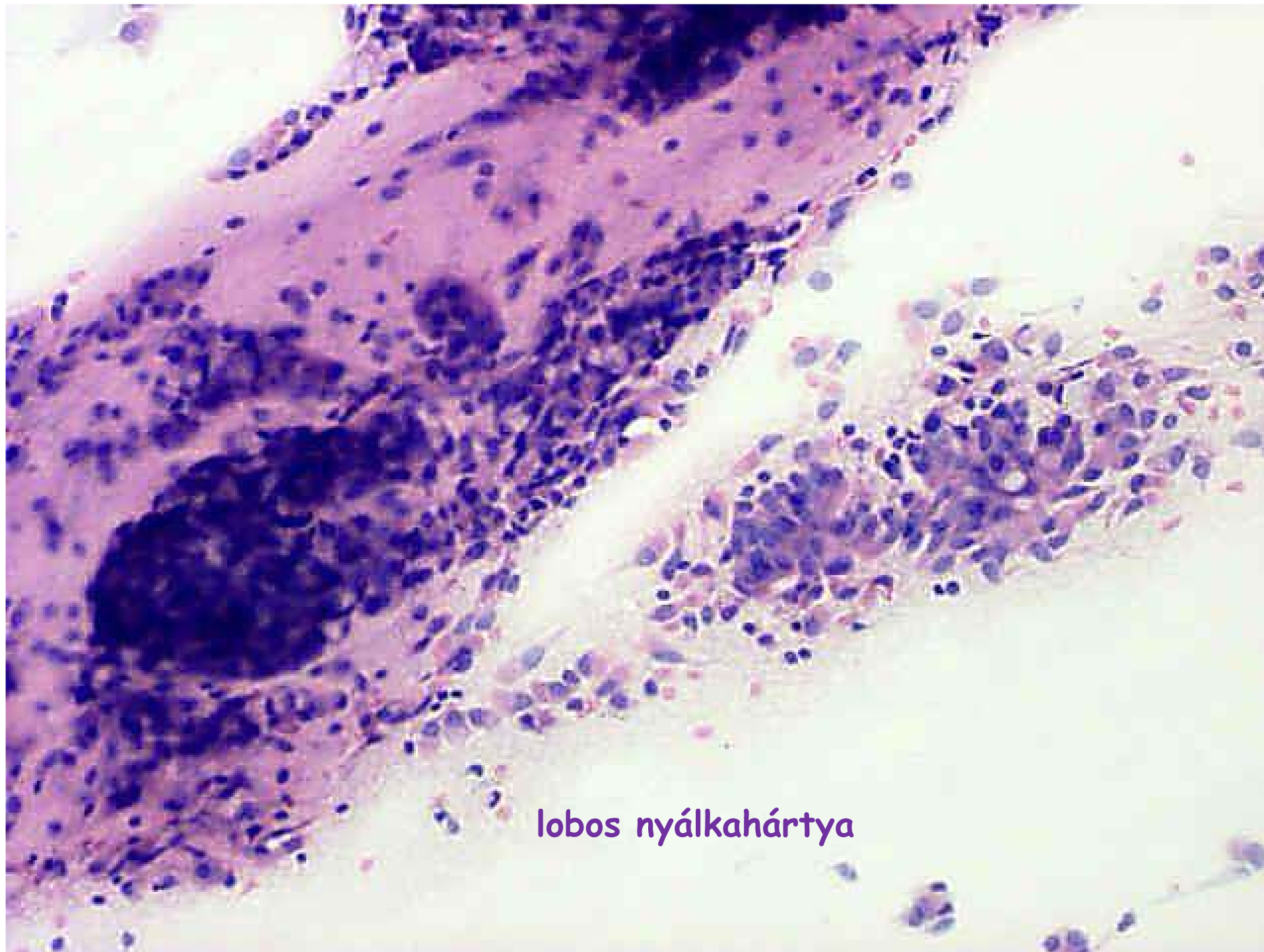
Pneumonia, DAD (diffúz alveolaris károsodás),
tüdőinfarctus, asthma, COPD, környezeti toxikus hatás,
irradiáció, kemotherápia.

Nagy nucleusok és a magok közötti
atípiá ADC gyanút kelthet.
Többmagvú sejtek magjai a
disszociált reaktív sejtekével
megegyezők.

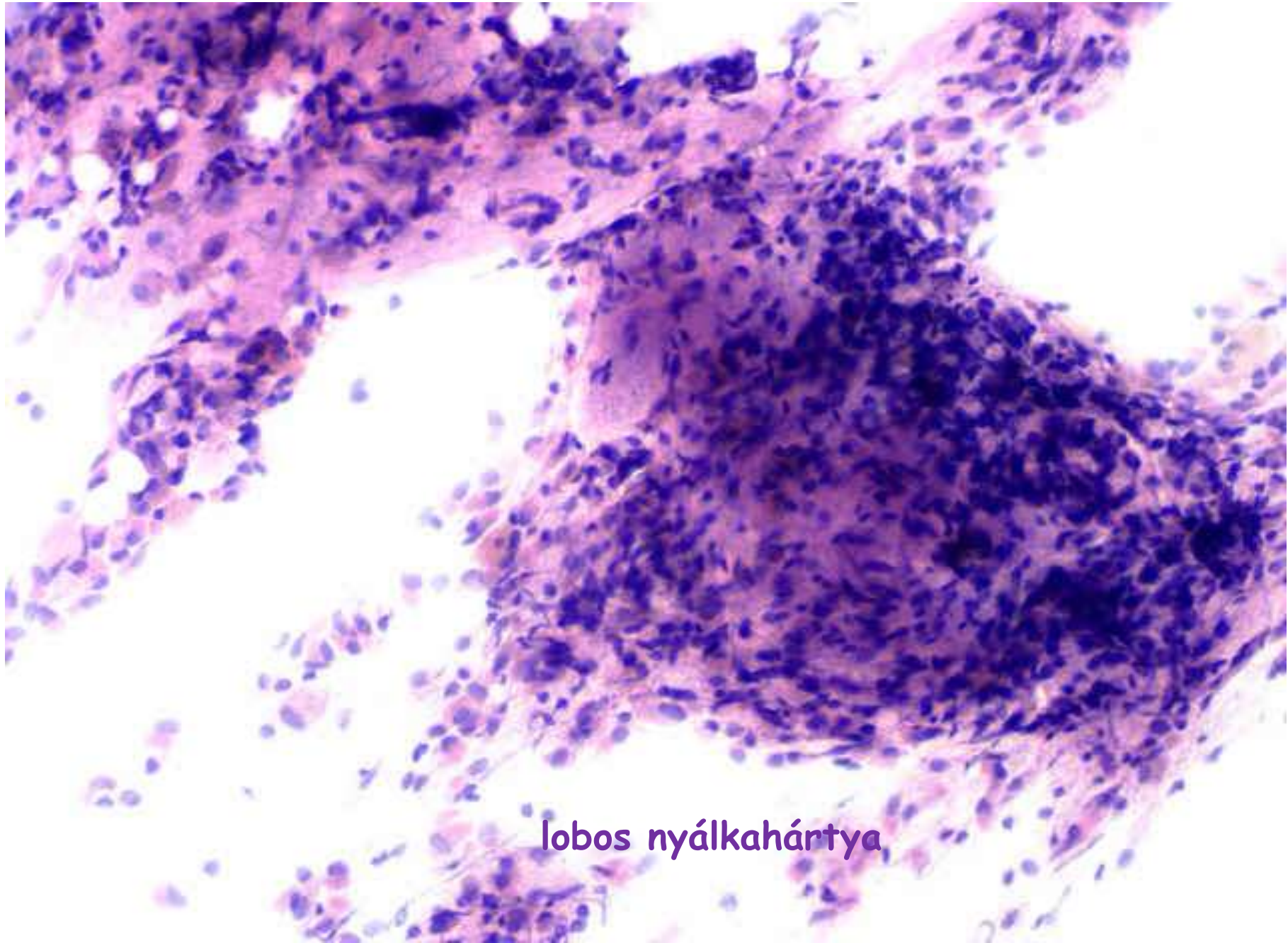
Bizonytalanság esetén ismételt
mintavétel, esetleg lobgátló
kezelést követő kontroll javasolt!



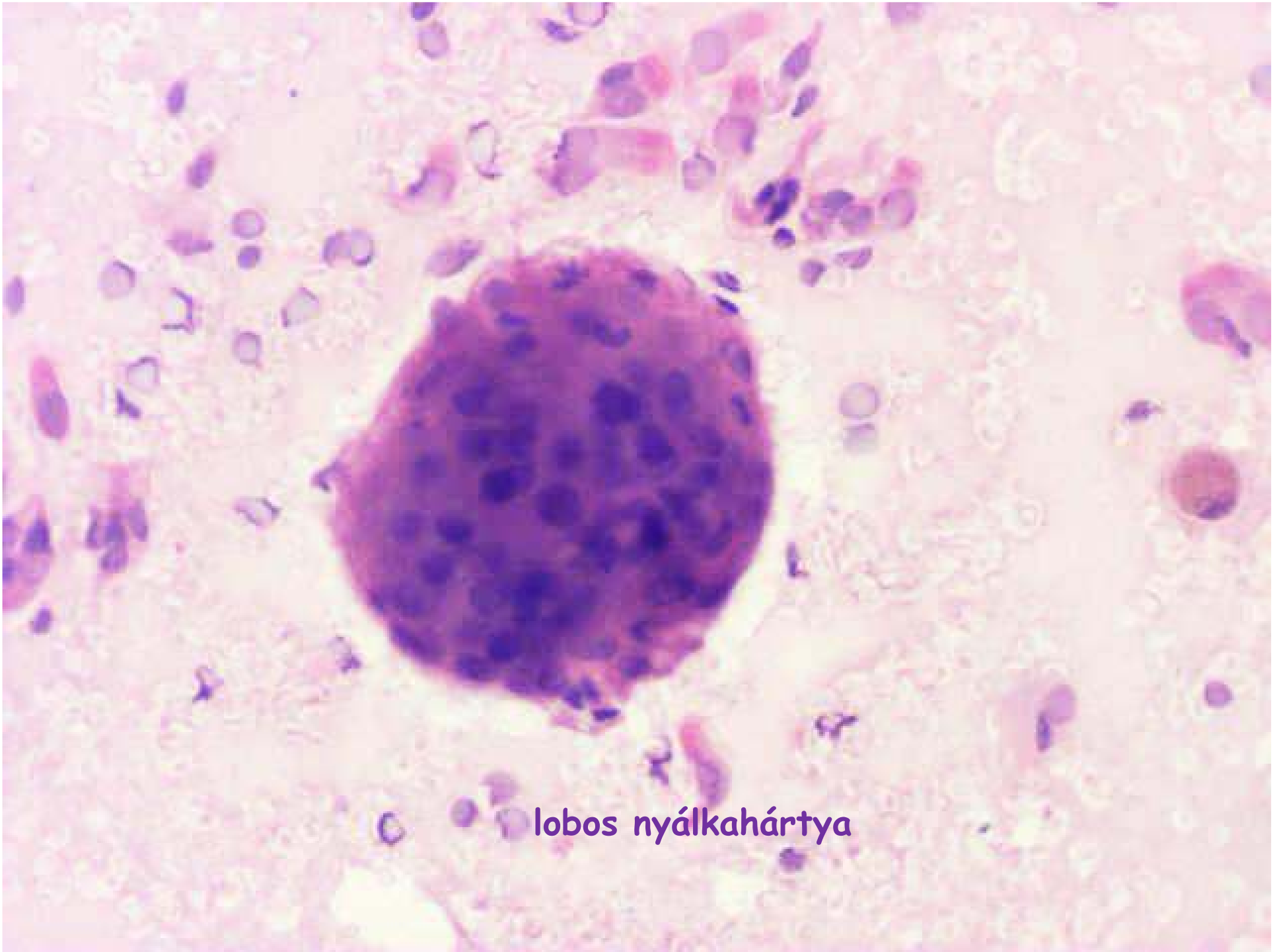




lobos nyálkahártya



lobos nyálkahártya




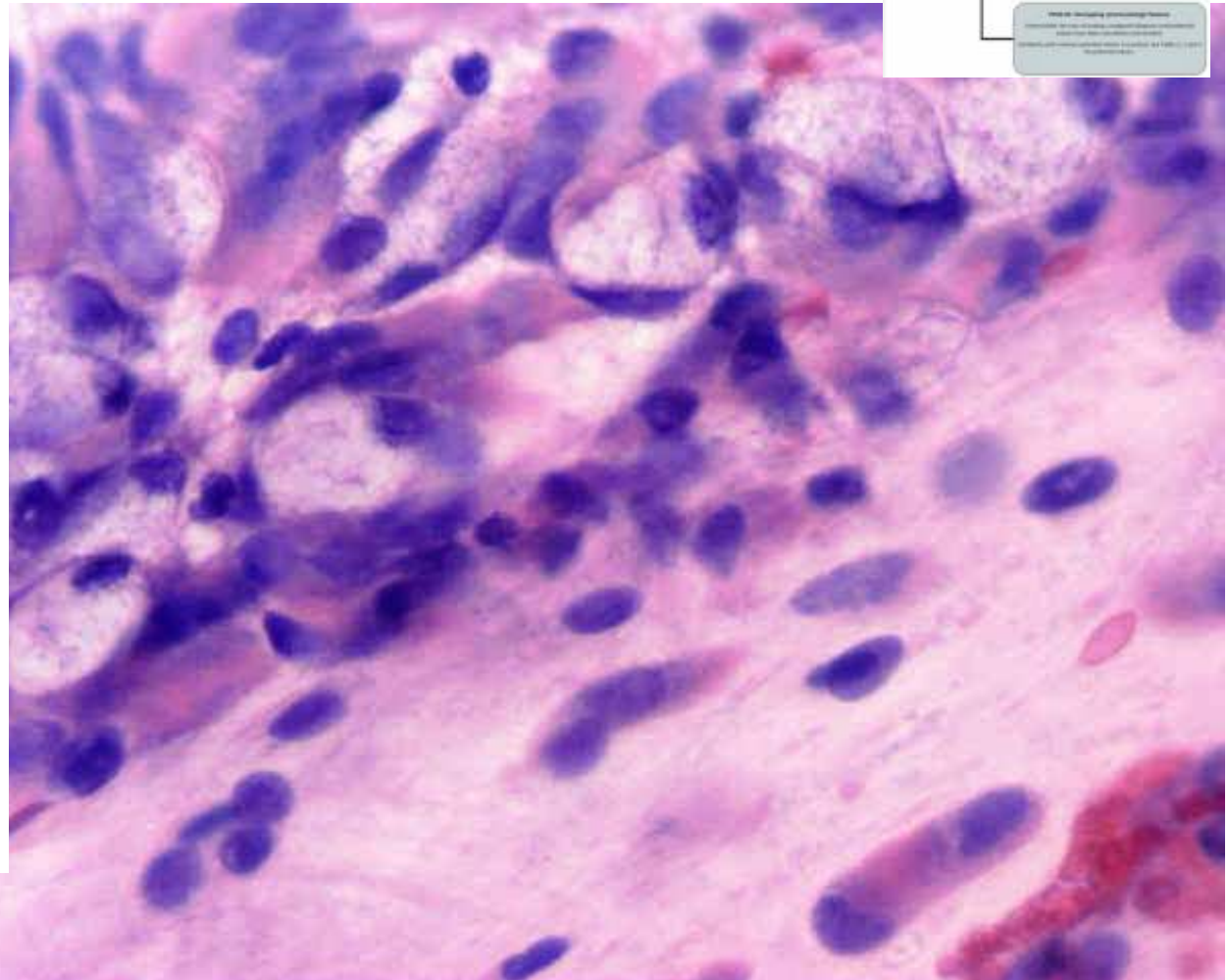
lobos nyálkahártya

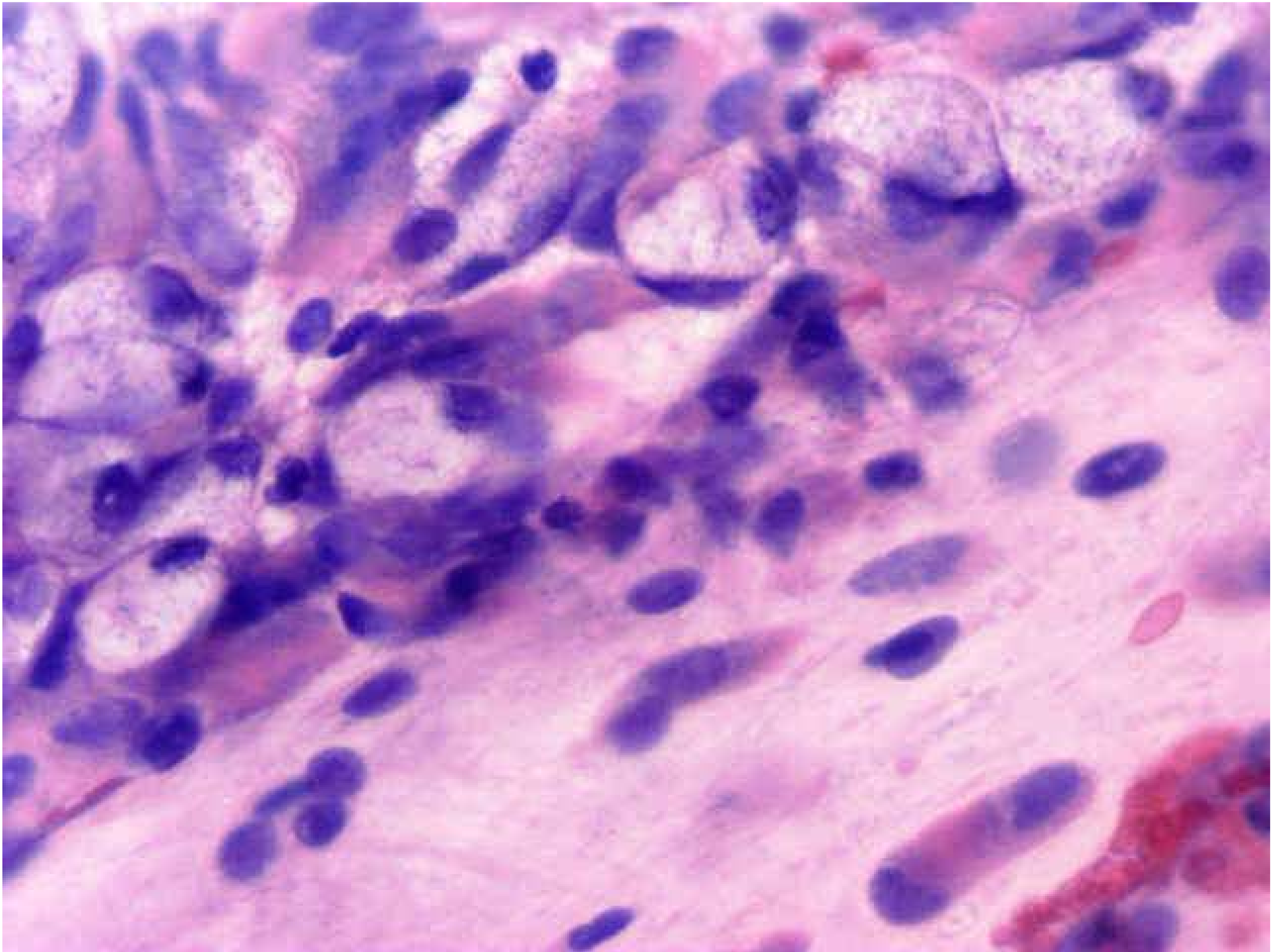
Adenocarcinoma

4. Kehelysejtes
hyperplasia
Asthma, COPD

Gyakrabban
bronchoszkópia vagy UH
vezérelt FNA mintavételt
követően látható.
Percutan FNA kevésbe ad
ilyen sejteket.

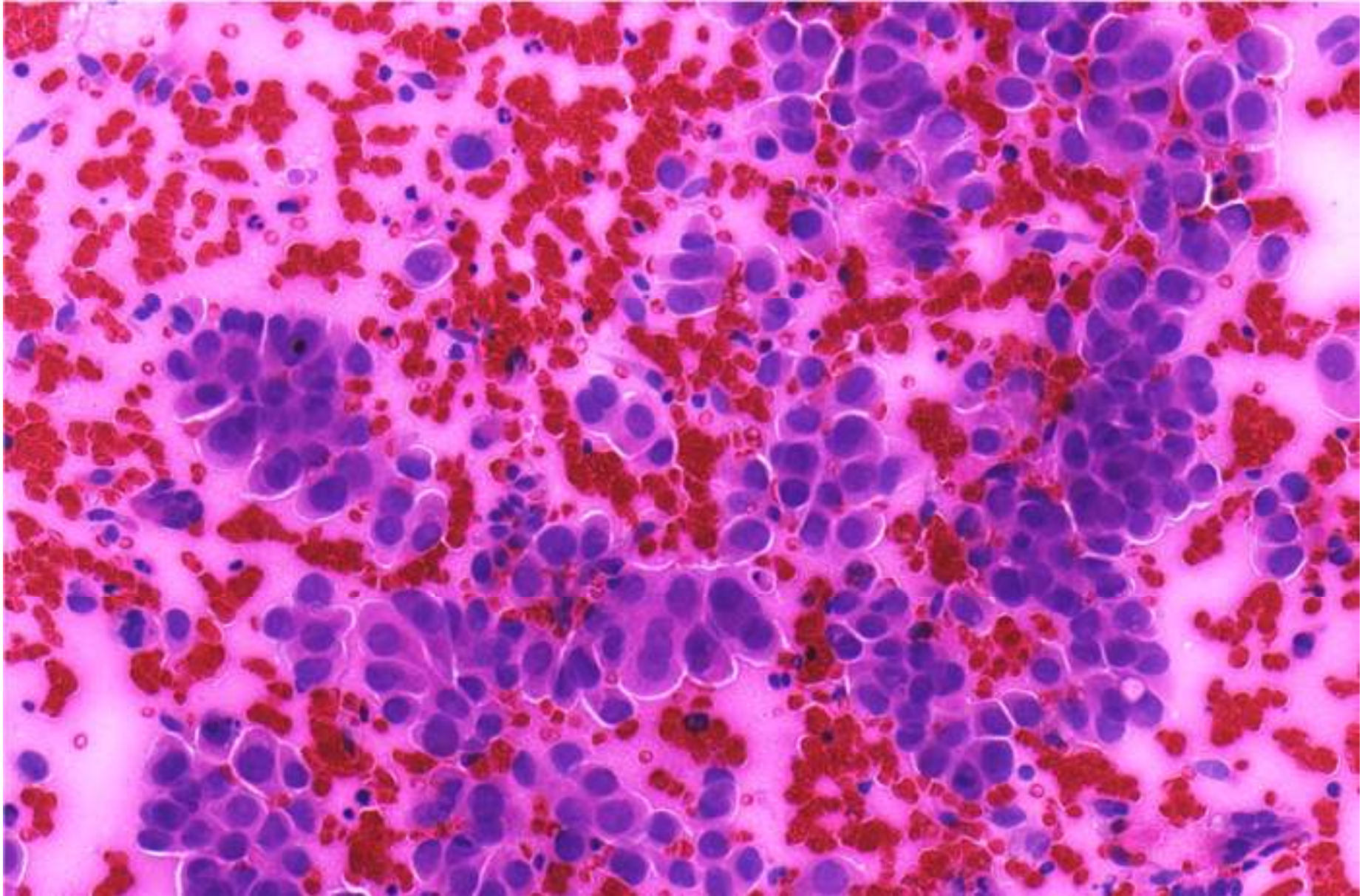
Mucin-teremlő ADC,
mucinosus BAC jelleg,
pecsétgyűrűsejtes
carcinoma

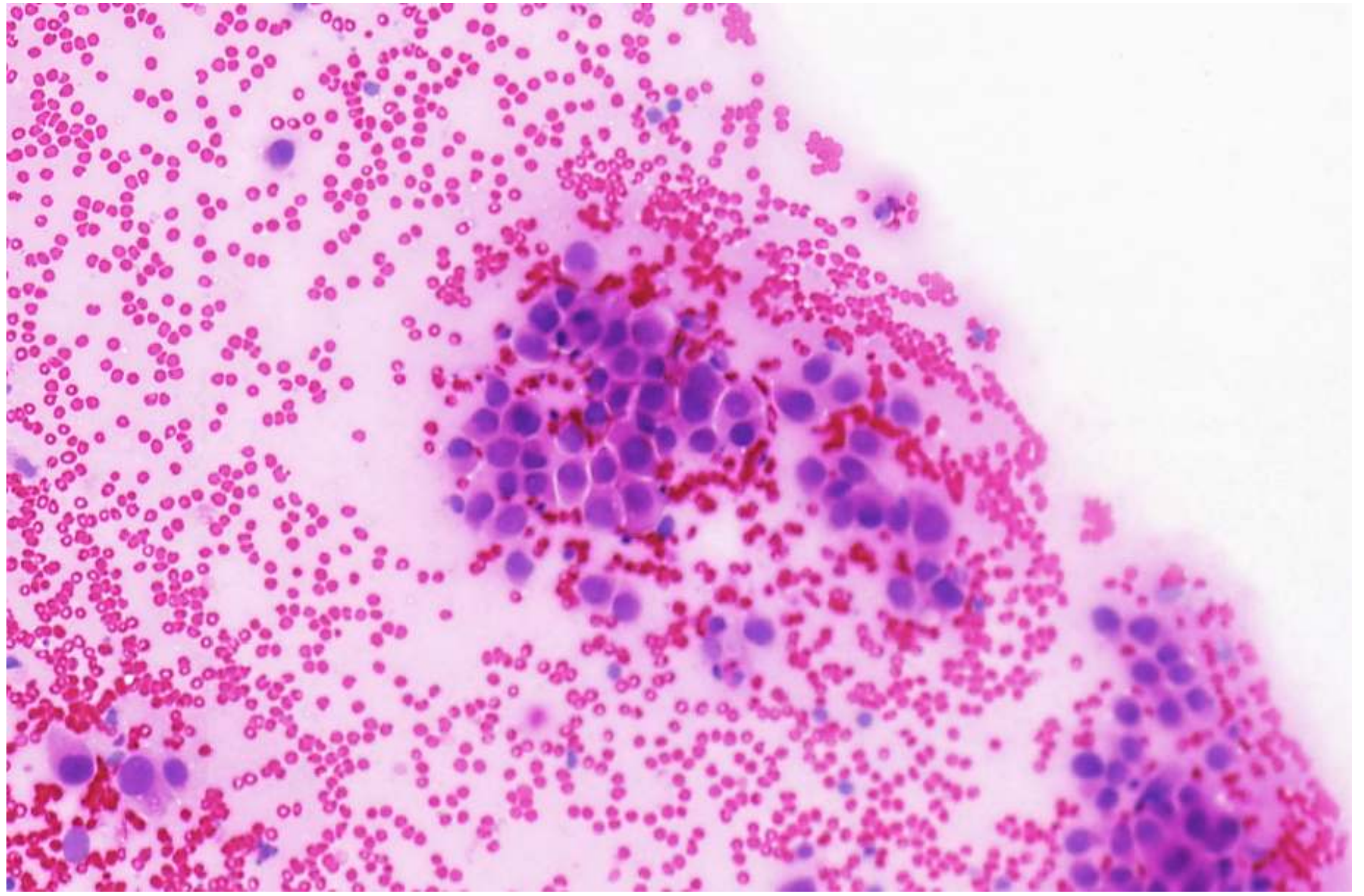


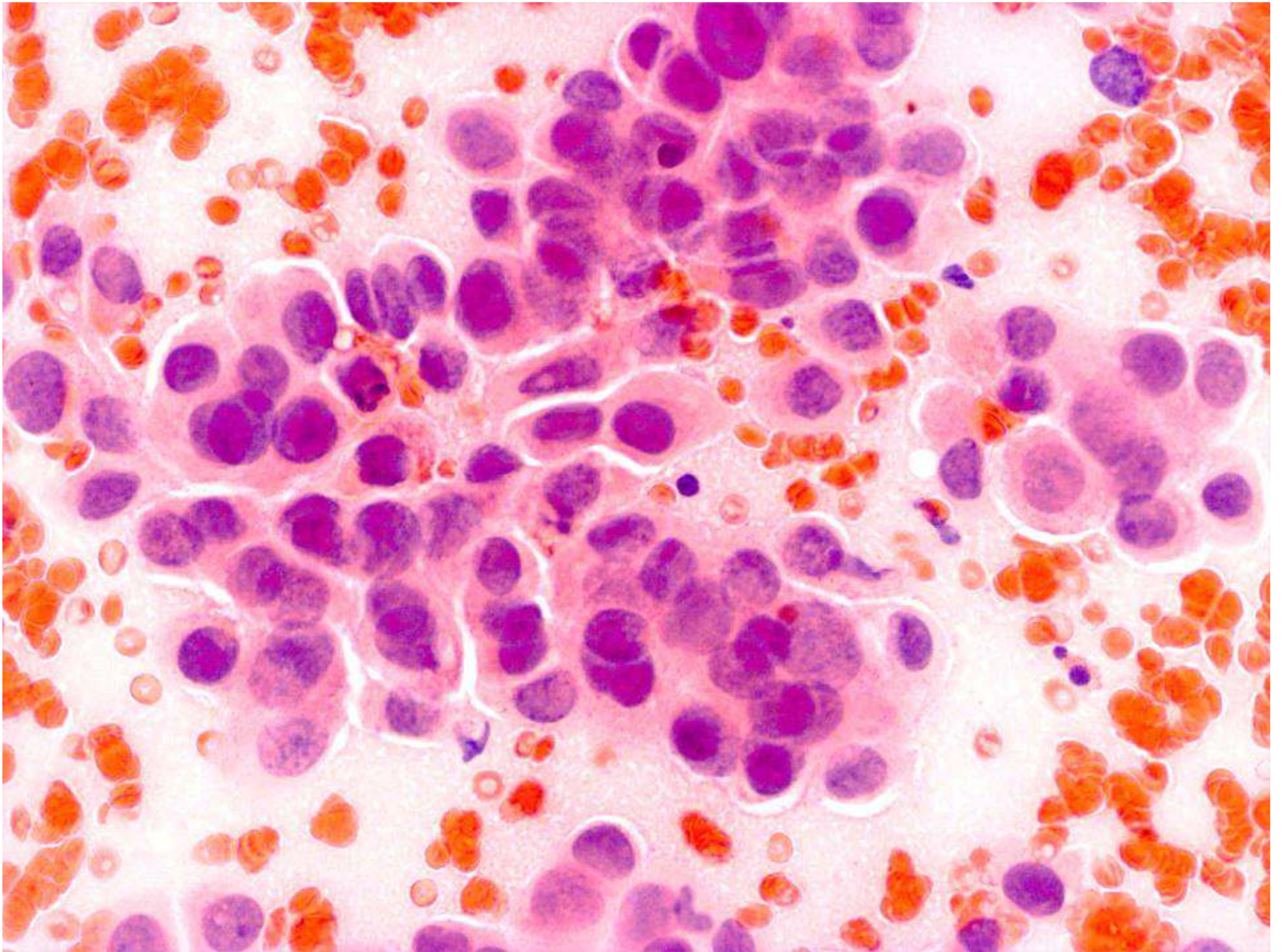


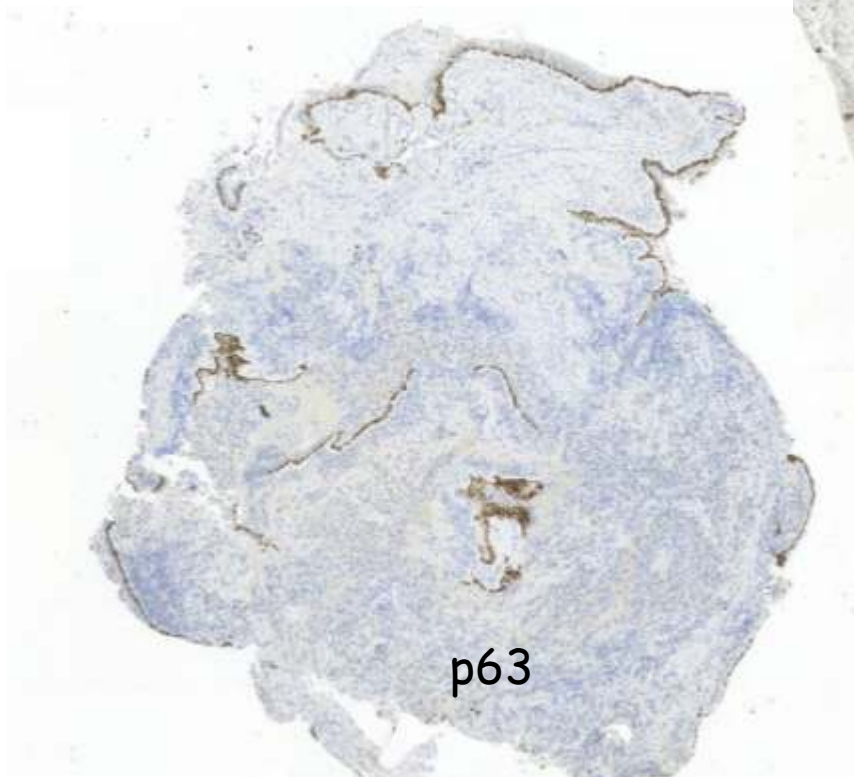
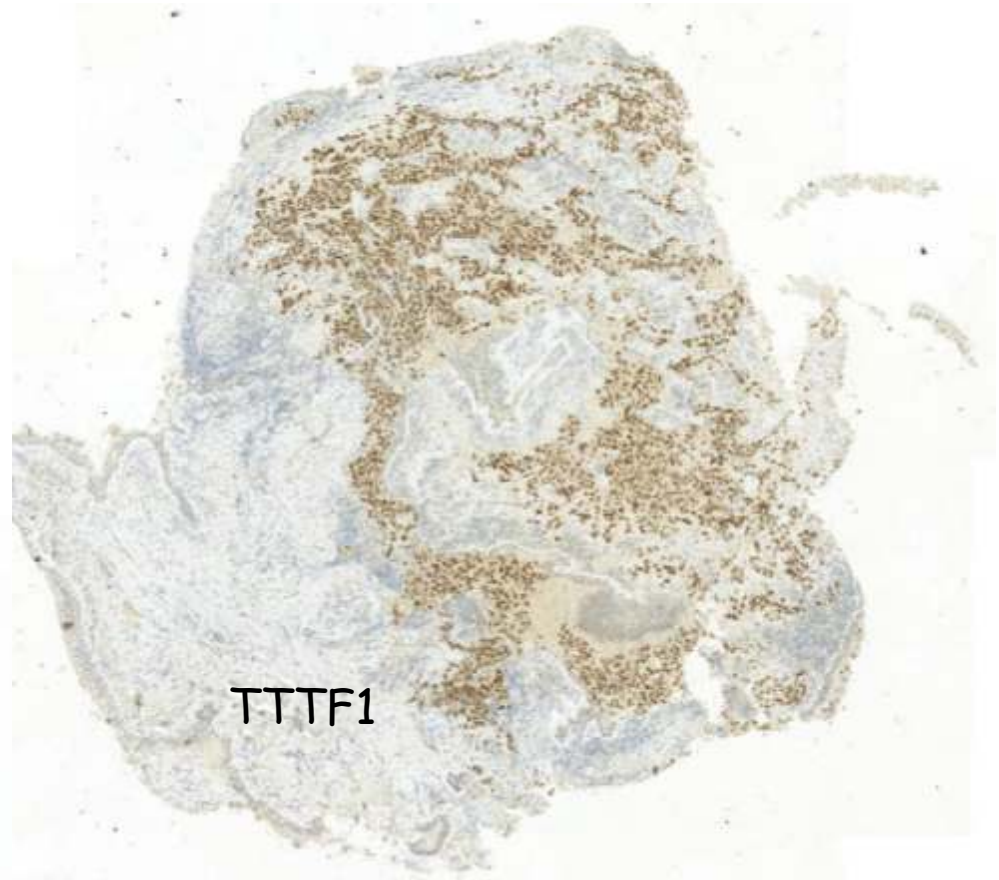
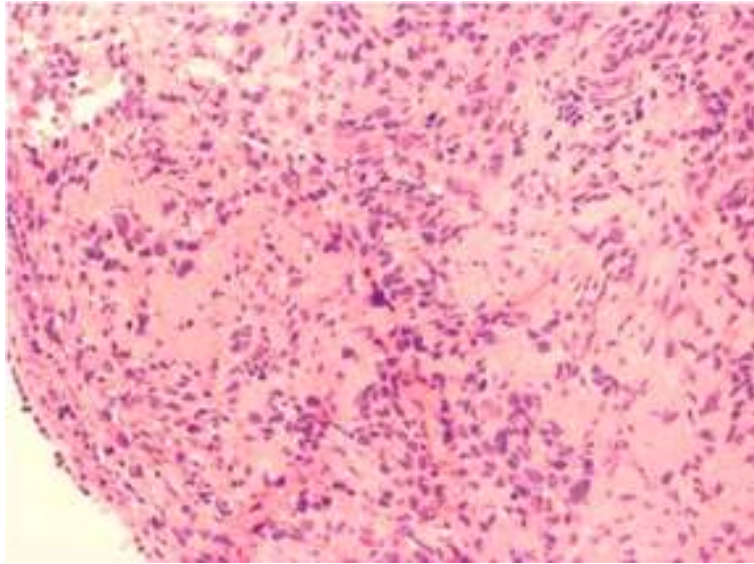
**Amikor a cytológiai kép
többet mond, mint a
szövettan.....**

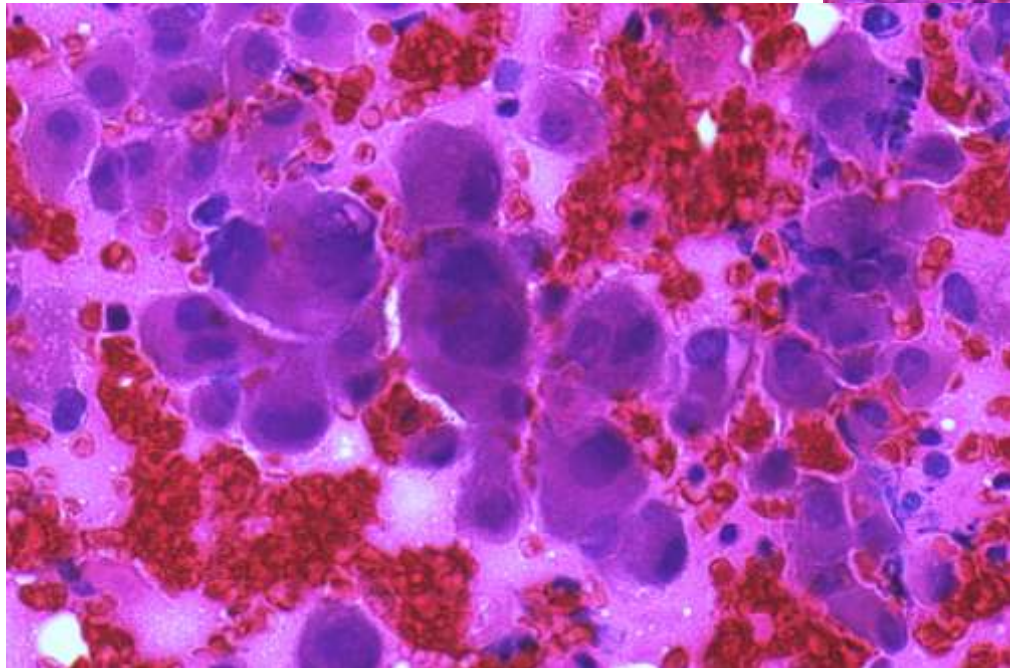
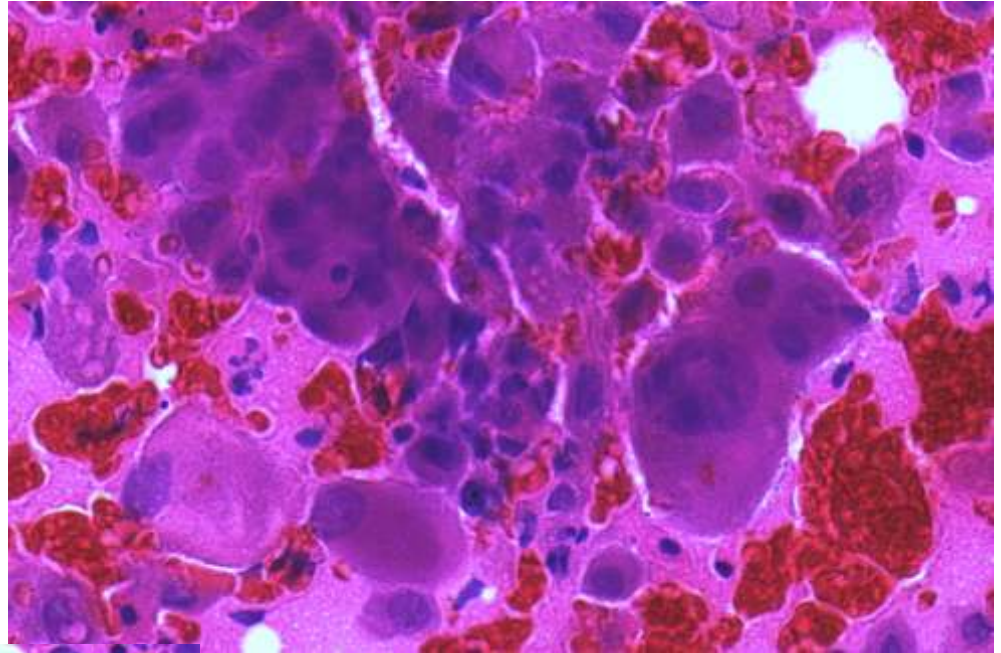
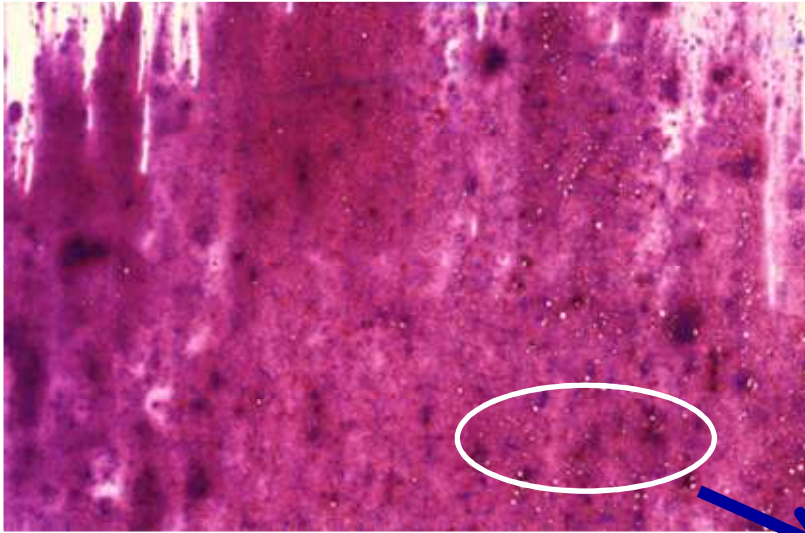
Imprint - ADC



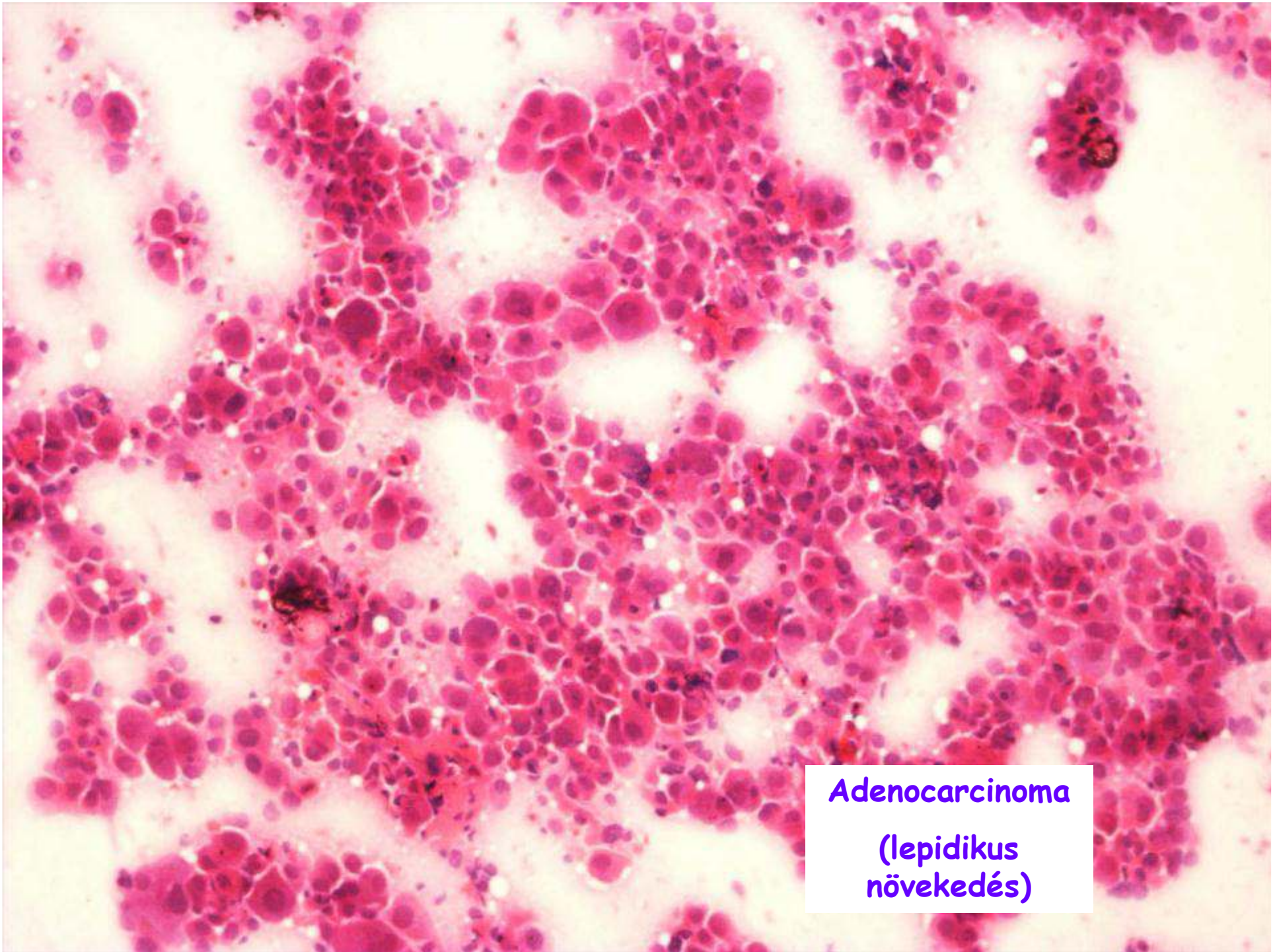








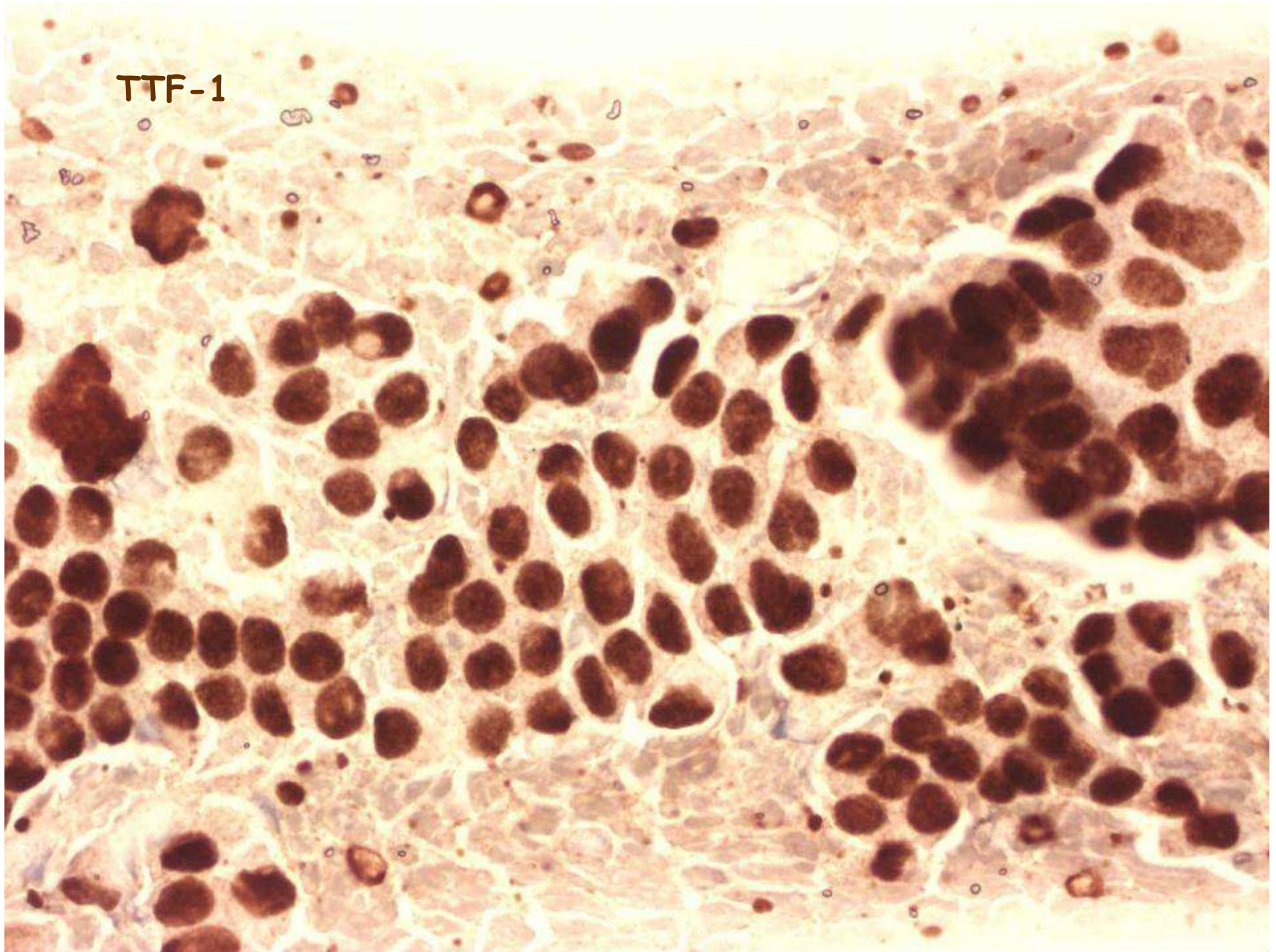
TTP - ADC

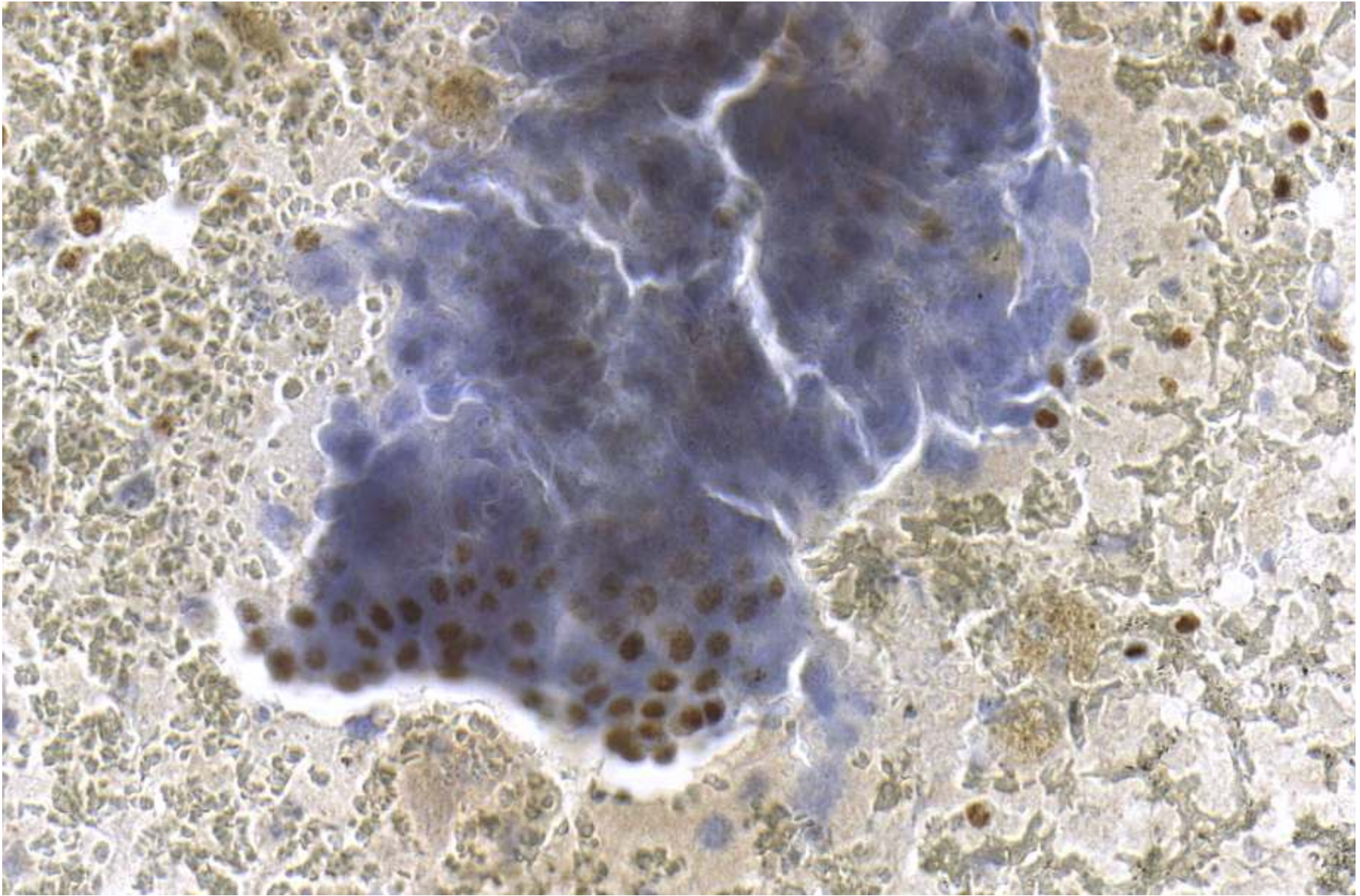


Adenocarcinoma
(lepidikus
növekedés)

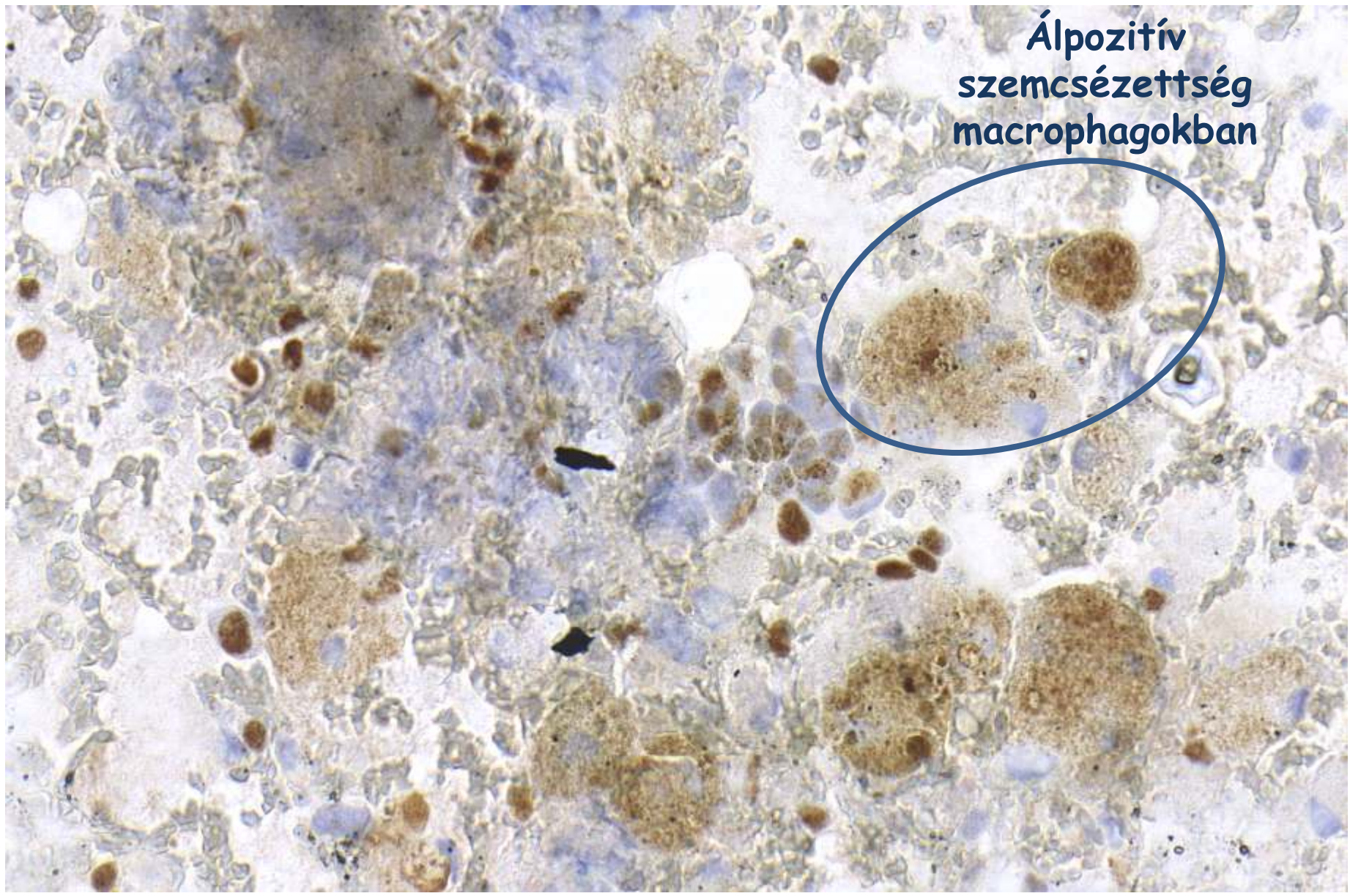
Néhány immuncitokémiai
reakció.....

TTF-1



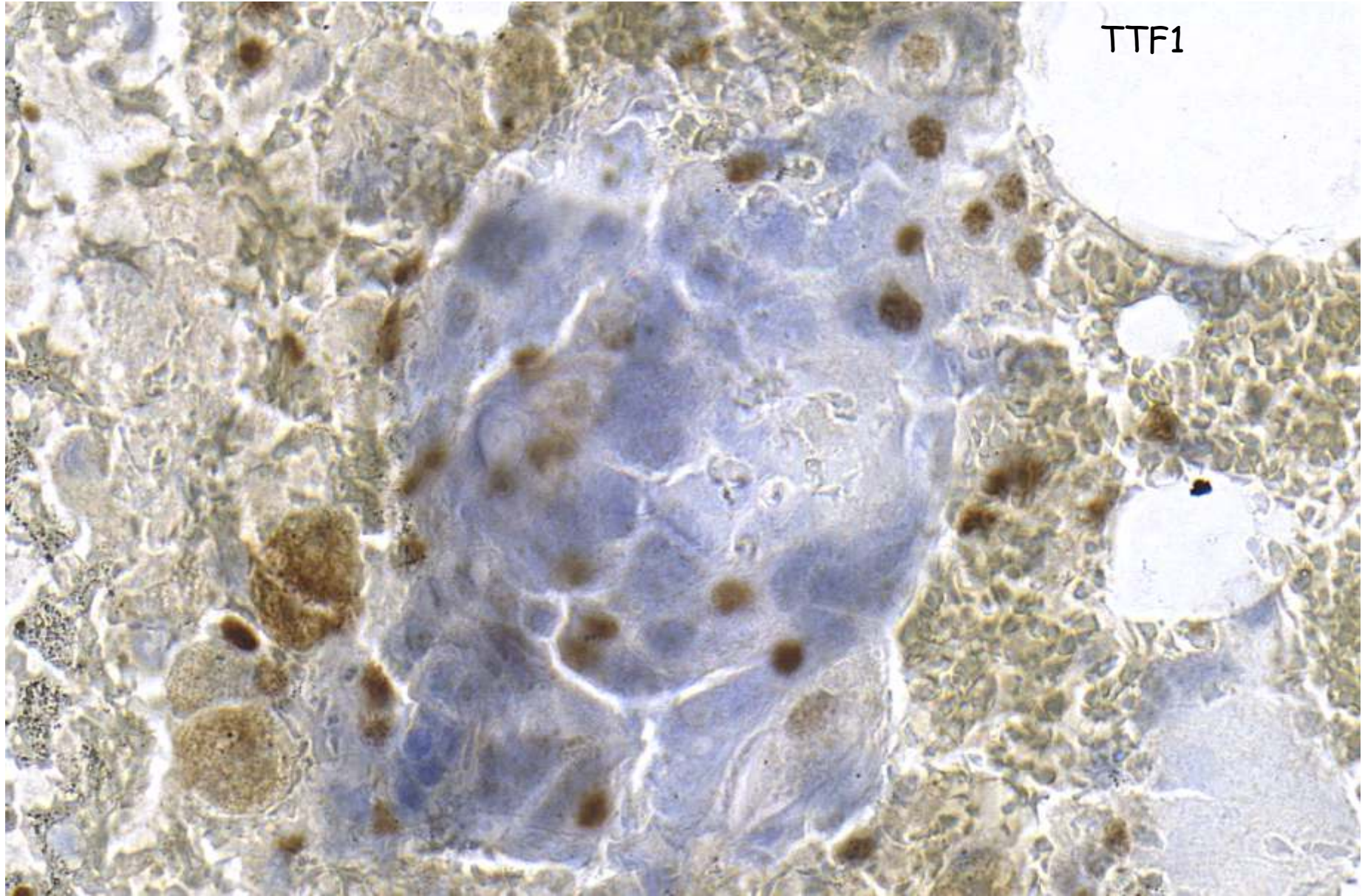


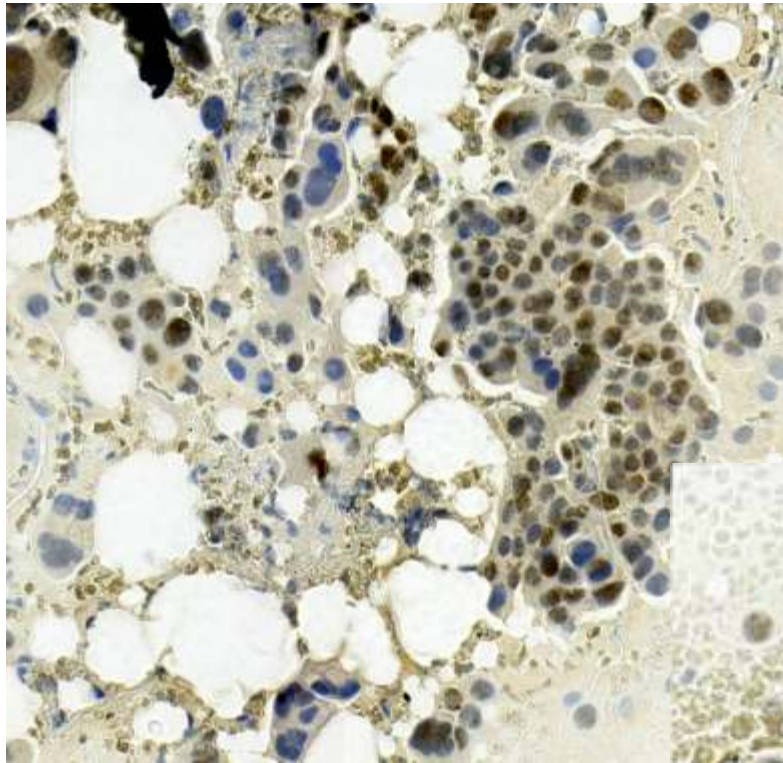
TTF1



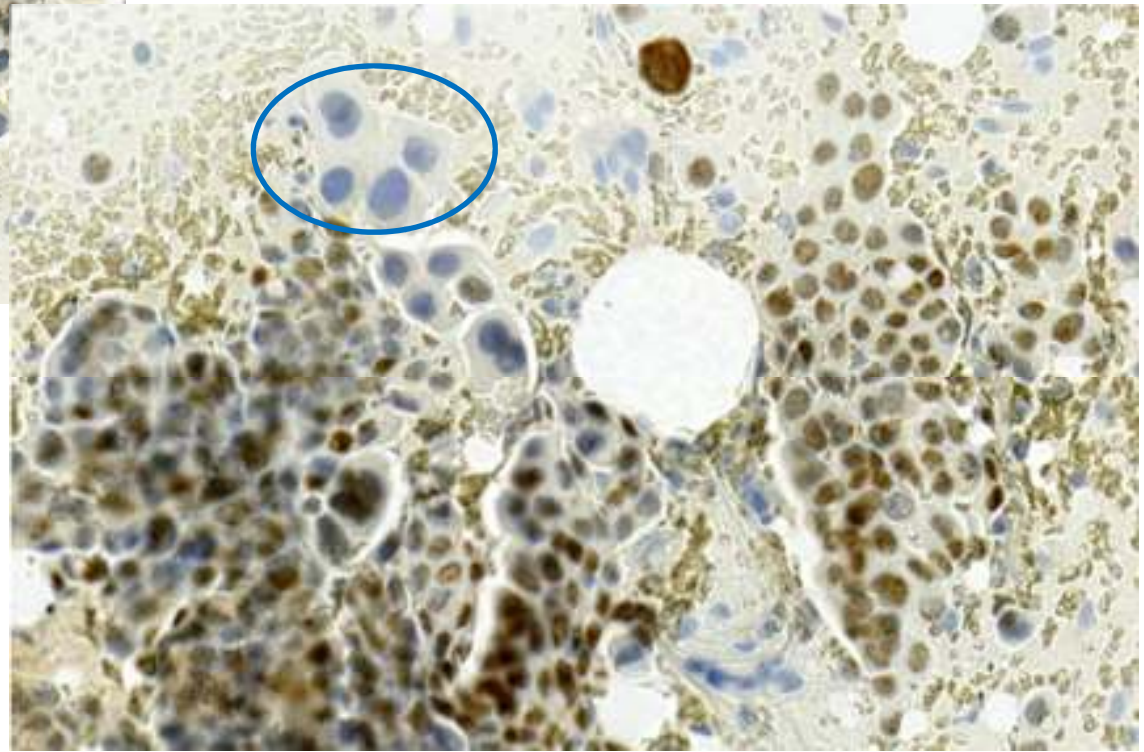Álpozitív
szemcsézettség
macrophagokban

TTF1






Reaktív sejtek a
háttérben - belső
kontroll

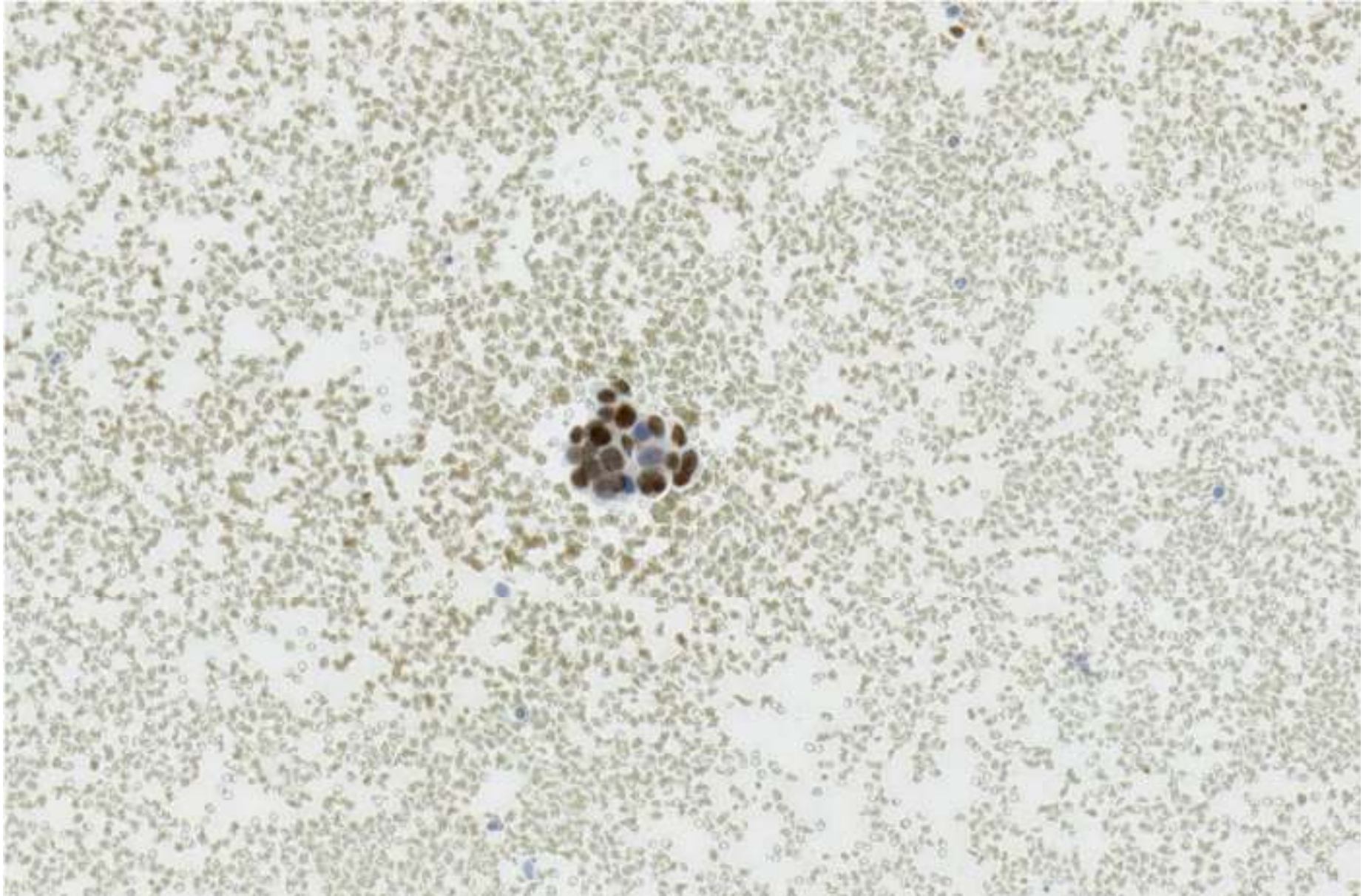


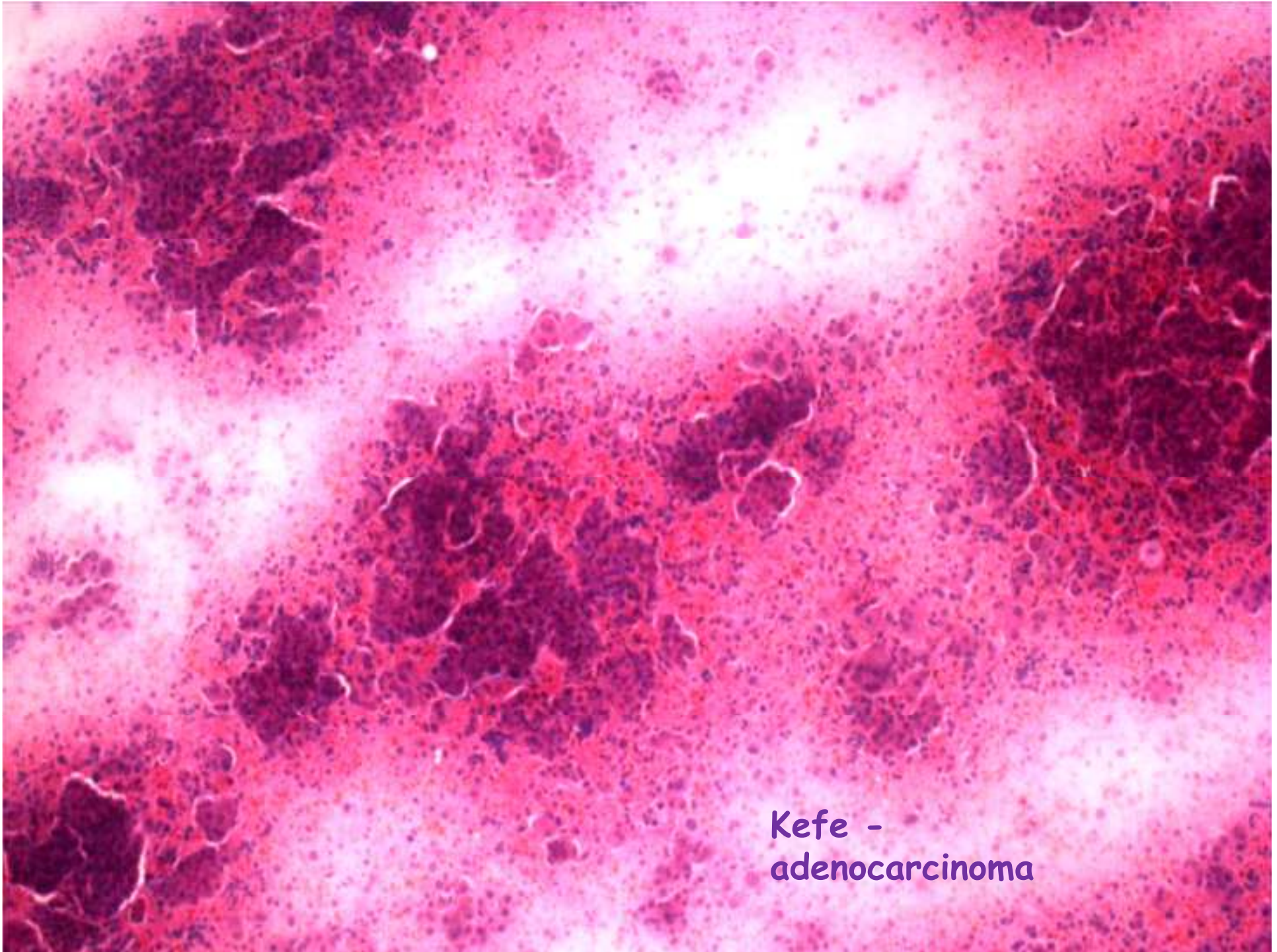
**Ne az immuncitokémiai
reakció eredménye
vezesse a diagnózist!**

Nagyon véres TBNA



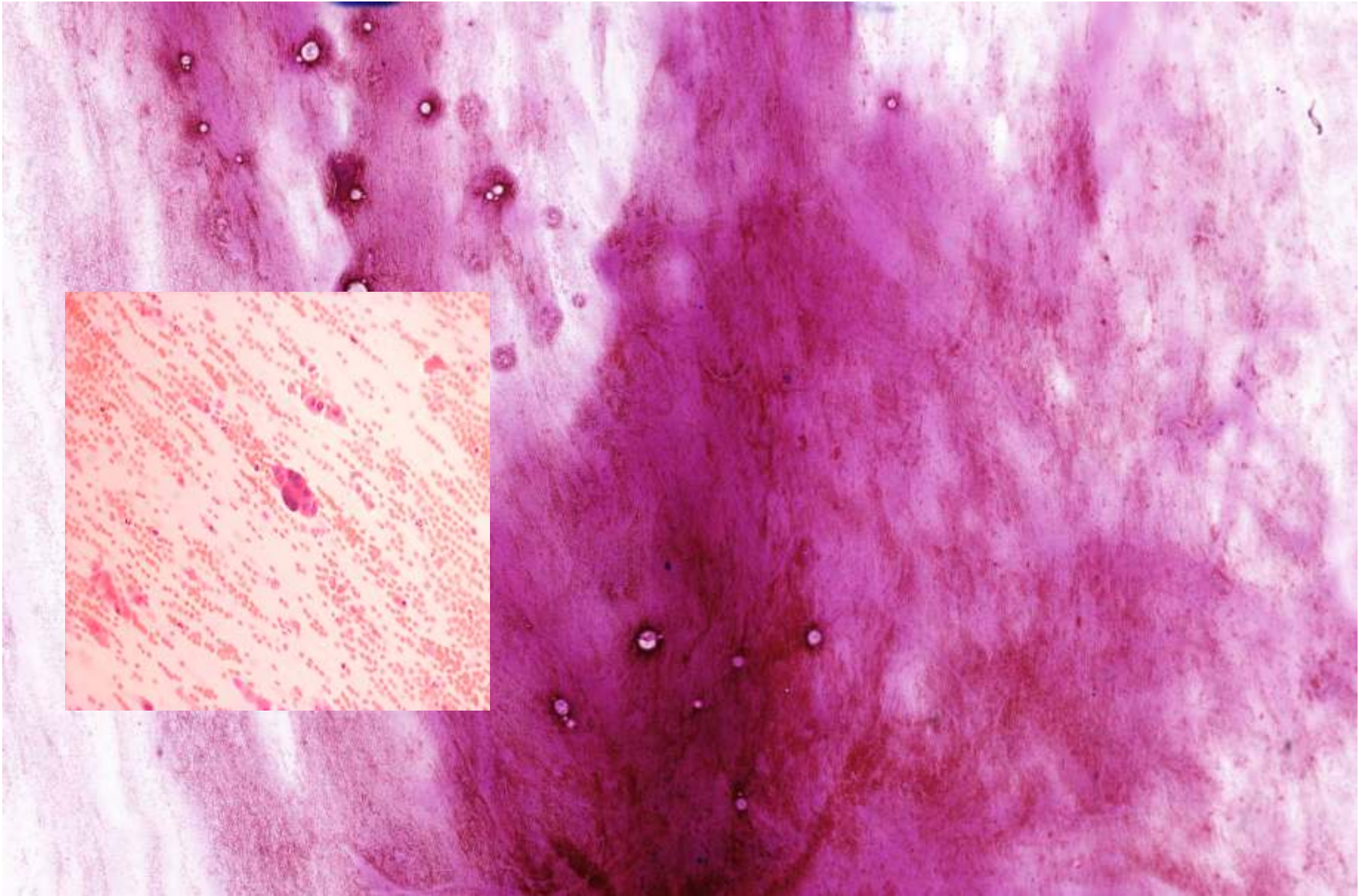
Nagyon véres TBNA -ból TTF1

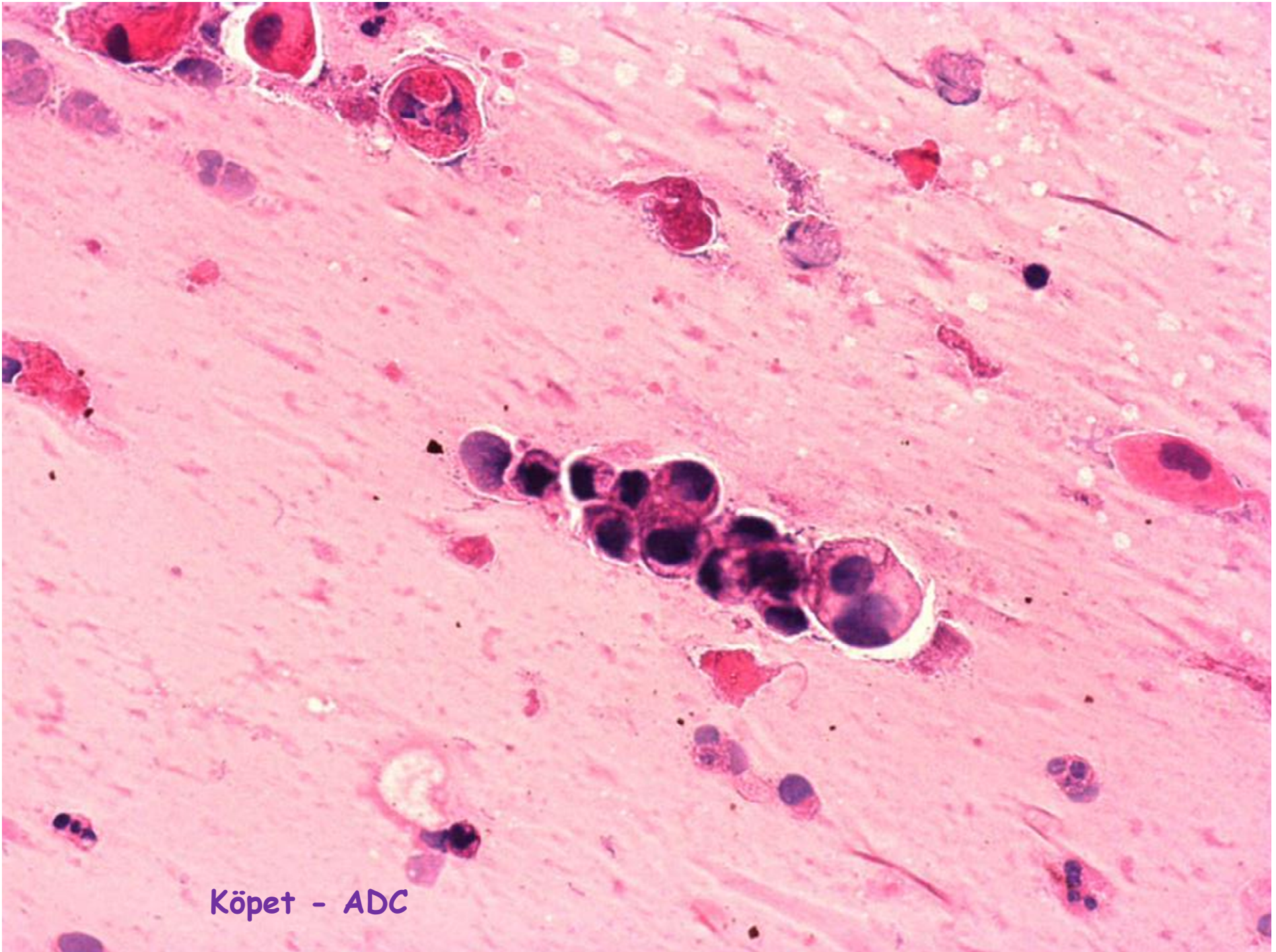




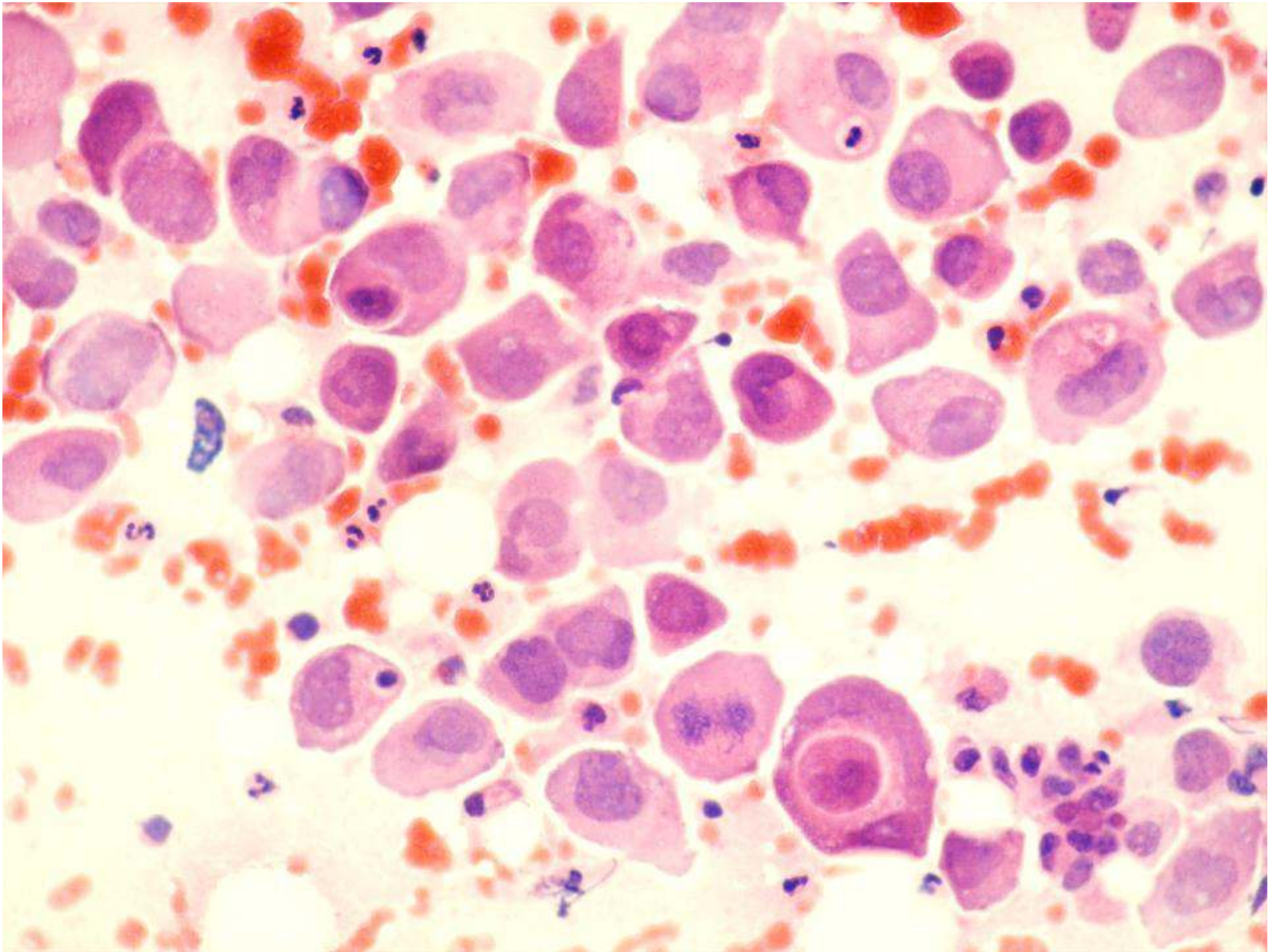
Kefe -
adenocarcinoma

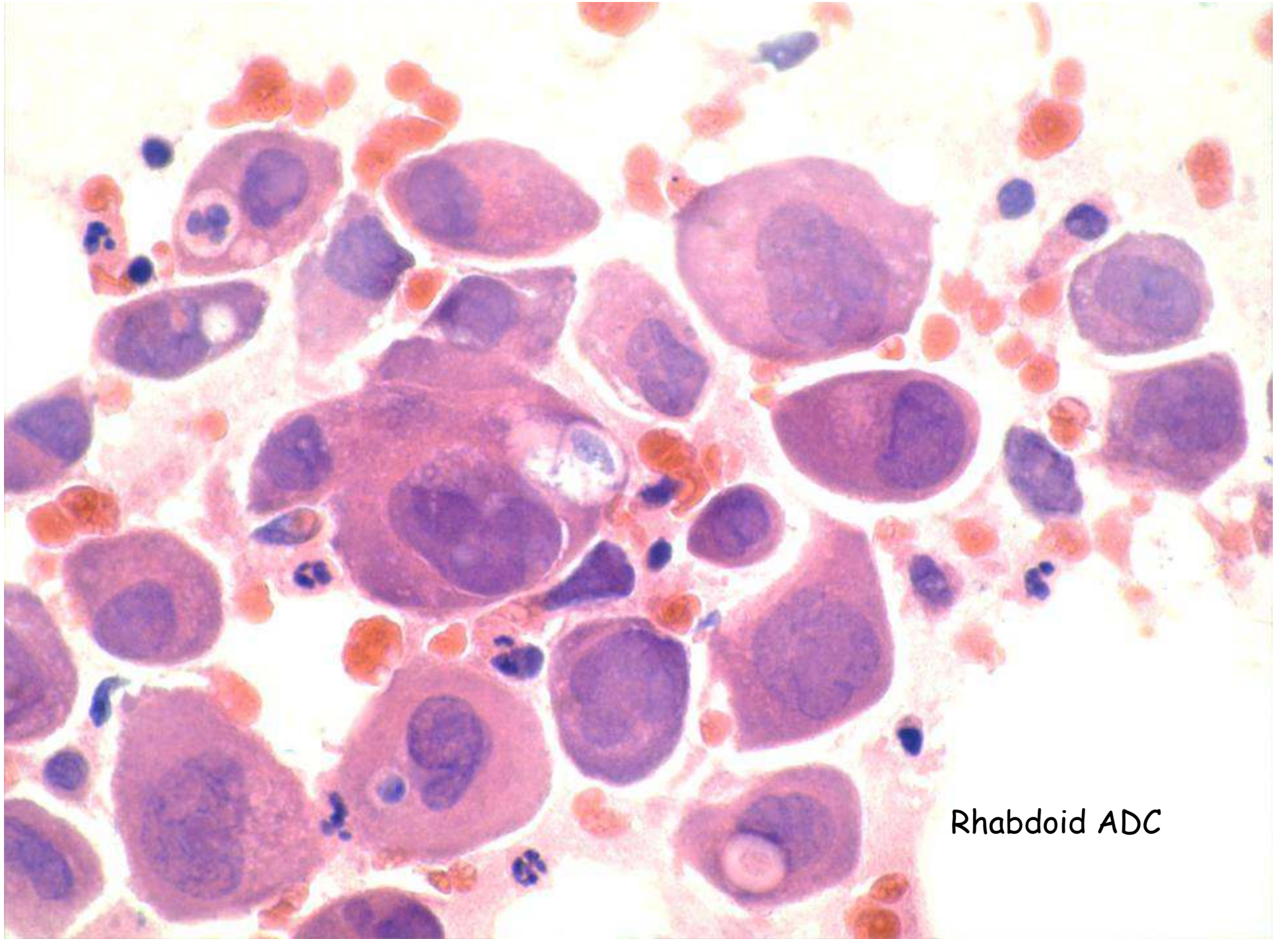
ADC kefe





Köpet - ADC





Rhabdoid ADC

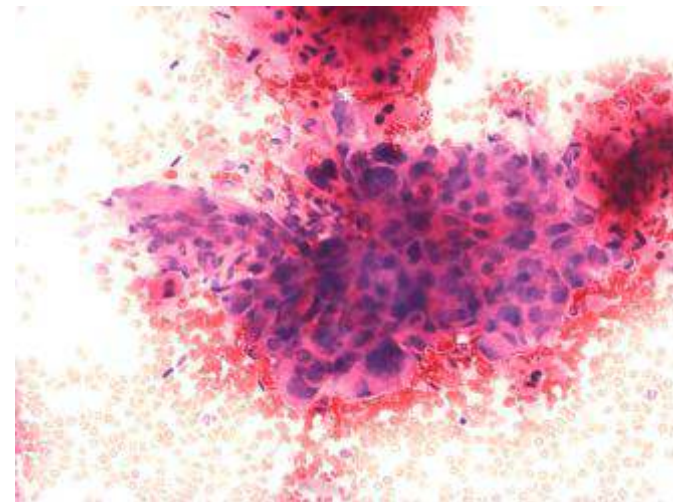
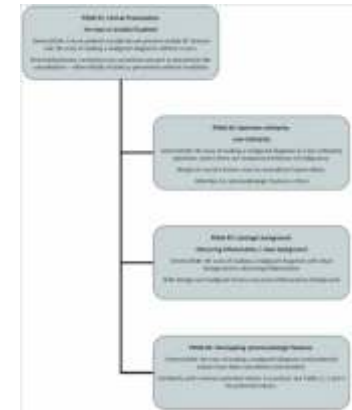Laphámsejtes carcinoma (SCC)

Elszarusodó laphámrákban
degeneratív, hyperchrom magok.

A kenet általában nem sejtdús.
Sok haemosiderin tartalmú
macrophag.

Diff.dg.:

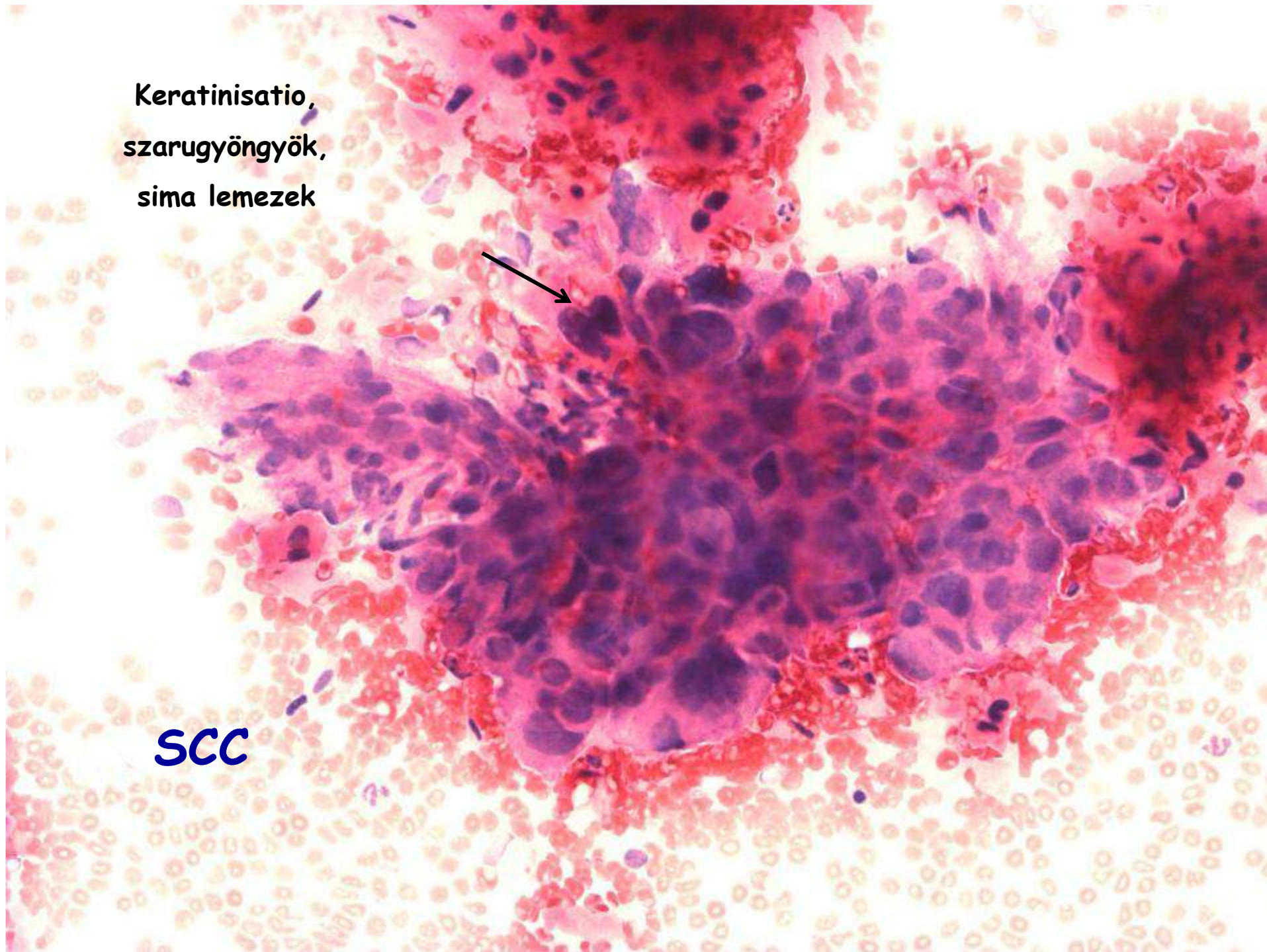
Laphám-metaplázia
- dohányzás, tracheostoma,
eszközös beavatkozás

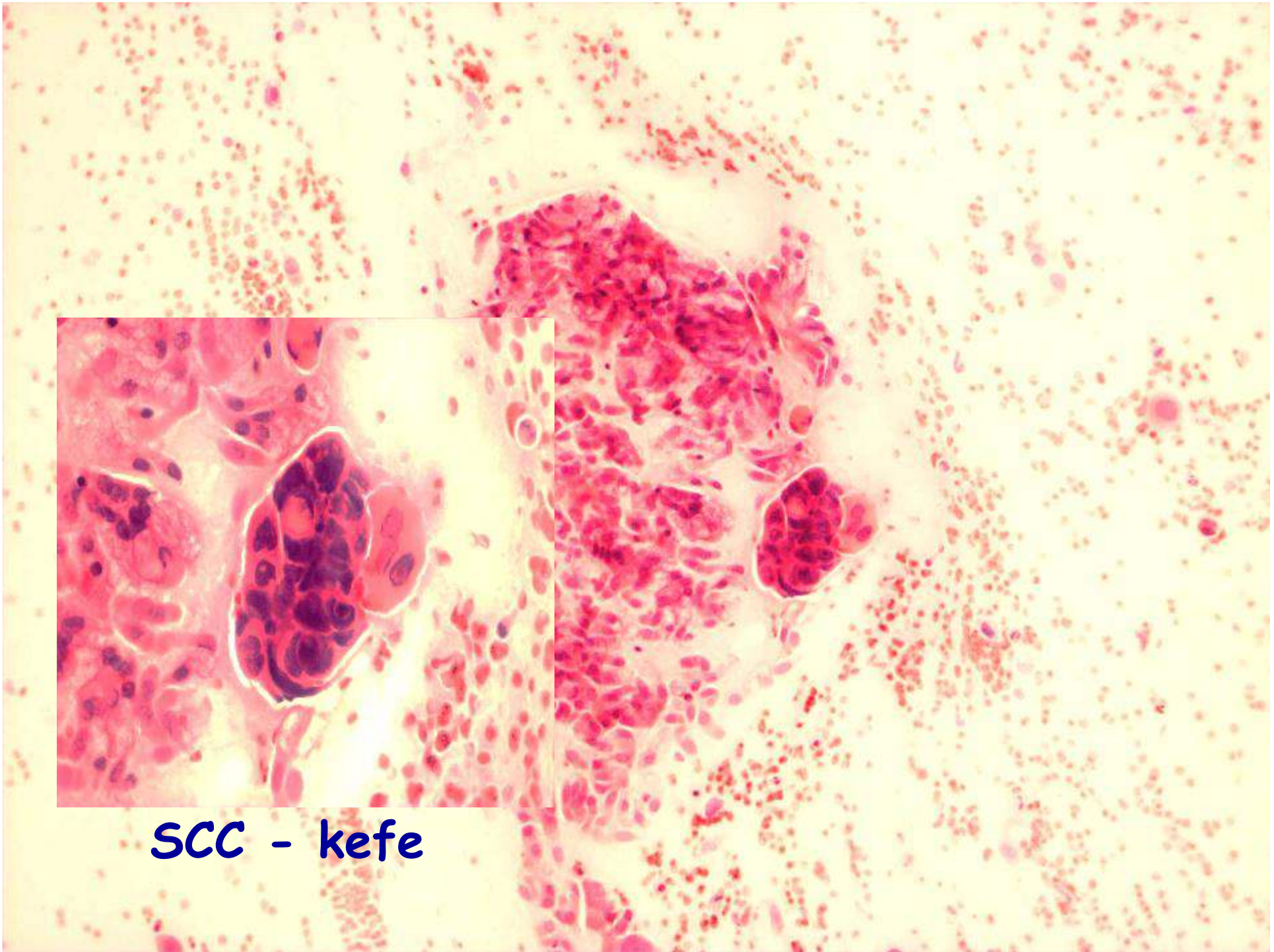


Keratinisatio,
szarugyöngök,
sima lemezek



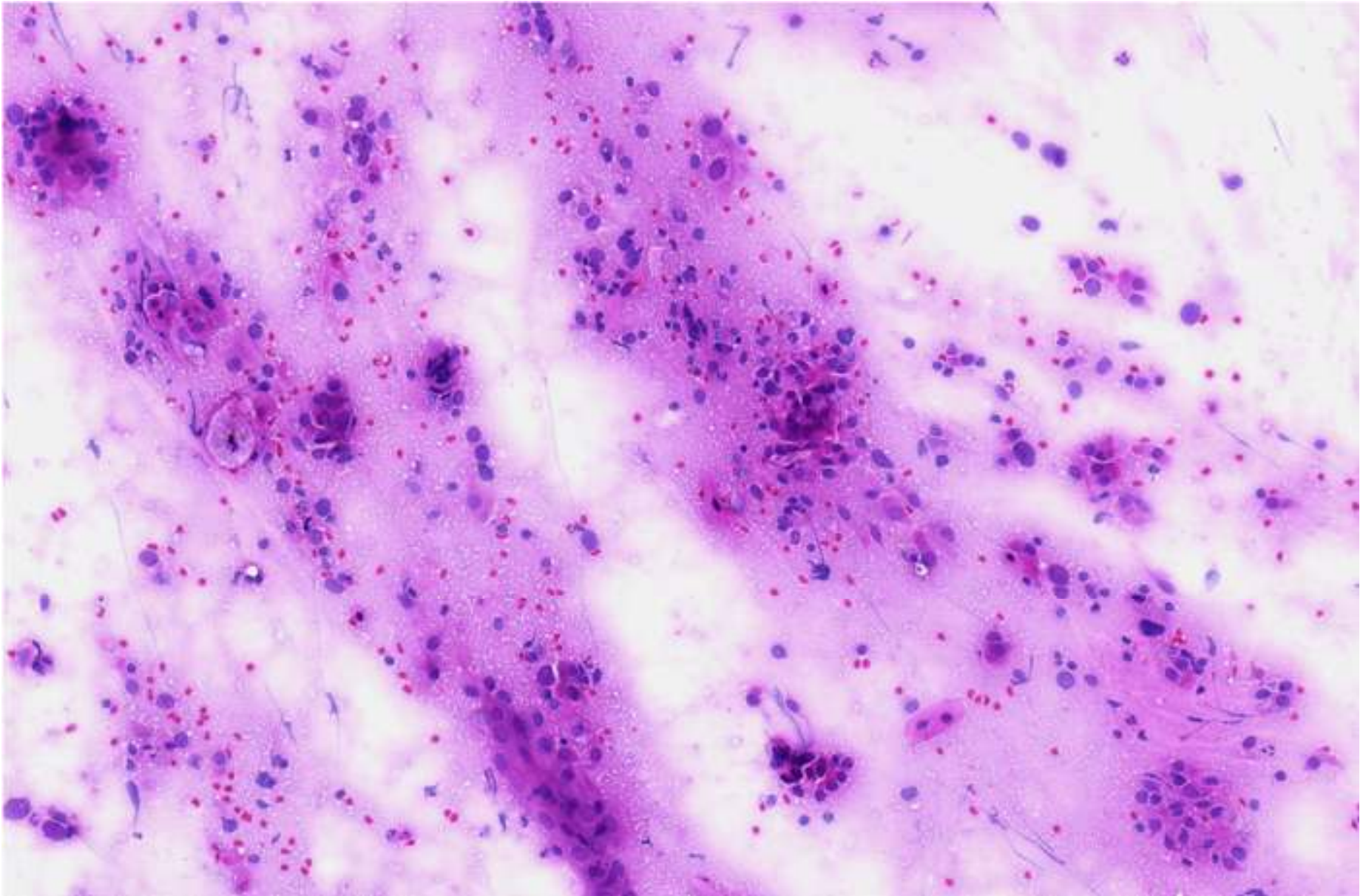
SCC



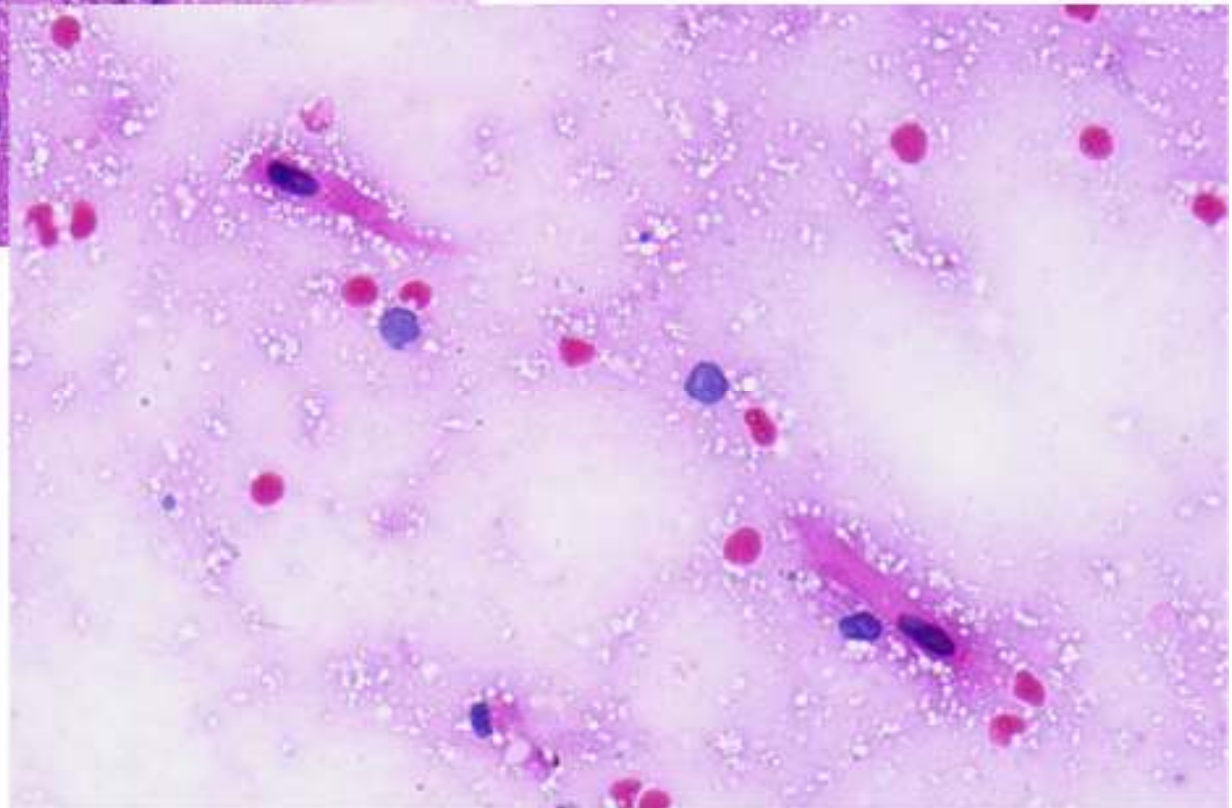
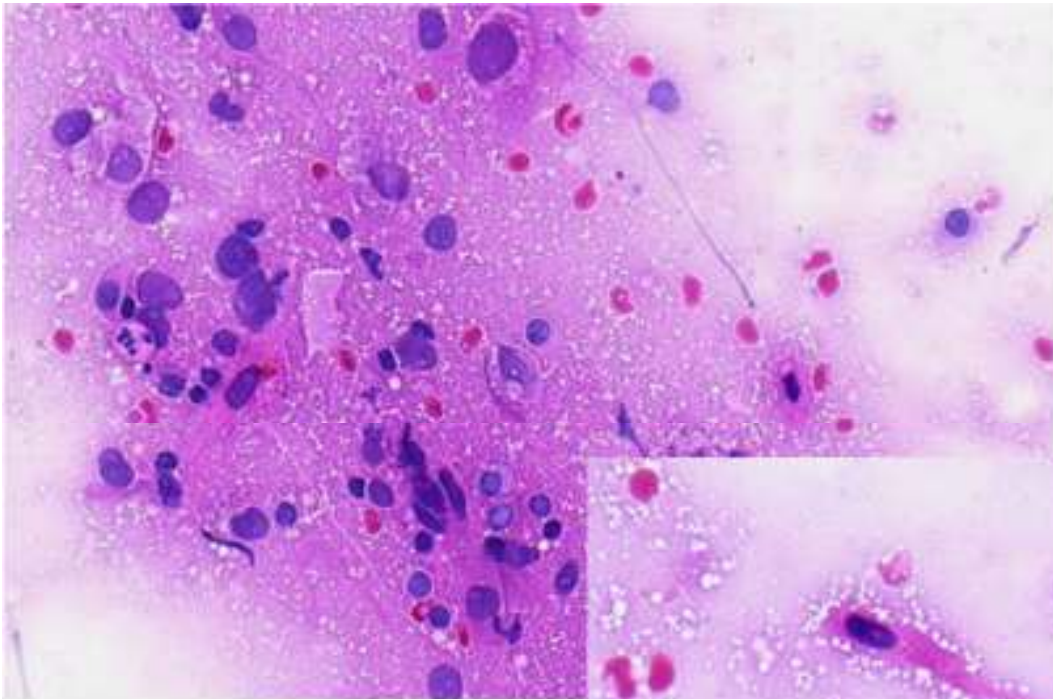


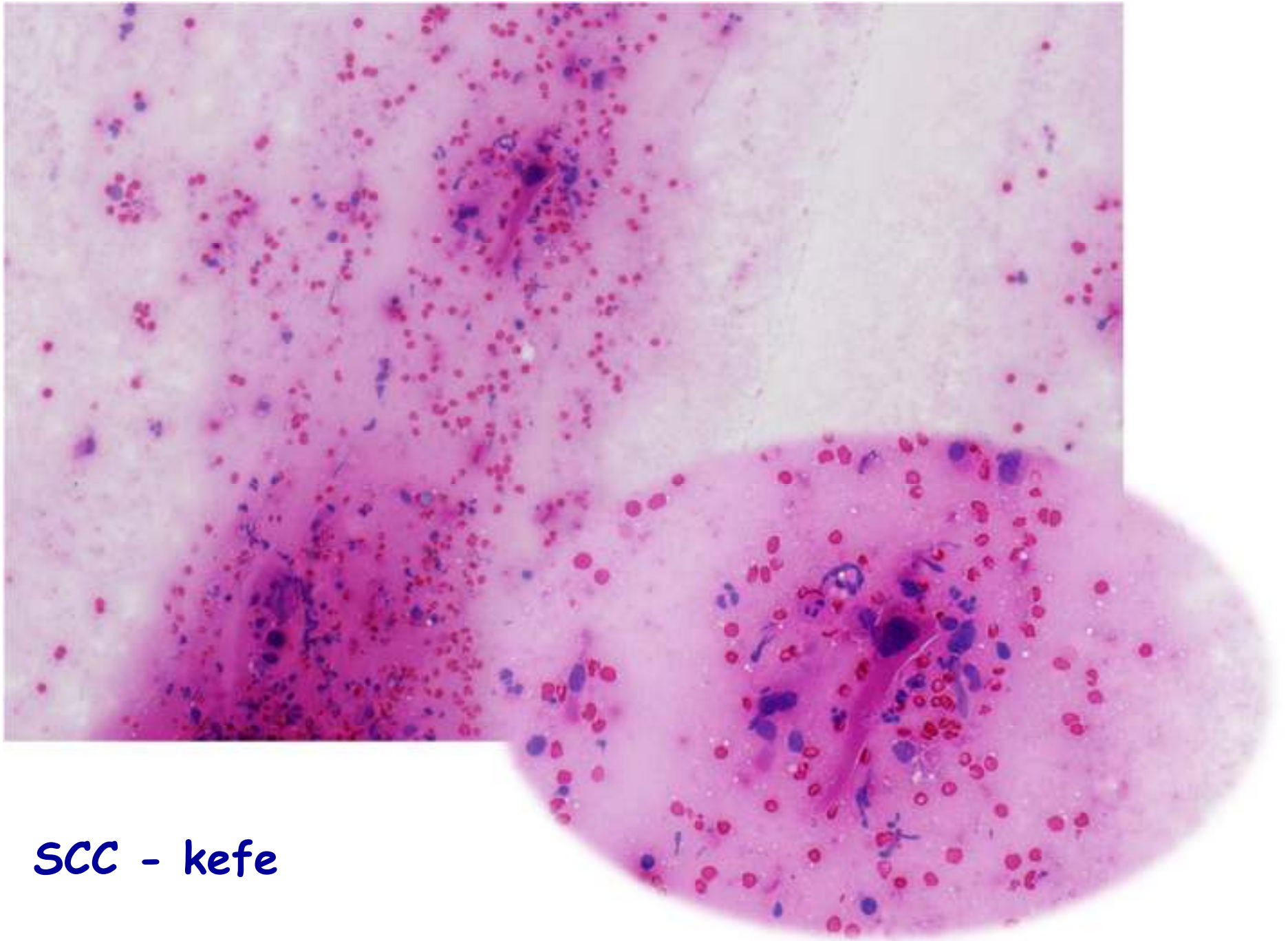
SCC - kefe

Kefe - SCC - fiber (szíj) sejtek

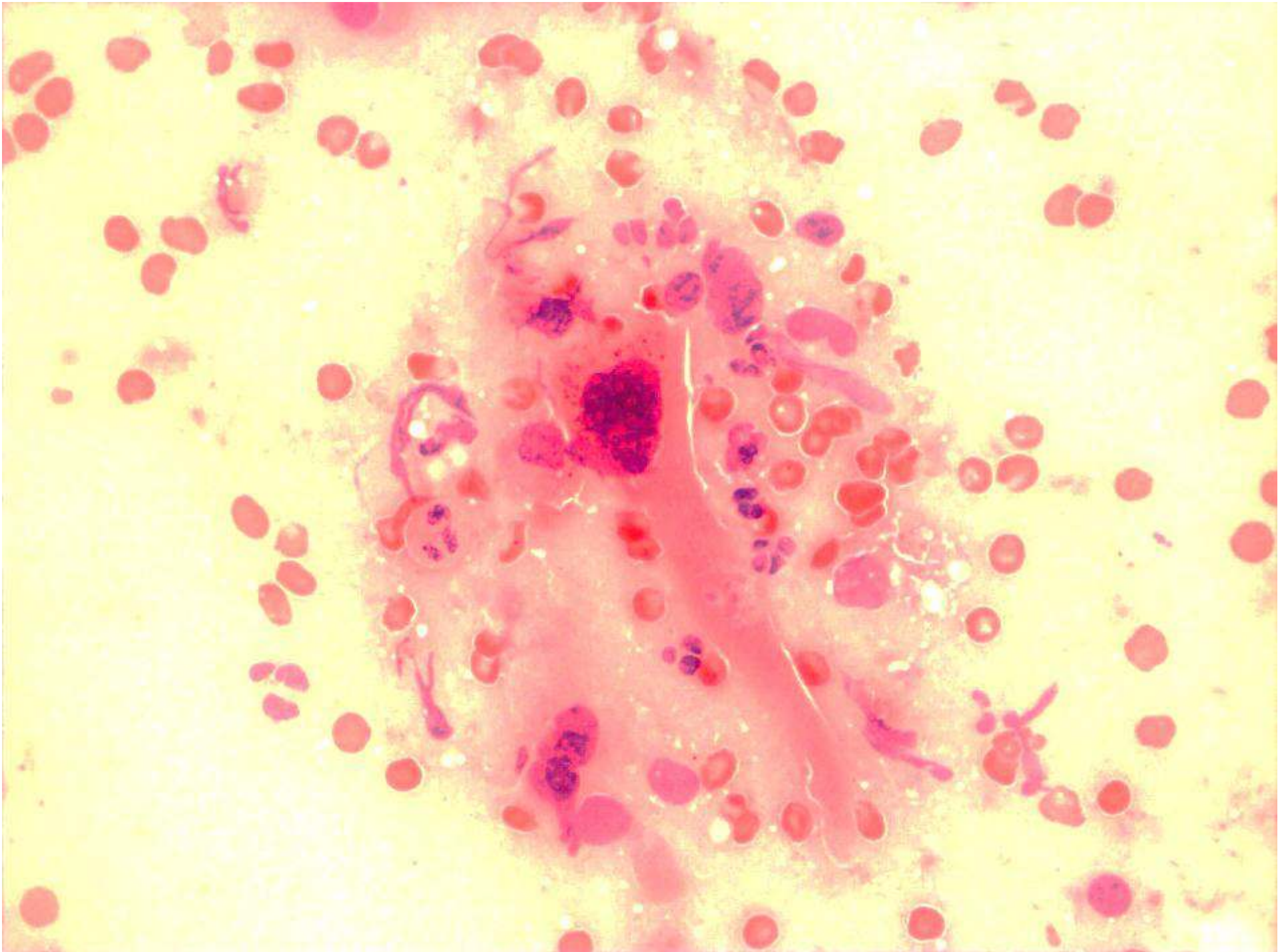


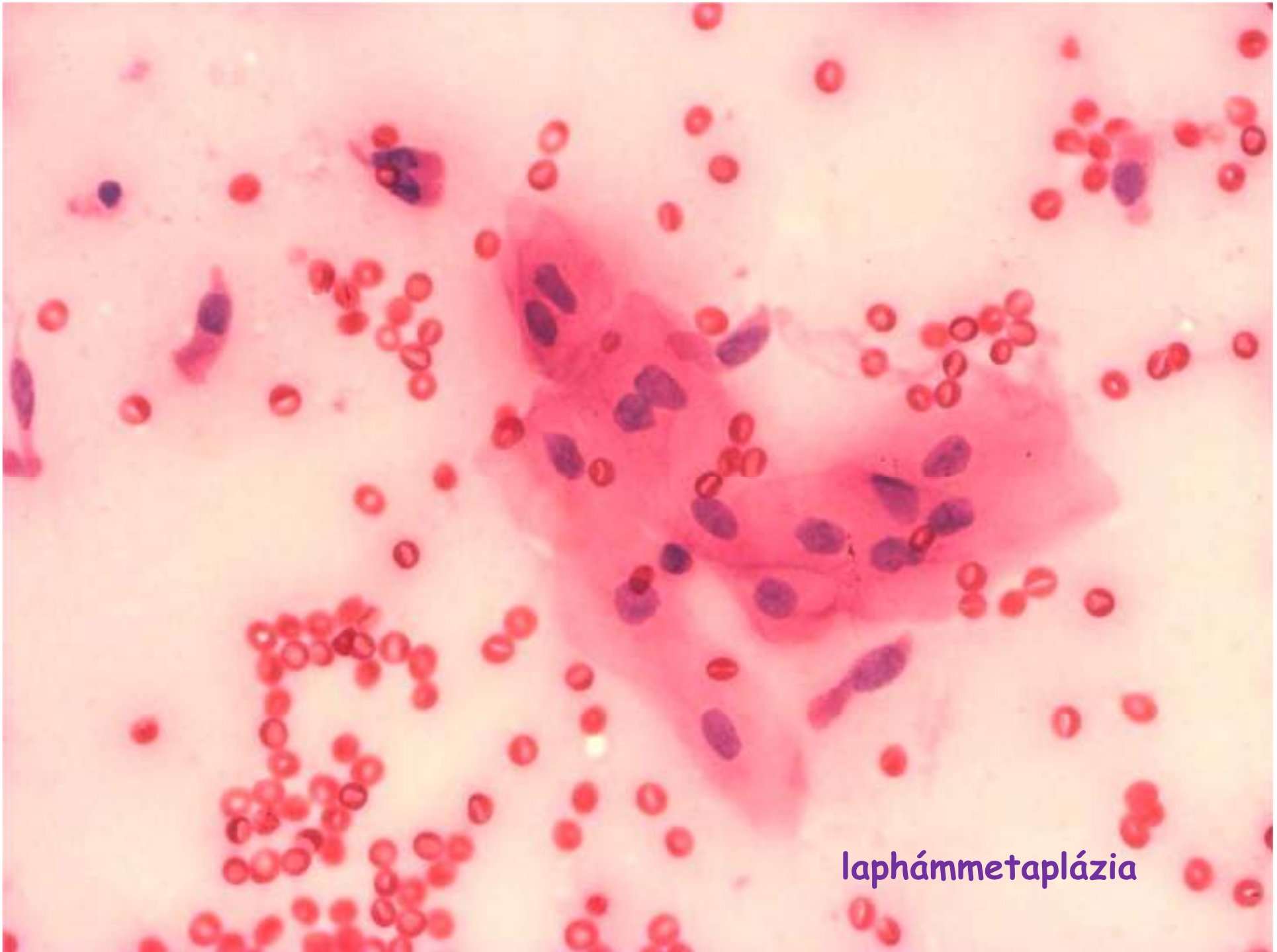
Kefe - SCC - fiber (szíj) sejtek





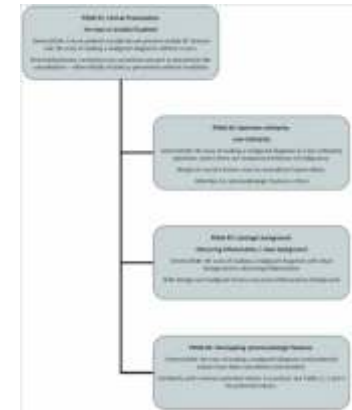
SCC - kefe





laphámmetaplázia

SCLC kissejtes carcinoma neuroendocrin kissejtes carcinoma



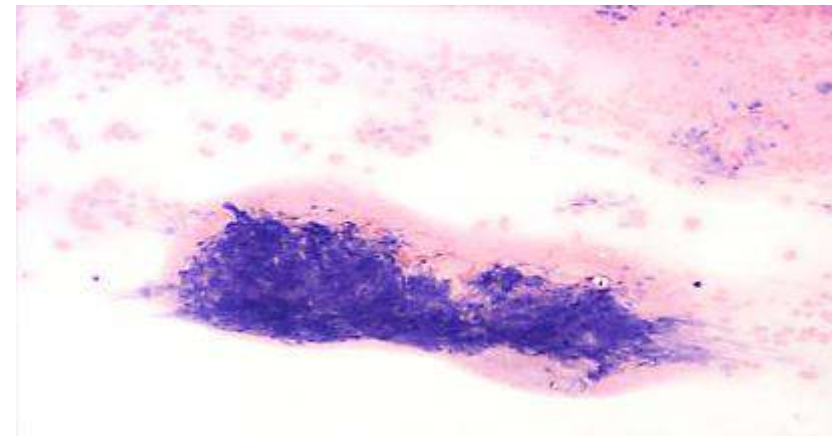
Diff.dg:

Carcinoid - típusos/atípusos

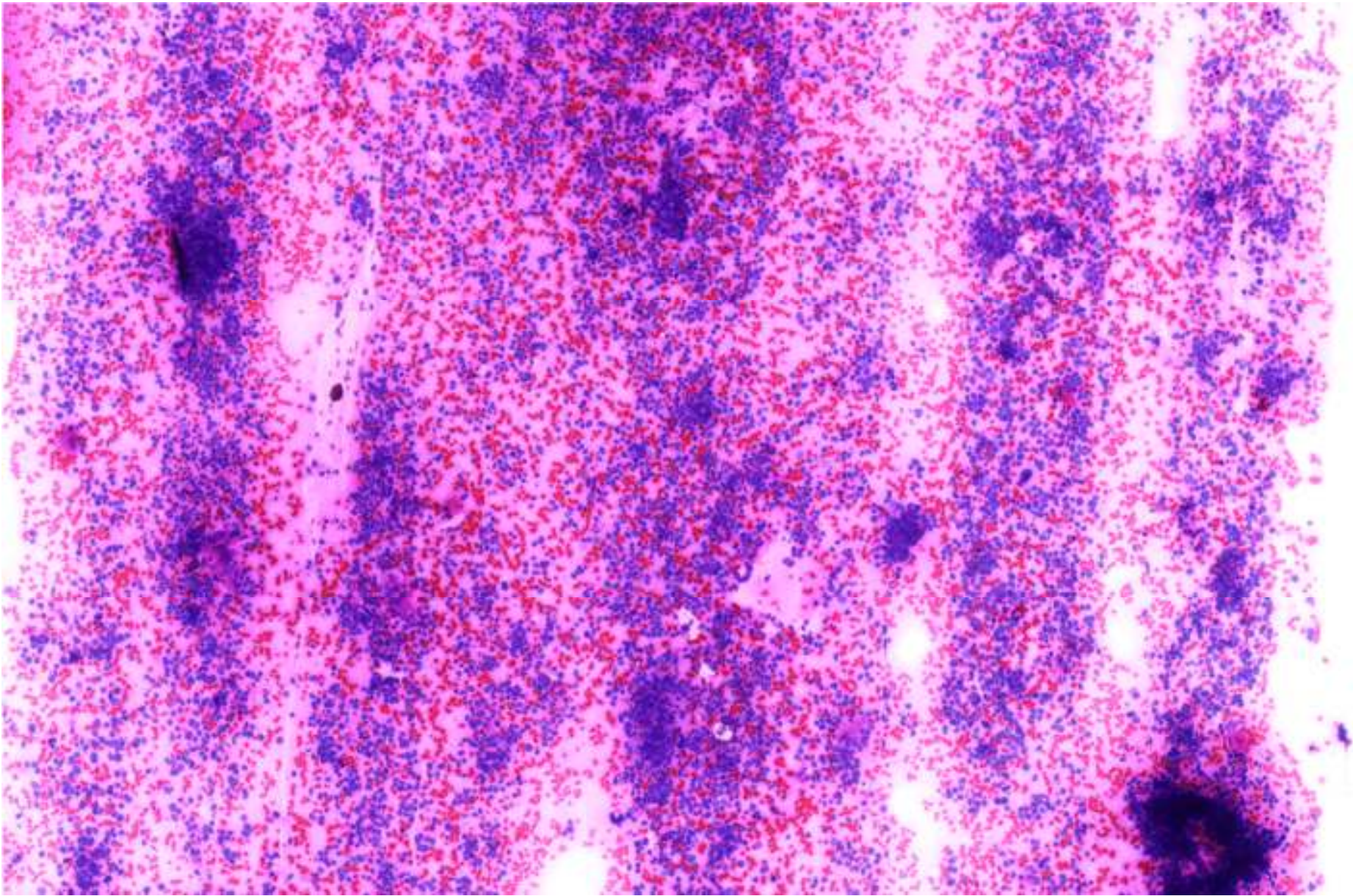
Lymphoproliferatív betegség

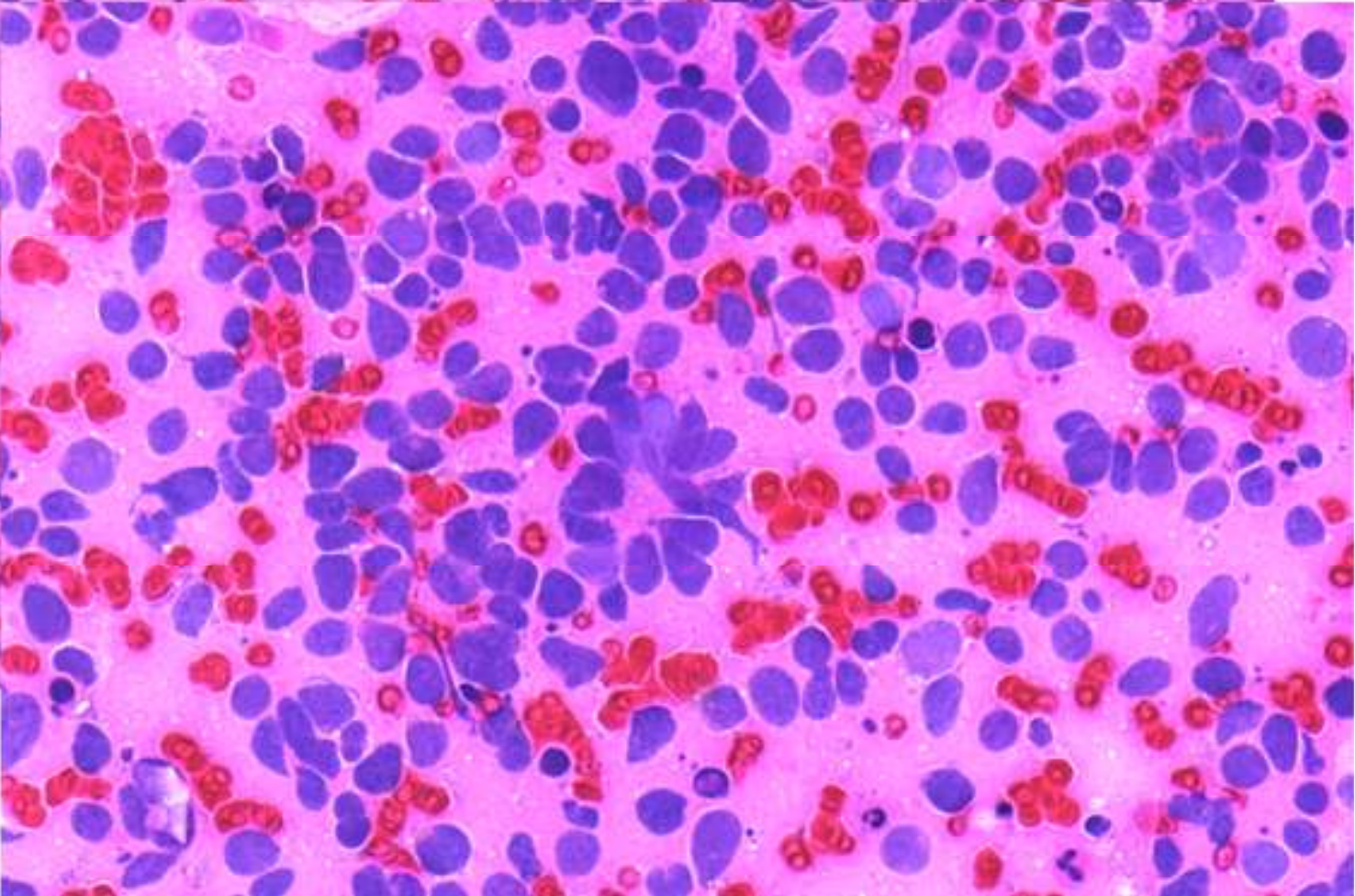
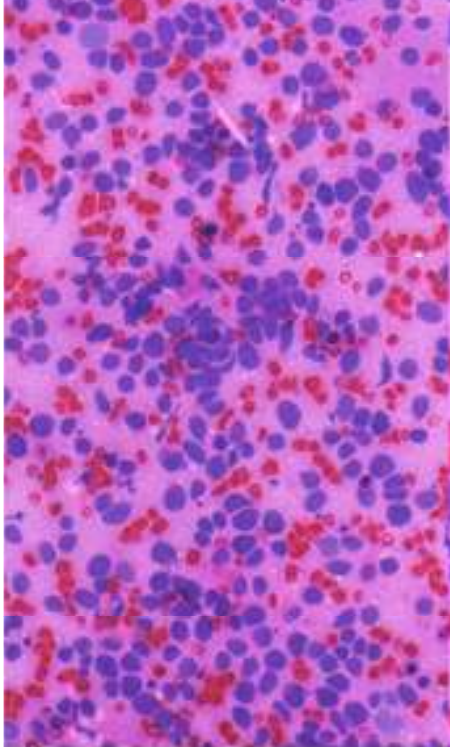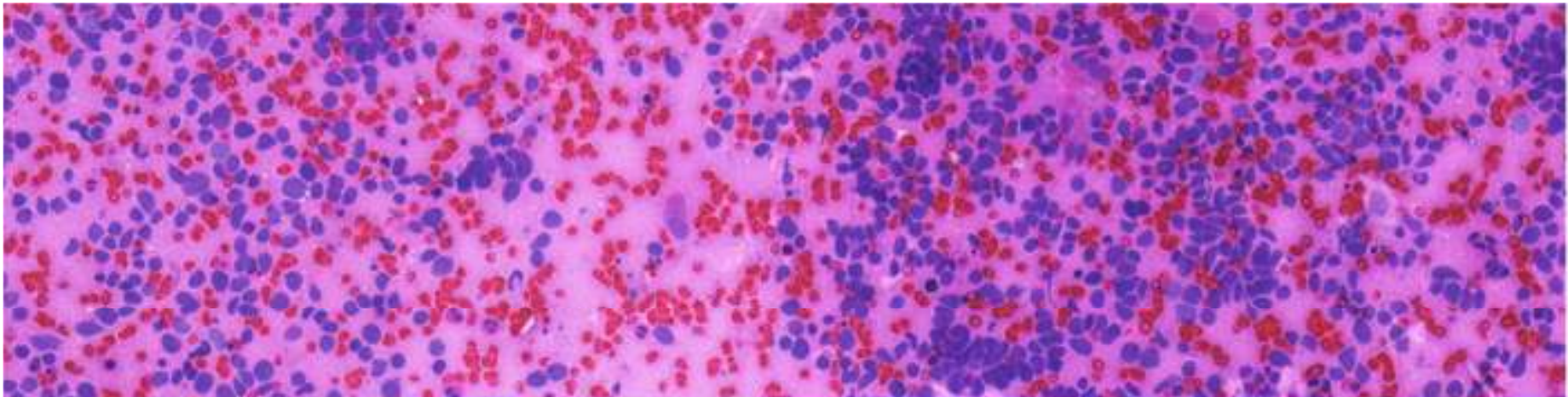
Rezerv sejtes hyperplasia

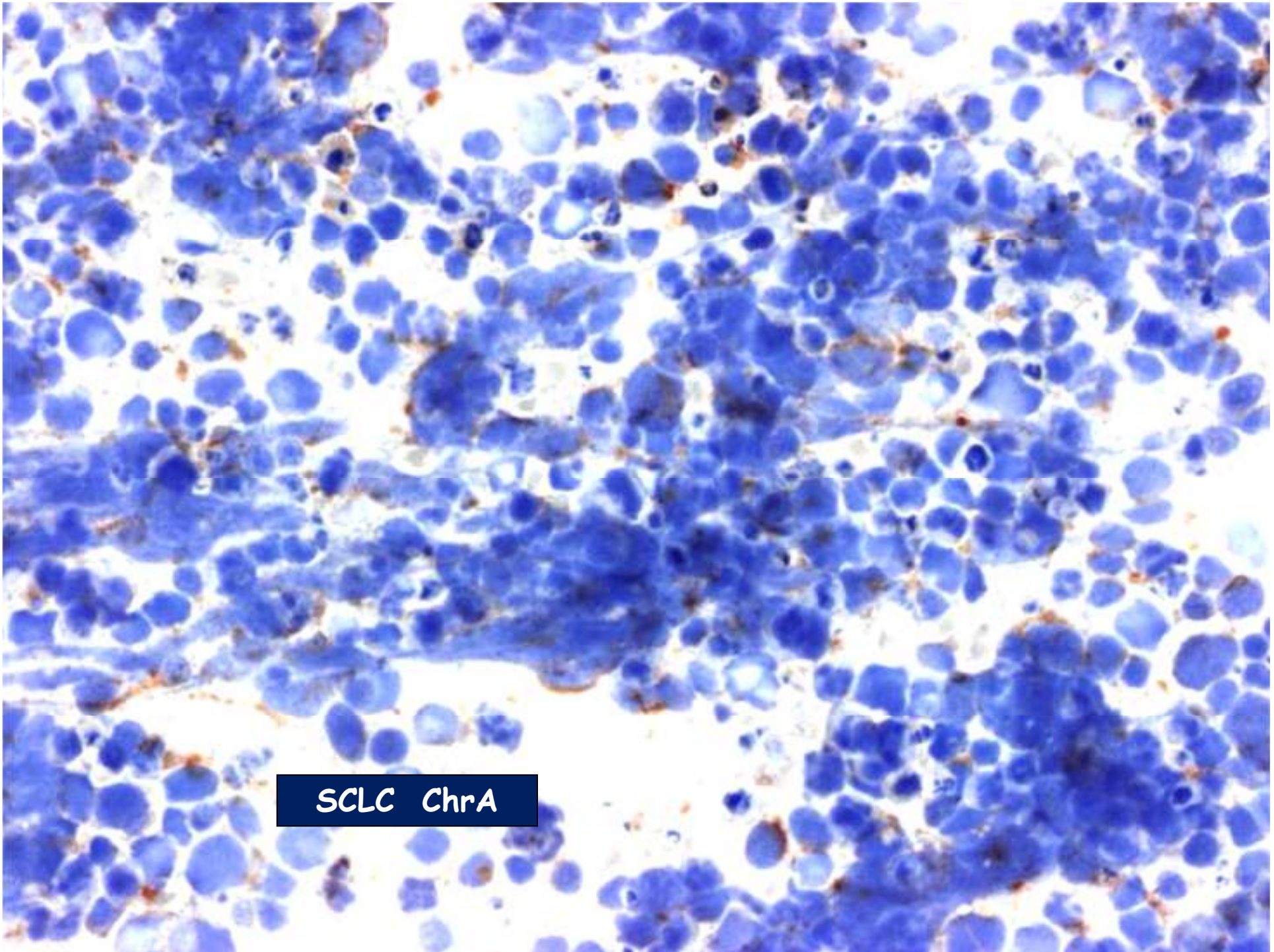
Basaloid laphámrák



Keefe: SCLC



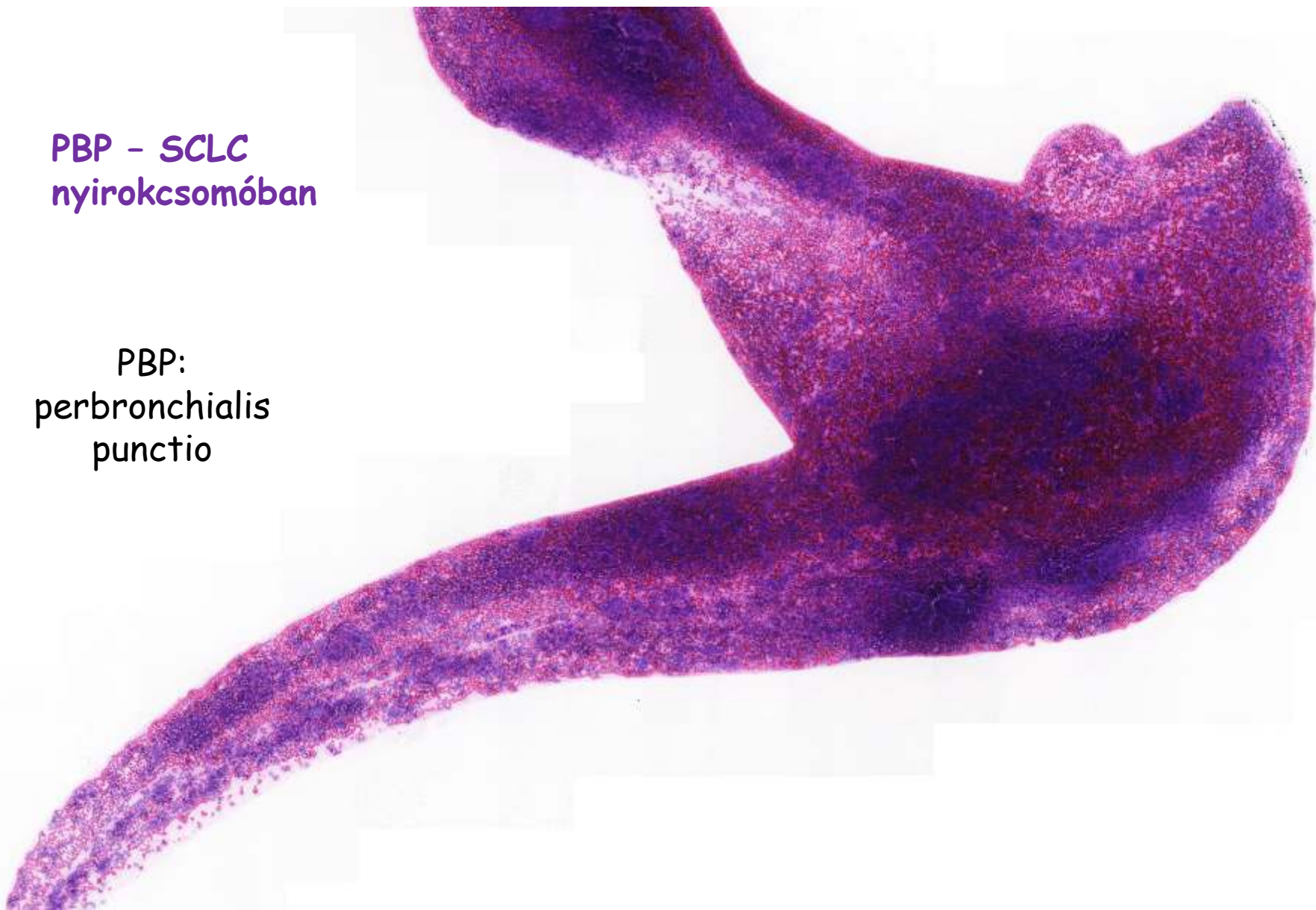


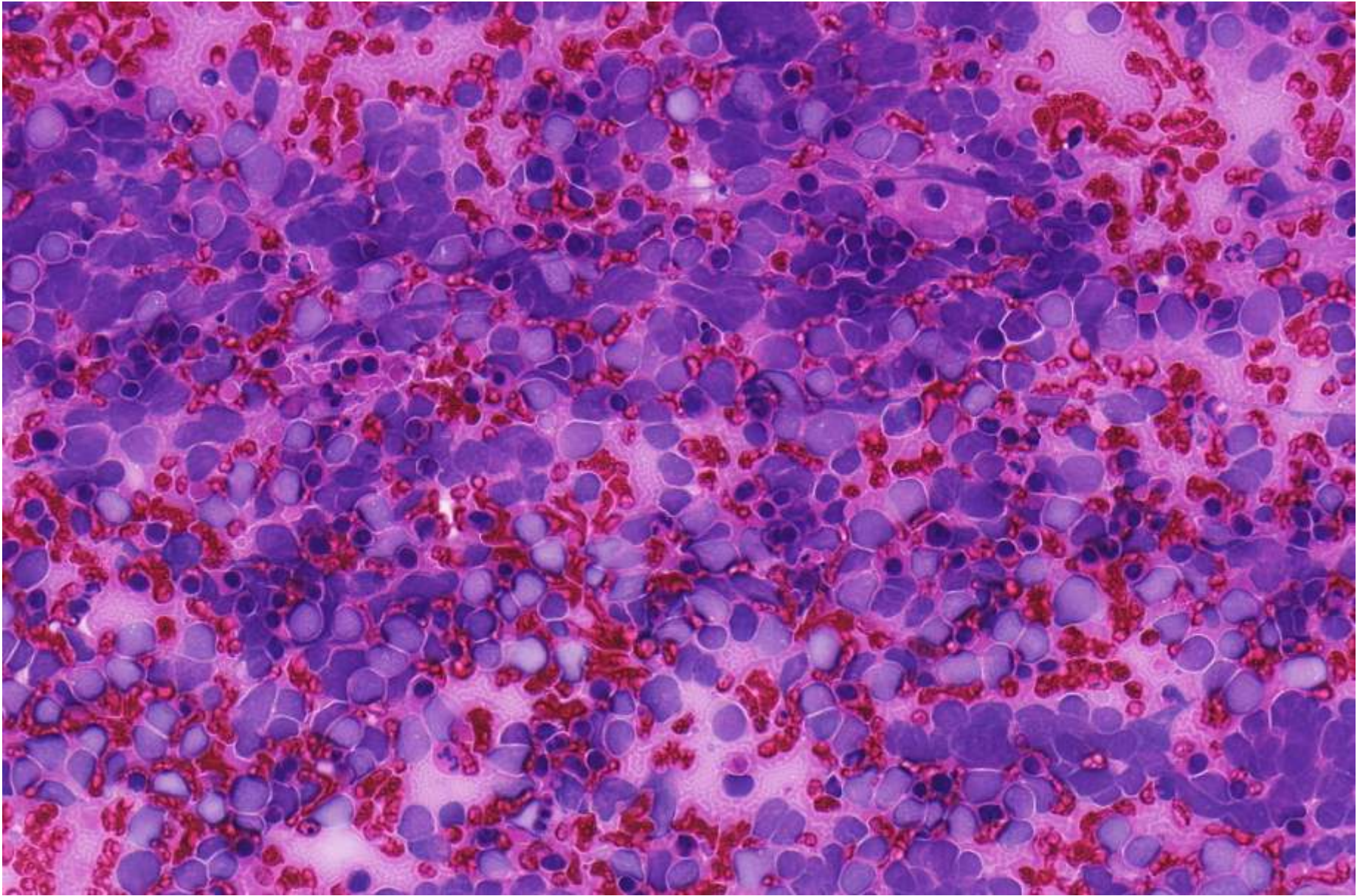


SCLC ChrA

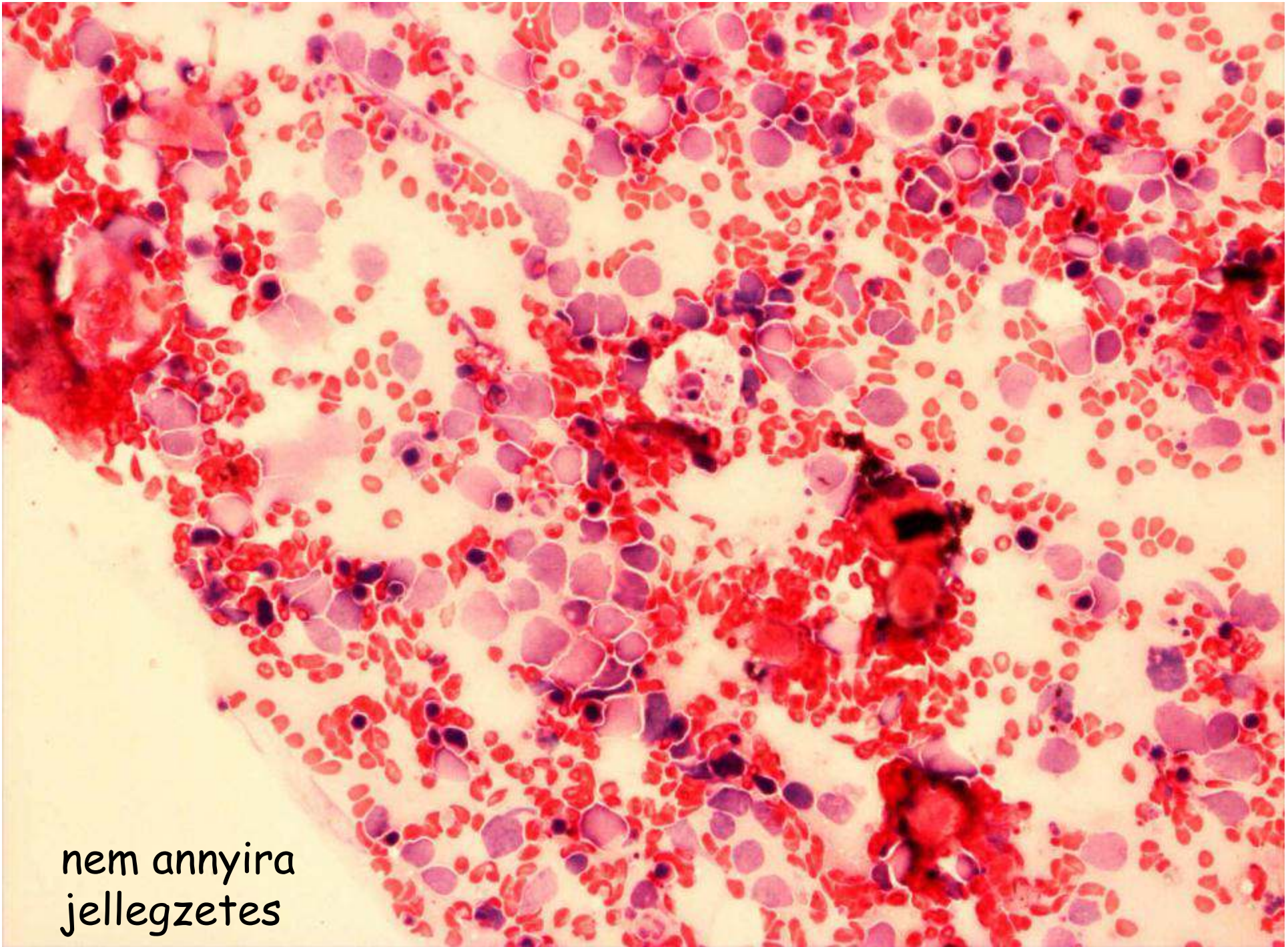
PBP - SCLC
nyirokcsomóban

PBP:
perbronchialis
punctio

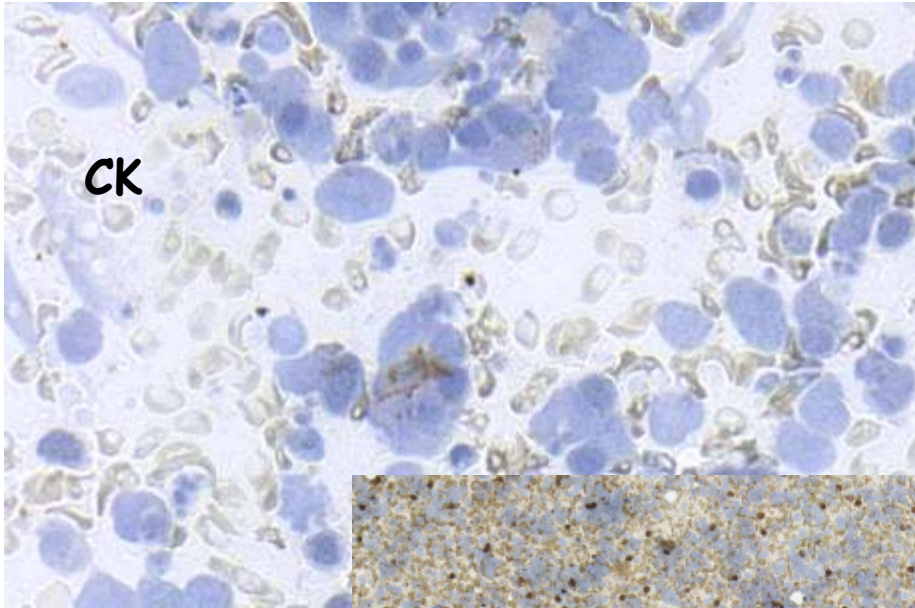




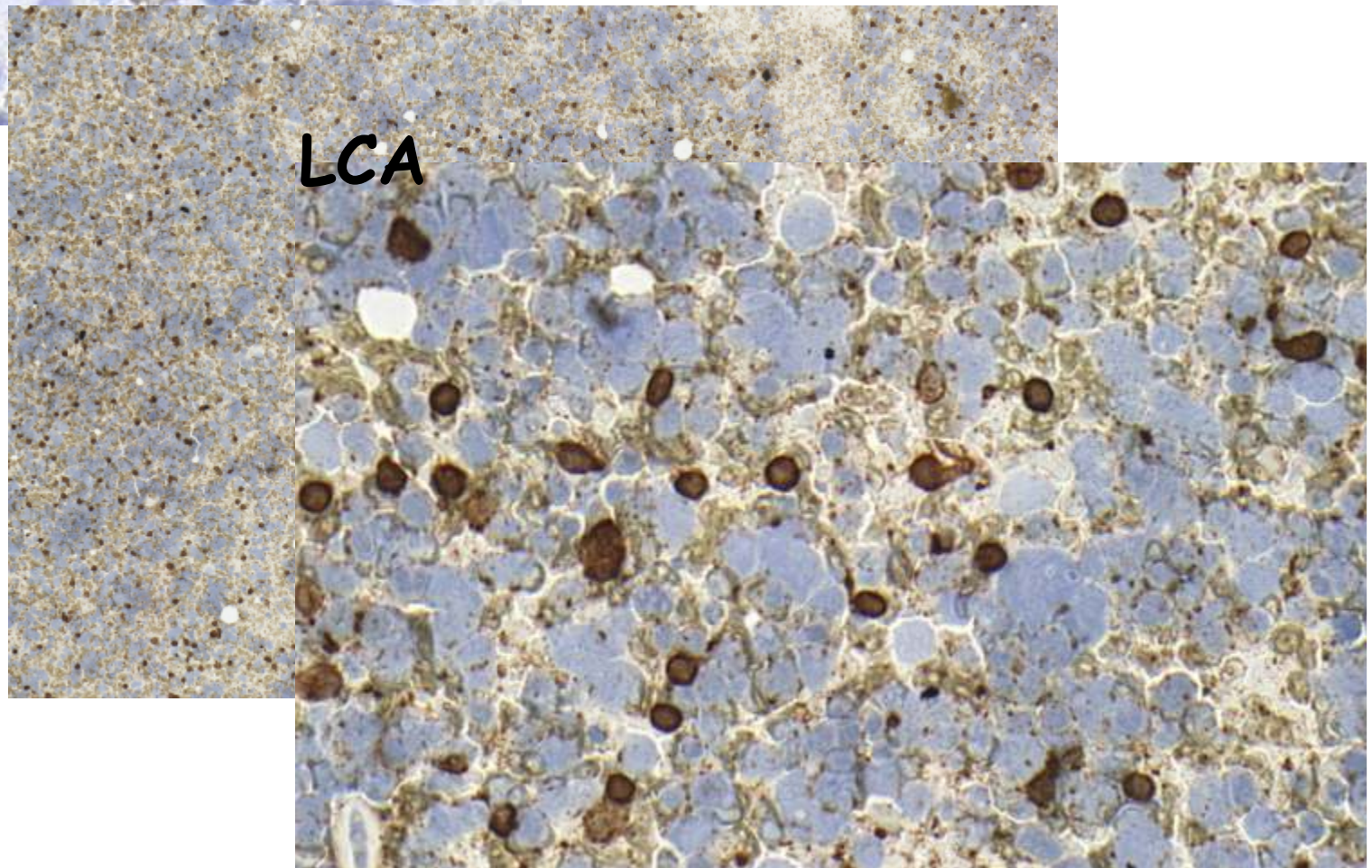
jellegetes

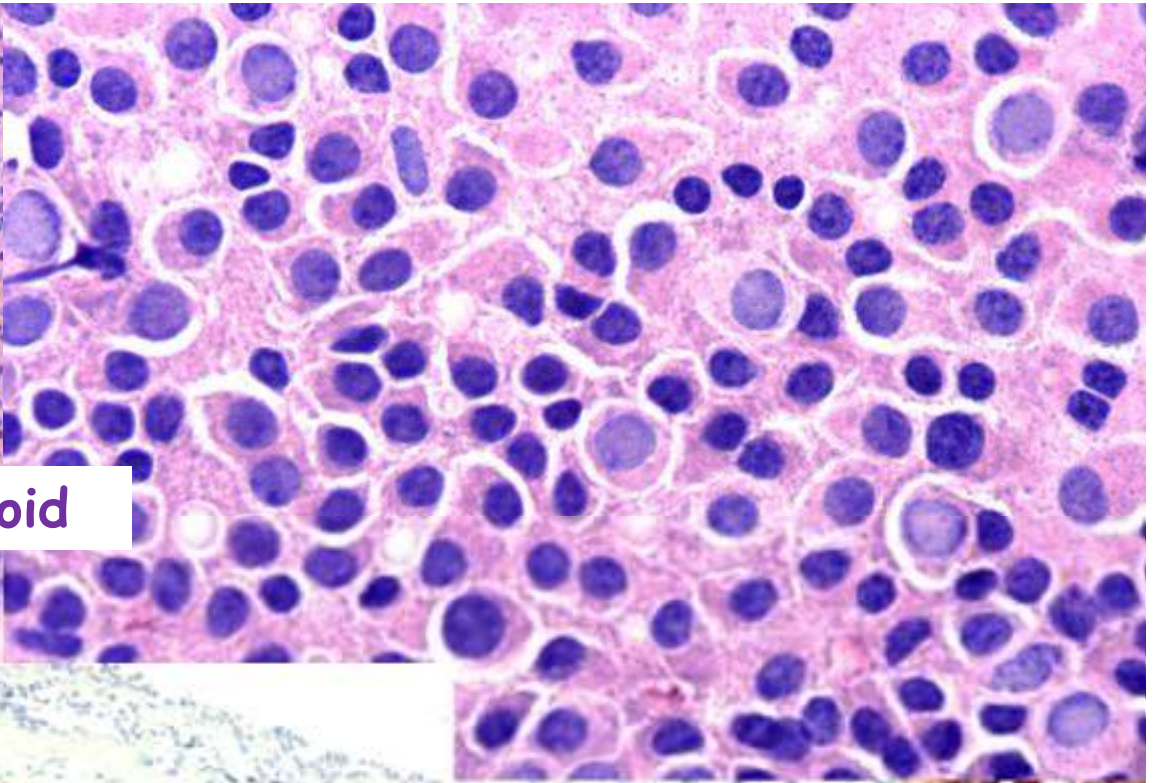
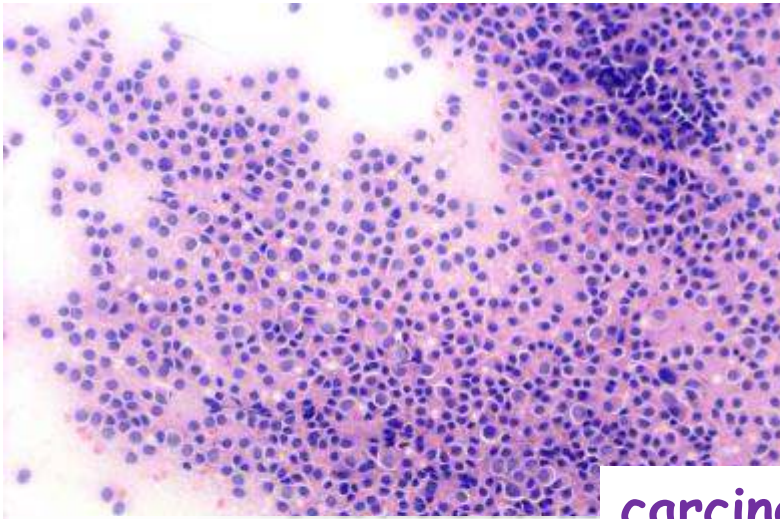


nem annyira
jellegzetes

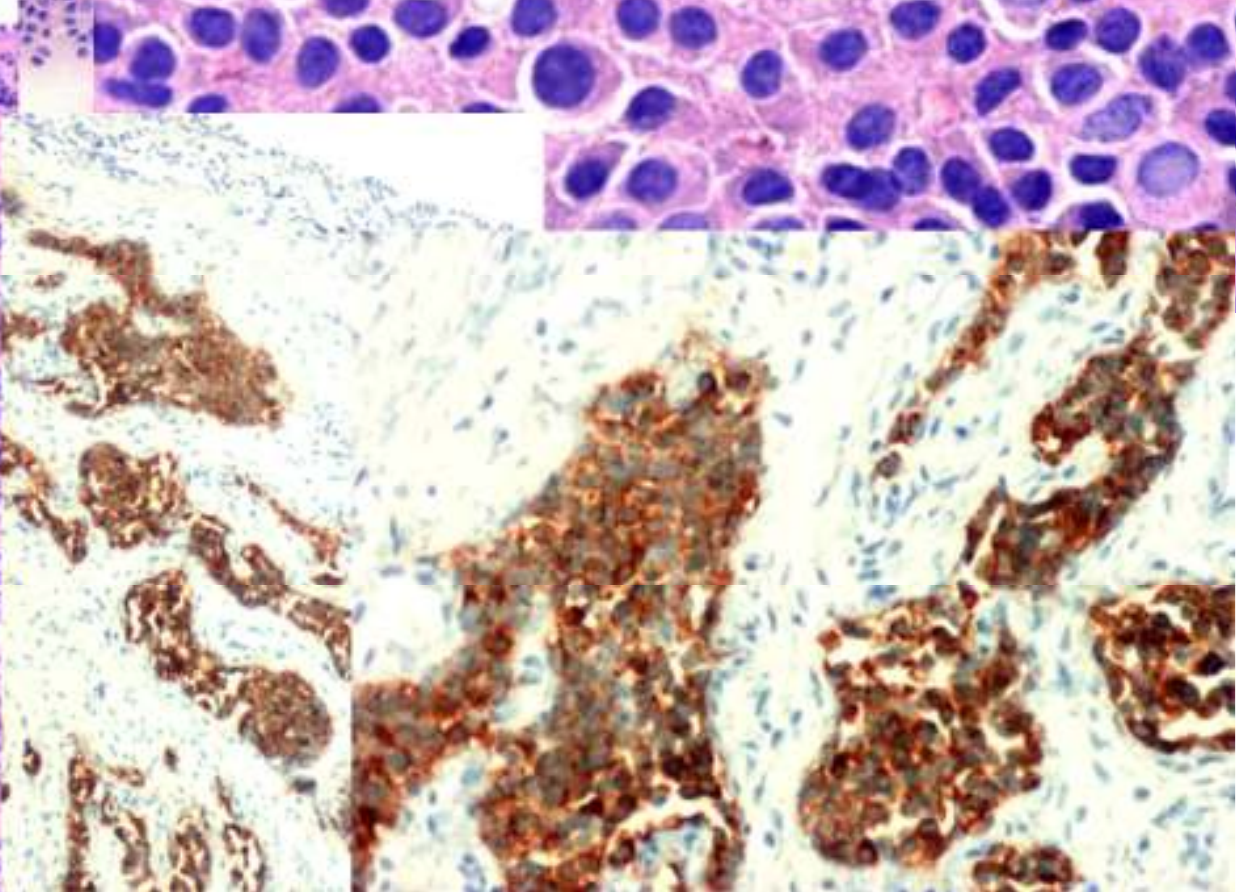
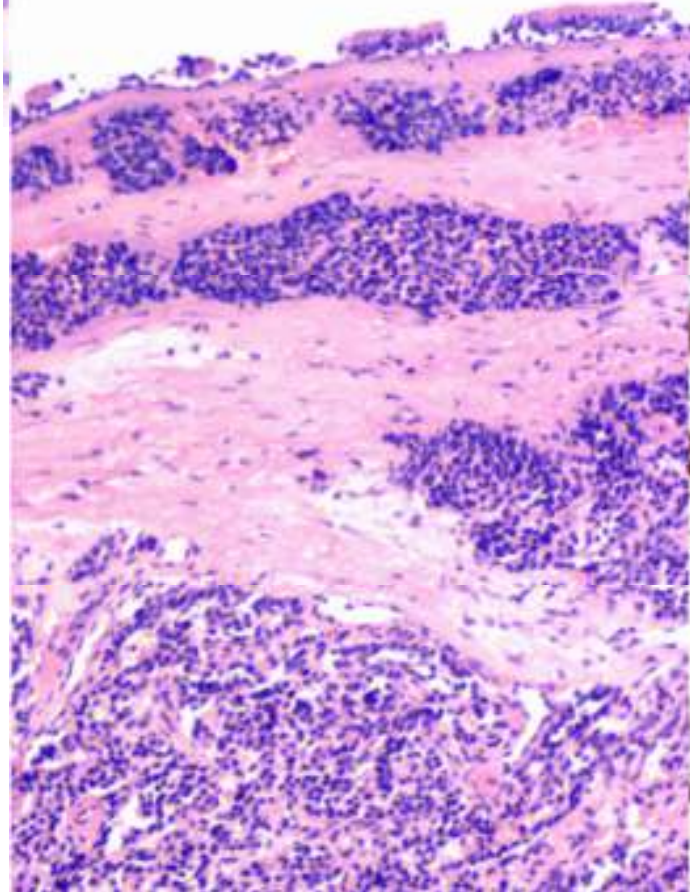


SCLC - nyirokcsomóban
CK, LCA

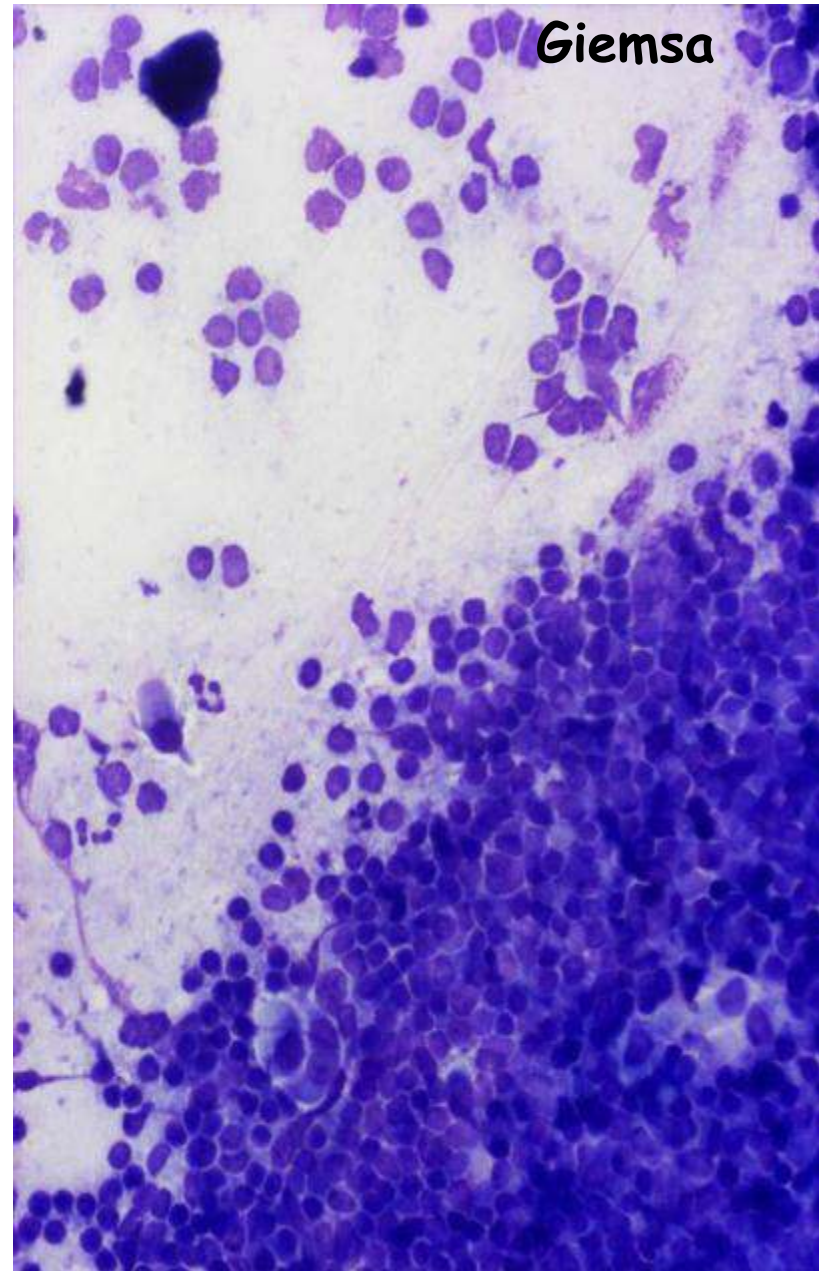
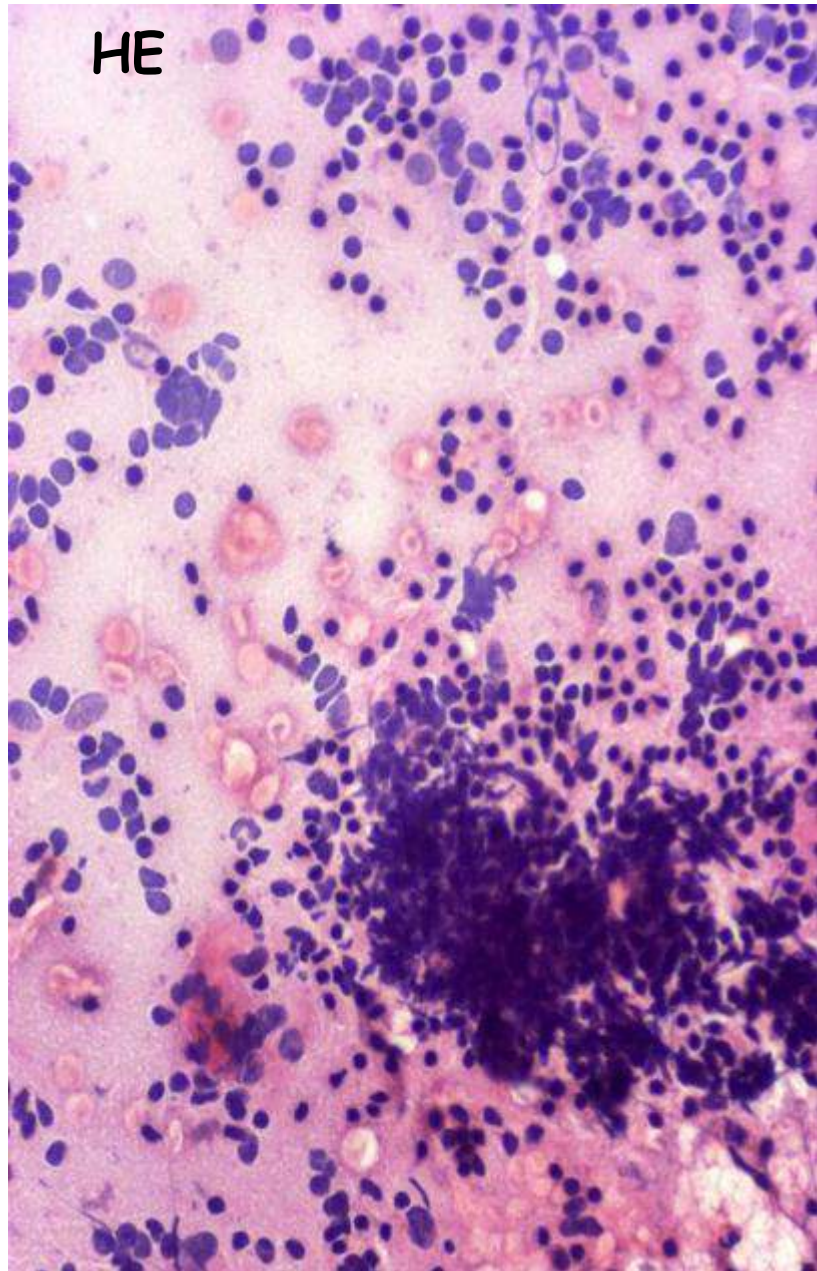




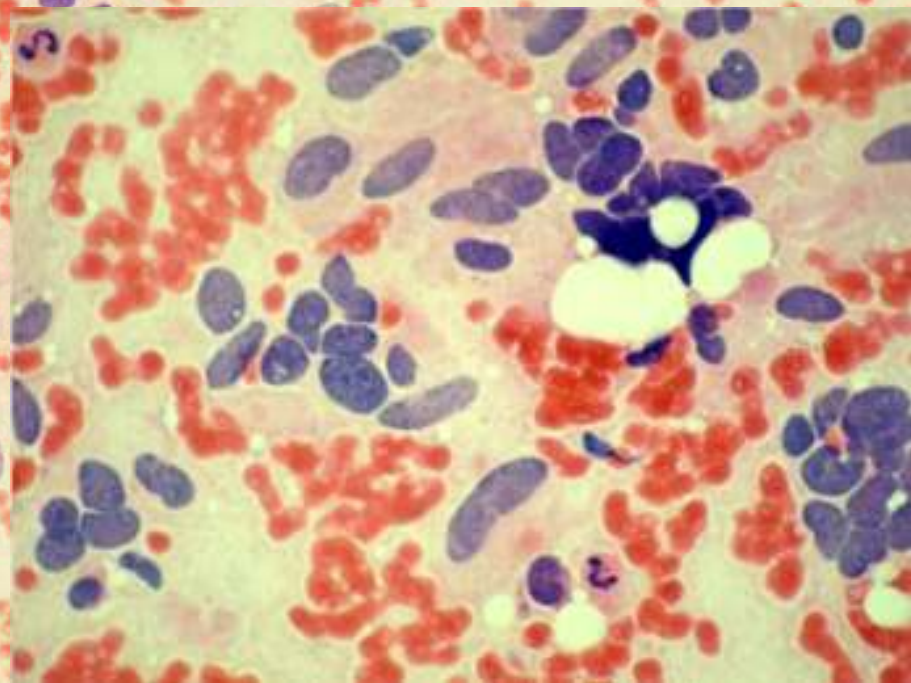
carcinoid



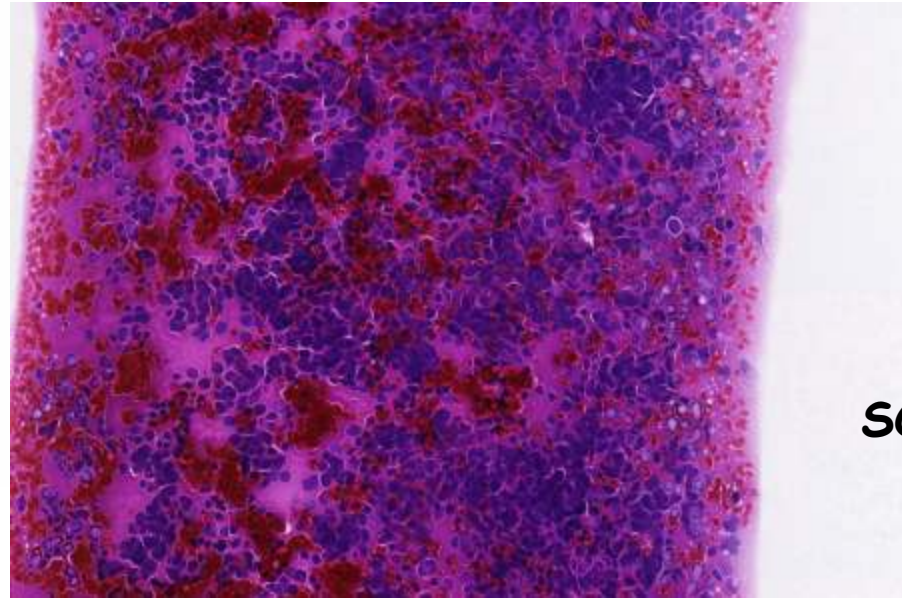
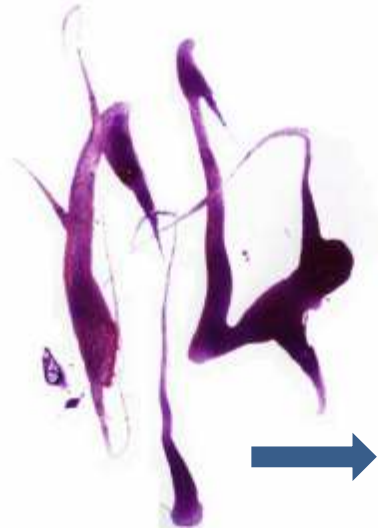lymphoproliferatív betegség



**synovialis
sarcoma**



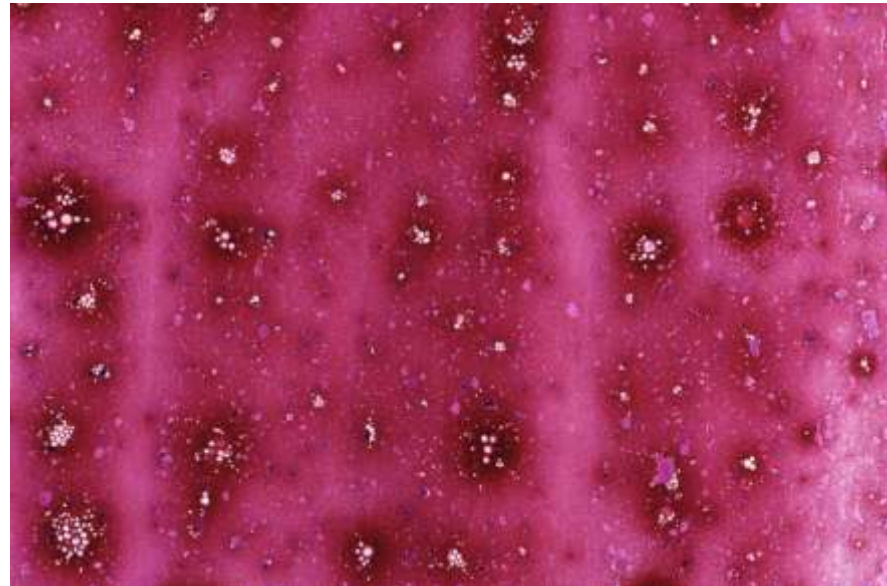
PBP



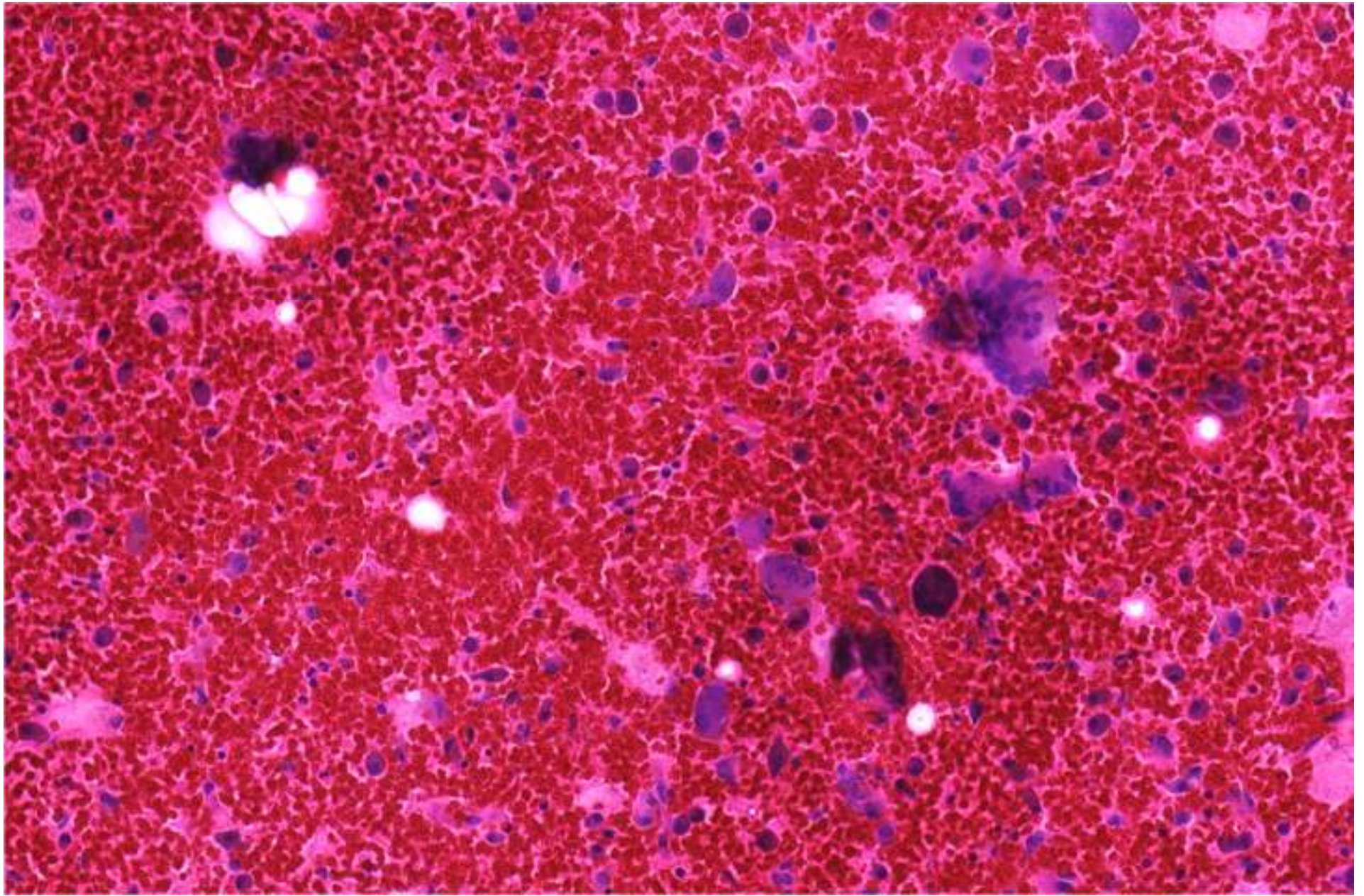
SCLC

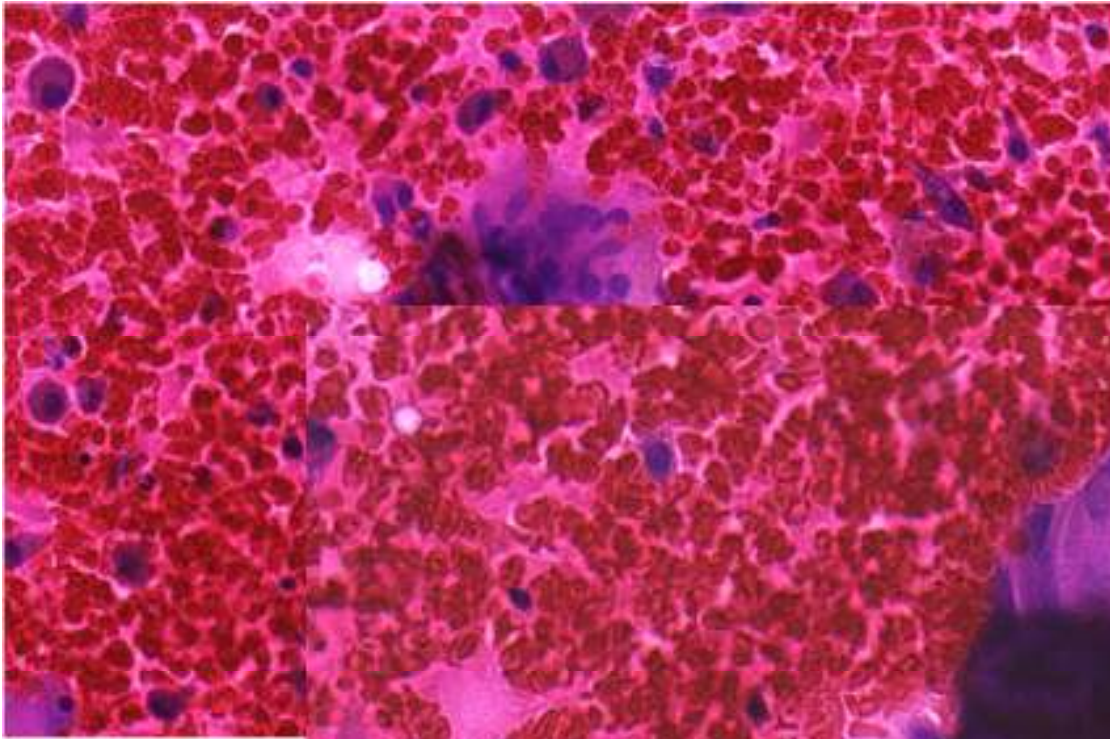
1 beteg

**Perifériás
kefe**

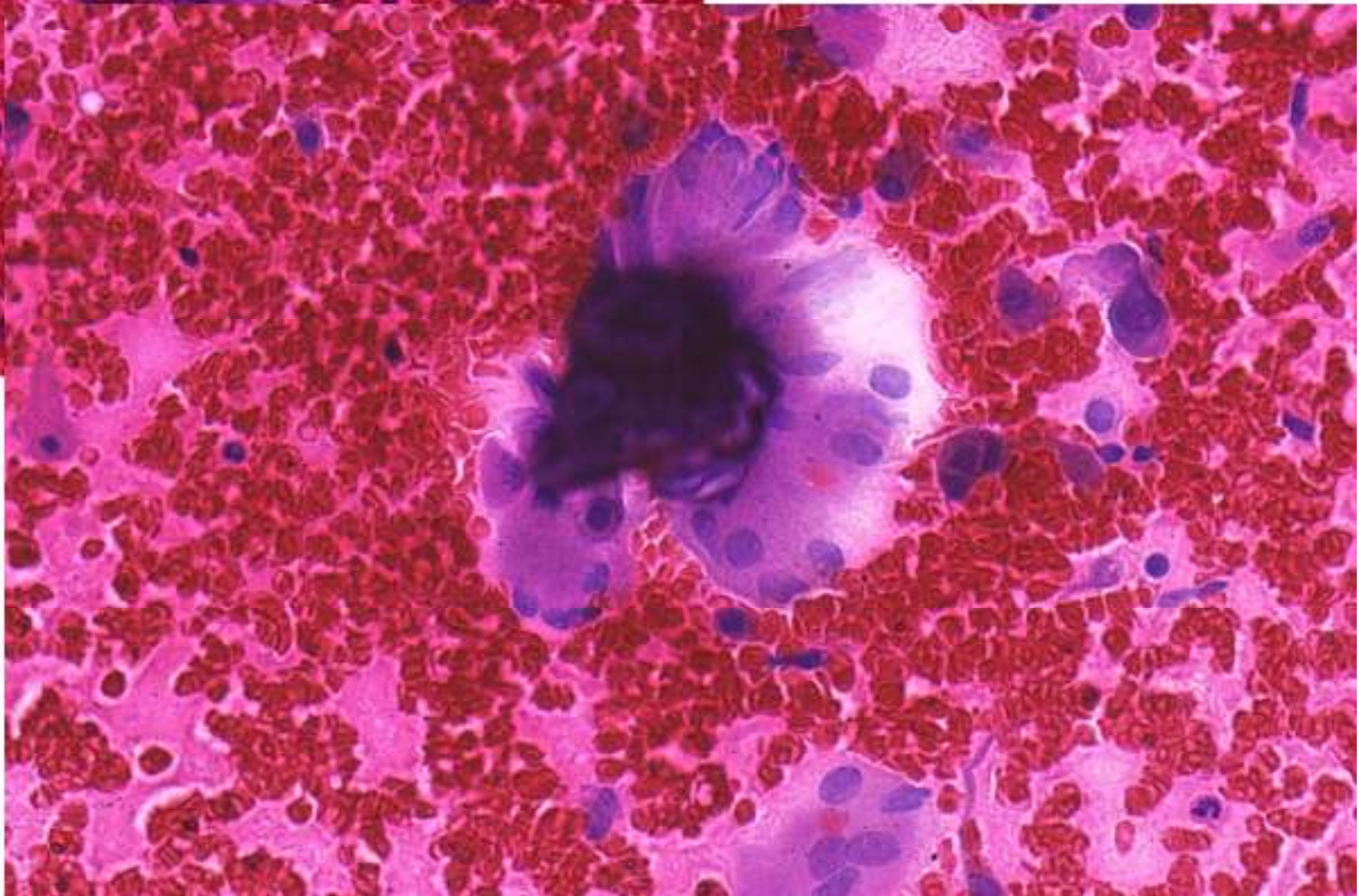


?

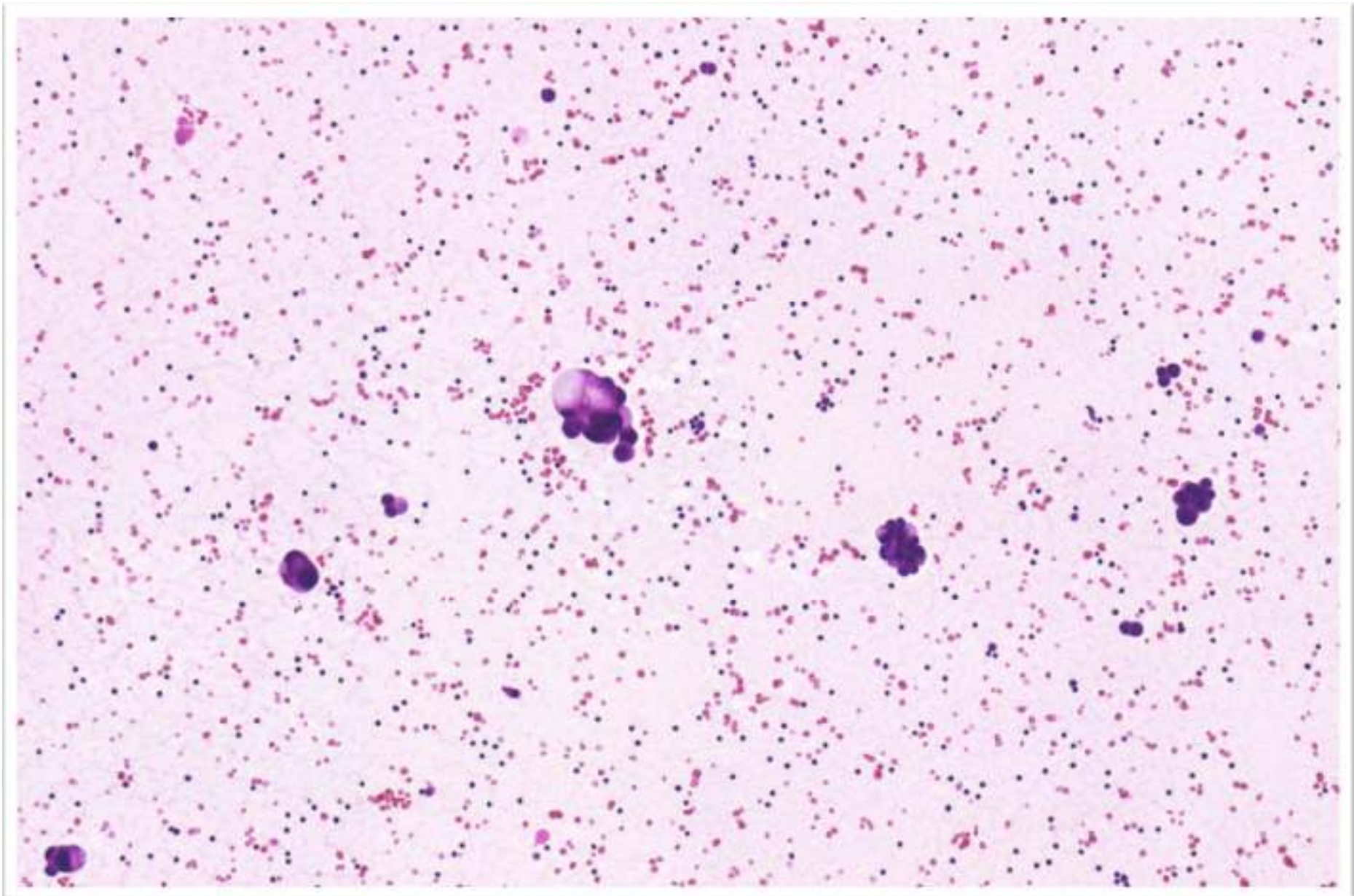


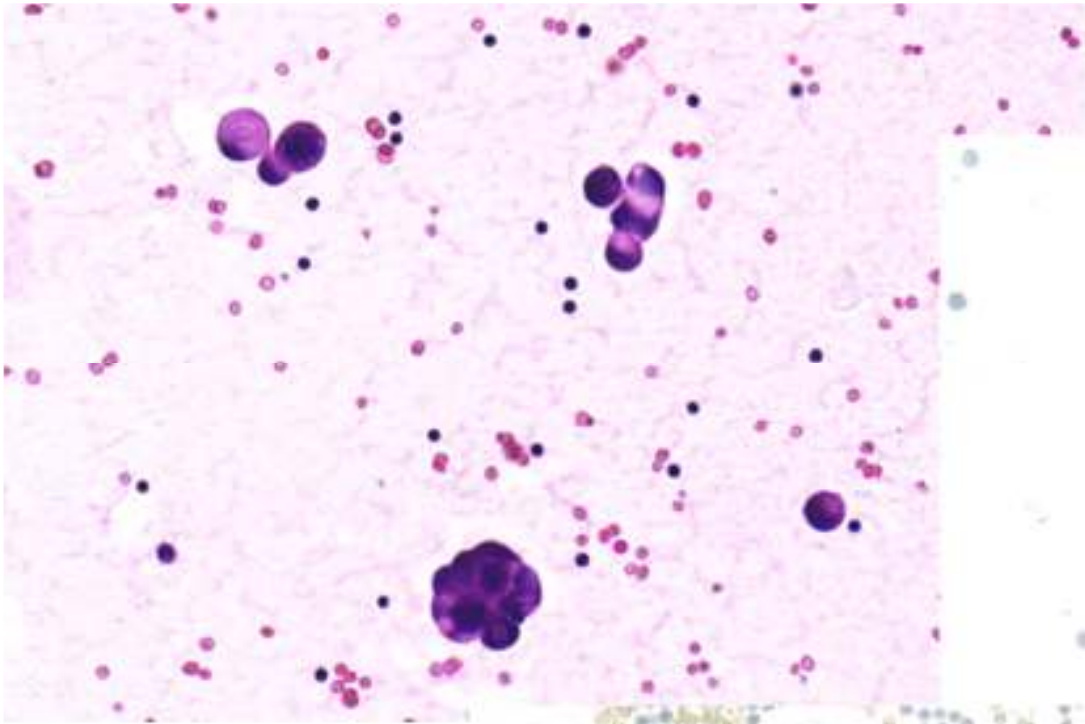


?

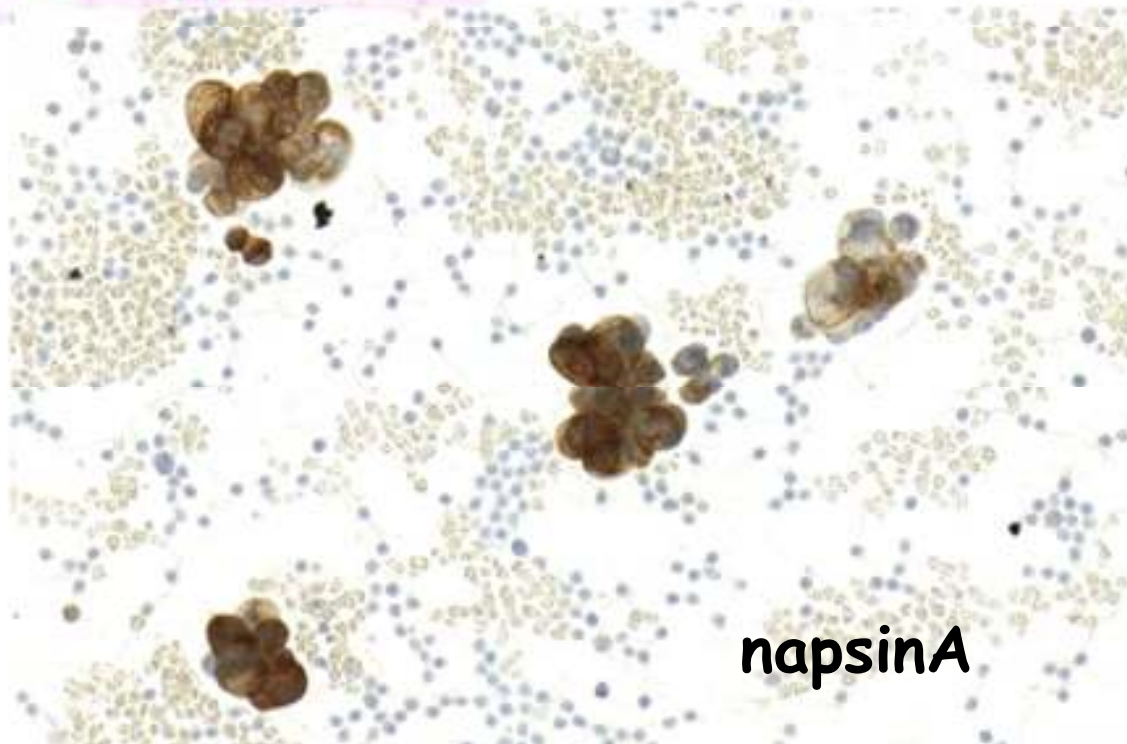
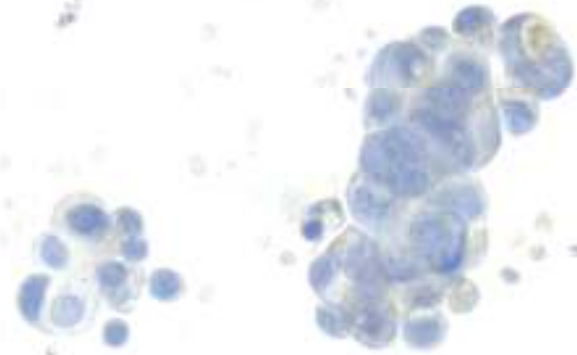


Mellkasi folyadék HE





TTF1

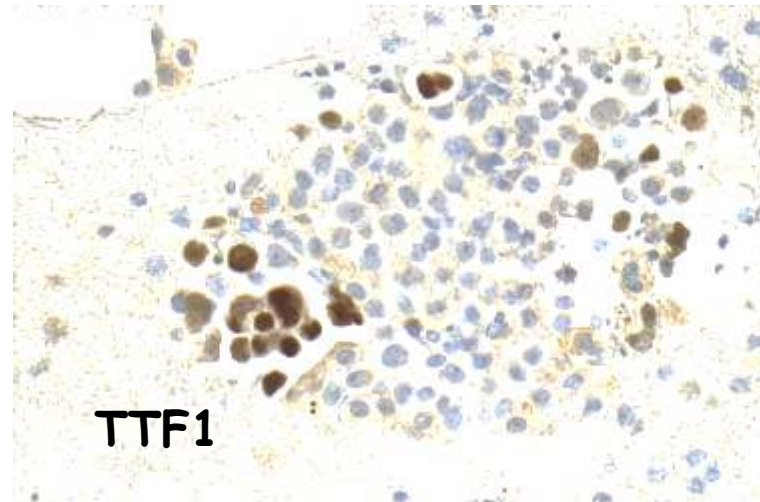
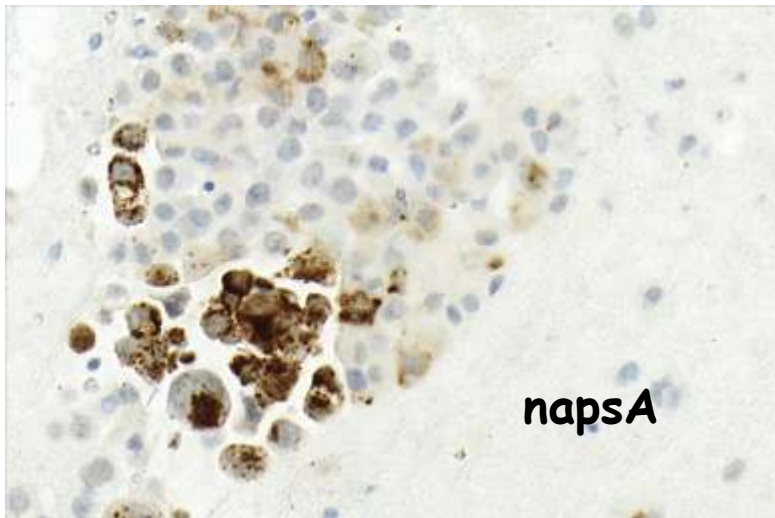
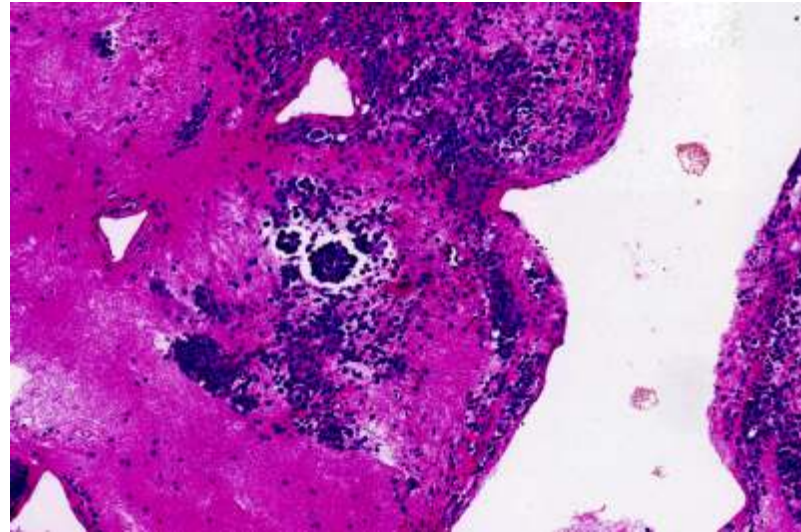


napsinA

Role of Napsin A and TTF1 as a diagnostic marker for lung adenocarcinoma. *Iqbal J. Arch Pathol Lab Med. 2013 Feb; 137(2):155.*



sejtblokk



Diff.dg.: Reaktív mesothel, mesothelioma és adenocarcinoma

E cadherin + : mesothelioma és adenocarcinoma

- : reaktív mesothel

Desmin +: reaktív mesothel

-: carcinoma

Glut-1 +: carcinoma

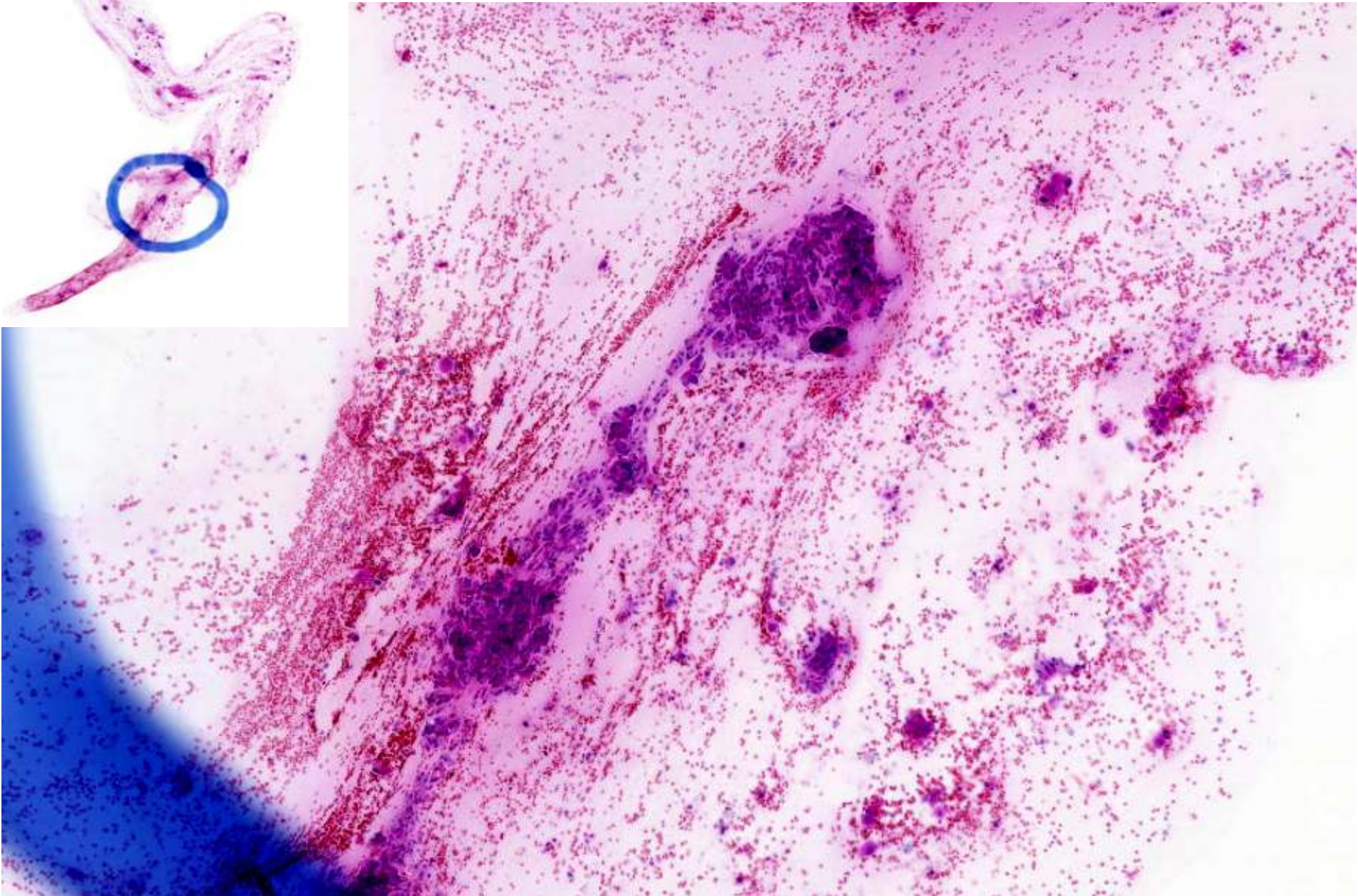
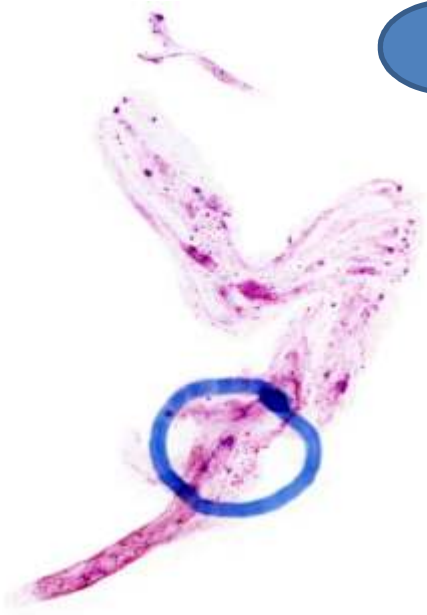-: reaktív mesothel

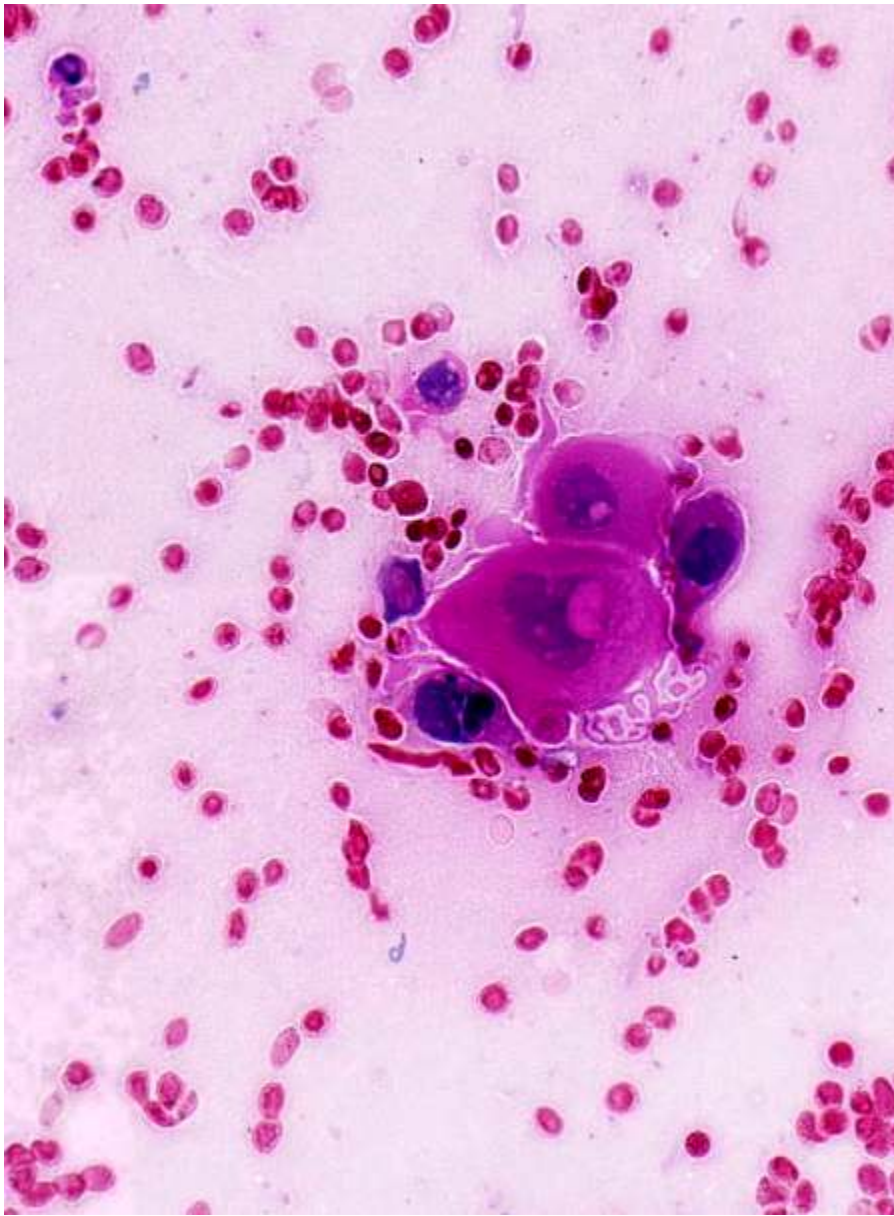| Sejttípus | E cadherin | Desmin | Glut-1 |
|------------------|------------|---------|---------|
| Reaktív mesothel | negatív | pozitív | negatív |
| Mesothelioma | pozitív | negatív | negatív |
| Adenocarcinoma | pozitív | negatív | pozitív |

Afify A, Zhou H, Howell L and Paulino AF. Diagnostic utility of GLUT-1 expression in cytologic evaluation of serous fluids. Acta Cytol 2005; 49: 621-626.

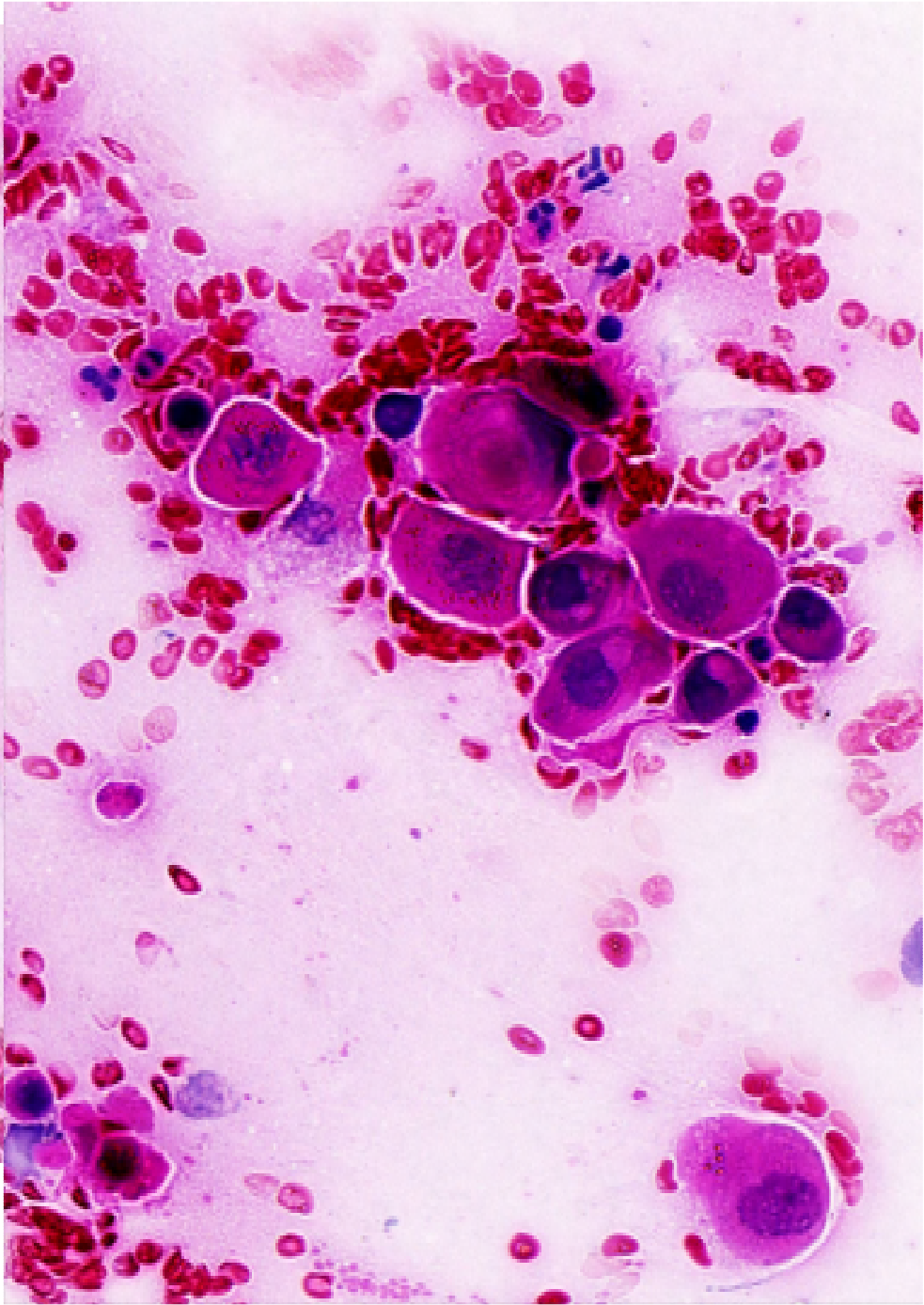
A háttér.....

1.

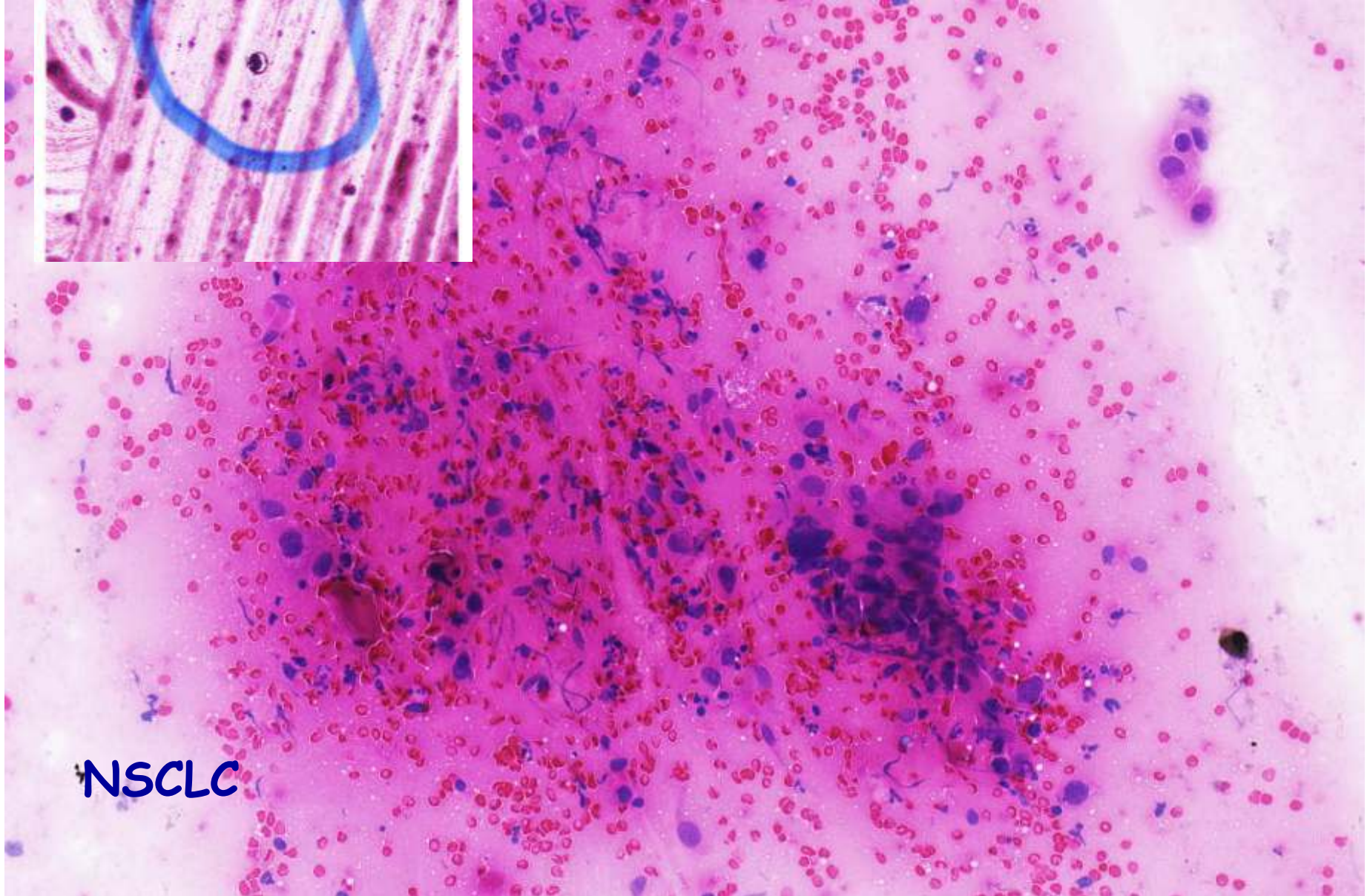
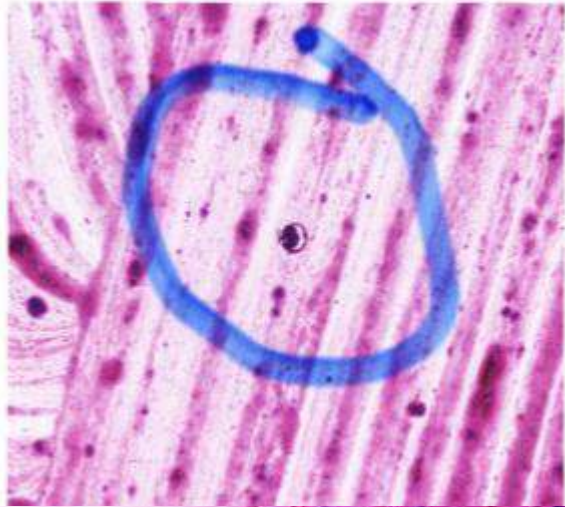




SCC

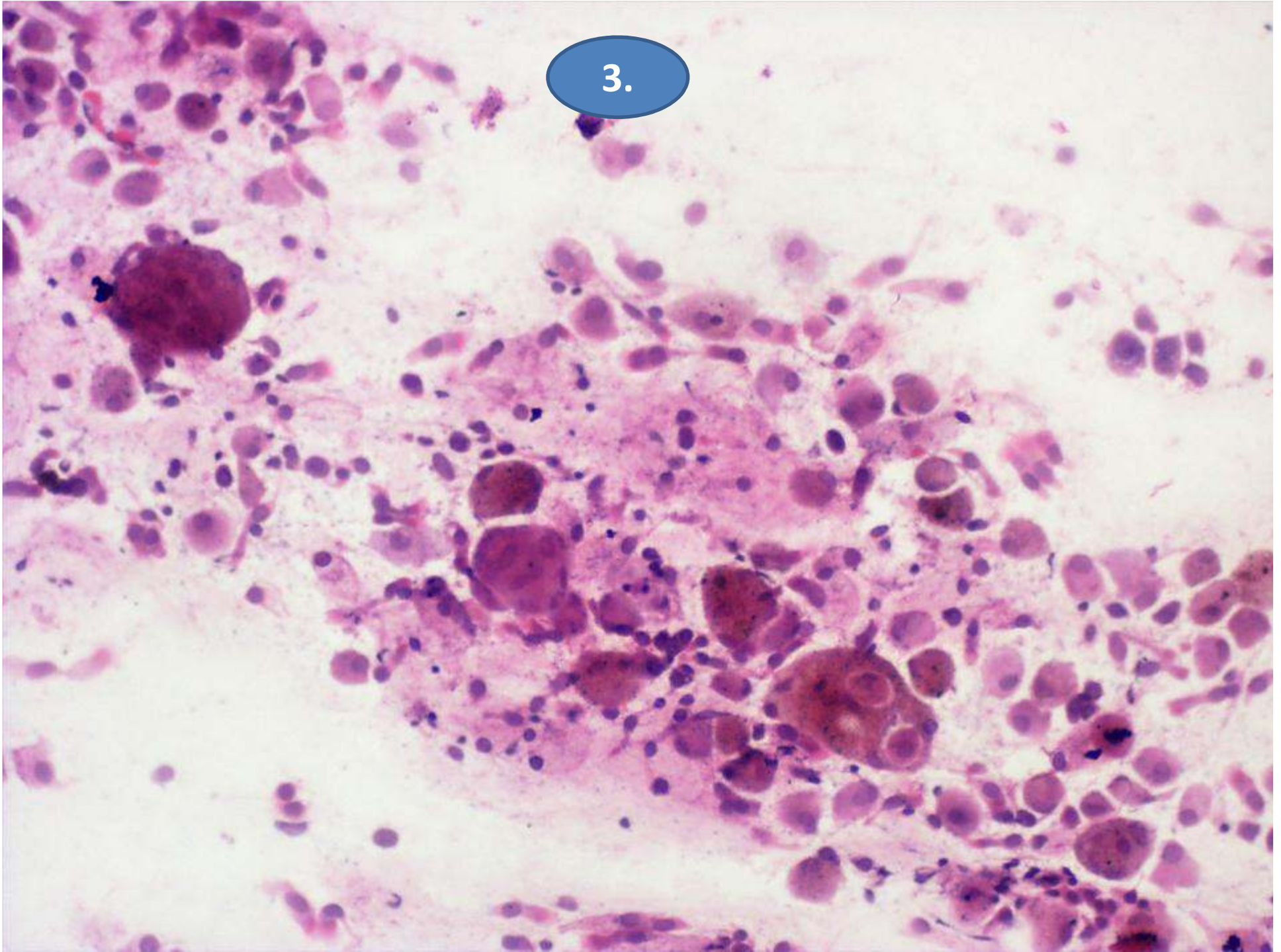


2.

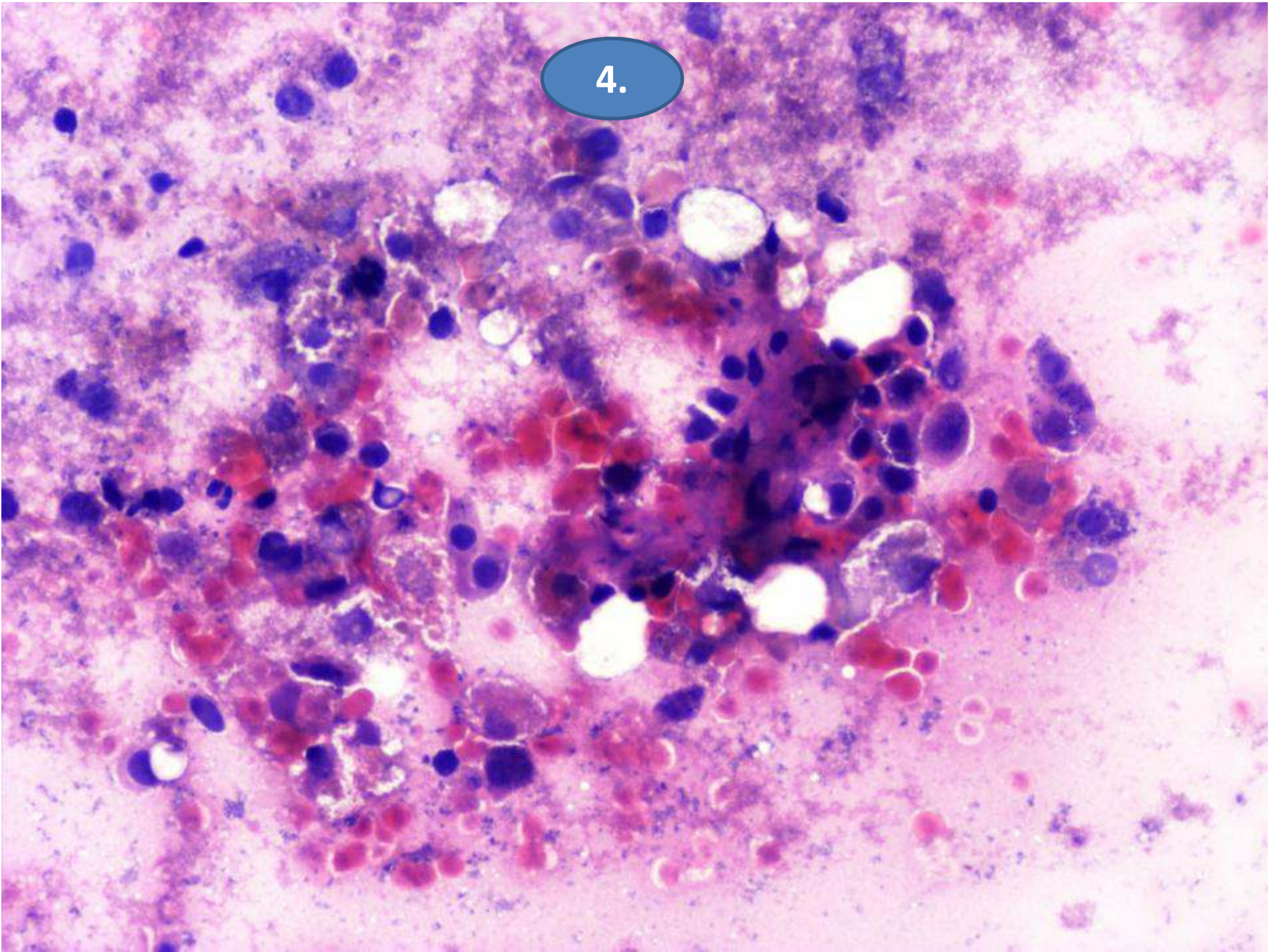


NSCLC

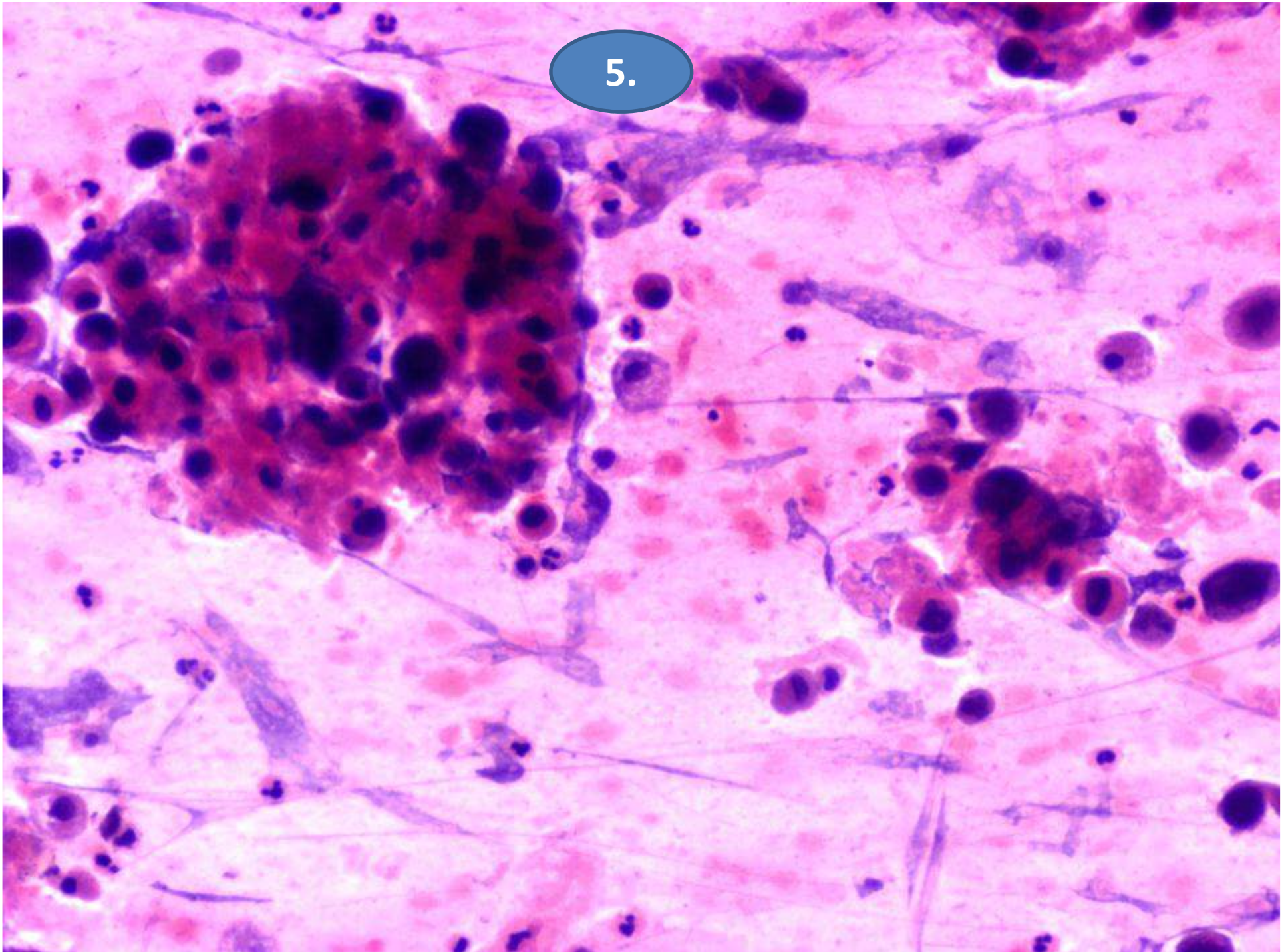
3.



4.

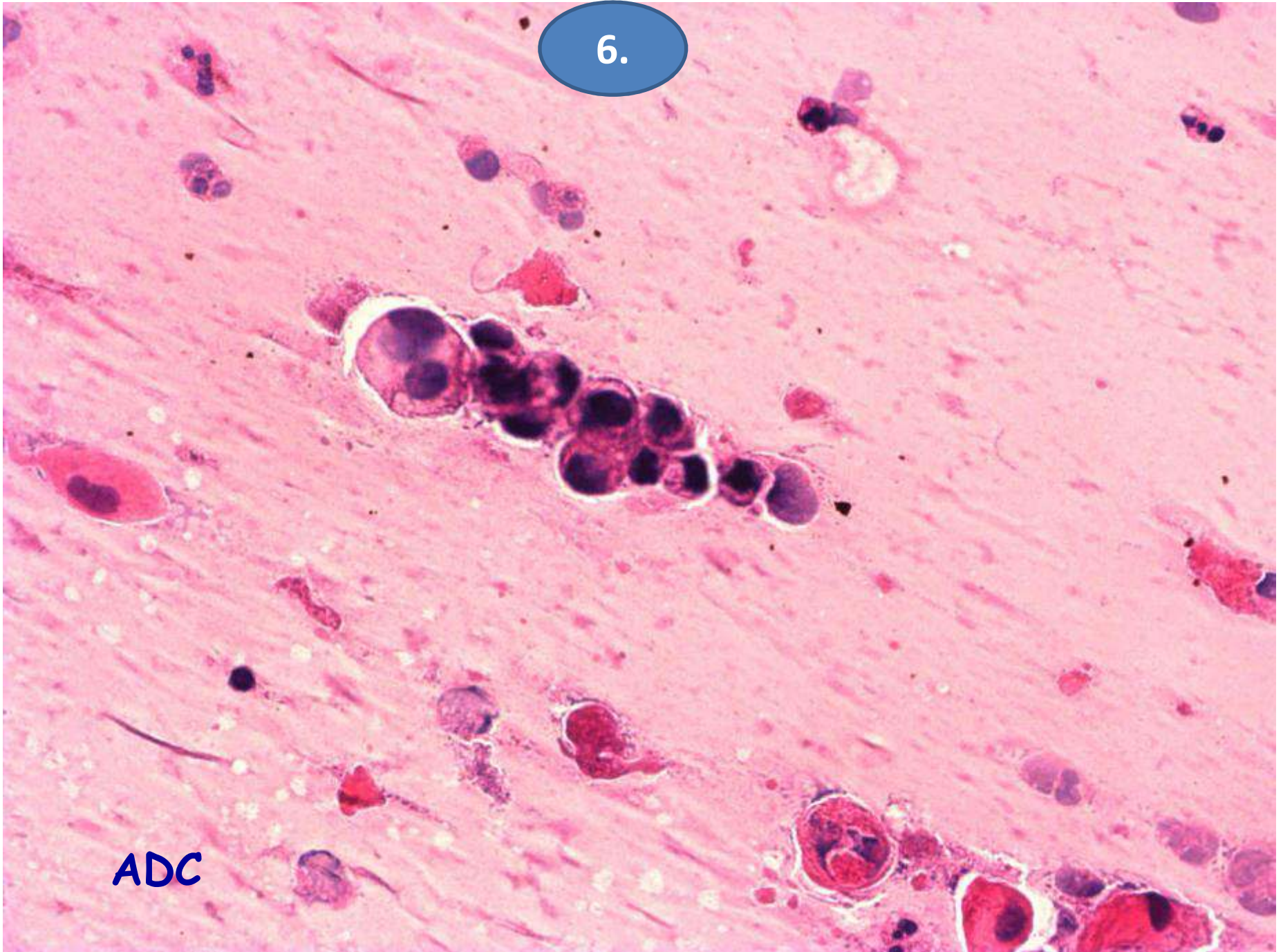


5.



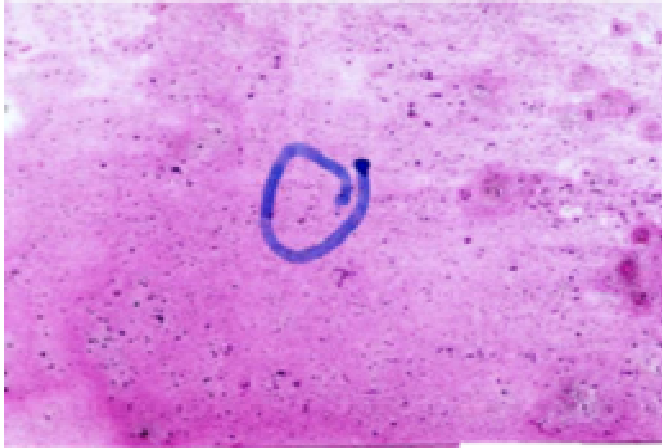
6.

ADC

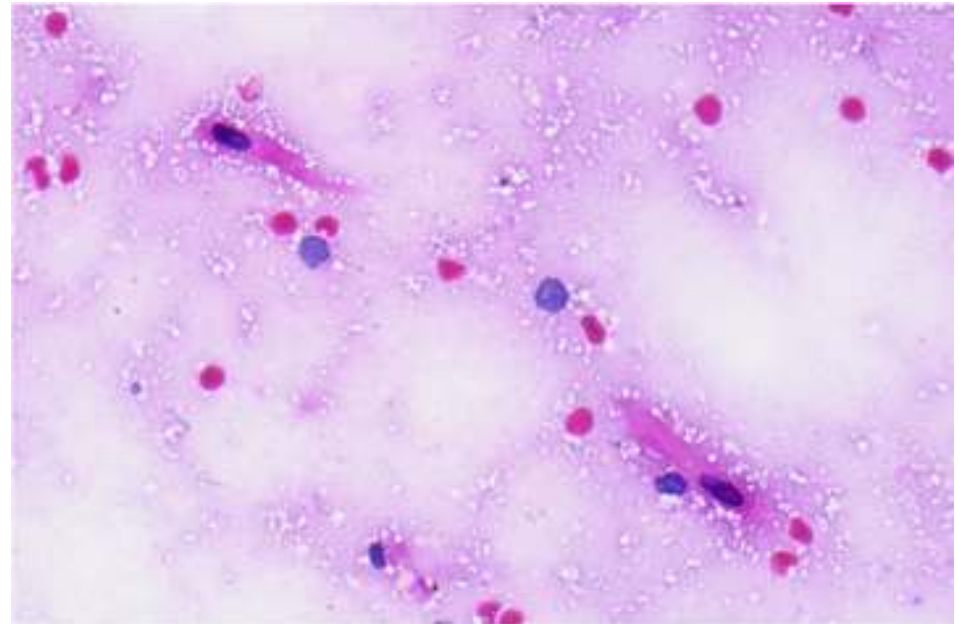
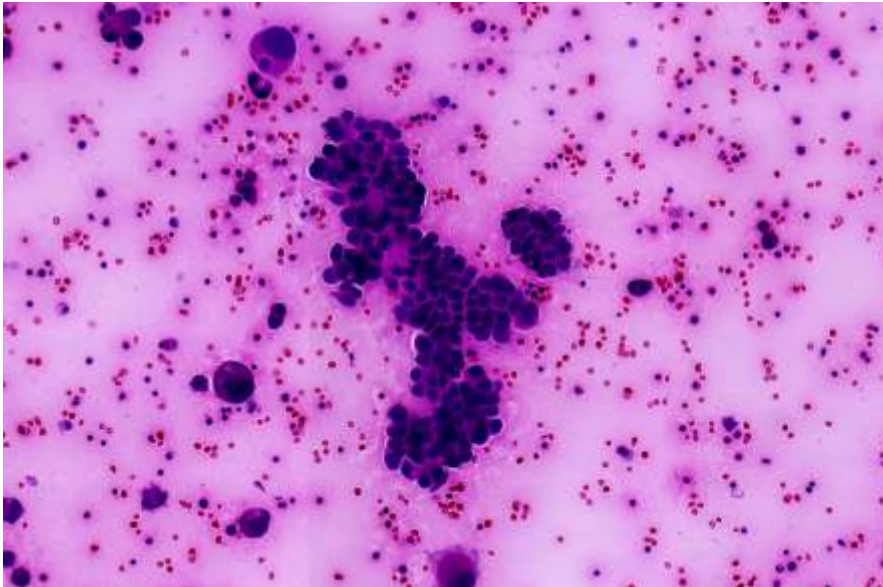
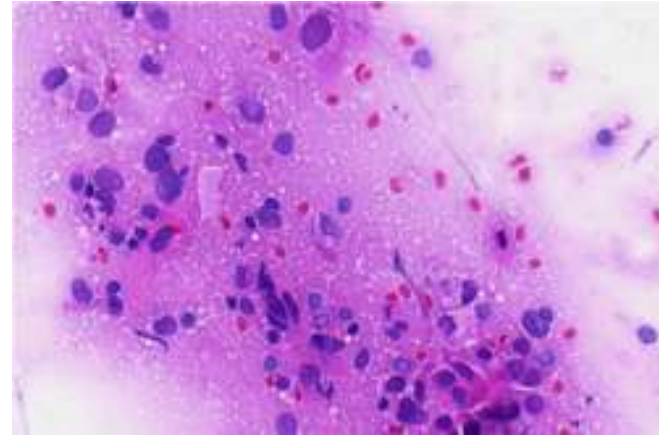


**De nem a háttér dönti el a
diagnózist!**

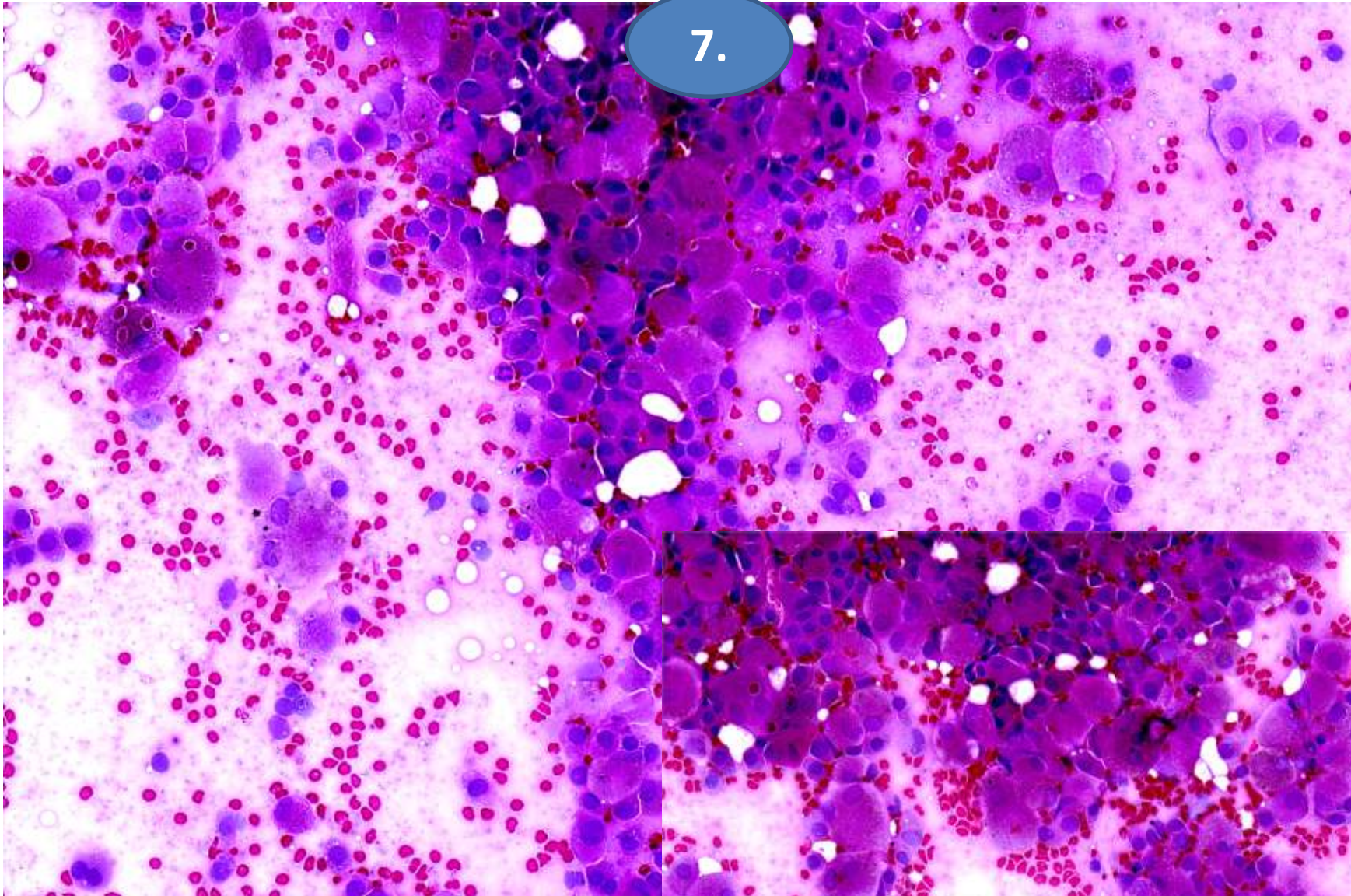
ADC



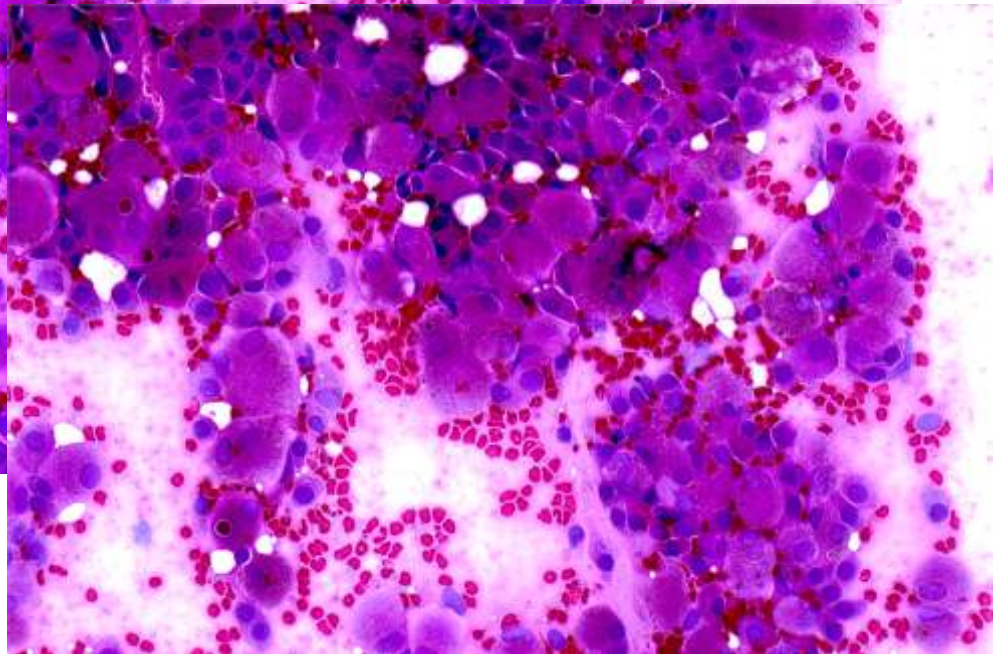
SCC

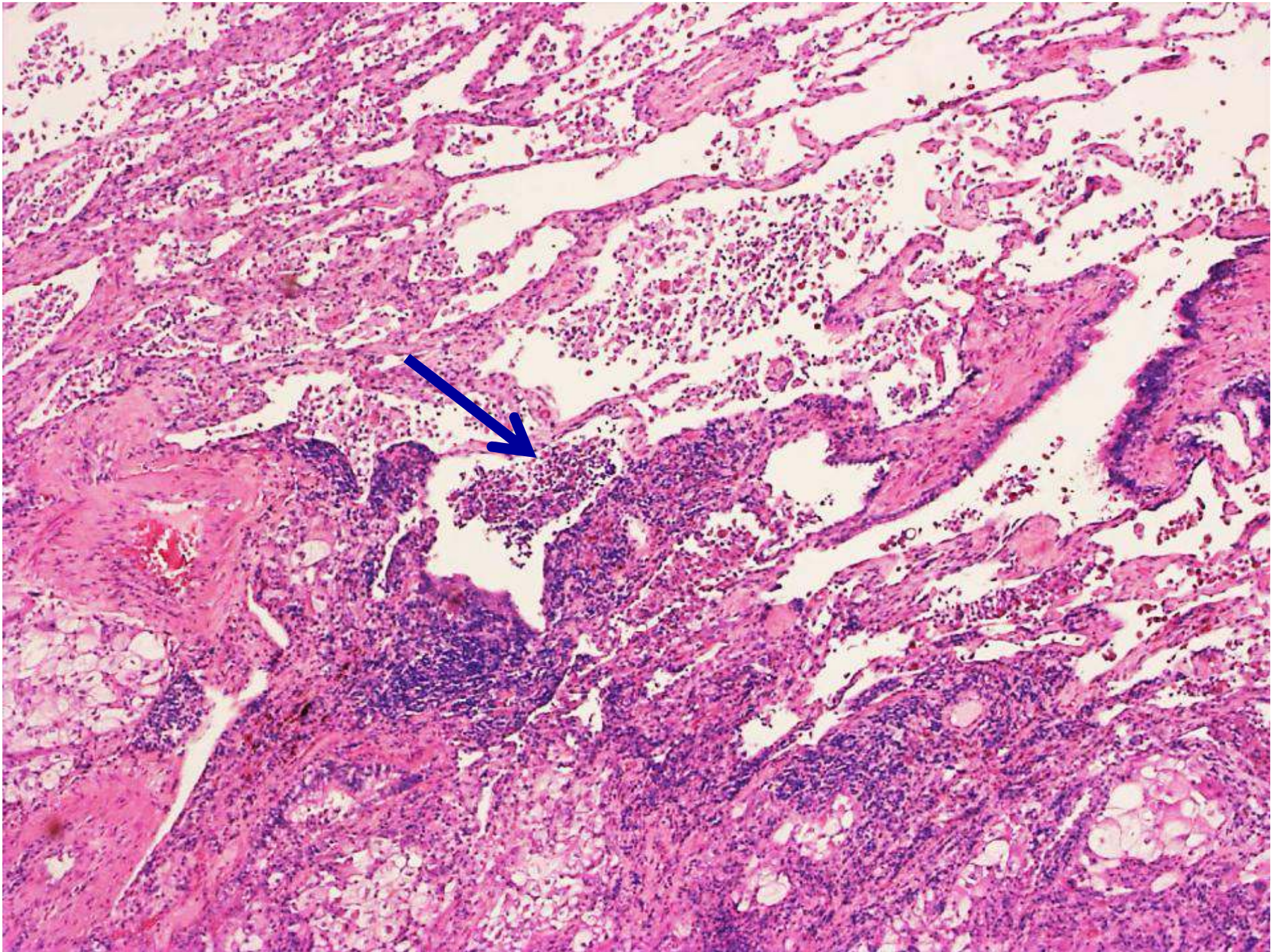


7.



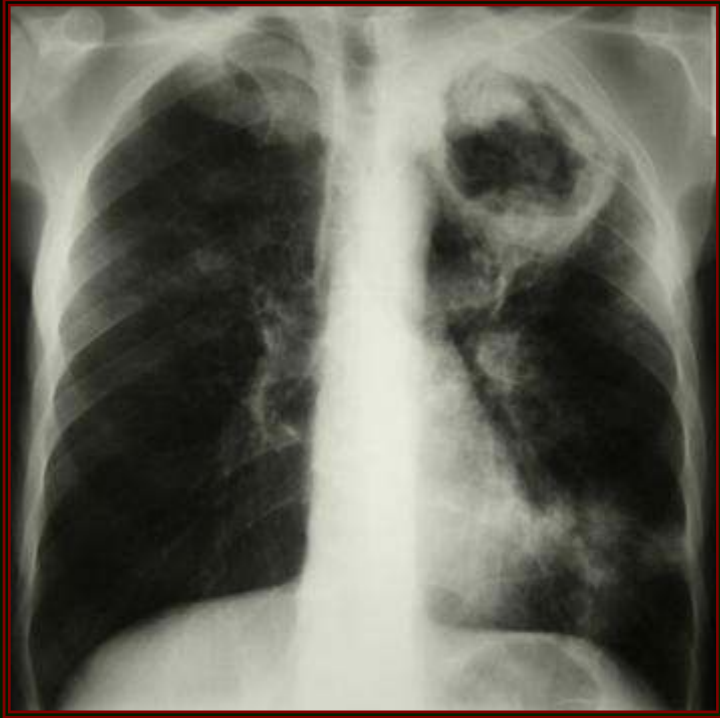„perifocalis“ TTP



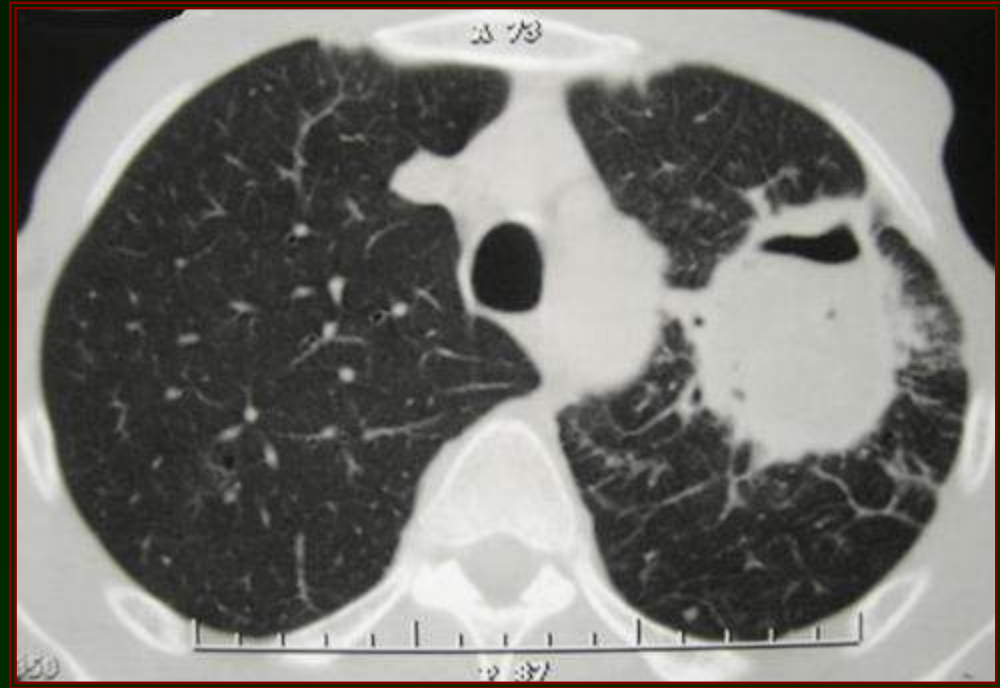


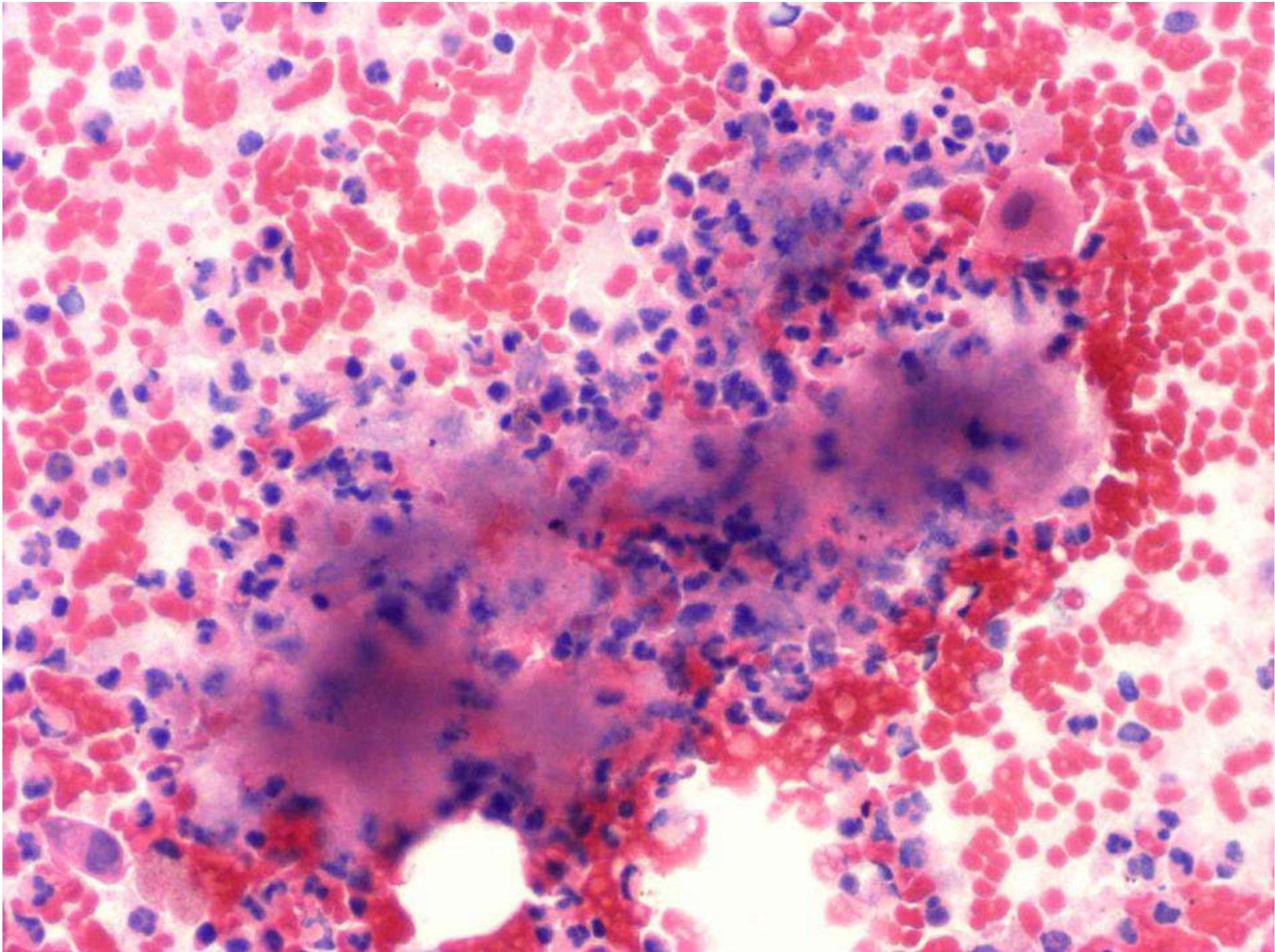
Más...

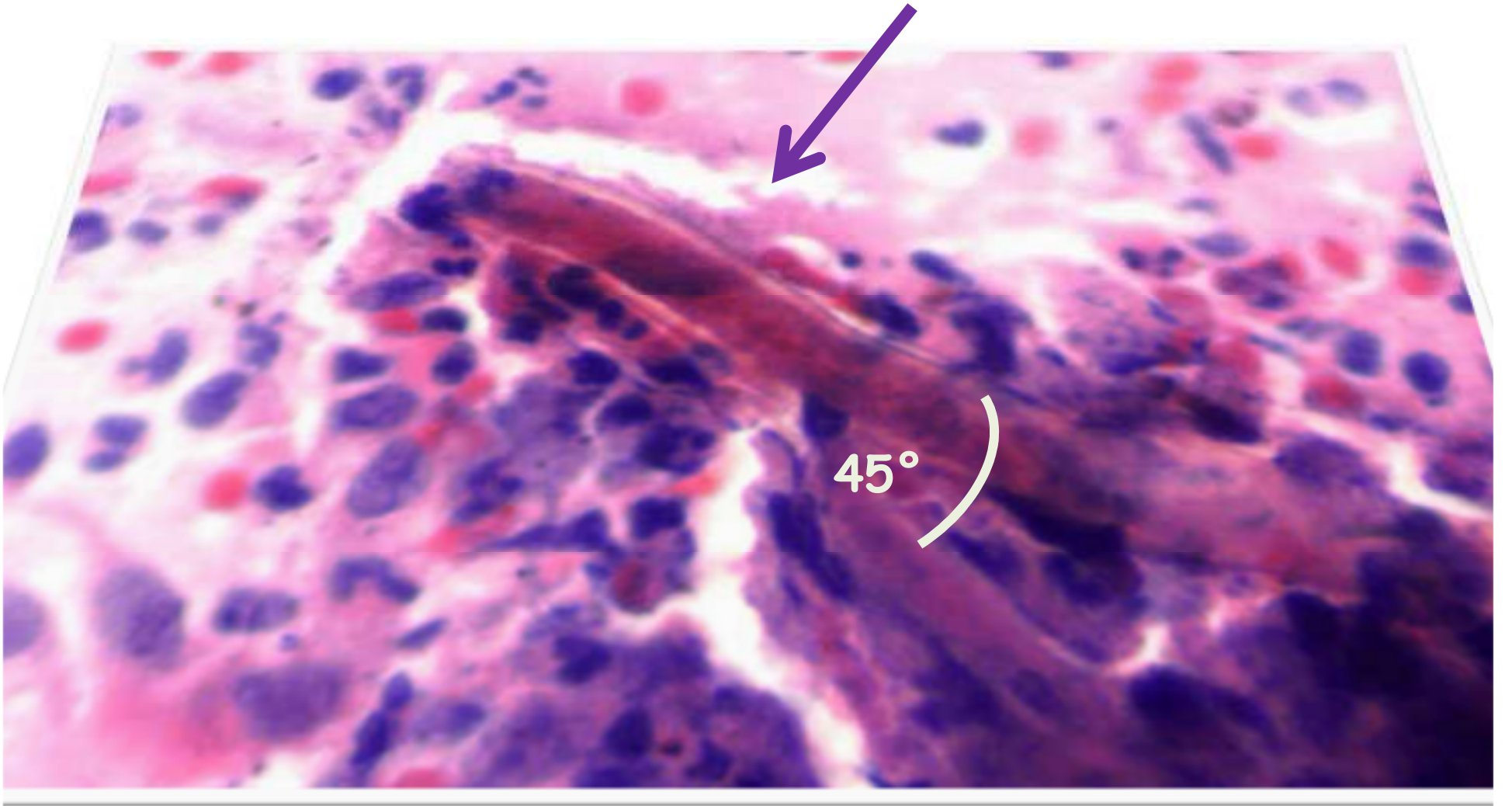
1. Mellkas RTG

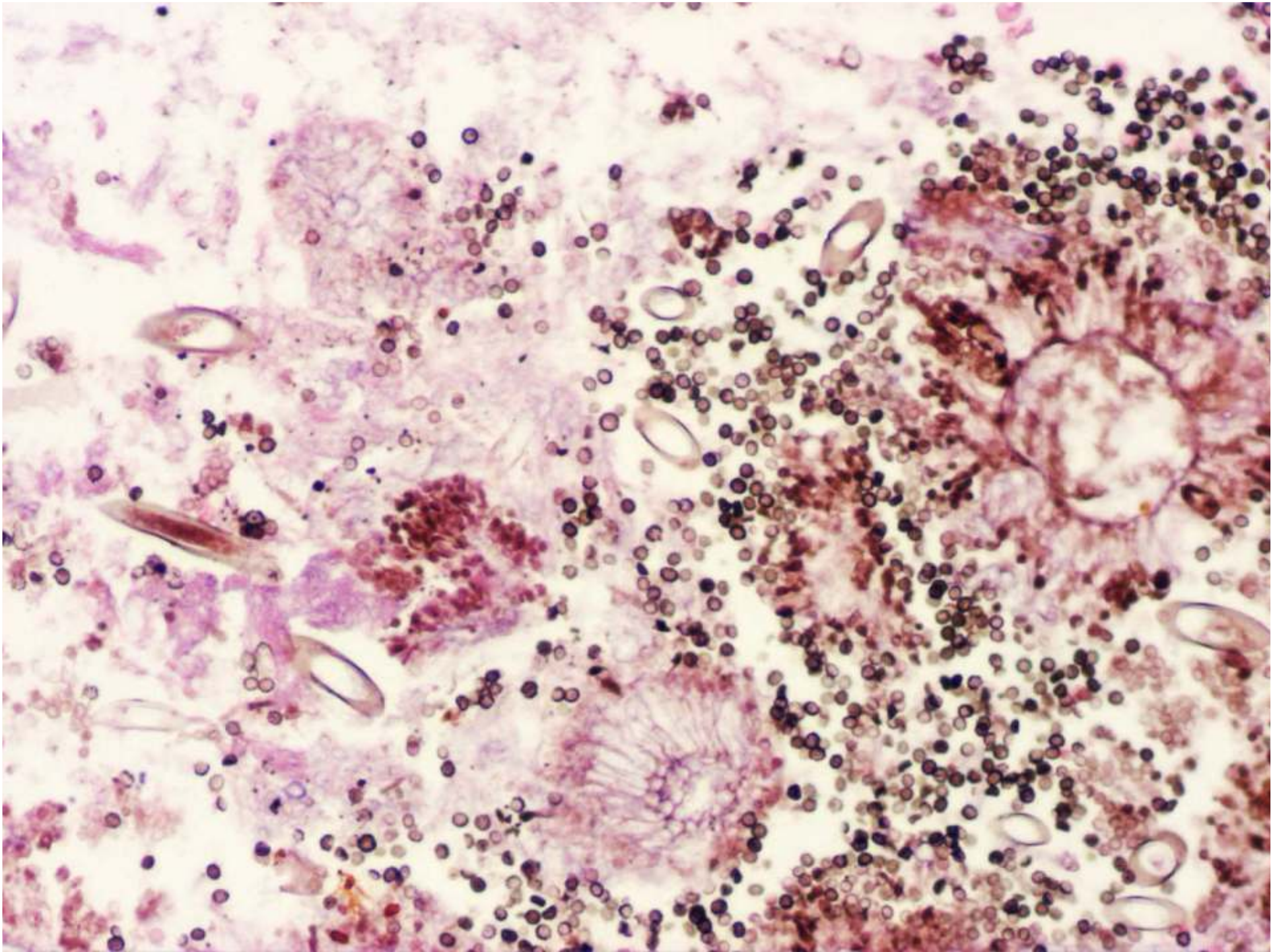


Mellkas CT



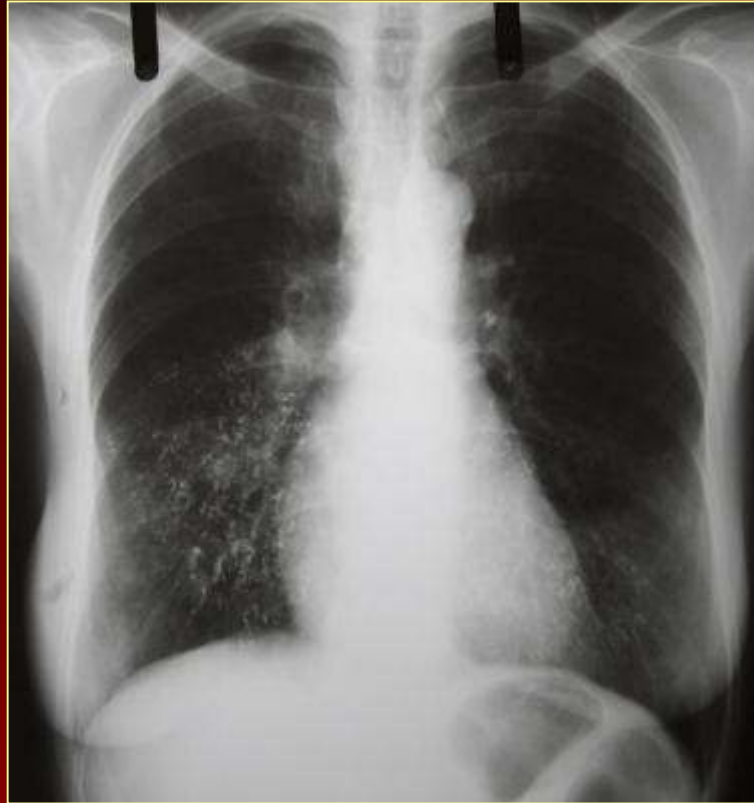



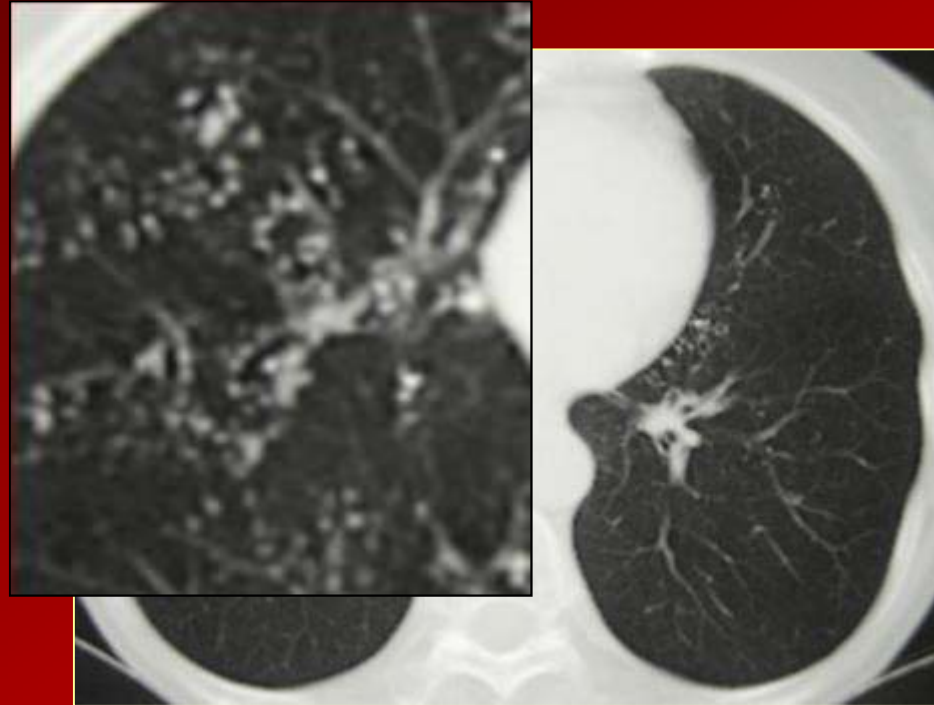


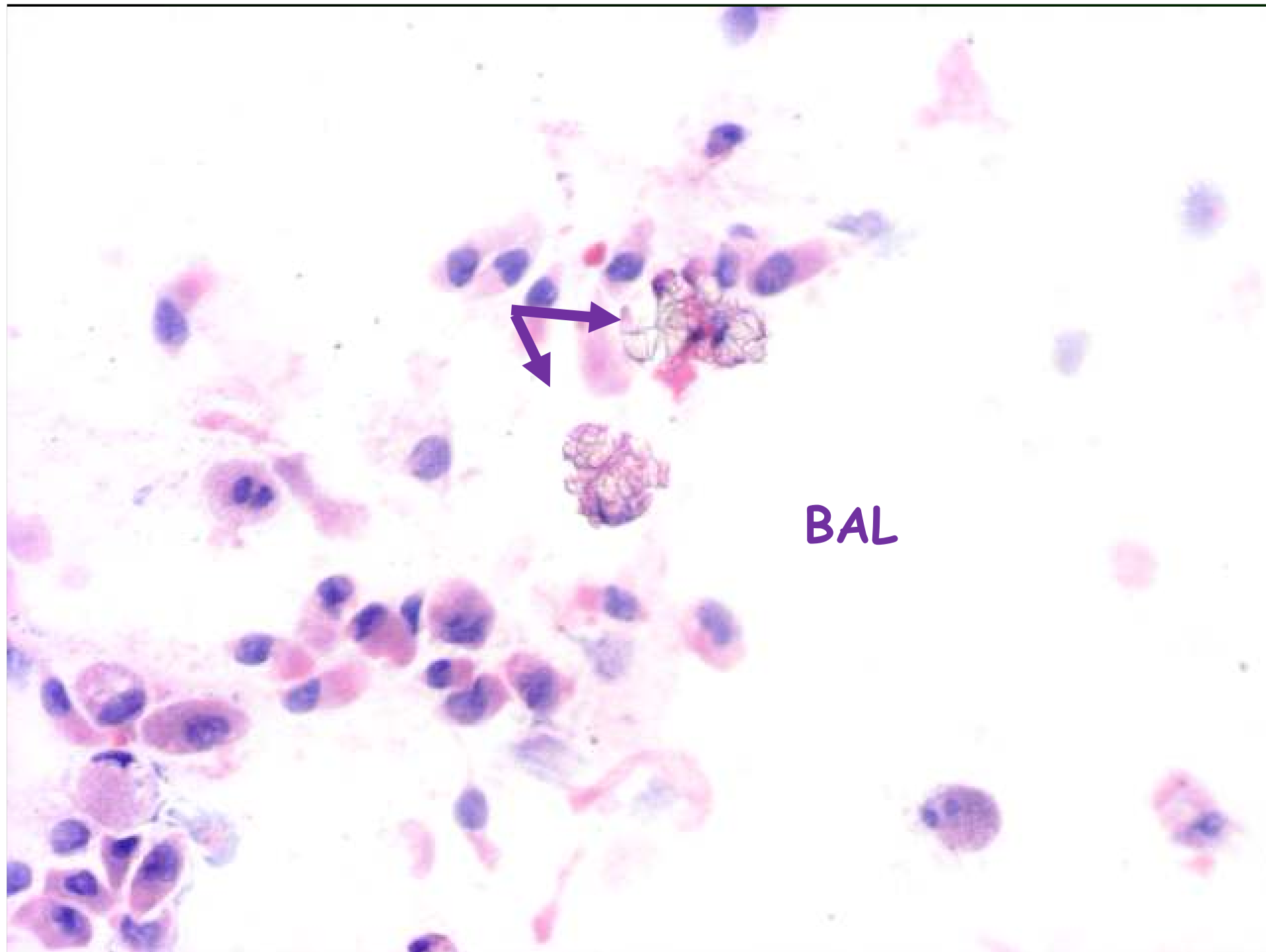
2.

Mellkas RTG

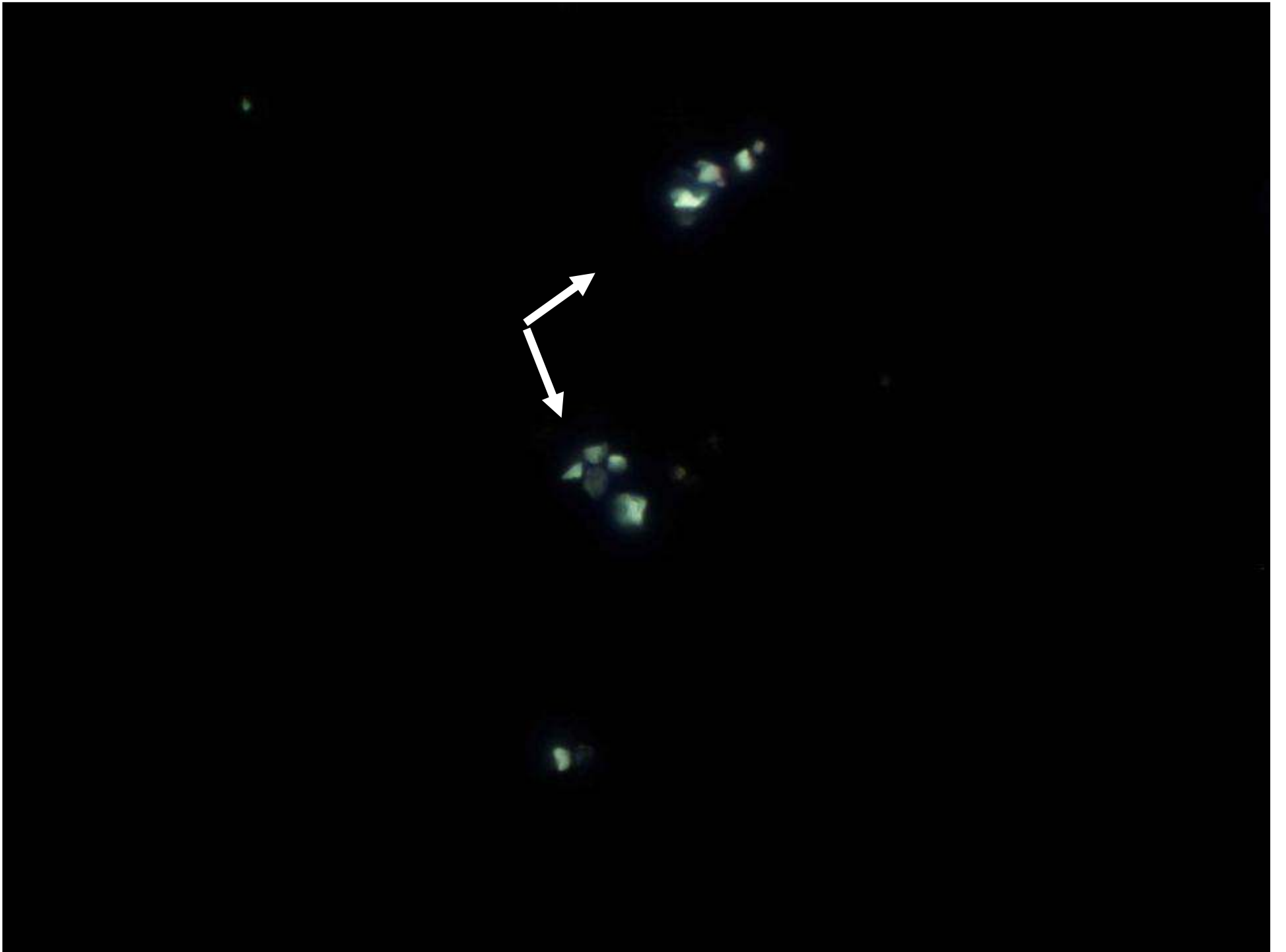


Mellkas CT

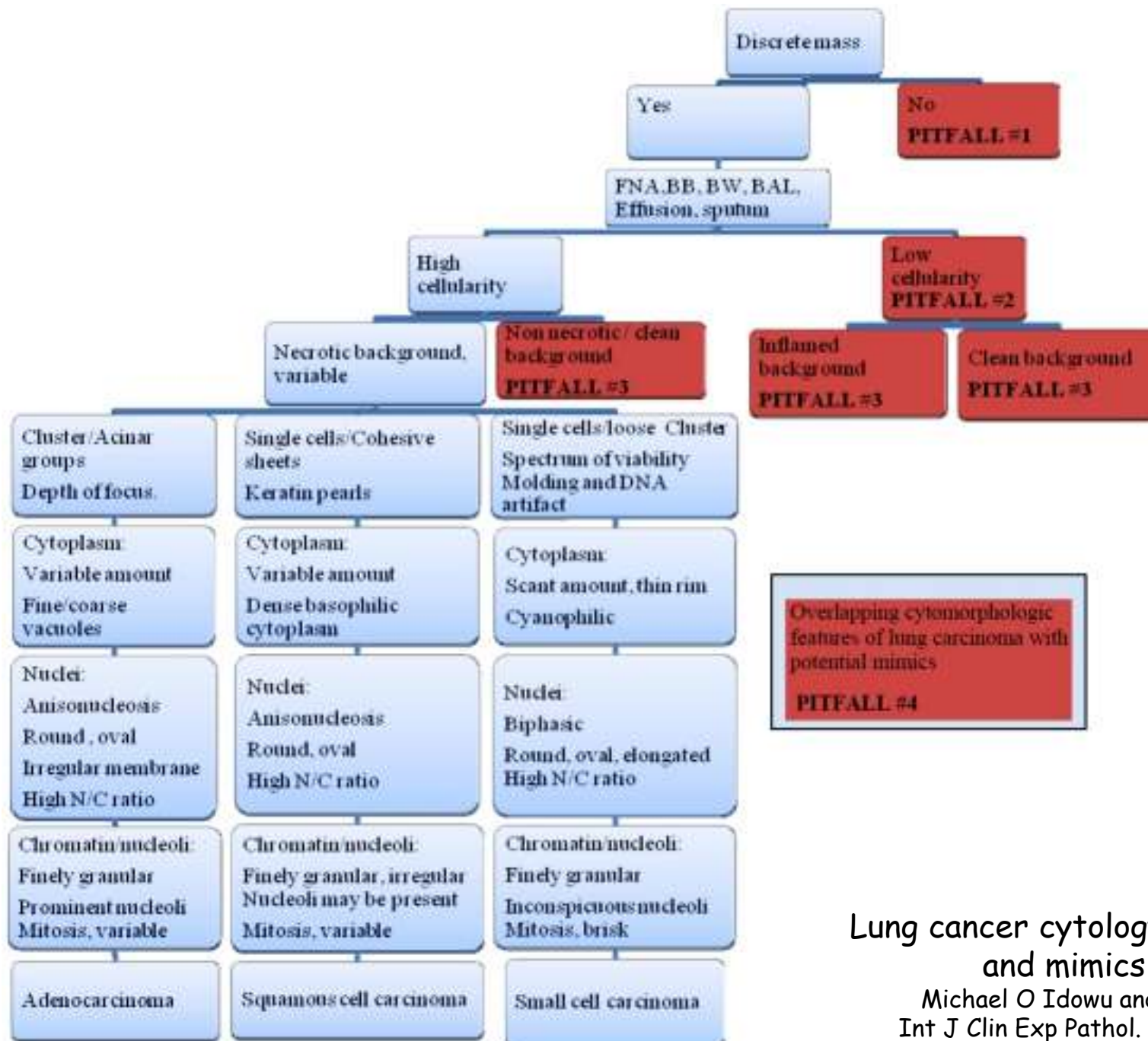




BAL



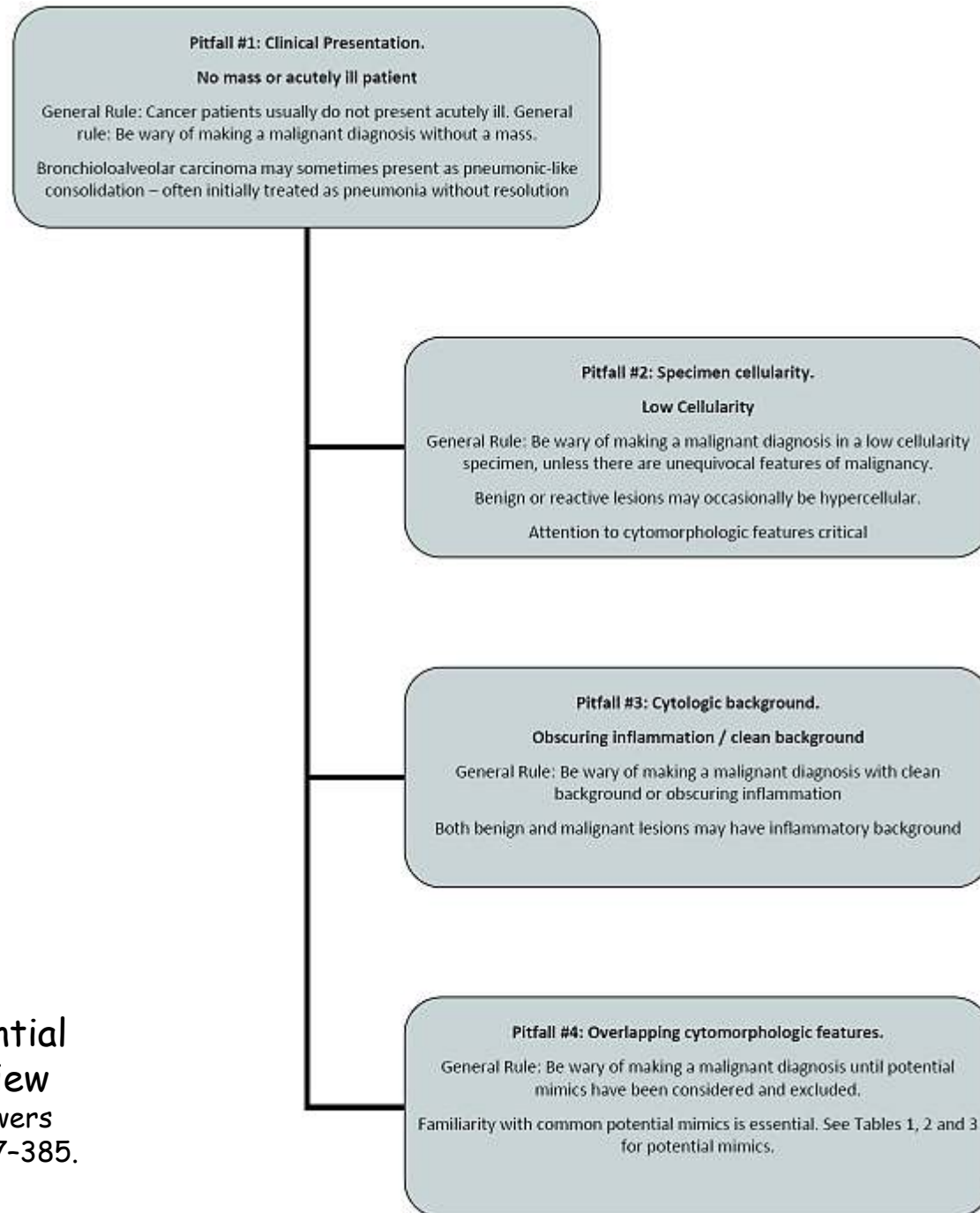
Összefoglalva, tehát...



Lung cancer cytology: potential pitfalls and mimics - a review

Michael O Idowu and Celeste N Powers
Int J Clin Exp Pathol. 2010; 3(4): 367-385.

Lung cancer cytology: potential pitfalls and mimics - a review
Michael O Idowu and Celeste N Powers
Int J Clin Exp Pathol. 2010; 3(4): 367-385.



Lung cancer cytology: potential pitfalls and mimics - a review

Michael O Idowu and Celeste N Powers
Int J Clin Exp Pathol. 2010; 3(4): 367-385.

(nyomán)

Klinikai prezentáció

A daganatos beteg ritkán lesz „hirtelen” beteg.
A BAC tumor gyakran pneumonia képében jelenik meg.

1. buktató

A minta cellularitása

Sejtszegény kenet

Óvatosan adjunk pozitív leletet sejtszegény kenet alapján!
Benignus és reaktív elváltozások is lehetnek sejtűsok.

2. buktató

Sejtes háttér

Feltűnő gyulladás/tiszta háttér.
A jó és rosszindulatú elváltozások háttére egyaránt lehet lobos.

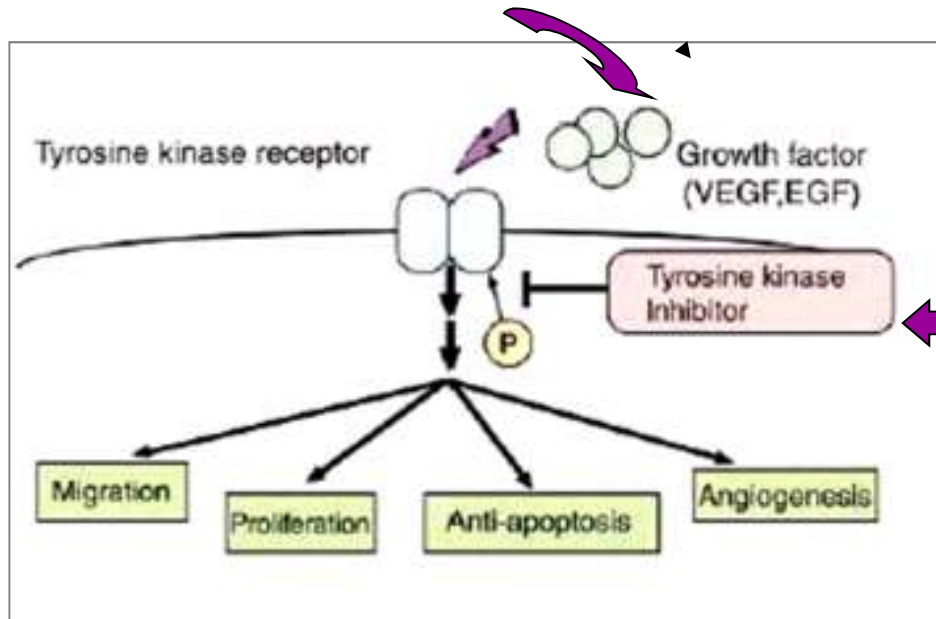
3. buktató

Átfedő cytomorfológiai jellegzetességek

Malignitás kimondása csak akkor, ha az utánzó elváltozás biztosan kizárható.

4. buktató

Molekulárisan célzott terápia alapja



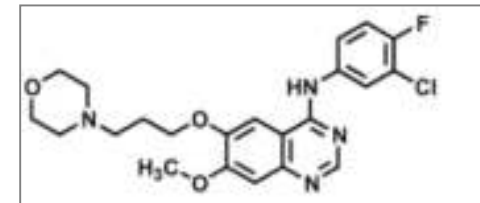
Michihiko Kuwano
Professor, Dean, Faculty of Medical Sciences

**EGFR gén kinázdoménjének aktiváló
mutációi fokozott érzékenységet jelentenek
az EGFR-TKI szerekkel szemben**

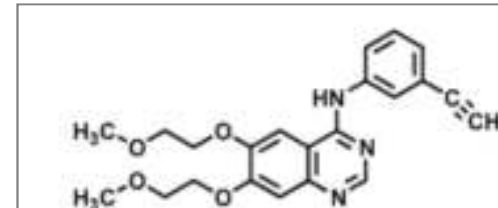
EGFR: Epidermal Growth Factor Receptor

TKI: Tyrosine Kinase Inhibitor

Gefitinib (Iressa™, ZD-1839)



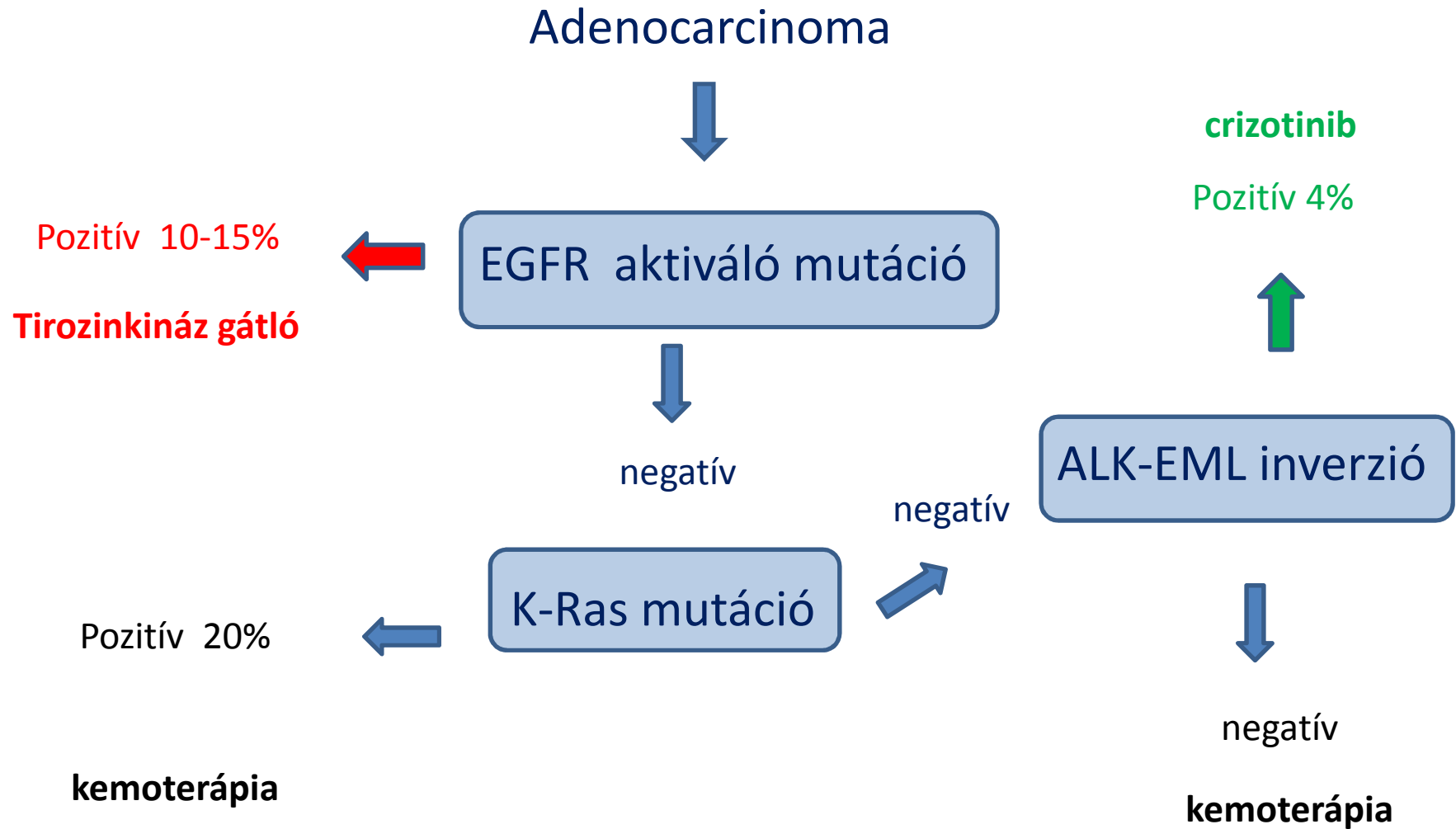
Erlotinib (Tarceva™, OSI-774)



**Kompetitív ATP
gátlás, foszforiláció
blokkolása**

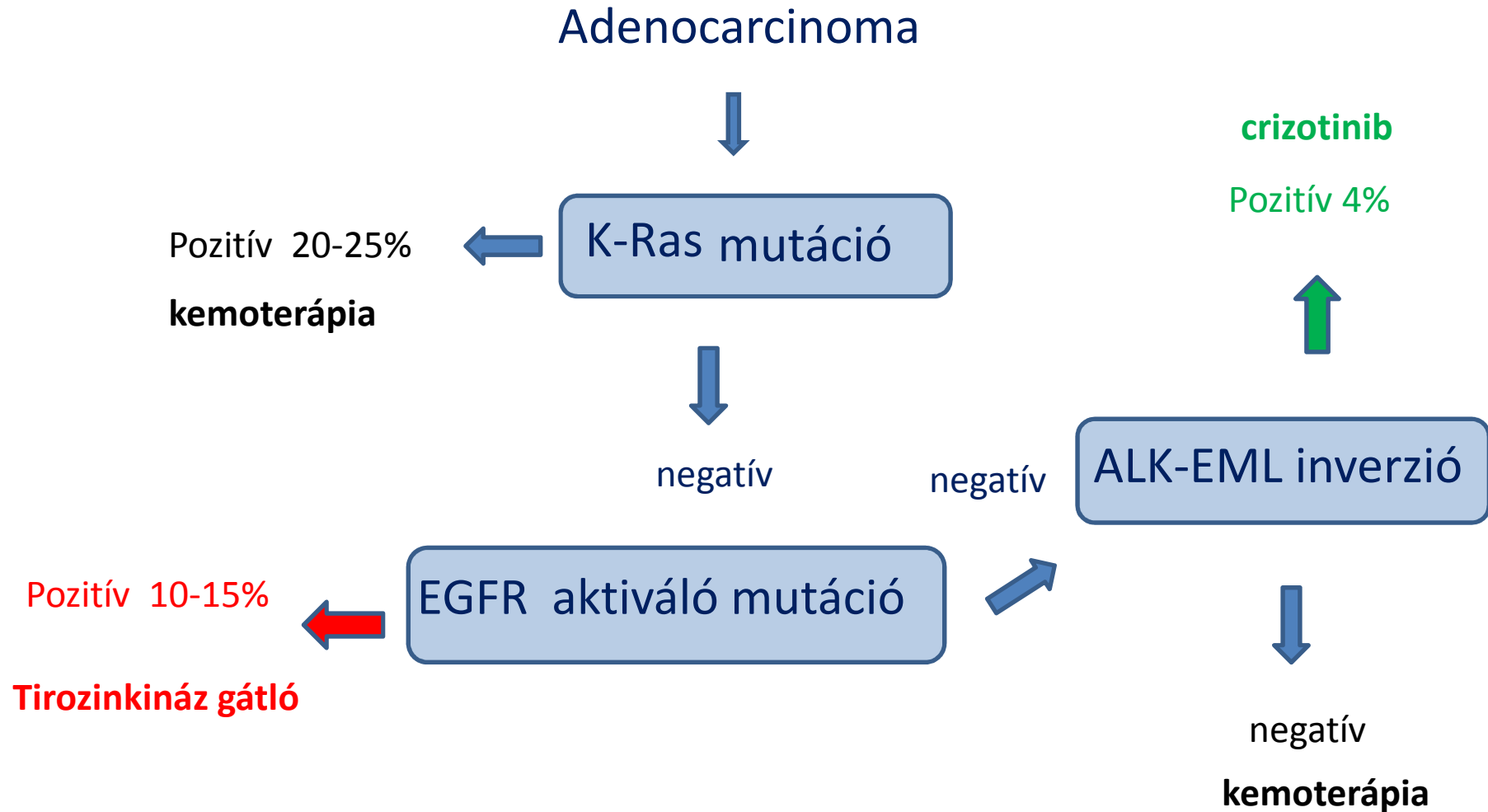
A MOLEKULÁRIS DIAGNOSZTIKA ALGORITMUSA

elsővonalú TK gátló kezelés szándéka esetén



A MOLEKULÁRIS DIAGNOSZTIKA ALGORITMUSA

TK gátló kezelés szándéka esetén



Köszönöm a
figyelmet!